

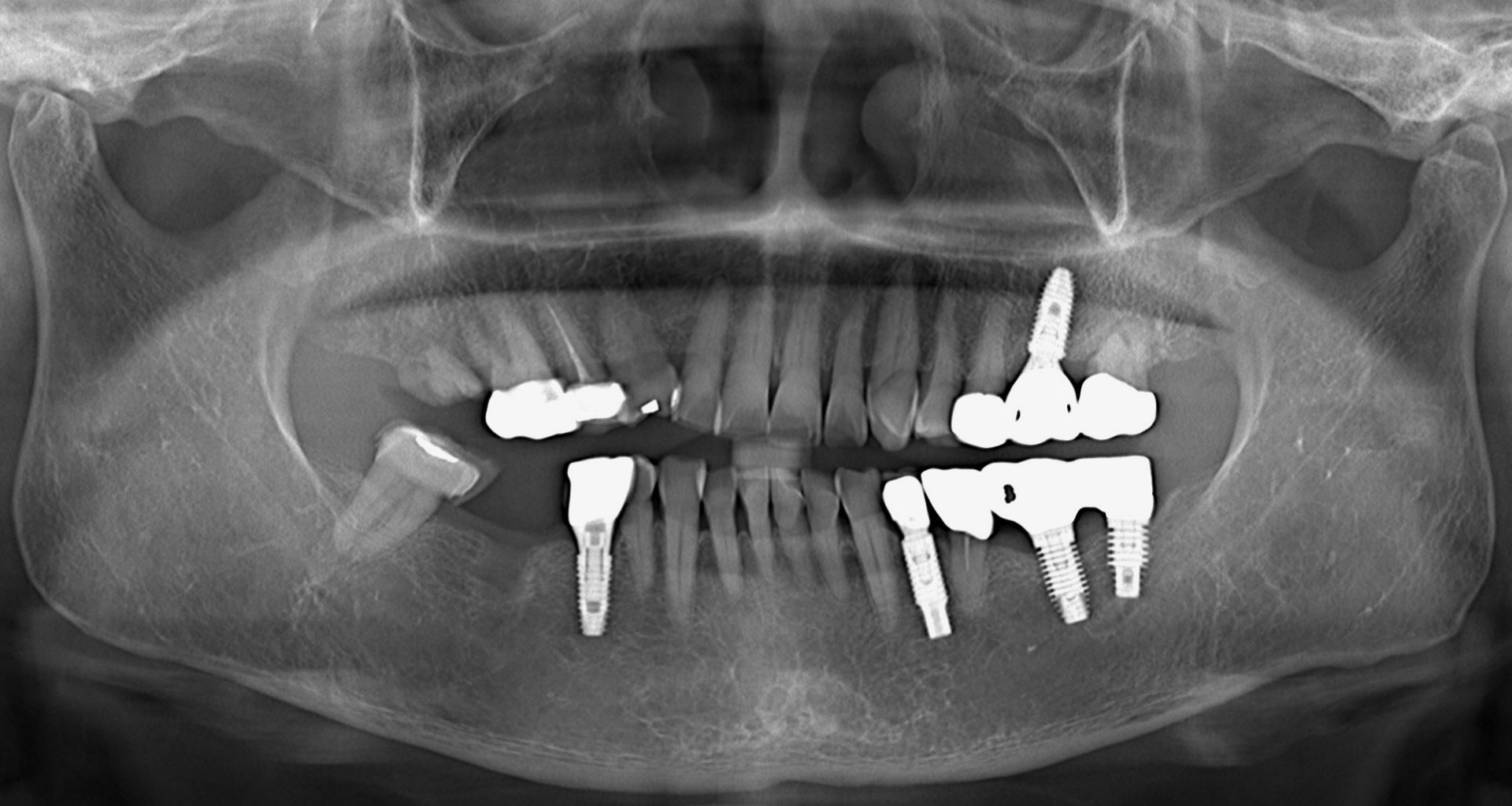Socket preservation & Implantation

(Bone Level, OSTEON™ 3, Collagen graft, Osteotome, Digital Guide(F))

65y/F

Dr.SM Chung

Pre-op (2019-03-27)



Pre-op (2019-03-27)




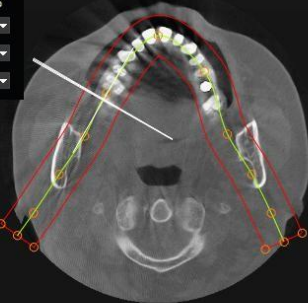

rainbow 3D Viewer

IMPLANT MPR Cross Report

Curve Info
W 80mm
I 0.5mm
T 0.0mm

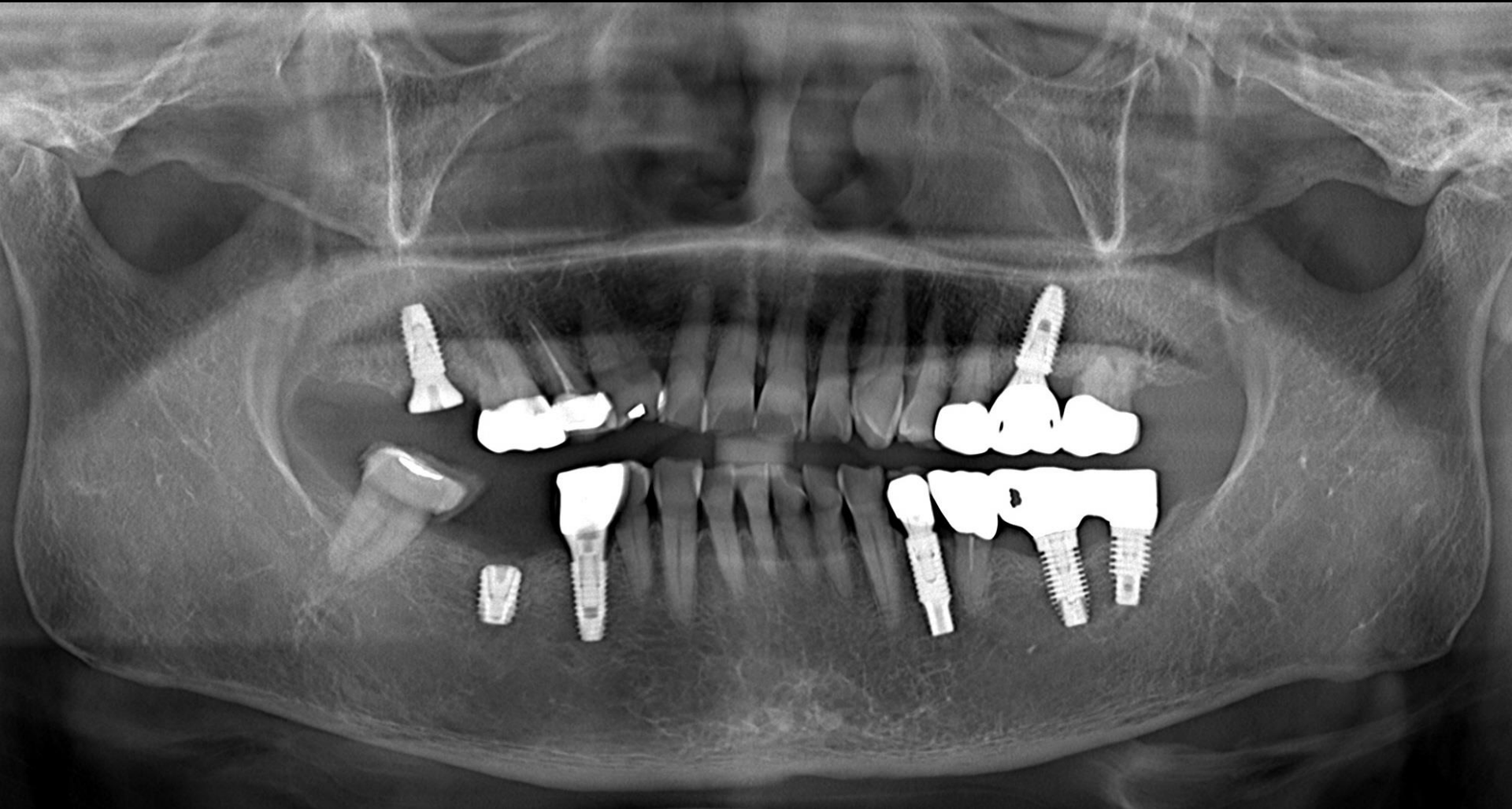
김민지
FEMALE
19530215
65
8 [mA]
94 [KVP]
CT

Nerve Info
R 1.0mm

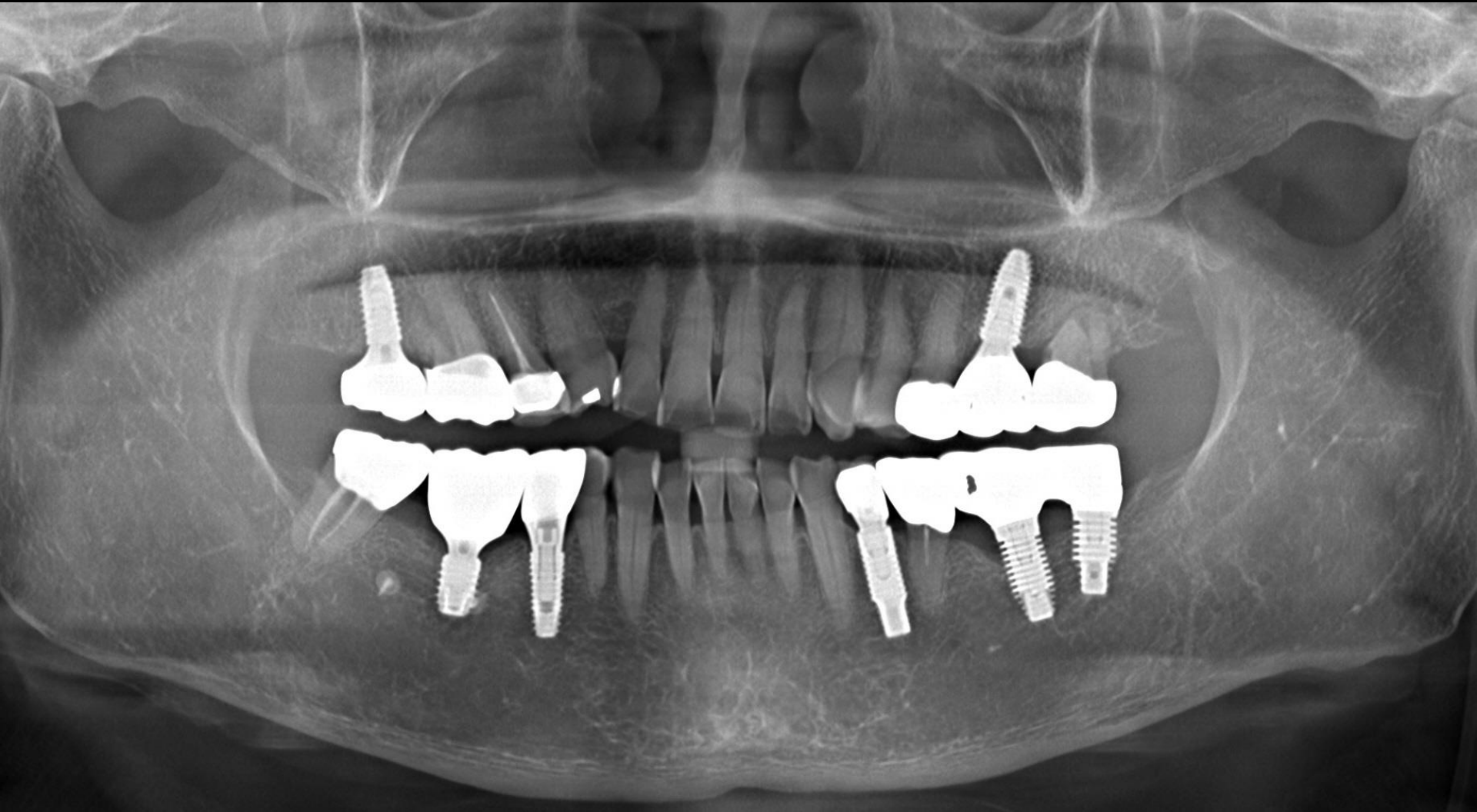


3D Viewer interface showing a 3D model of a human skull with a red wireframe implant plan overlaid on the teeth. The interface includes a top toolbar with icons for file operations and a 'rainbow 3D Viewer' title. A left sidebar contains navigation tabs: IMPLANT, MPR, Cross, and Report. A 'Curve Info' panel shows parameters: W 80mm, I 0.5mm, T 0.0mm. A patient information panel on the right lists: 김민지, FEMALE, 19530215, 65, 8 [mA], 94 [KVP], CT. A 'Nerve Info' panel at the bottom left shows R 1.0mm. The main view is divided into several panels: a large 3D skull model, an axial CT scan with red and green curves, a sagittal CT scan, a panoramic CT scan, and three sagittal CT scans. A 3D coordinate system is visible in the center-right. The bottom right corner features the Dentium logo and 'For Dentists by Dentists'.

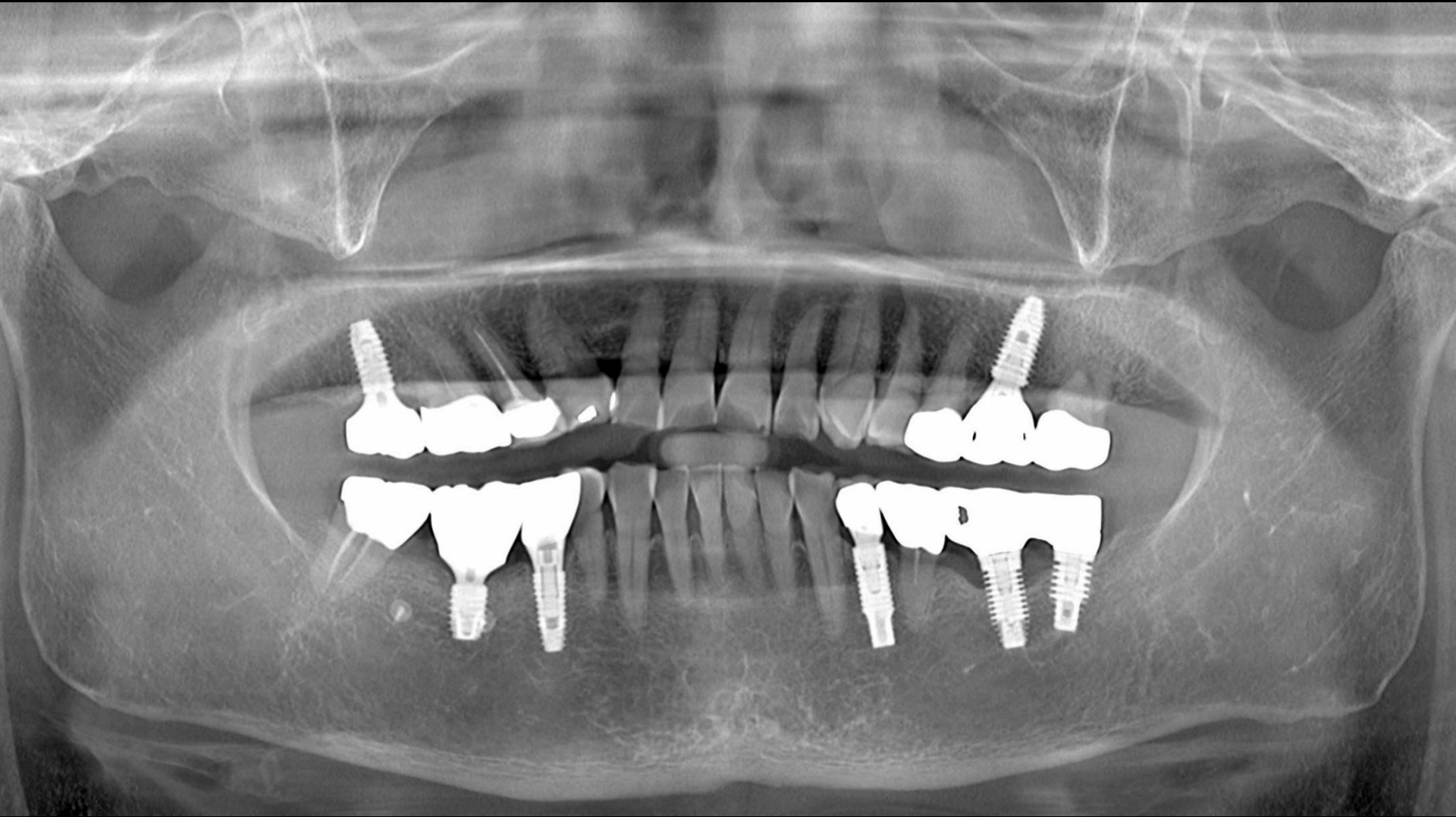
Post-op (2019-04-11)



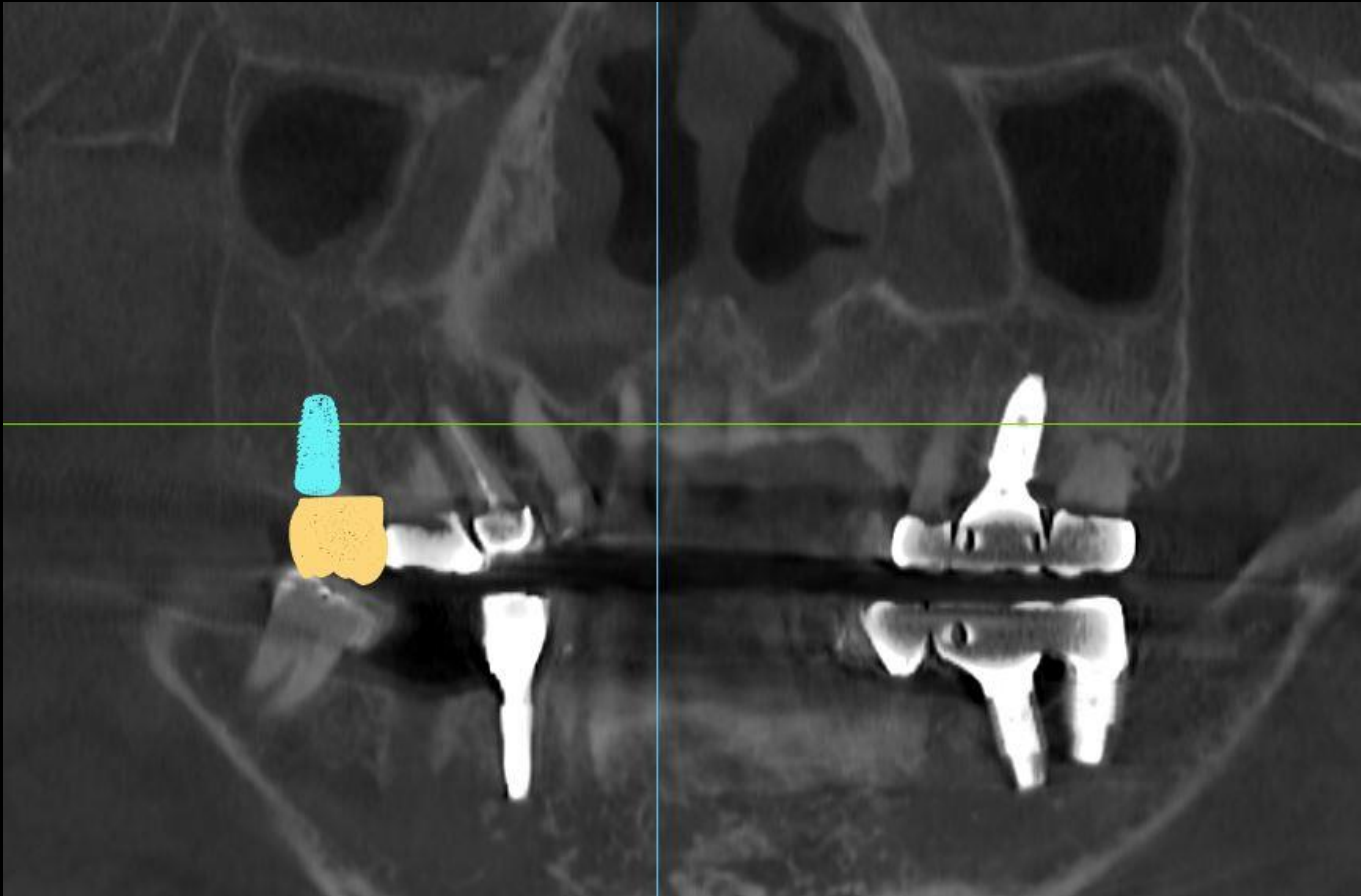
Final prosthesis (2019-12-19)



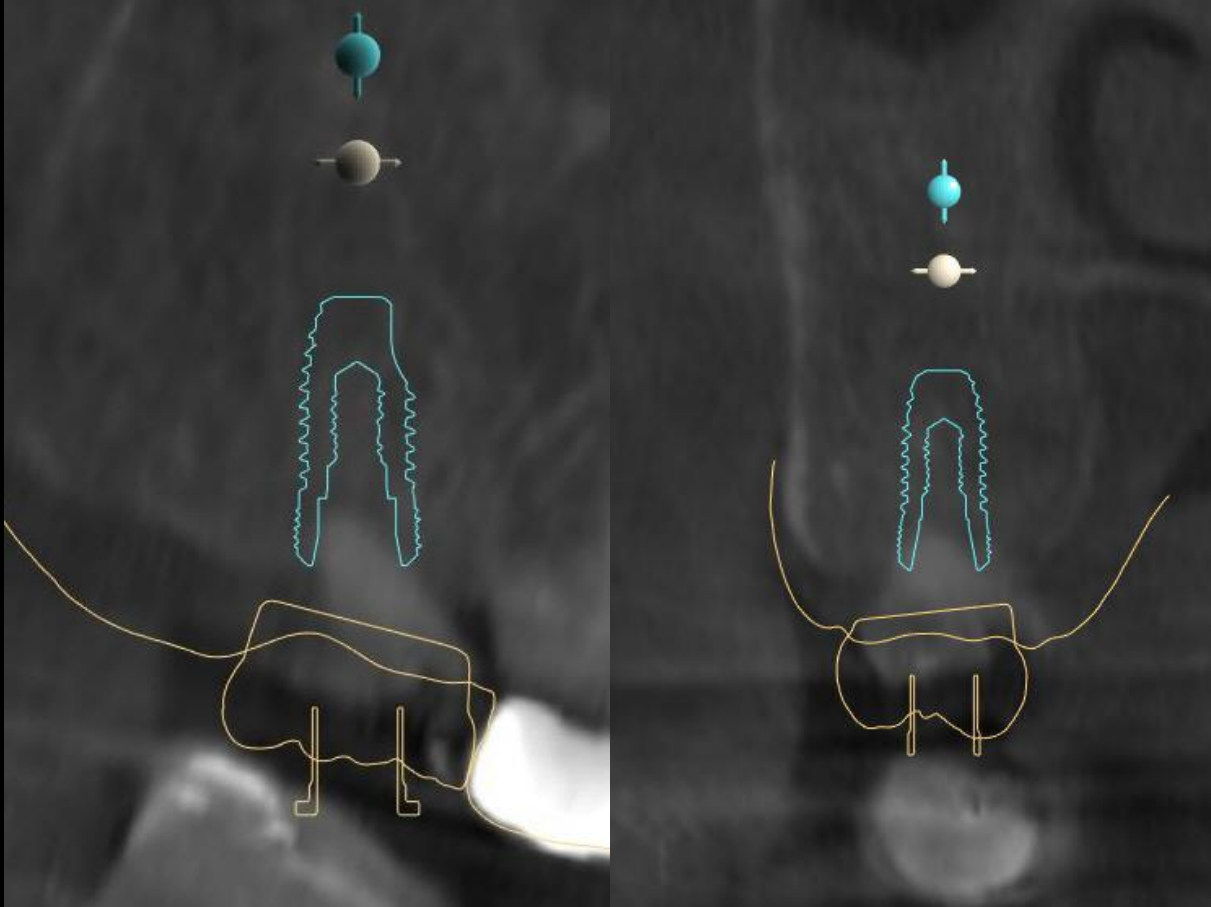
Follow up : 1 year 1 months (2021-01-05)



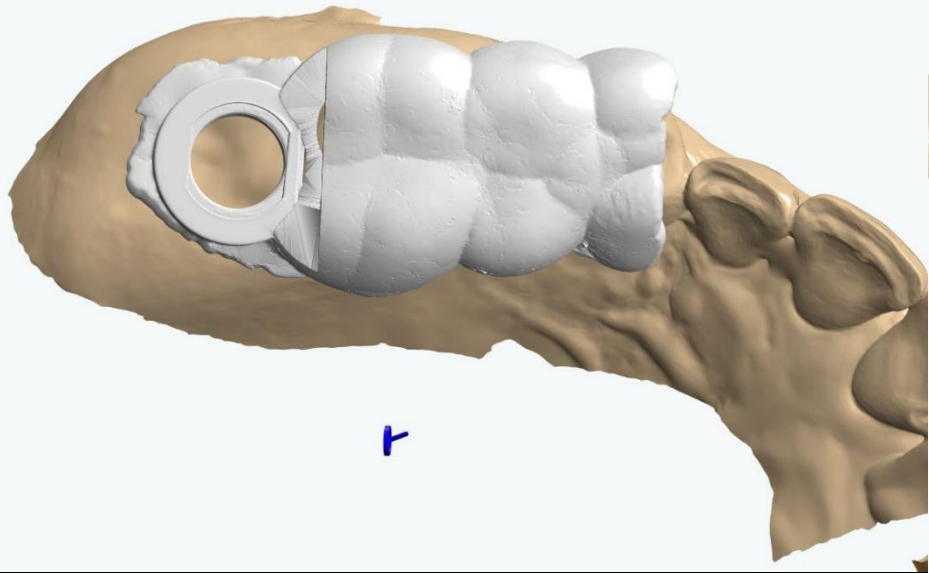
Implant Planning



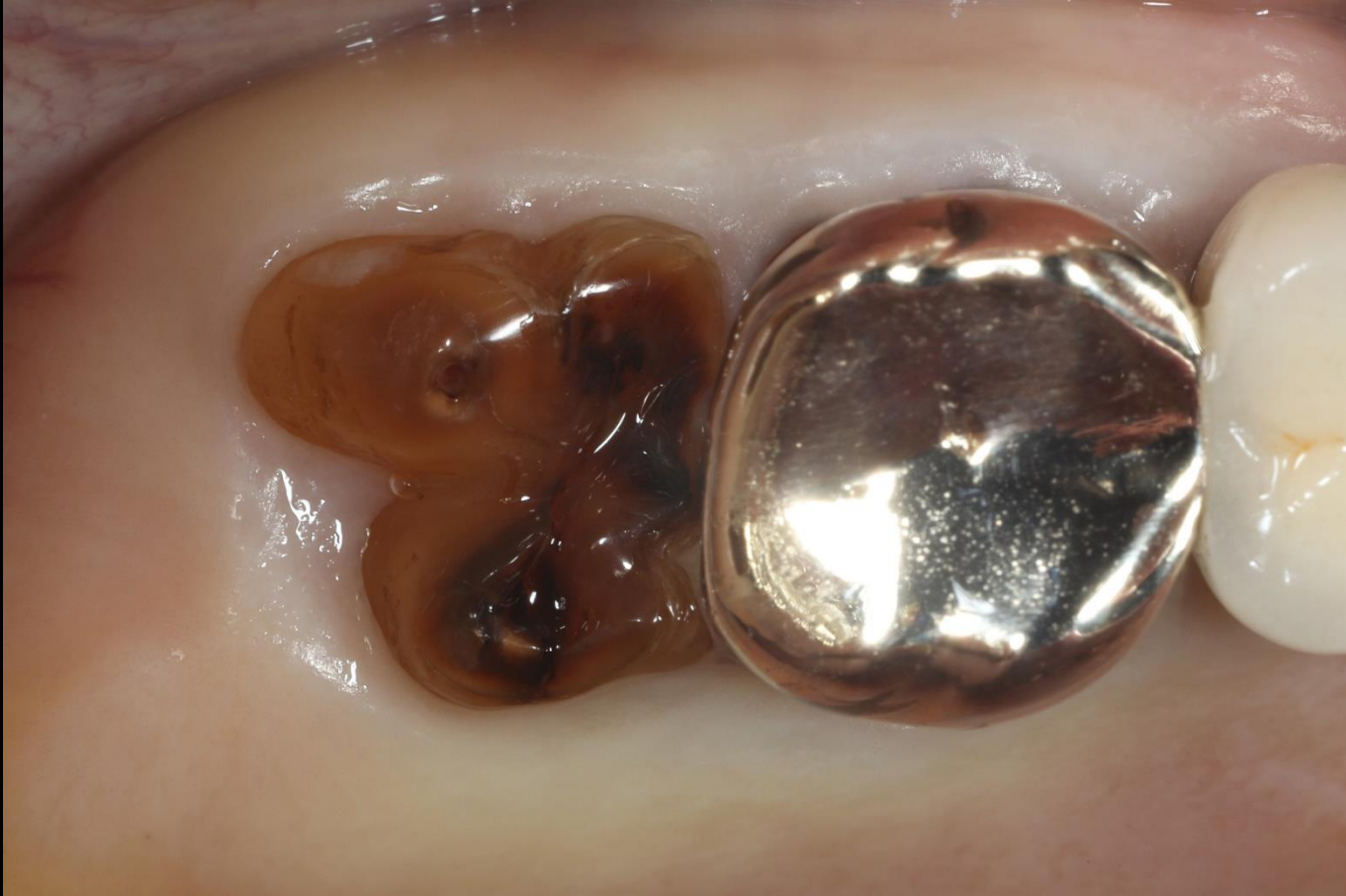
Implant Planning

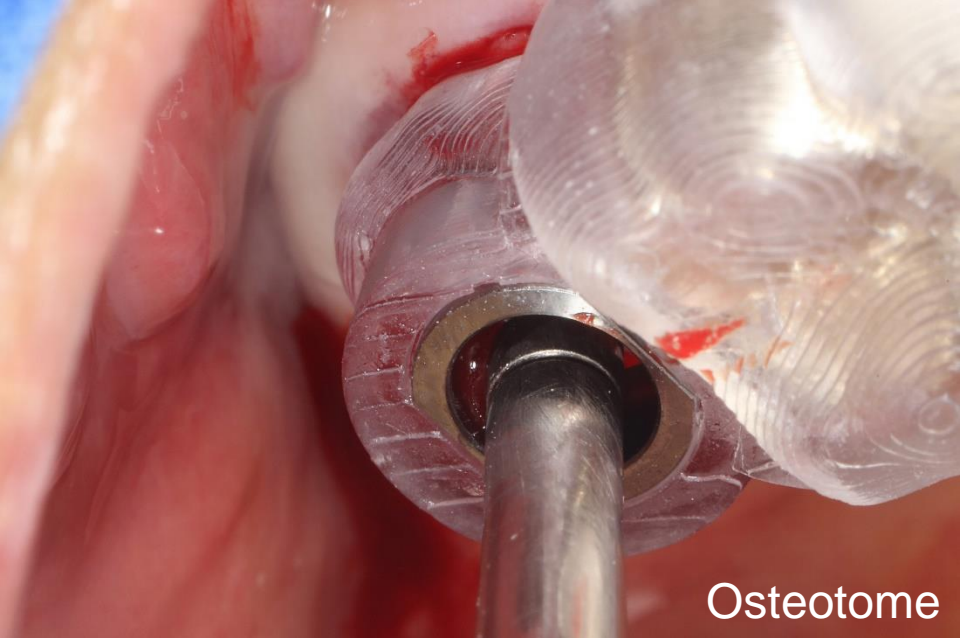
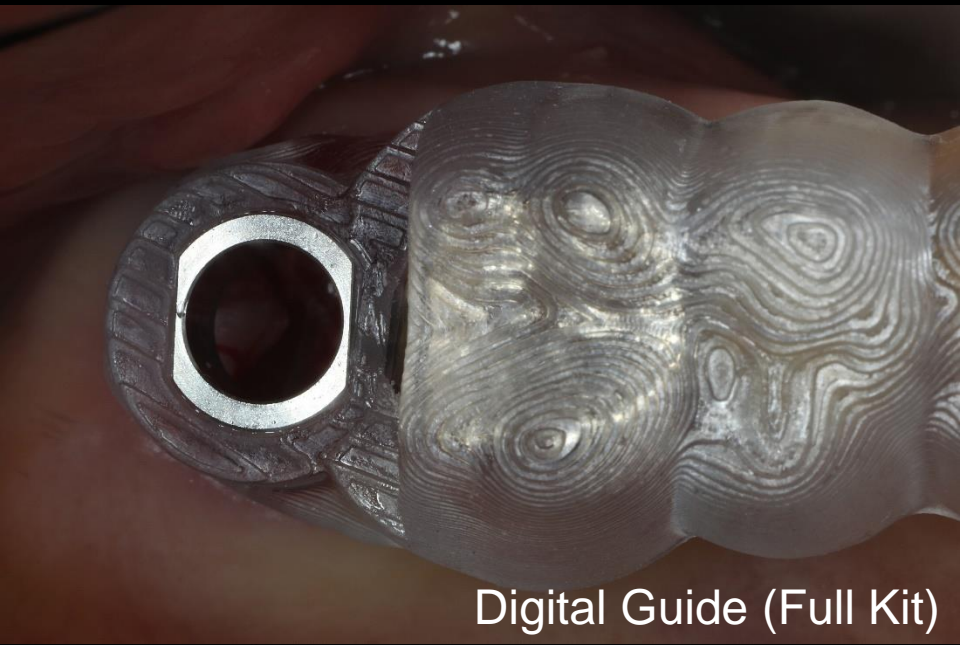
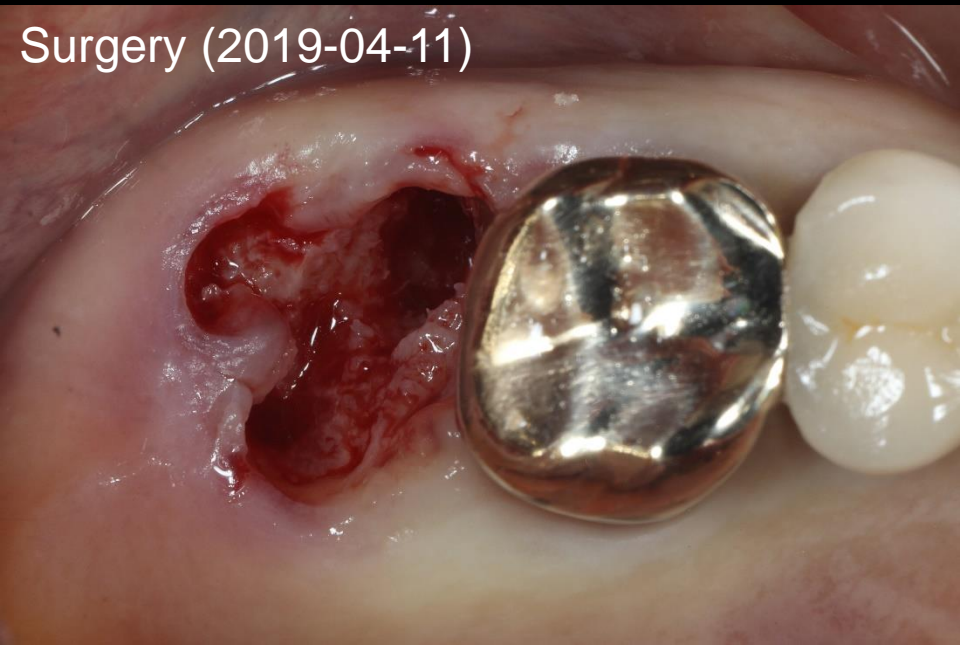


Stent Design

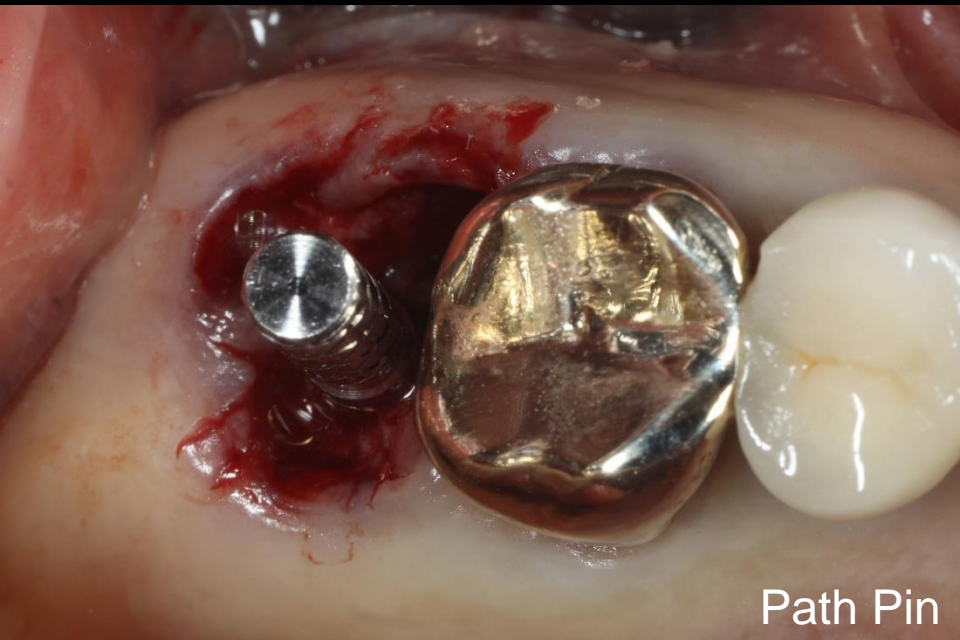
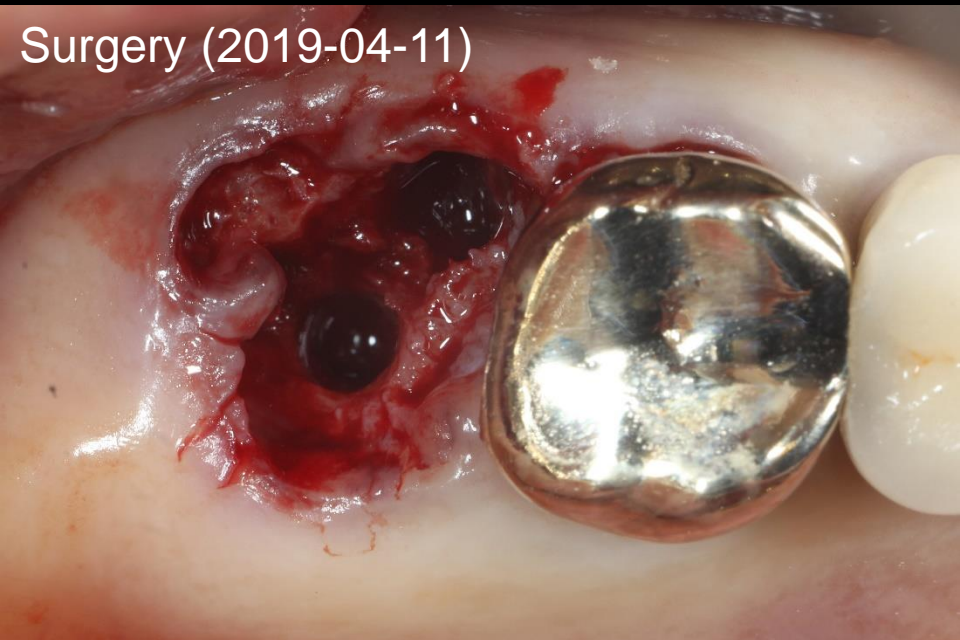


Pre-op (2019-04-11)

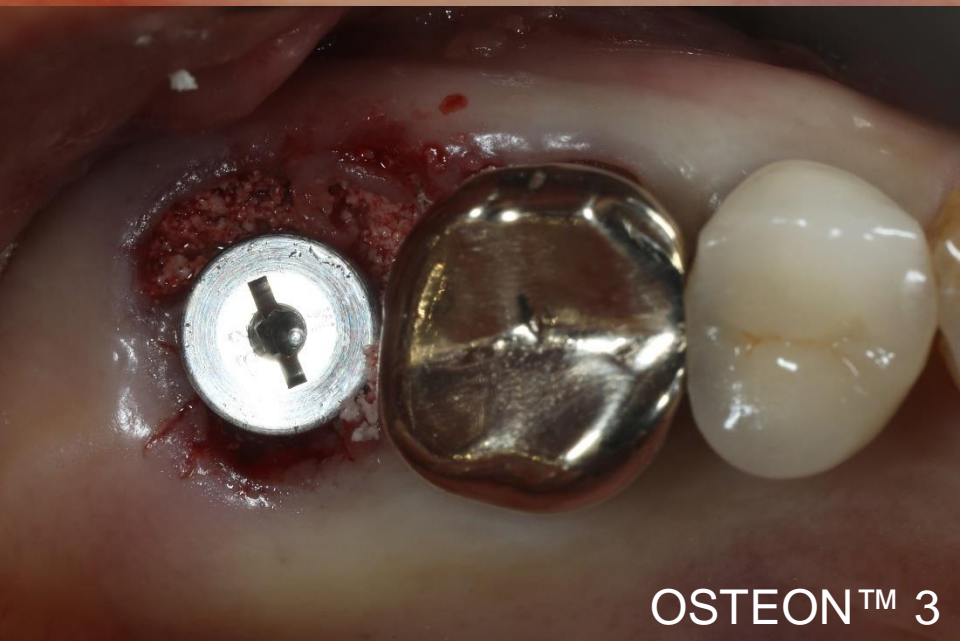



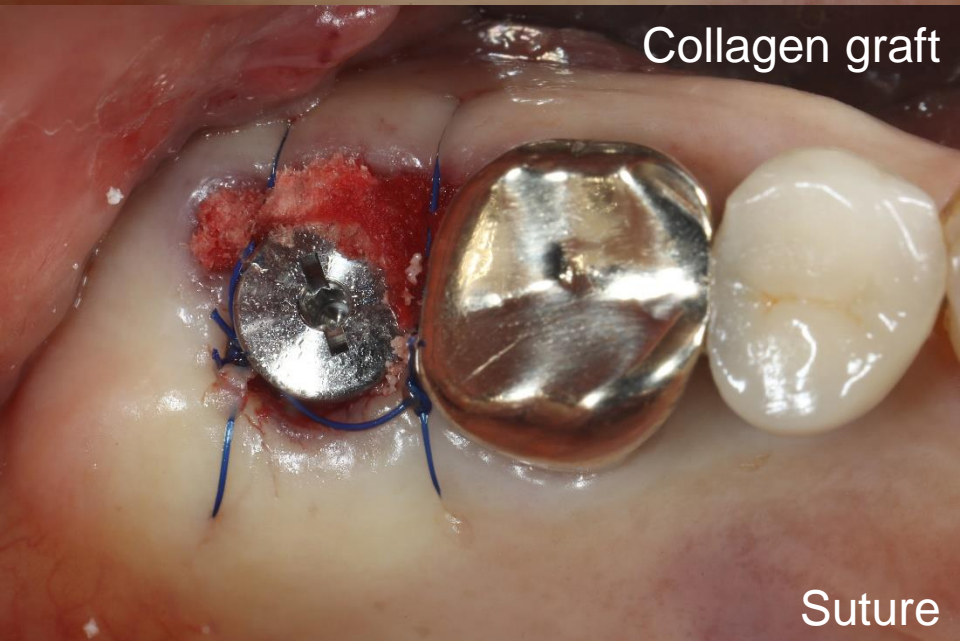
Surgery (2019-04-11)



Path Pin



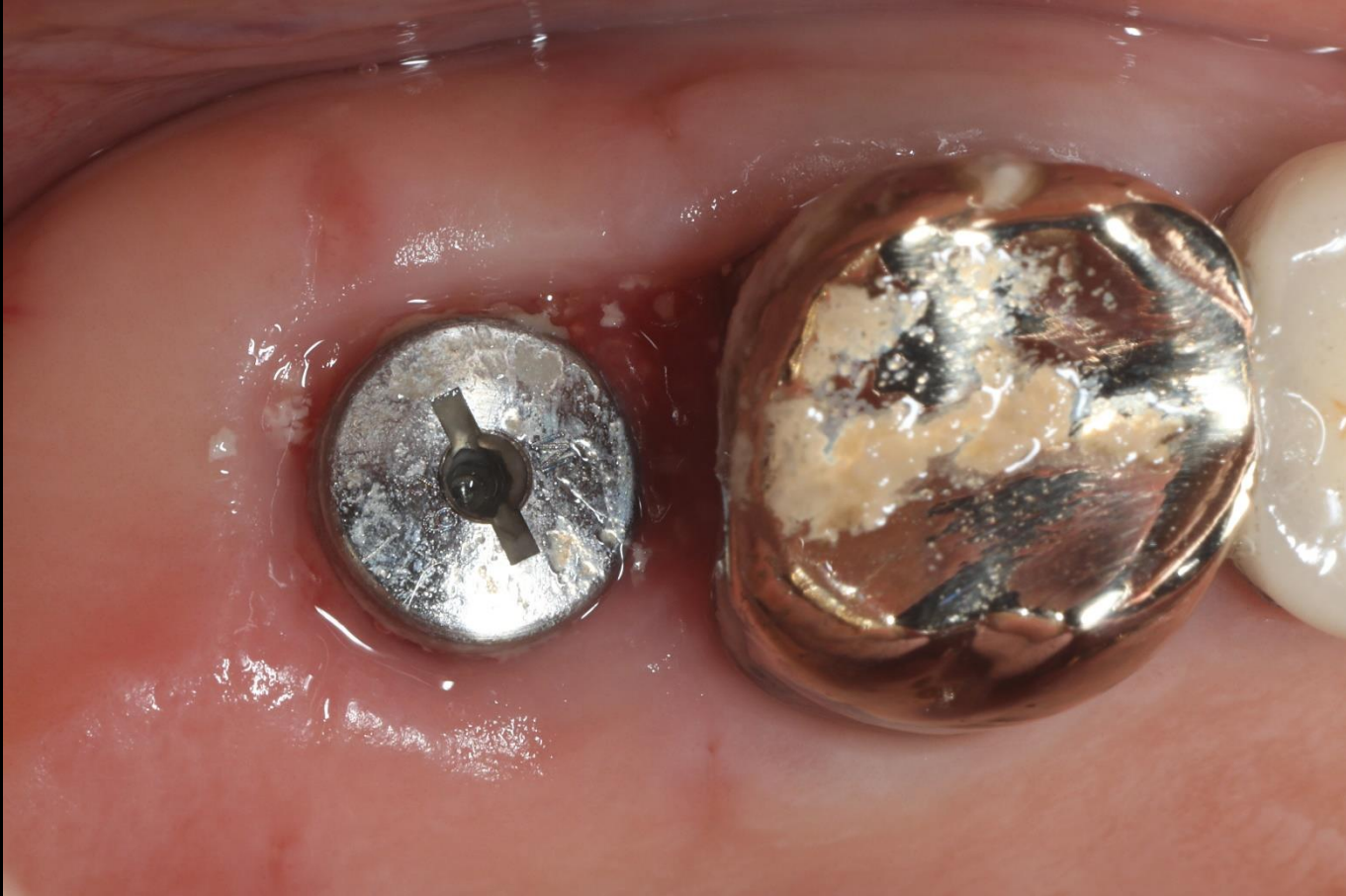OSTEON™ 3



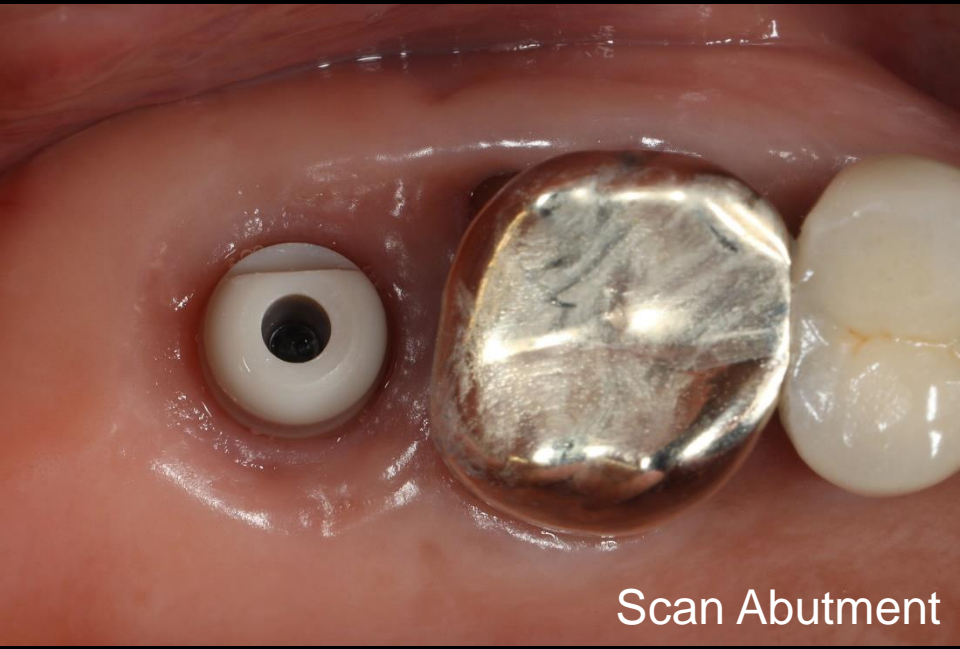
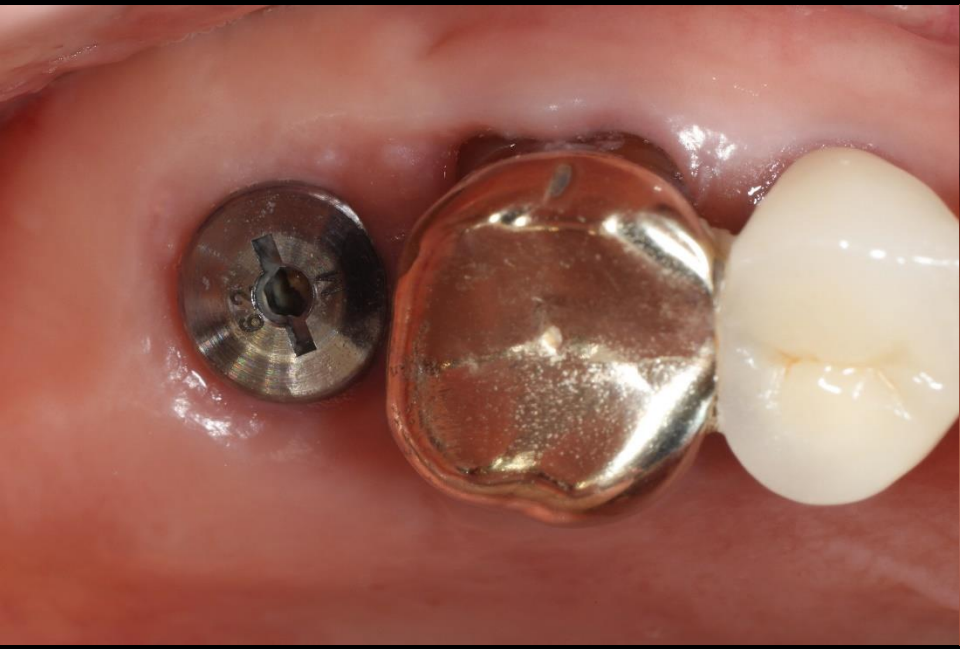
Collagen graft

Suture

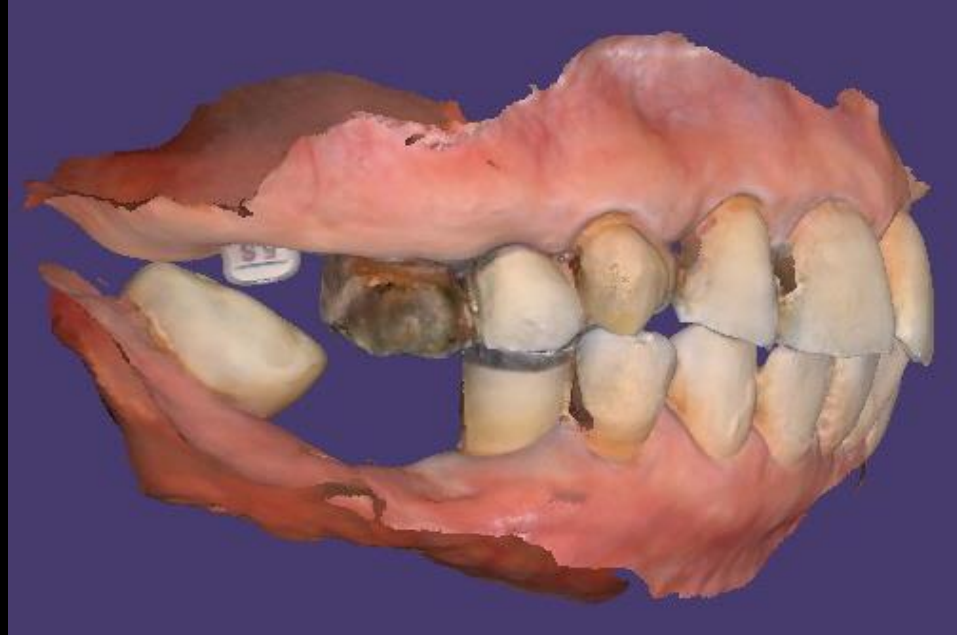
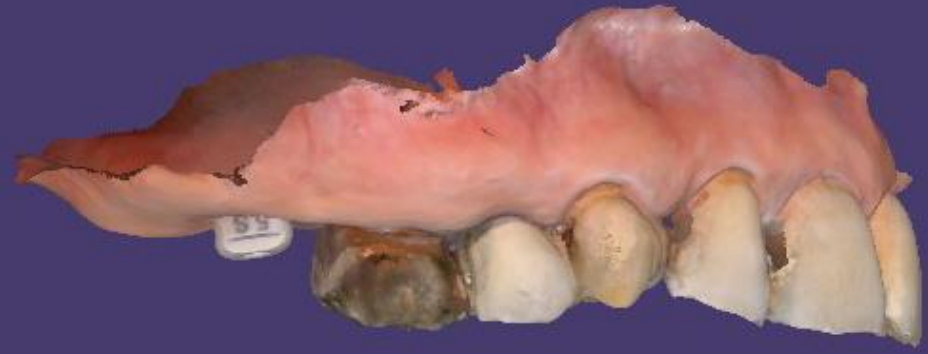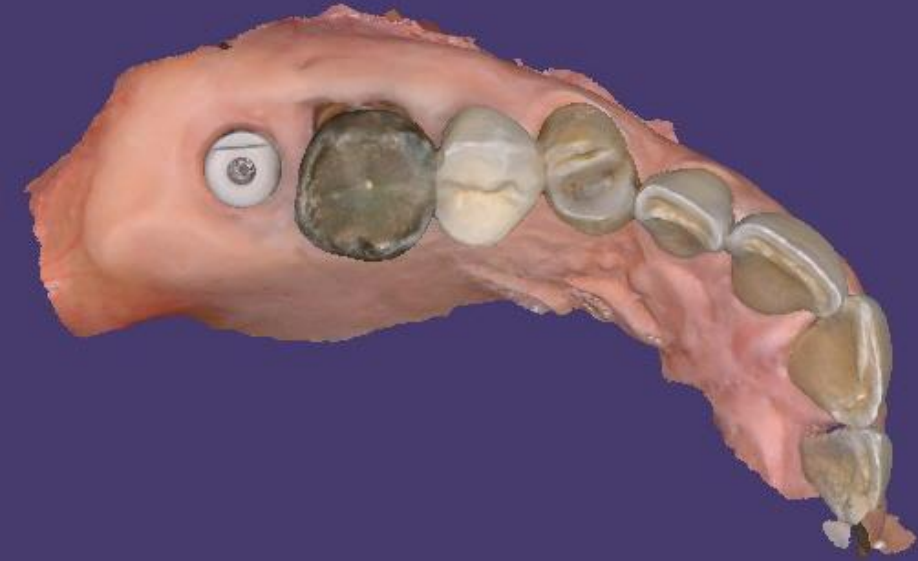
Healing : 2 weeks (2019-04-29)



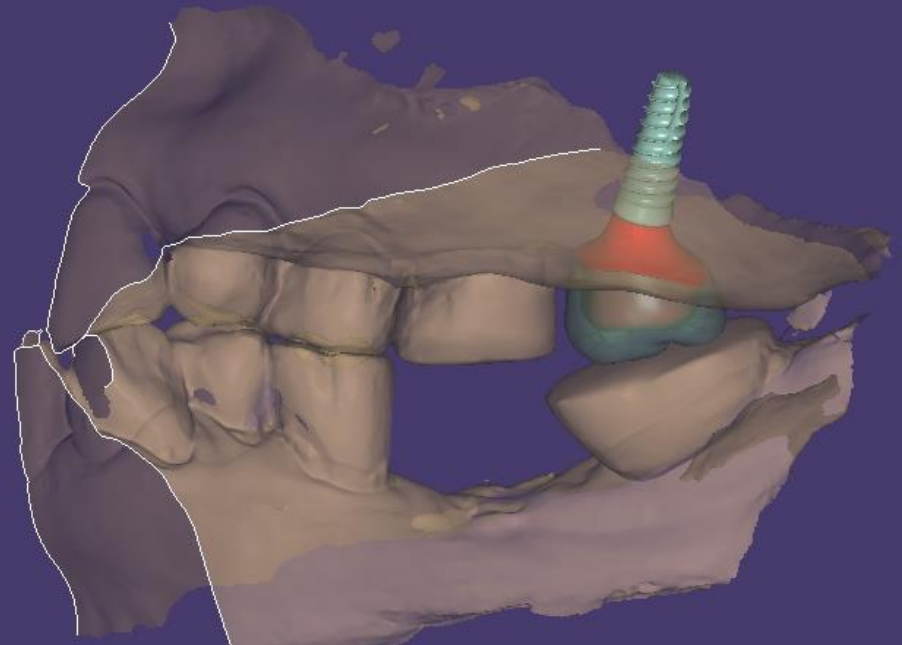
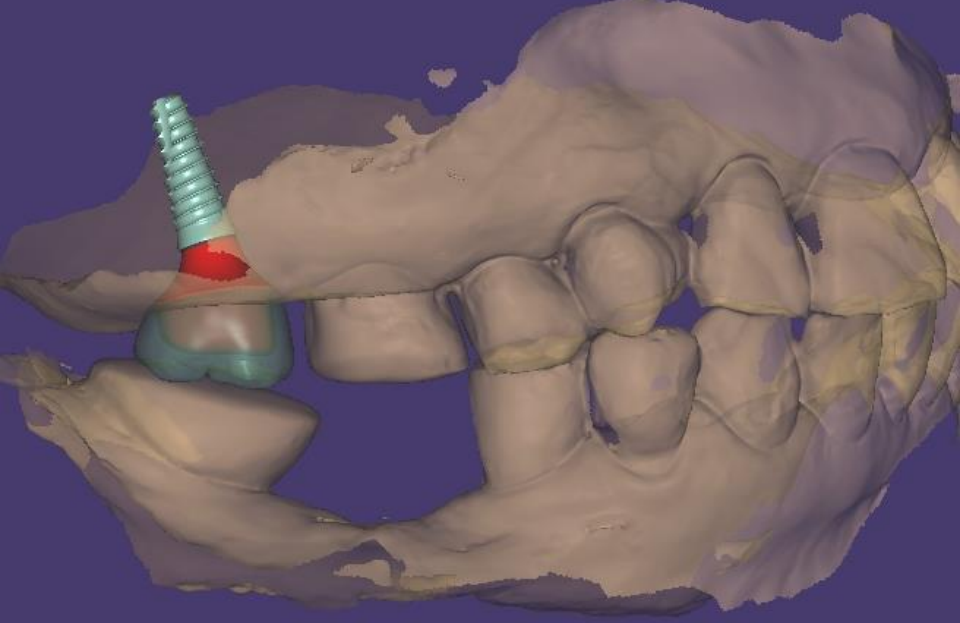
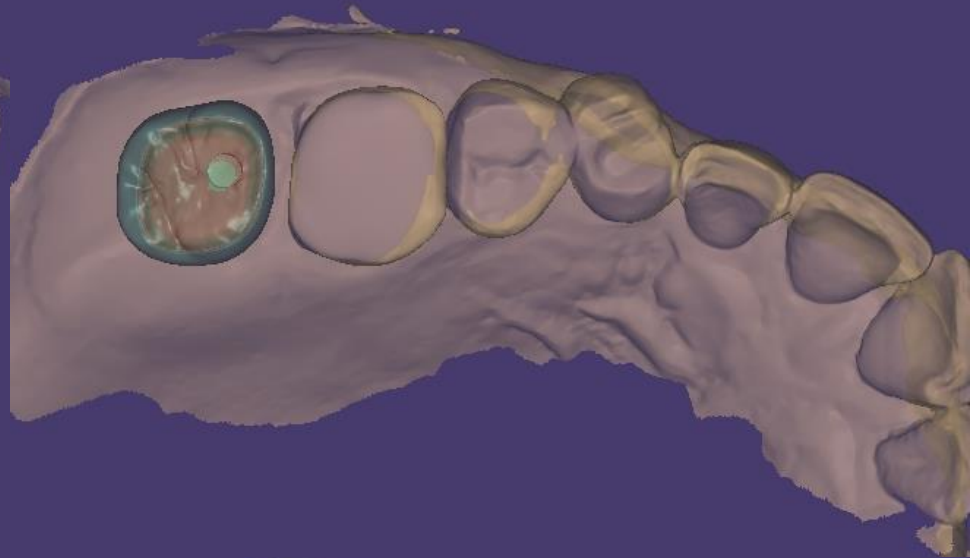
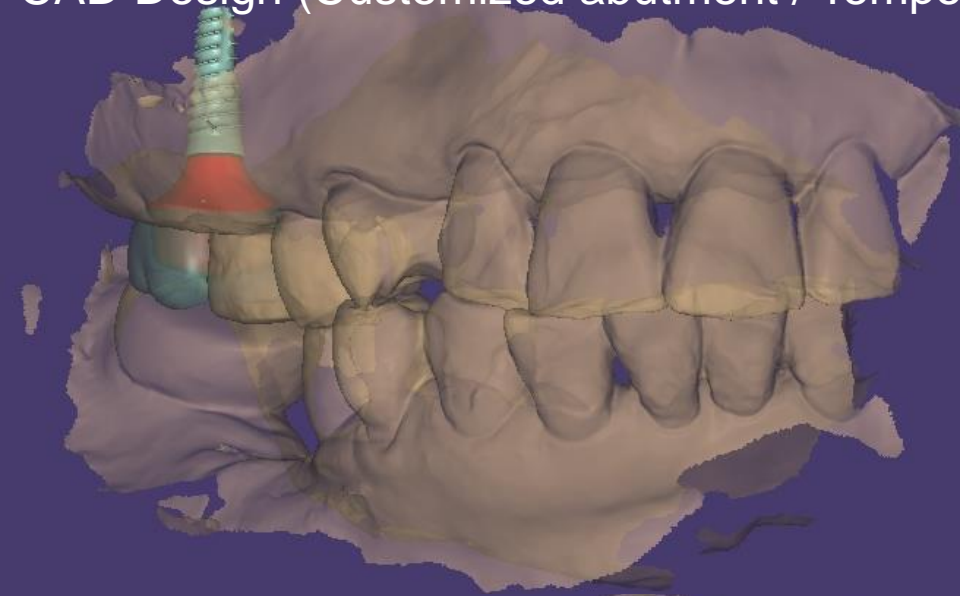Healing : 3 months (2019-07-10)



Intra Oral Scanning



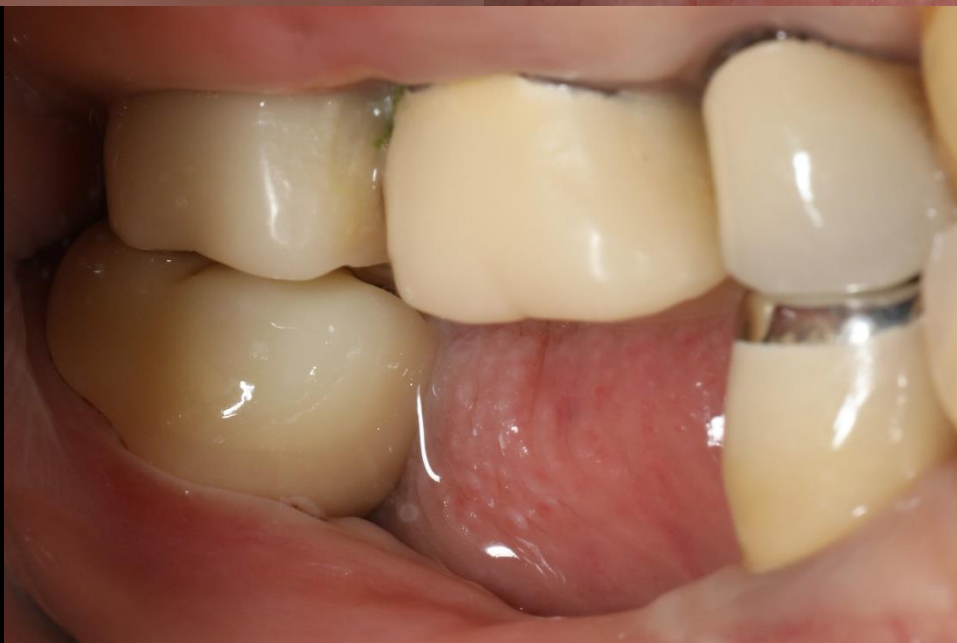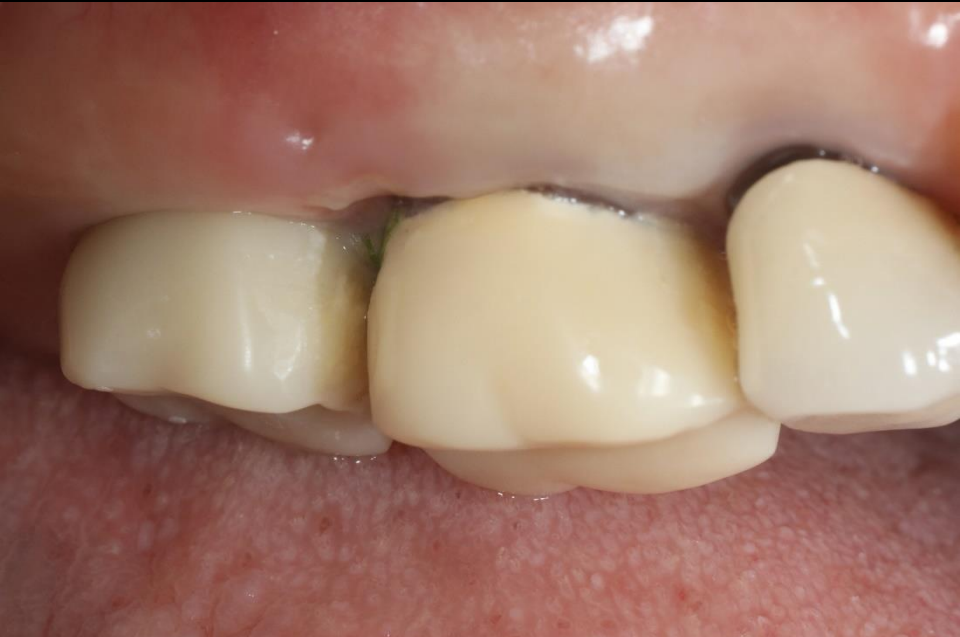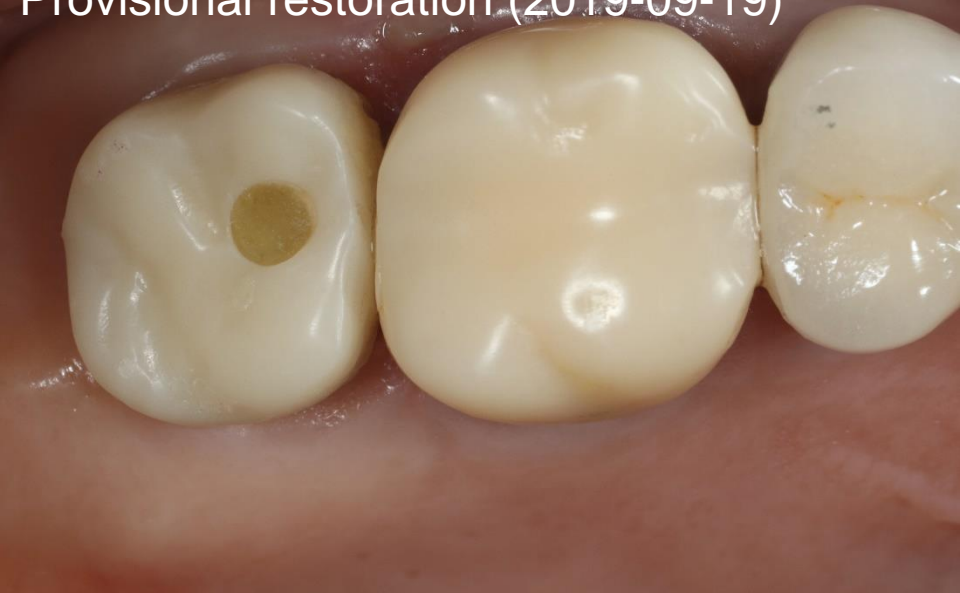CAD Design (Customized abutment / Temporary)



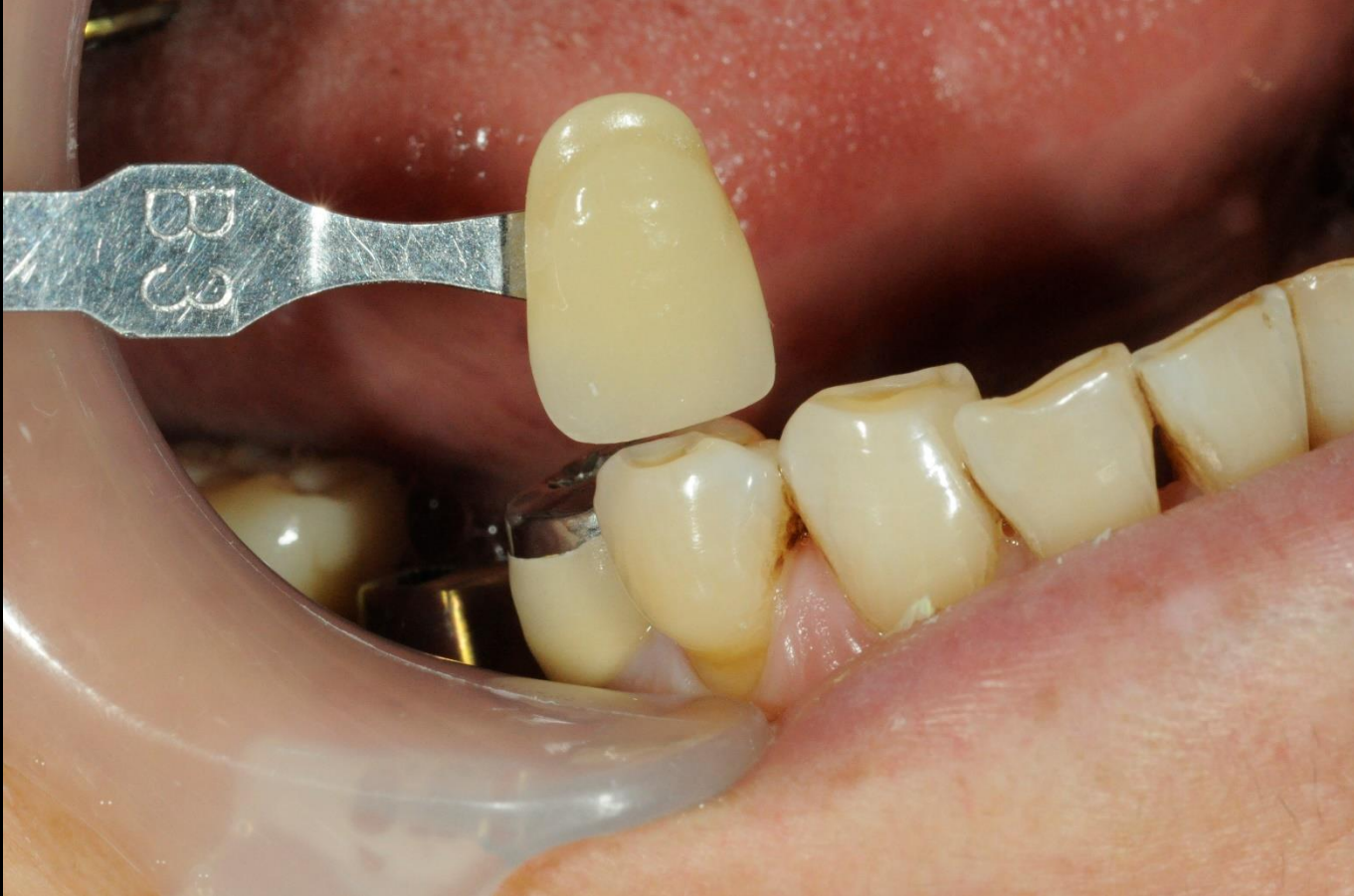Customized abutment / Temporary



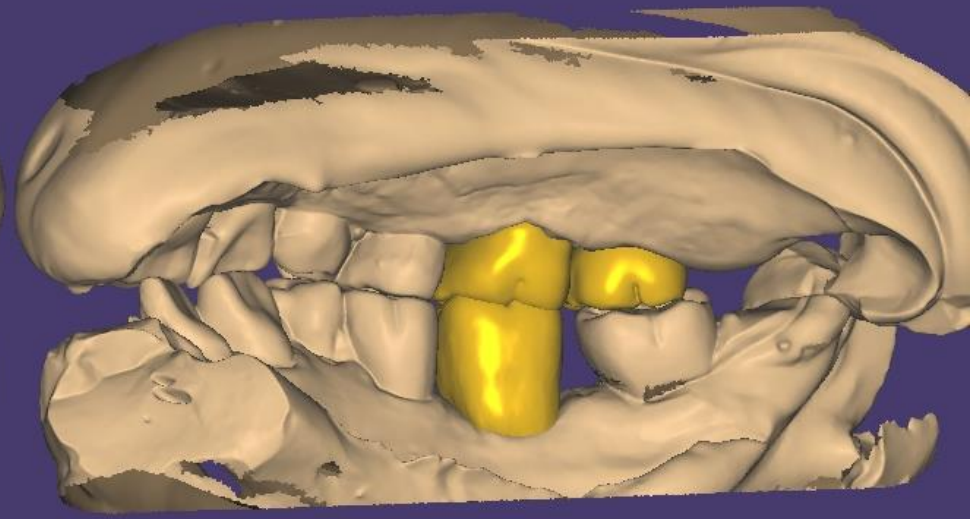
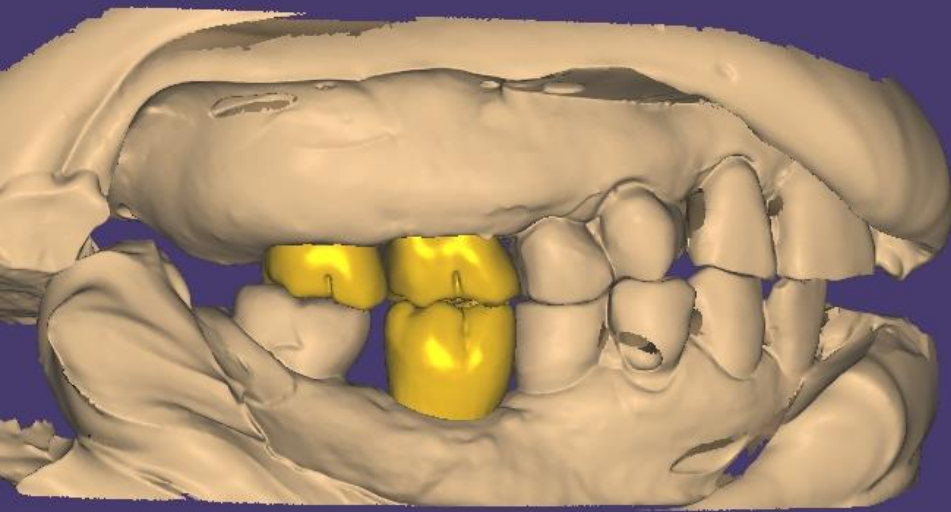
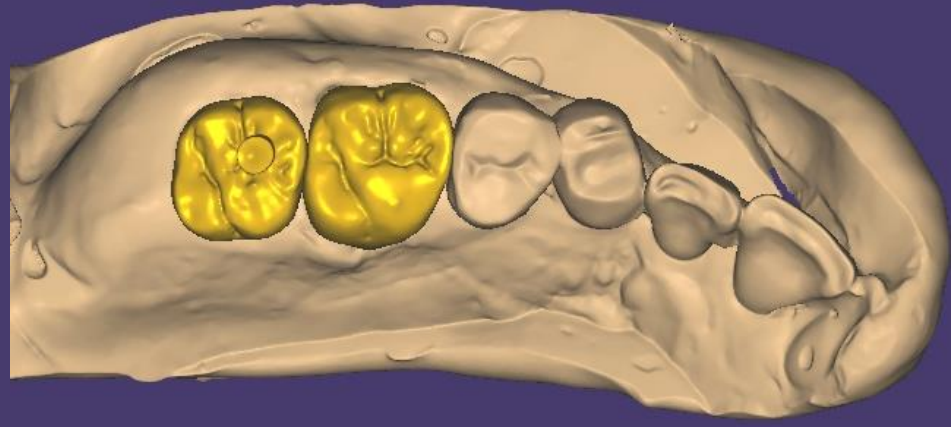
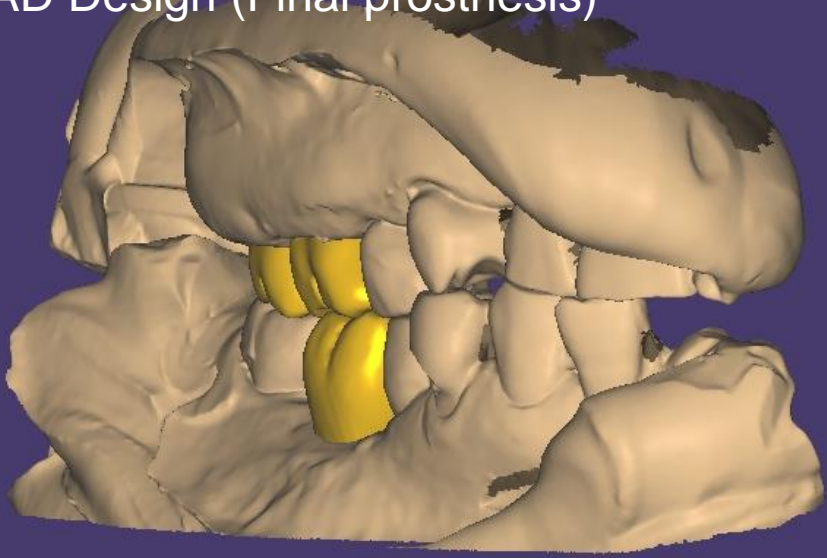
Provisional restoration (2019-09-19)



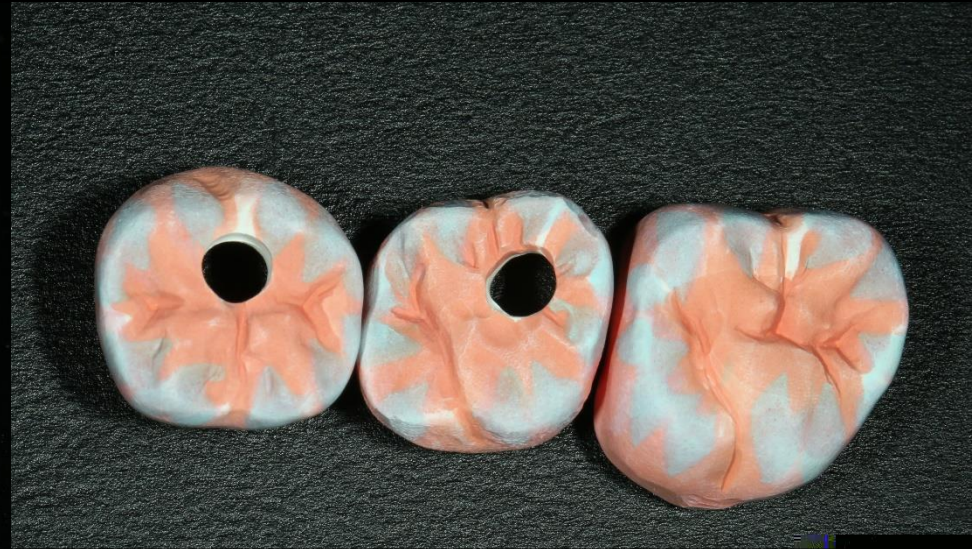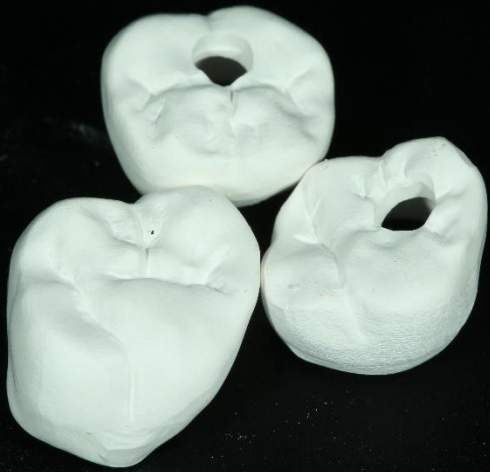Shade taking



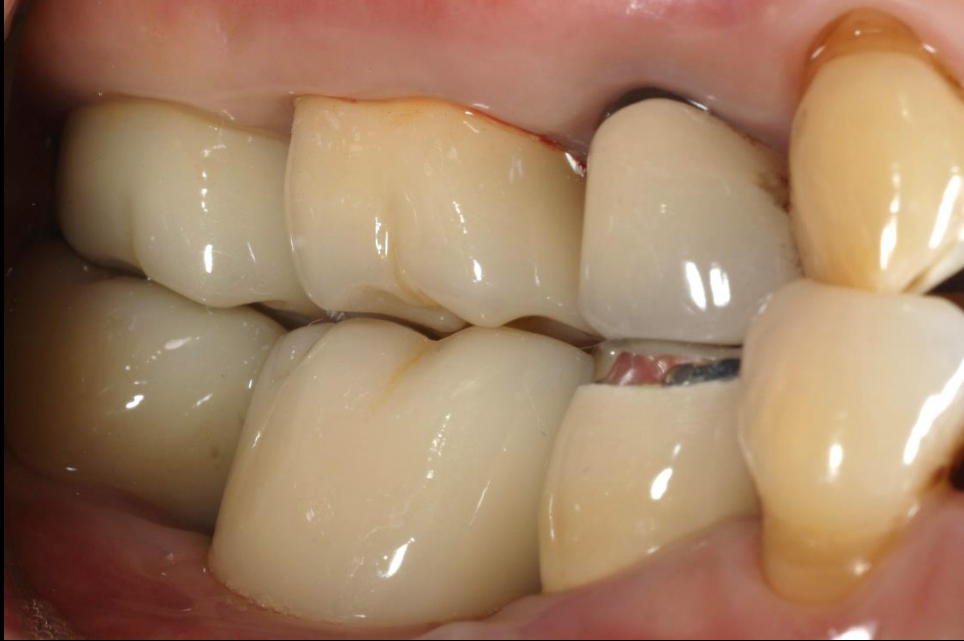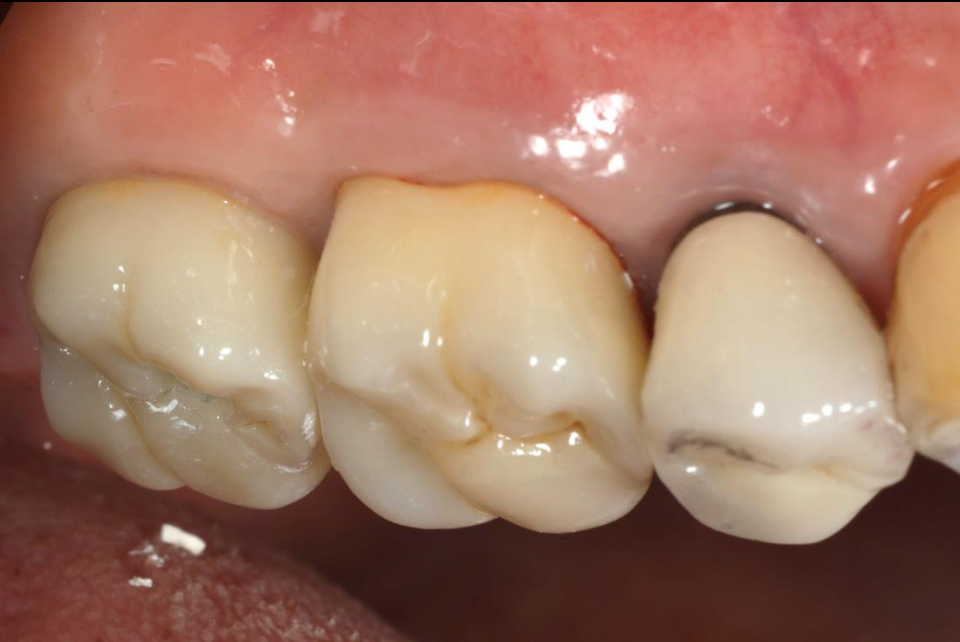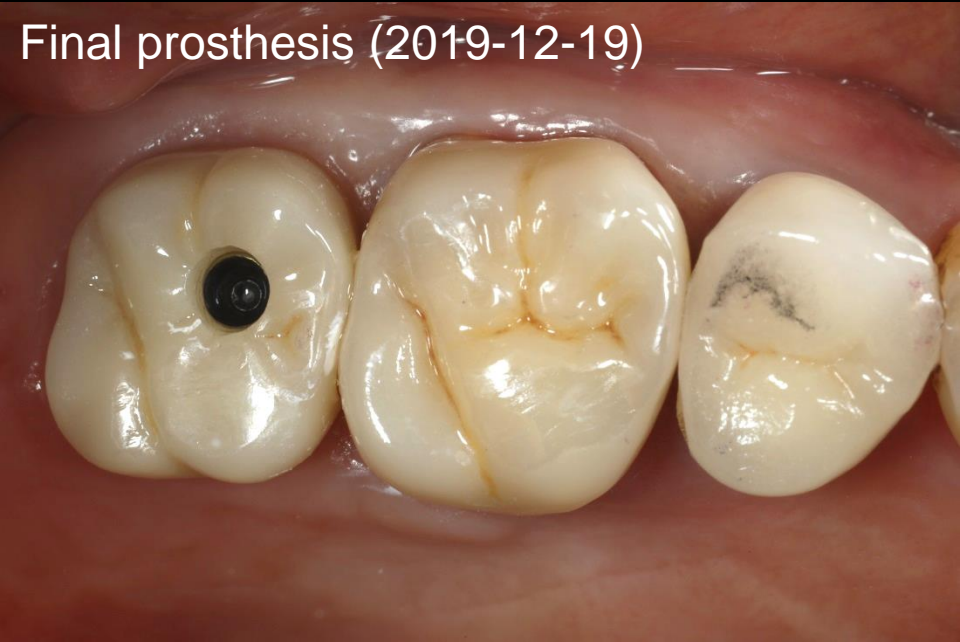CAD Design (Final prosthesis)



Milling / Brushing



Final prosthesis (2019-12-19)



Follow up : 1 year 1 month (2021-01-05)

