

**Simple Implantation
with Minimally invasive incision**

(Bone Level, Osteotome, Digital Guide(S))

75y/F

Dr.SM Chung

Pre-op (2019-01-10)

rainbow 3D Viewer

이환자
FEMALE
19440224
74
7 [mA]
94 [kVp]
CT

IMPLANT
MPR
Cross
Report

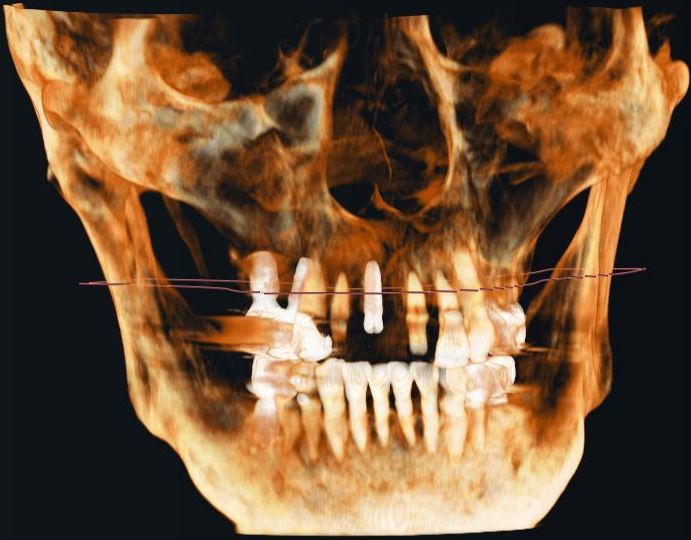
Curve Info
W 80mm
I 0.5mm
T 0.0mm

Nerve Info
R 1.0mm

Post-op (2019-03-07)

rainbow 3D Viewer


IMPLAN
MPR
Cross
Report



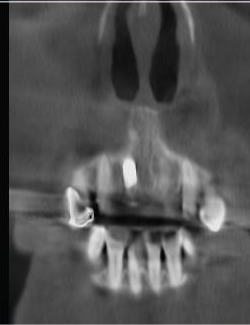
Curve Info
W 80mm
I 0.5mm
T 0.0mm

이환자
FEMALE
19440224
75
8 [mA]
94 [kVp]
CT


H
R A L
F



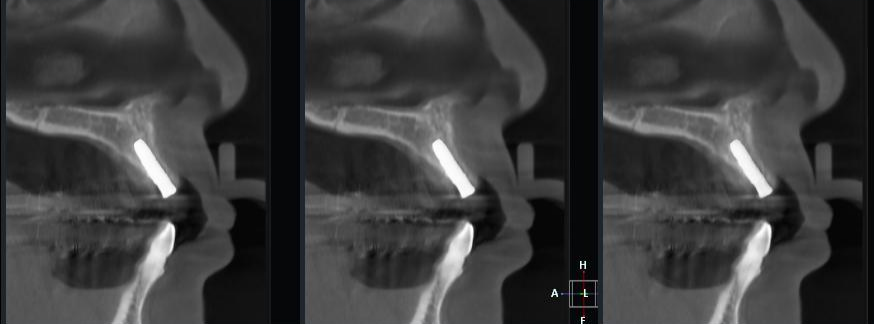
A
R F L
P



H
R A L
F



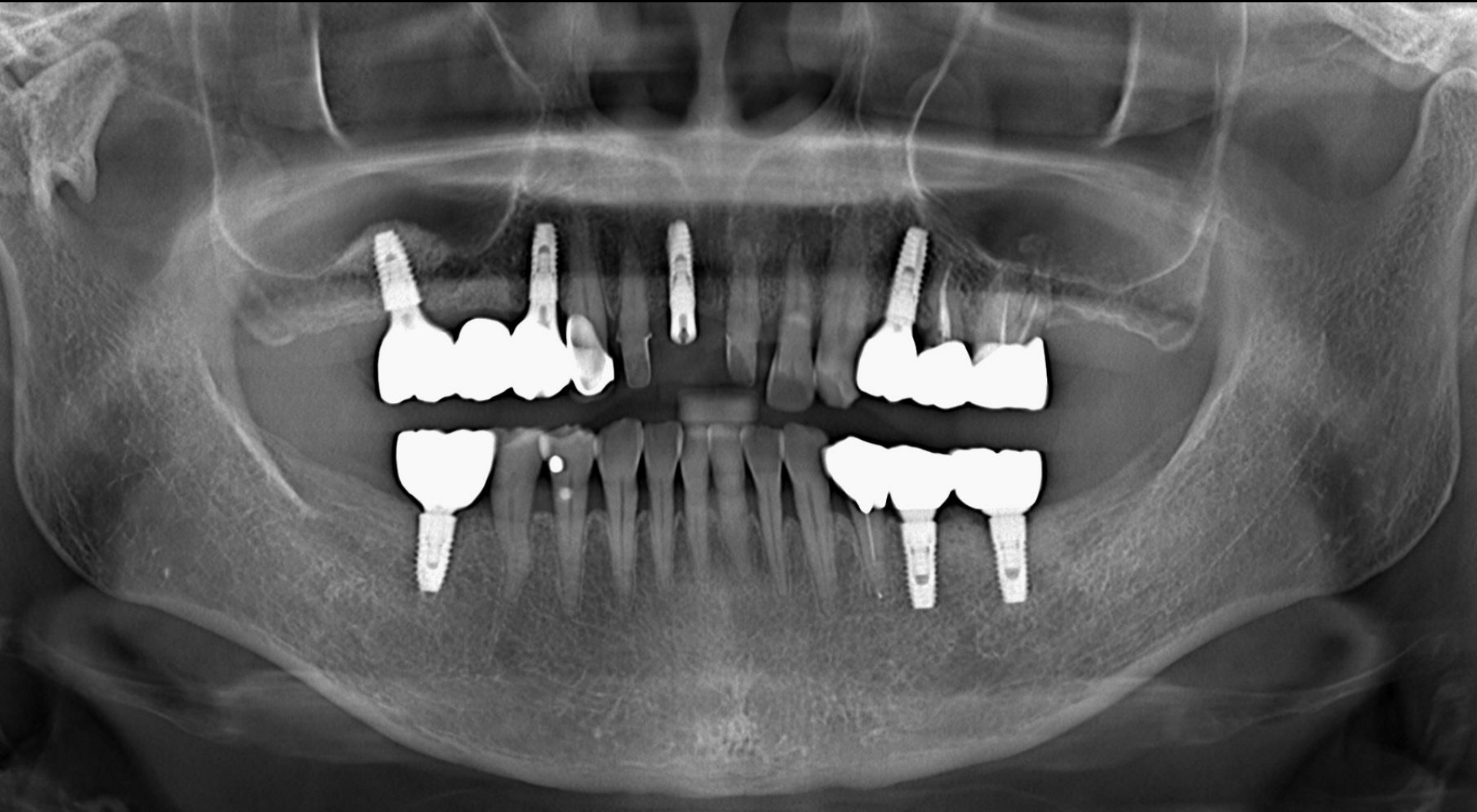
Nerve Info
R 1.0mm



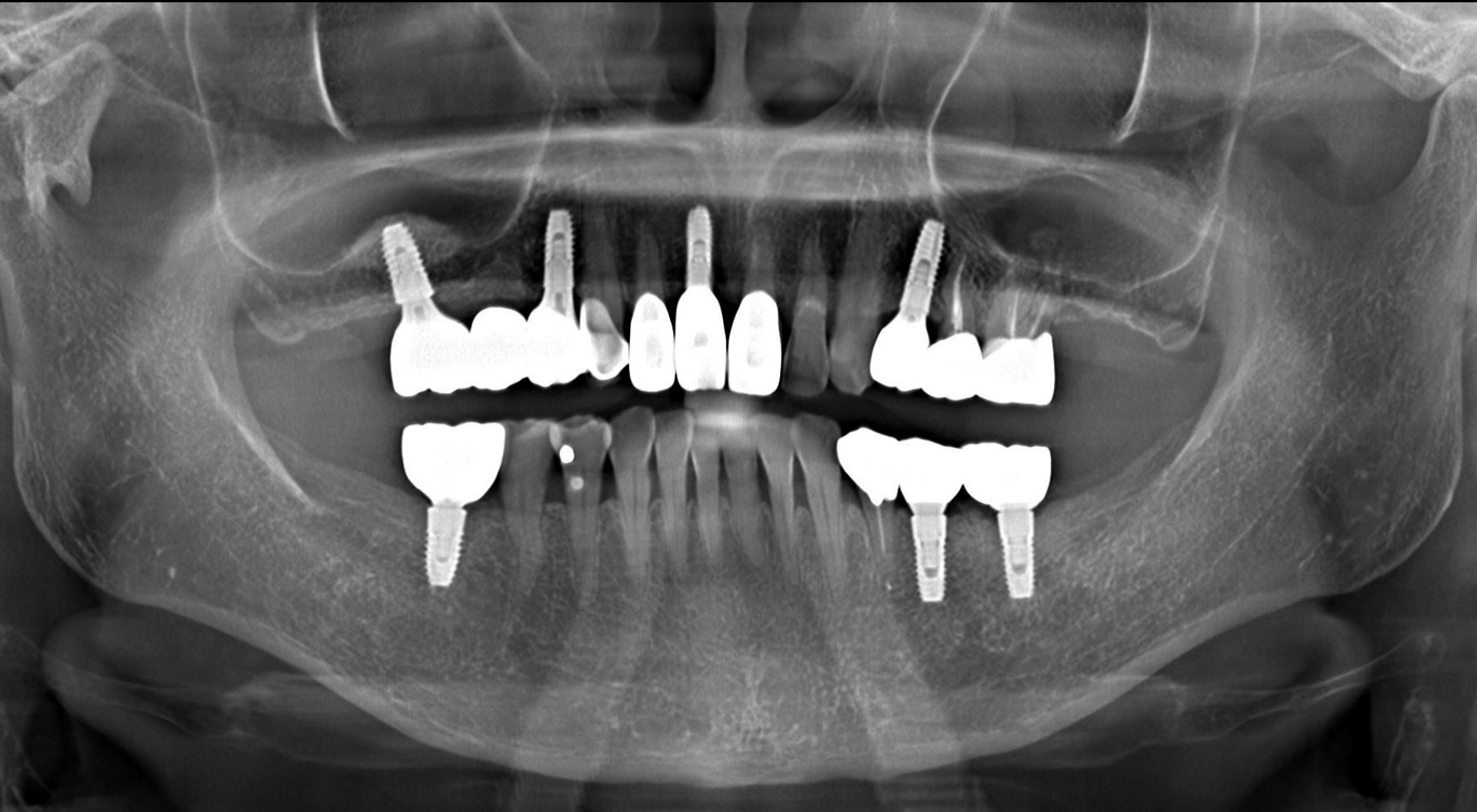H
A L
F

Dentium
For Dentists By Dentists

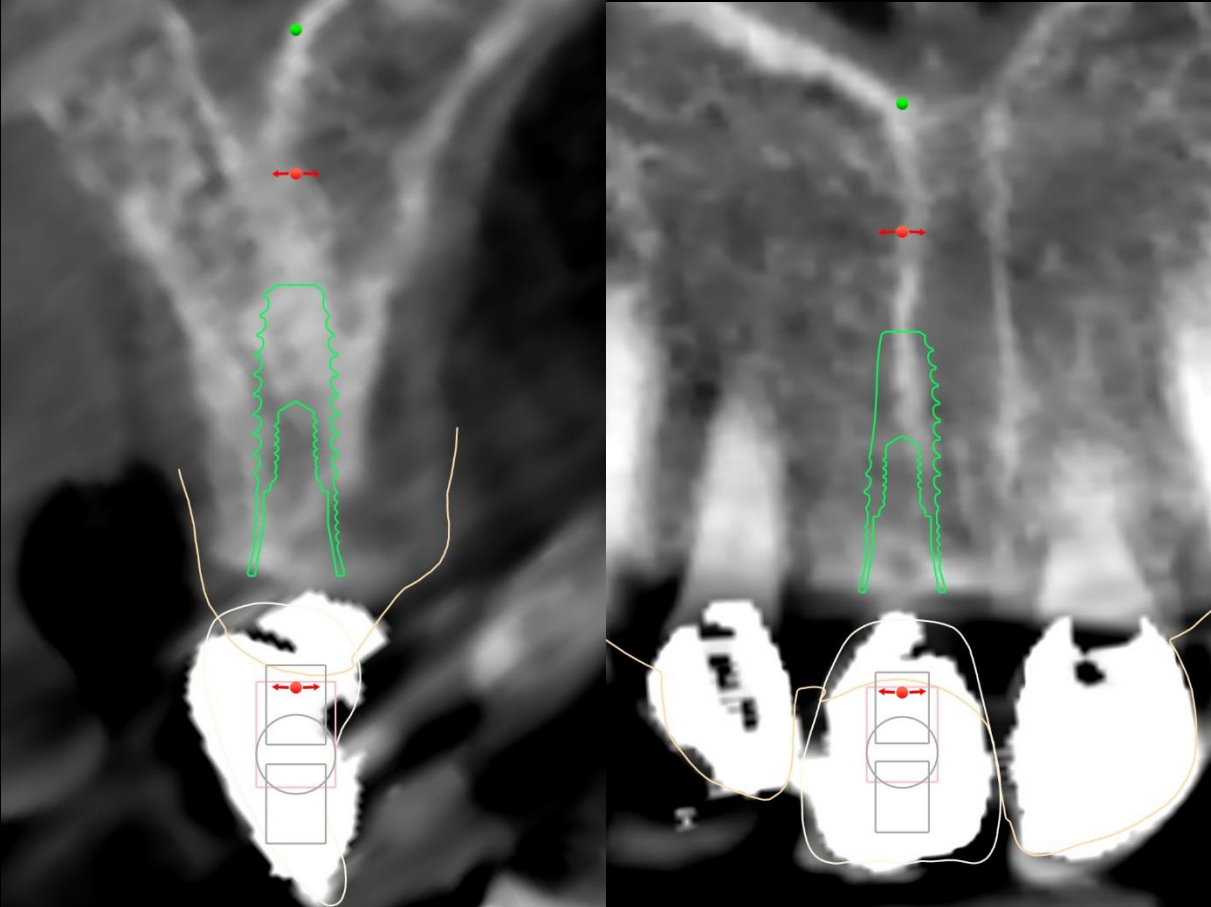
Healing : 1 month (2019-04-06)



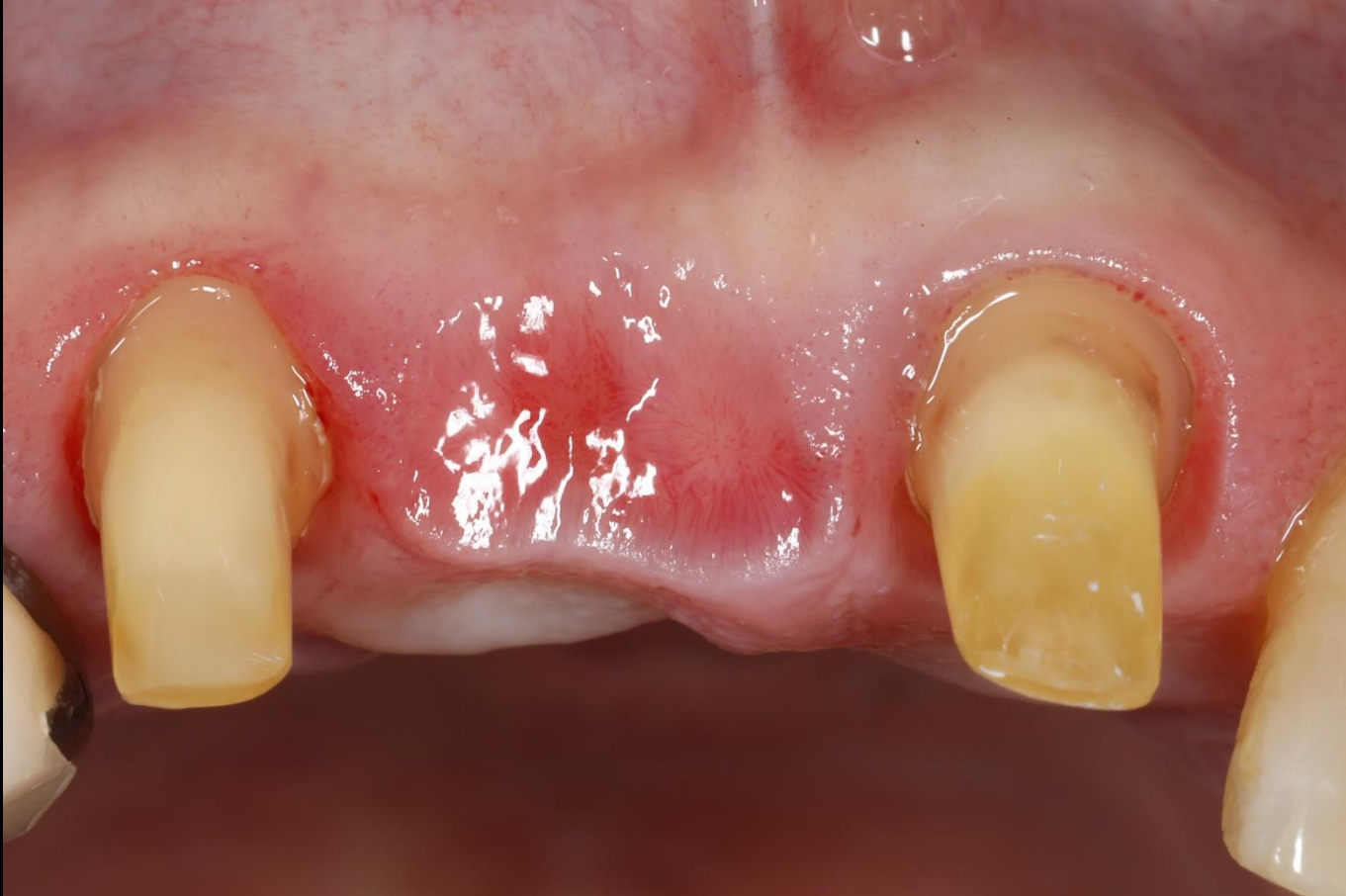Final prosthesis (2019-10-18)

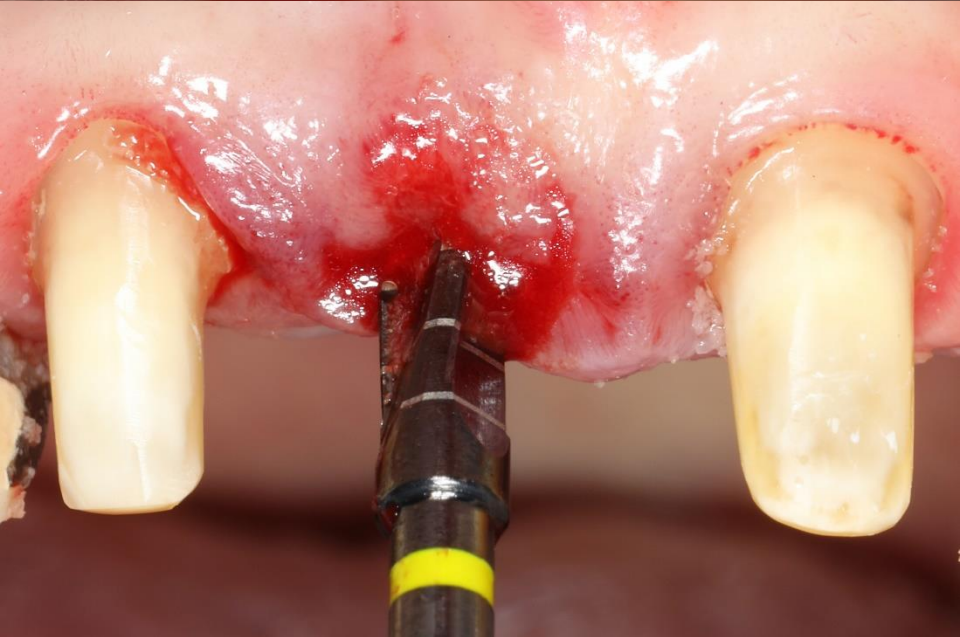
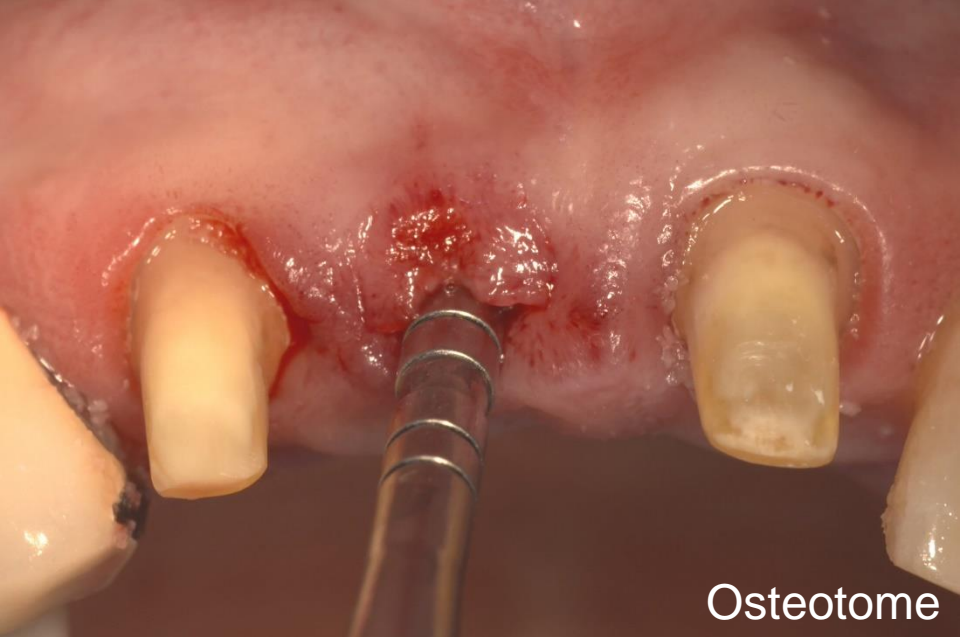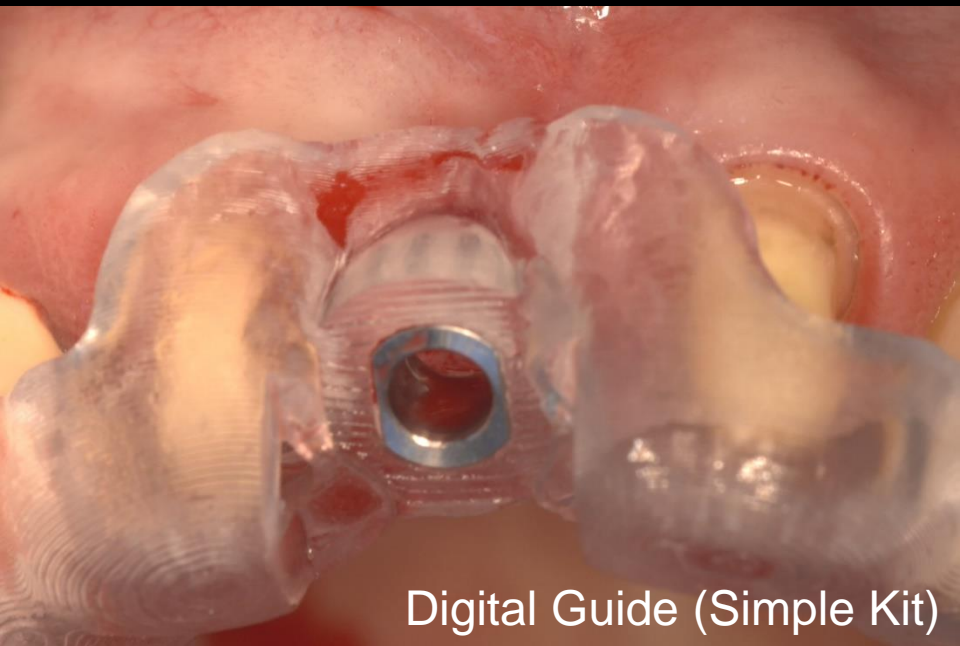

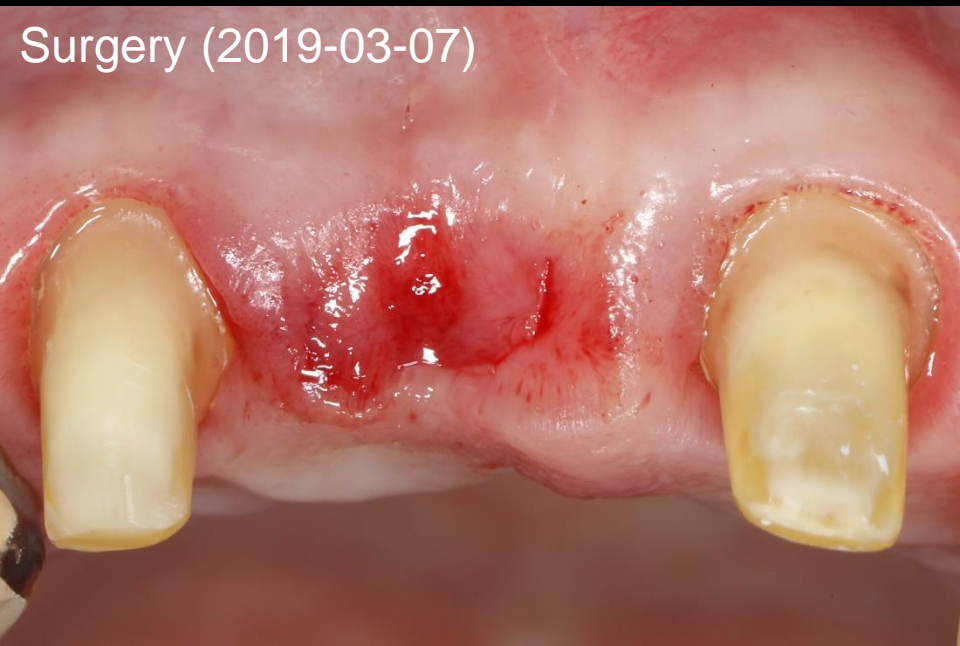
Implant Planning



Pre-op (2019-03-07)

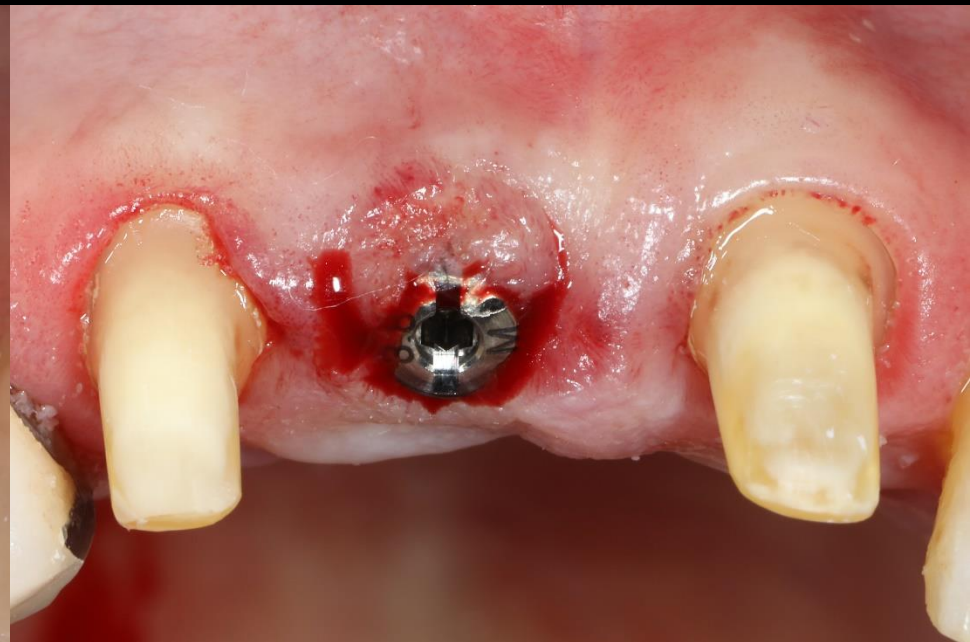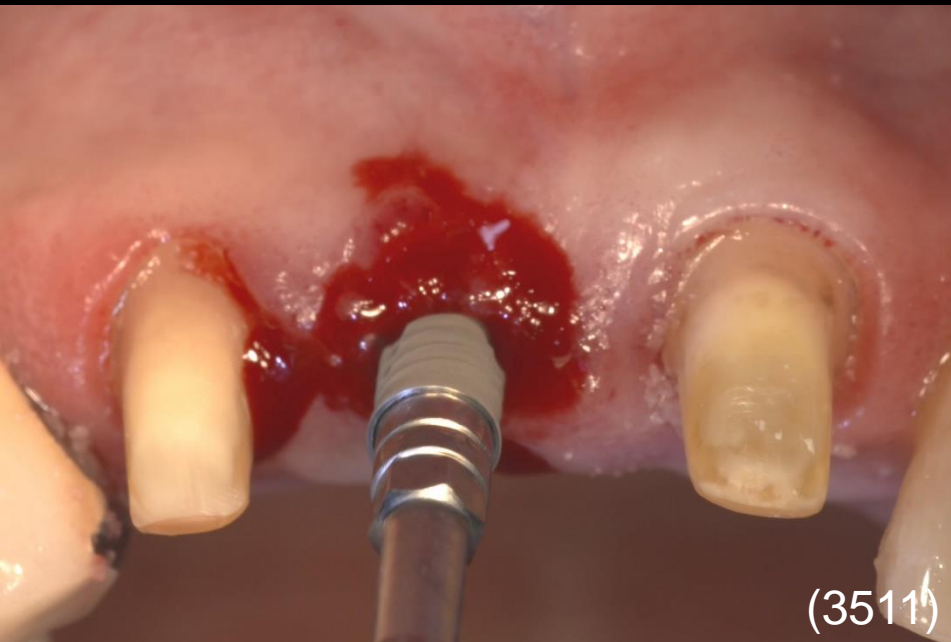




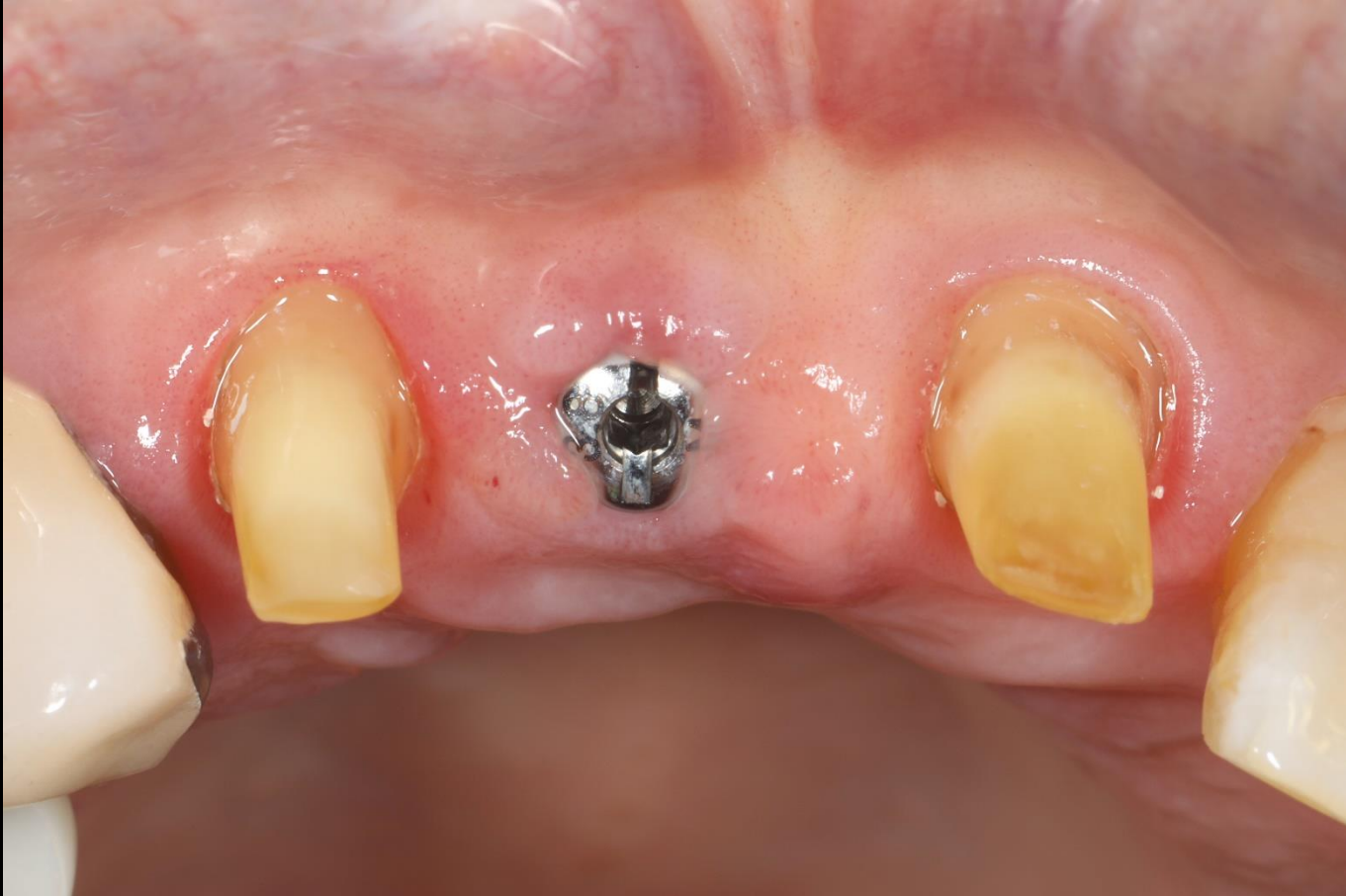Digital Guide (Simple Kit)

Osteotome

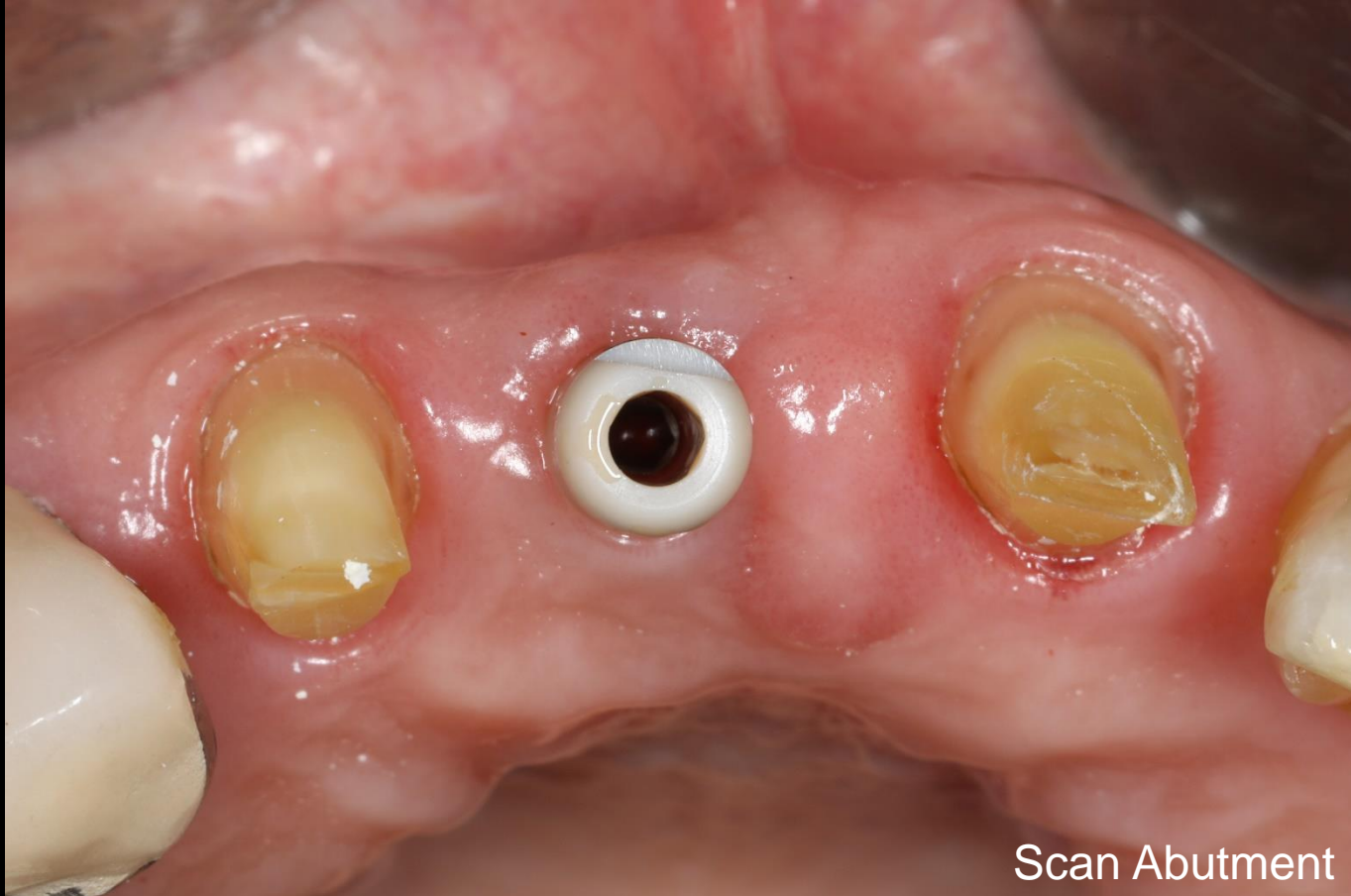Surgery (2019-03-07)



Healing : 1 month (2019-04-03)

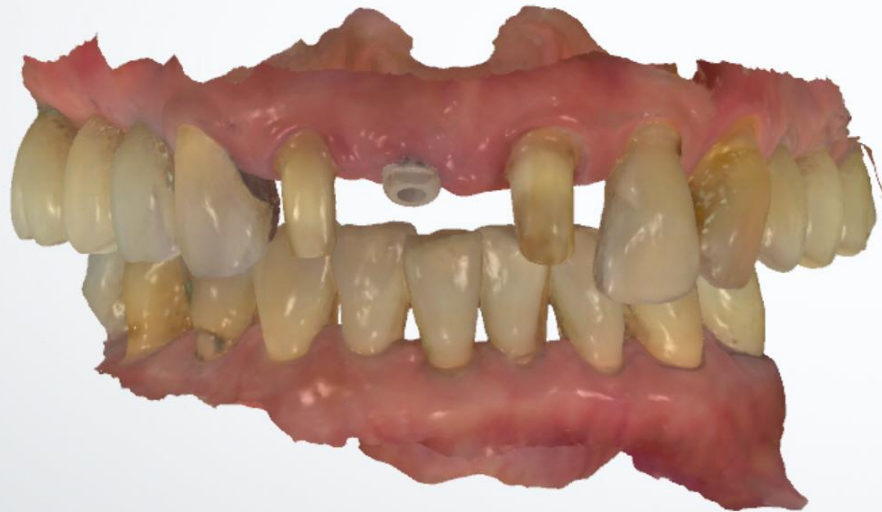
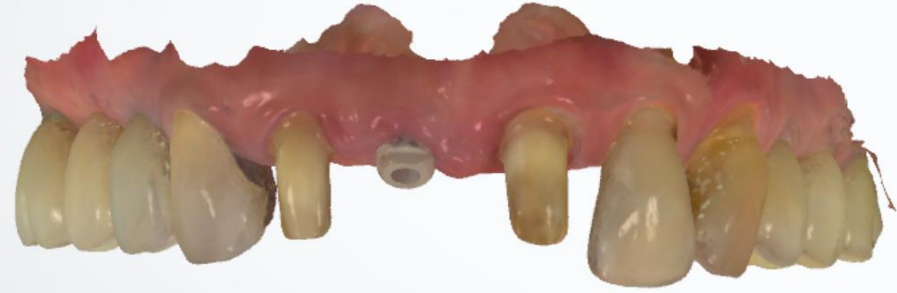
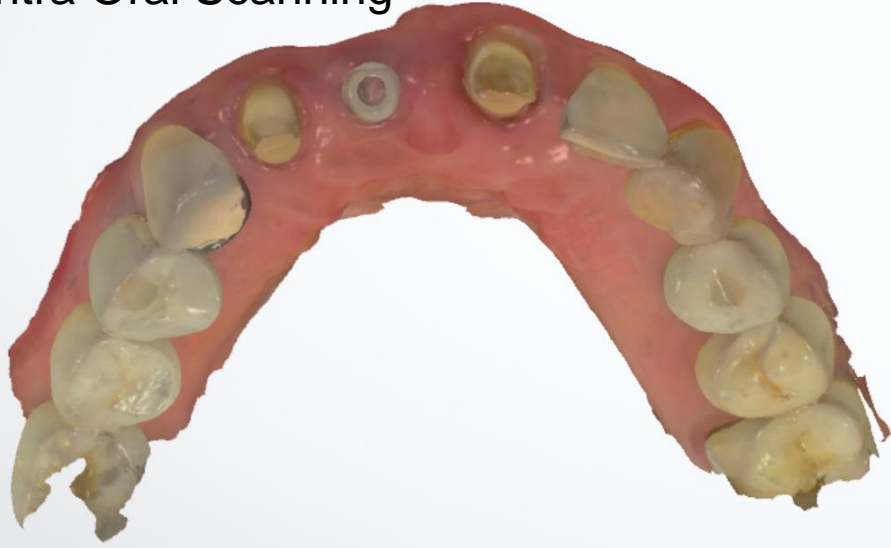Healing : 2 months (2019-05-03)

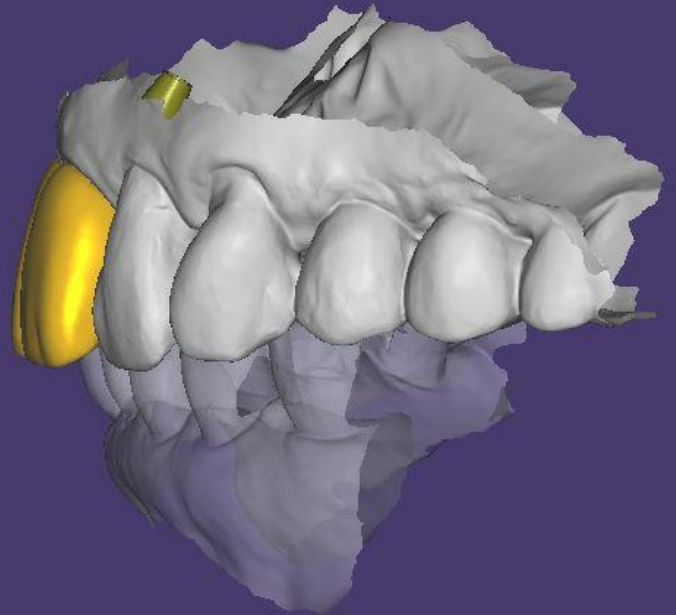
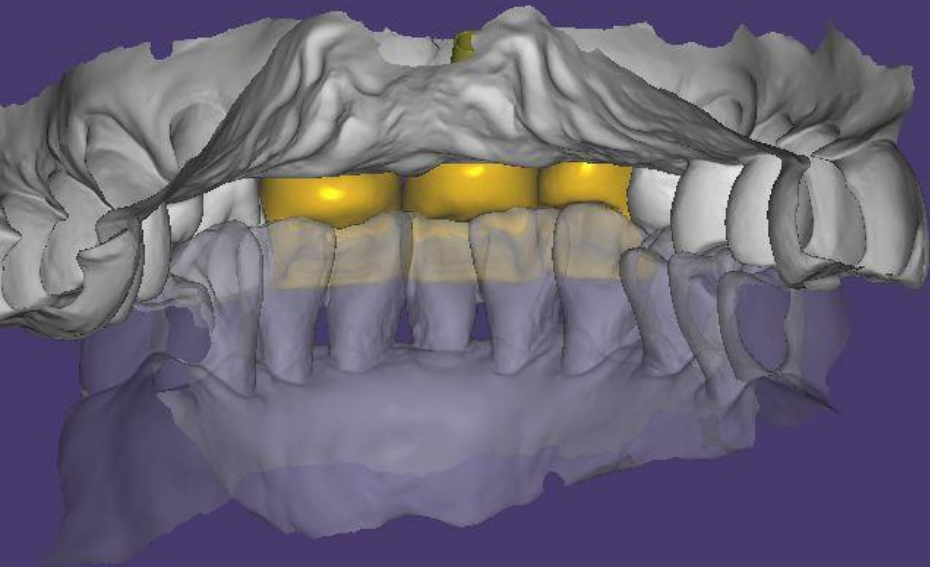
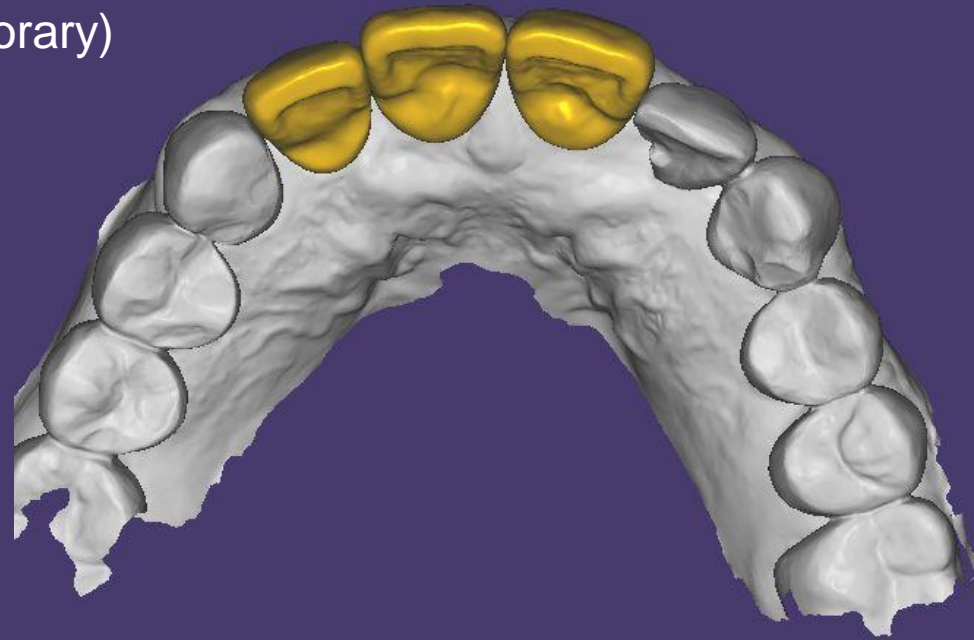
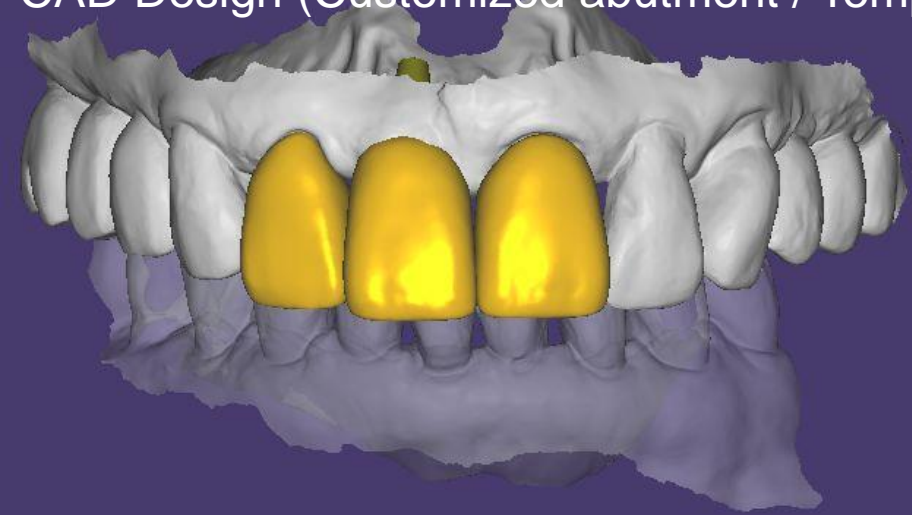


Scan Abutment

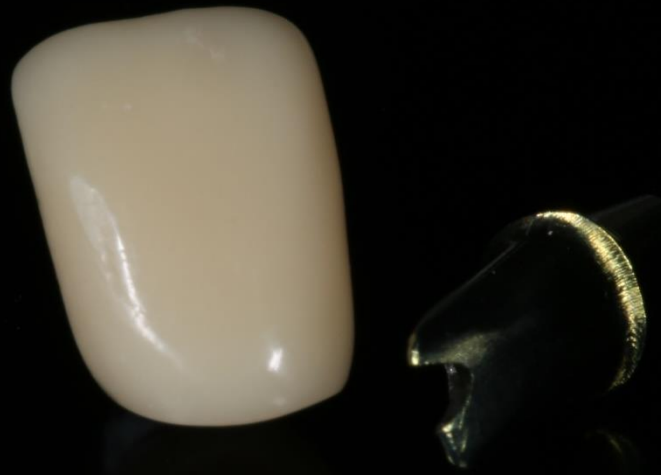Intra Oral Scanning



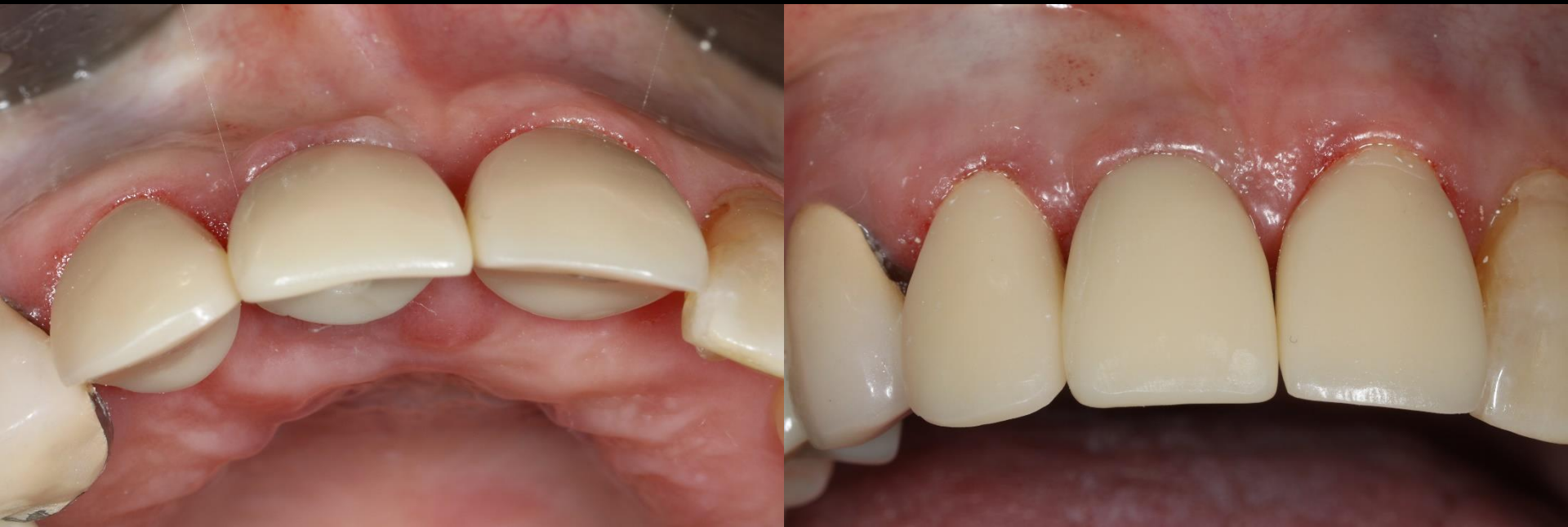CAD Design (Customized abutment / Temporary)



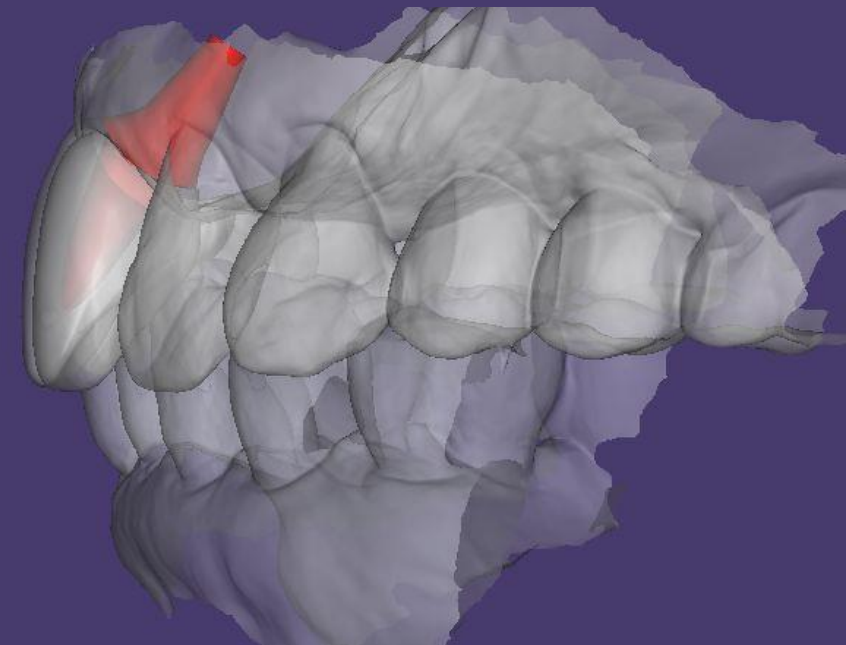
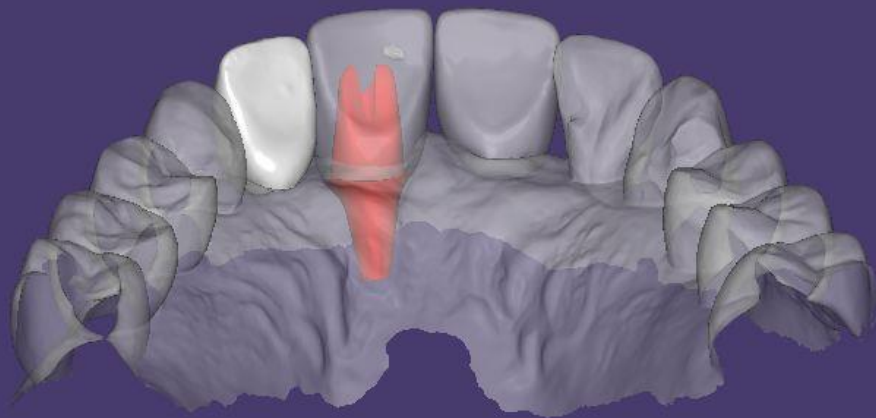
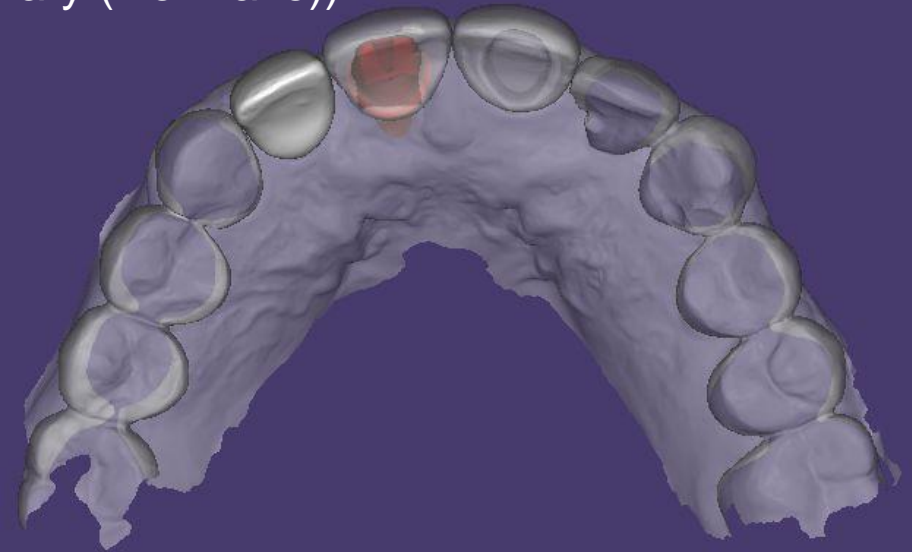
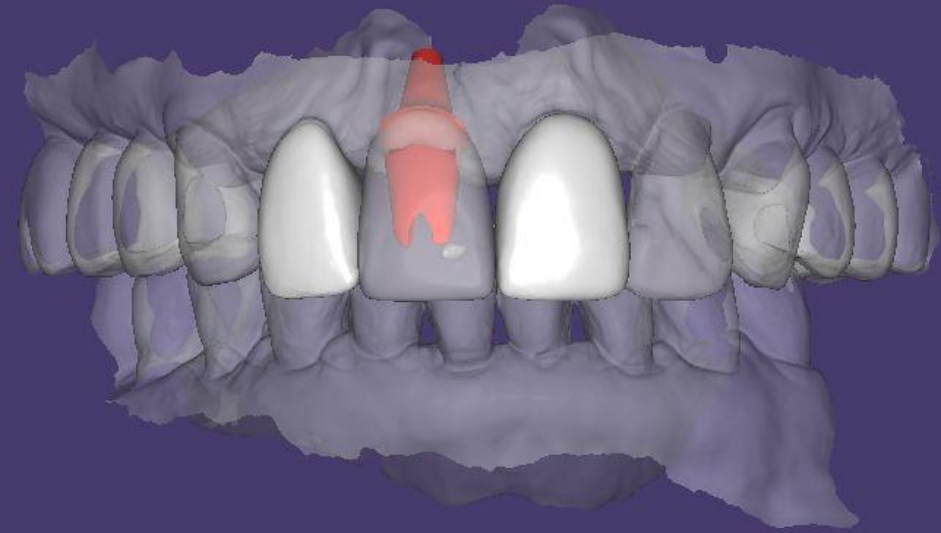
Customized abutment / Temporary



Provisional restoration (2019-05-29)



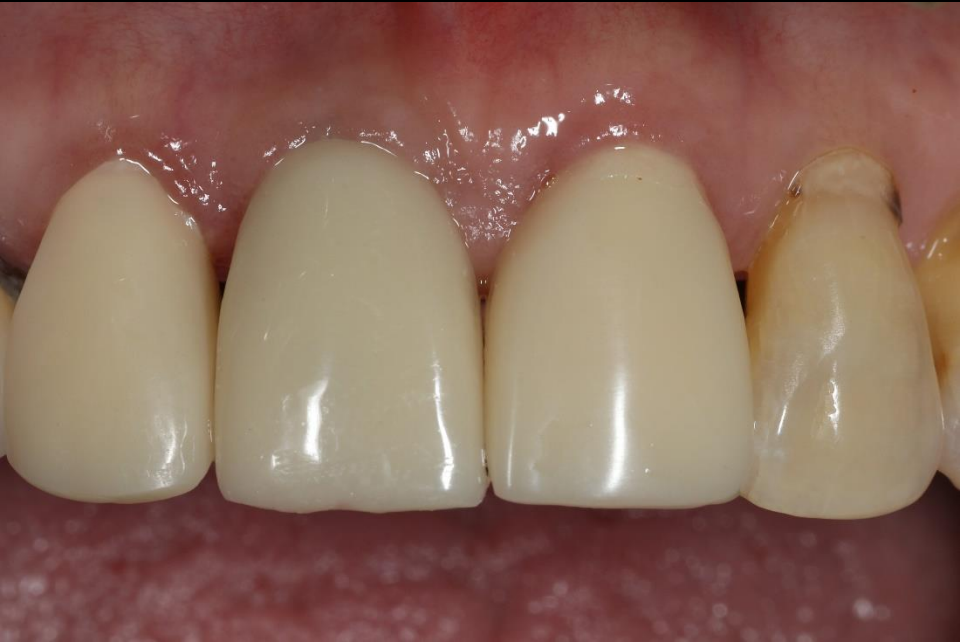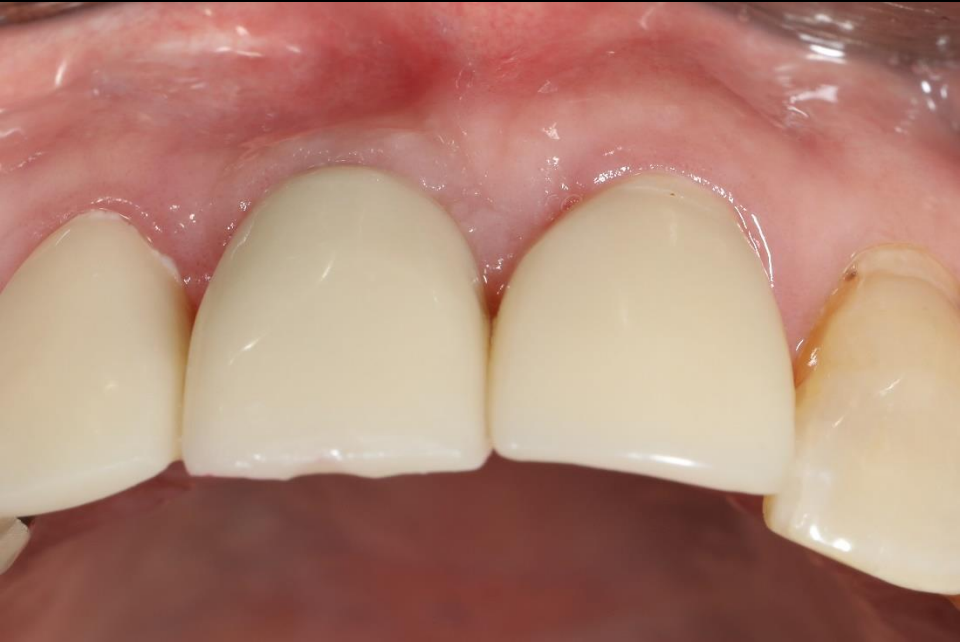CAD Design (Customized abutment / Temporary (Re-make))



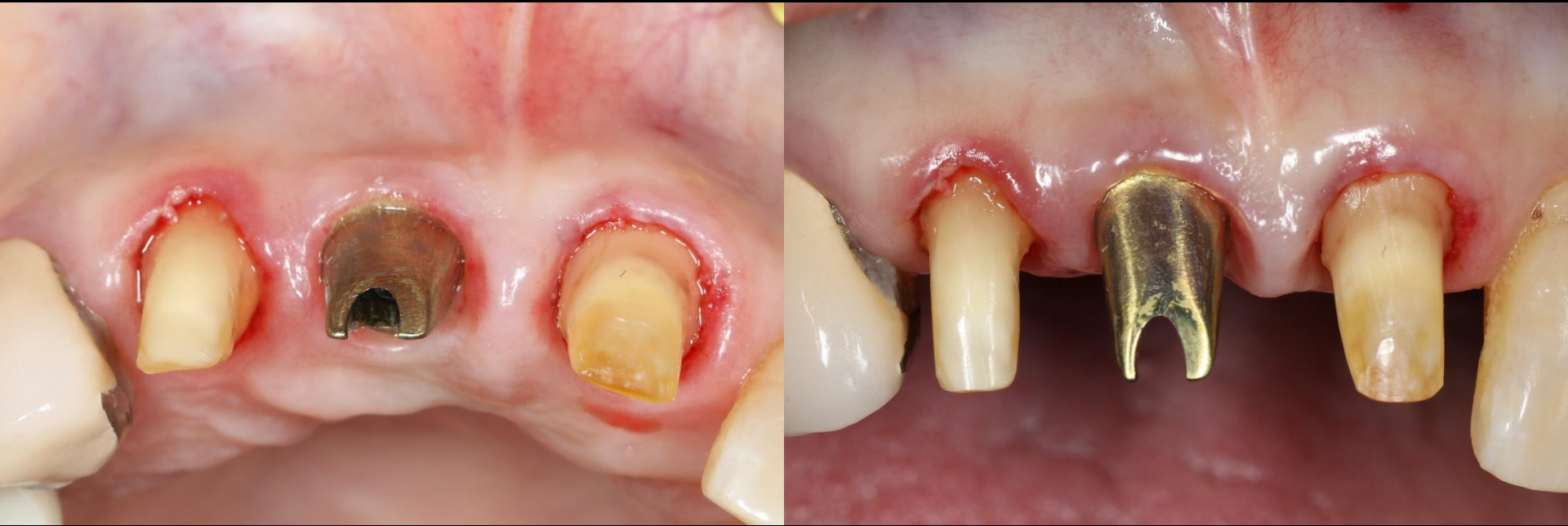Customized abutment / Temporary (Re-make)



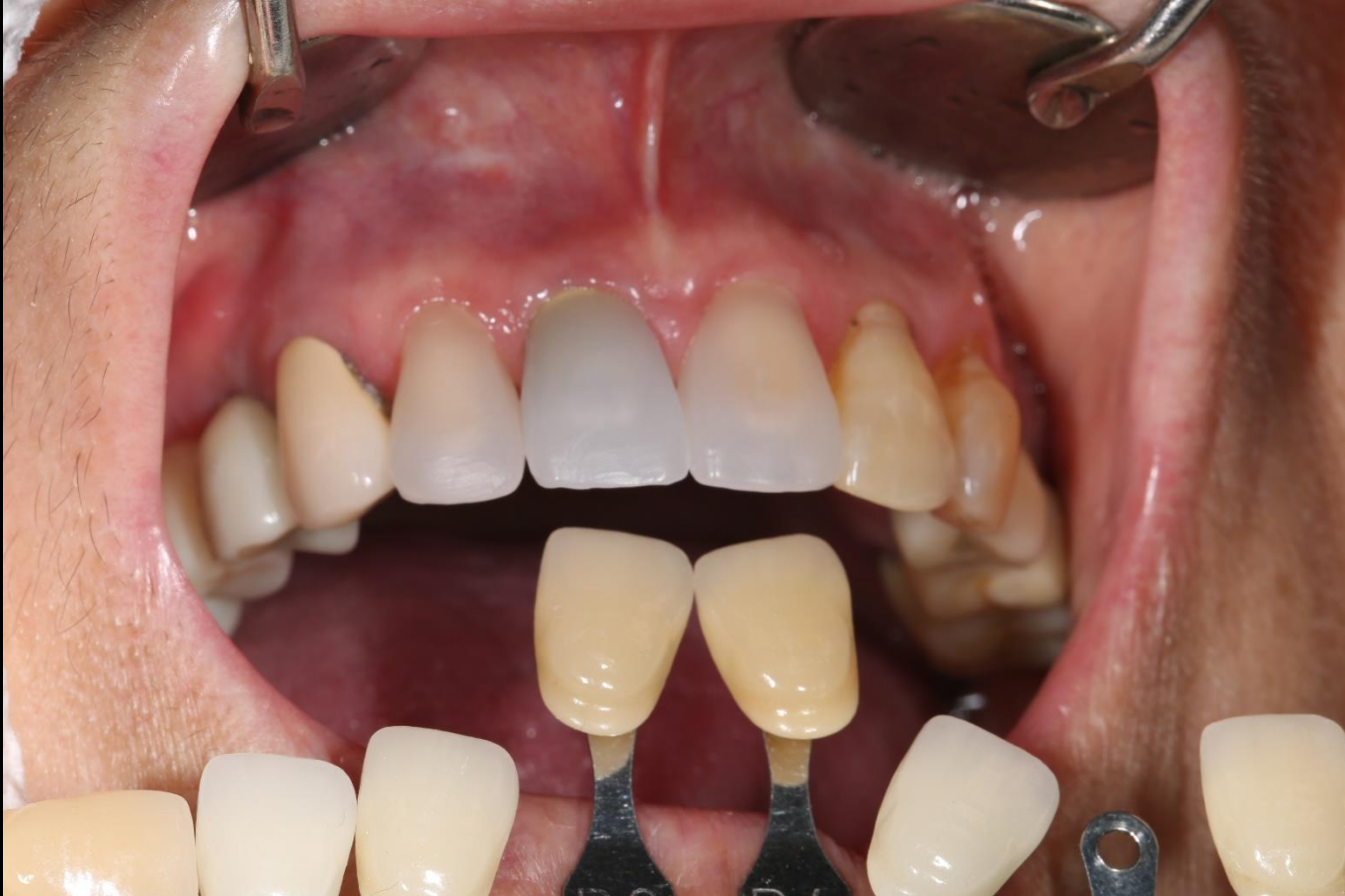Provisional restoration (Re-make) (2019-07-05)



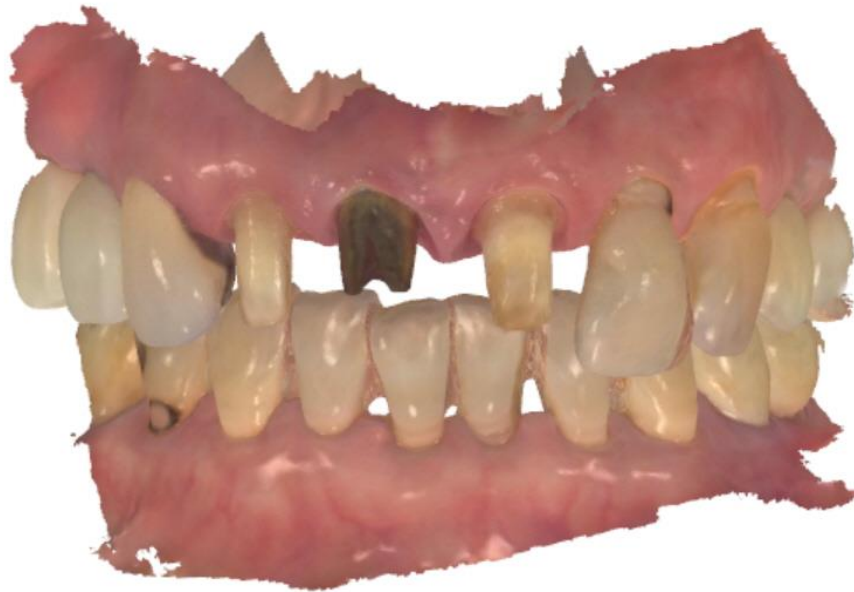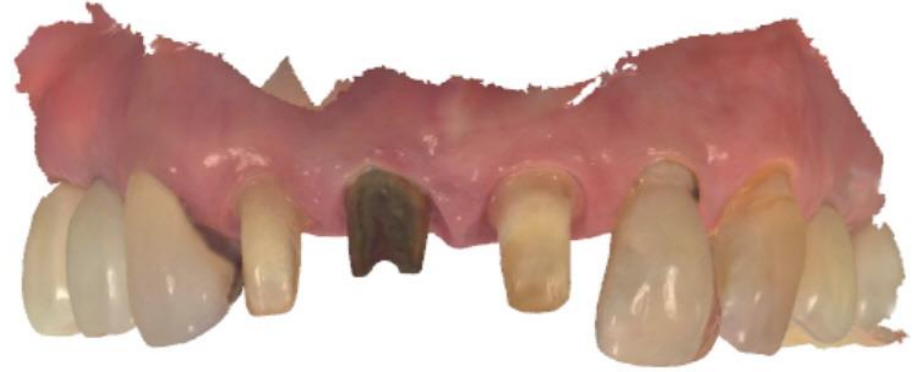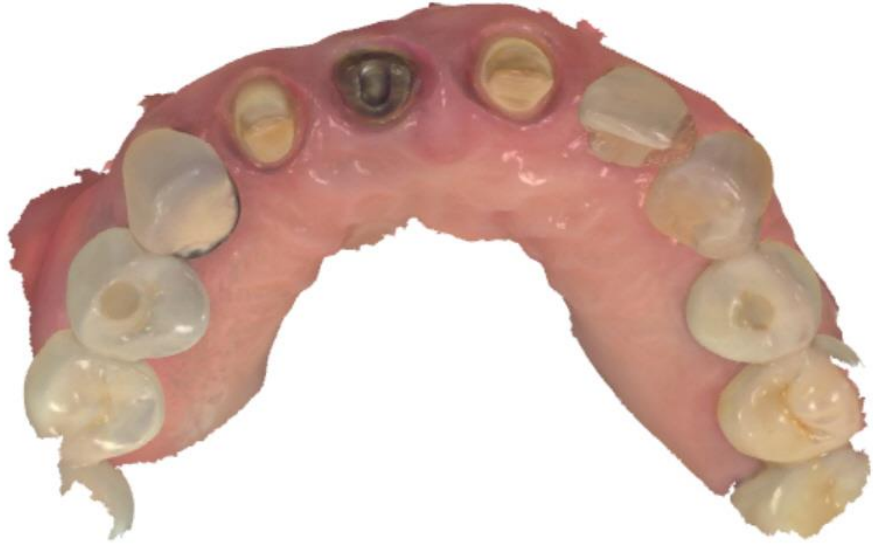Impression (2019-08-07)



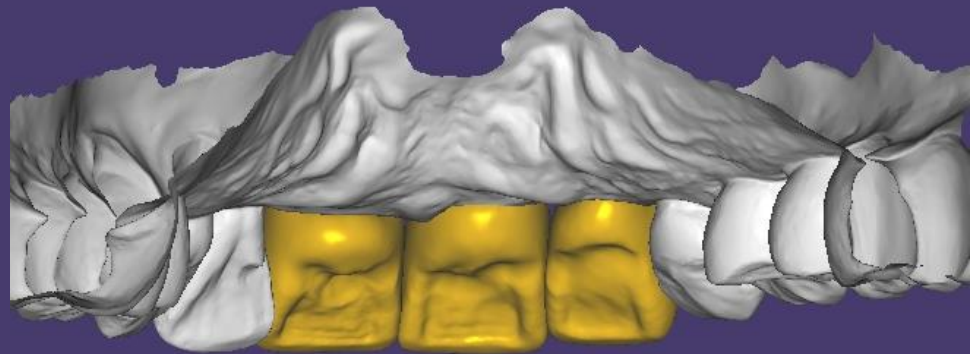
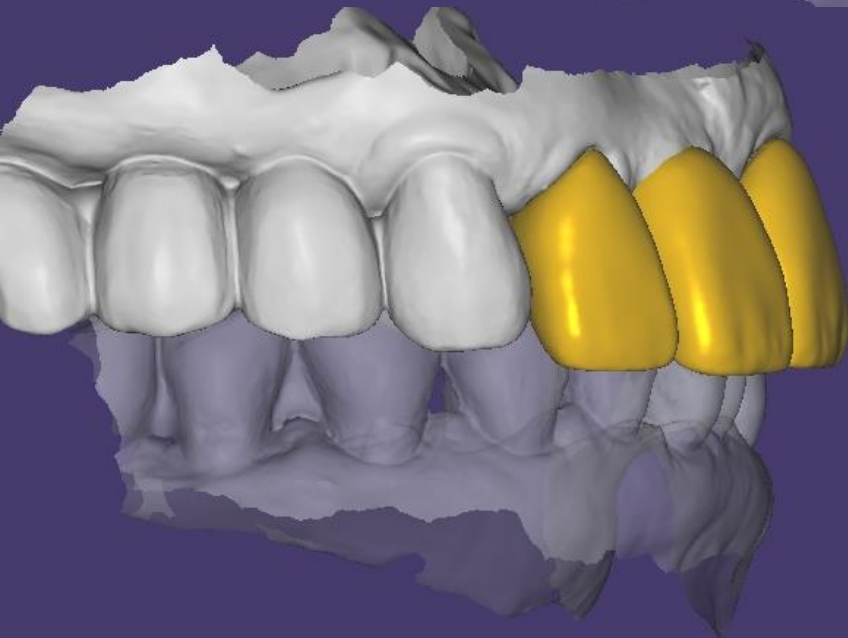
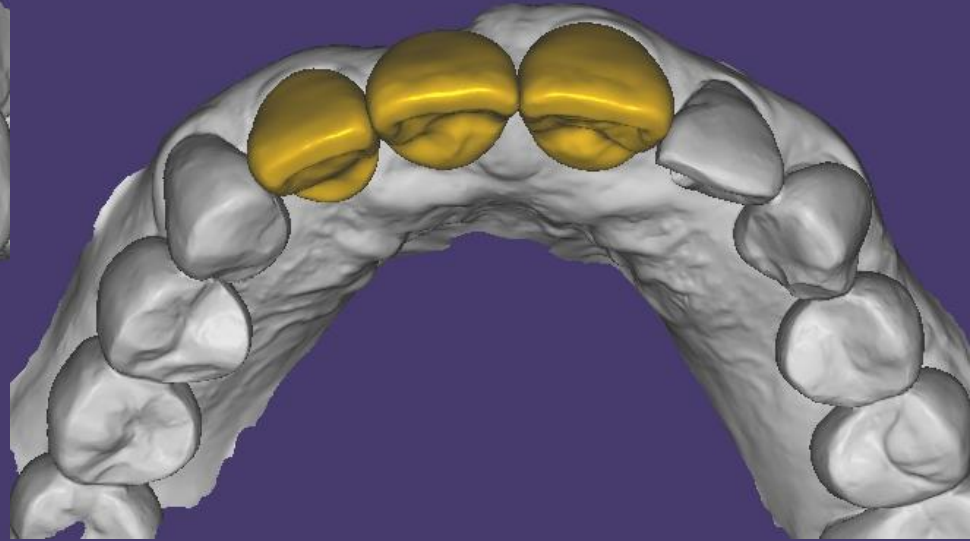
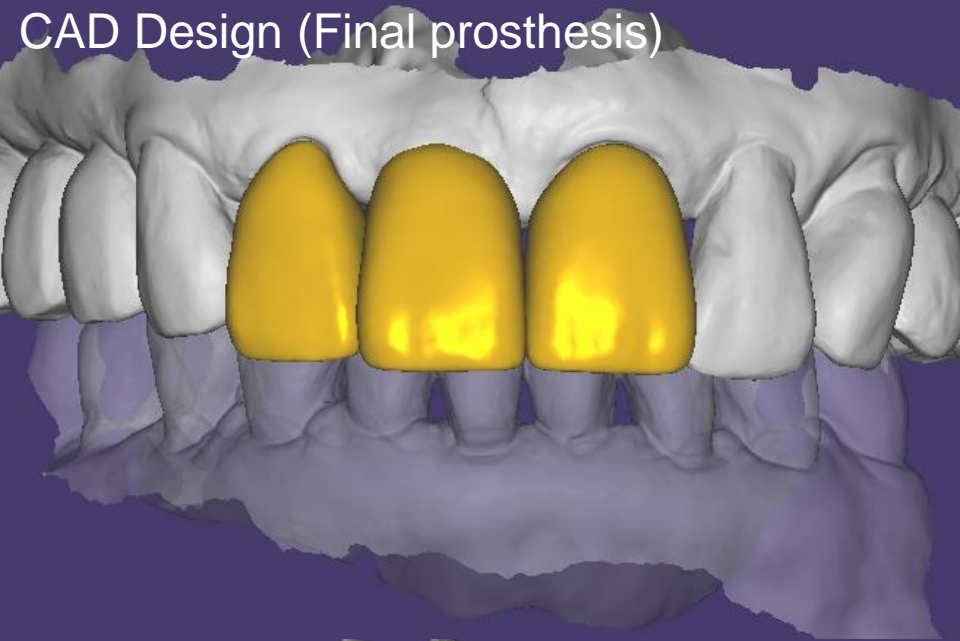
Shade taking



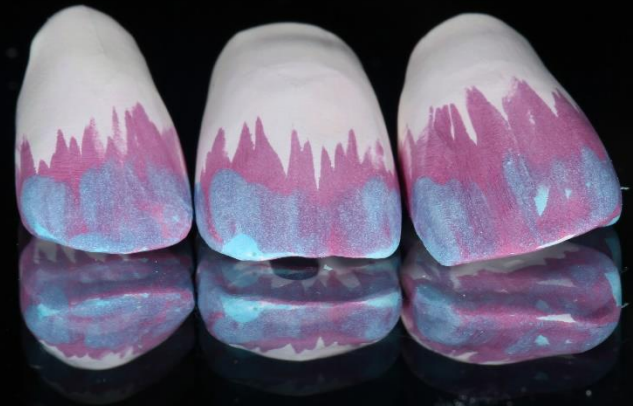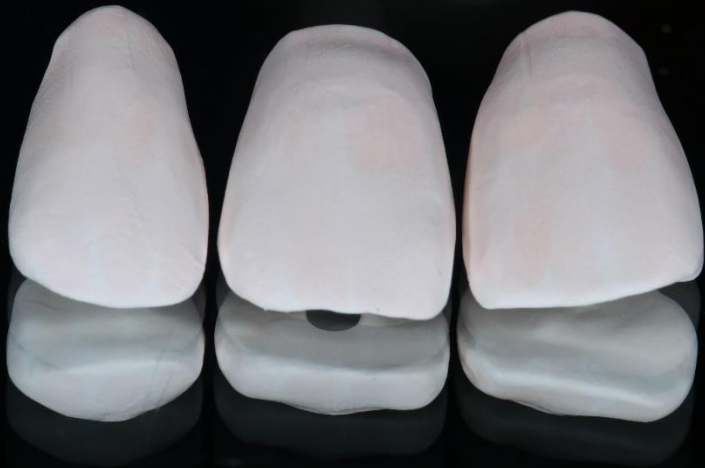Intra Oral Scanning



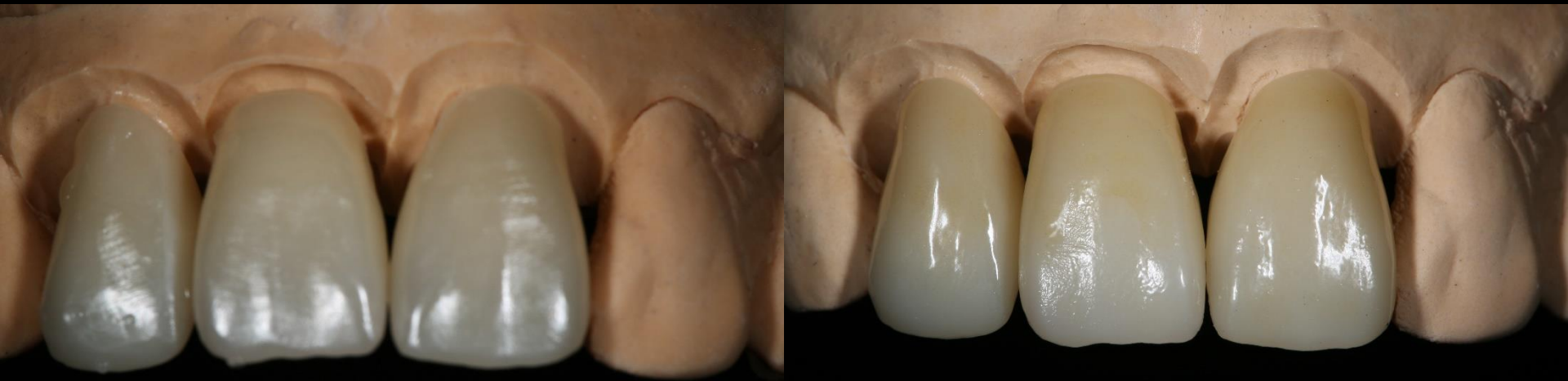CAD Design (Final prosthesis)



Brushing



Sintering / Finishing



Final prosthesis (2019-10-18)

