

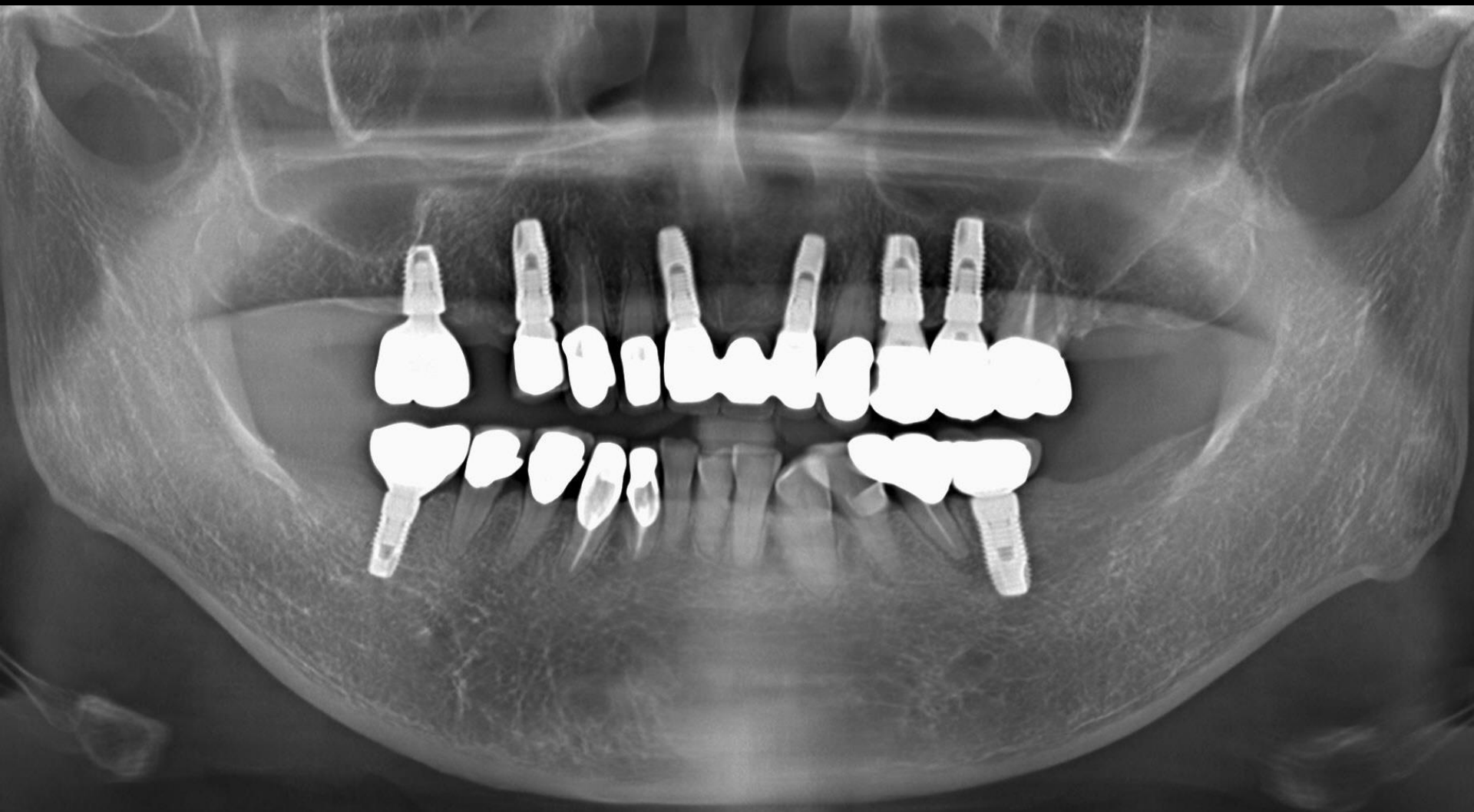
# Simple Implantation using NTI

(Tissue Level)

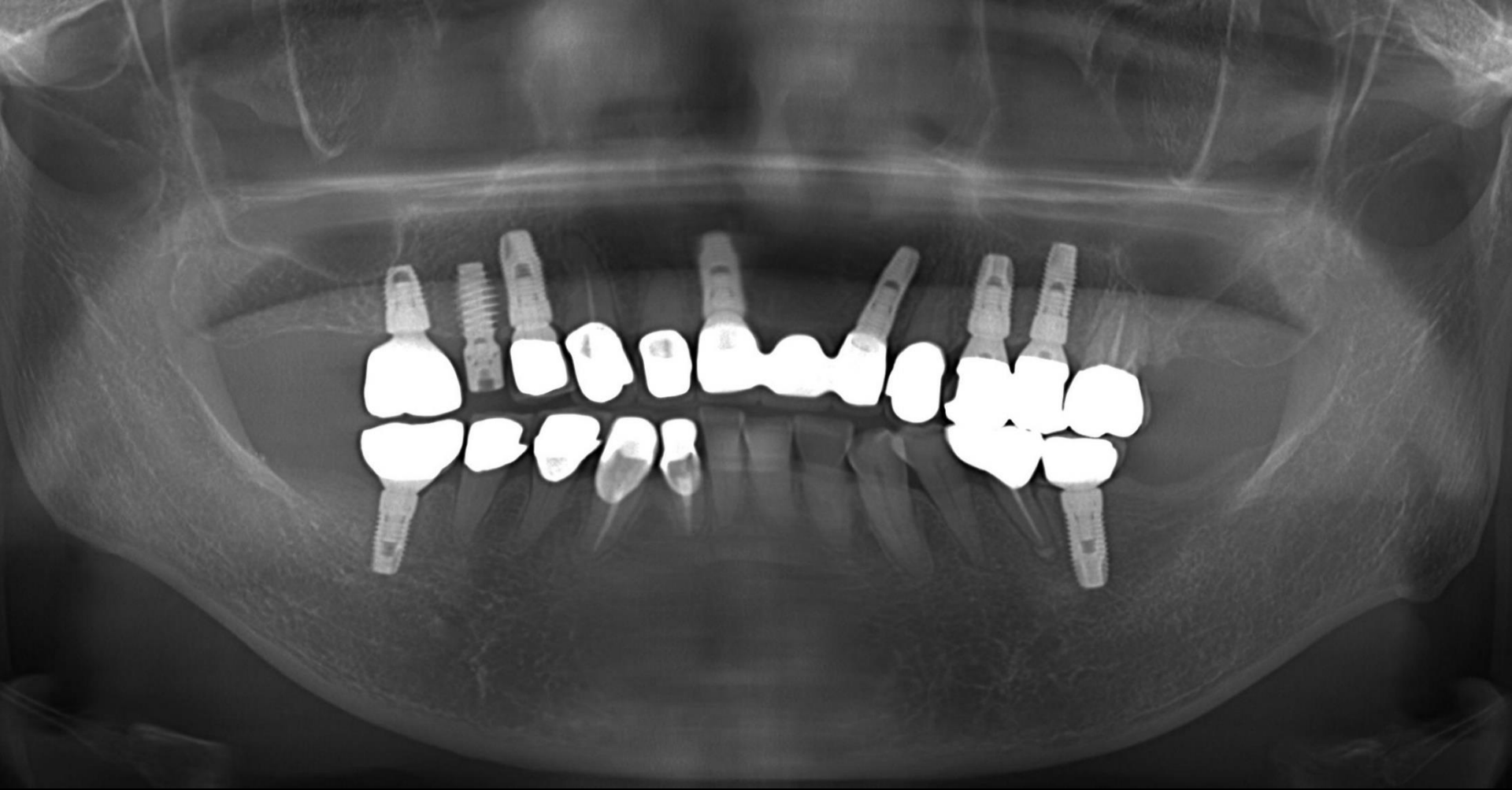
78y/F

Dr. SM Chung

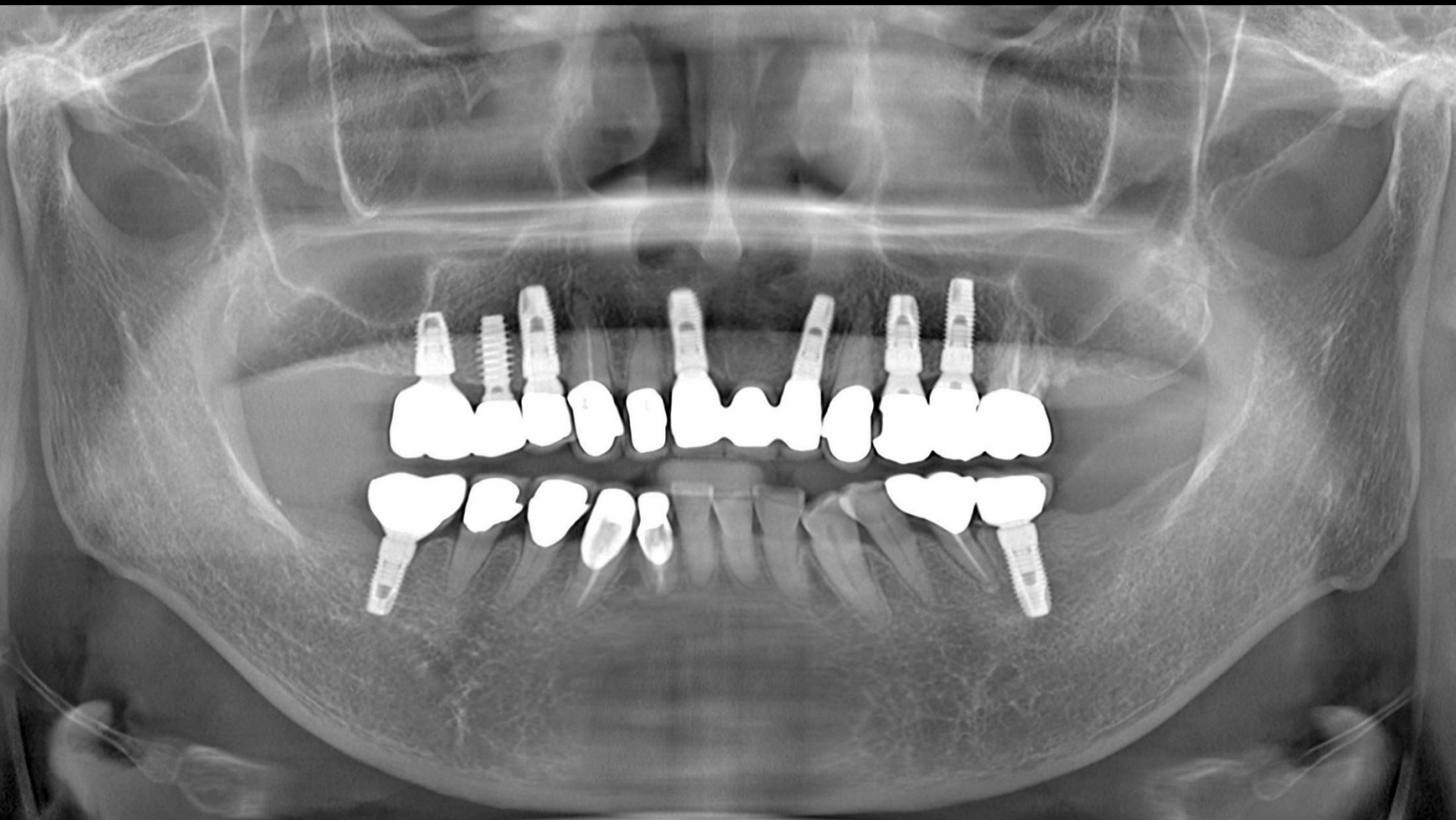
Pre-op (2019-10-30)



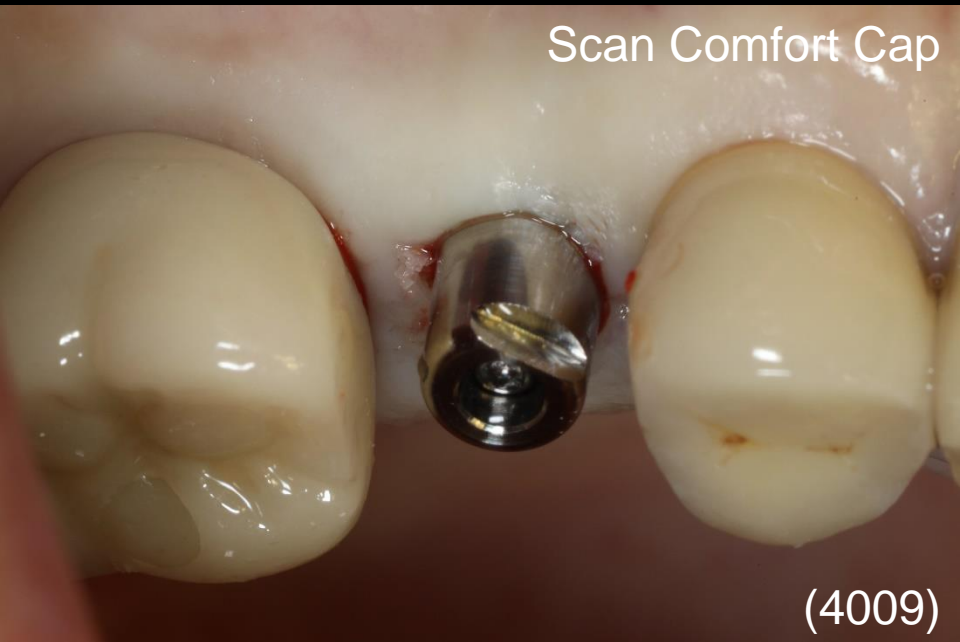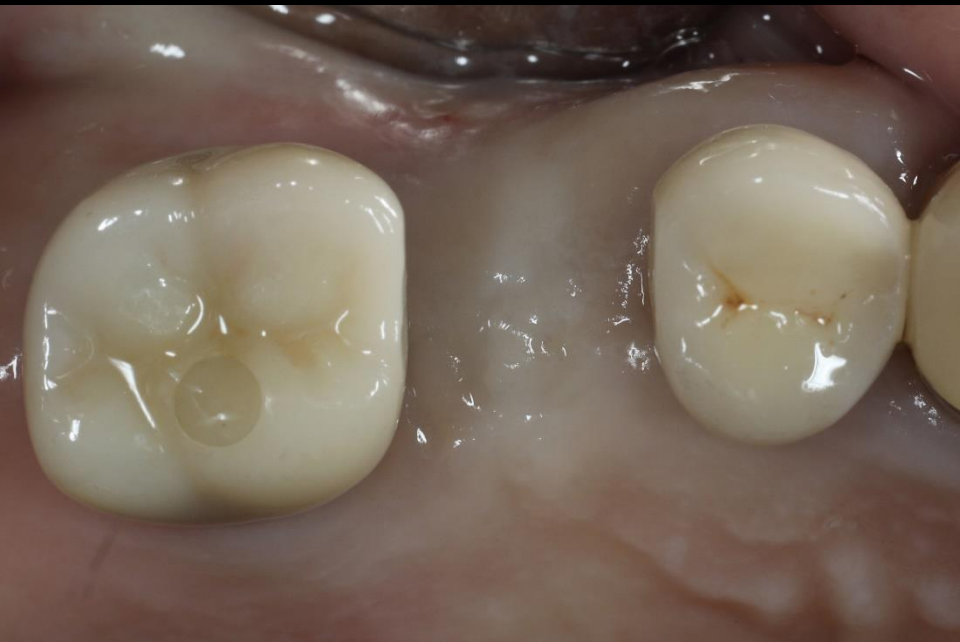Post-op (2020-02-13)



Final prosthesis (2020-08-05)



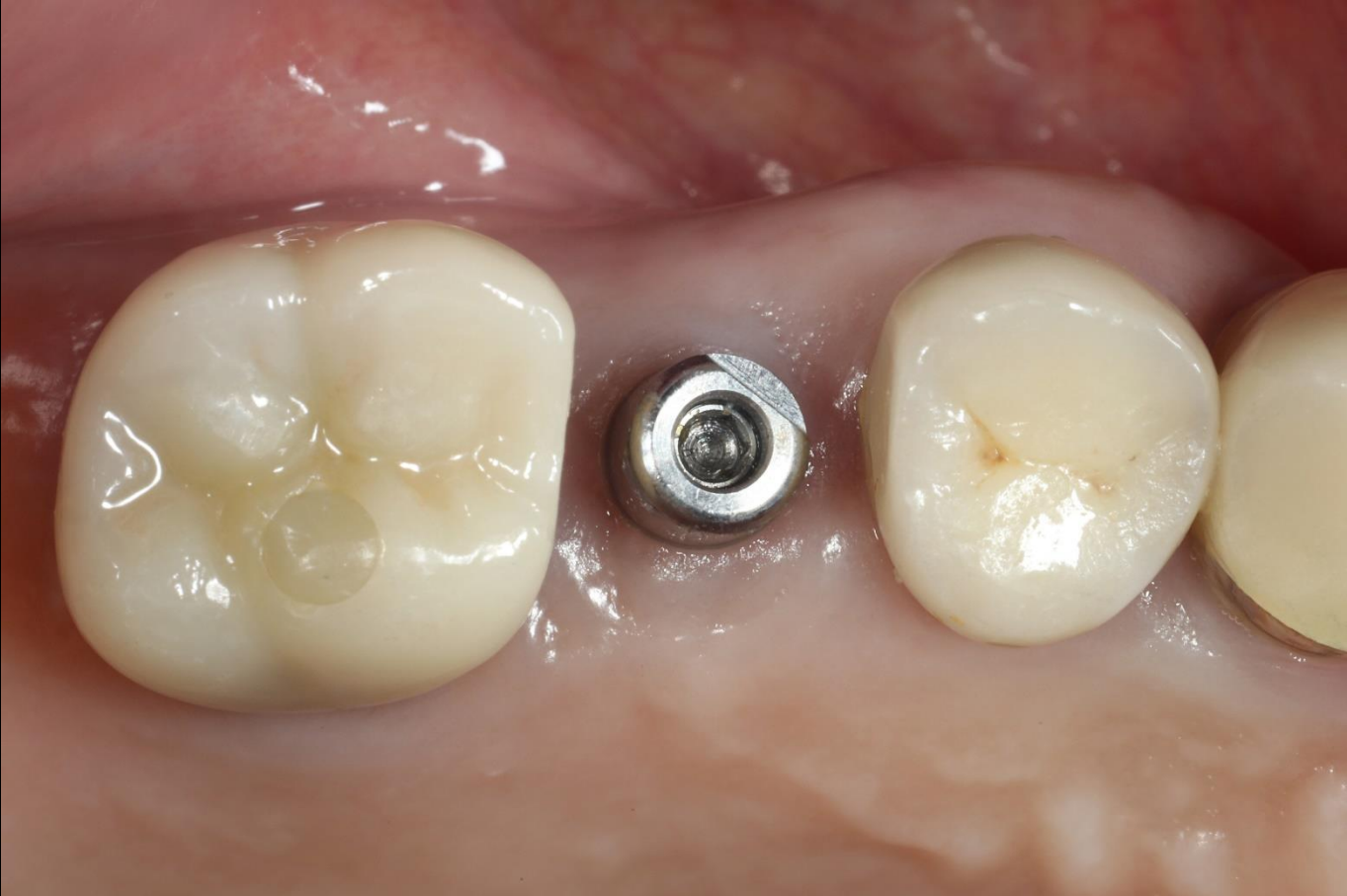Surgery (2020-02-13)



Scan Comfort Cap

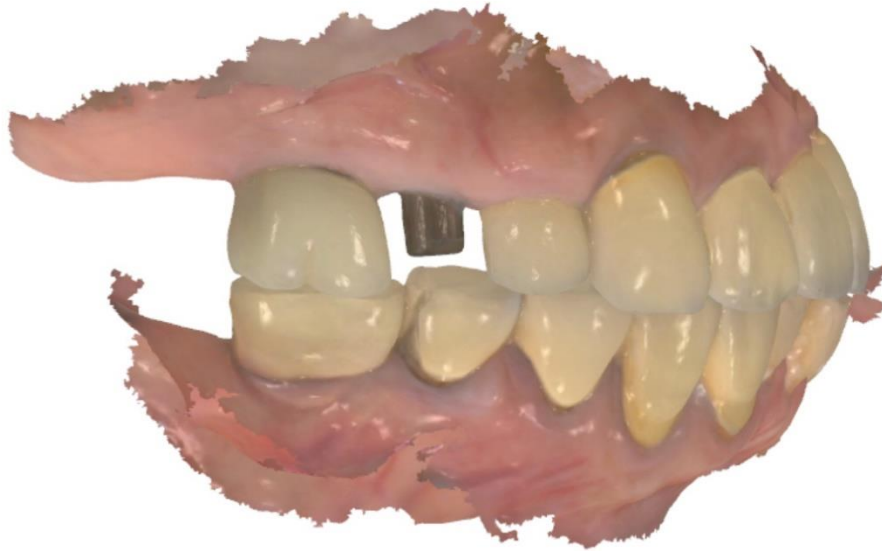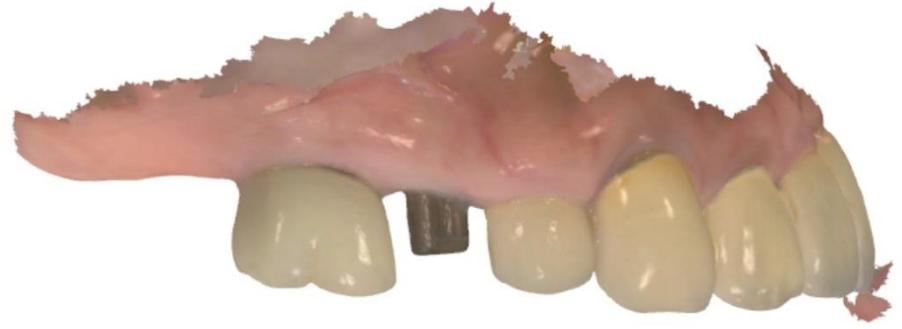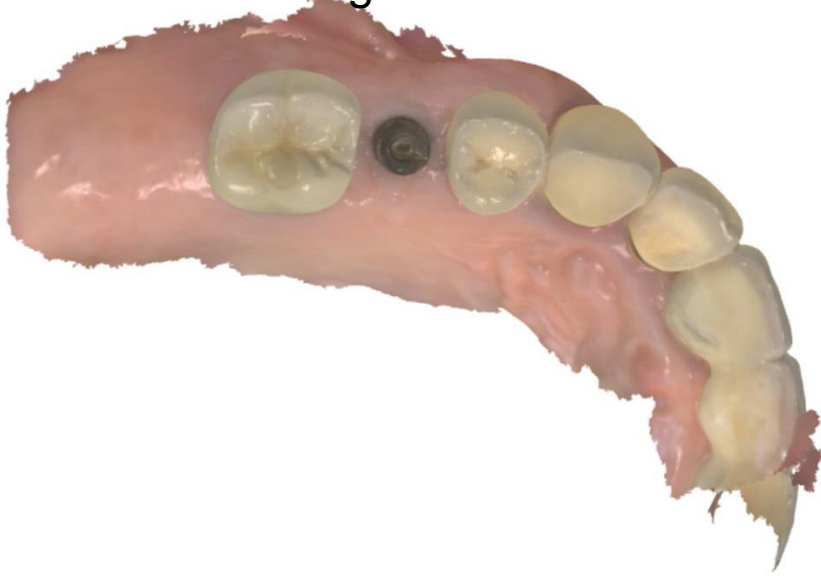(4009)

Healing : 4 months (2020-06-04)

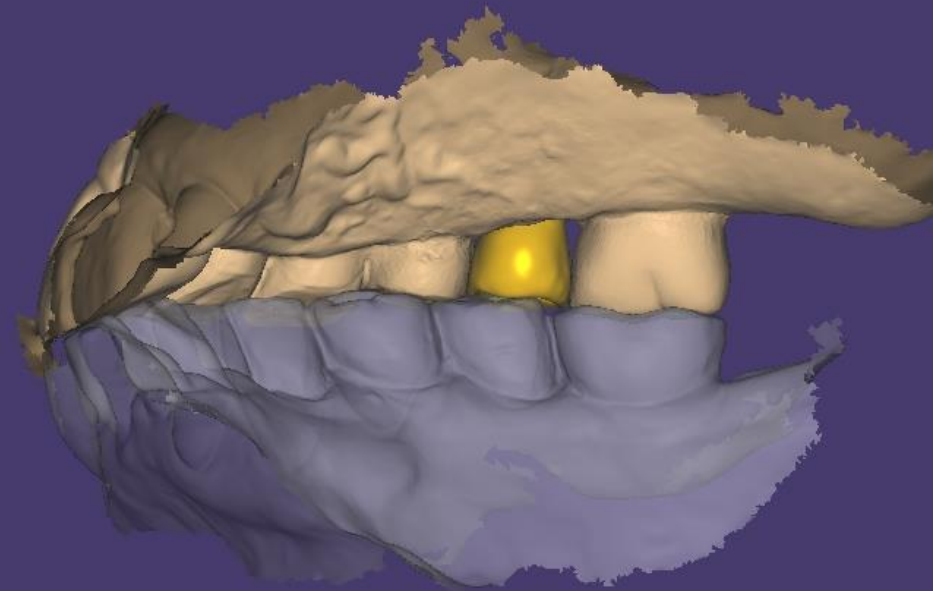
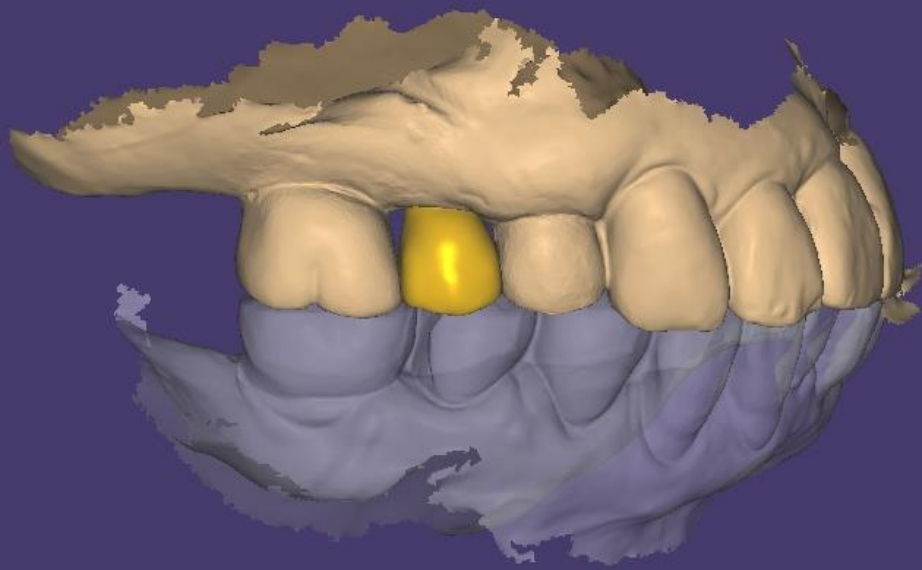
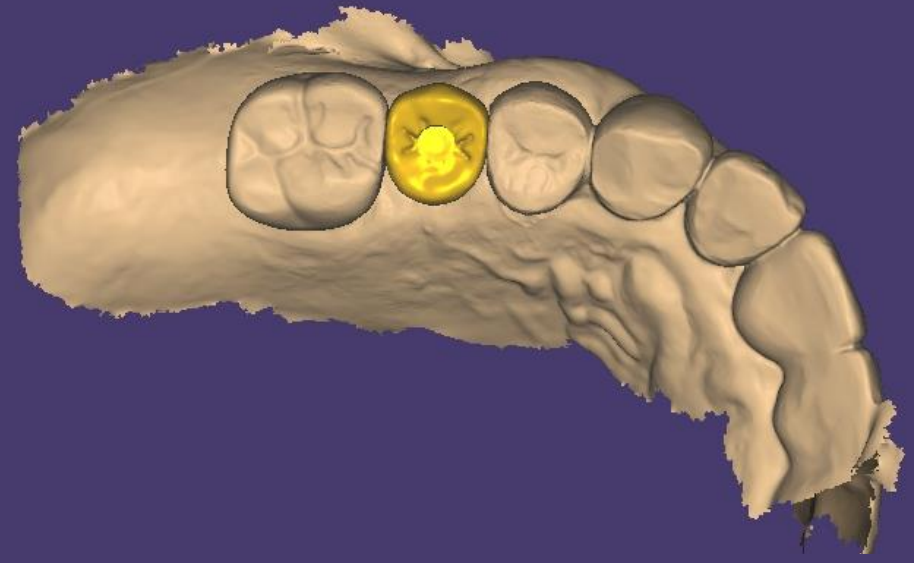
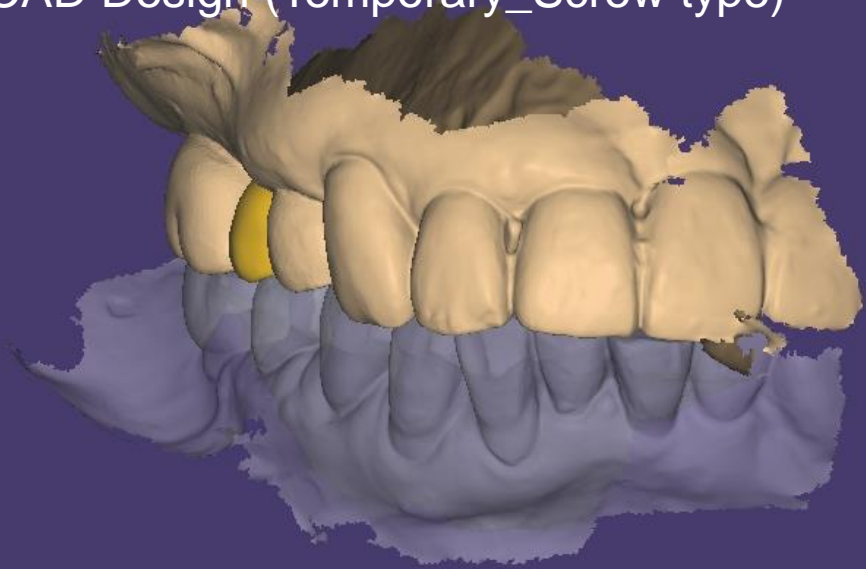




# Intra Oral Scanning

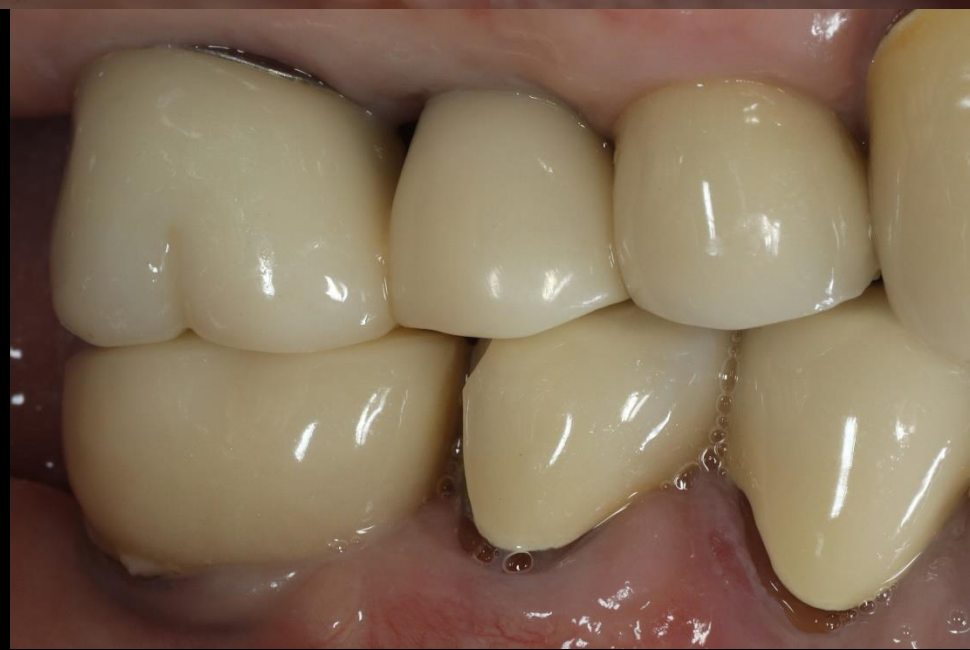
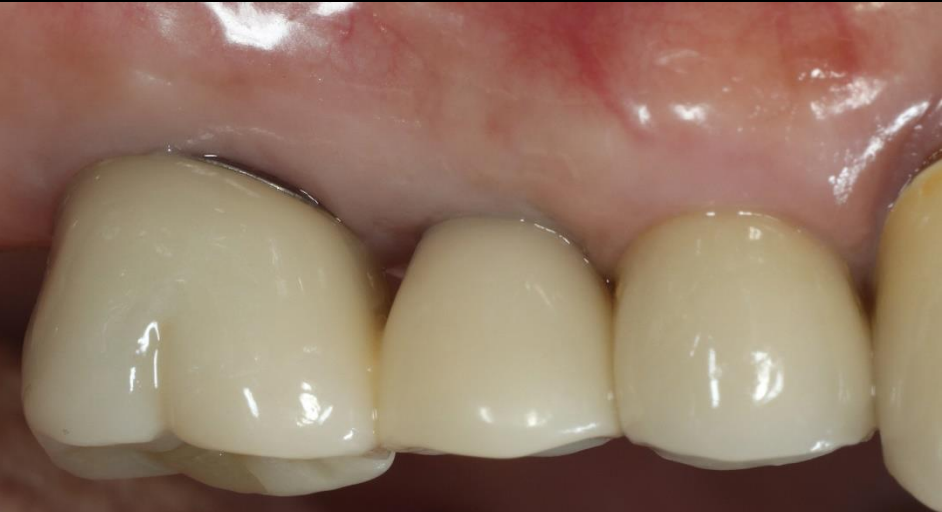
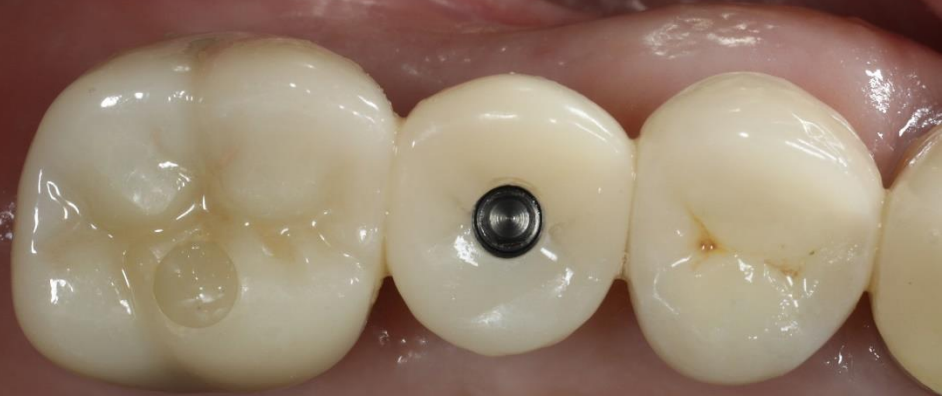# CAD Design (Temporary\_Screw type)

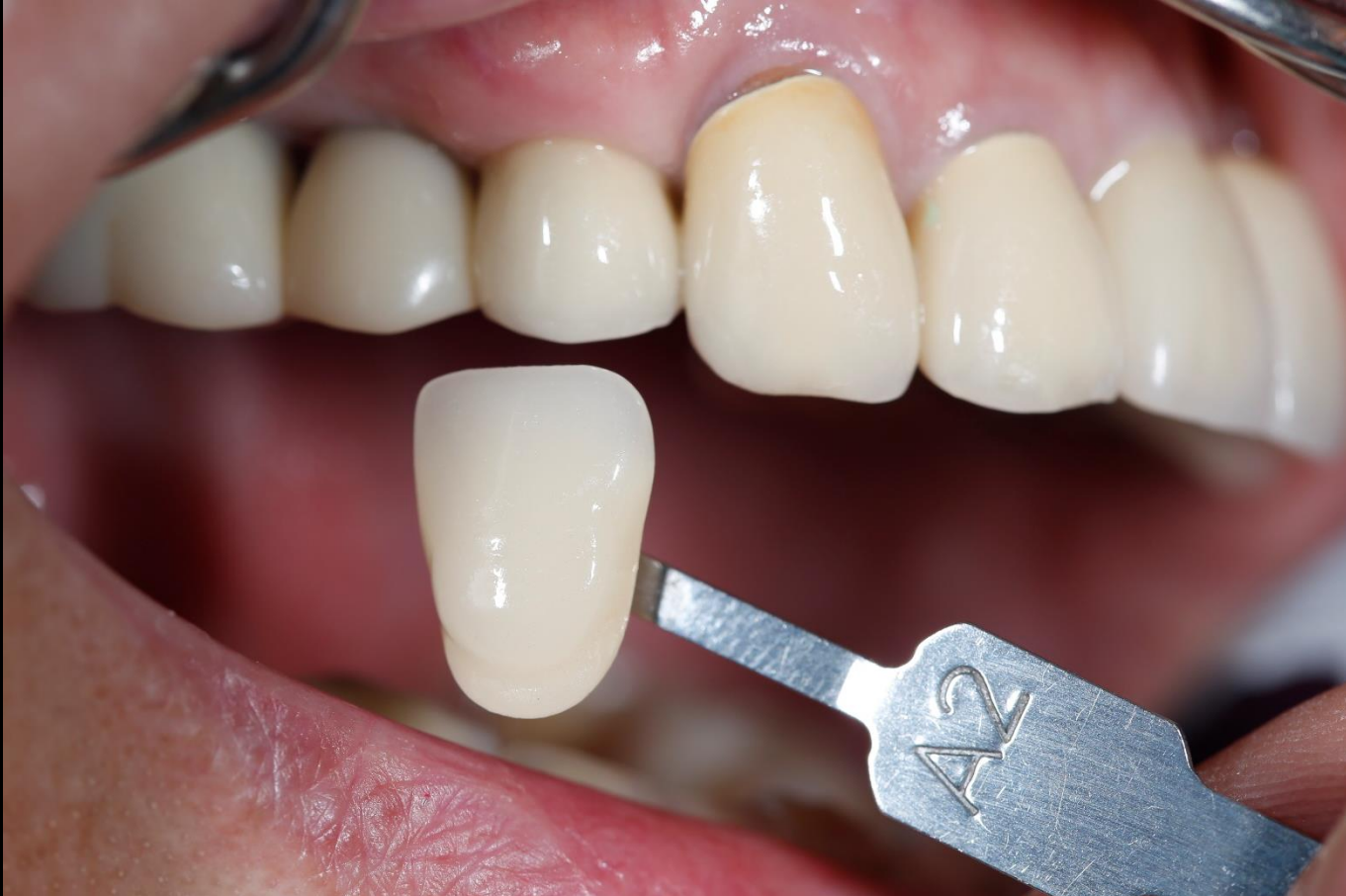



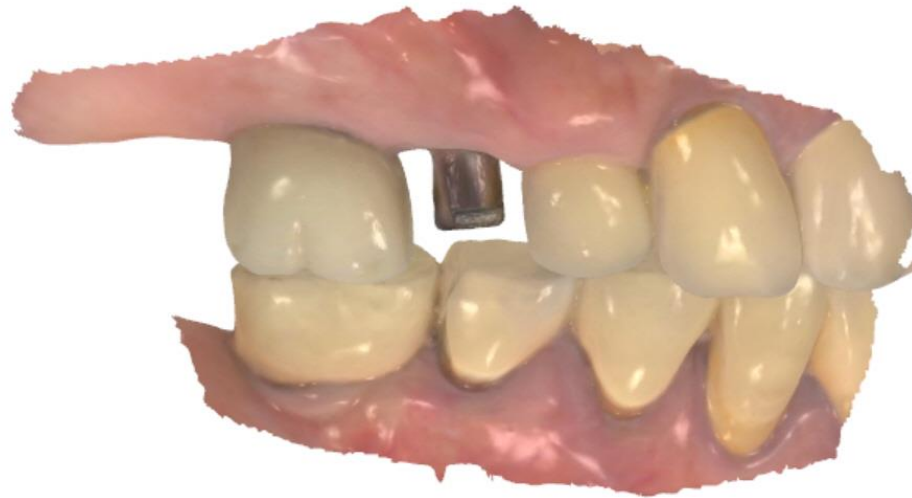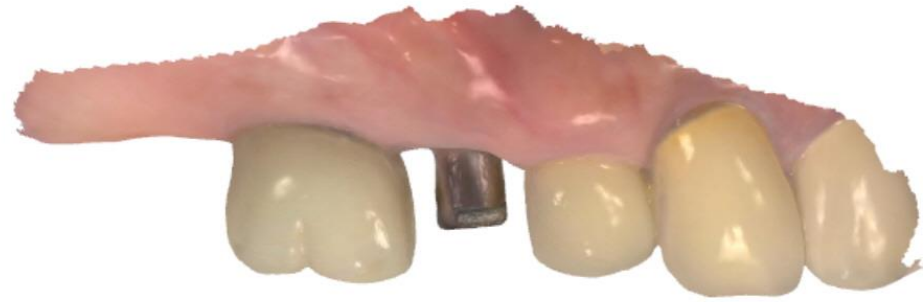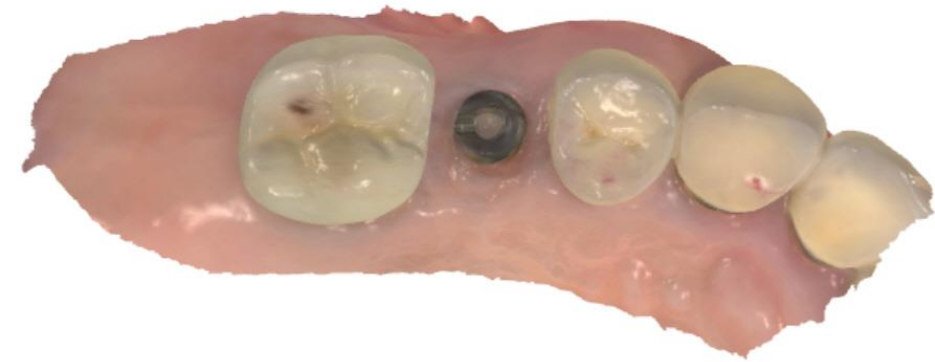Provisional restoration (2020-06-18)



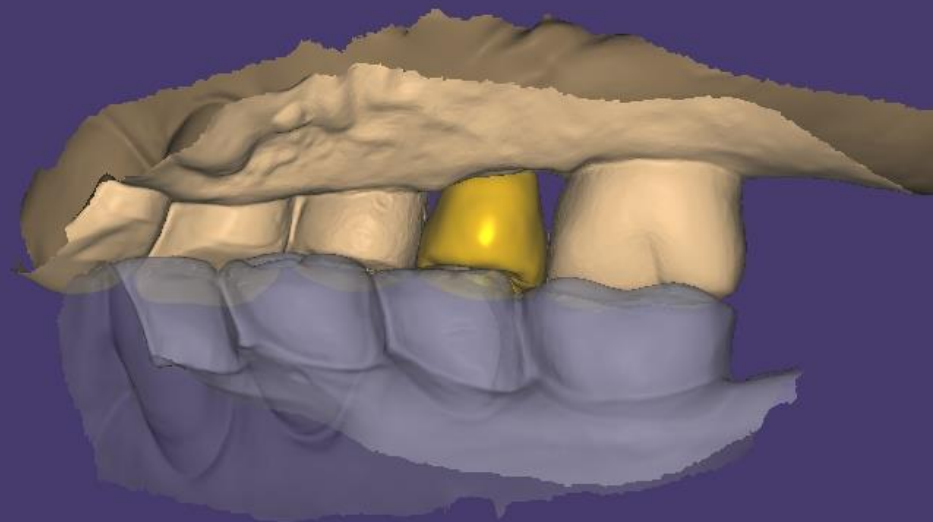
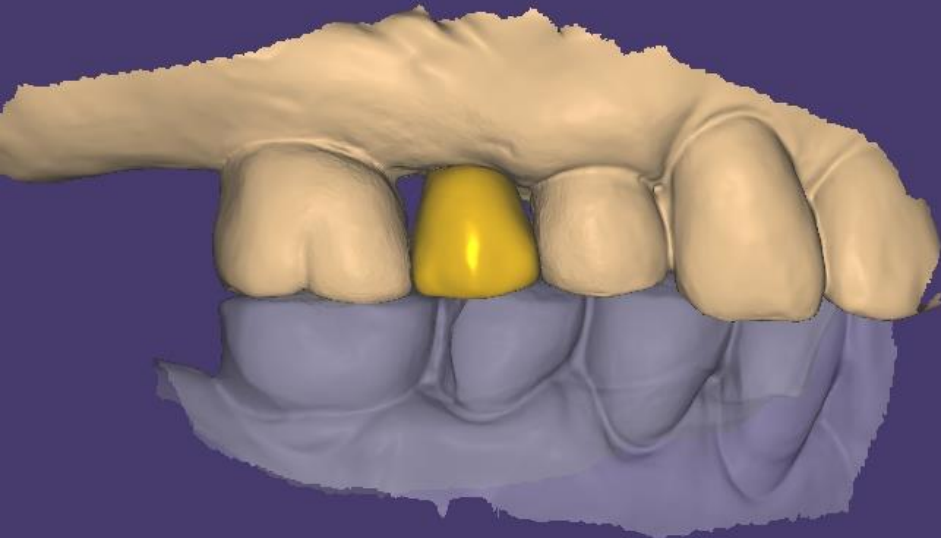
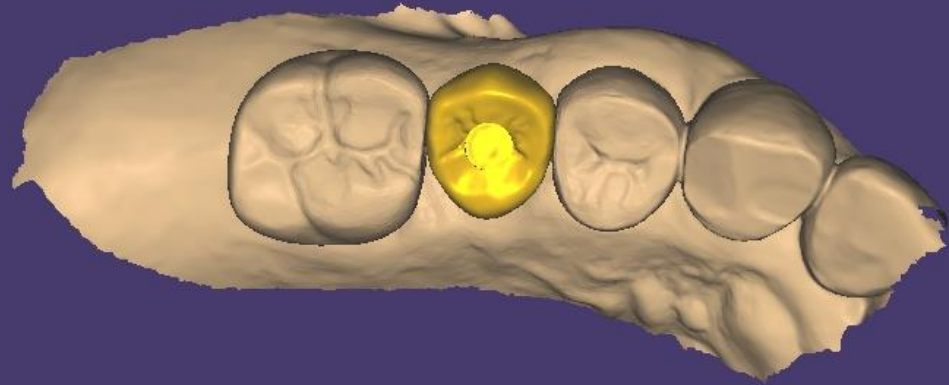
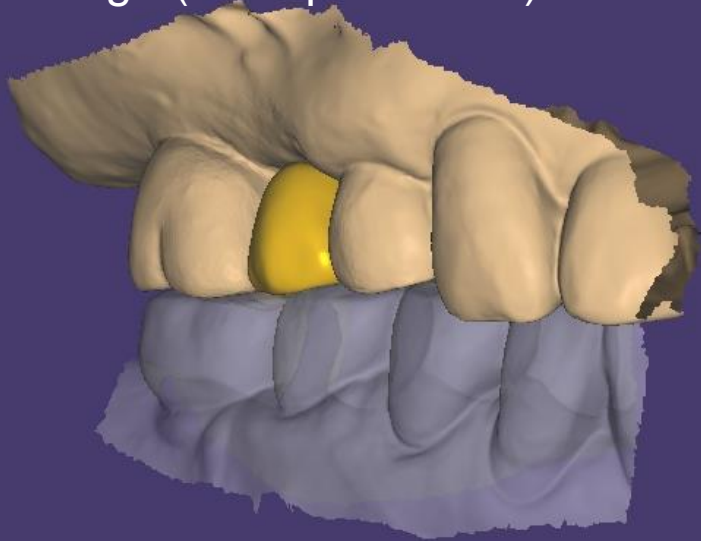# Shade taking



# Intra Oral Scanning

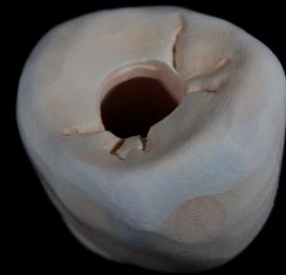
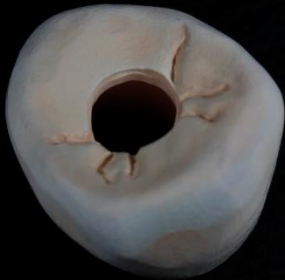
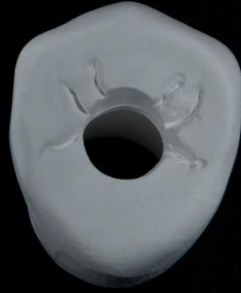# CAD Design (Final prosthesis)

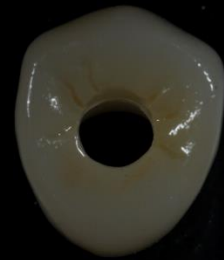



Milling / Brushing

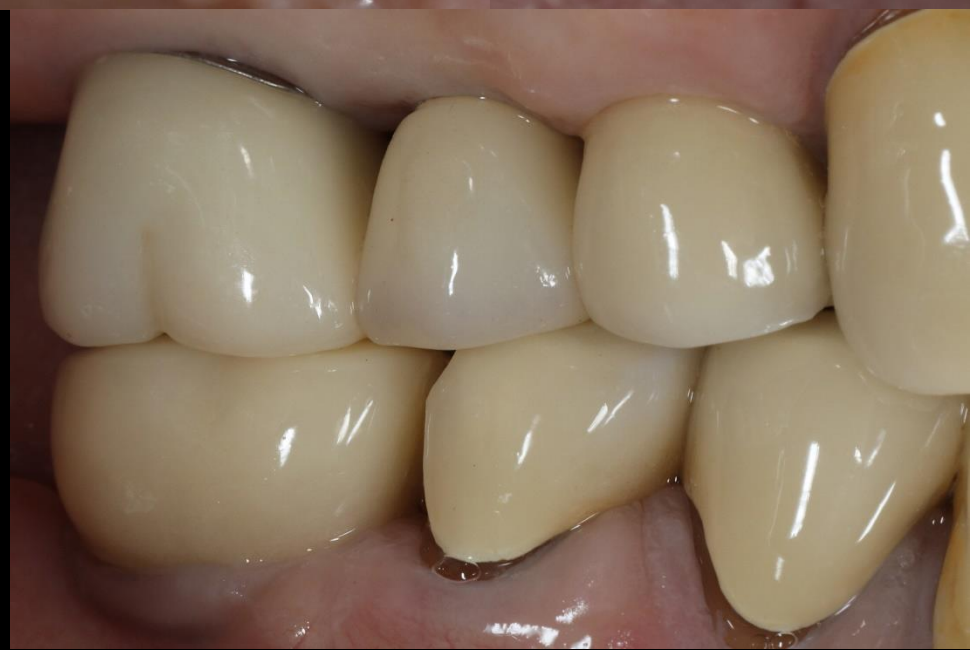
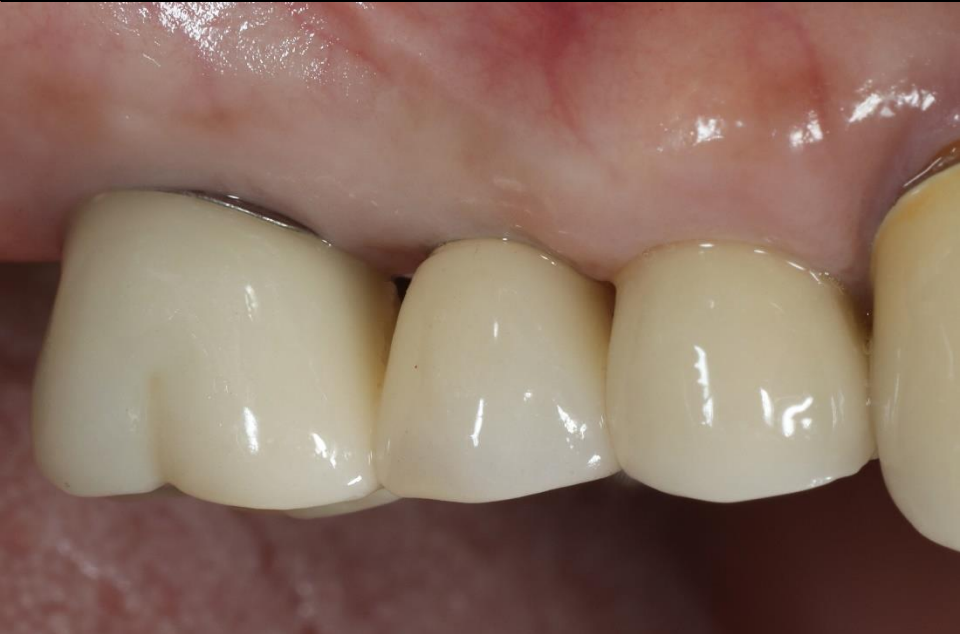
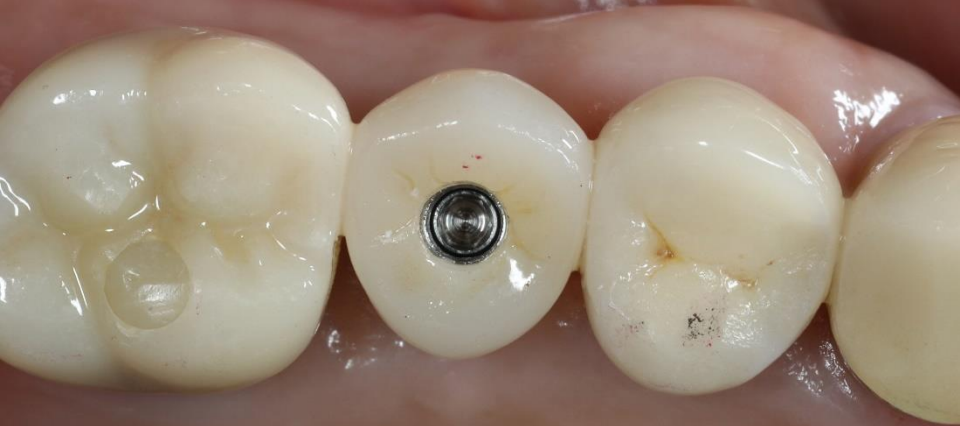Sintering / Finishing





Final prosthesis (2020-08-05)



HRF (2020-09-09)

