

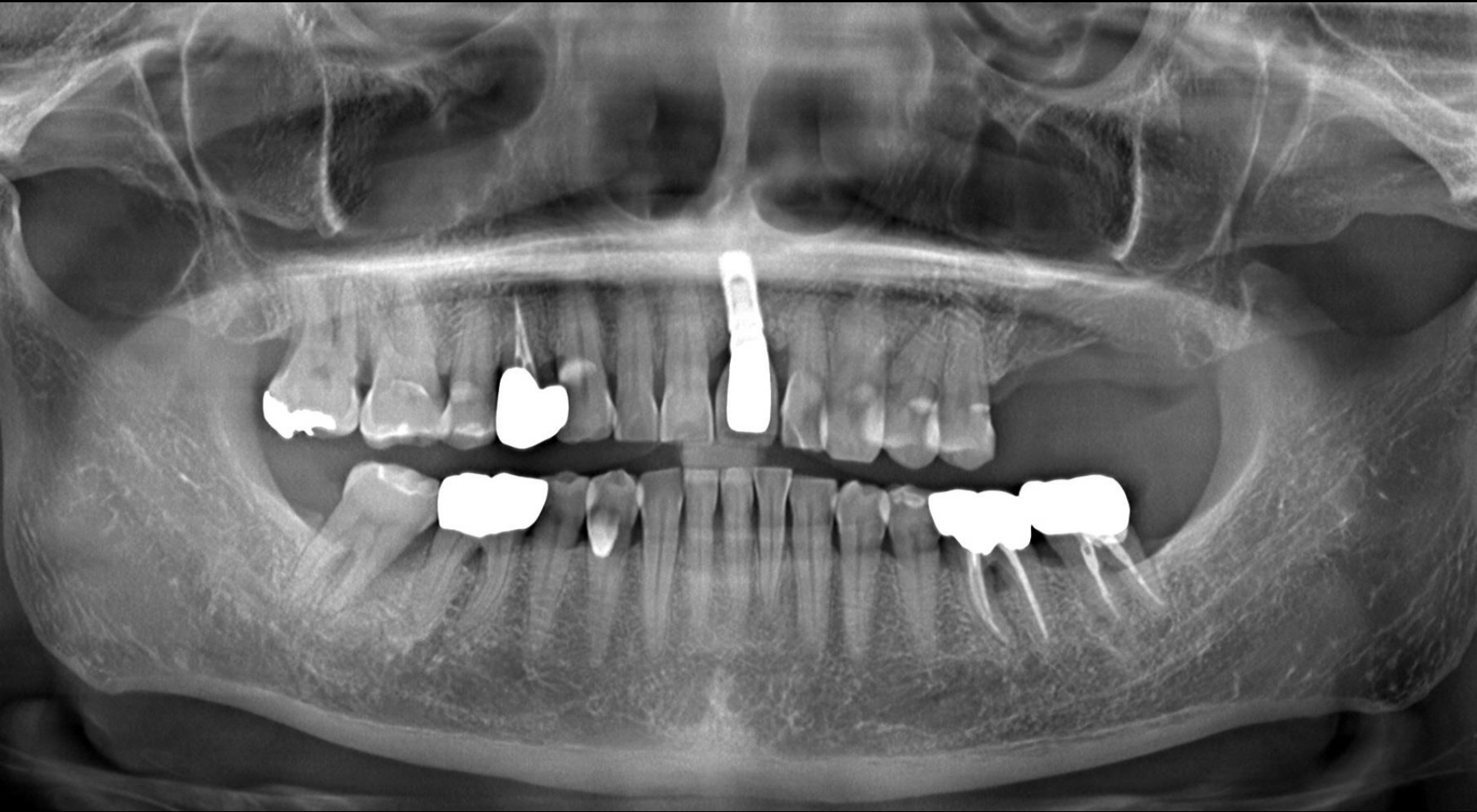
NTI installation with Osteotome

(Tissue Level, Osteotome, Implant Guide Kit)

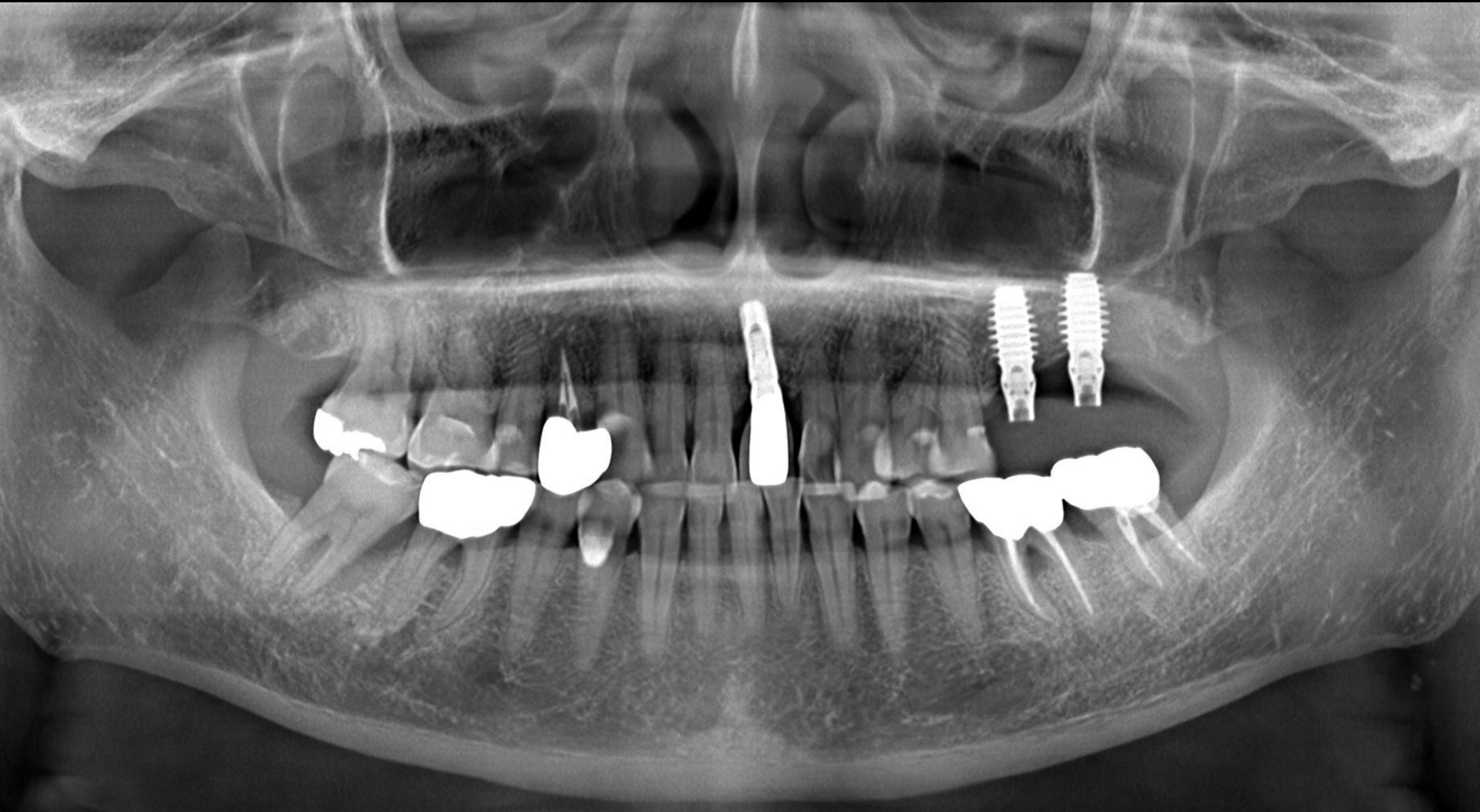
58y/F

Dr. SM Chung

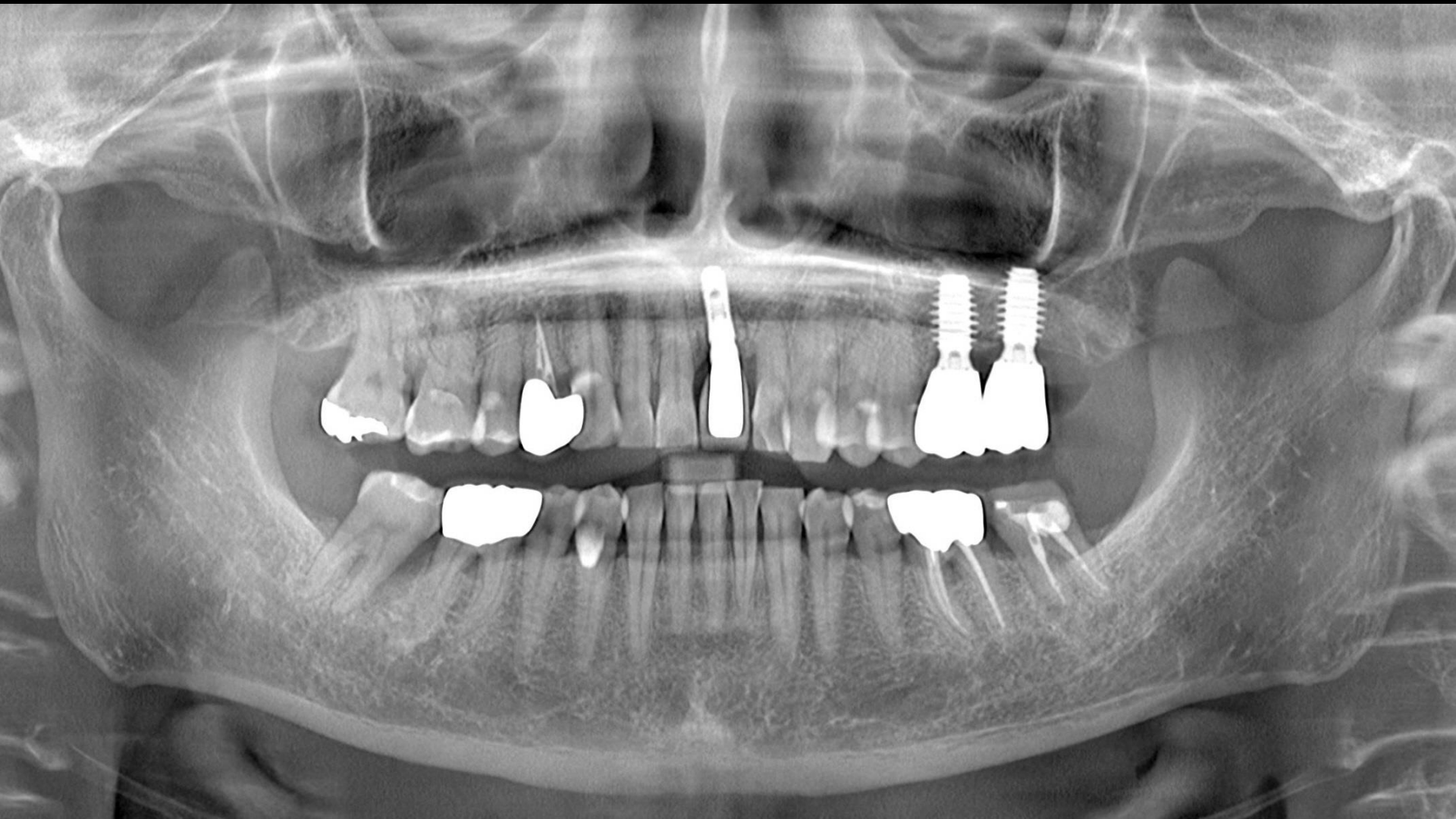Pre-op (2019-12-12)



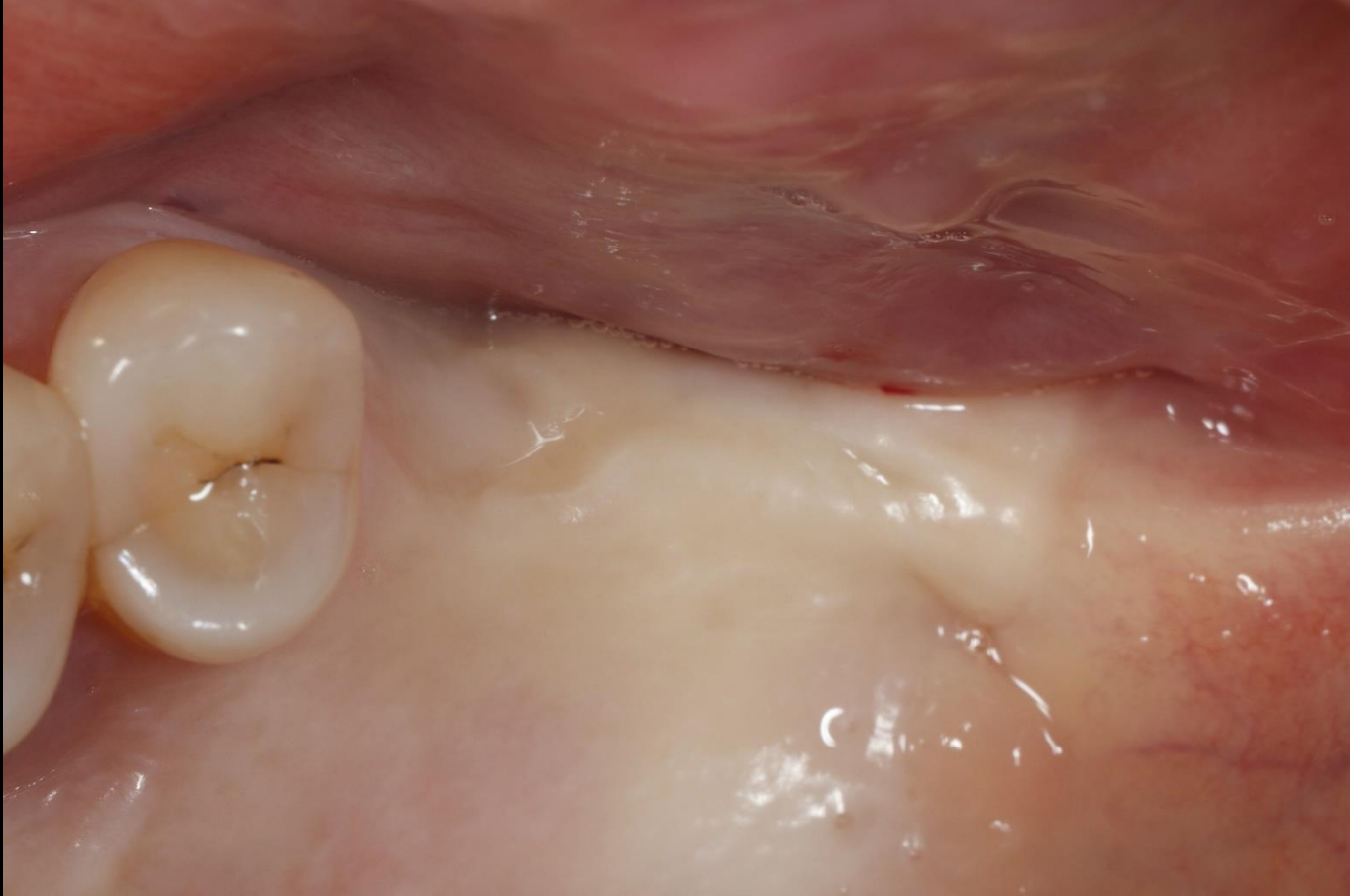
Post-op (2019-12-12)

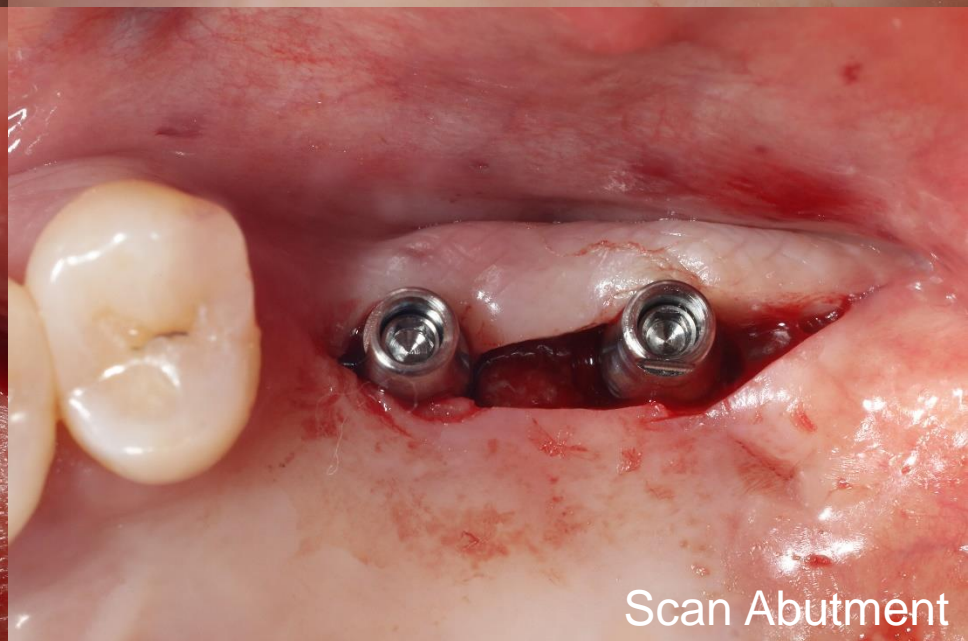
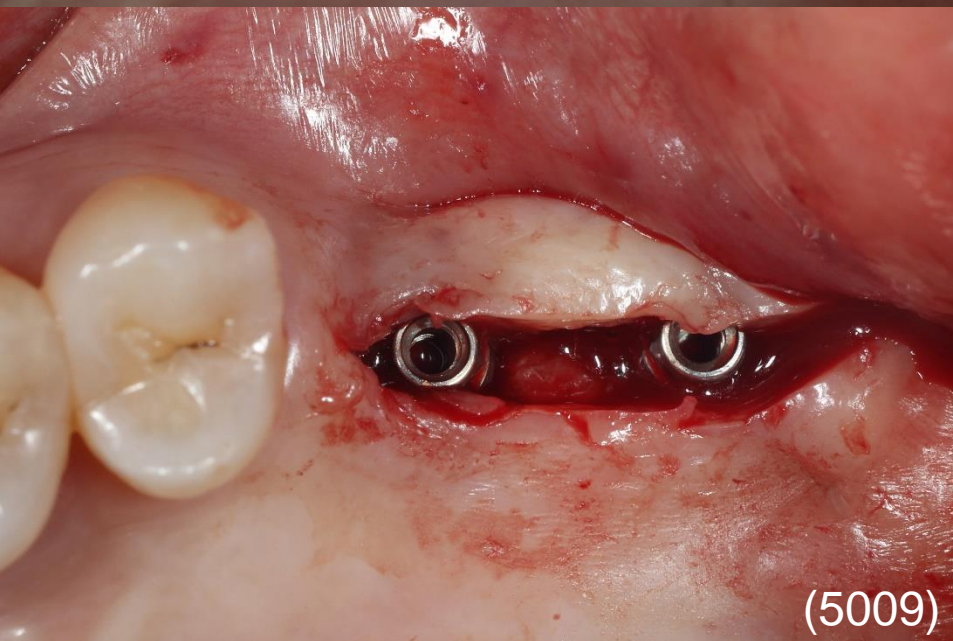
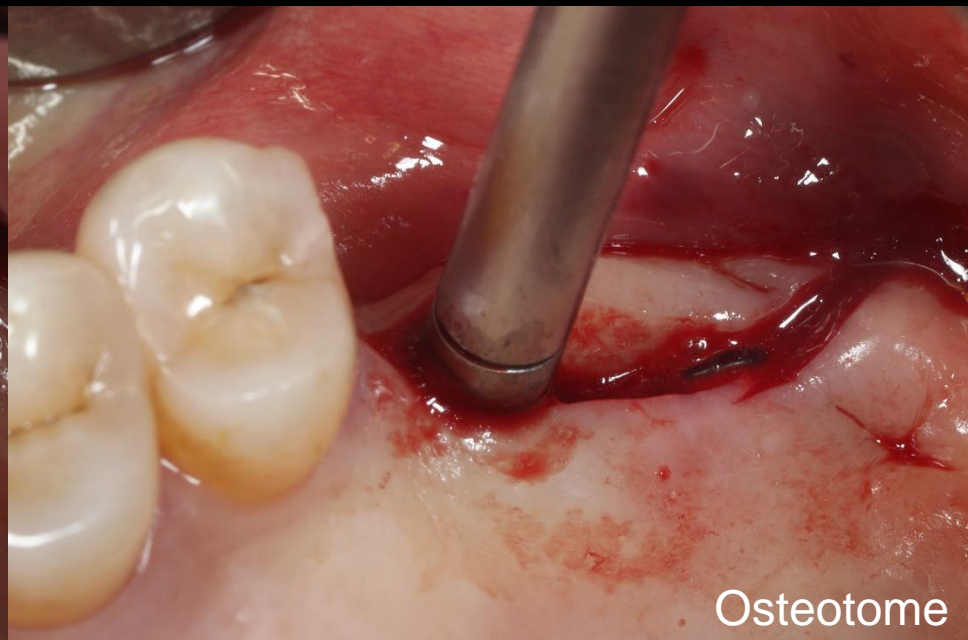
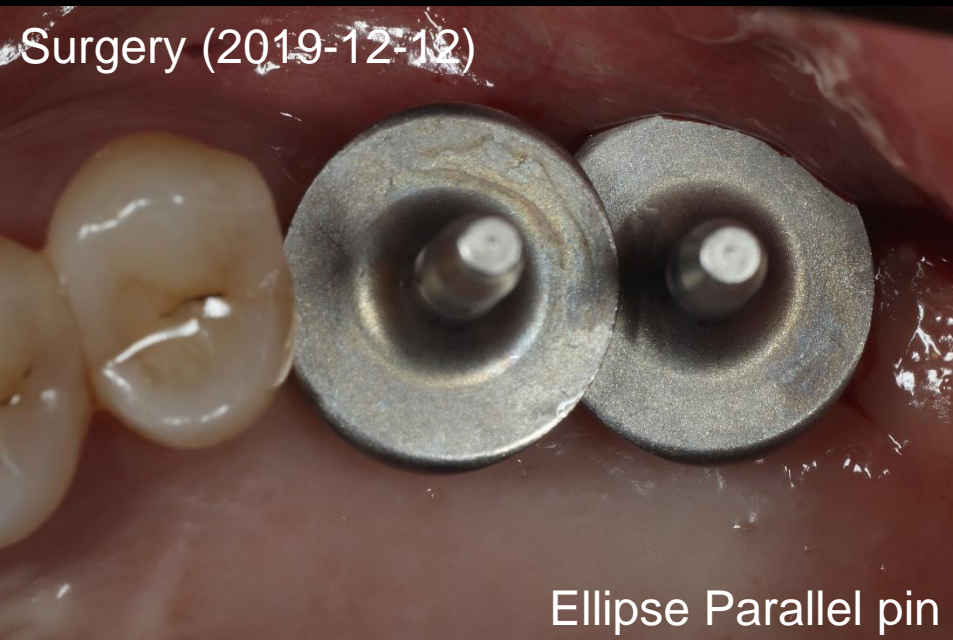
Final prosthesis (2020-05-21)

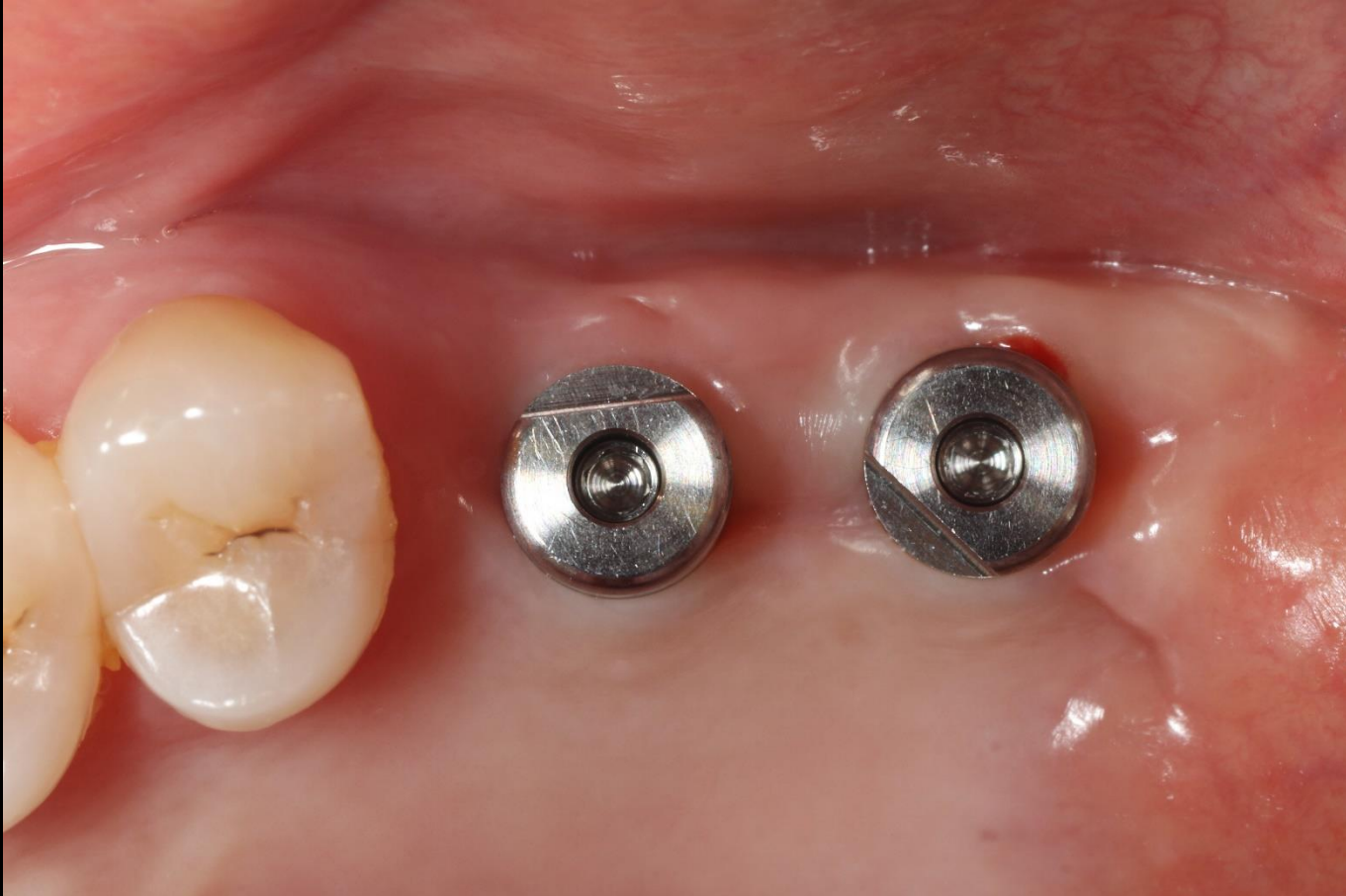

Pre-op (2019-12-12)

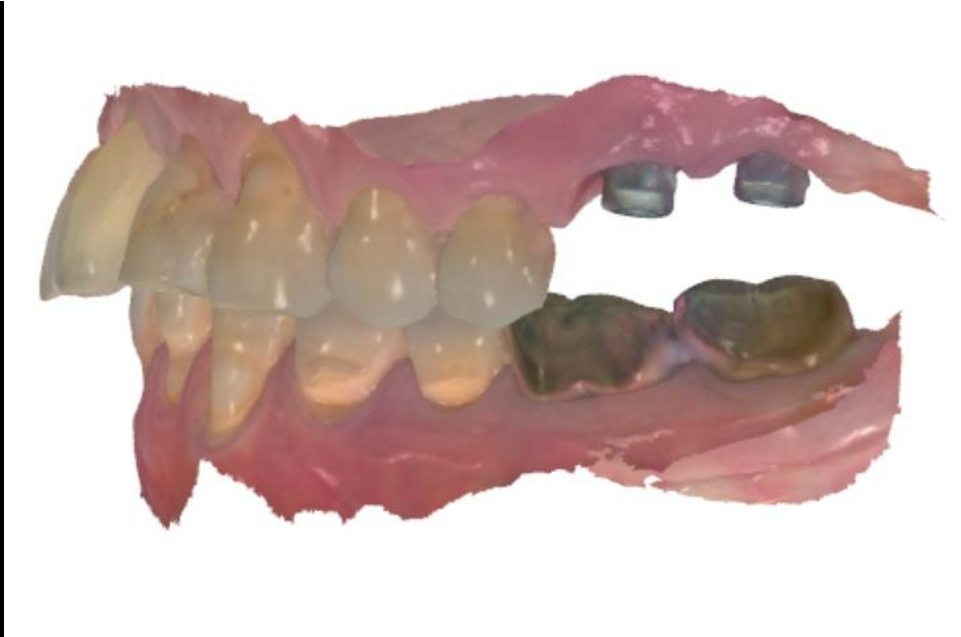
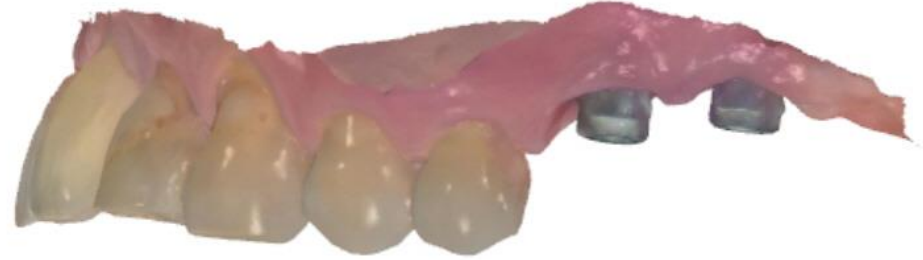
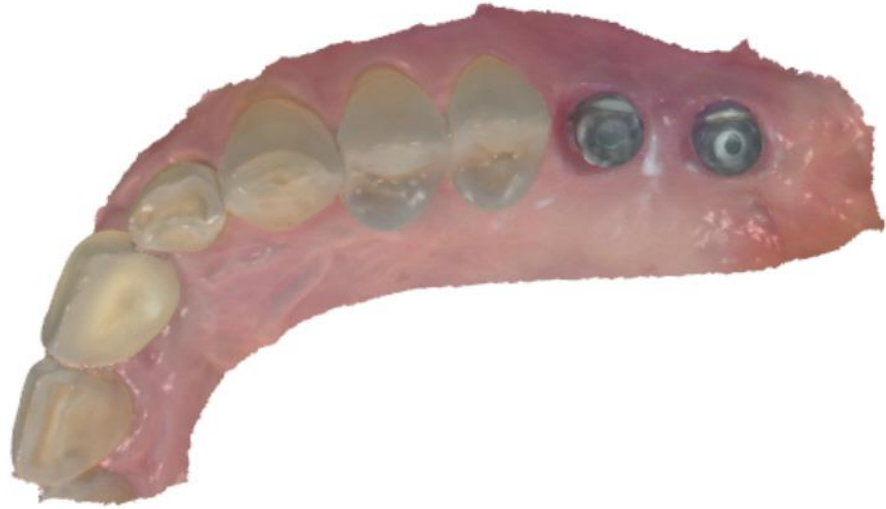

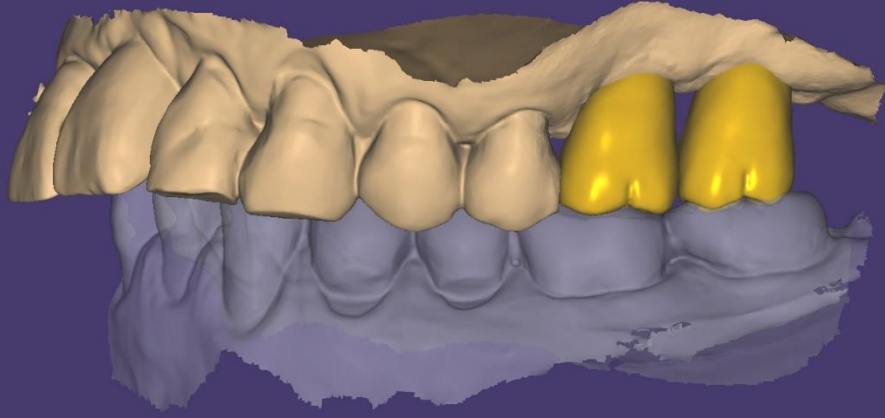
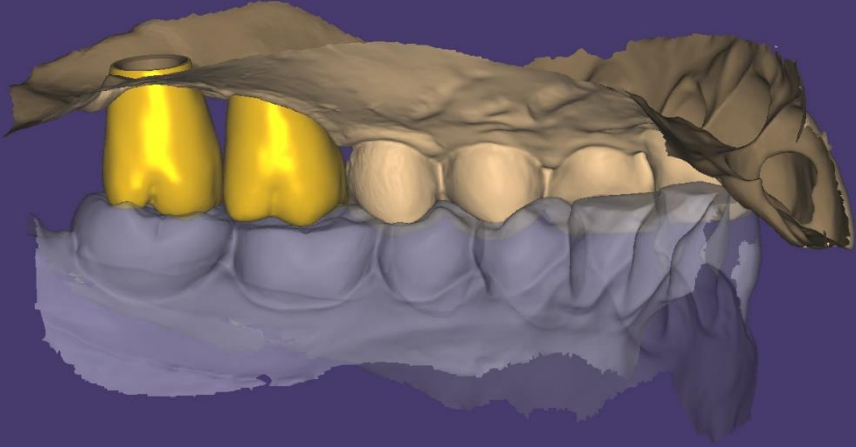
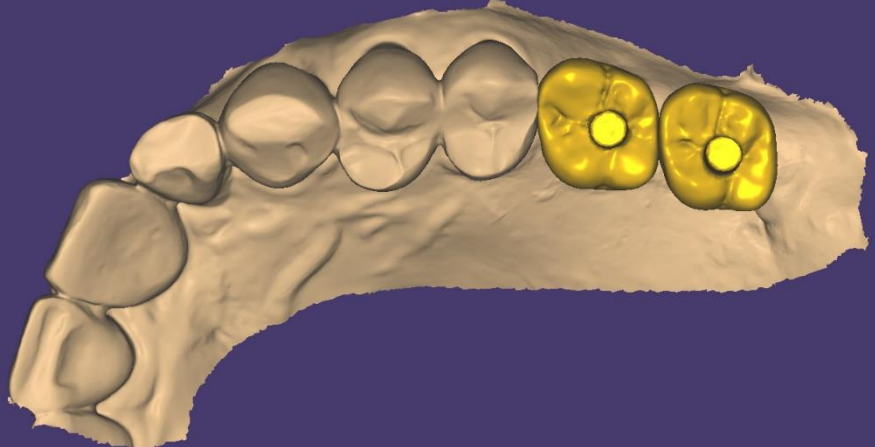
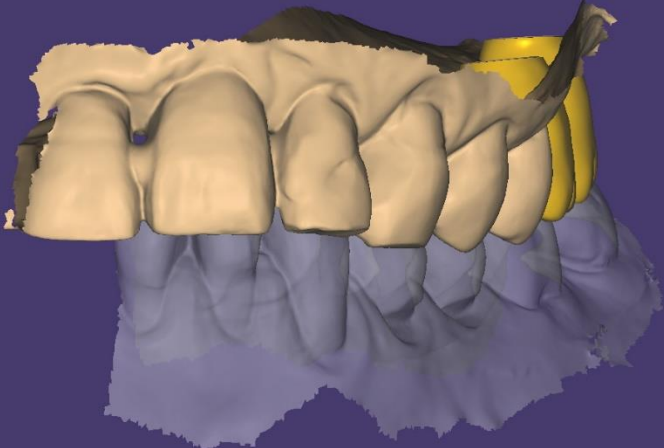
Healing : 2 weeks (2019-12-26)



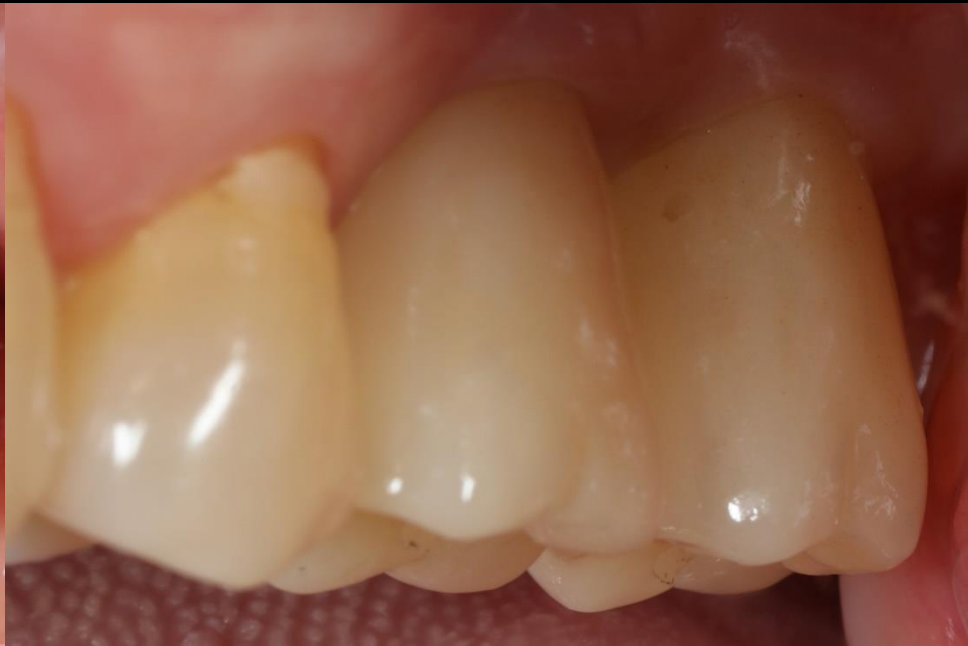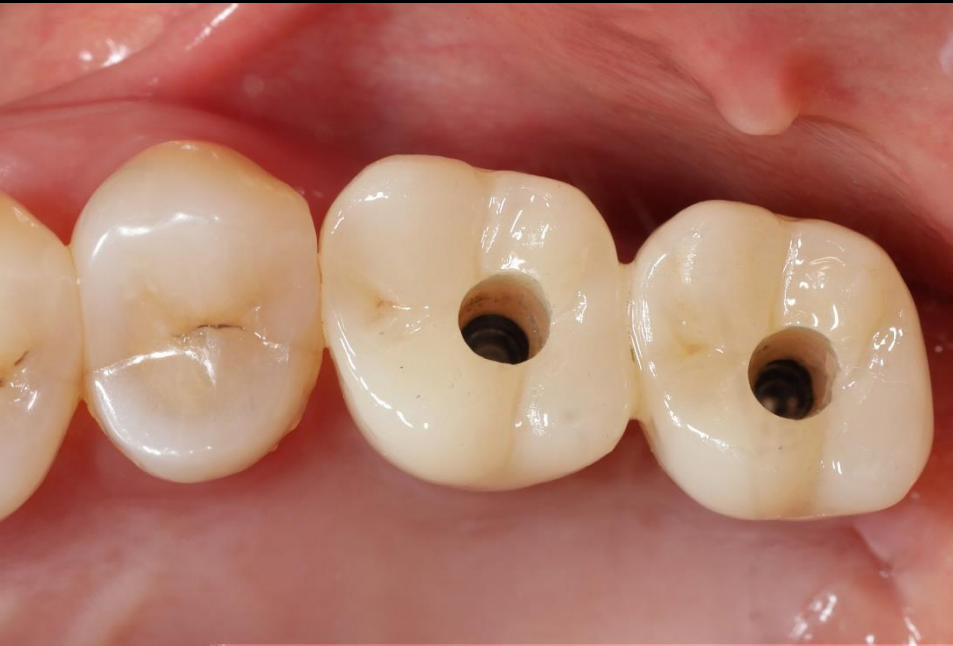Intra Oral Scanning



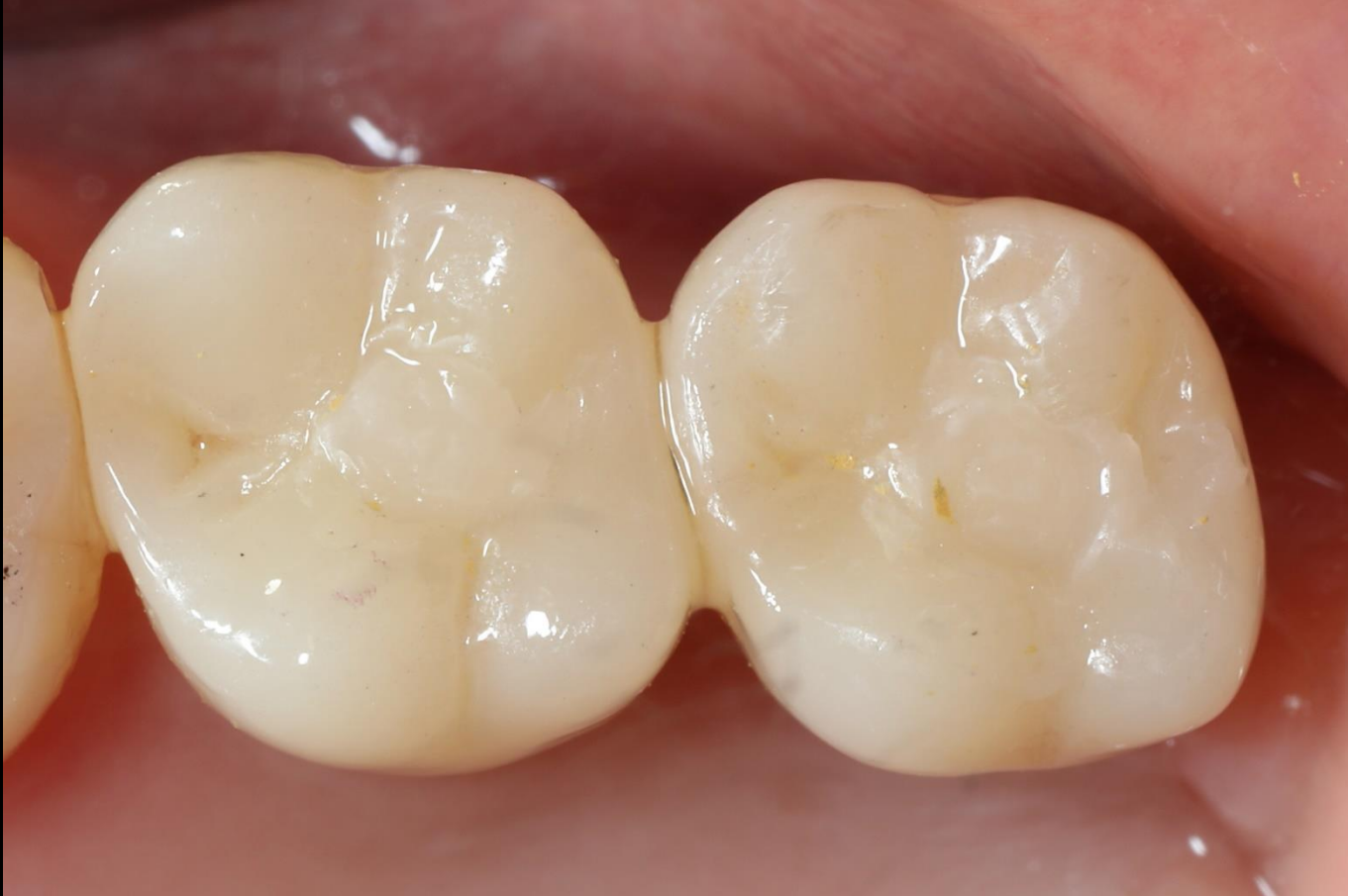CAD Design (Final prosthesis_Screw type)



Final prosthesis (2020-05-21)



HRF (2020-05-21)



Follow up : 9 months (2021-02-18)

