

Dentium

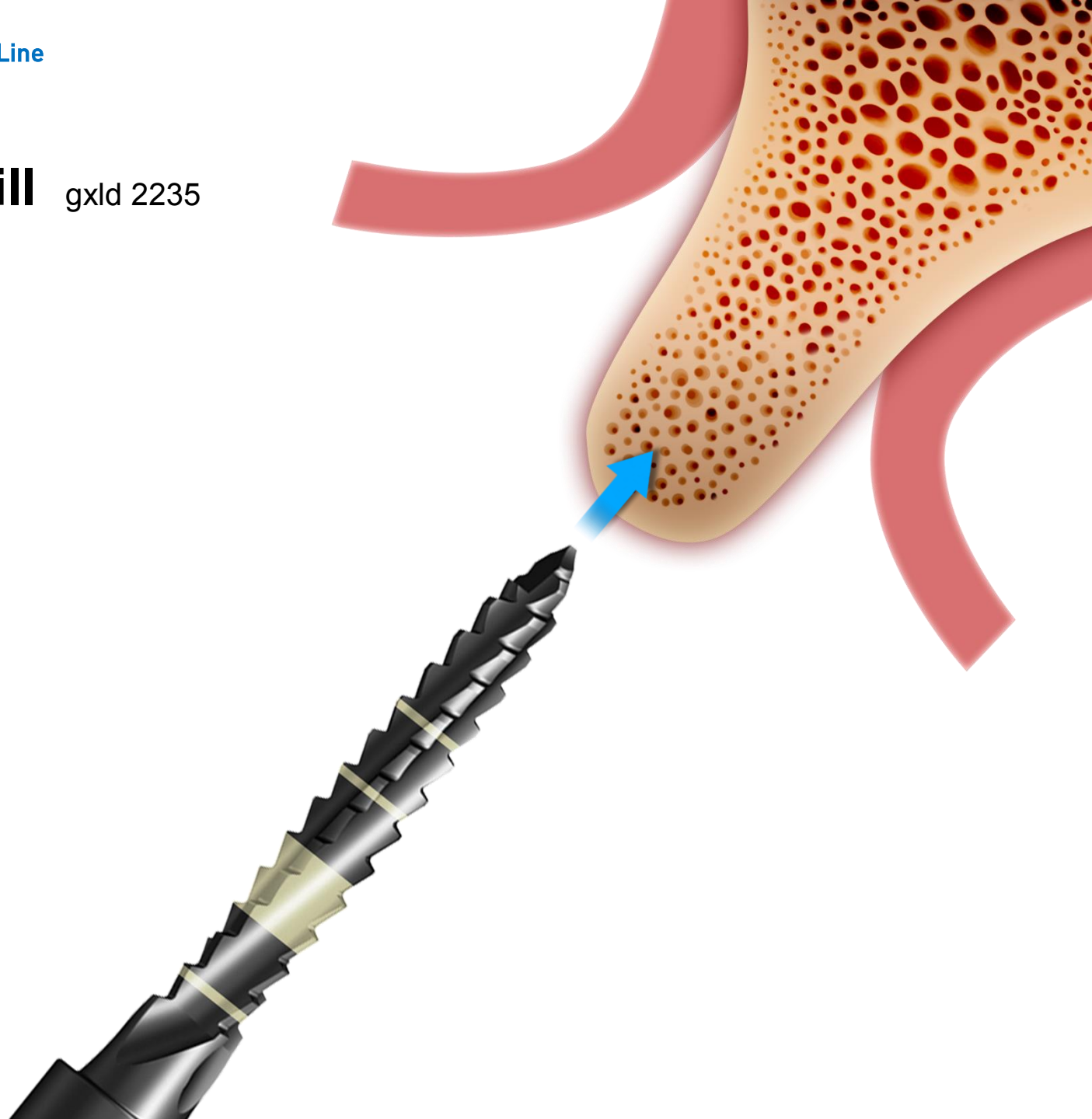NR Line Implant

NEW

Dentium Implant system : NR Line

First guide drill gxld 2235

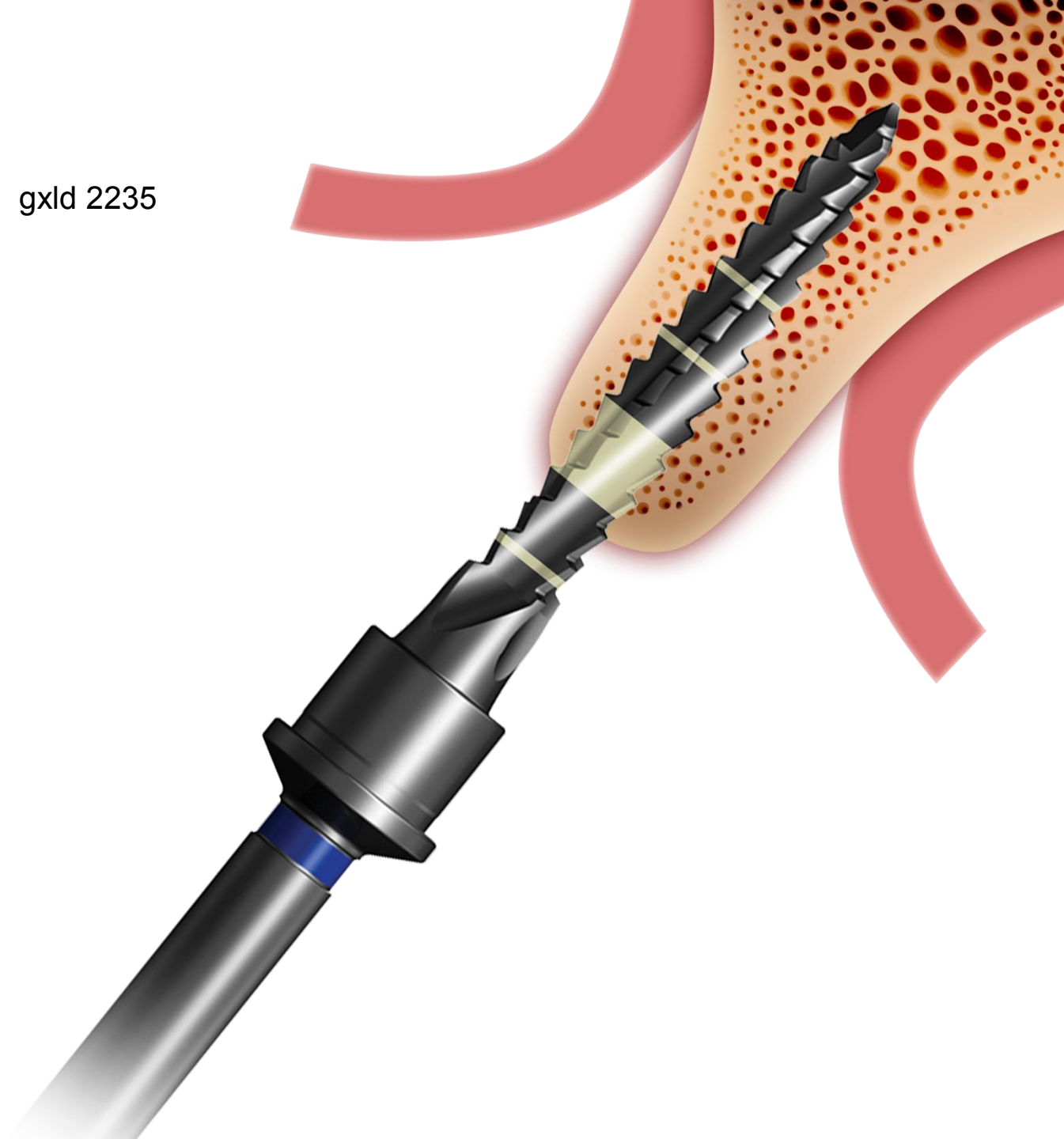
1000rpm/30~35cm·N



Dentium Implant system : NR Line

First guide drill gxld 2235

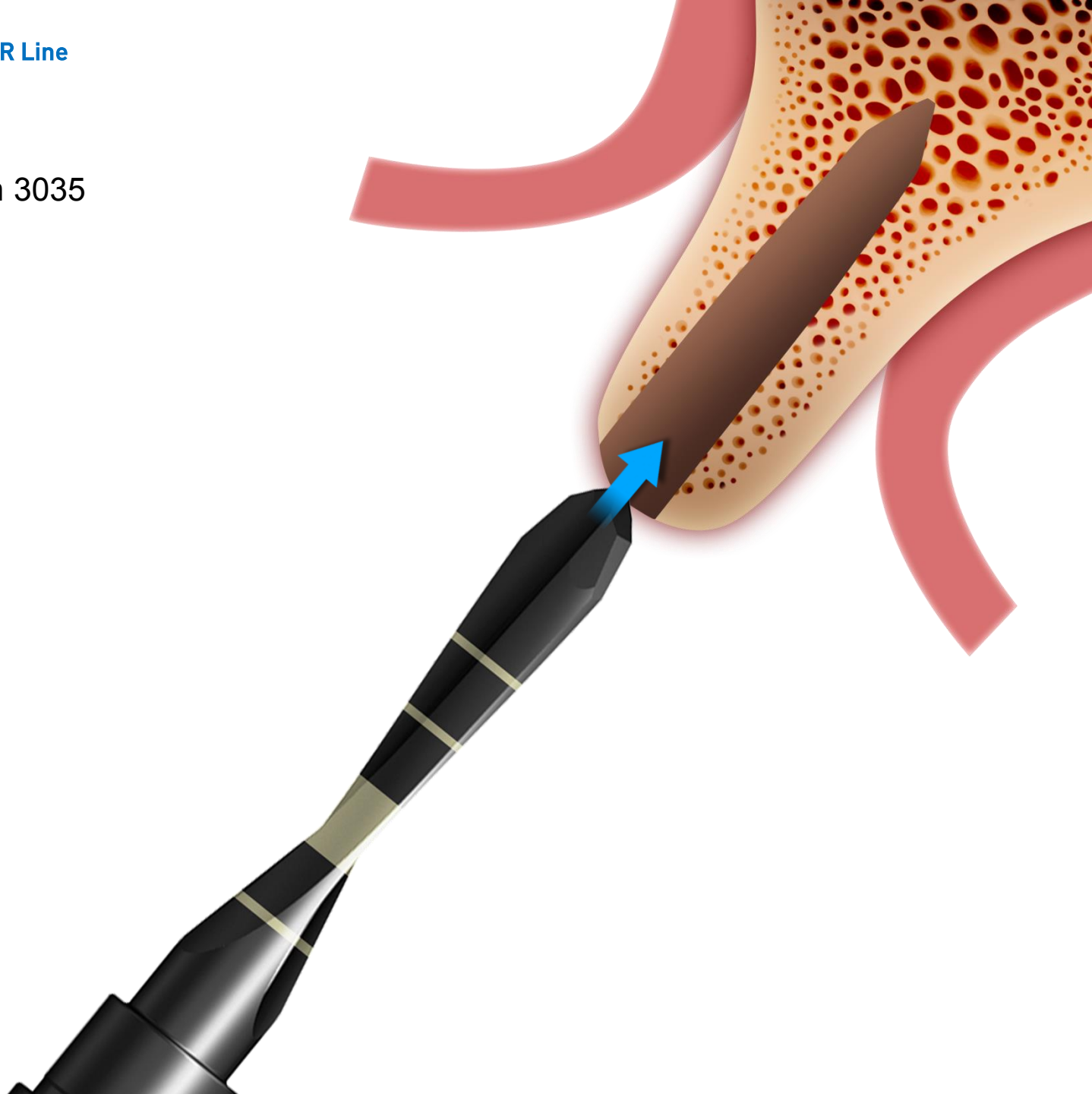1000rpm/30~35cm·N



Dentium Implant system : NR Line

Final drill gxfh 3035

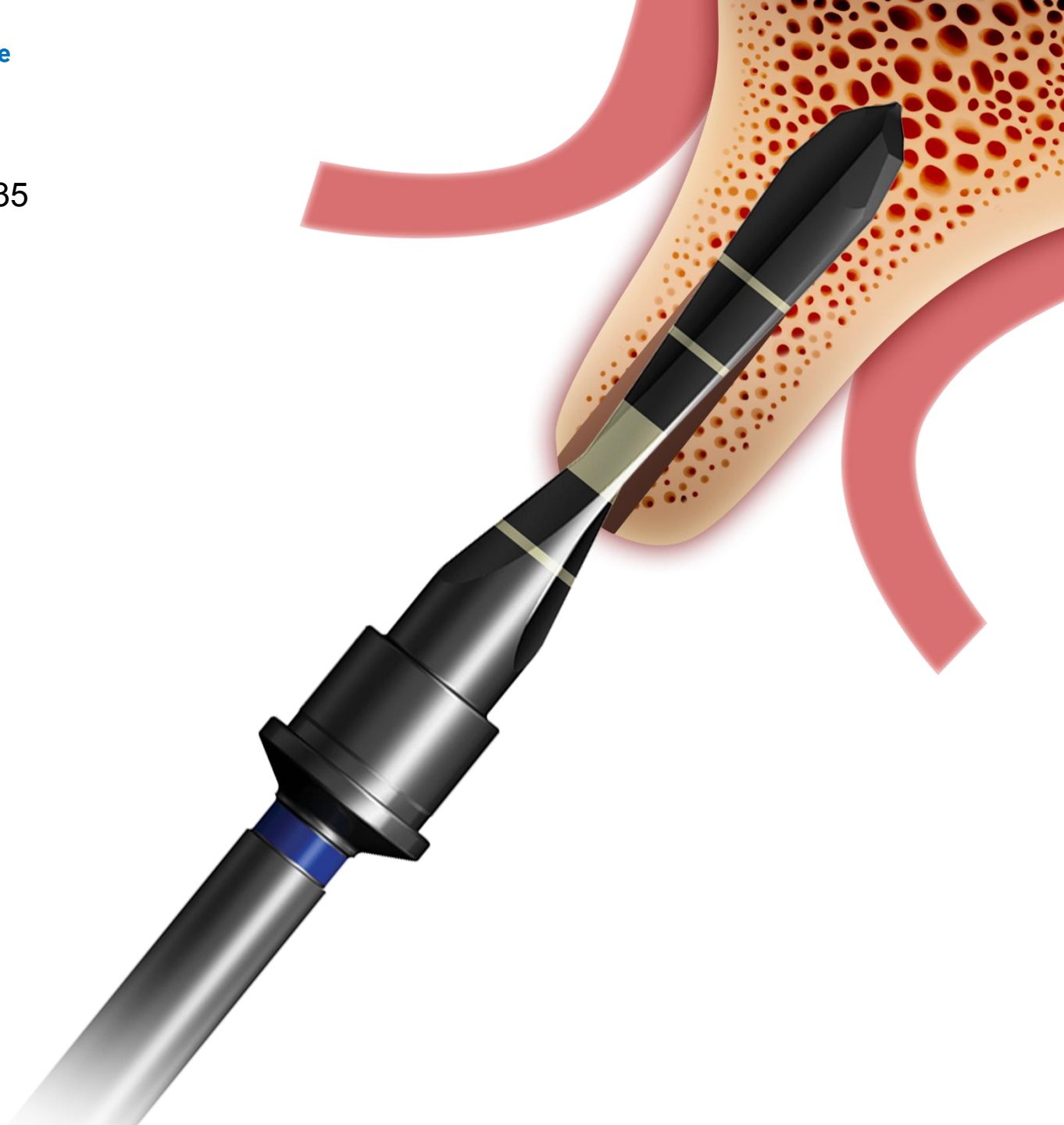
50rpm/50~70cm·N



Dentium Implant system : NR Line

Final drill gxfh 3035

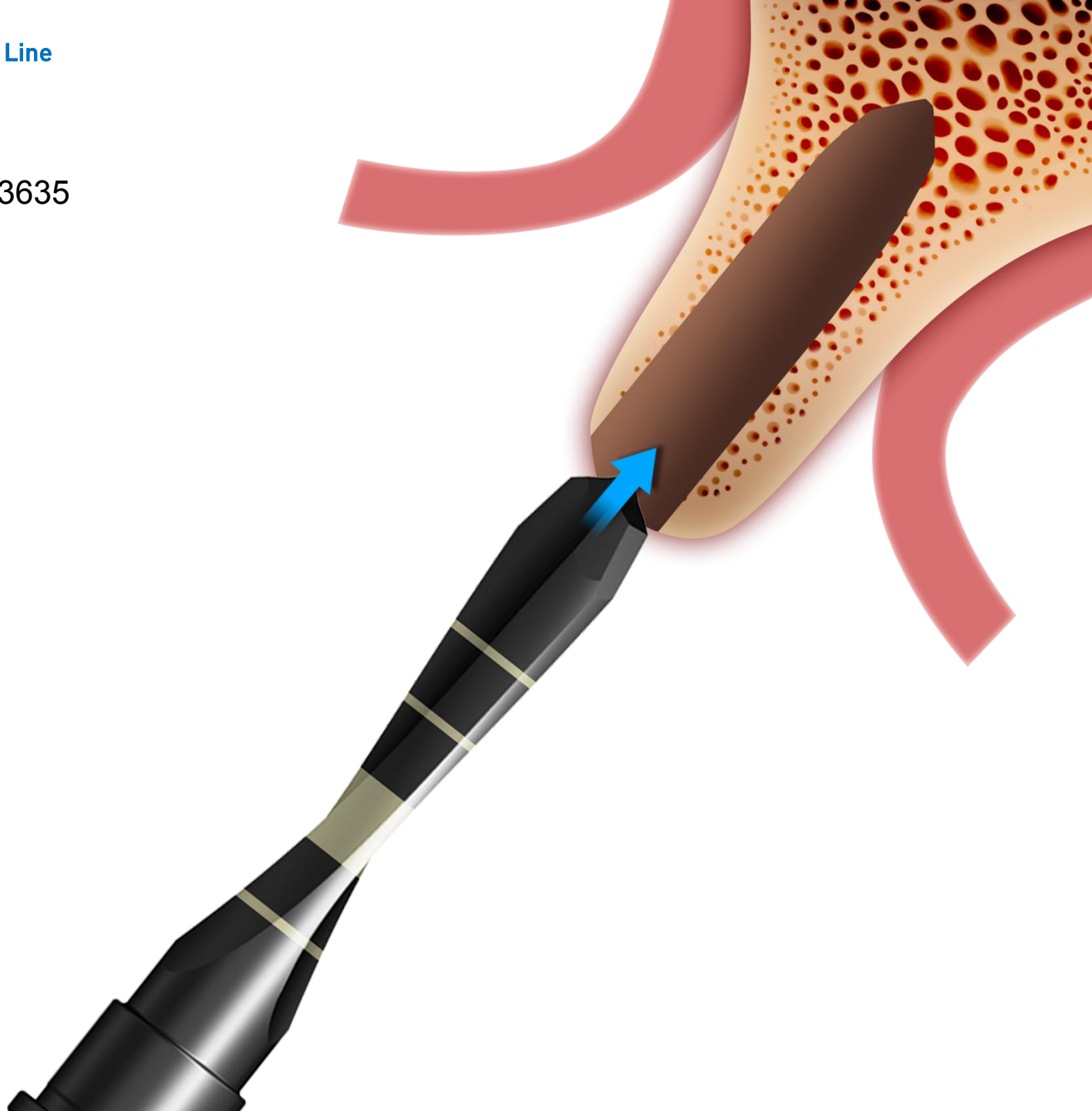50rpm/50~70cm·N



Dentium Implant system : NR Line

Final drill gxfh 3635

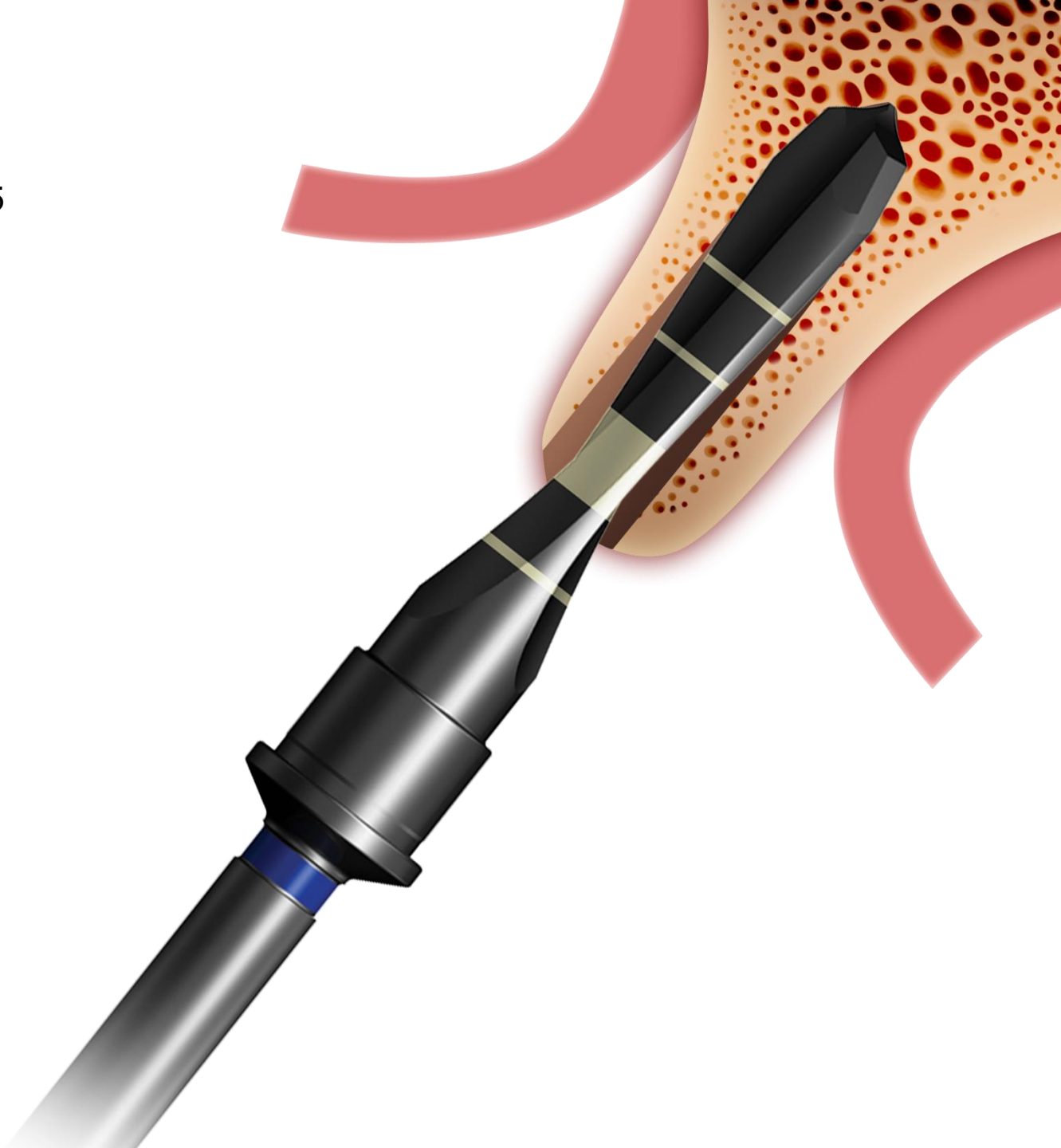
50rpm/50~70cm·N



Dentium Implant system : NR Line

Final drill gxfh 3635

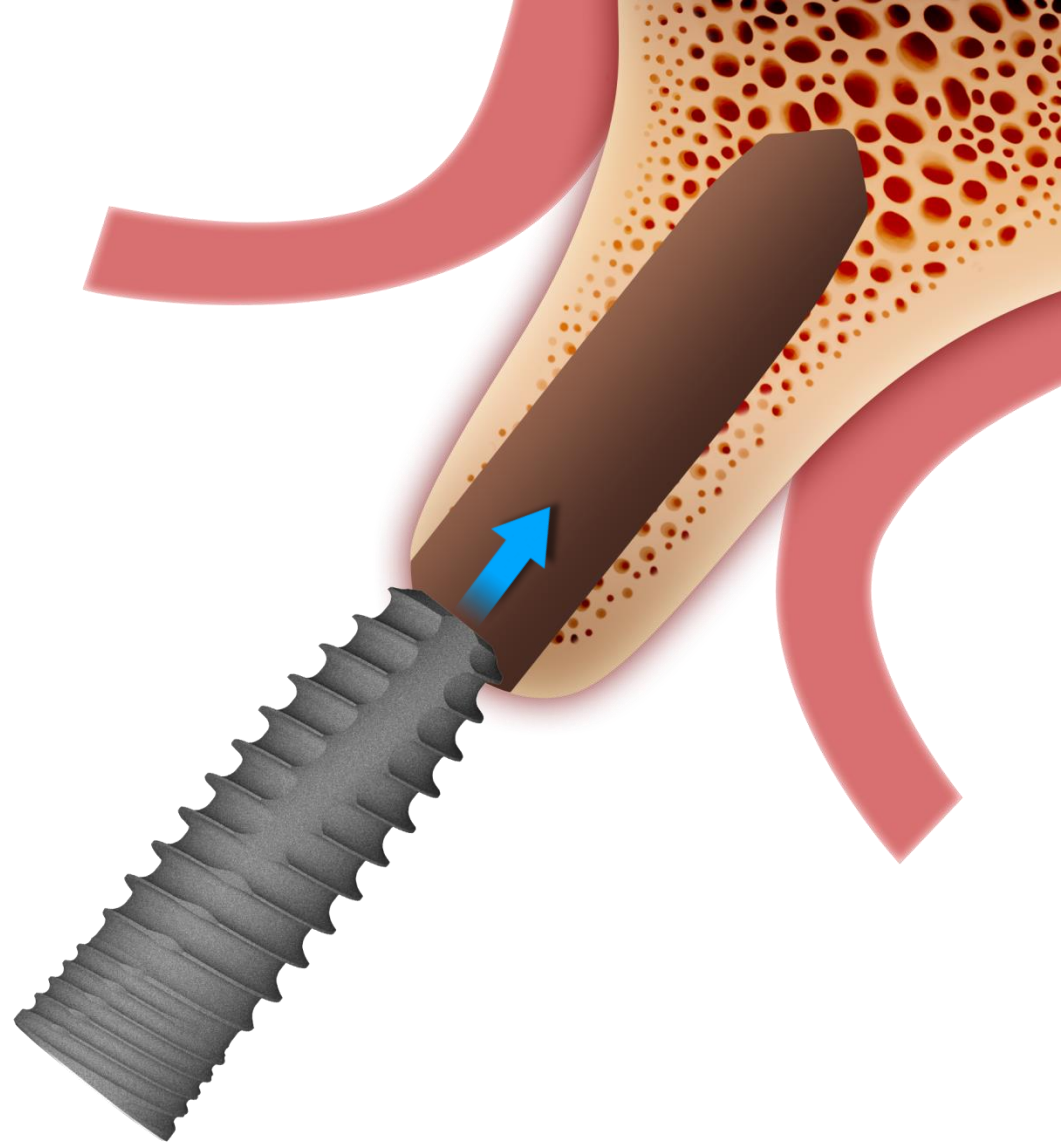
50rpm/50~70cm·N



Dentium Implant system : NR Line

Fixture Installation

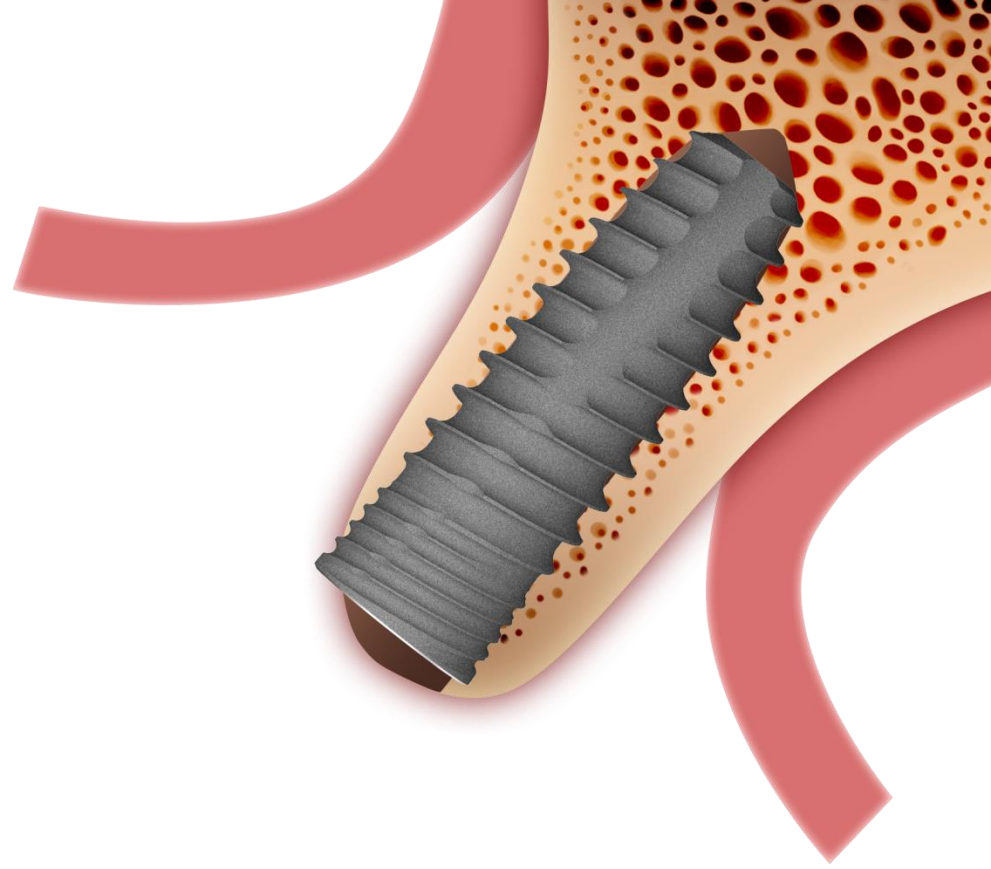
NR Line 3611



Dentium Implant system : NR Line

Fixture Installation

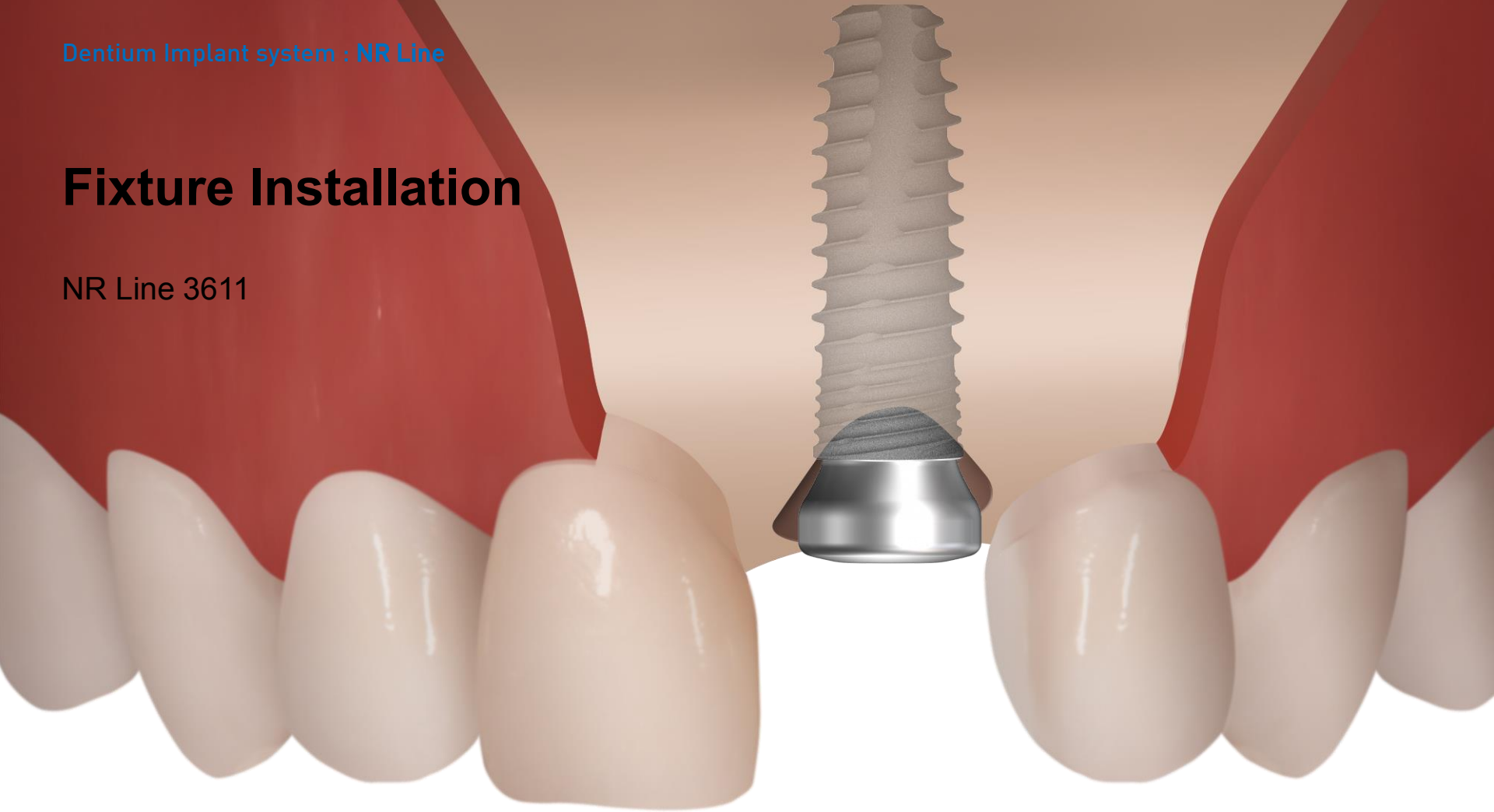
NR Line 3611



Dentium Implant system : NR Line

Fixture Installation

NR Line 3611

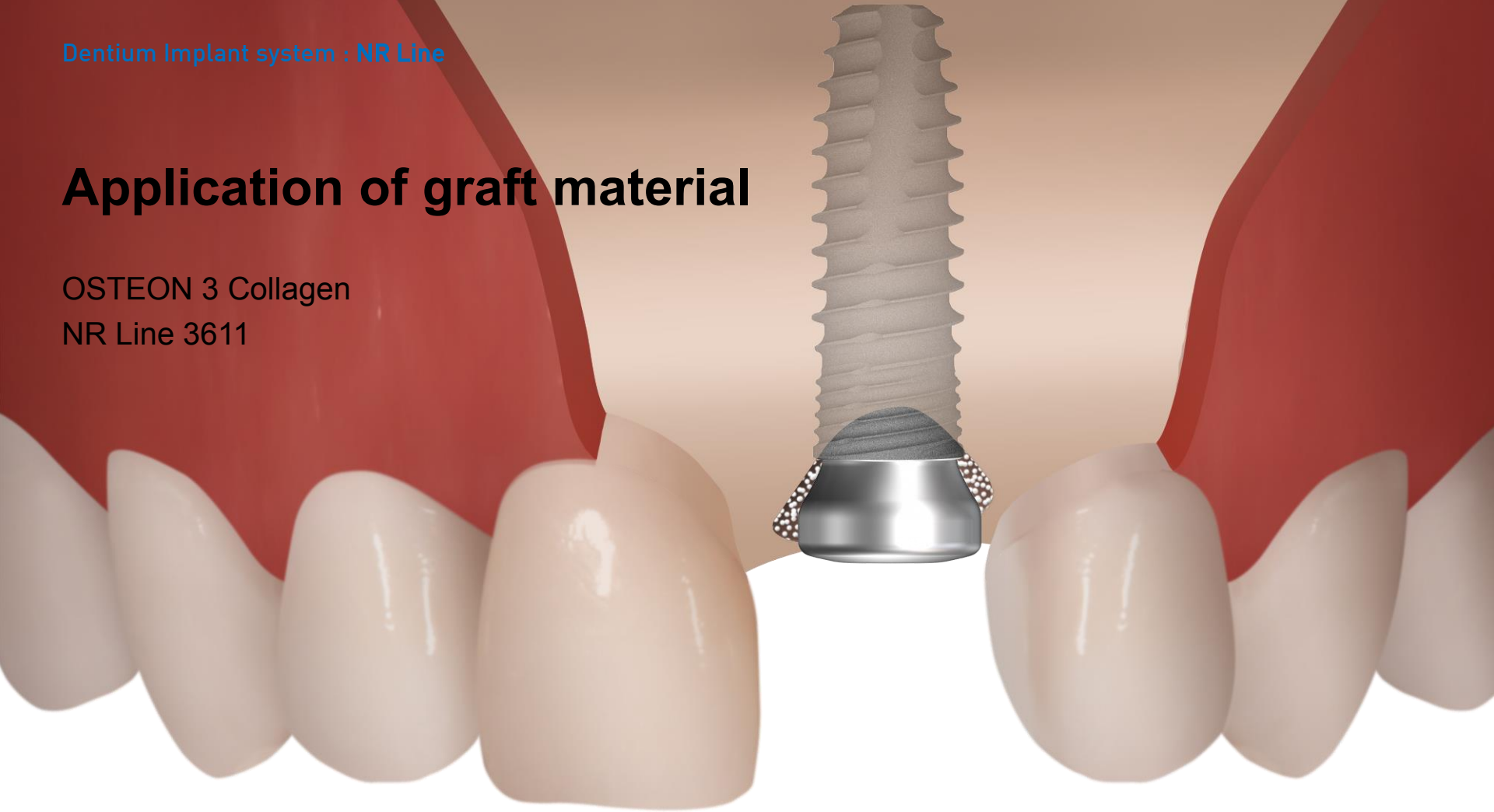


Dentium Implant system : NR Line

Application of graft material

OSTEON 3 Collagen

NR Line 3611



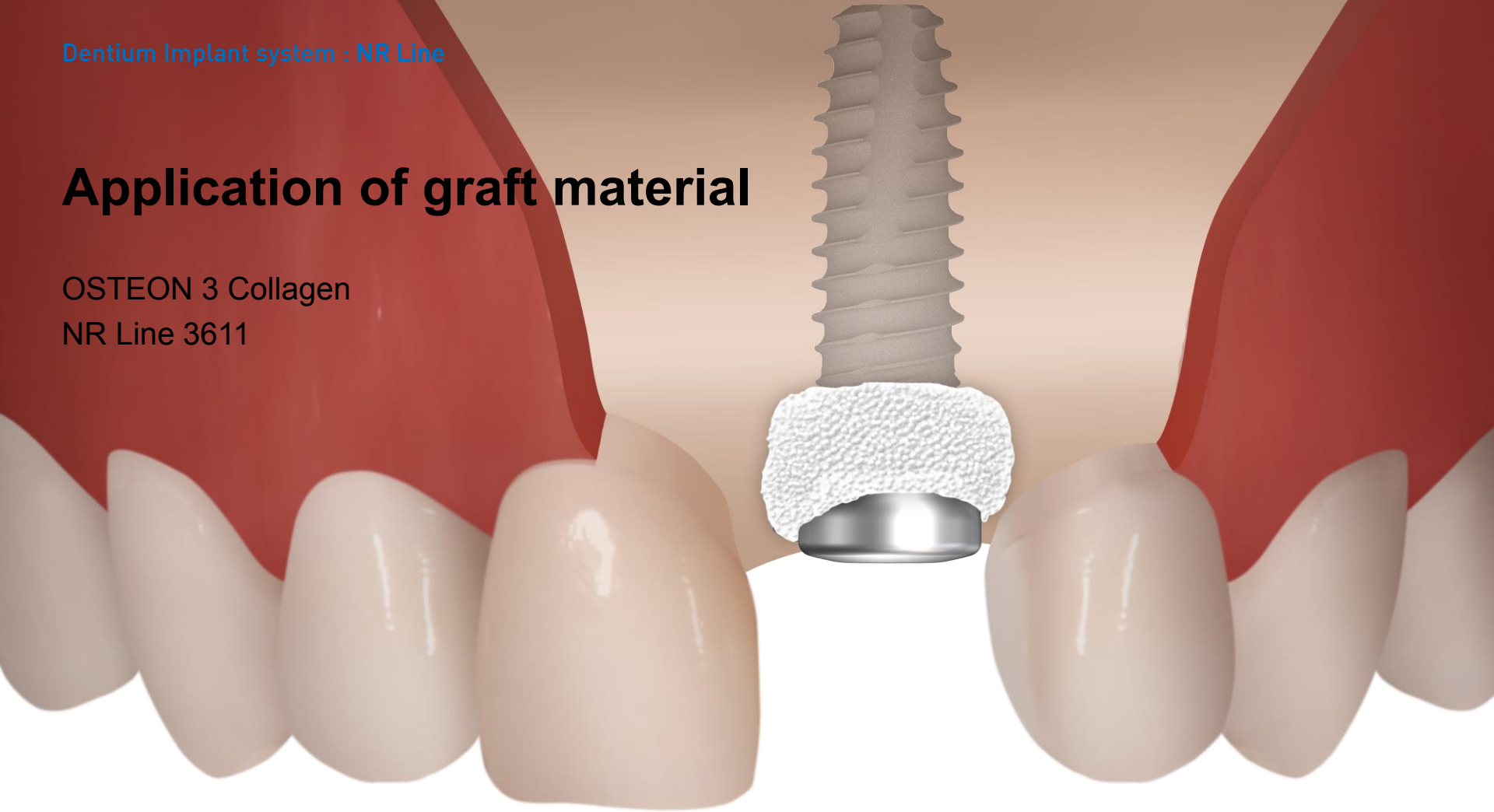
Minimize GBR

Dentium Implant system : NR Line

Application of graft material

OSTEON 3 Collagen

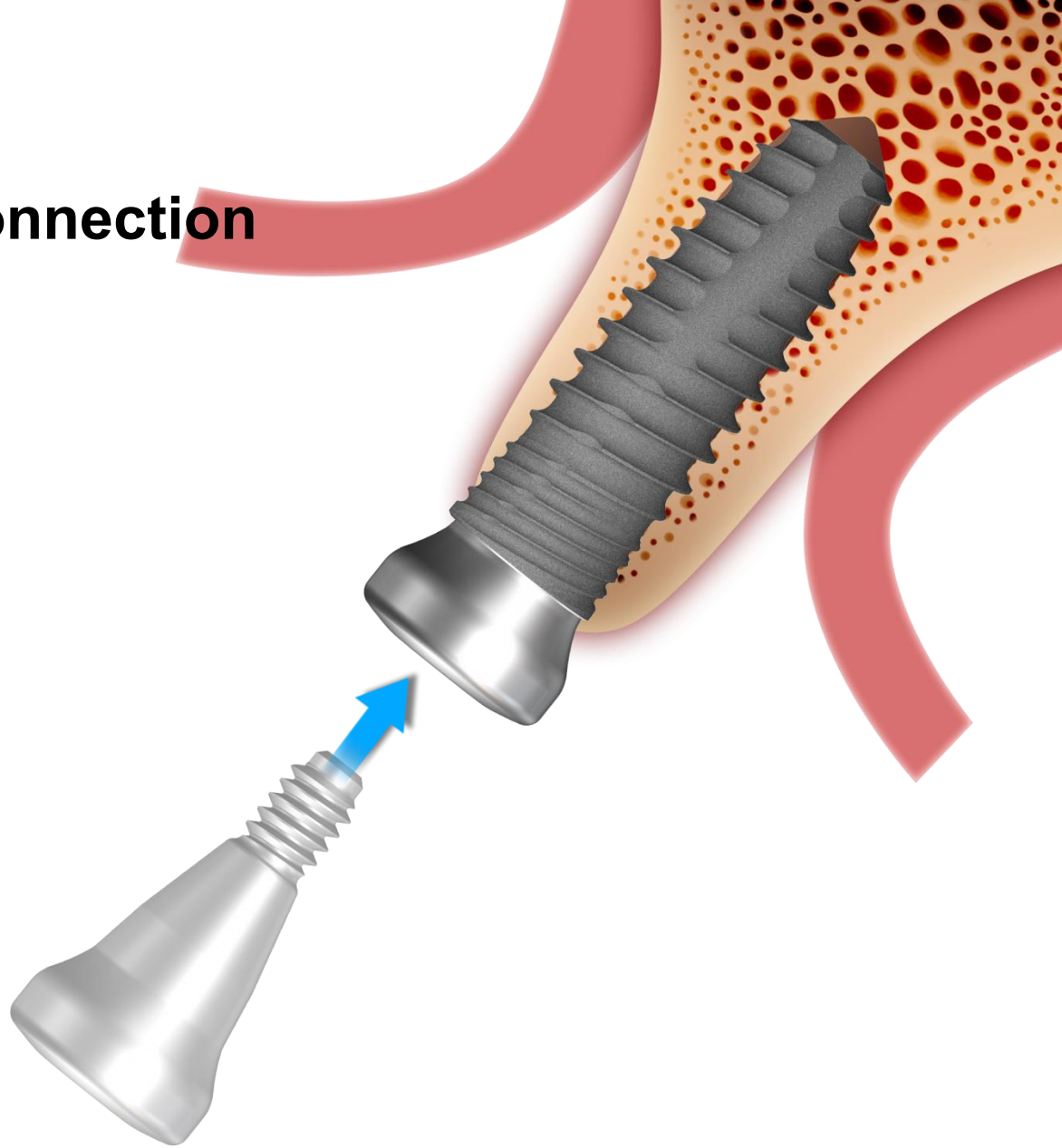
NR Line 3611



Minimize GBR

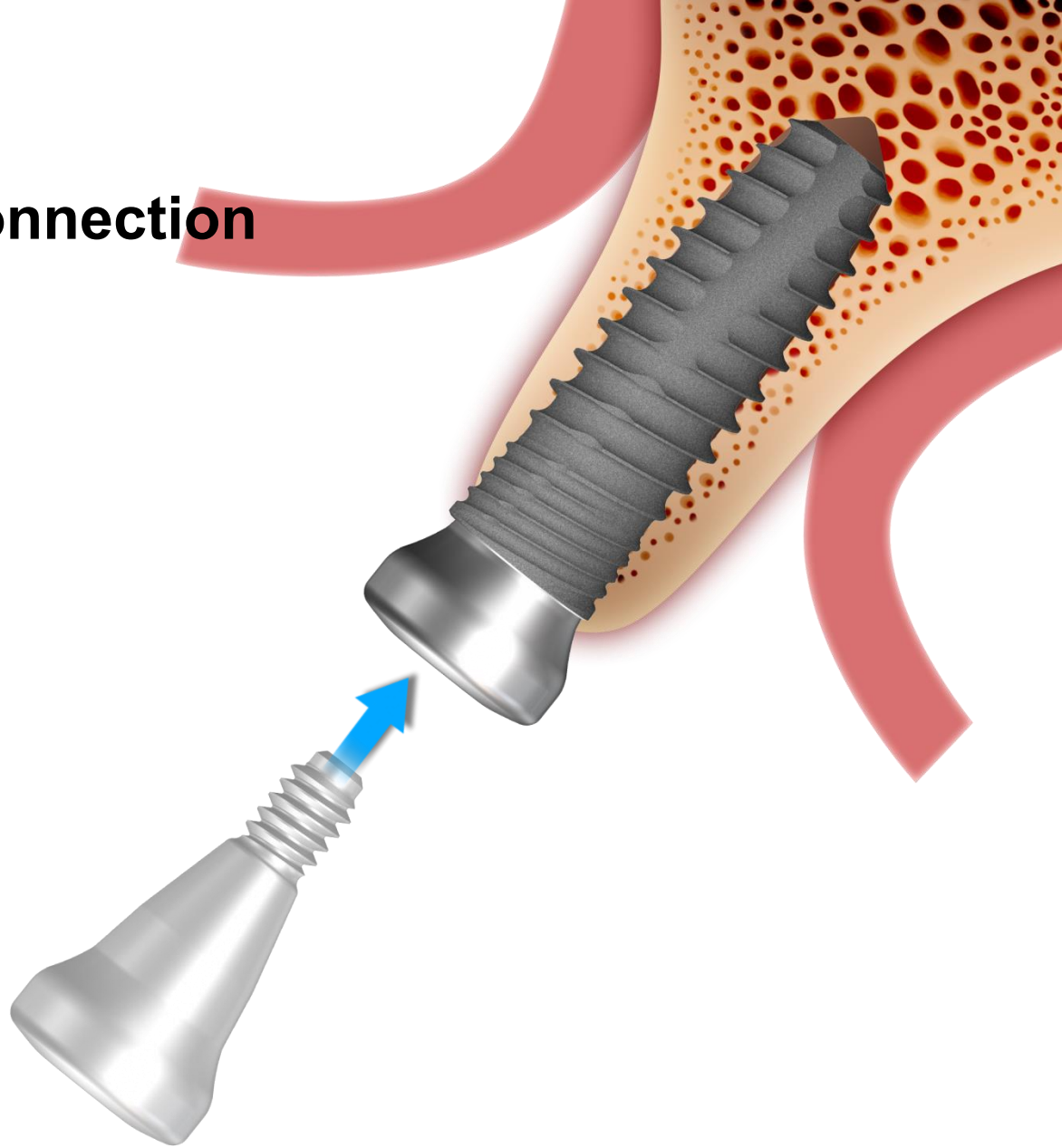
Healing Abutment Connection

GHAB 431525



Healing Abutment Connection

GHAB 431525



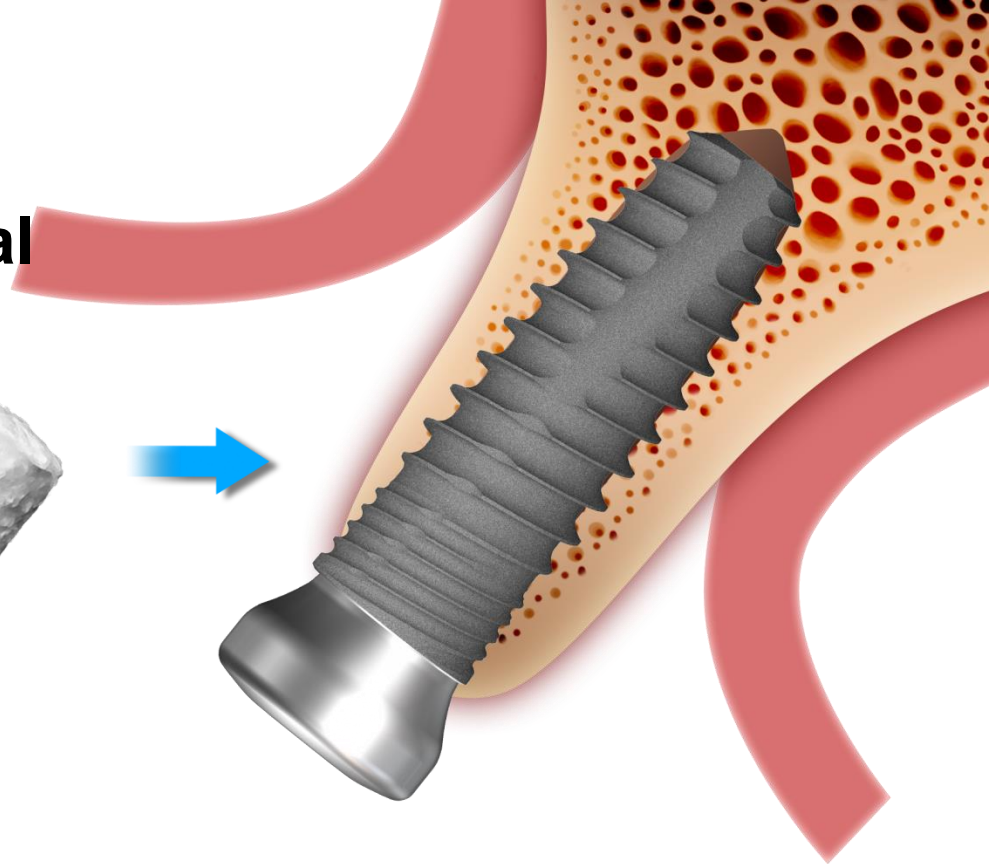
Application of graft material

OSTEON 3 Collagen

NR Line 3611



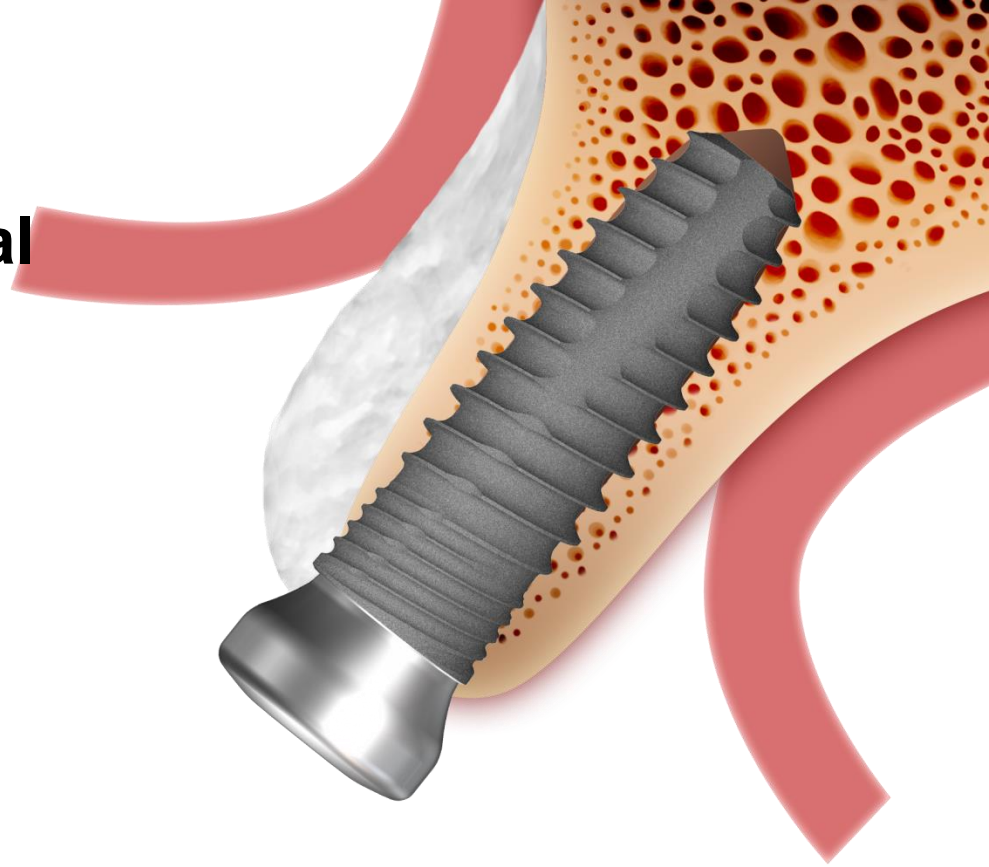
Minimize GBR



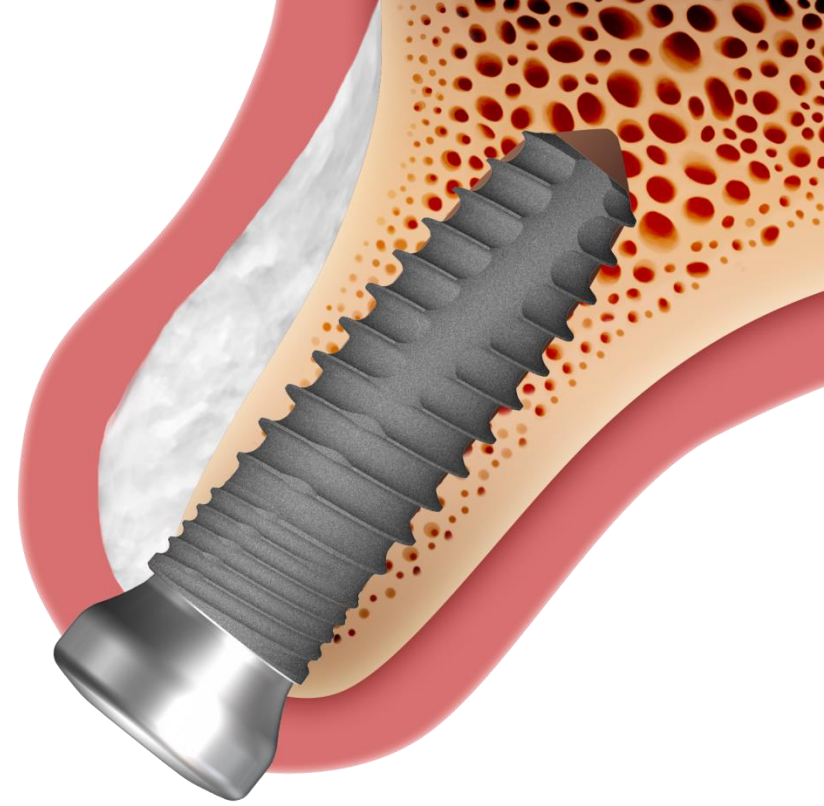
Application of graft material

OSTEON 3 Collagen

NR Line 3611

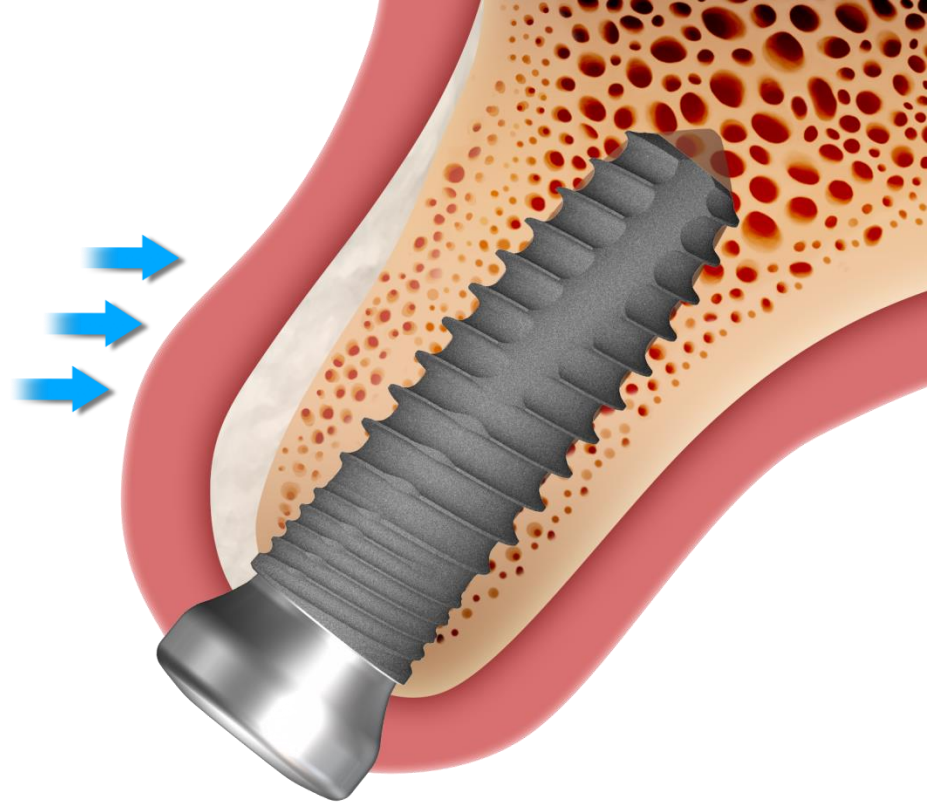


Suture



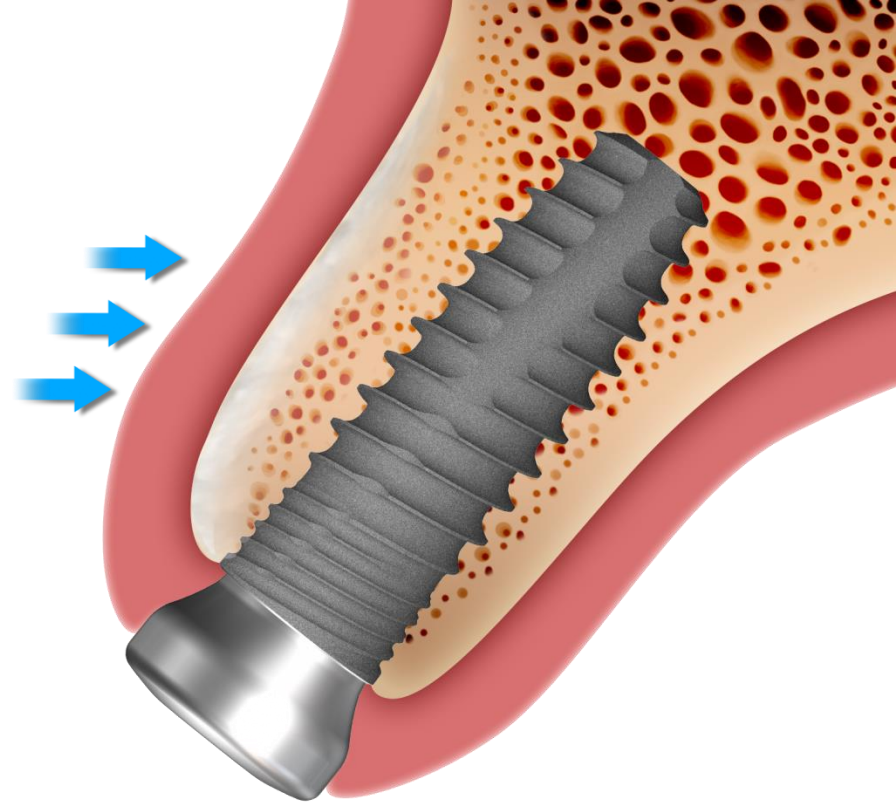
Dentium Implant system : NR Line

Healing



Dentium Implant system : NR Line

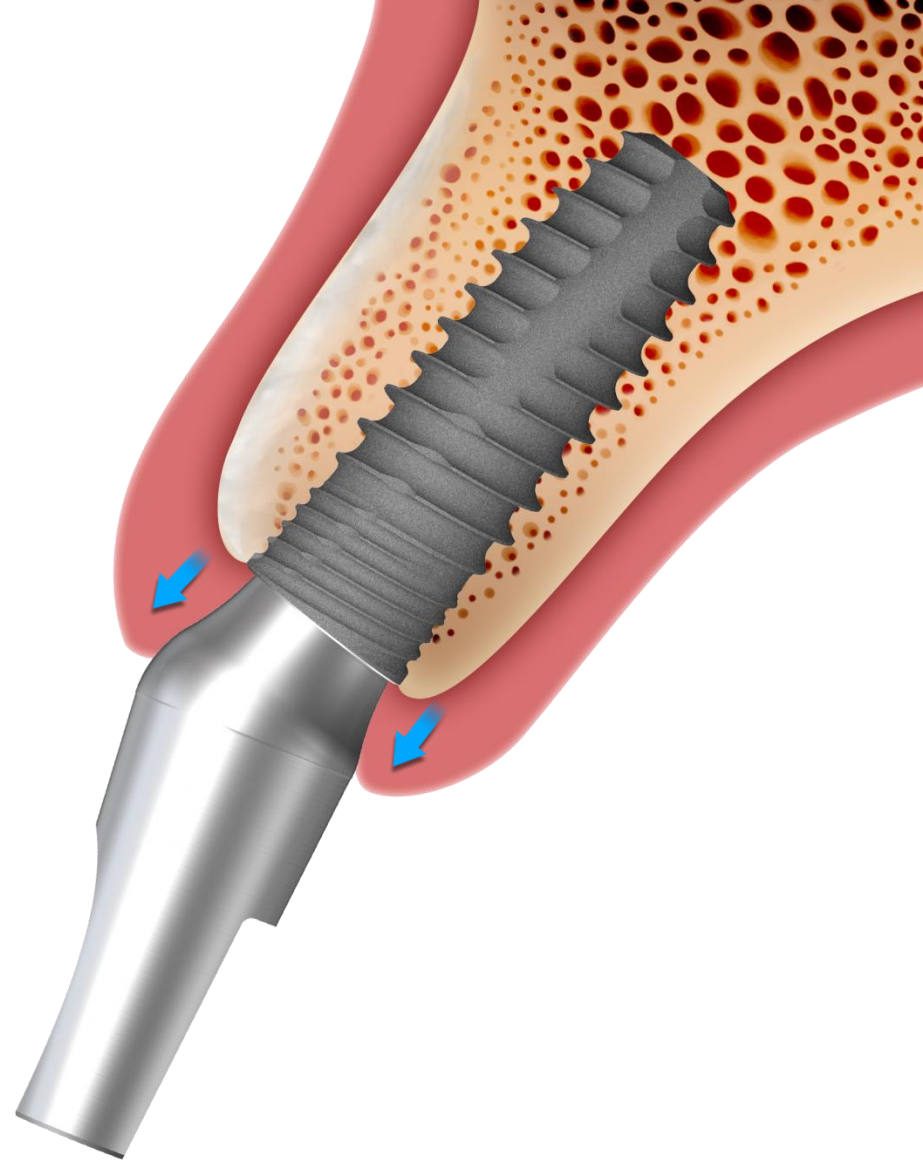
Healing



Dentium Implant system : NR Line

Abutment Selection

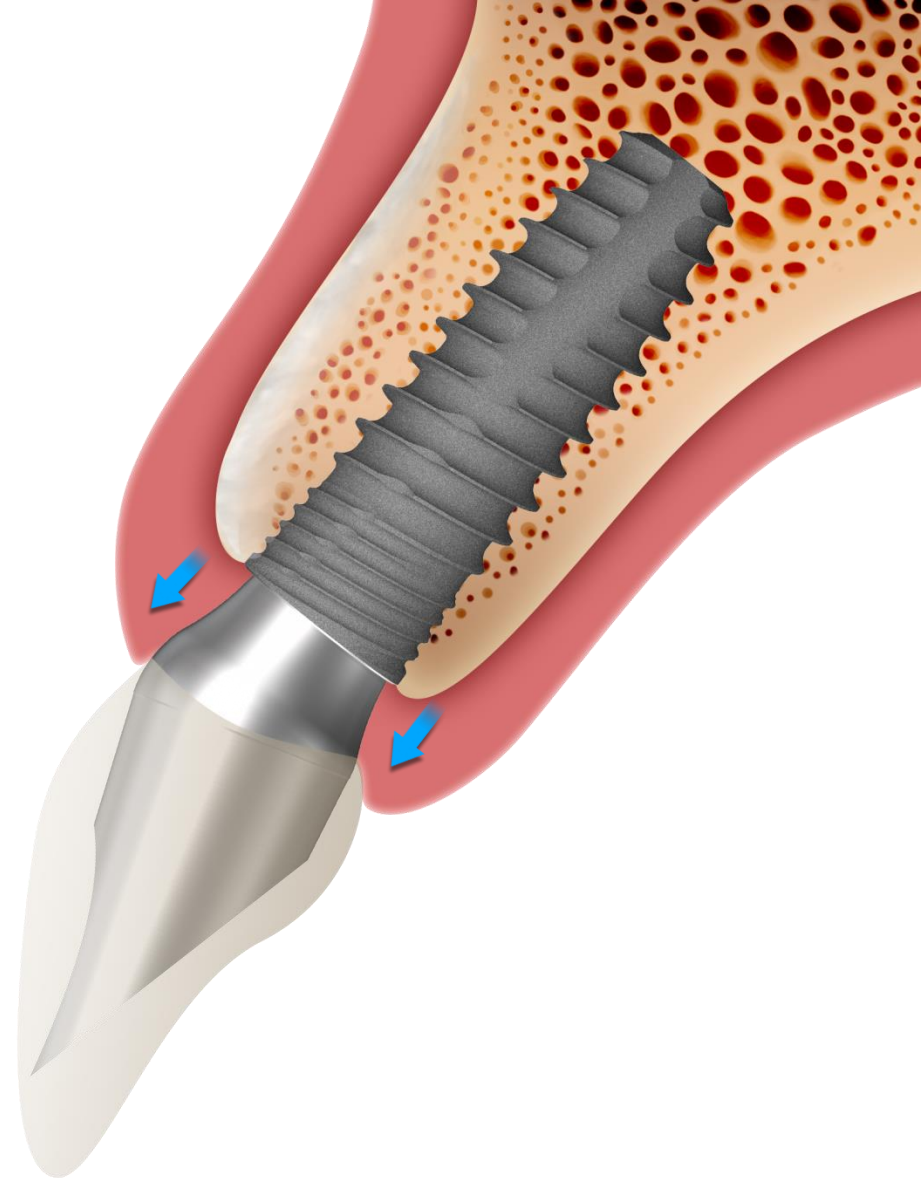
BAAB 154320



Dentium Implant system : NR Line

Final prosthesis

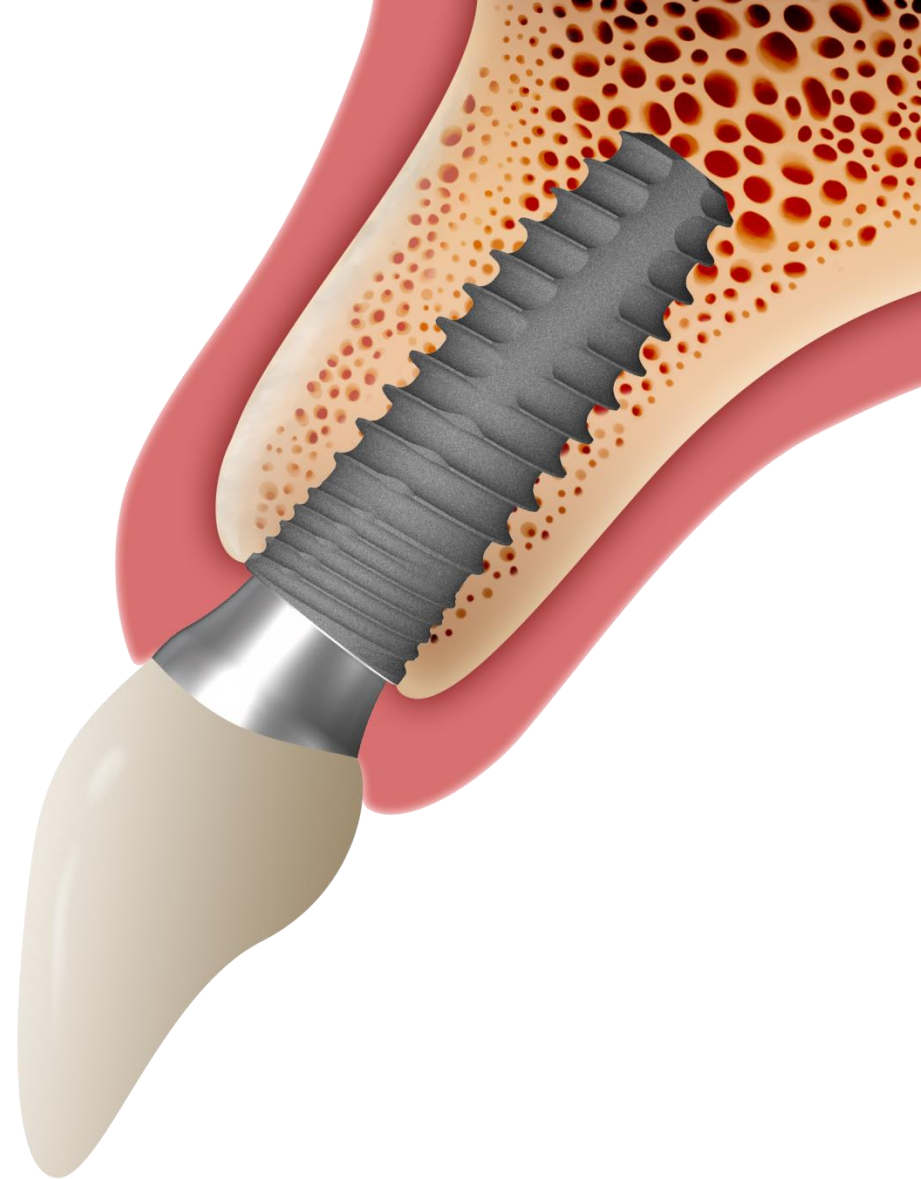
Emergence profile formation



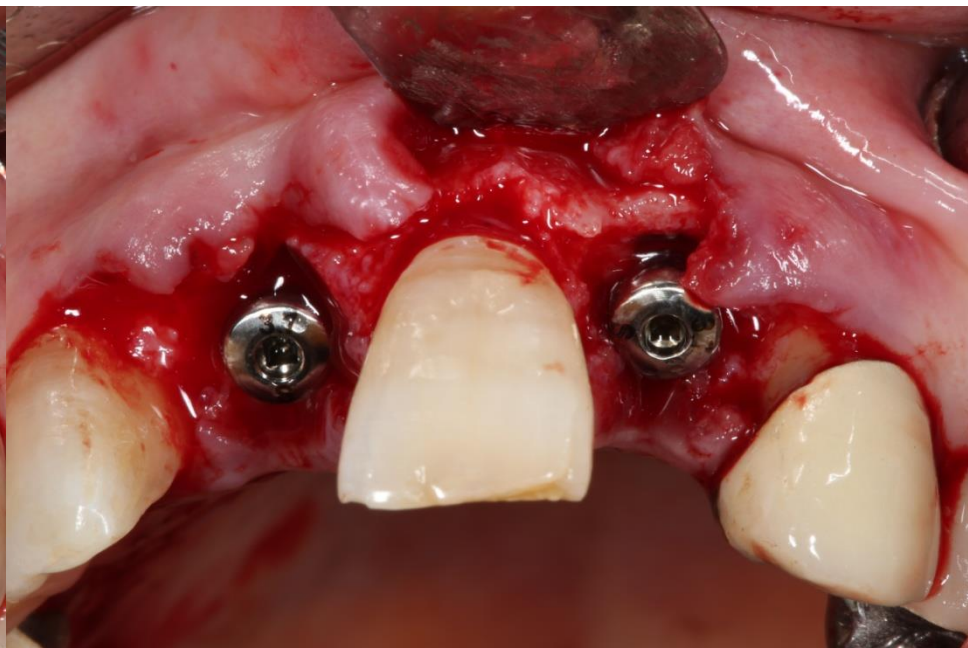
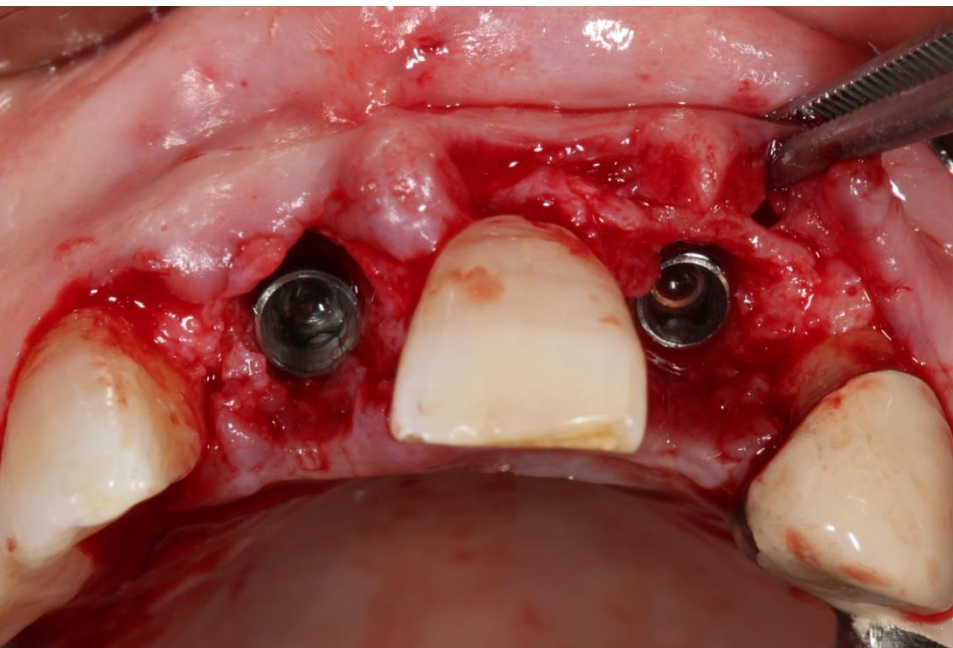
Dentium Implant system : NR Line

Final prosthesis

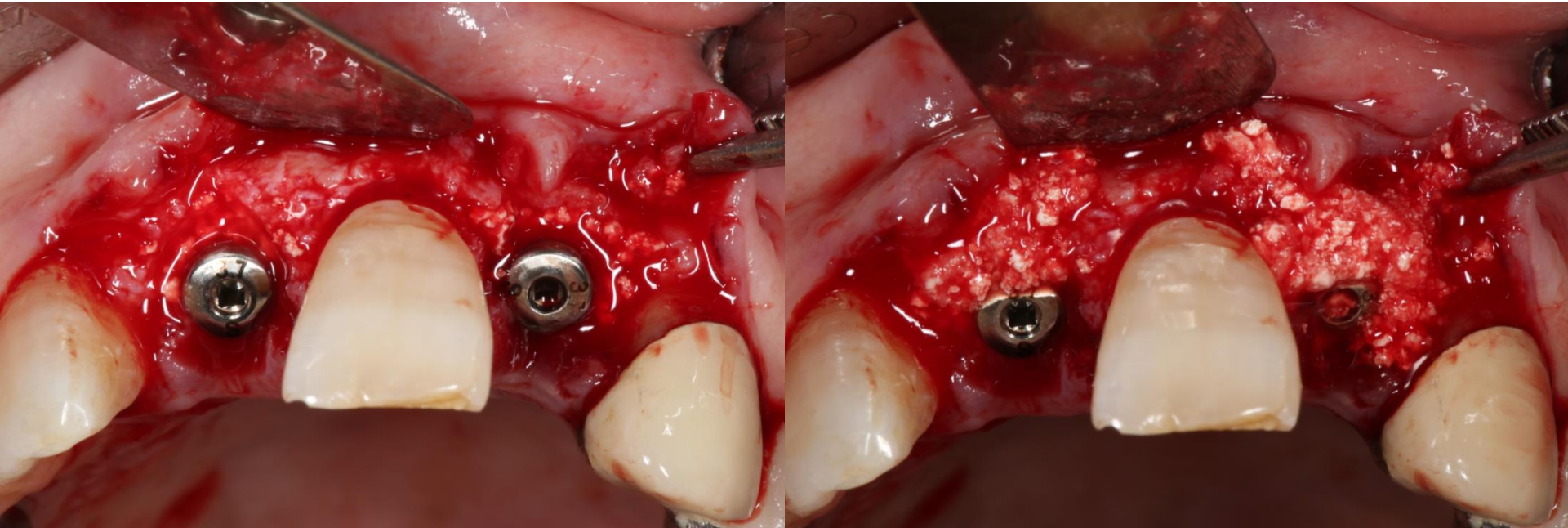
New bone formation



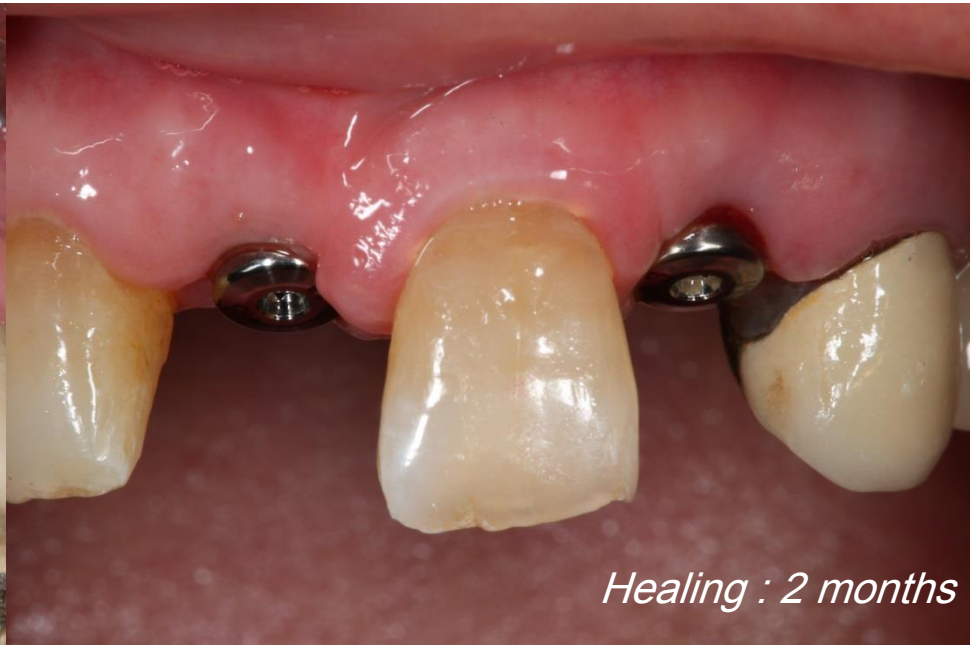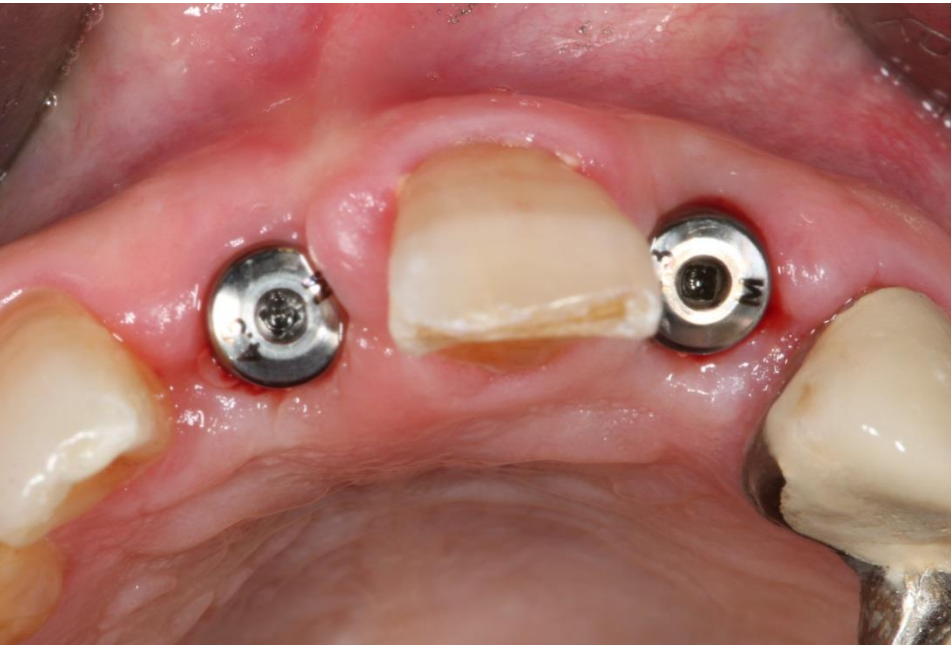Application of NR Line [Clinical case]



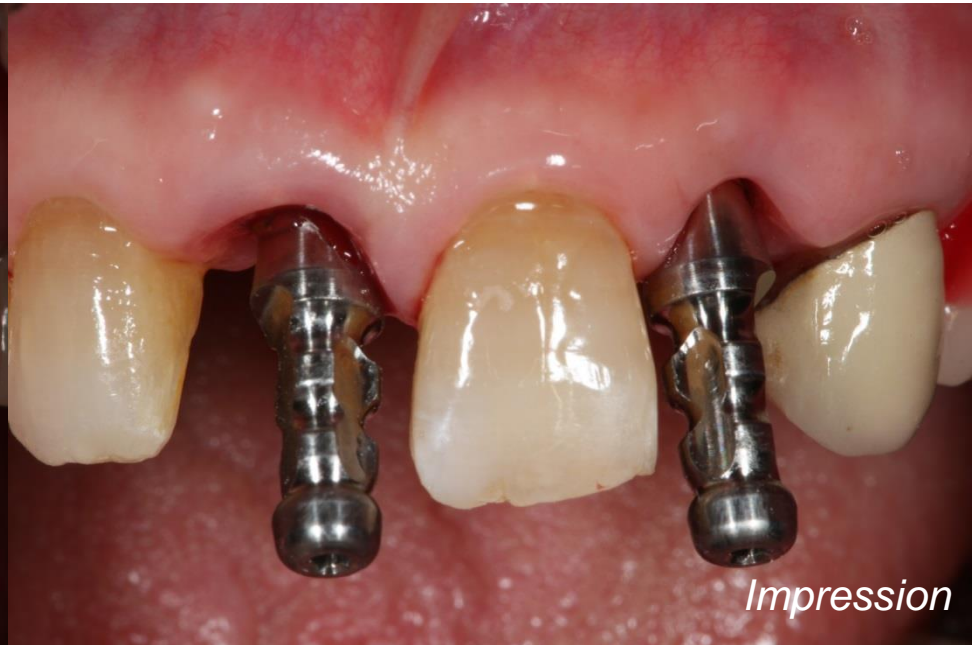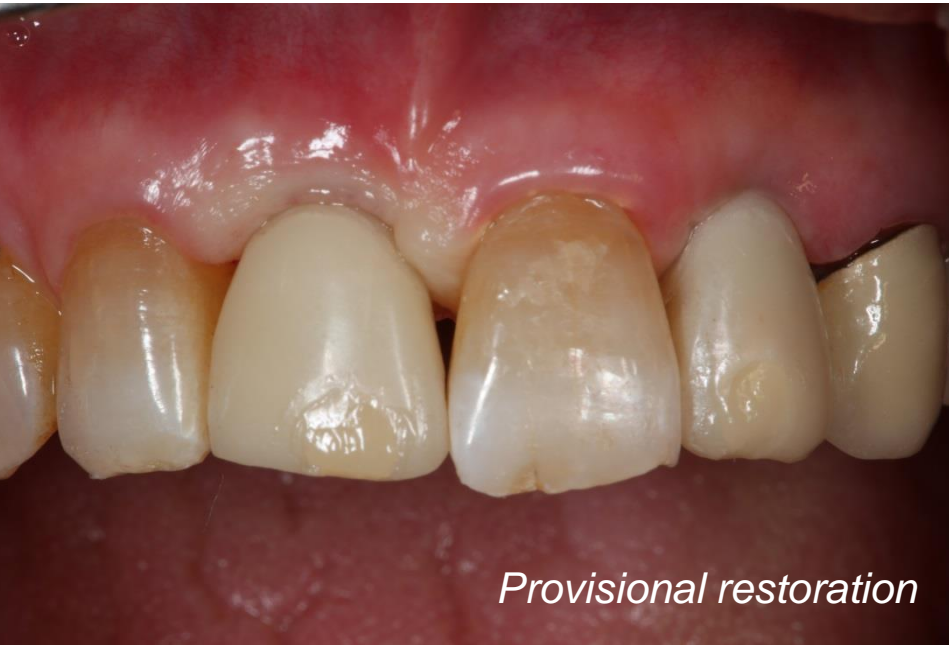Application of NR Line [Clinical case]



Application of NR Line [Clinical case]



Application of NR Line [Clinical case]



Application of NR Line [Clinical case]

