



Surgey

Dr. Root

2020.09.04 (Fri.)



[Case 1 Preview]

Minimalism Surgery on Lower Anterior area

Patient Information

Age : 75

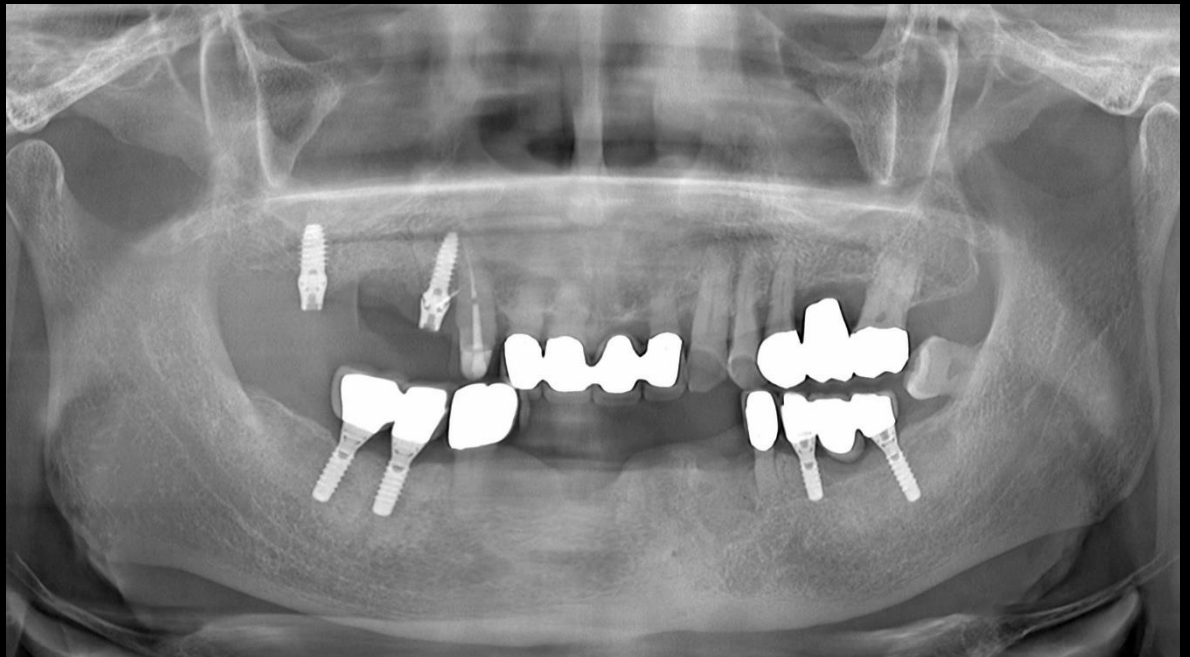
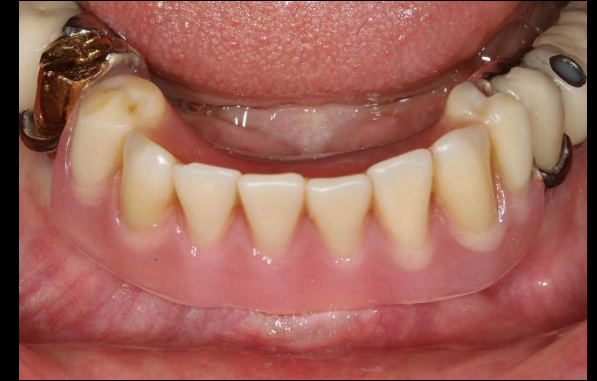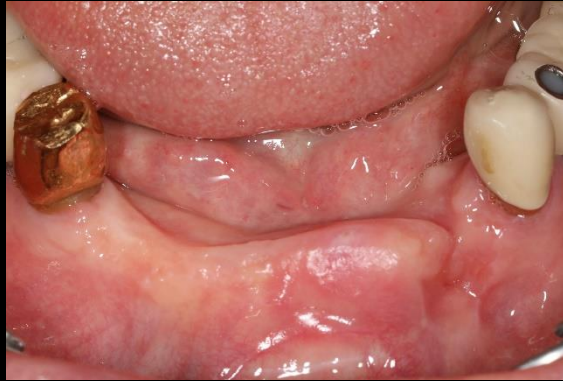Sex : Male

Chief Complaint

: I need to get dental implant treatment

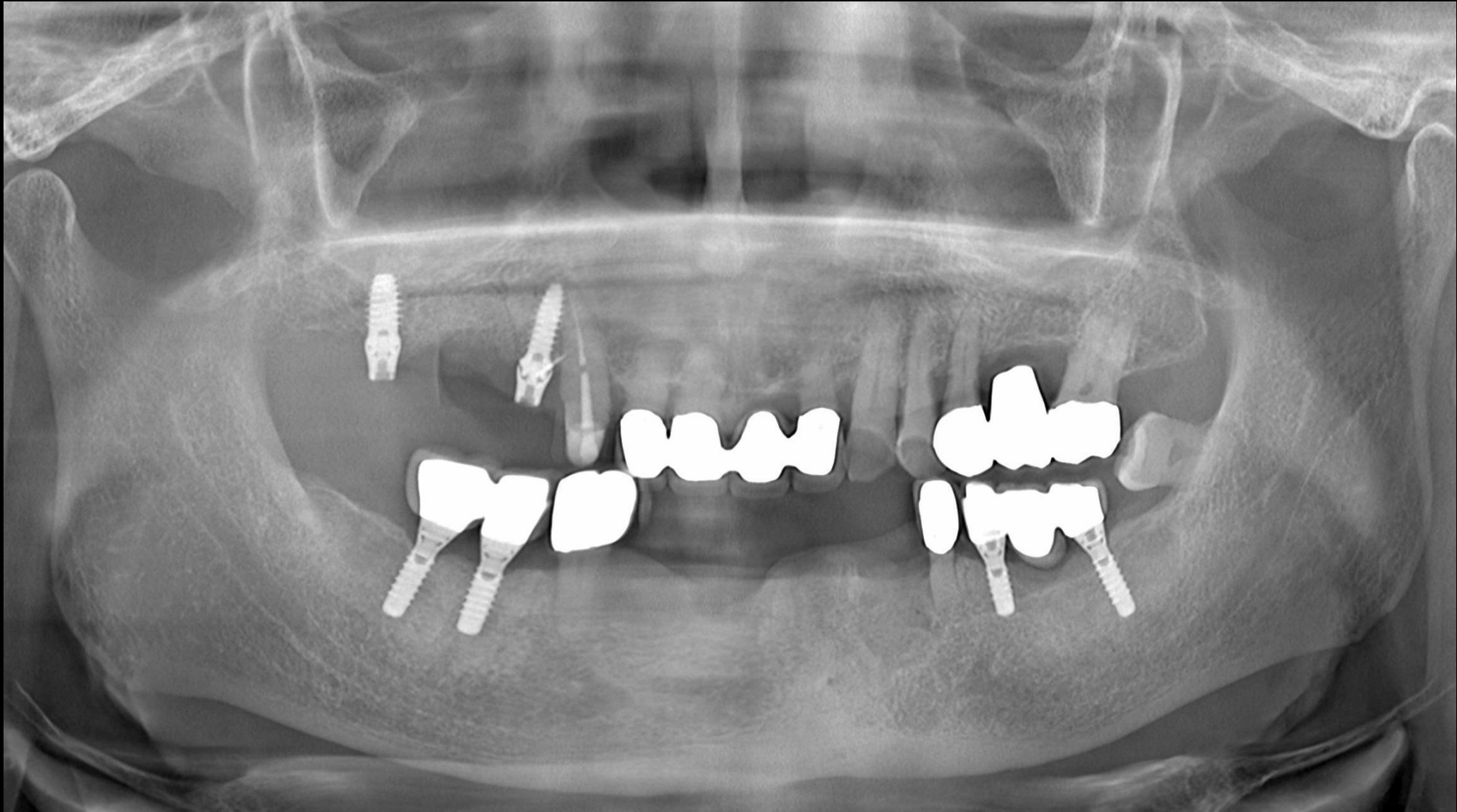
Past Medical History

: N/S



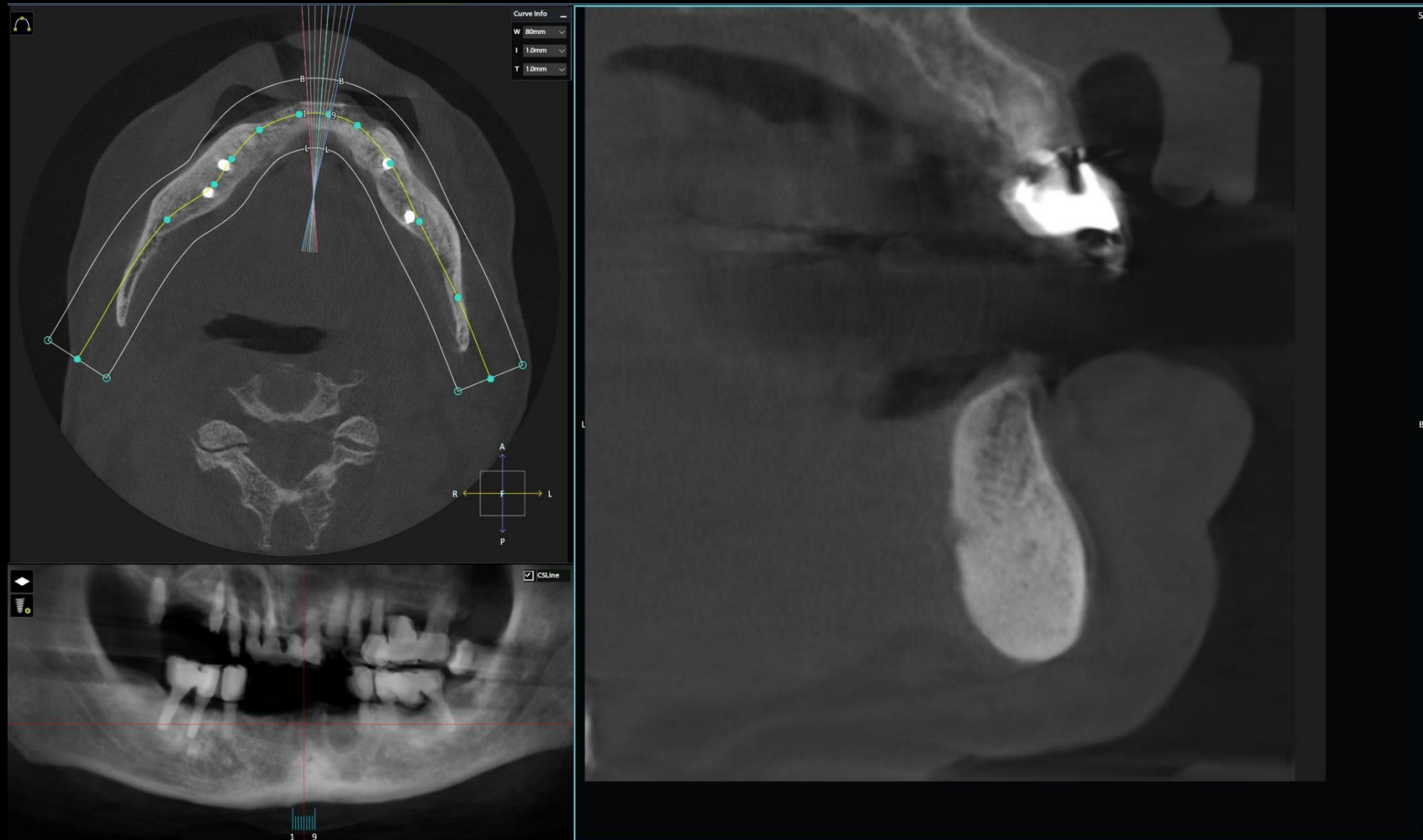
Pt. KYH (75/Male)

Pre-op (2020-08-27)



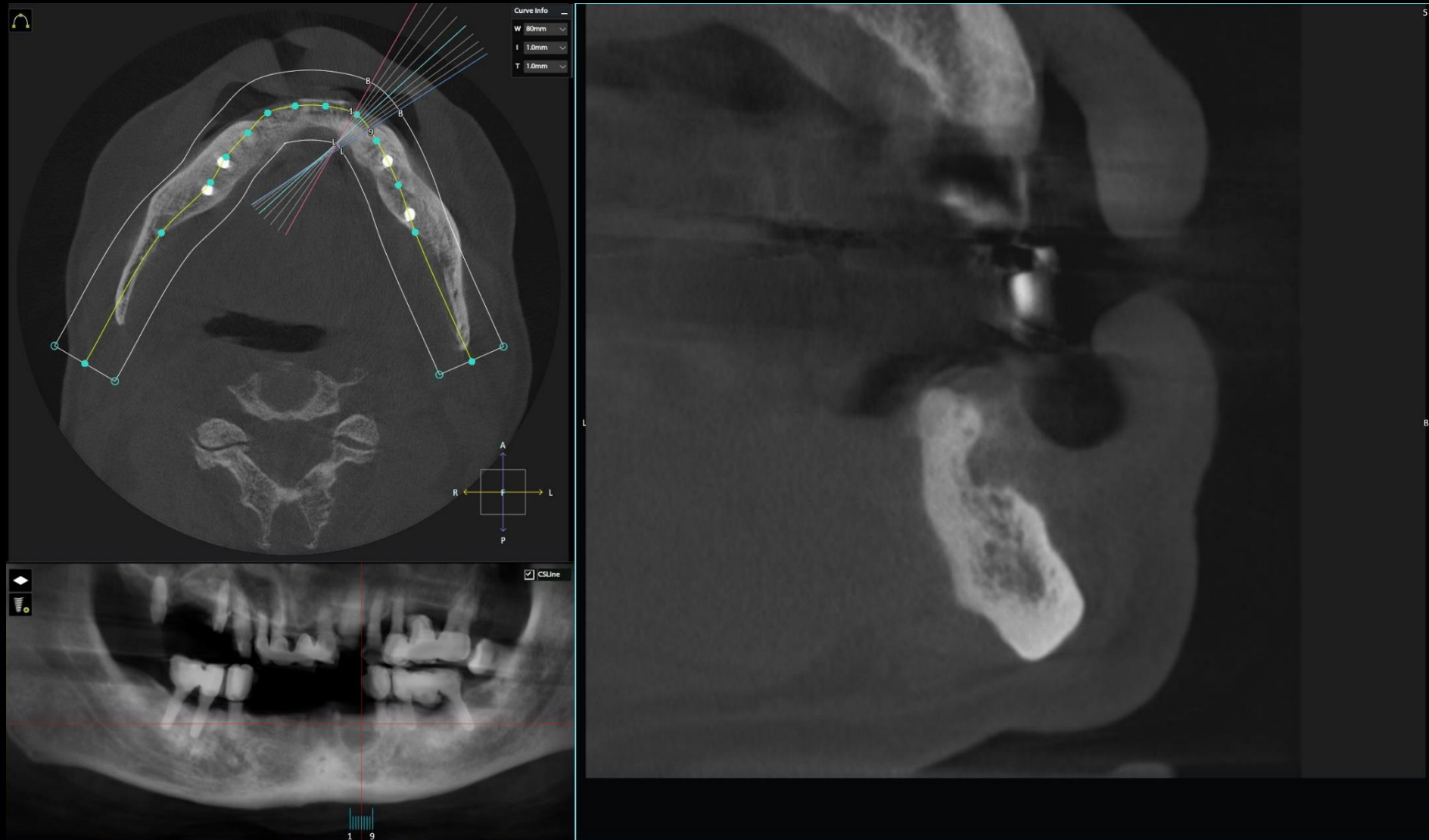Pt. KYH (75/Male)

#31 Pre-op (2020-08-27)



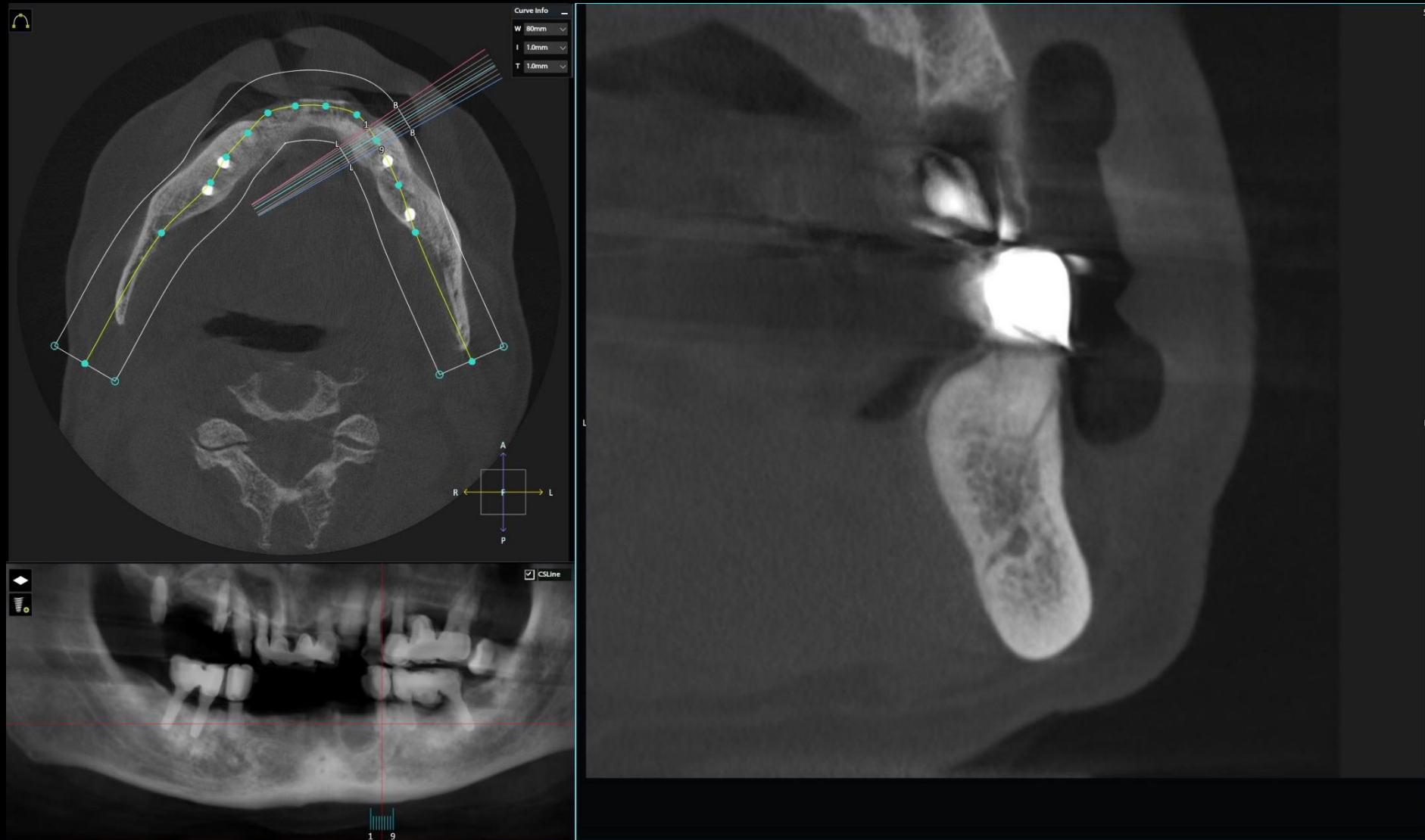Pt. KYH (75/Male)

#33 Pre-op (2020-08-27)



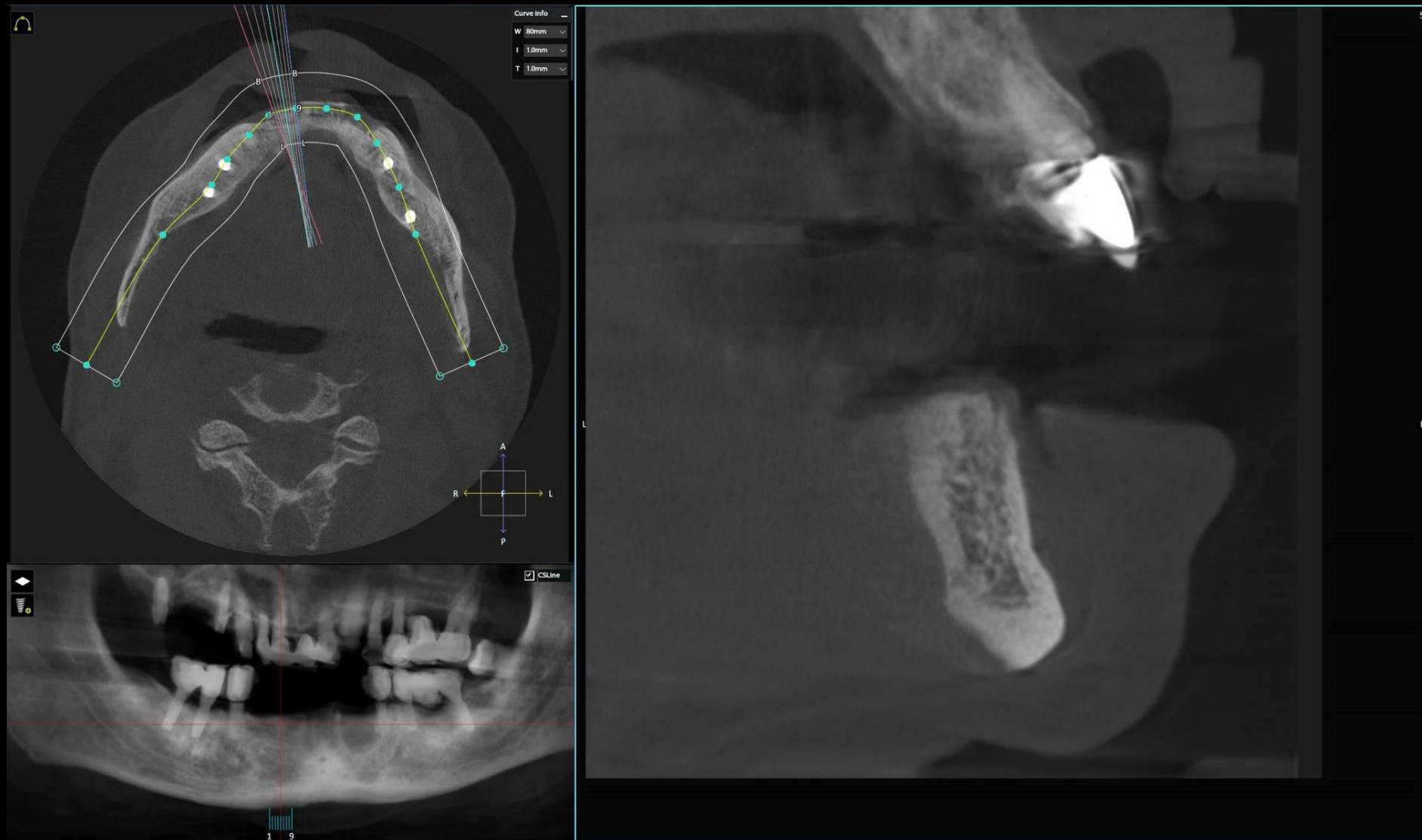Pt. KYH (75/Male)

#34 Pre-op (2020-08-27)



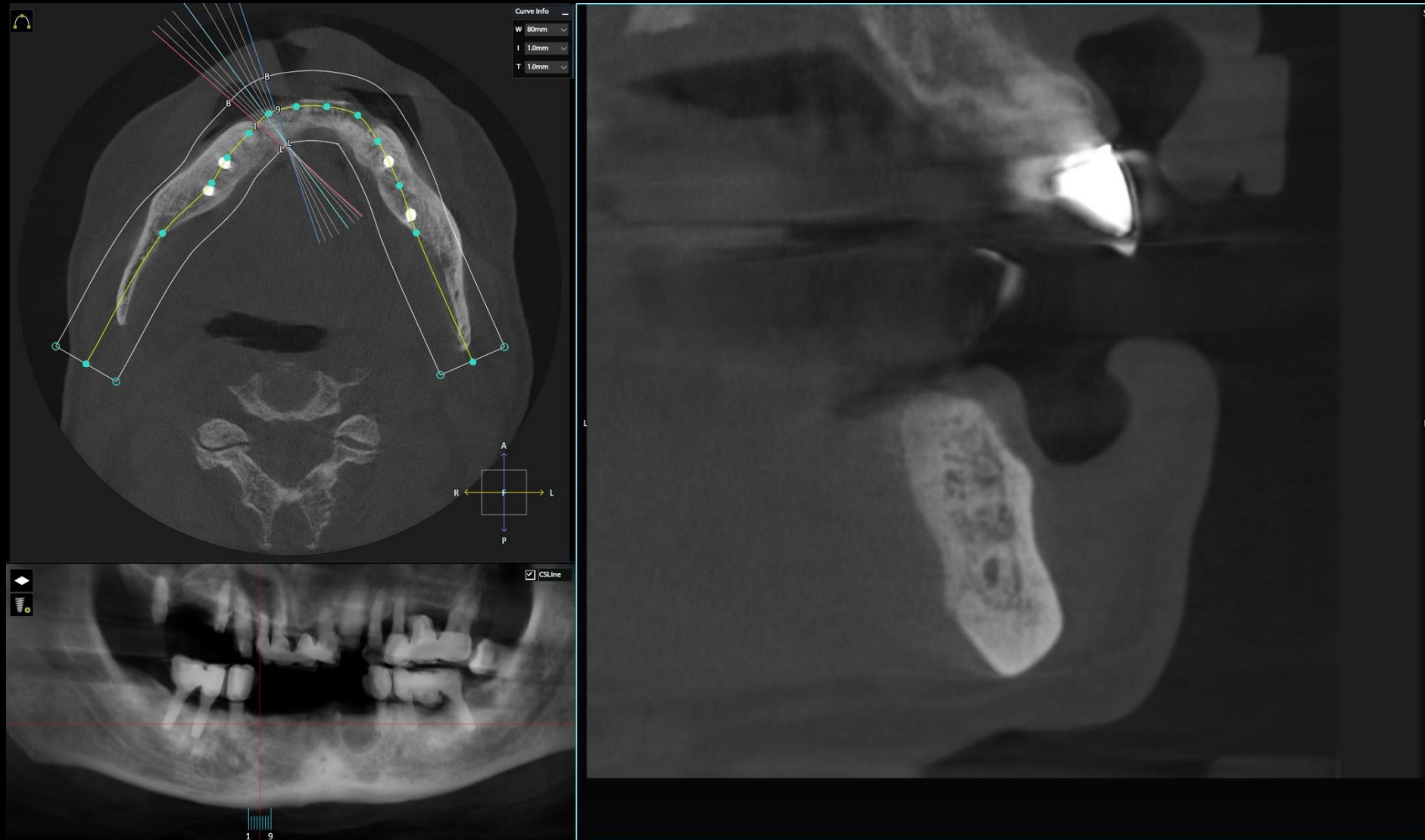Pt. KYH (75/Male)

#43 Pre-op (2020-08-27)

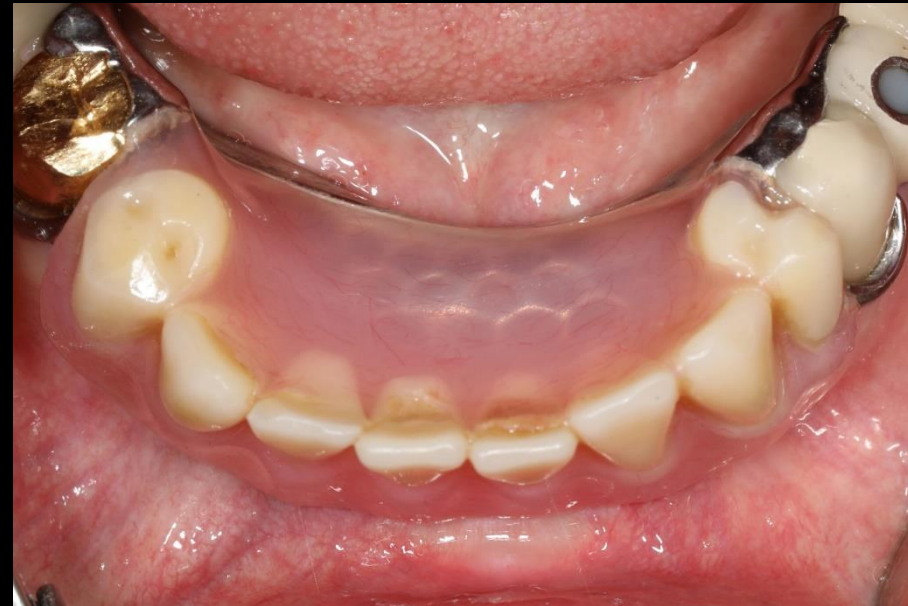
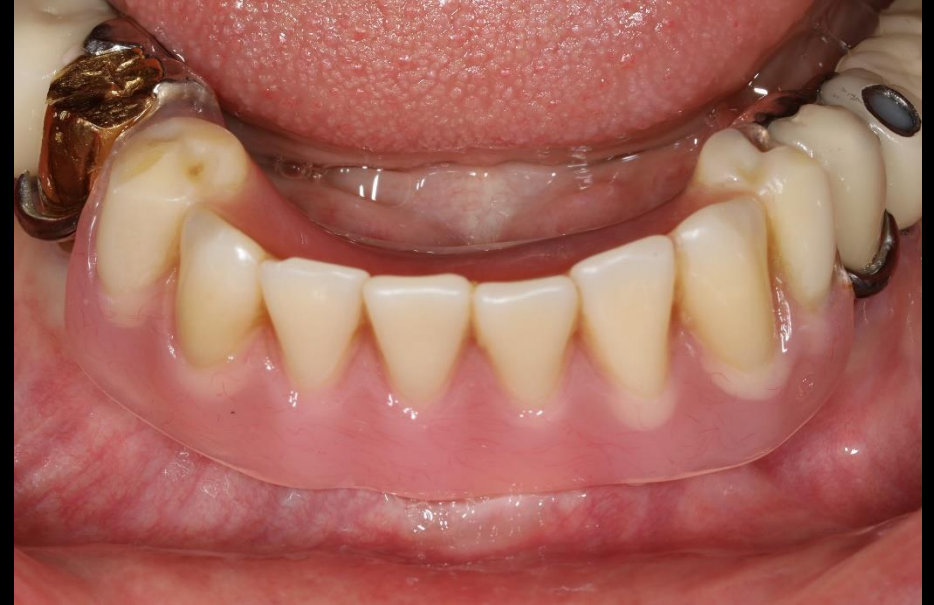
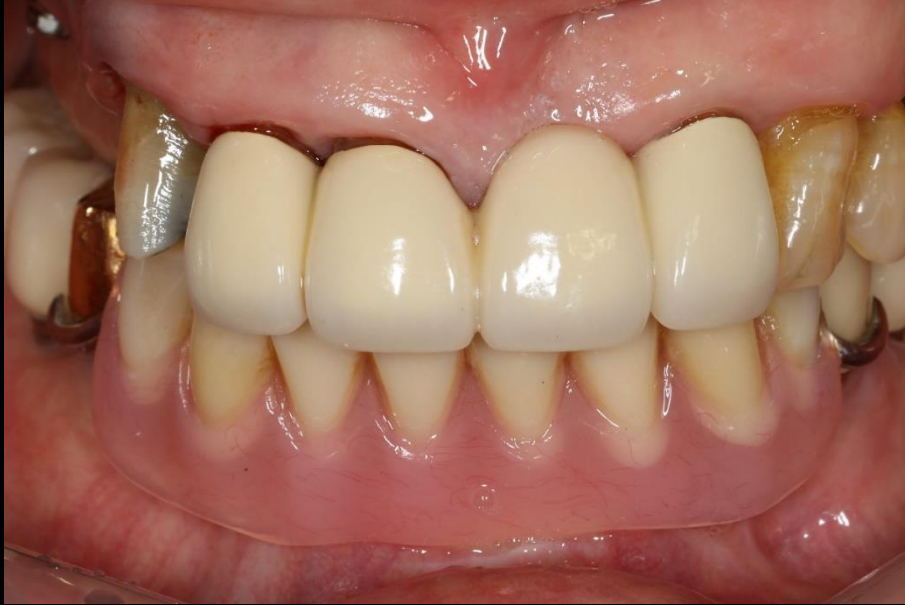Pt. KYH (75/Male)

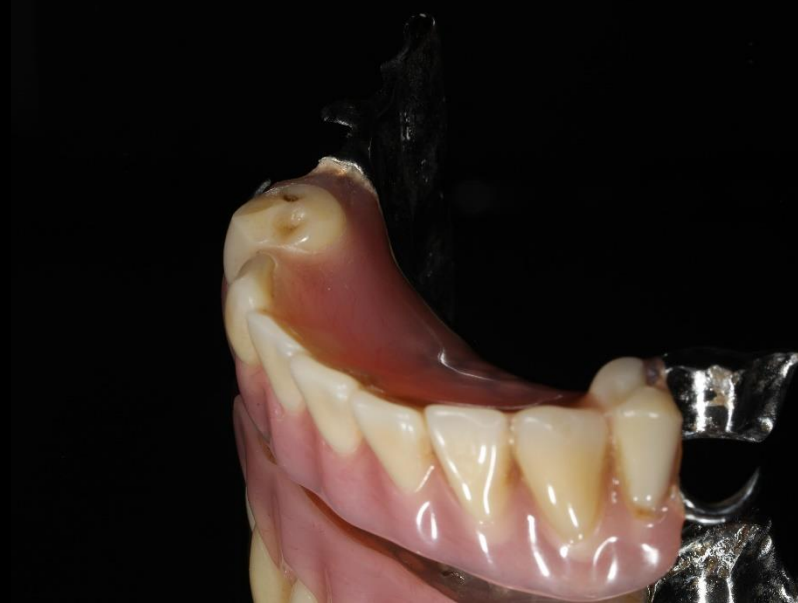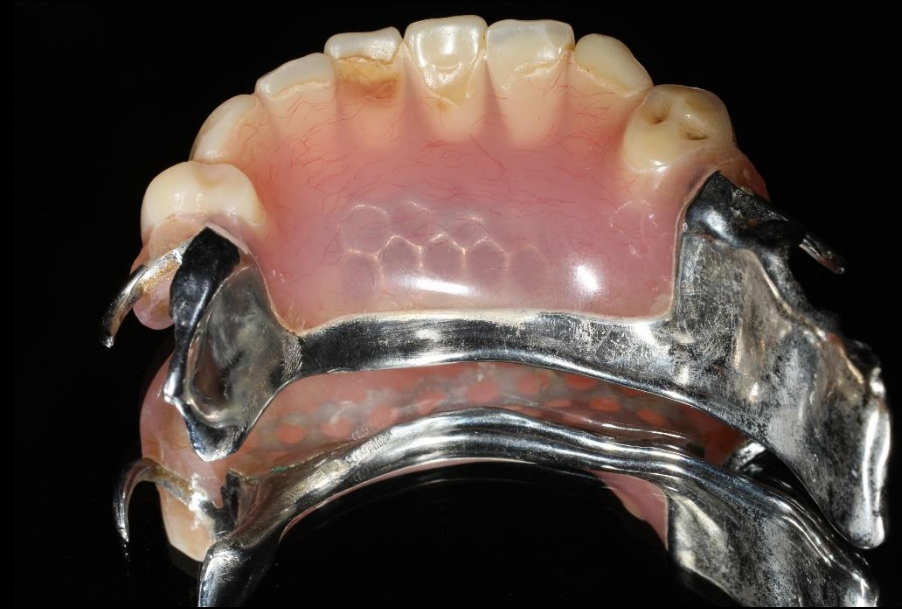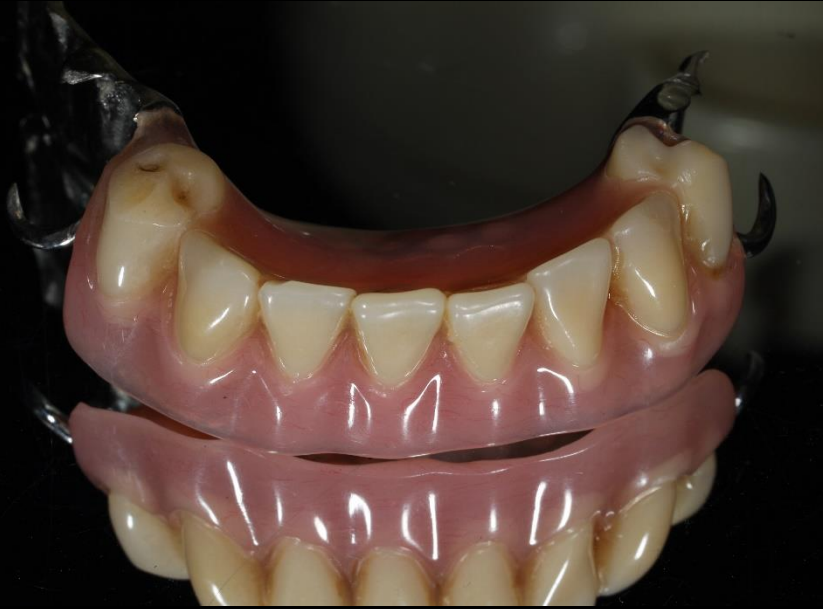#44 Pre-op (2020-08-27)



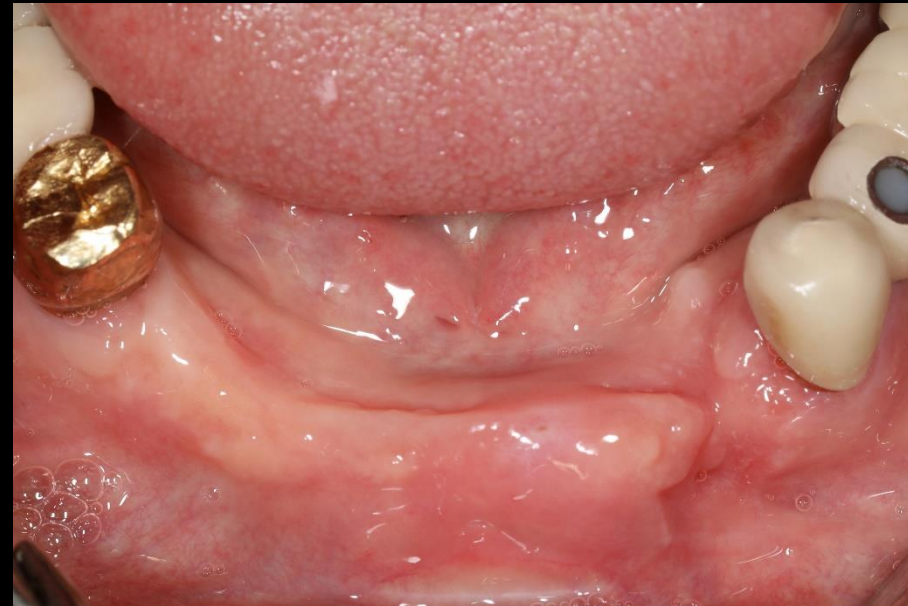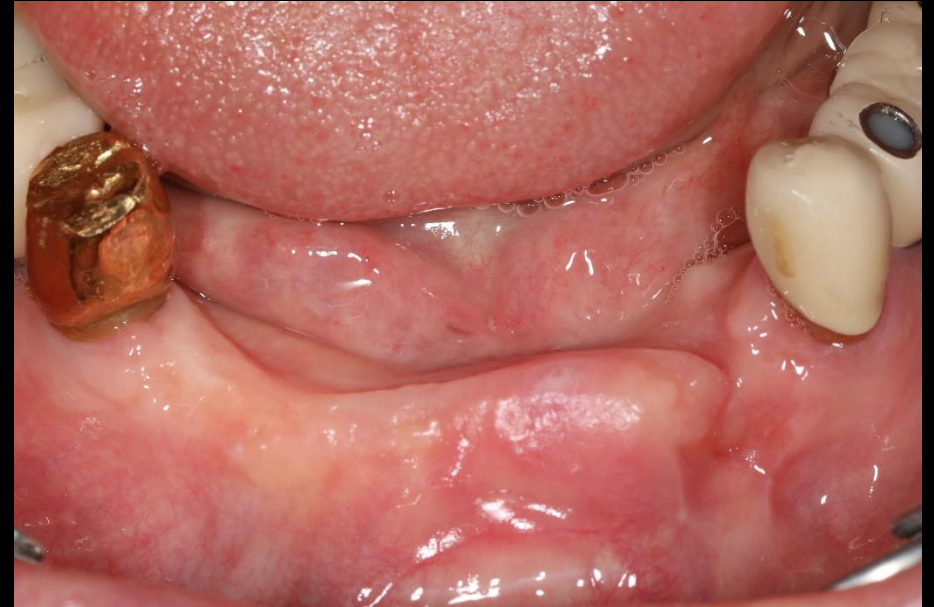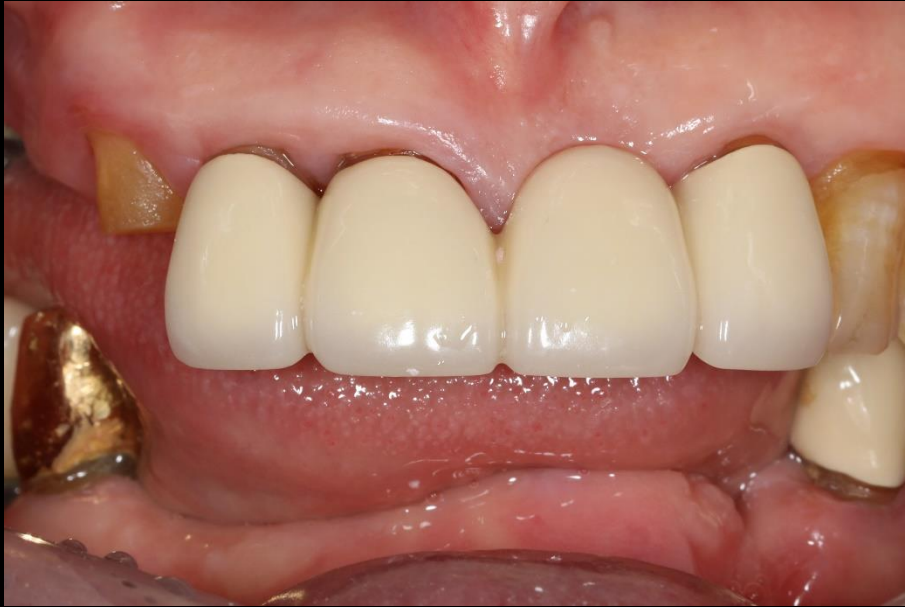Initial Photo (with Removable partial denture)



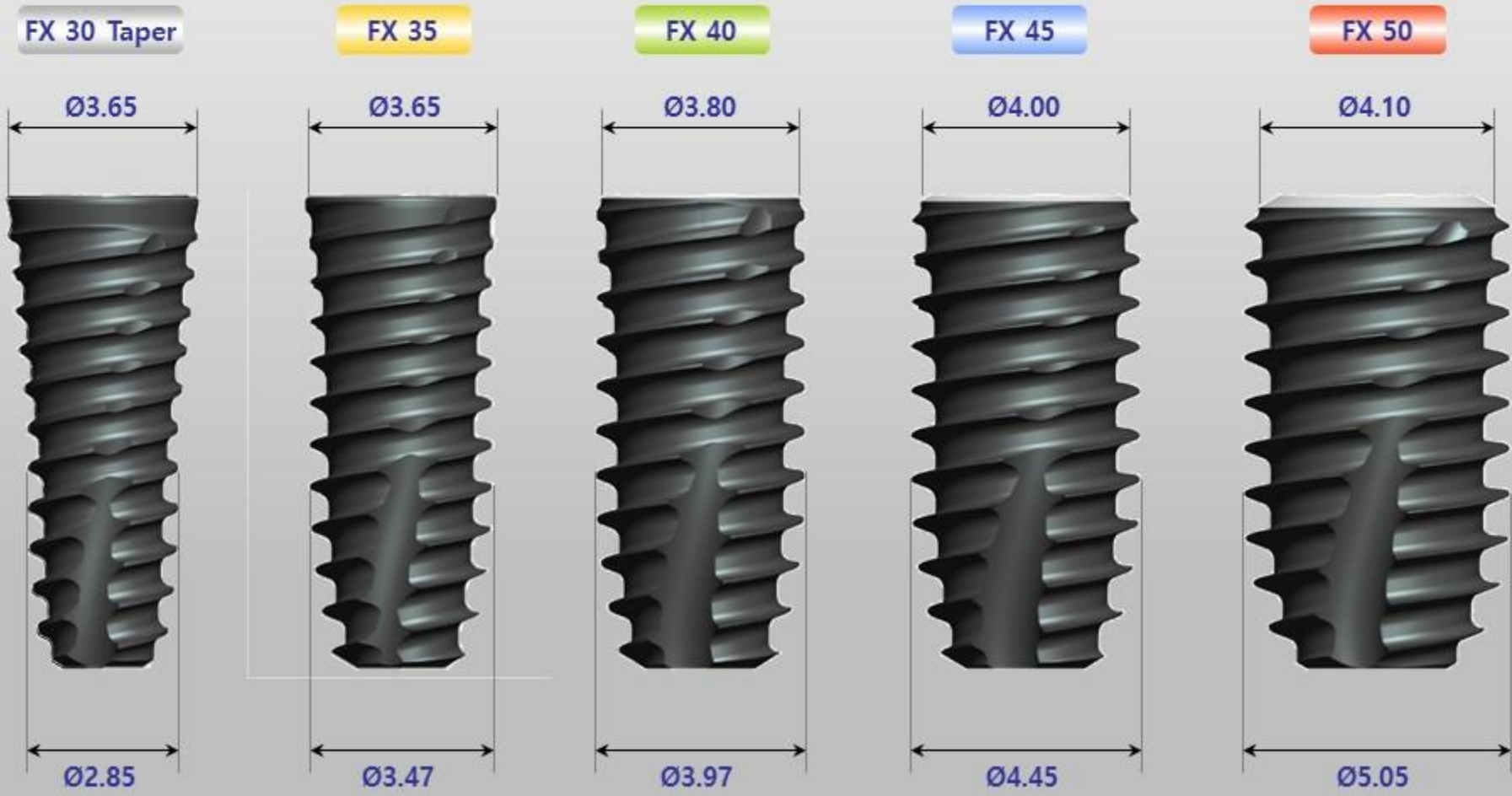
Removable partial denture



Initial Photo



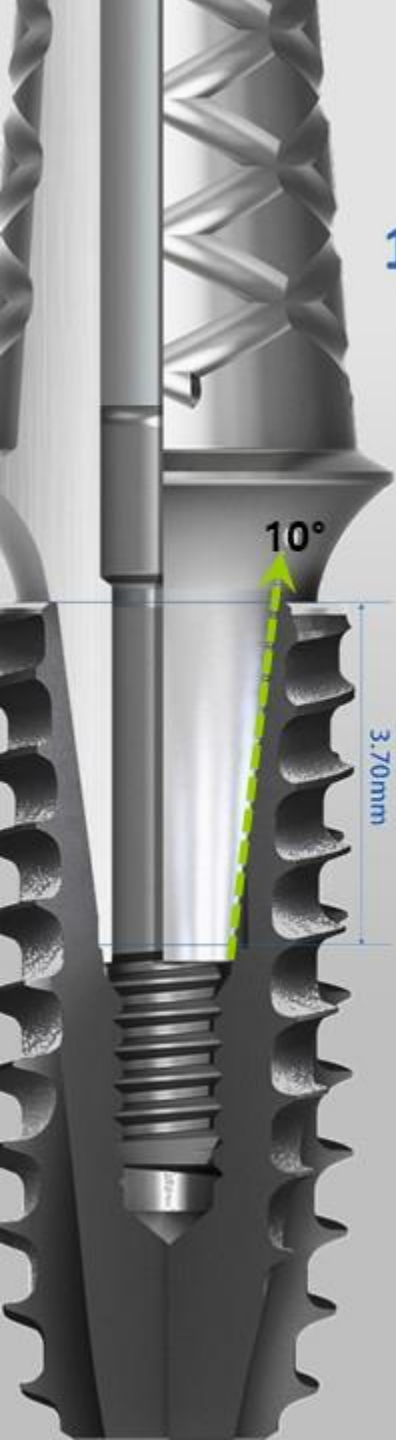
Bone Level Implant



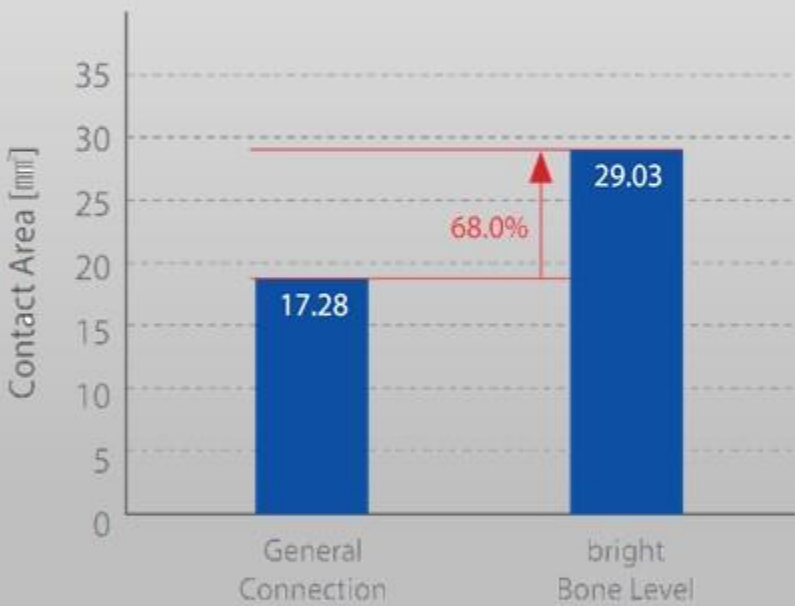
Bone Level Implant-Abutment Connection

10° , 3.70 mm Deep Connection

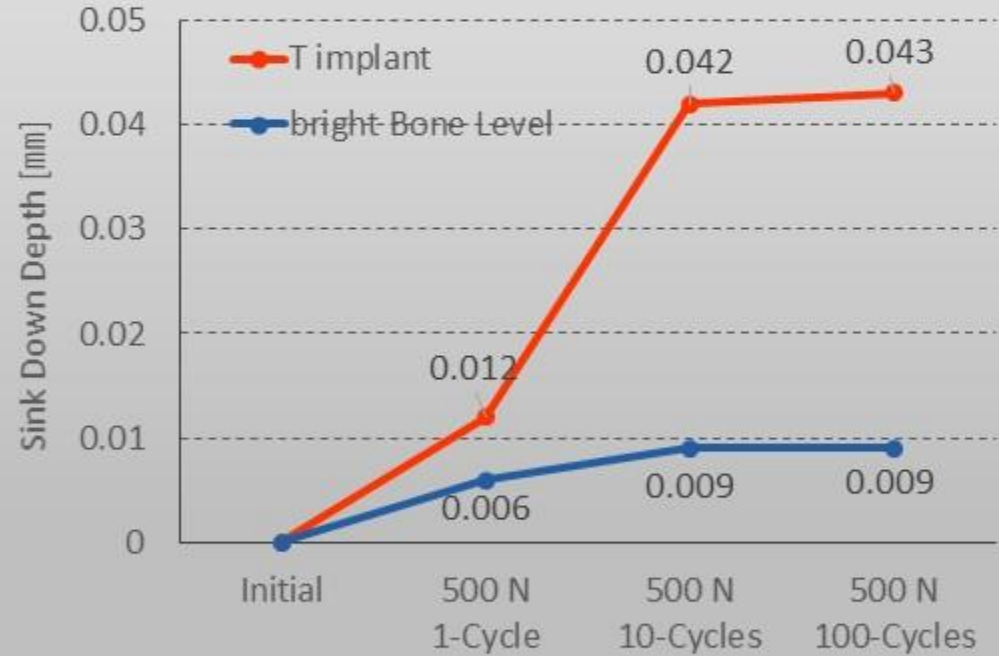- Excellent Joint Stability



Contact Area

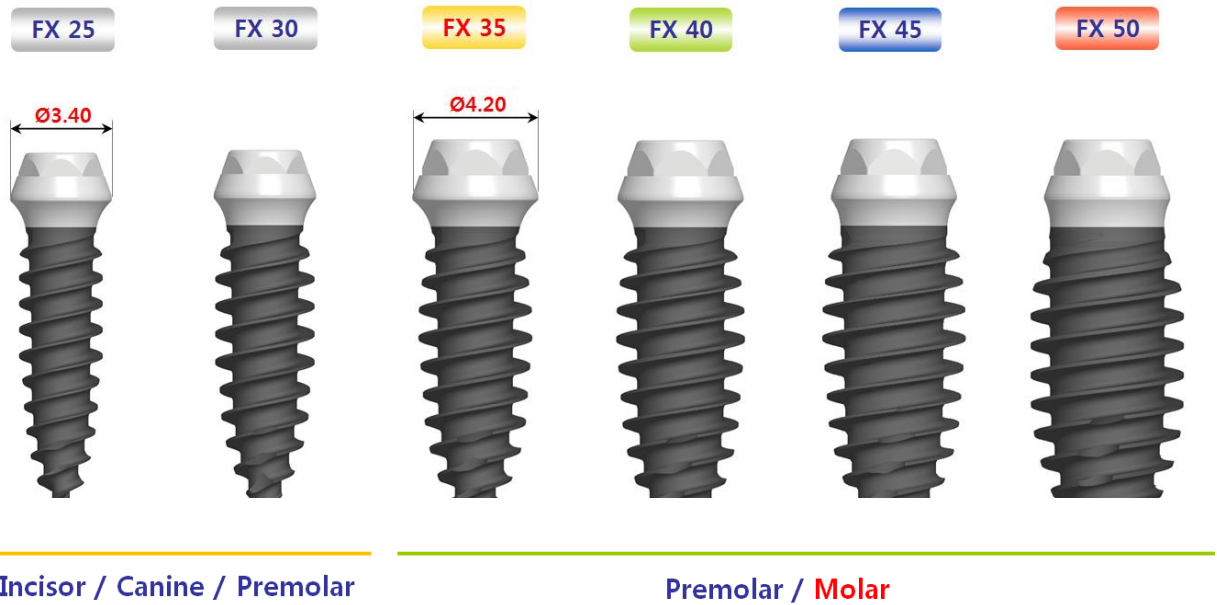
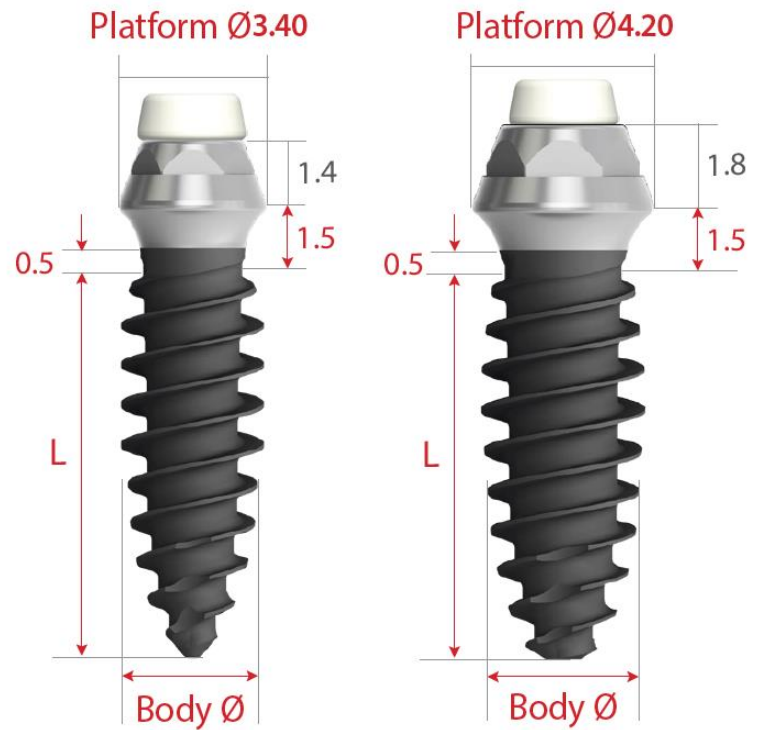


Sink Down



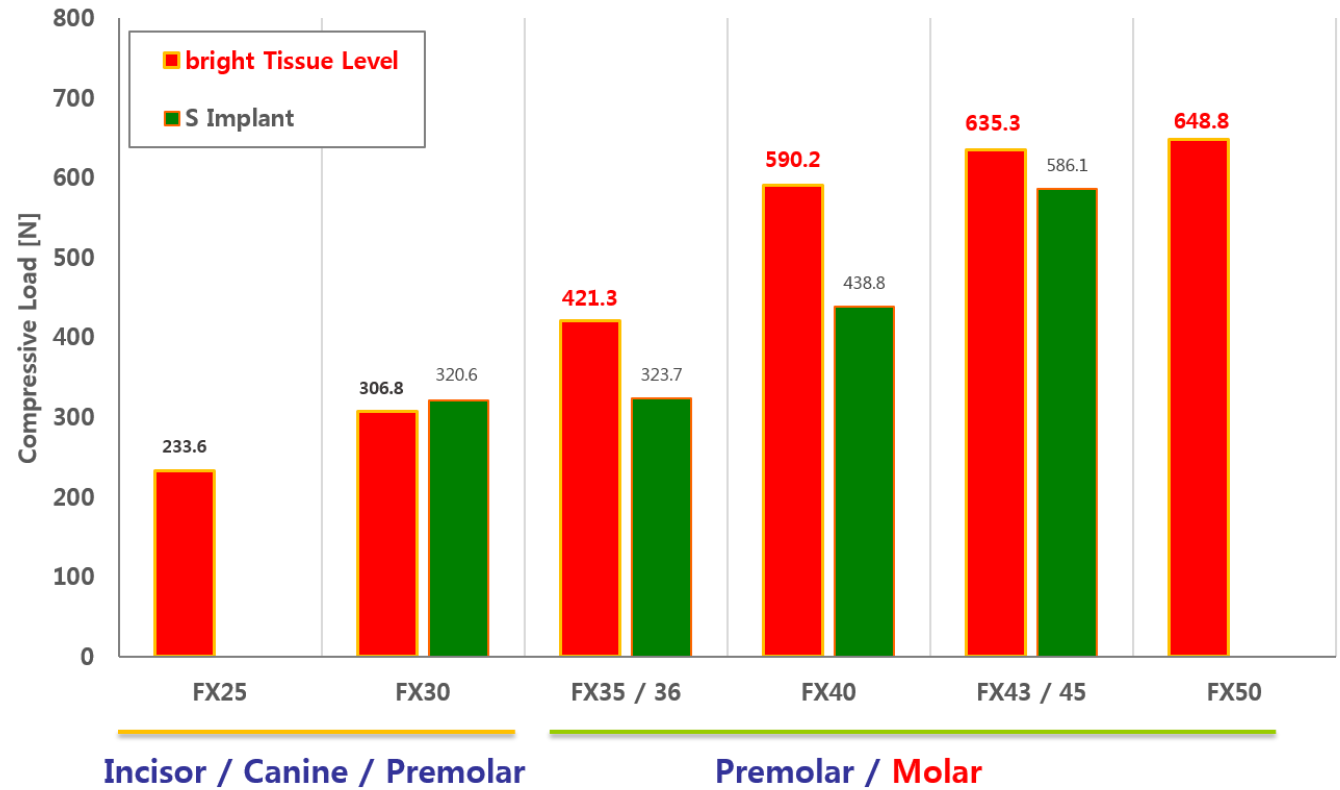
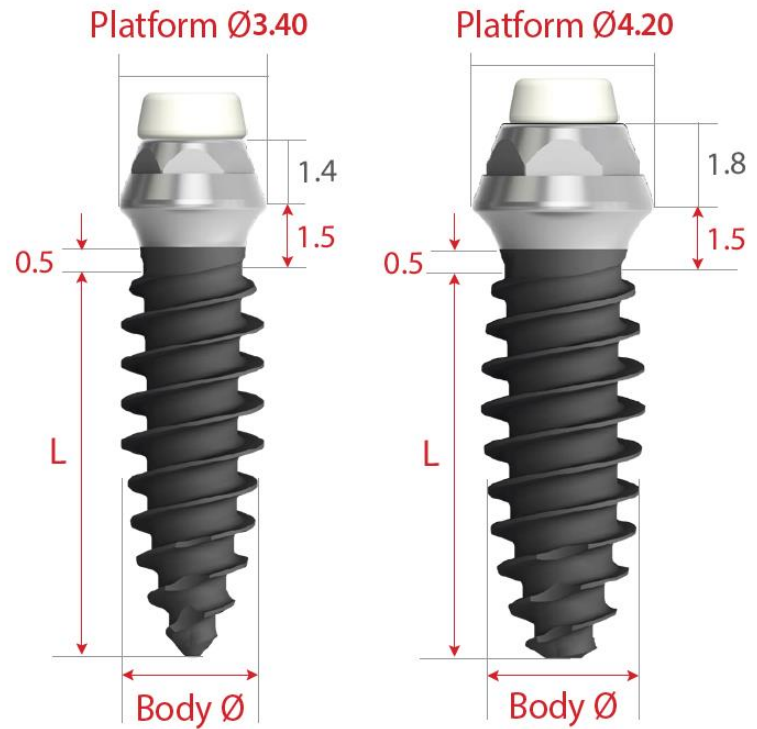
Tissue Level

Fixture (Included Cover Screw) 



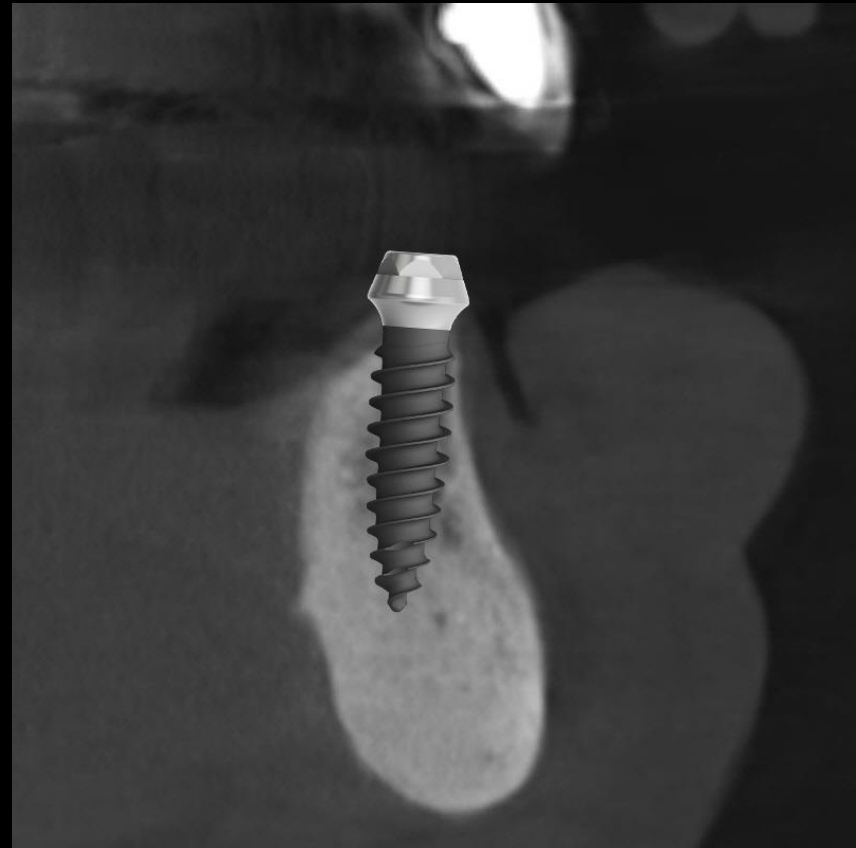
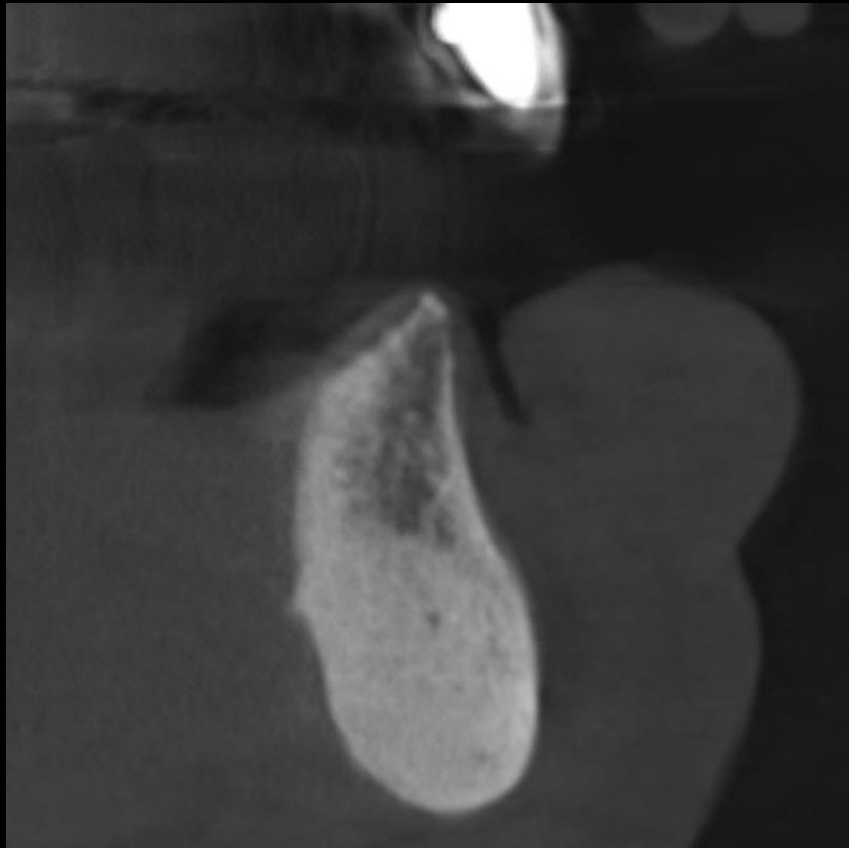
Tissue Level

Fixture (Included Cover Screw) 



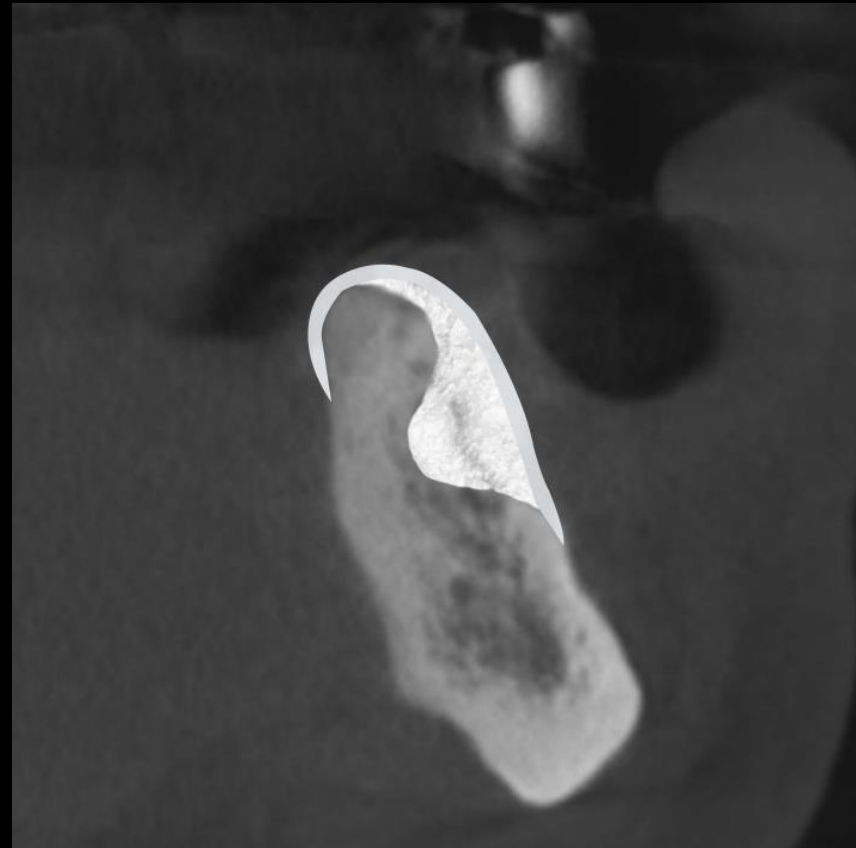
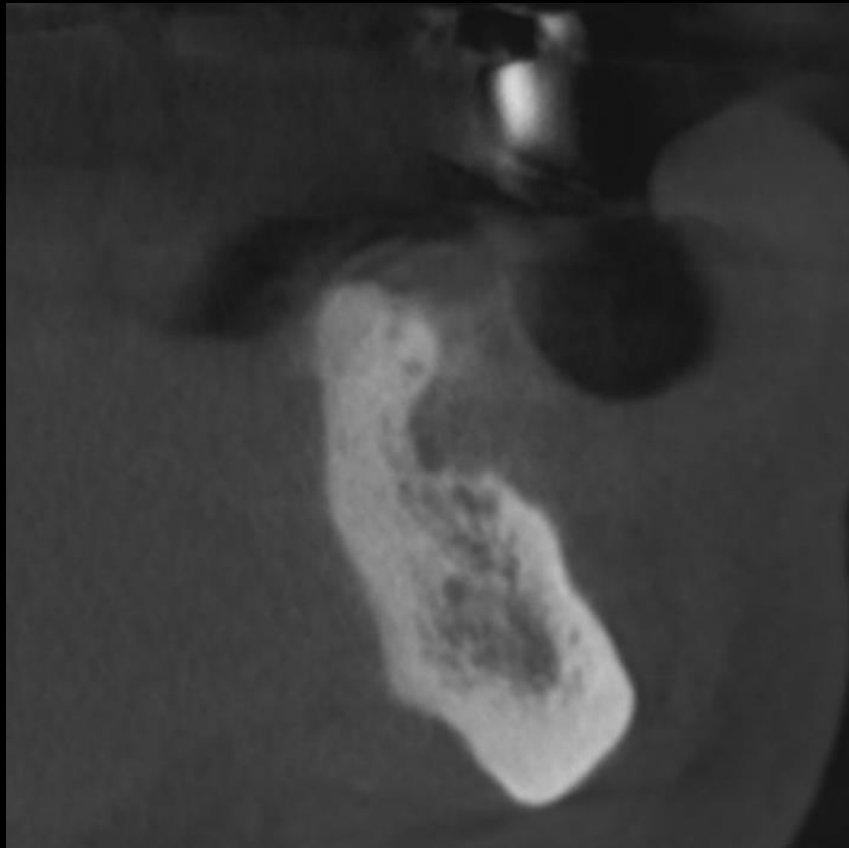
Treatment Plan (#31)

- #31 : Ø 2.5 Size fixture installation



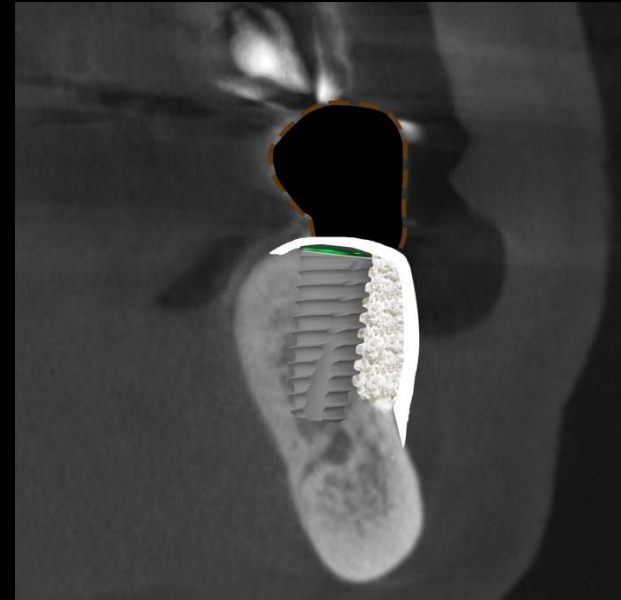
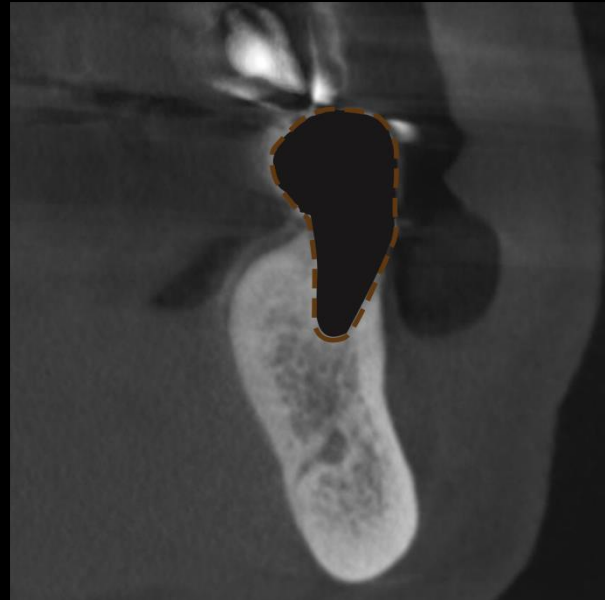
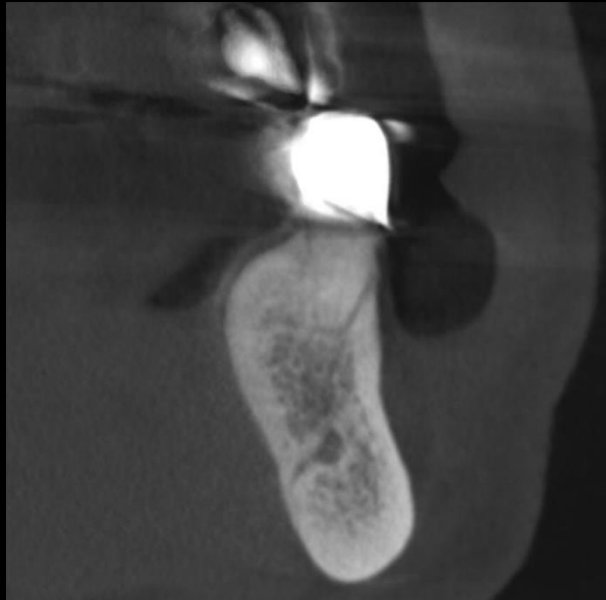Treatment Plan (#33)

- #33 : Bone graft using Block or Collagen Type



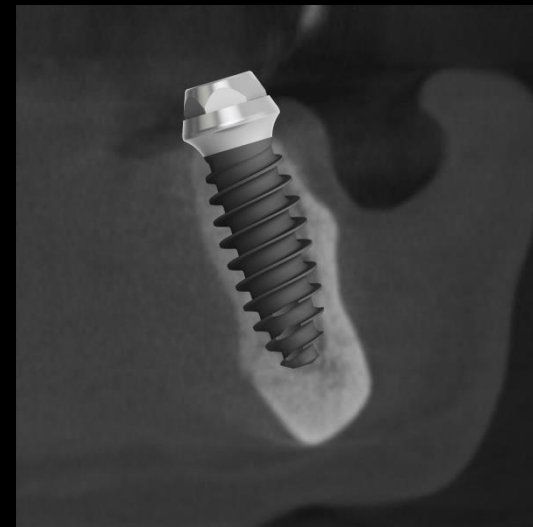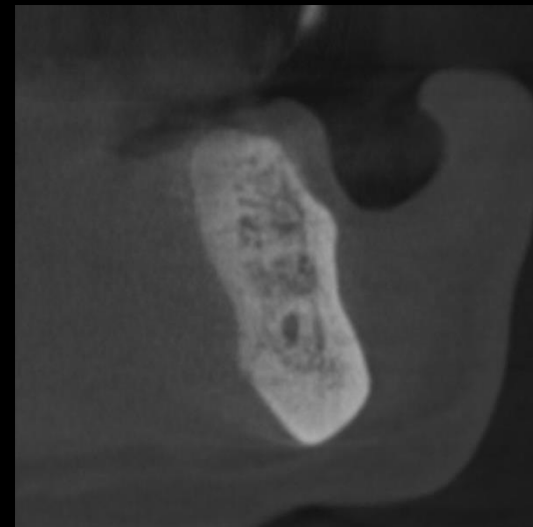
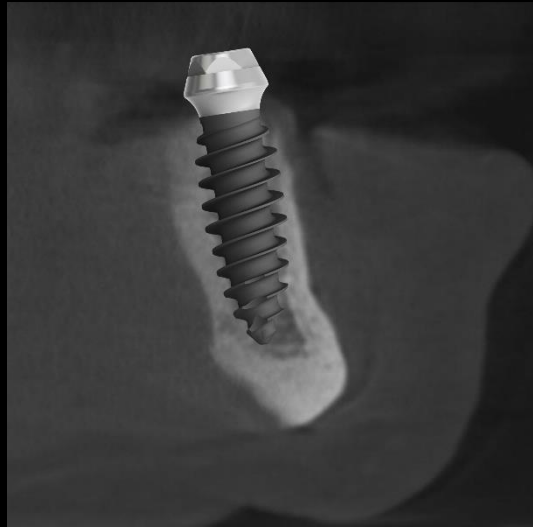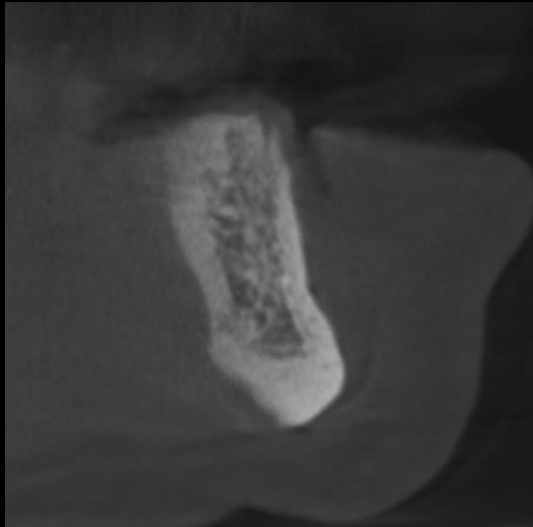
Treatment Plan (#34)

- #34 : Extraction & Gap Filling / \varnothing 4.0 Size fixture installation

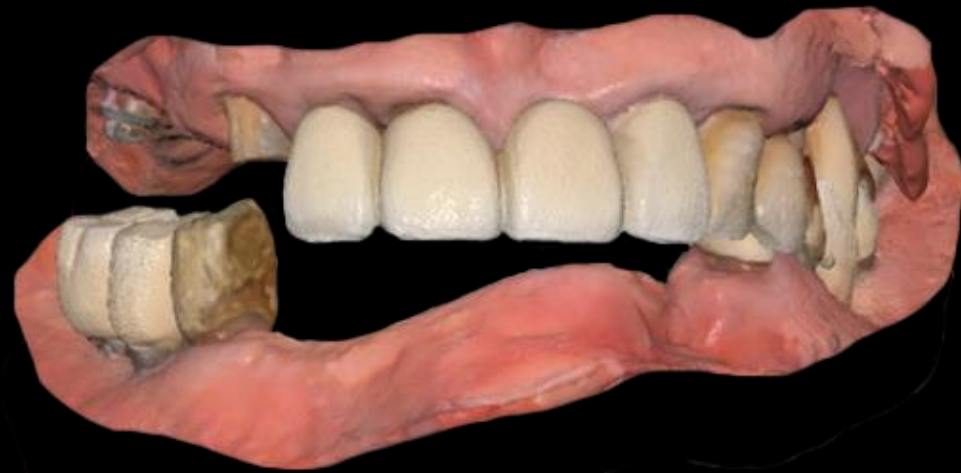
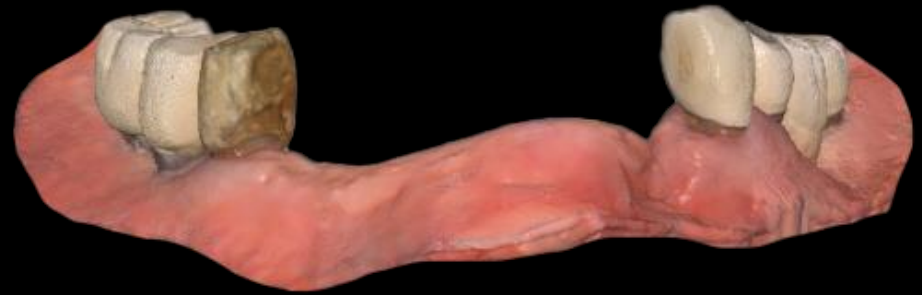
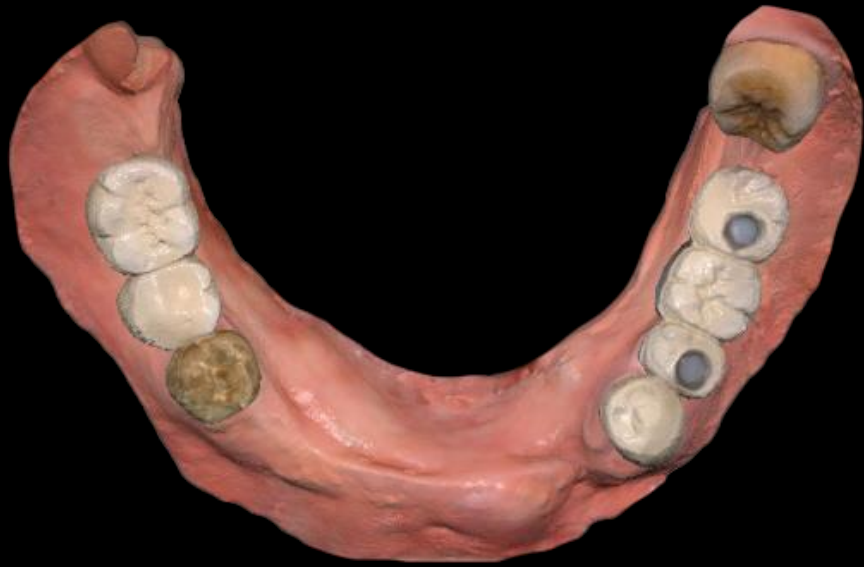Treatment Plan (#43, 44)

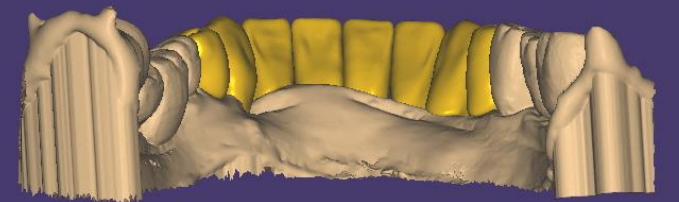
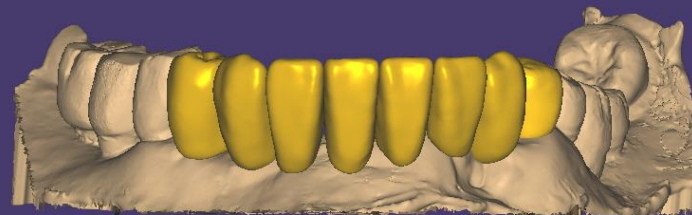
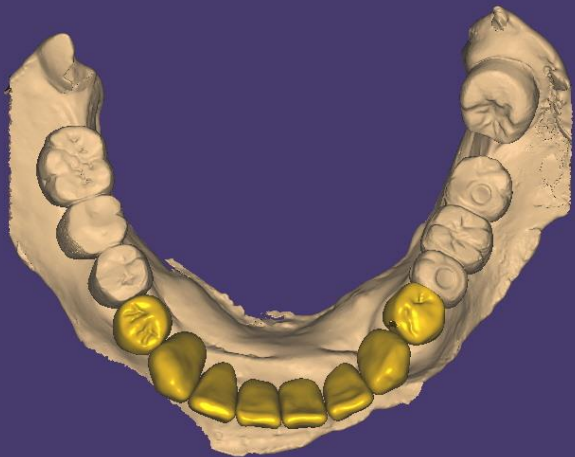
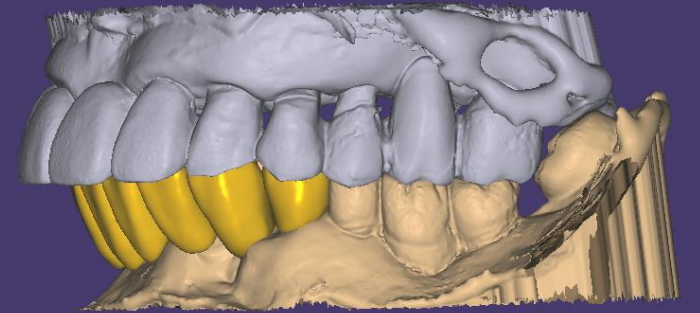
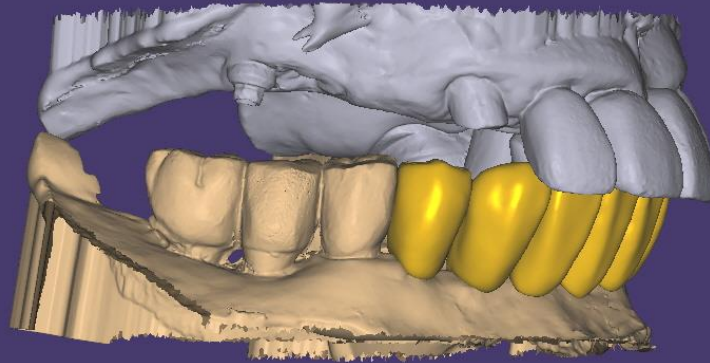
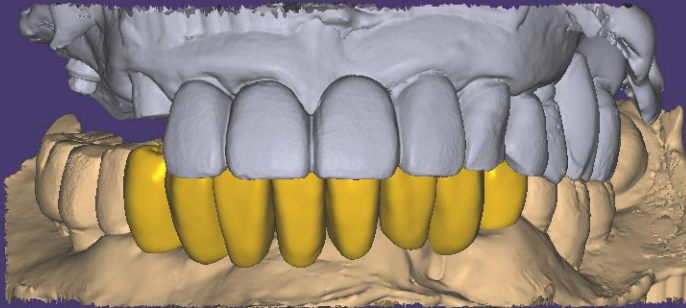
- #43 : **Ø 3.0** Size fixture installation & Minimalism surgery
- #44 : **Ø 3.5** Size fixture installation & Minimalism surgery



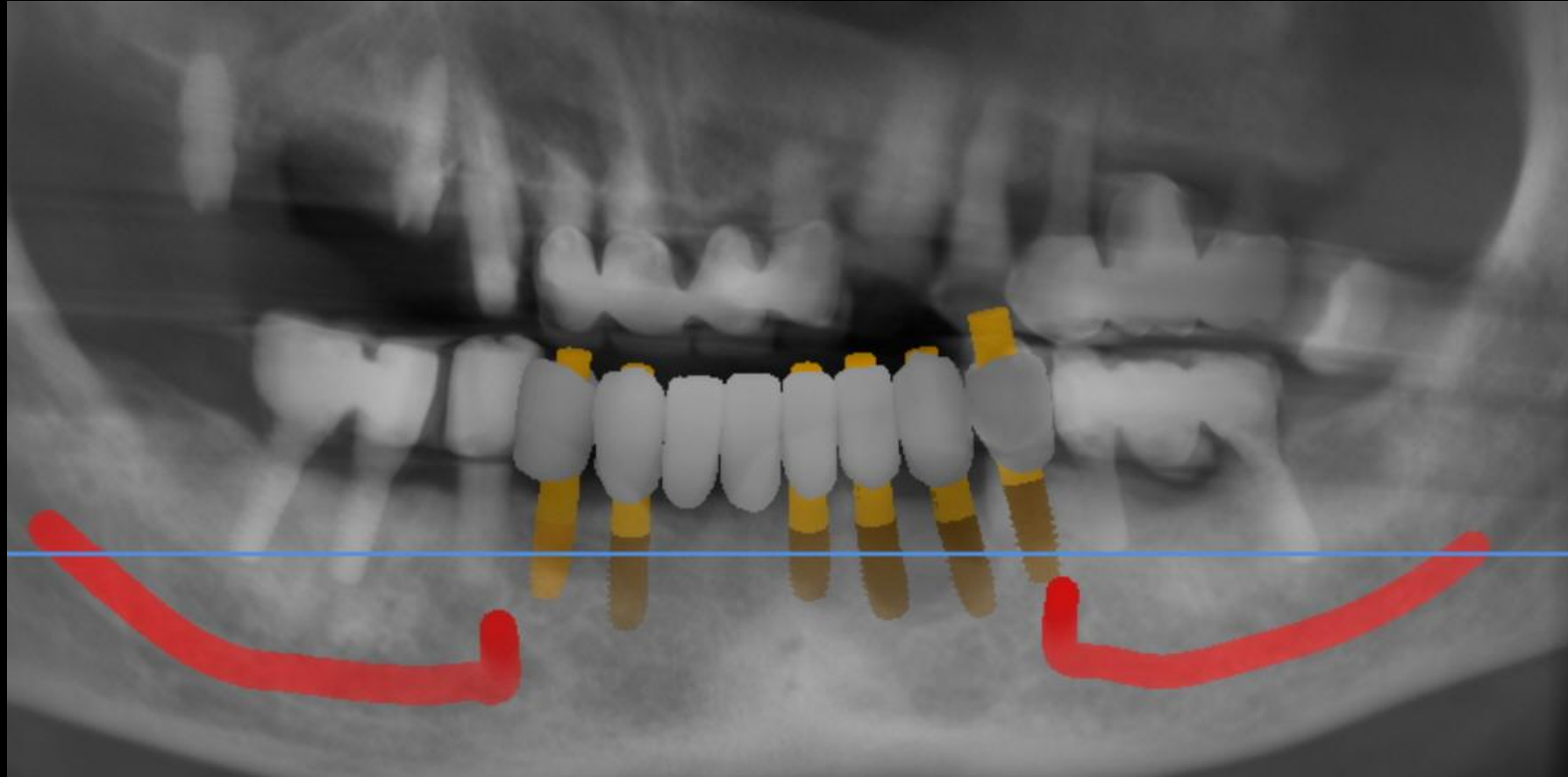
Intra Oral Scanning



Virtual Set up

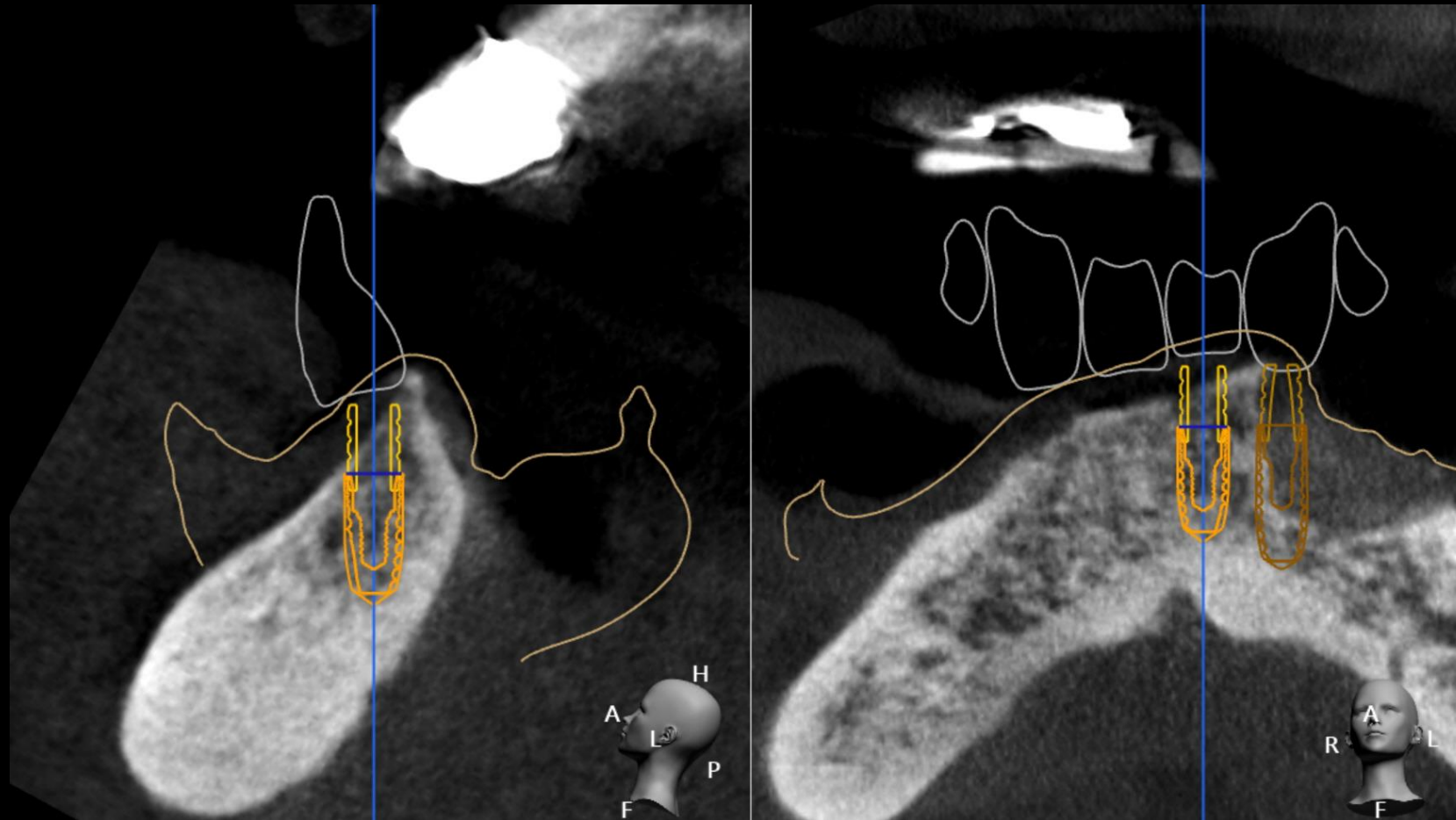


Implant Planning



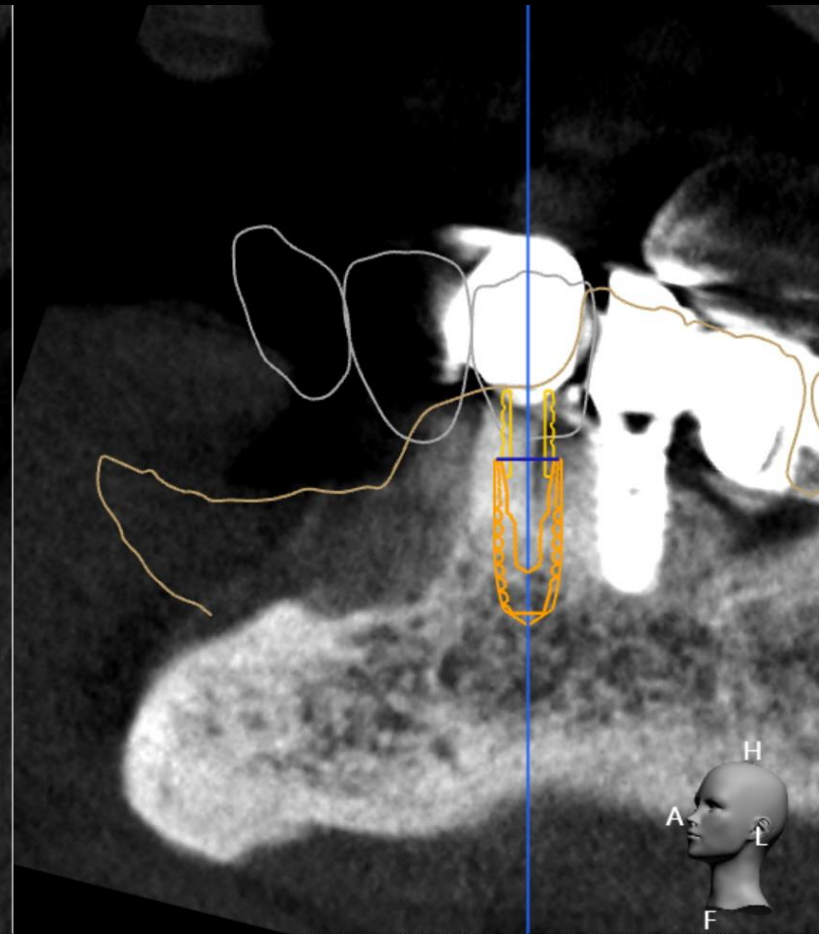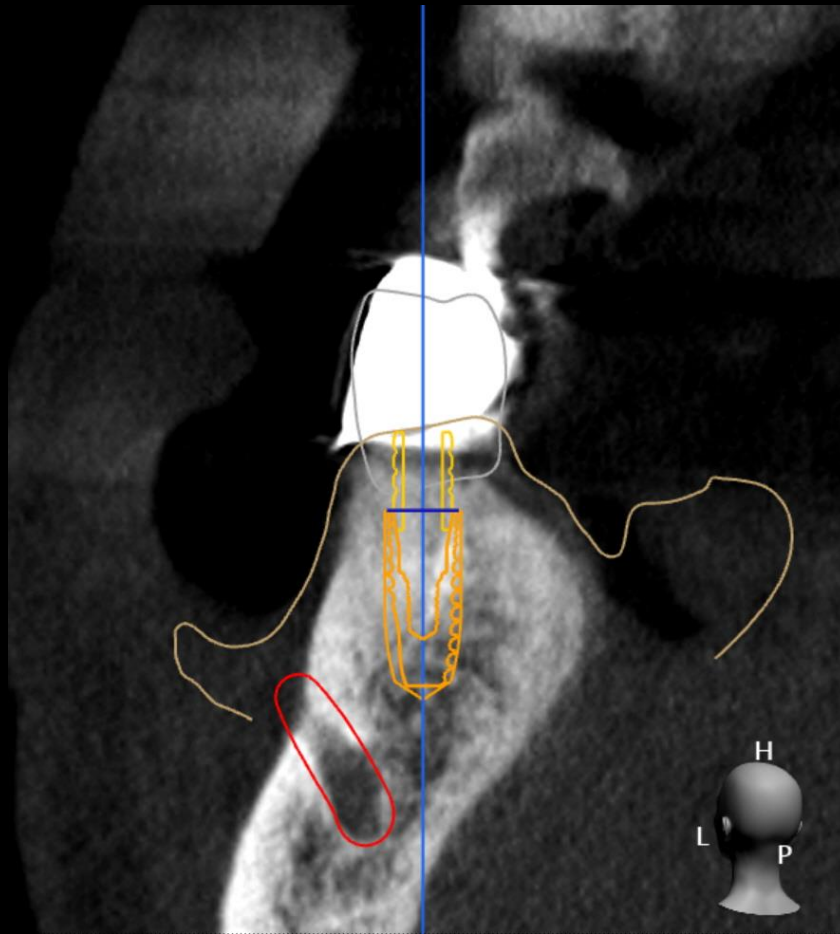
Implant Planning

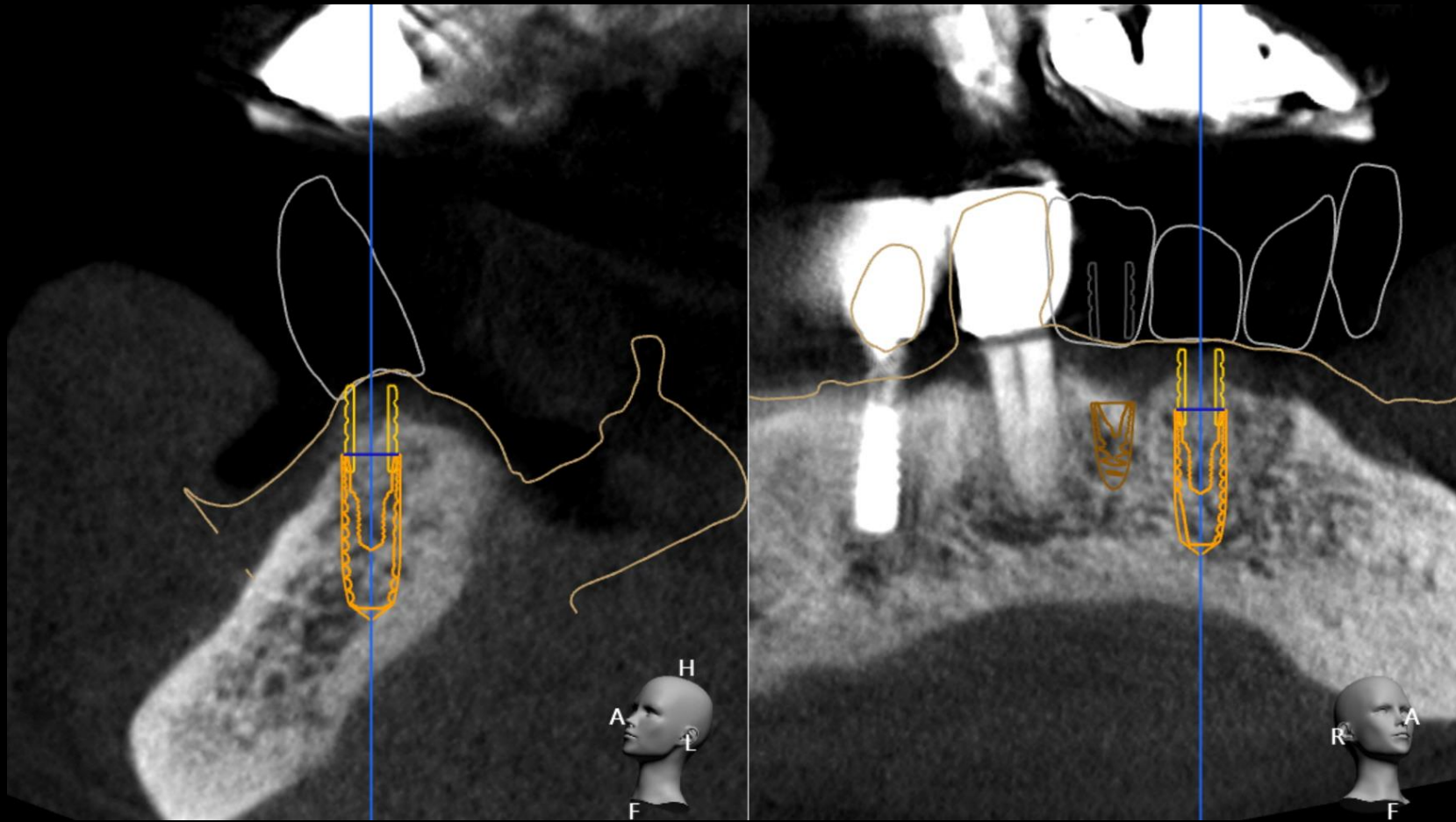
#31 (2509)

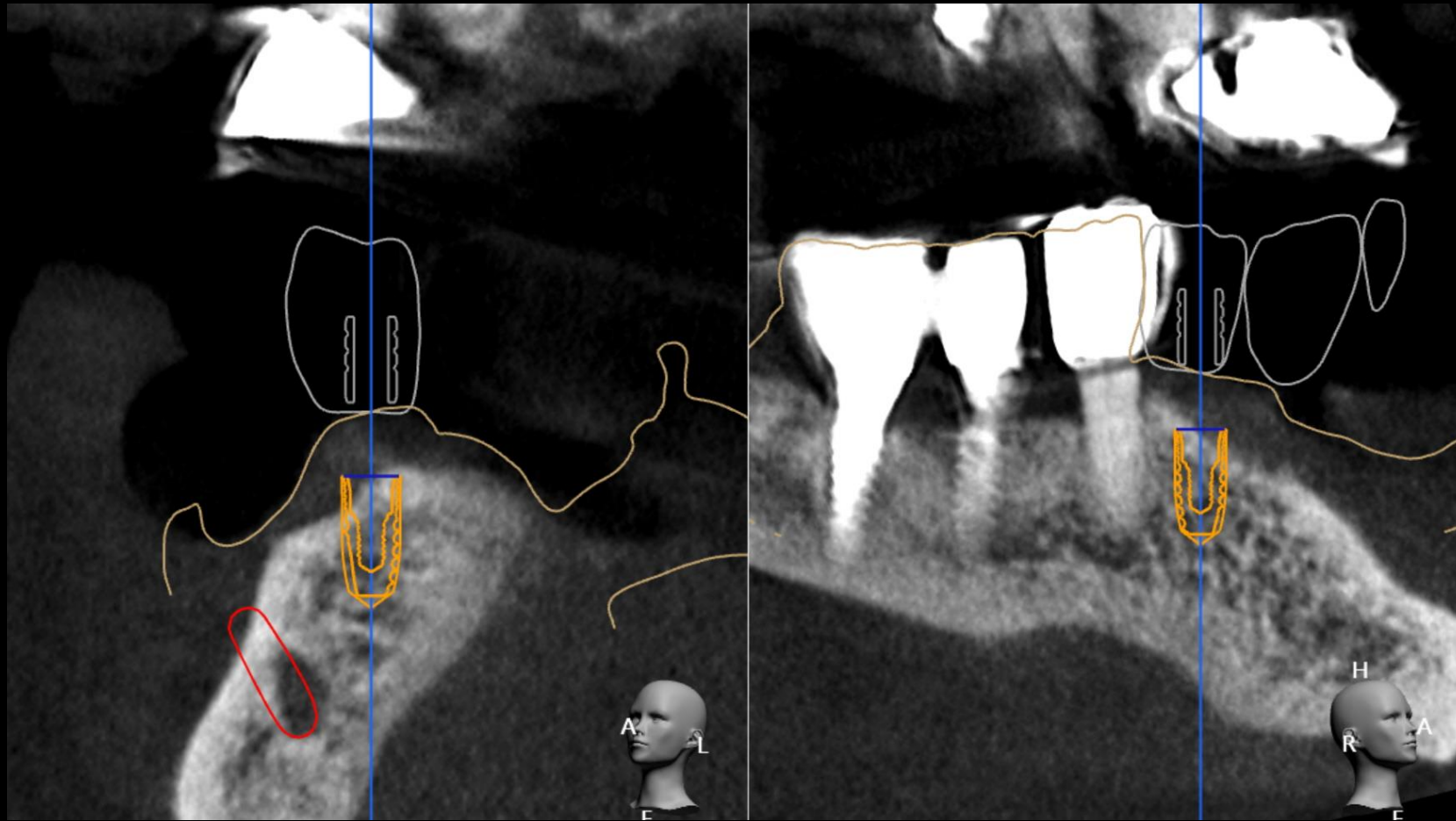


Implant Planning



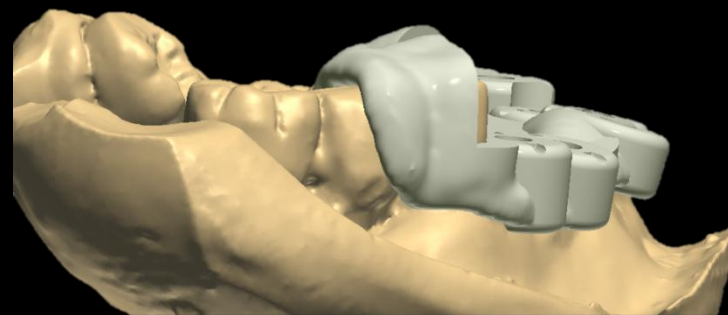

#34 (4009)



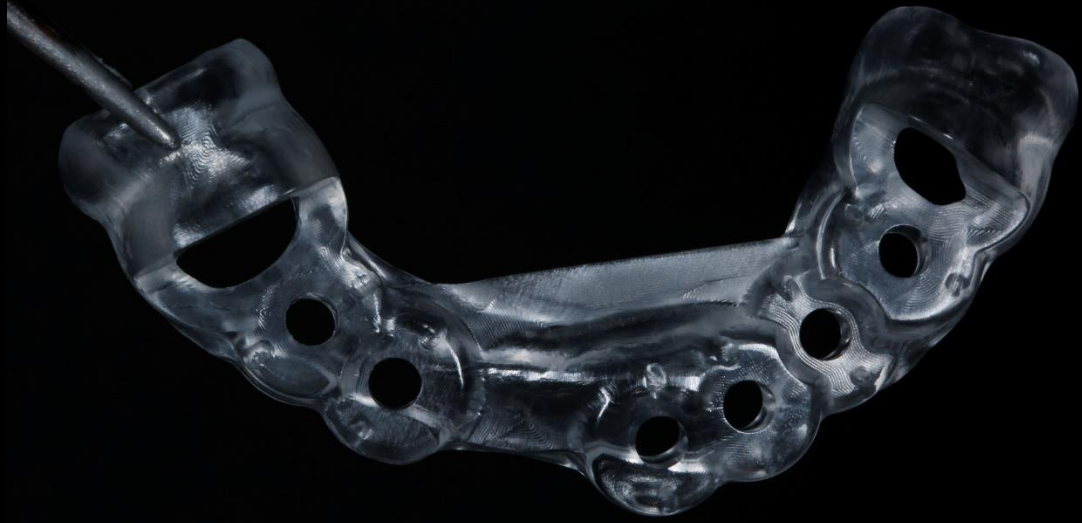



Stent Design (Digital Guide Simple Kit)



Milling Stent





[Case 2 Preview]

Overcoming Narrow ridge complication on Upper Posterior area

Patient Information

Age : 64

Sex : Female

Chief Complaint

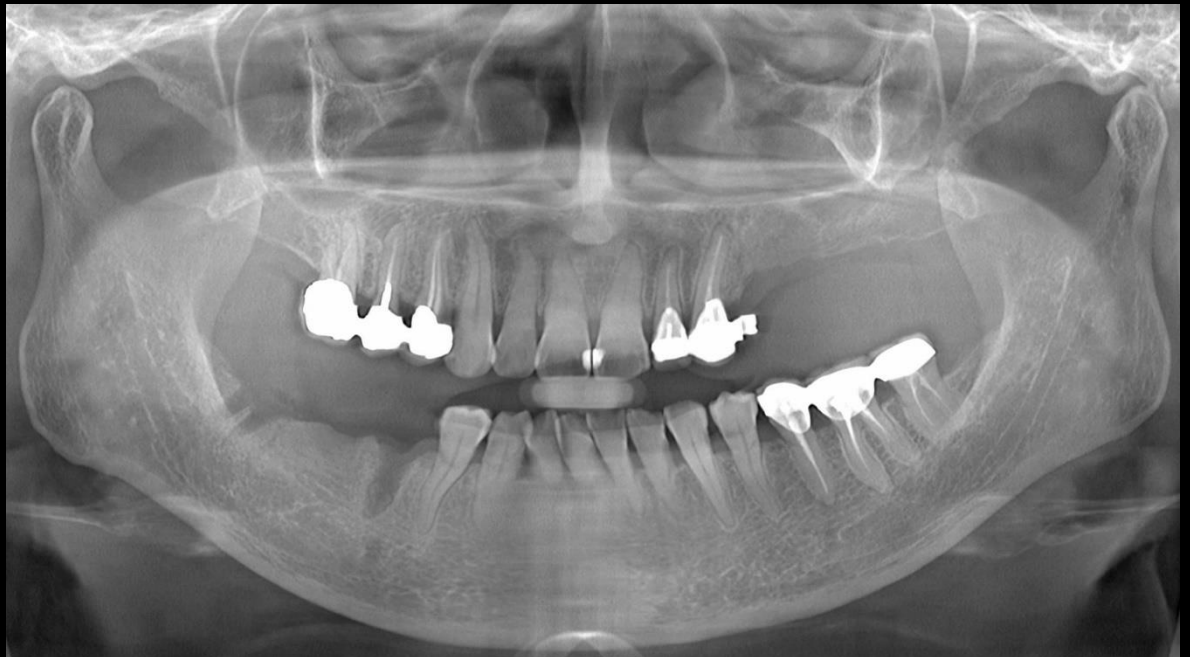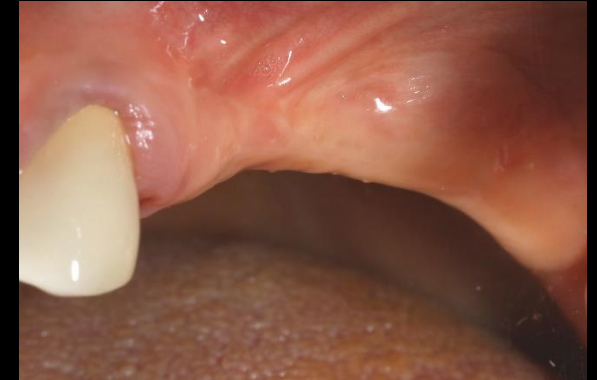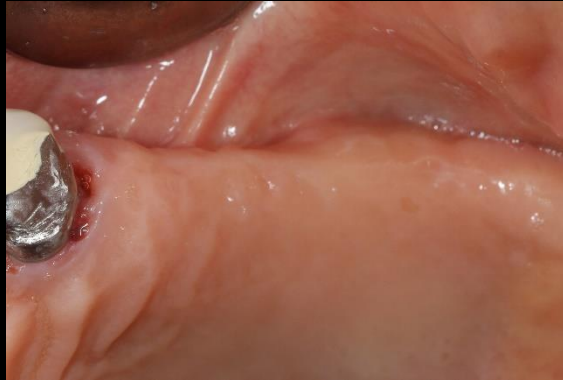
: I need to get dental implant treatment

Past Medical History

: N/S

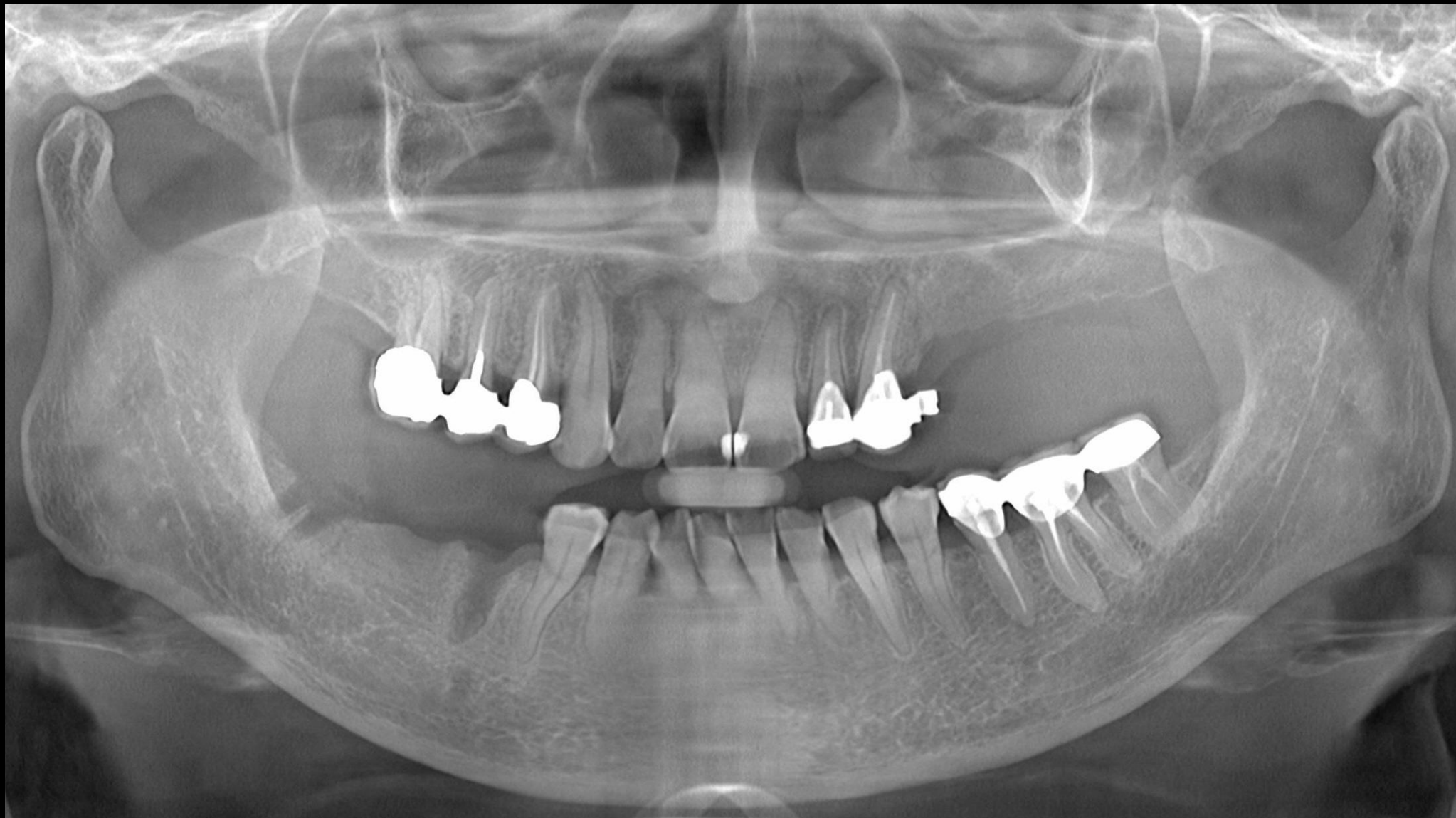
Past Dental History

: N/S



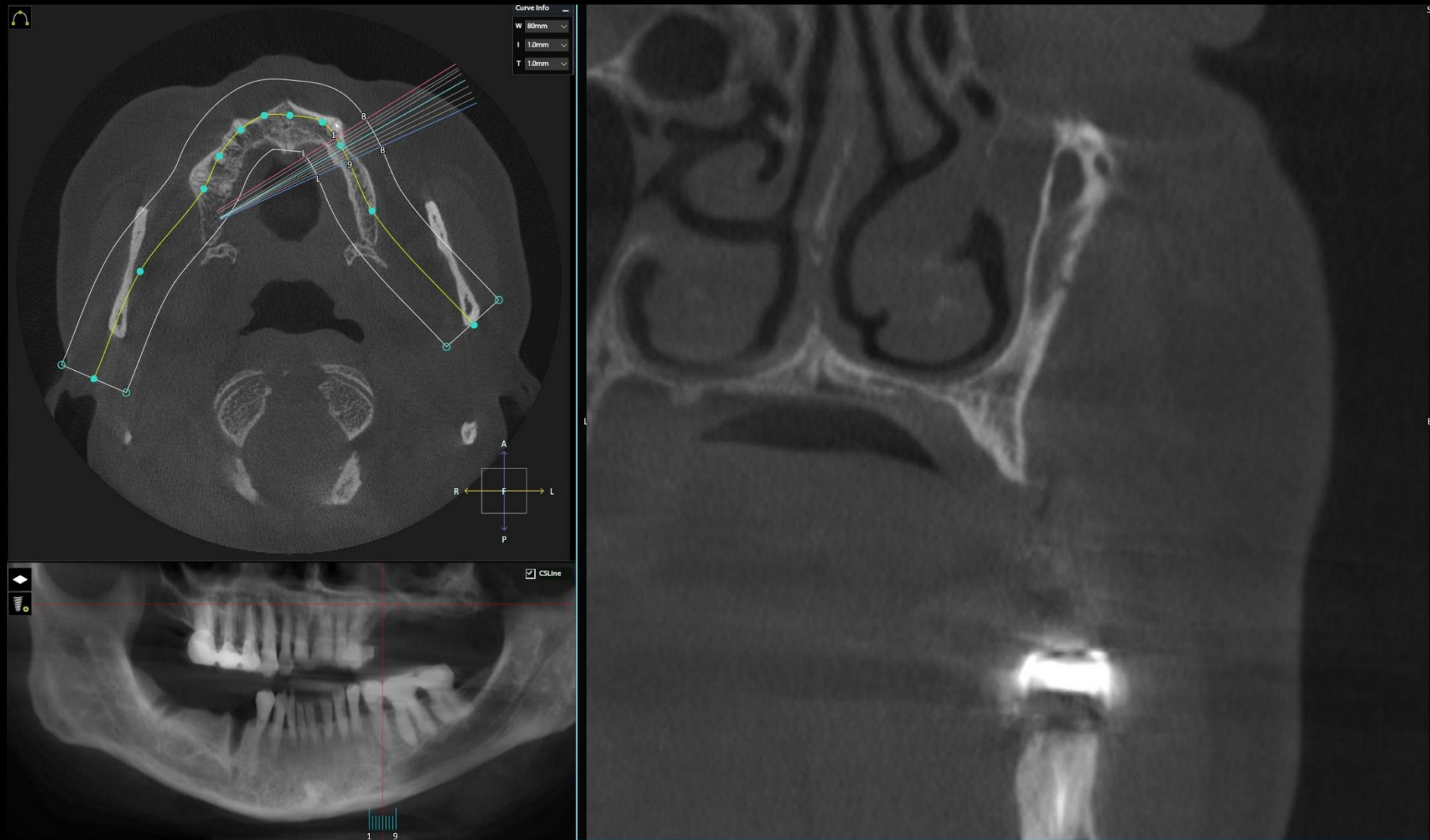
Pt. PMS (64/Female)

Pre-op (2020-08-27)



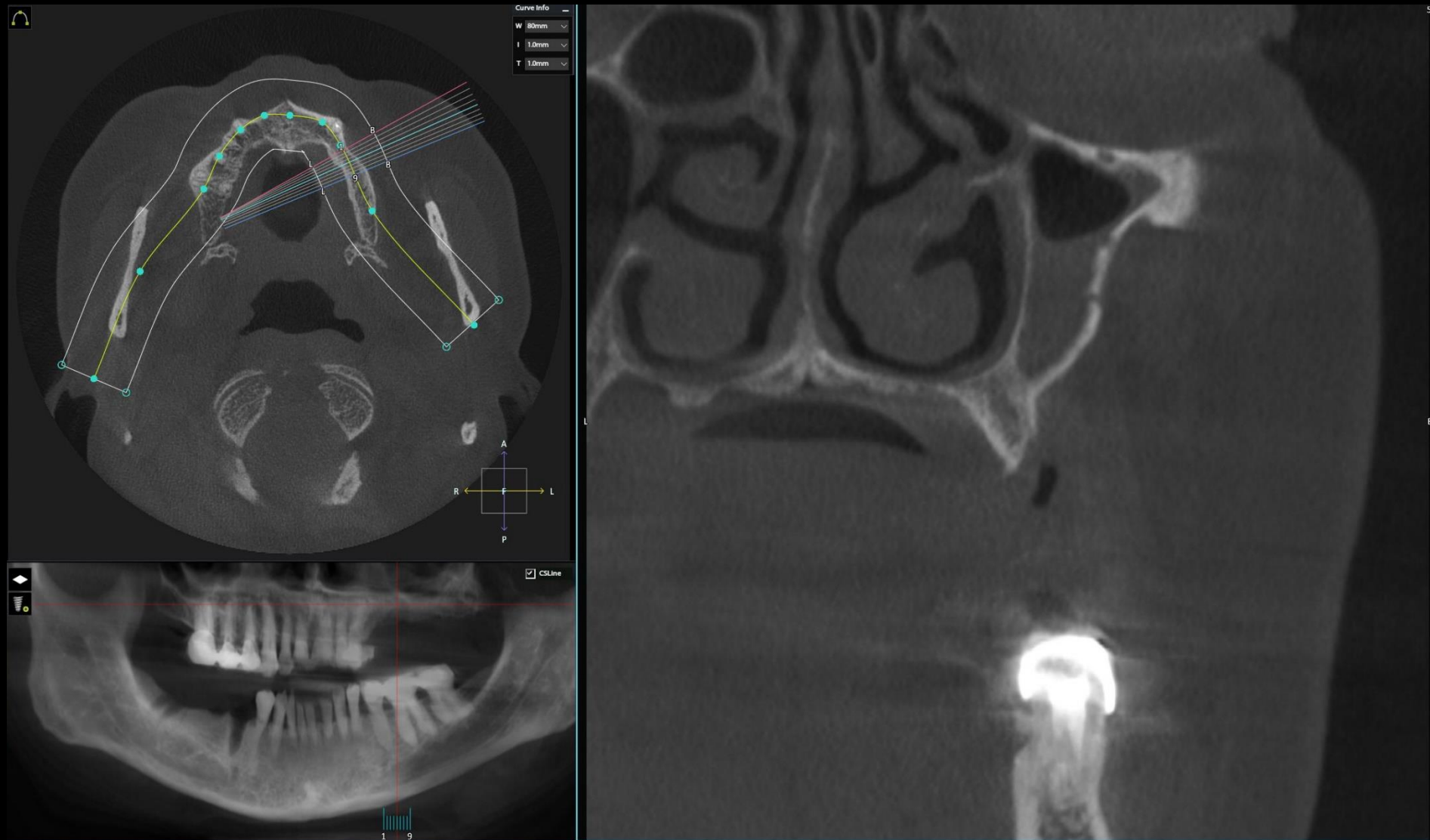
Pt. PMS (64/Female)

#24 Pre-op (2020-08-27)



Pt. PMS (64/Female)

#25 Pre-op (2020-08-27)



Pt. PMS (64/Female)

#26 Pre-op (2020-08-27)

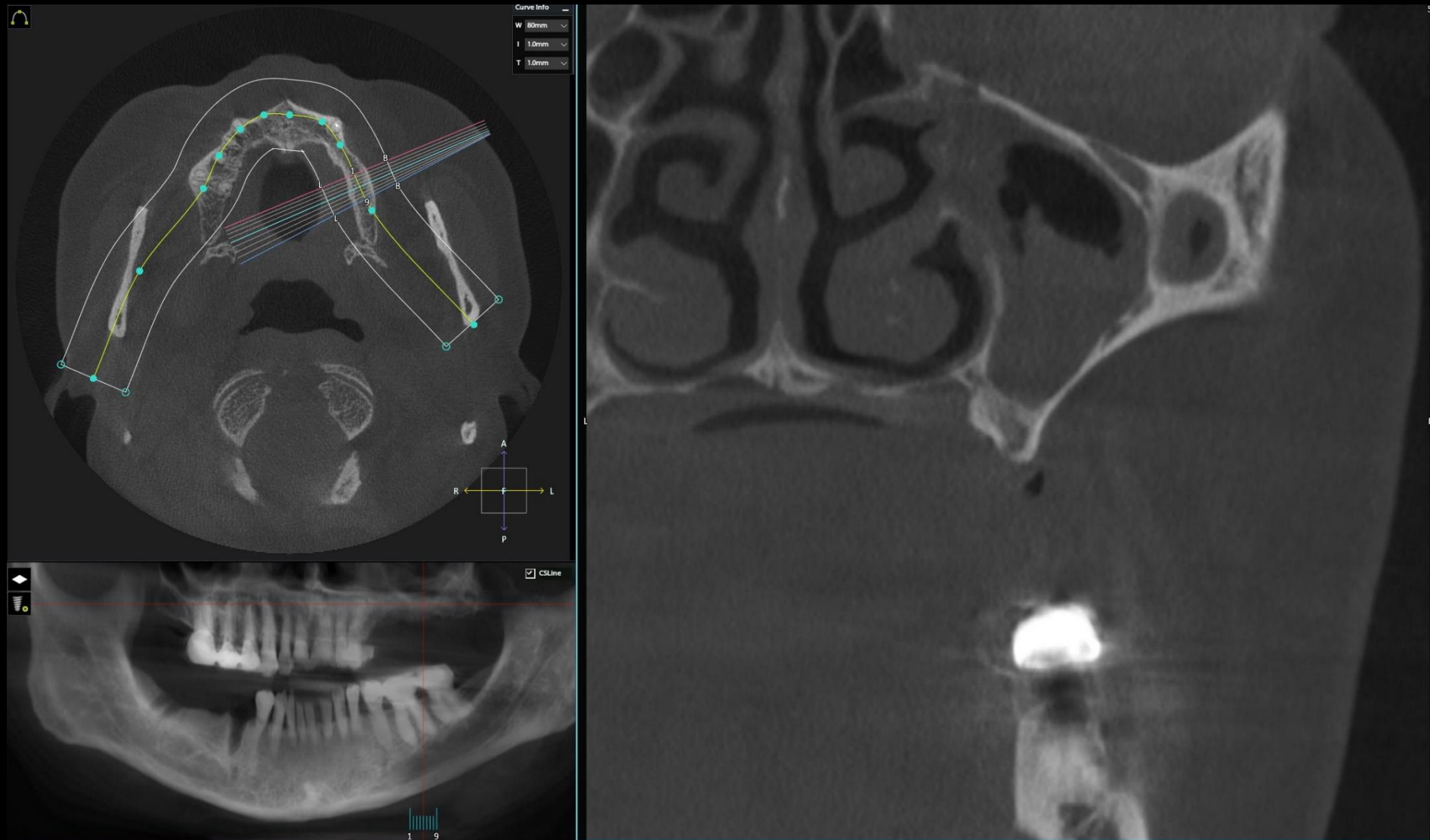
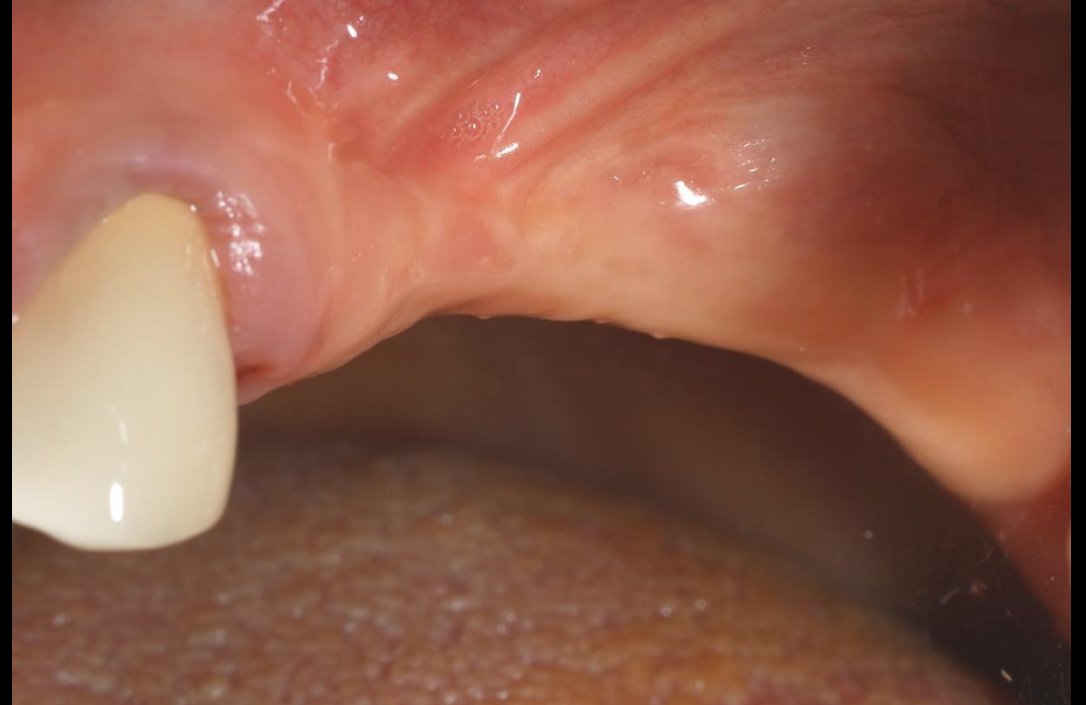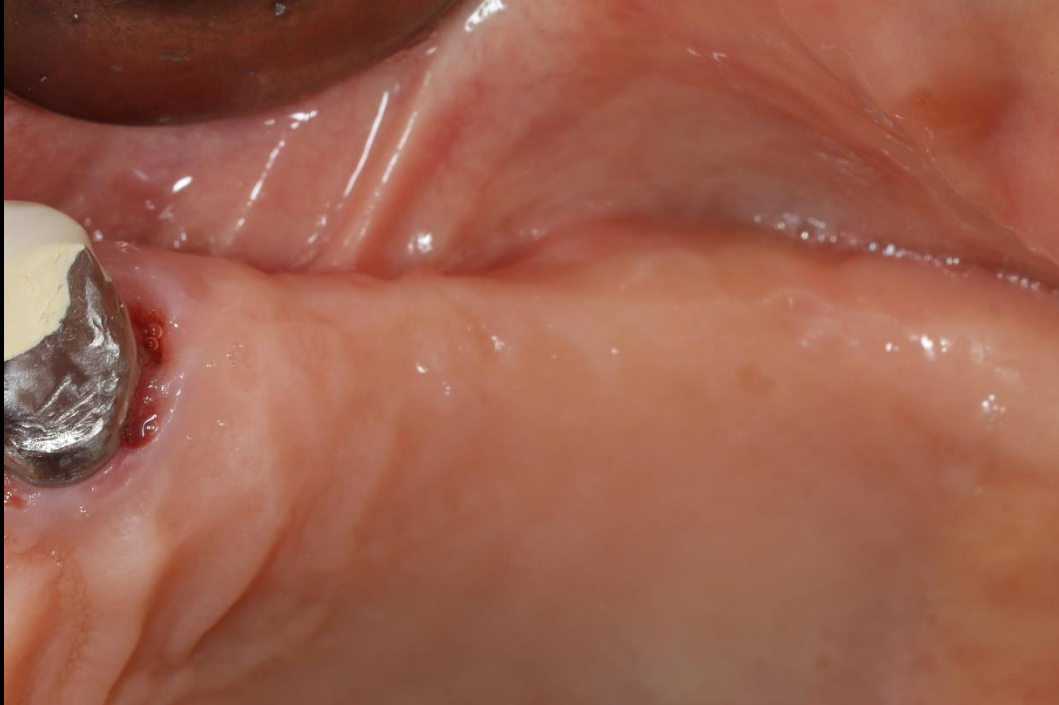


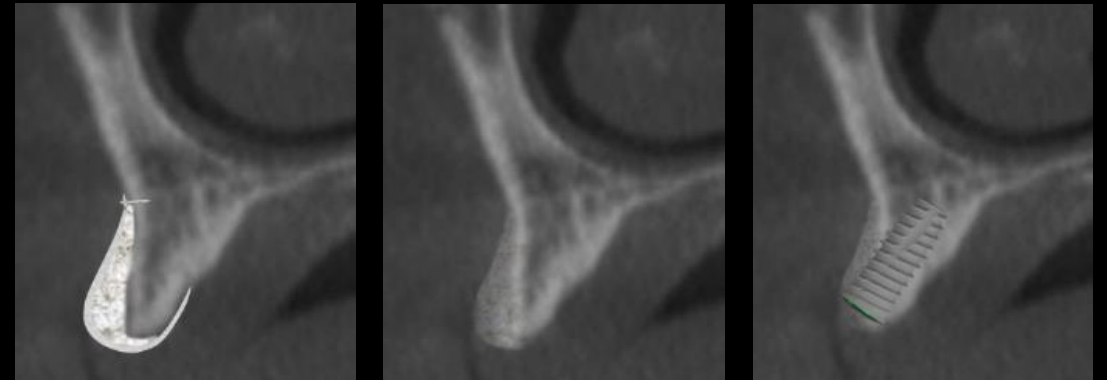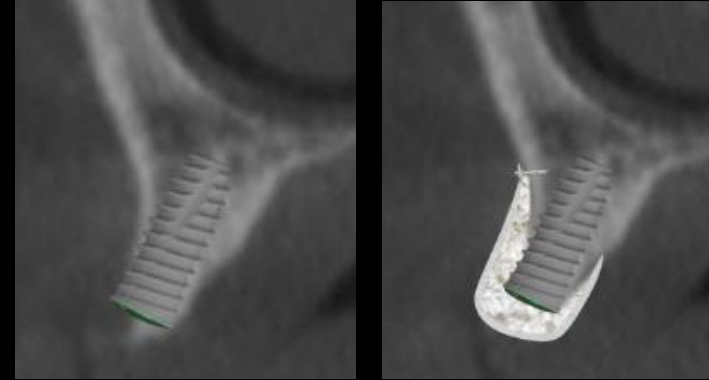
Photo (Pre-op)



Patient Information

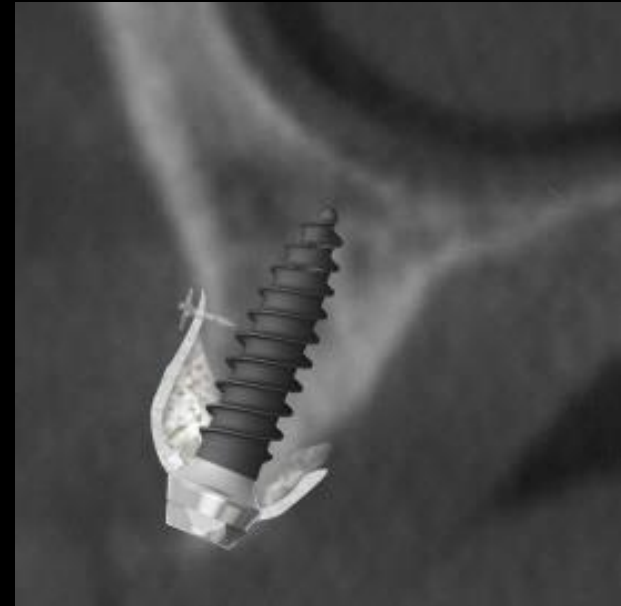
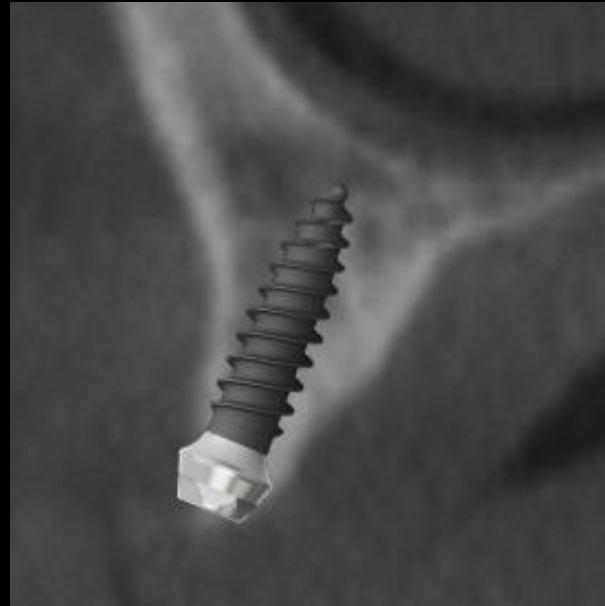
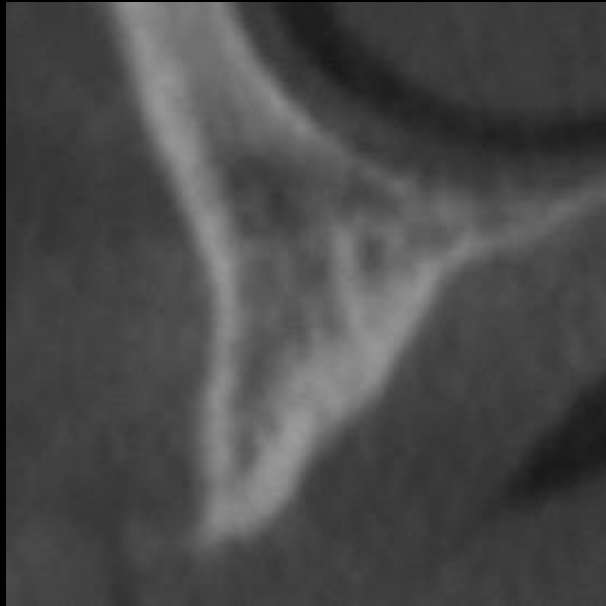
“ Treatment Plan? ”

- 1) Simultaneously approach**
Implant placement with extensive GBR
- 2) Staged surgery**
Onlay Bone graft → 6 months later
→ Implant placement
- 3) One stage surgery**
Narrow Implant placement With Contour augmentation



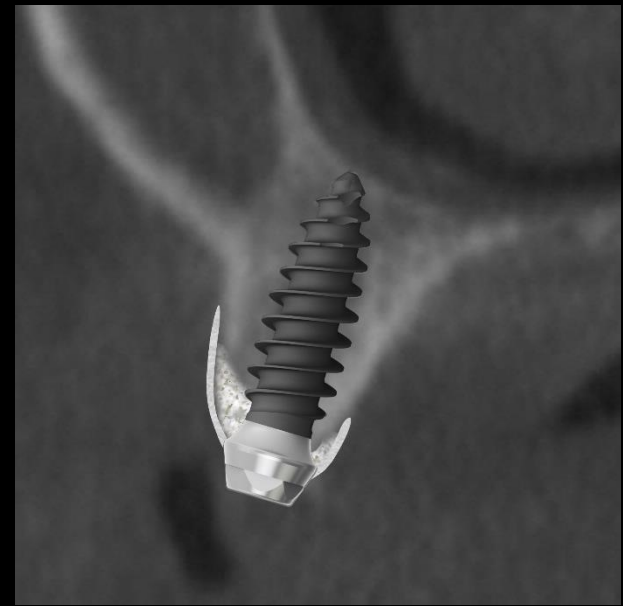
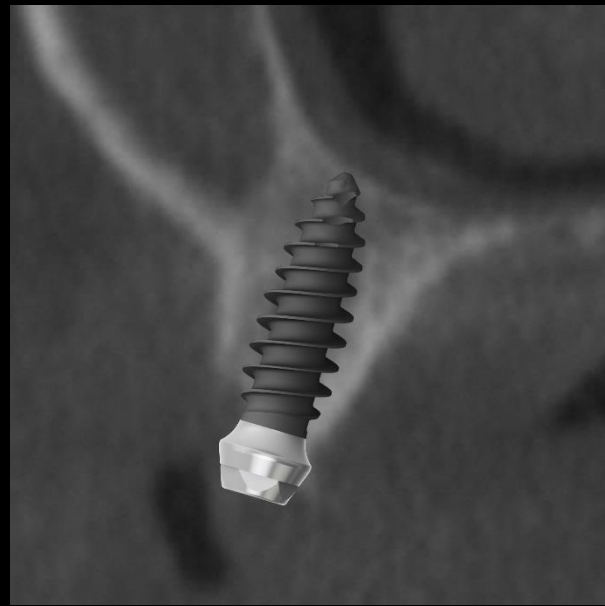
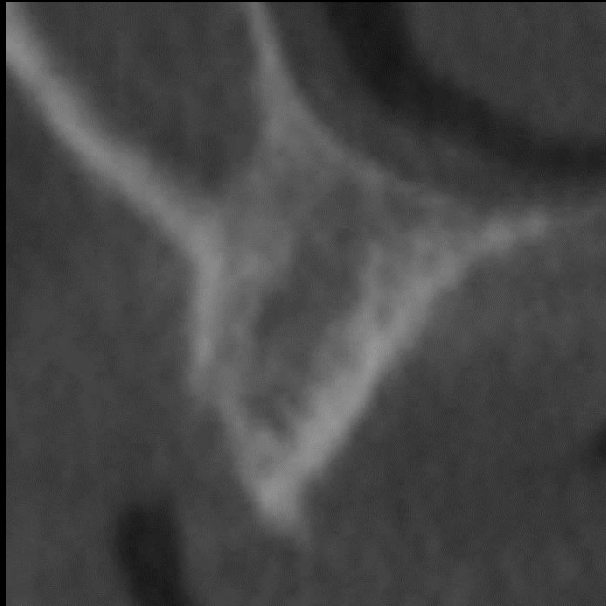
Treatment Plan (#24)

- Ø 2.5 Size fixture installation
- Contour augmentation & Collagen Membrane (Pin & Tugging)



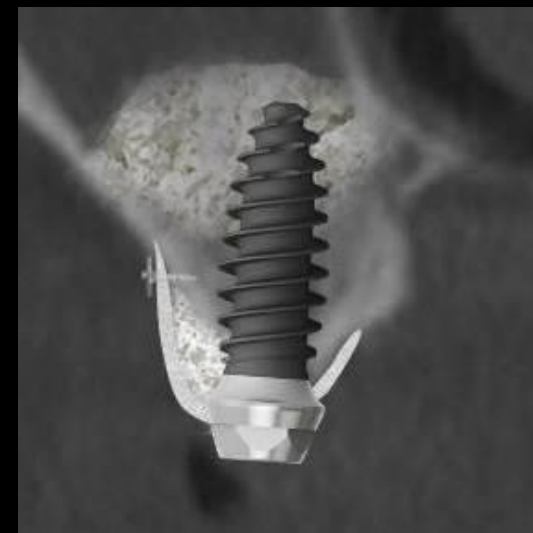
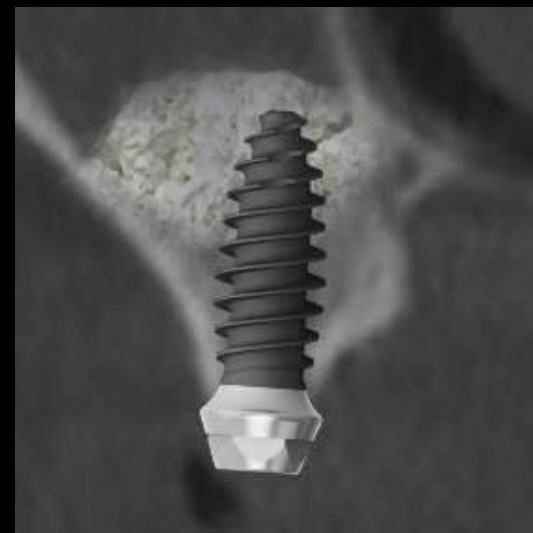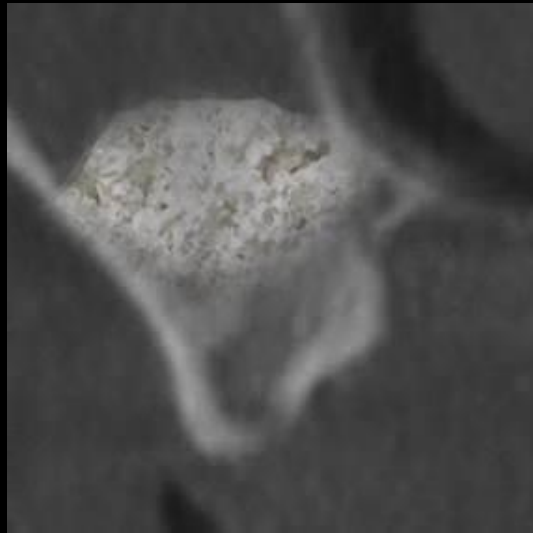
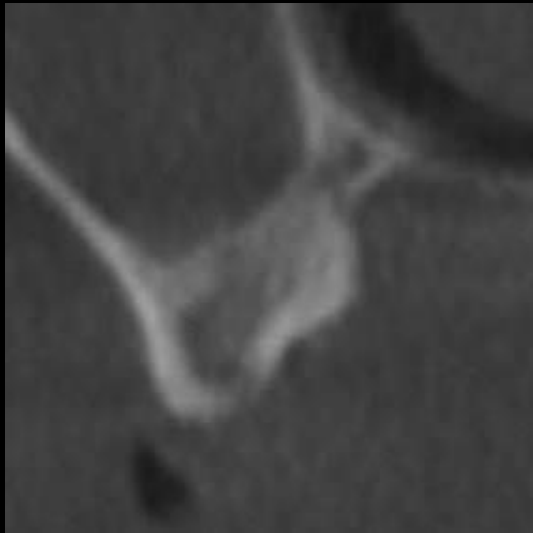
Treatment Plan (#25)

- Ø 3.0 Size fixture installation
- Contour augmentation & Collagen Membrane (Tugging)



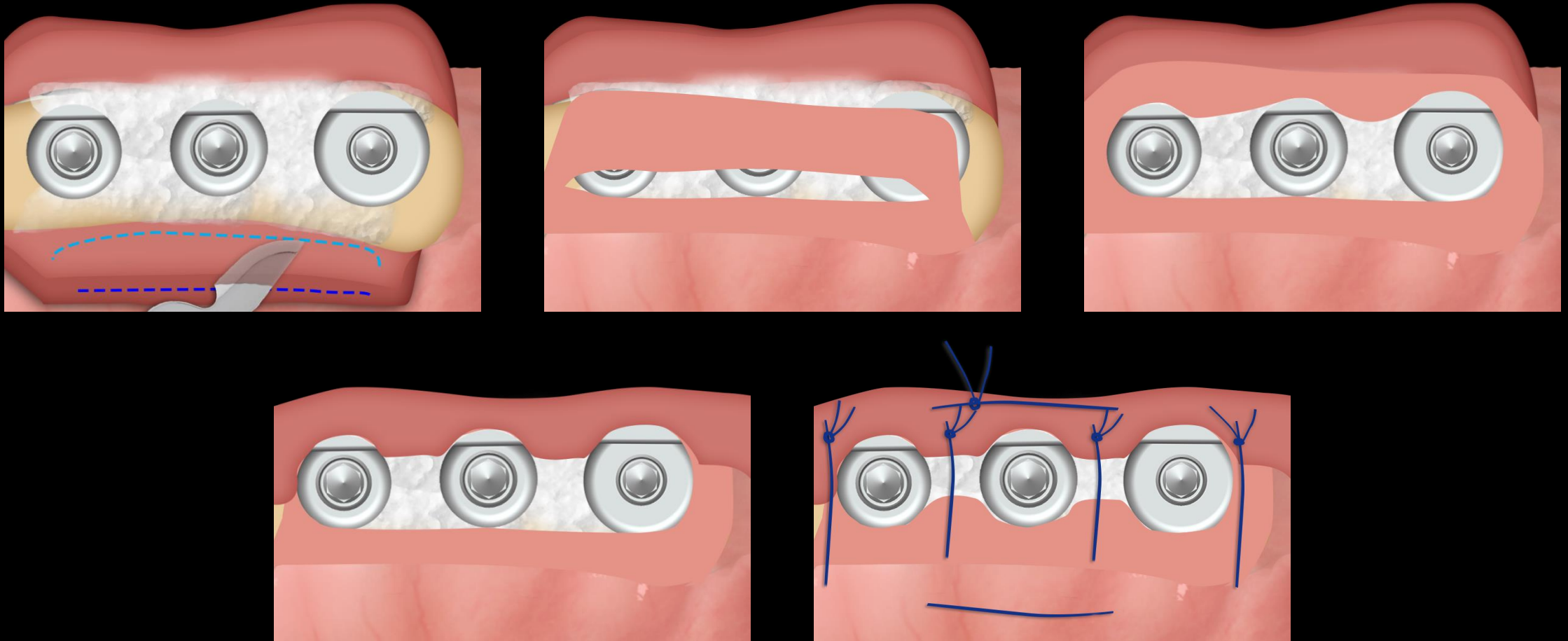
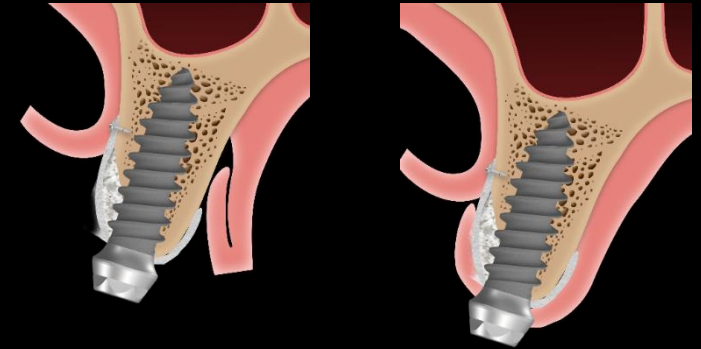
Treatment Plan (#26)

- Sinus elevation with Lateral approach
- **Ø 3.5** Size fixture installation
- Contour augmentation & Collagen Membrane (Pin & Tugging)

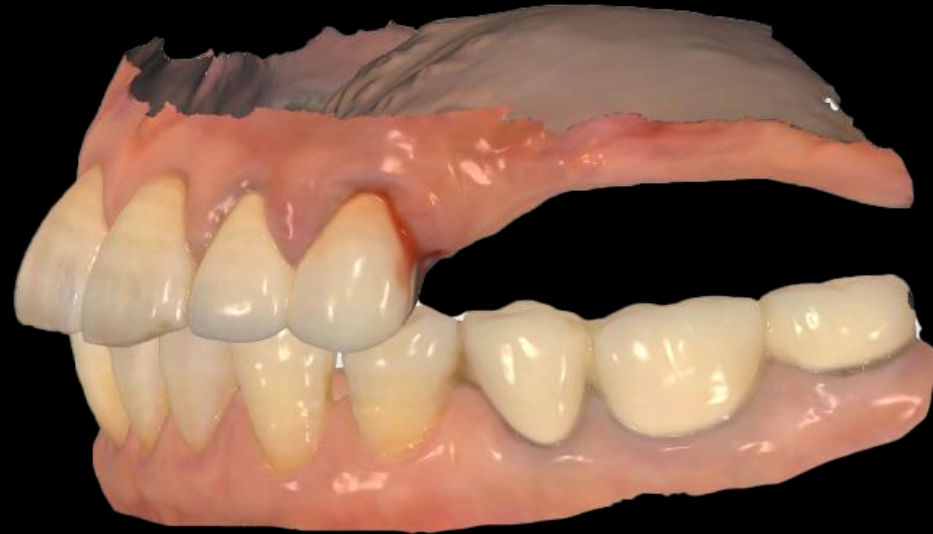
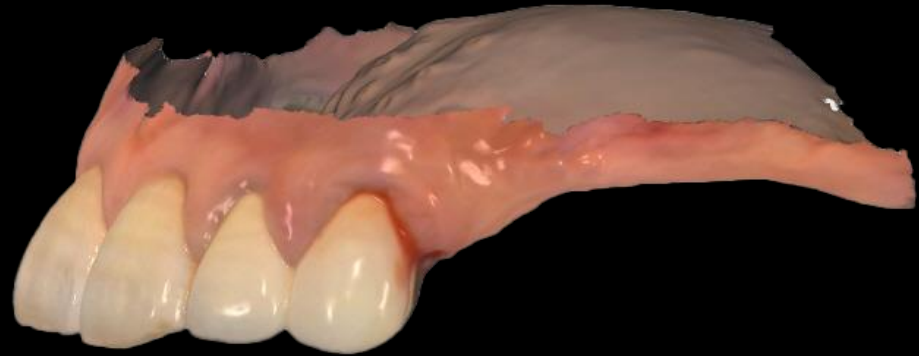
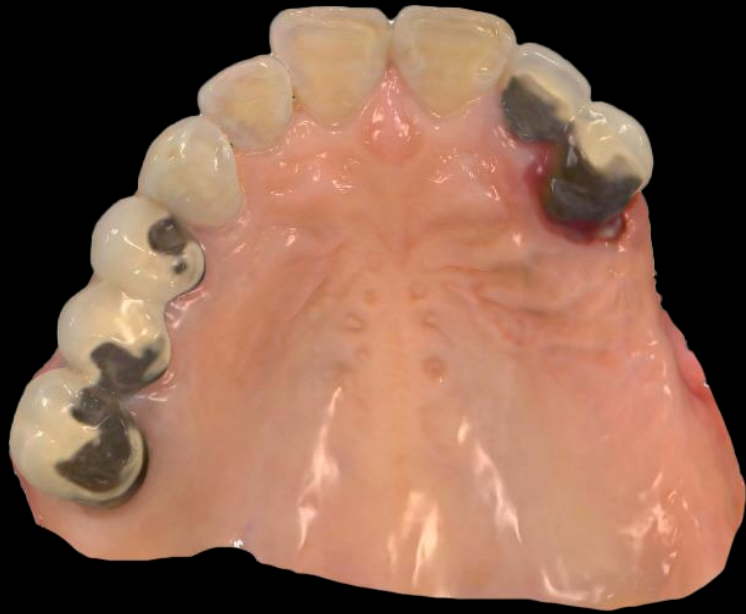Treatment Plan (Soft tissue management)

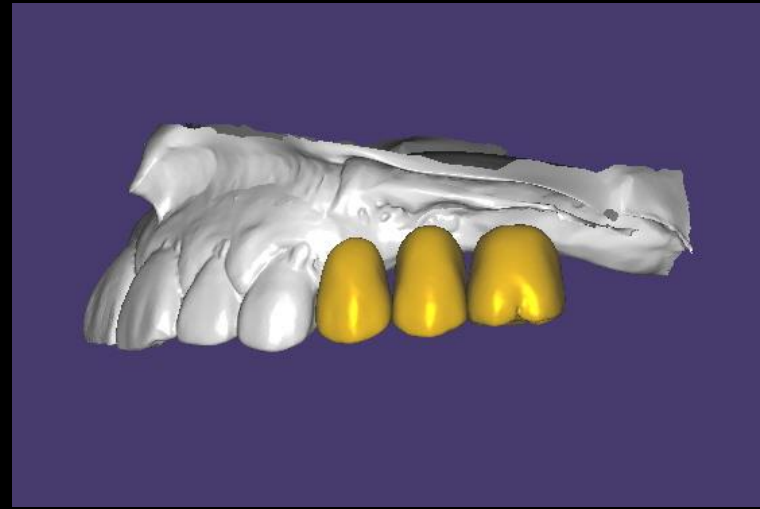
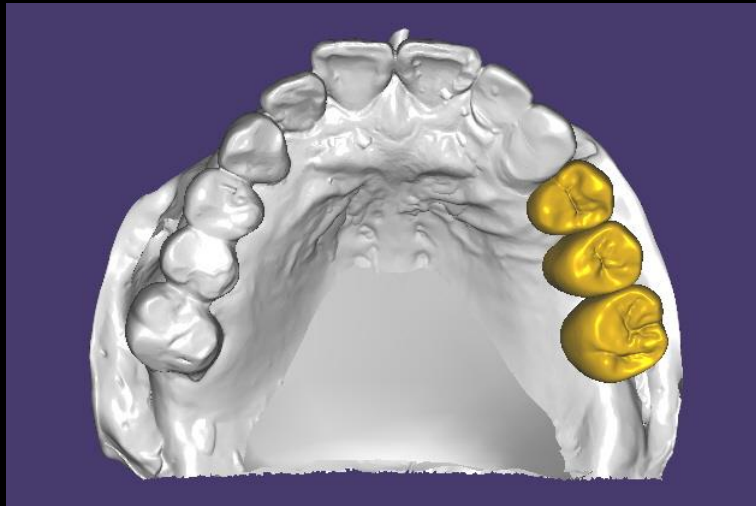
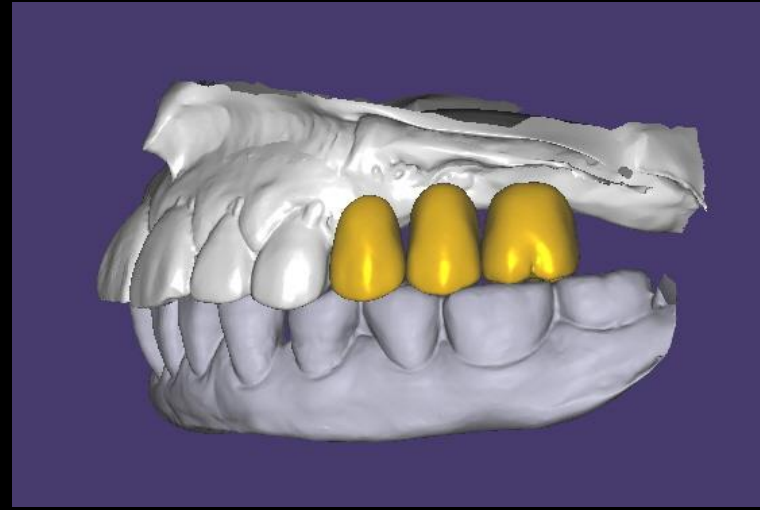
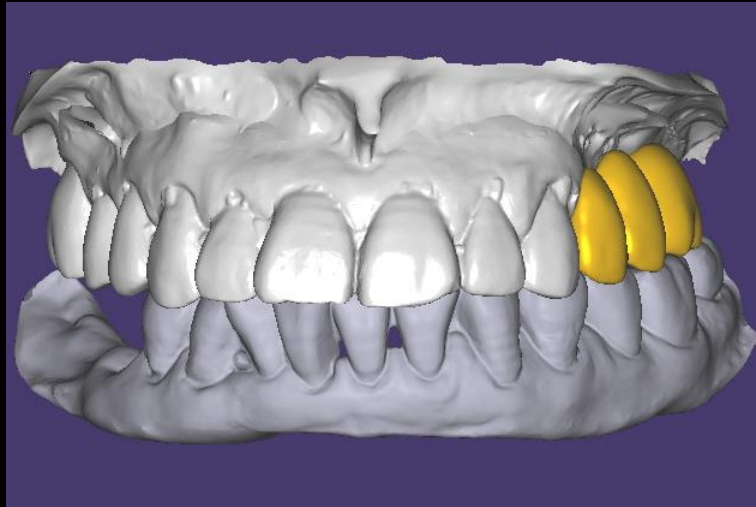
- Connective tissue graft (Palatal → Buccal)



Intra Oral Scanning

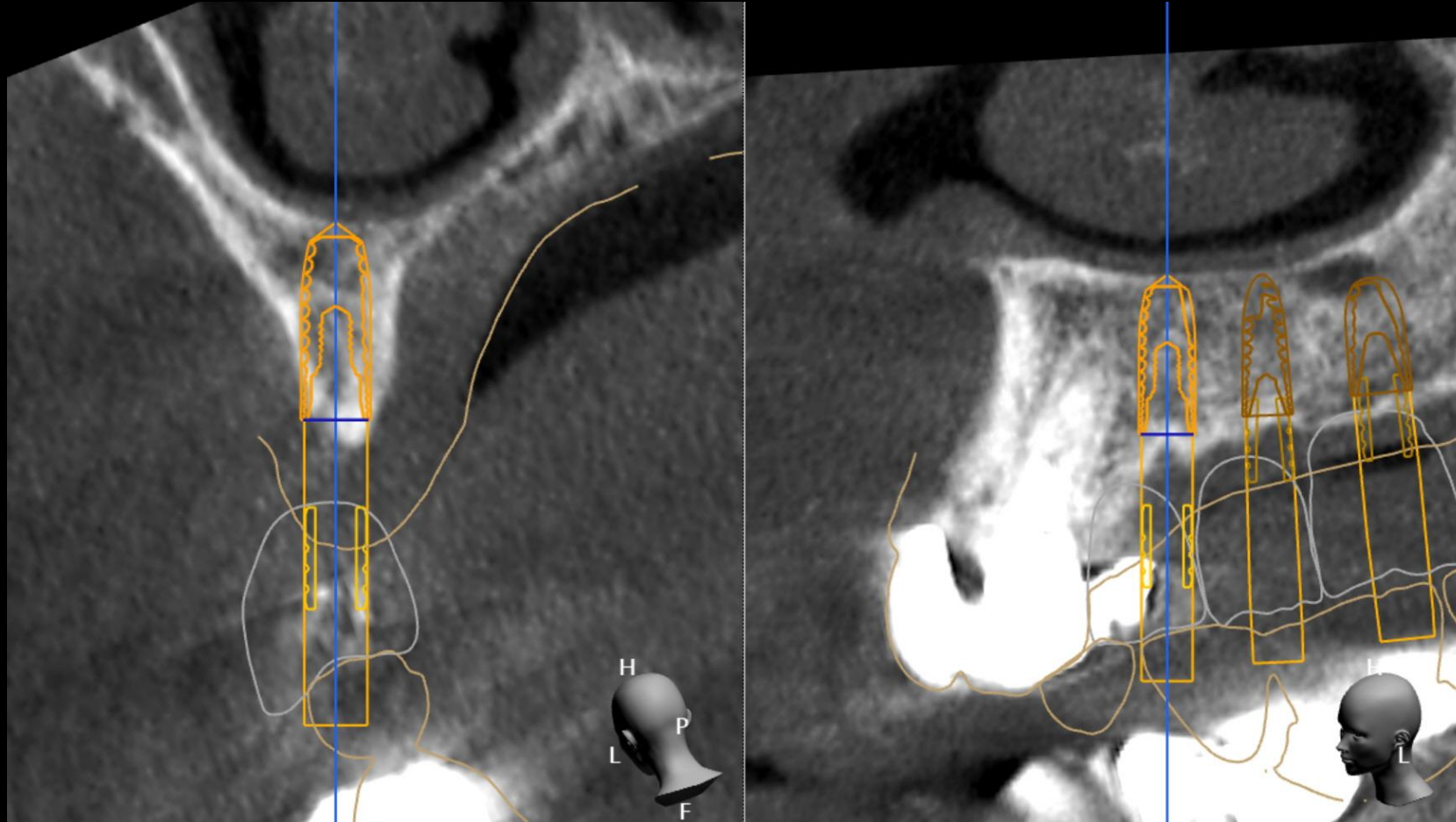


Virtual Set up



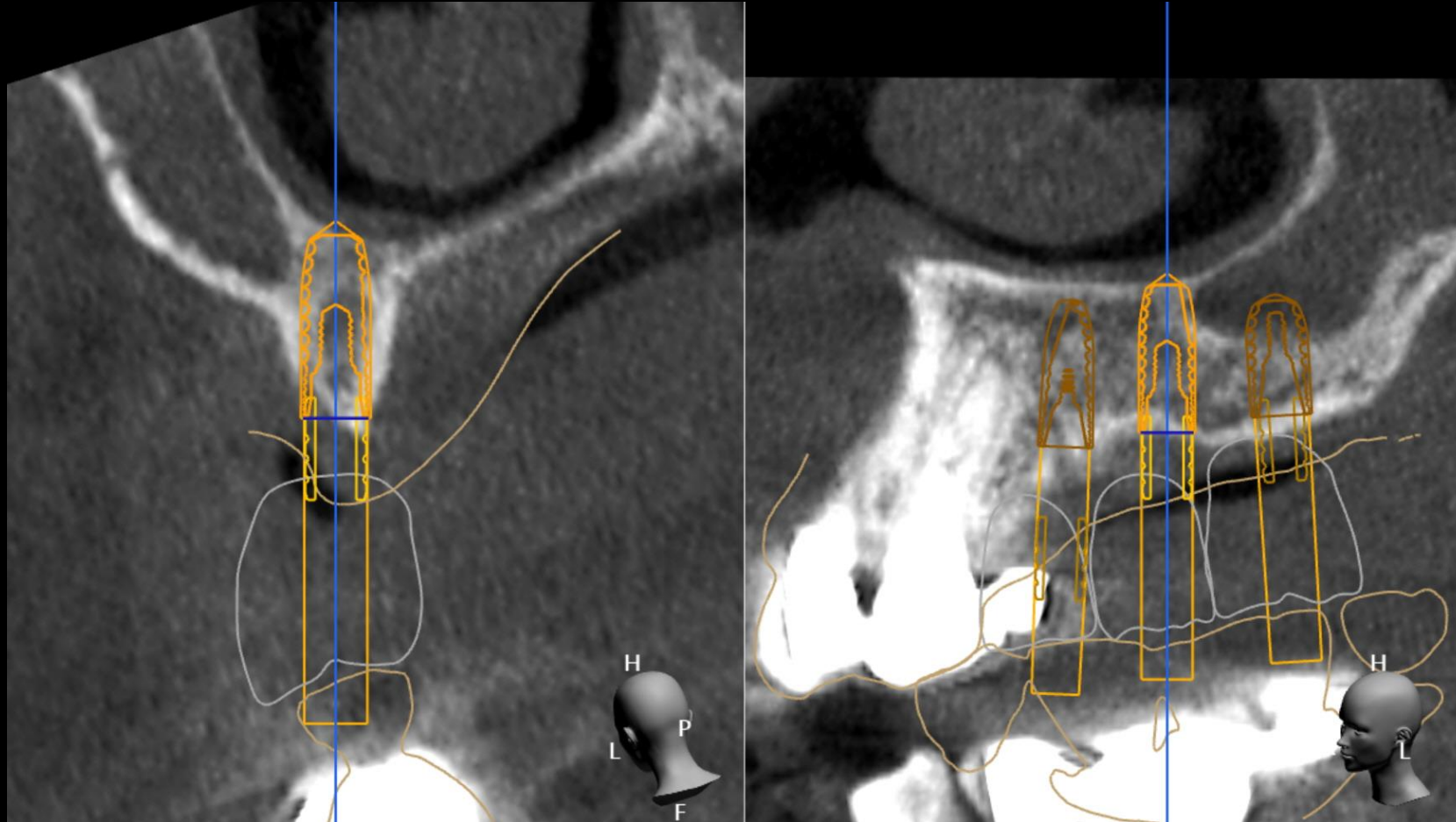
Implant Planning

#24 (2509)



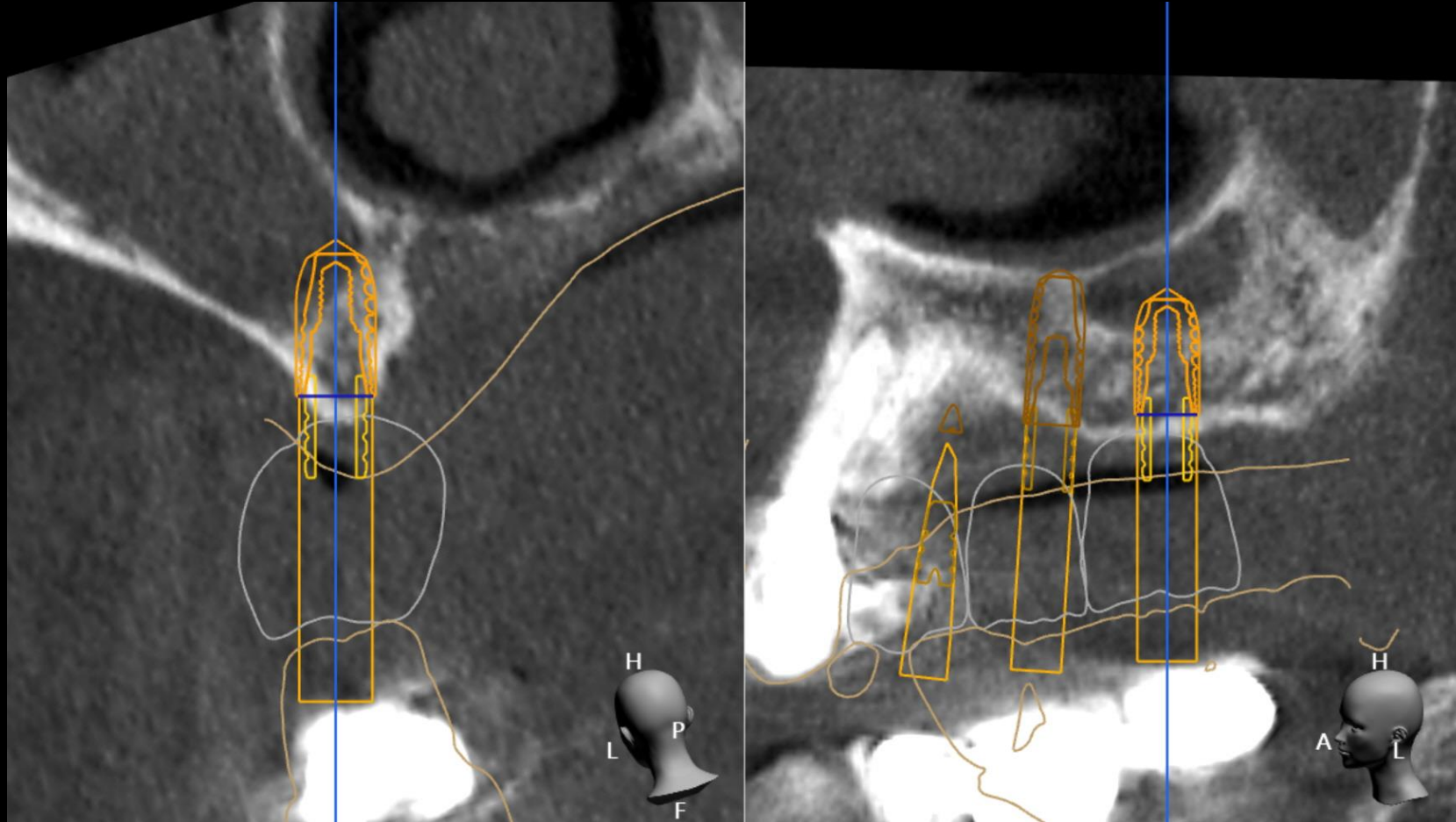
Implant Planning

#25 (3009)


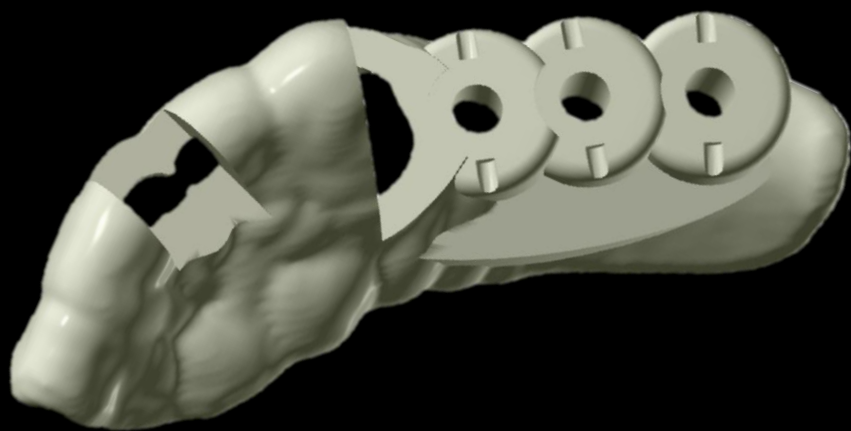

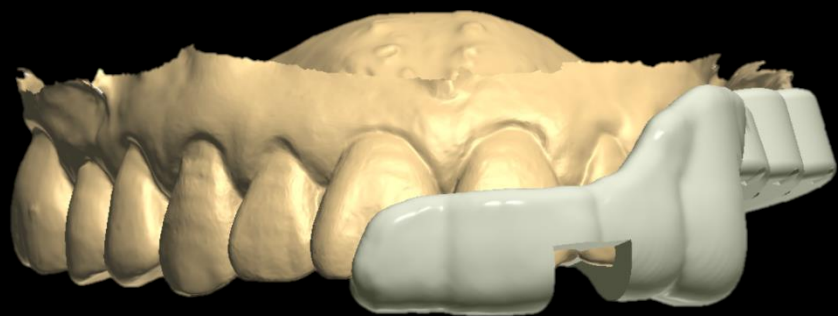


Implant Planning

#26 (3507)



Stent Design (Digital Guide Simple Kit)



Milling Stent

