



# Surgey

Dr. Jung-Hyun Park

2021.03.26 (FRI.)



# [Case Preview]

Digital Guide Implant placement with GBR

# Patient Information

**Age:** 58

**Sex:** Female

## **Chief Complaint**

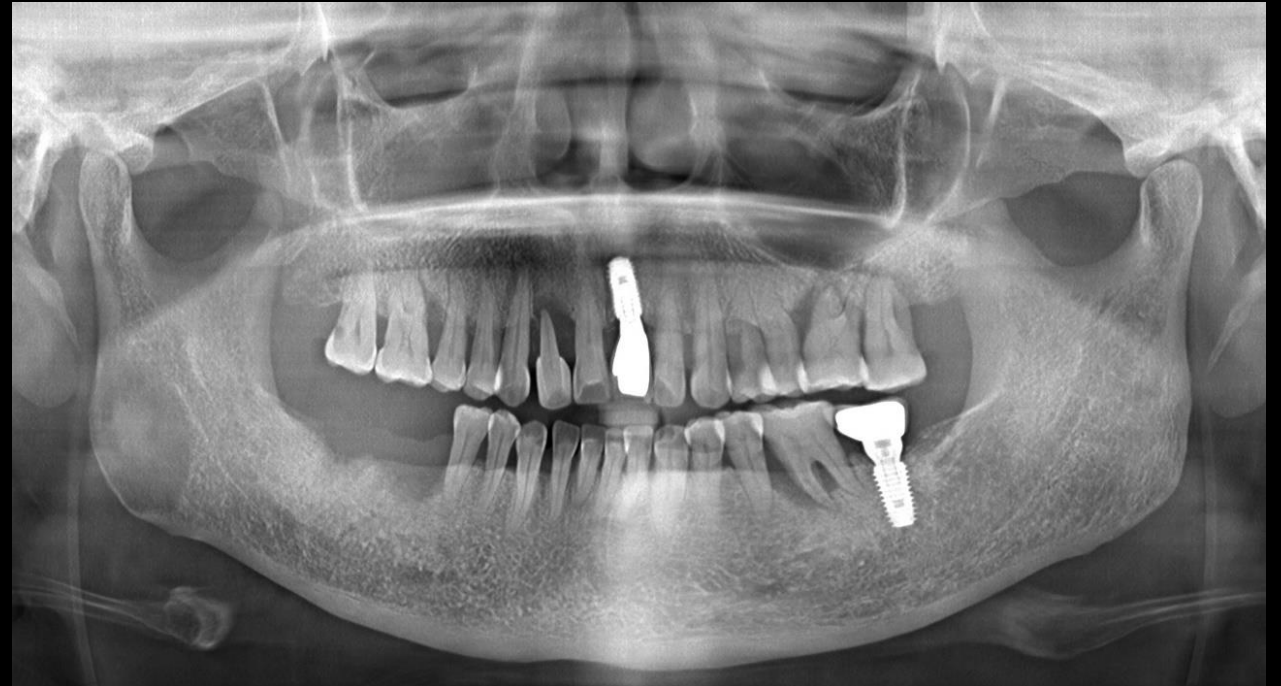
: I Can't eat anything due to loss of teeth

## **Past Dental History**

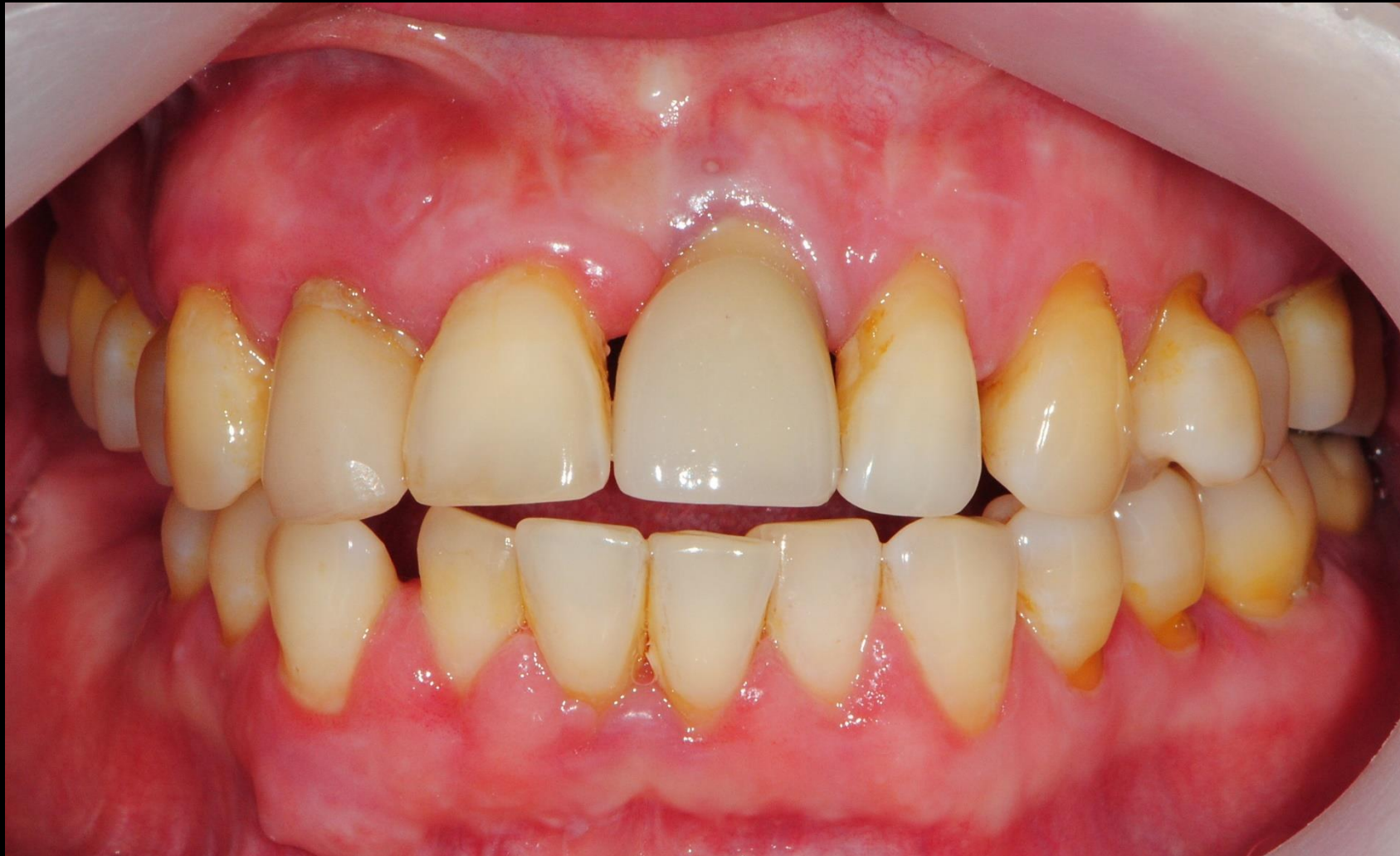: #21,37 implant placement

## **Past Medical History**

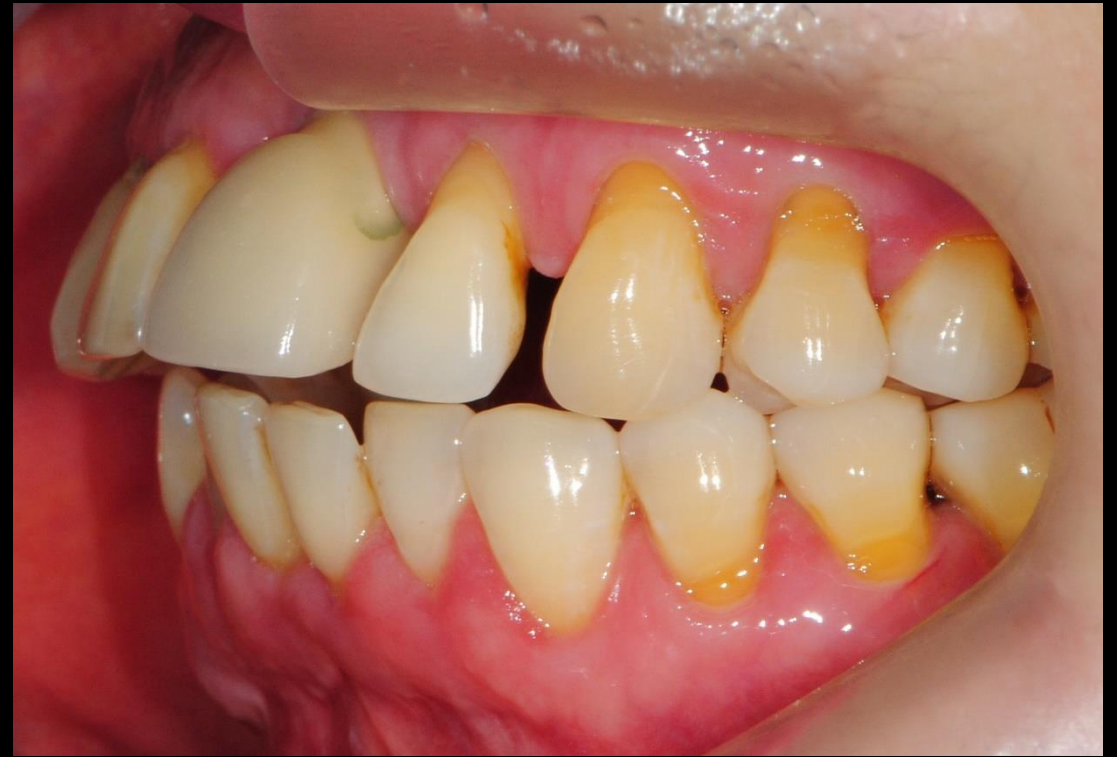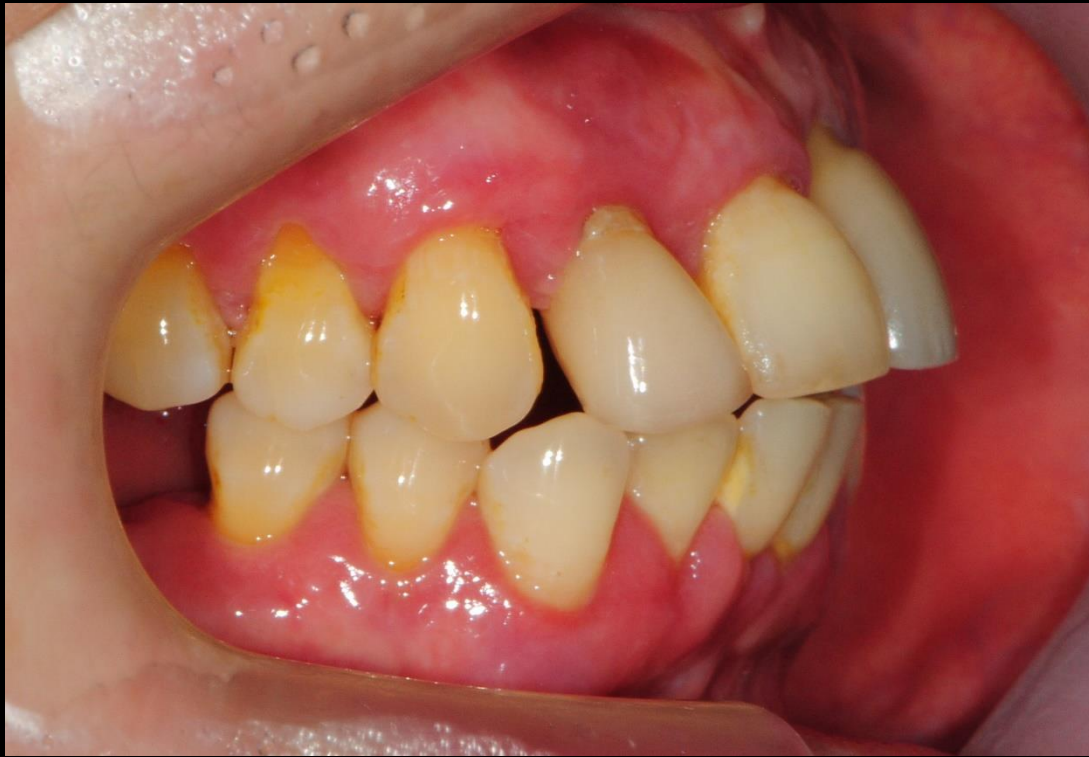: N/S



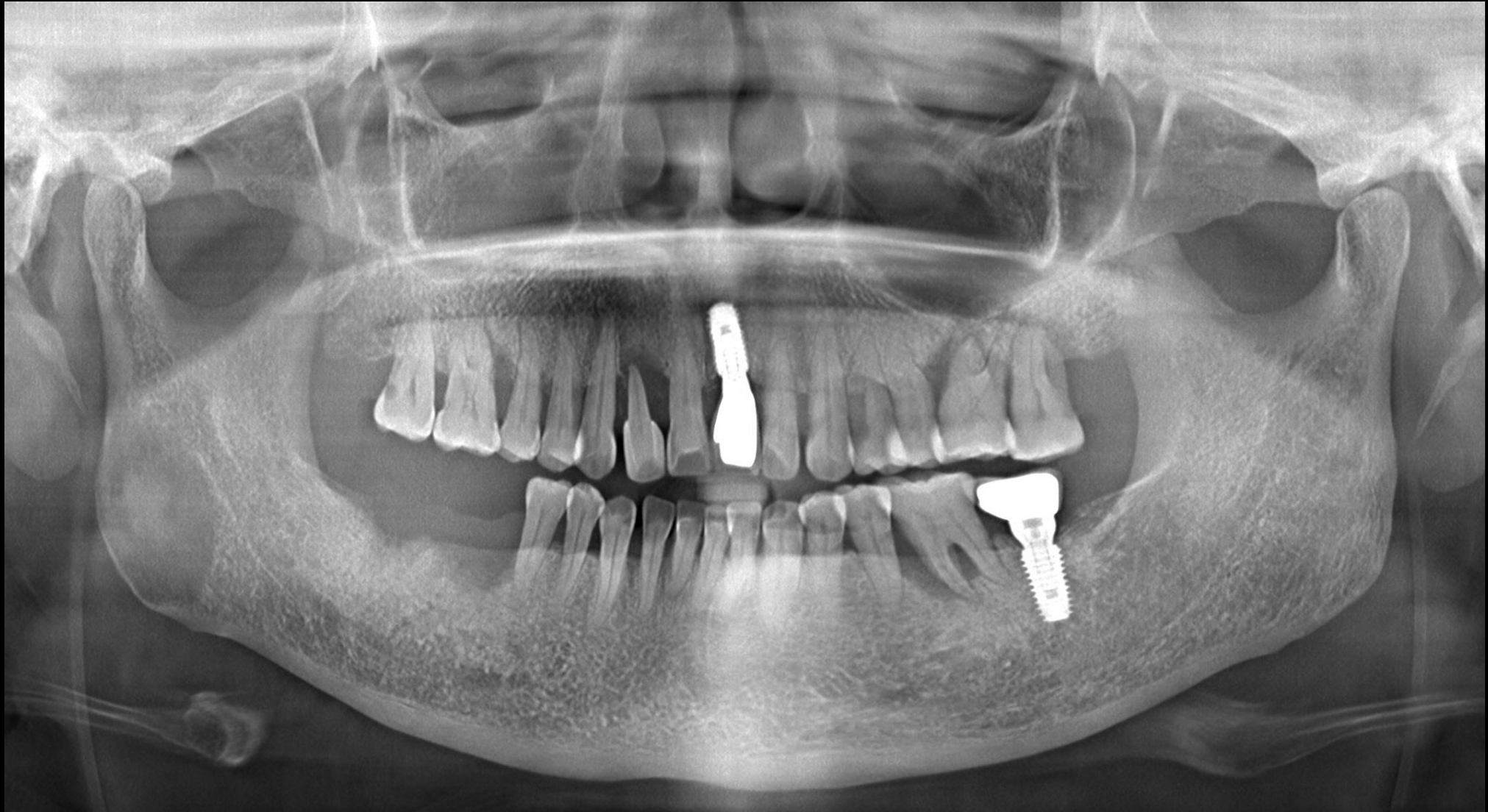
Oral exam (2021-03-10)

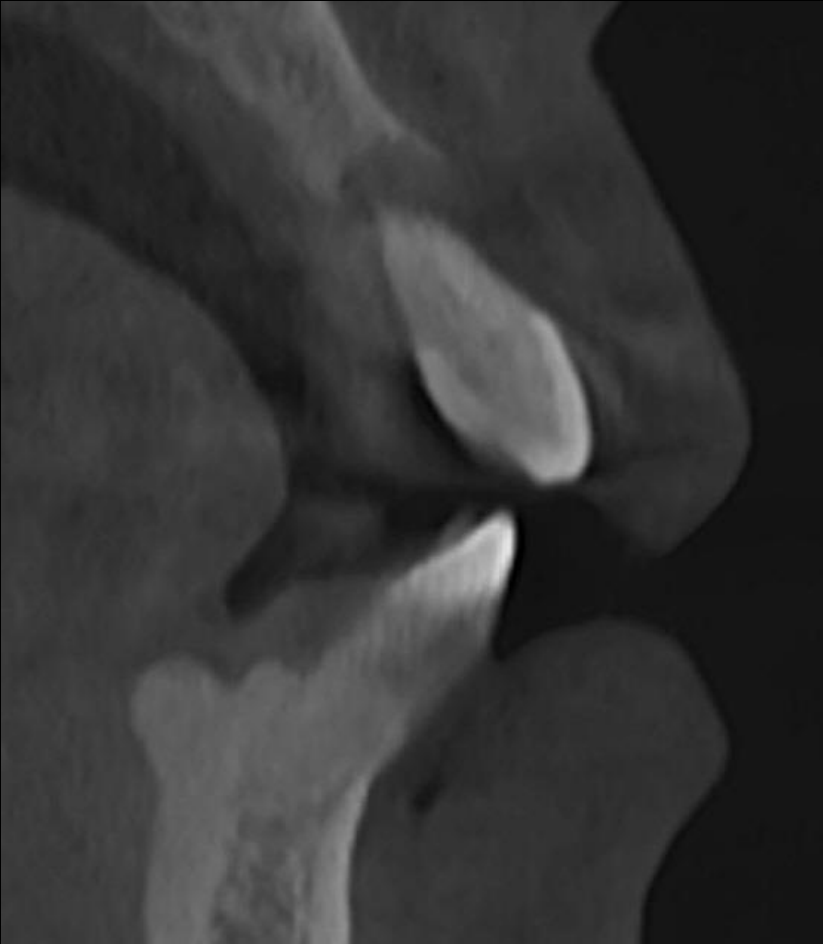
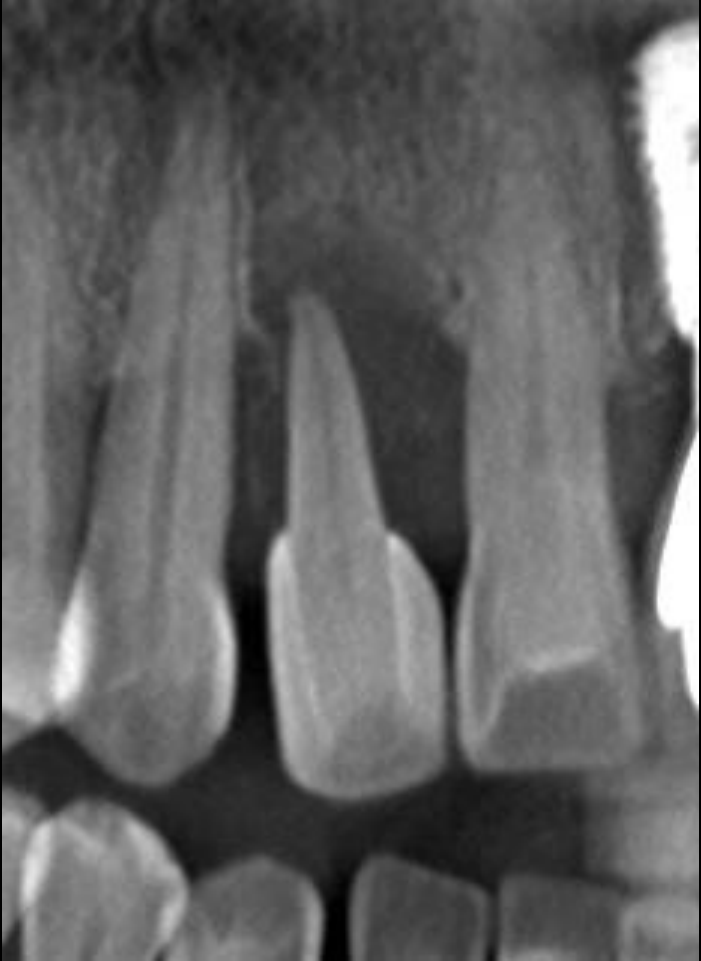

Oral exam (2021-03-10)

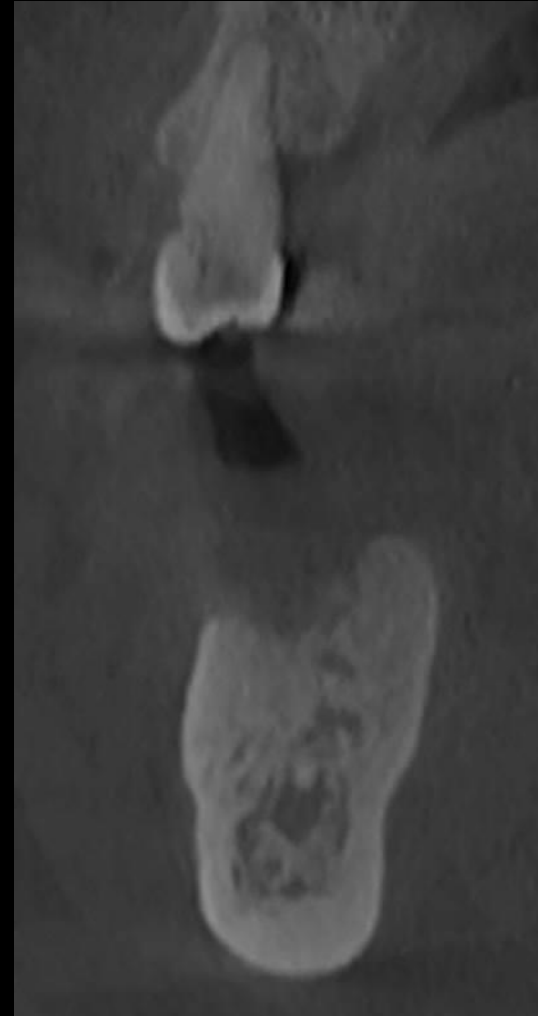
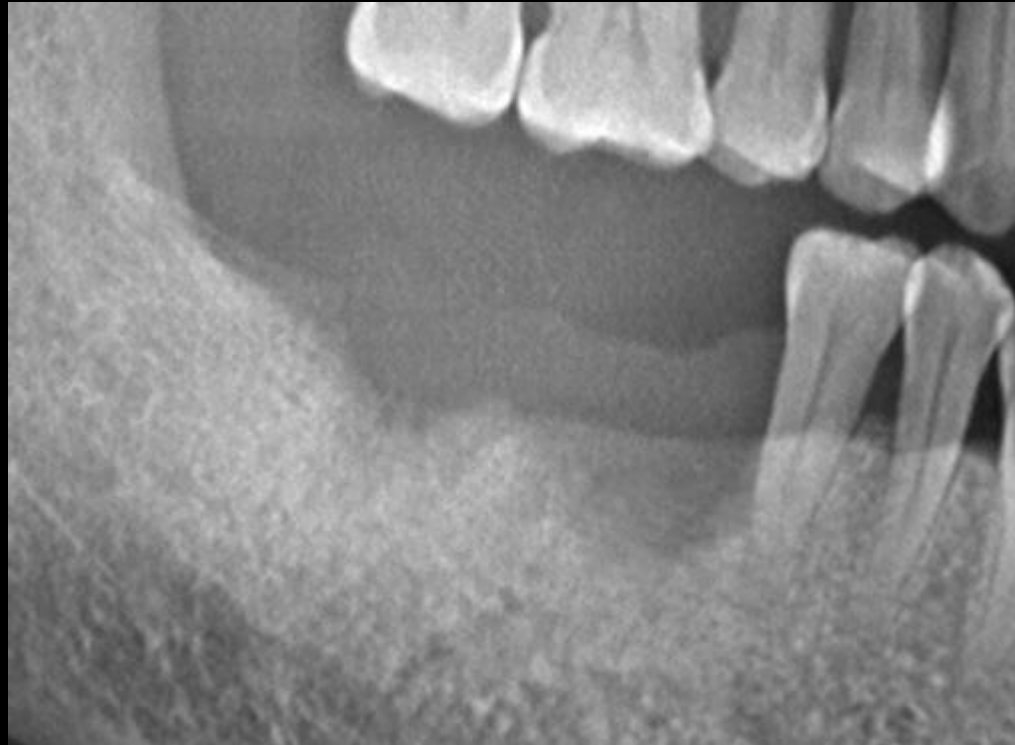
Oral exam (2021-03-10)

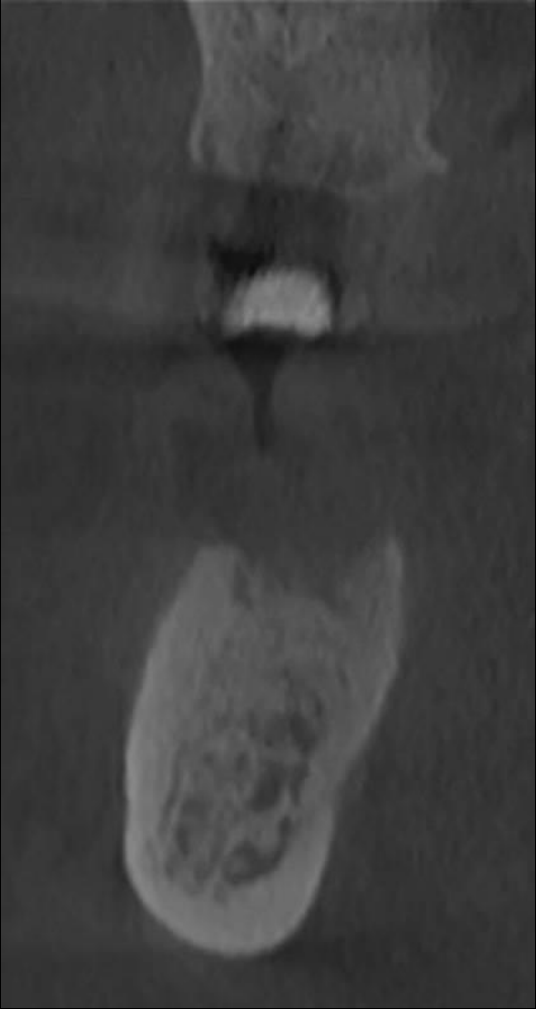
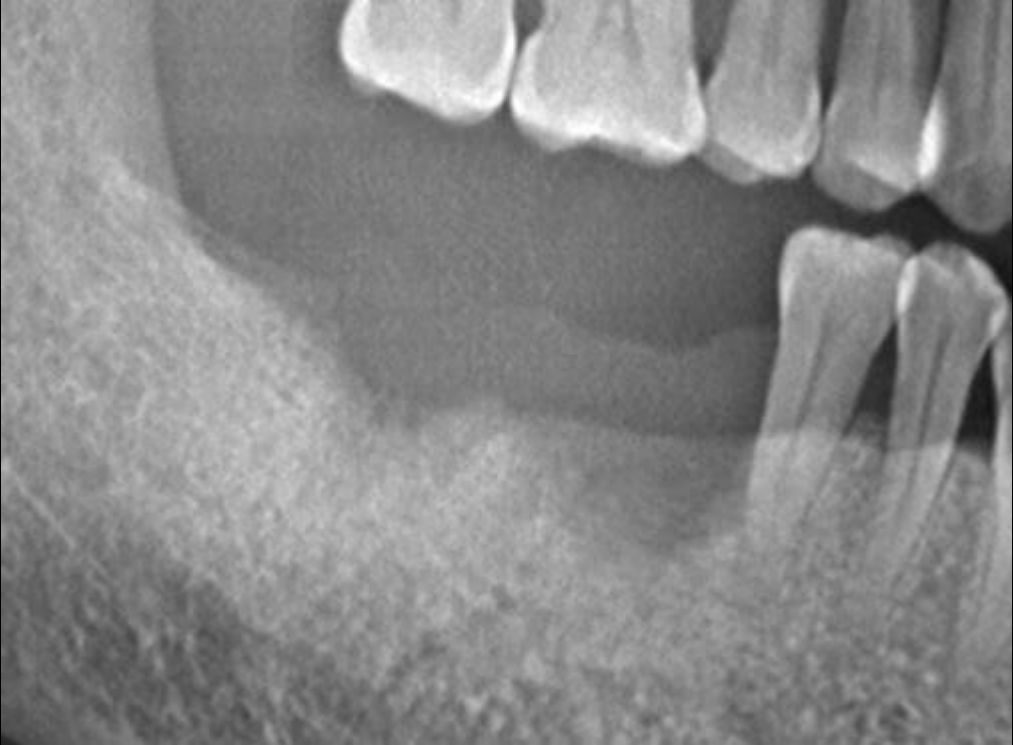



#46 Oral exam (2021-03-10)



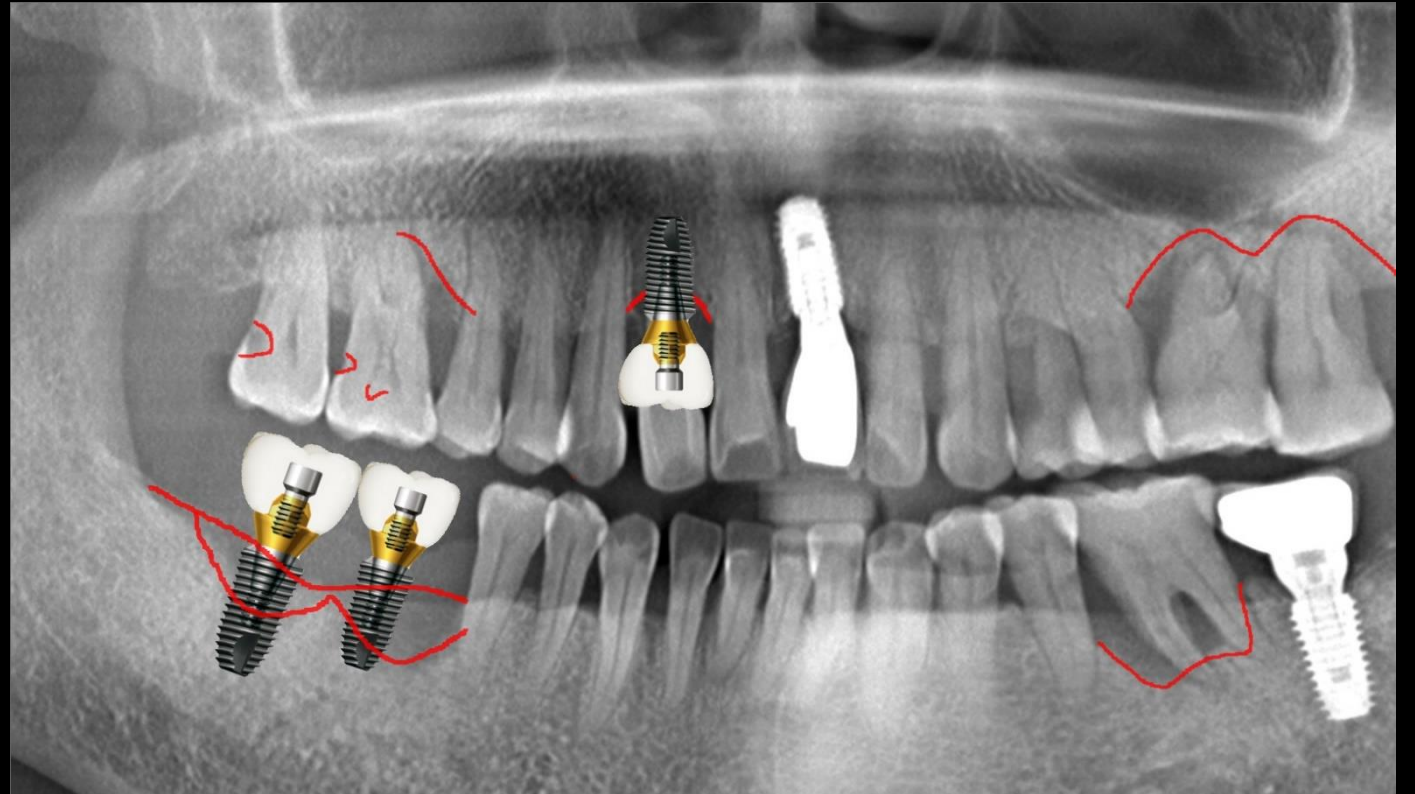




# Today's Surgery Plan

## #12

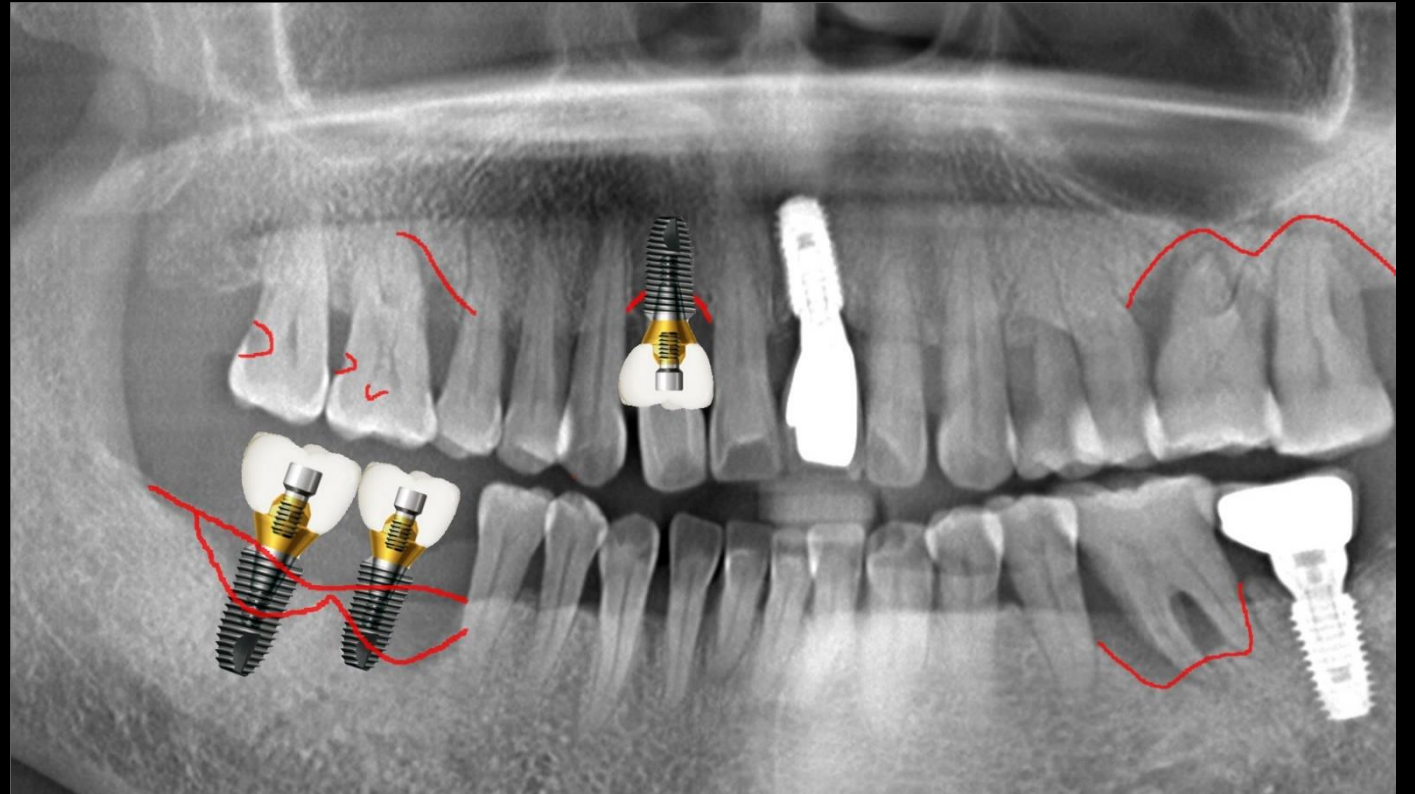
- Extraction
- Implant placement with Digital Guide Stent
- Bone graft
- Immediate loading



# Today's Surgery Plan

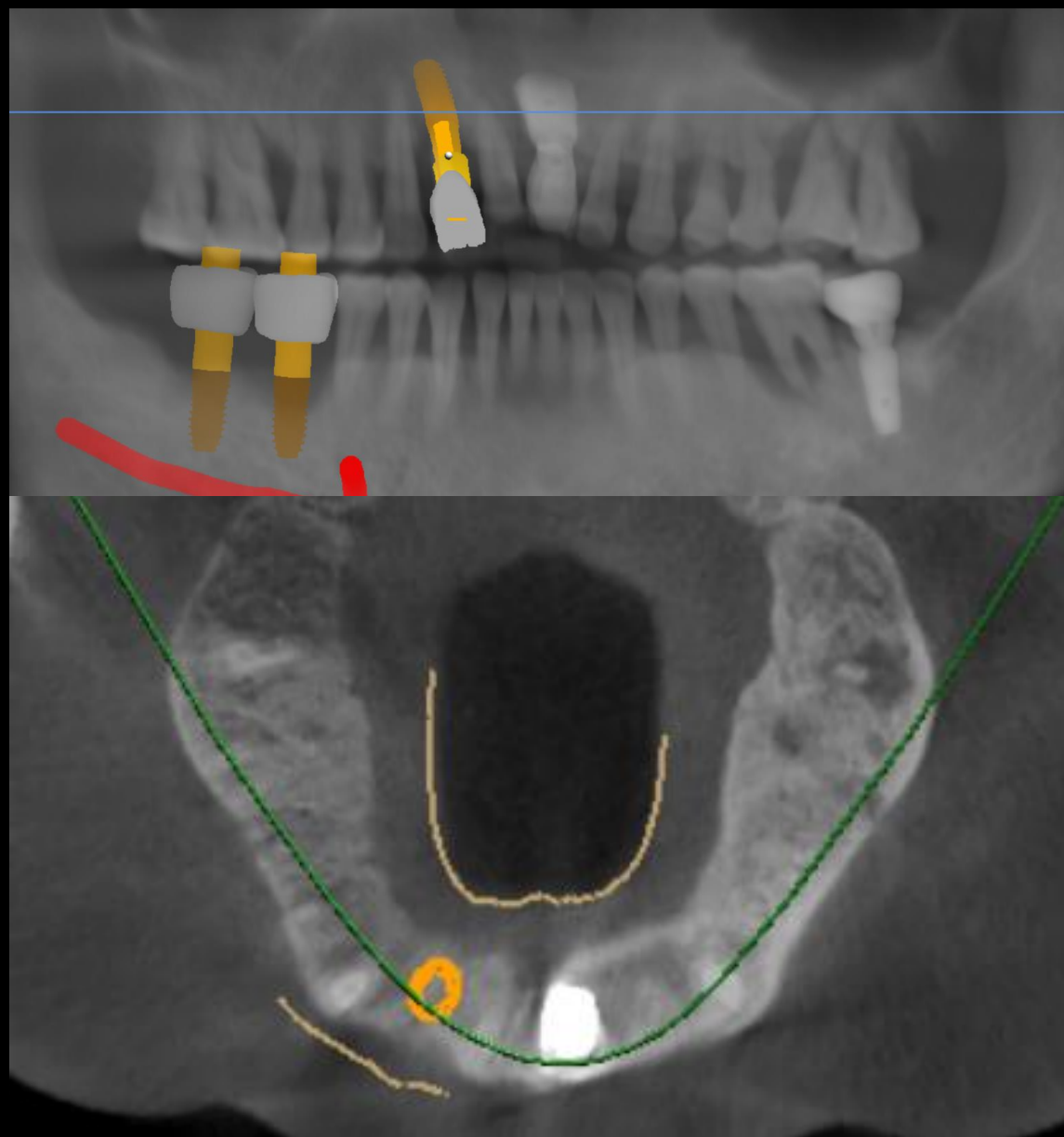
**#46, 47**

- Implant placement  
with Digital Guide Stent
- Bone graft



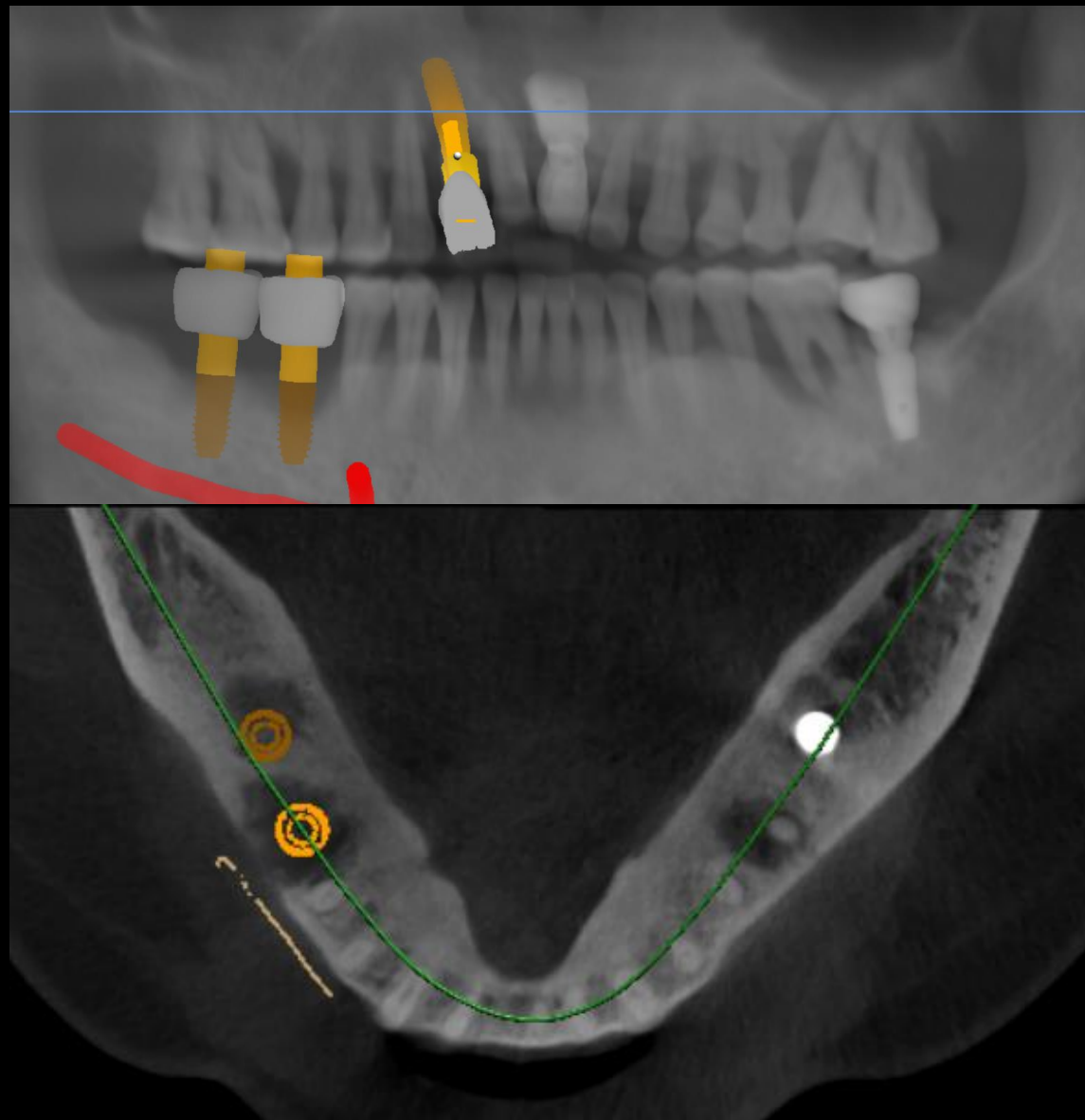
Pt. Mo (58/Female)

Pre-op(2021-03-10)



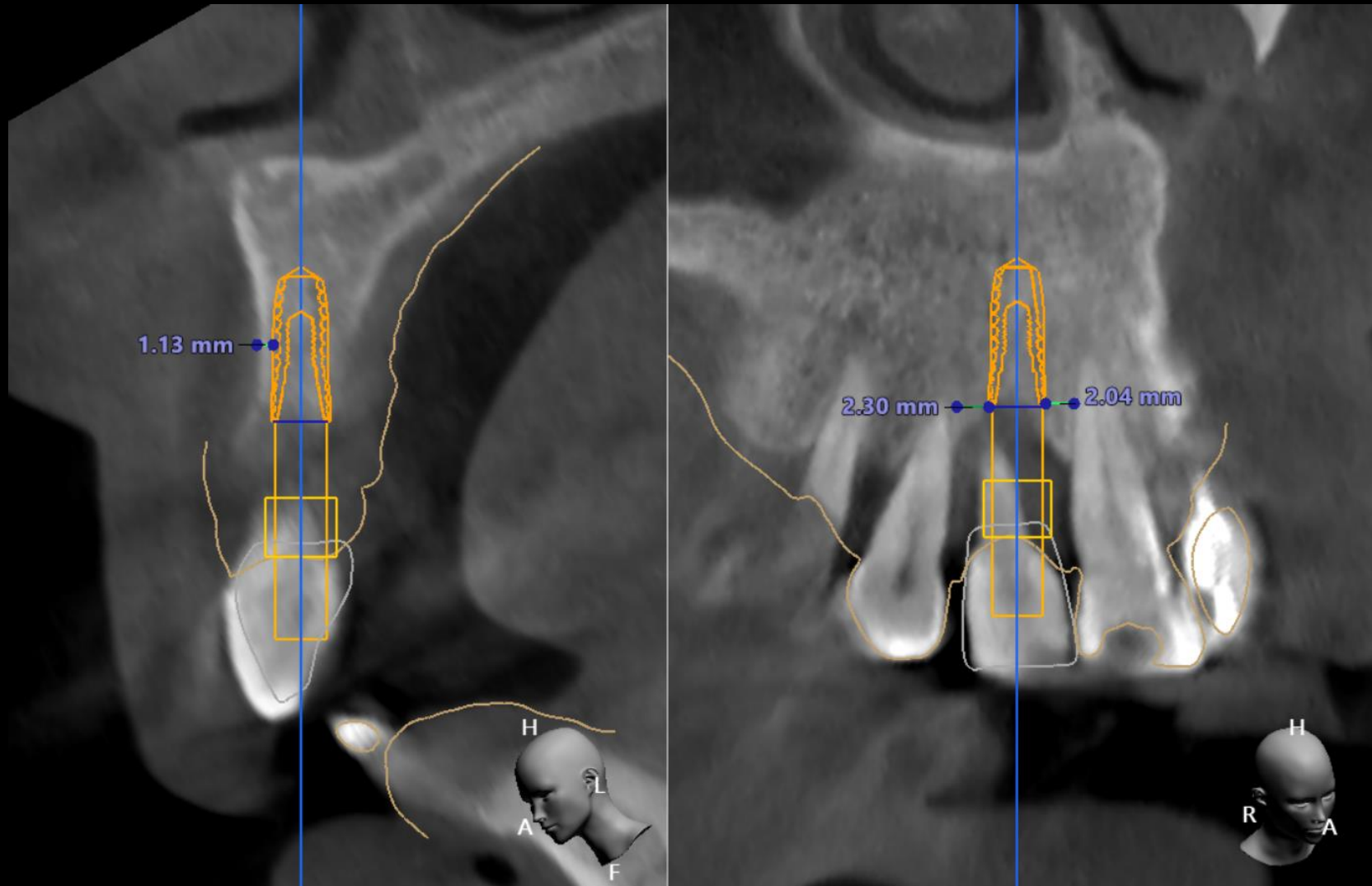
Pt. Mo (58/Female)

Pre-op(2021-03-10)



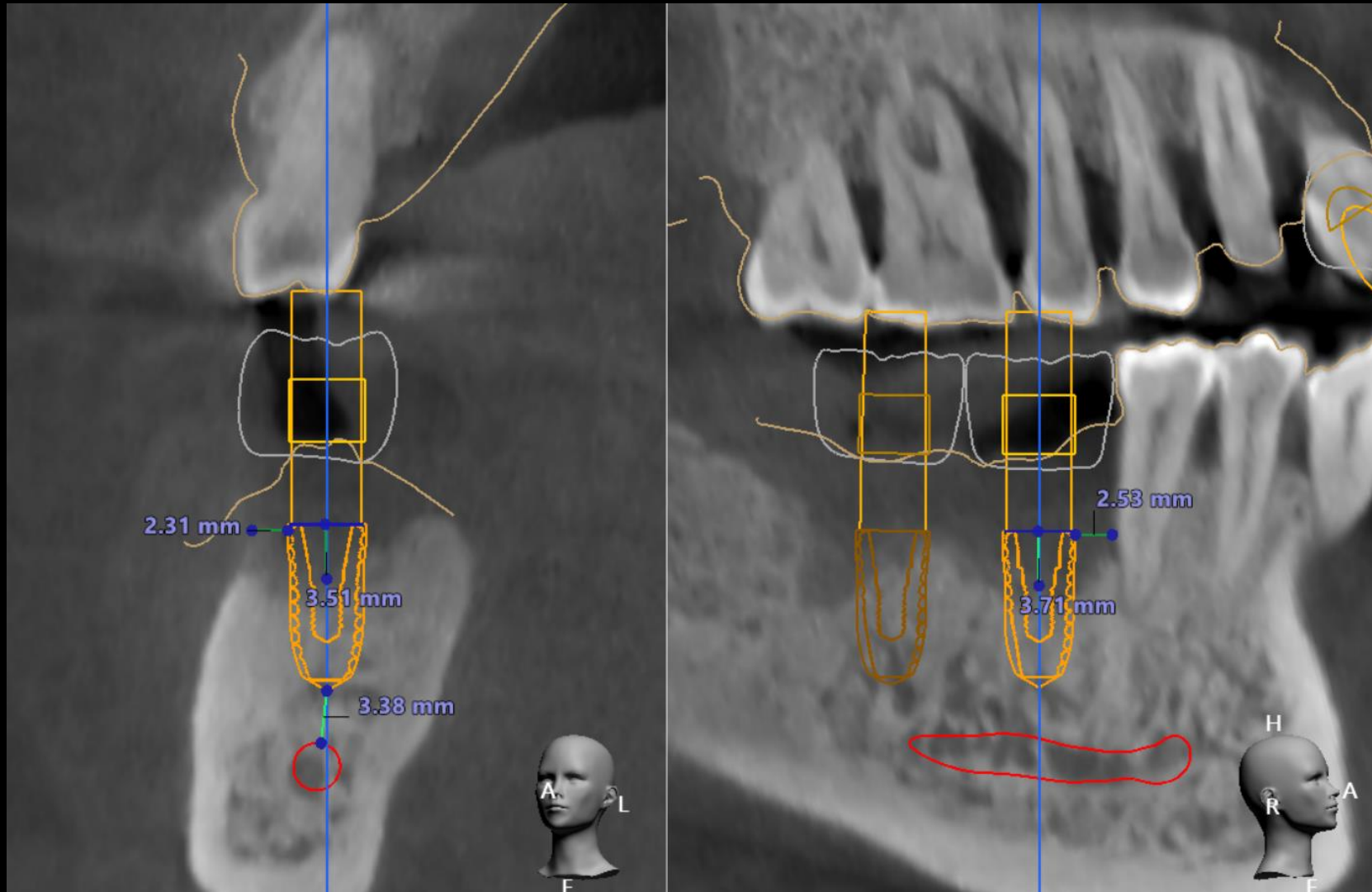
# #12 Implant Planning

(3610)



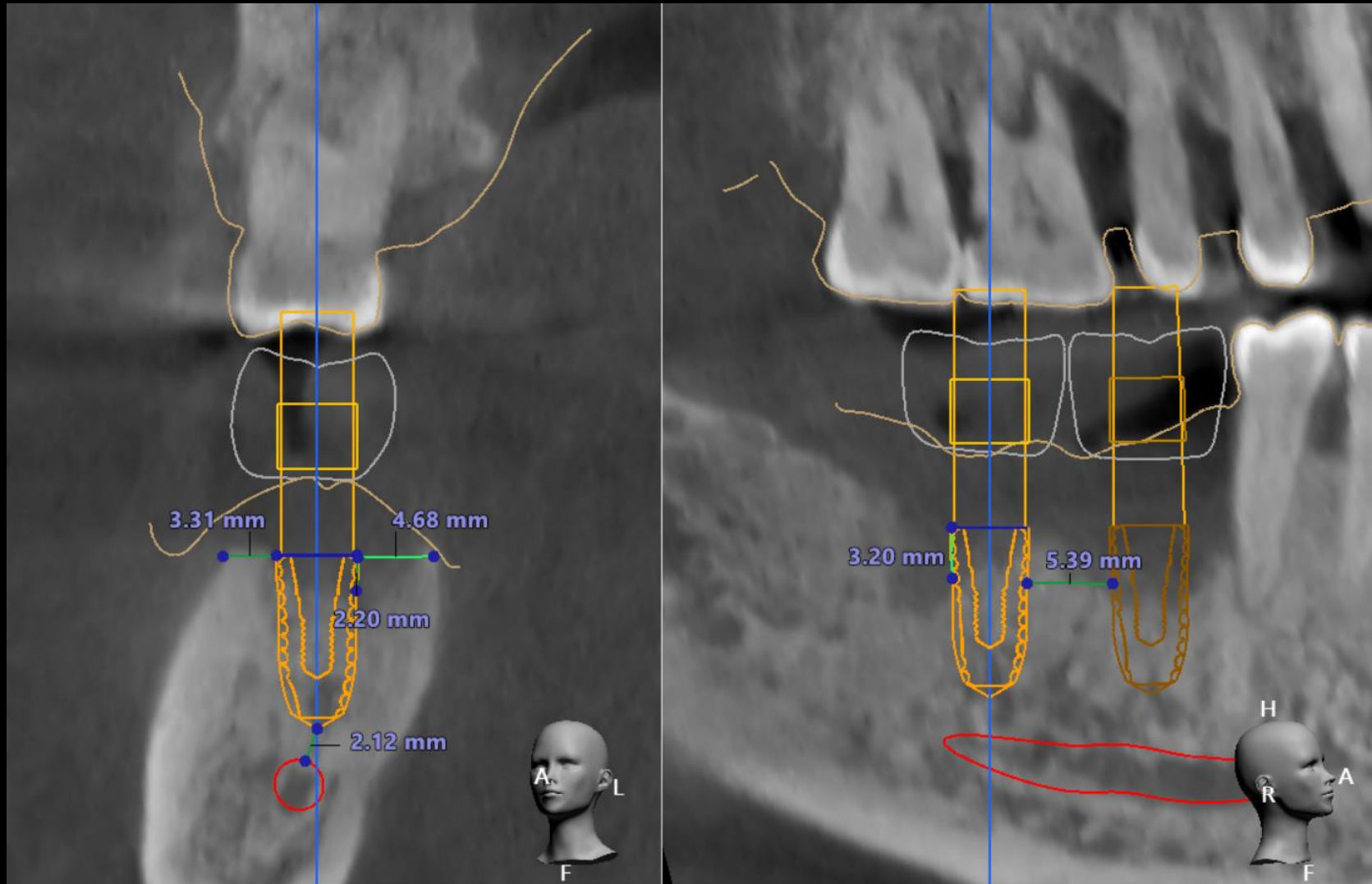
# #46 Implant Planning

(4510)



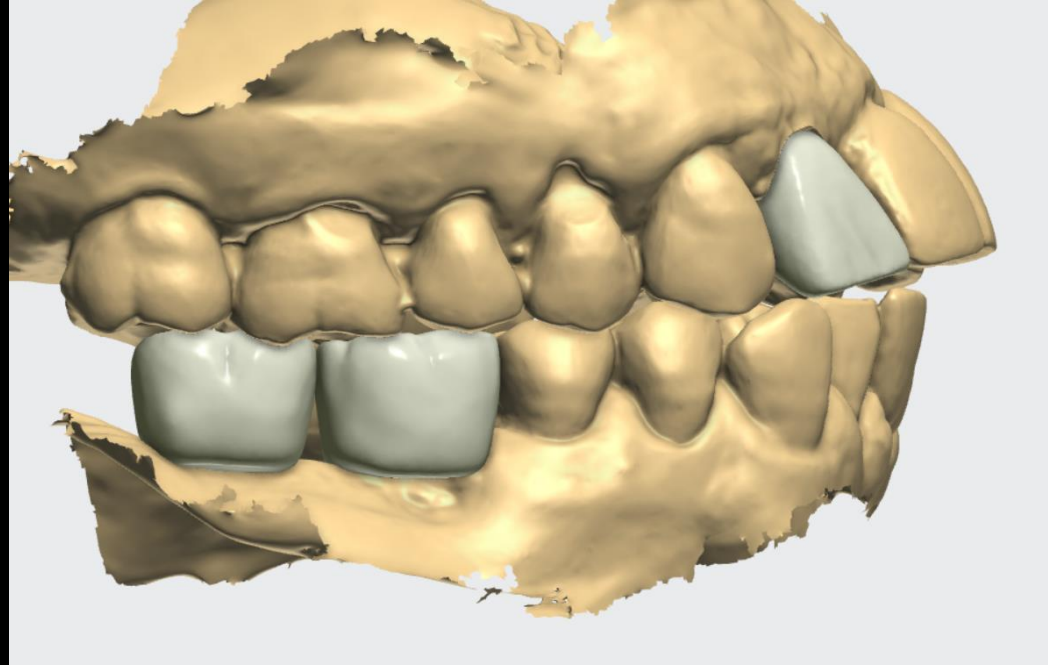
# #47 Implant Planning

(4510)

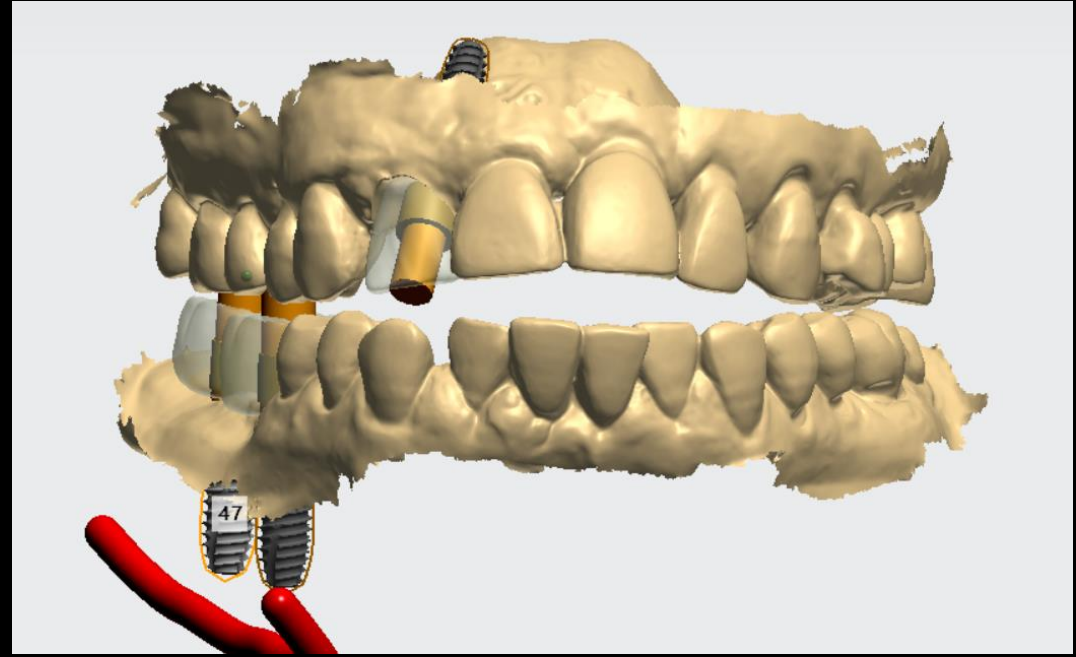
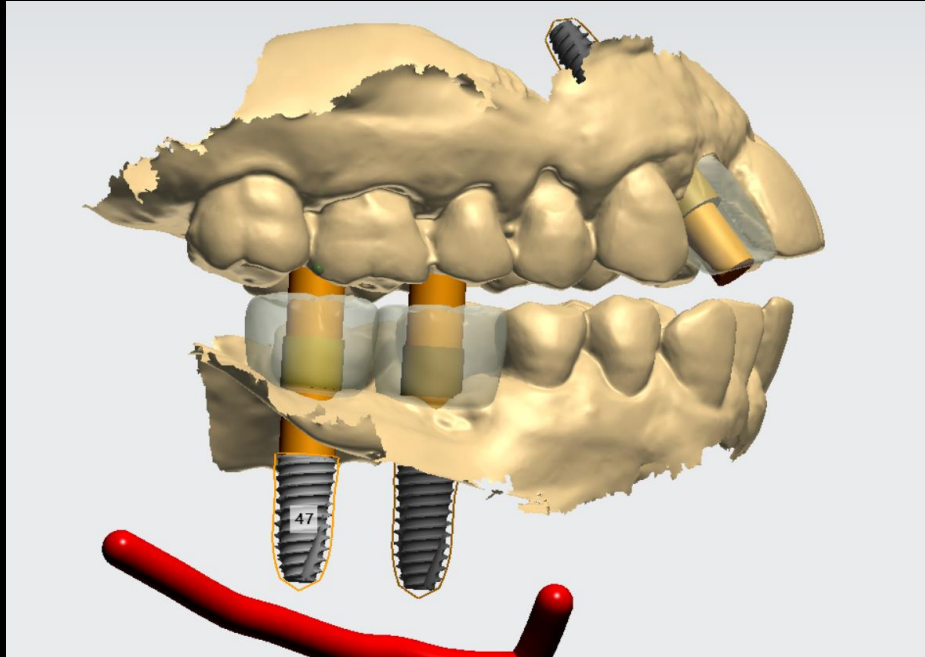





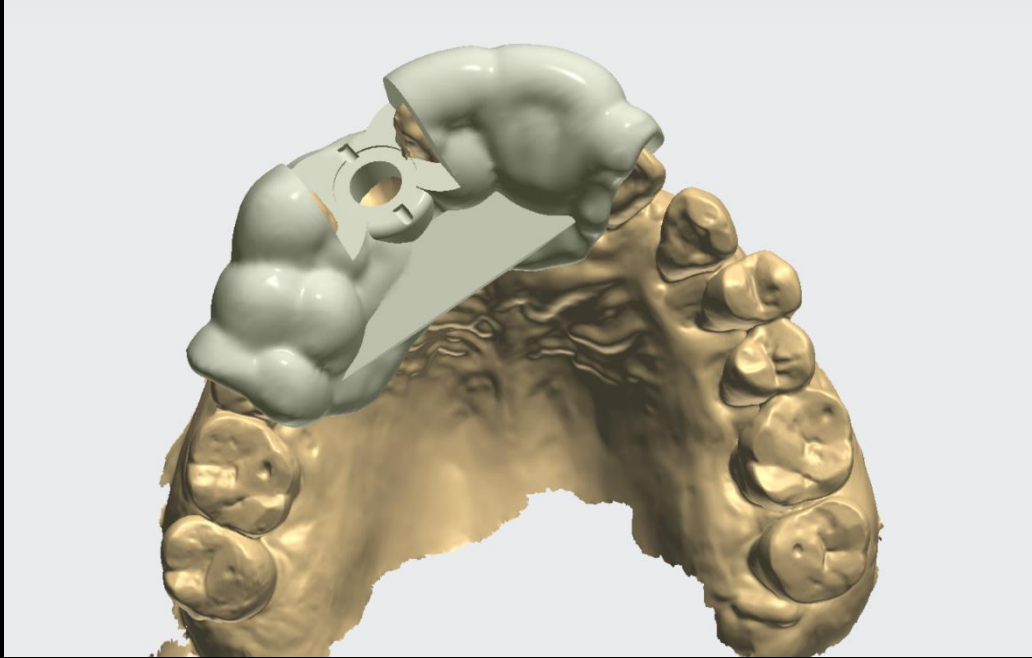
# Stent Design



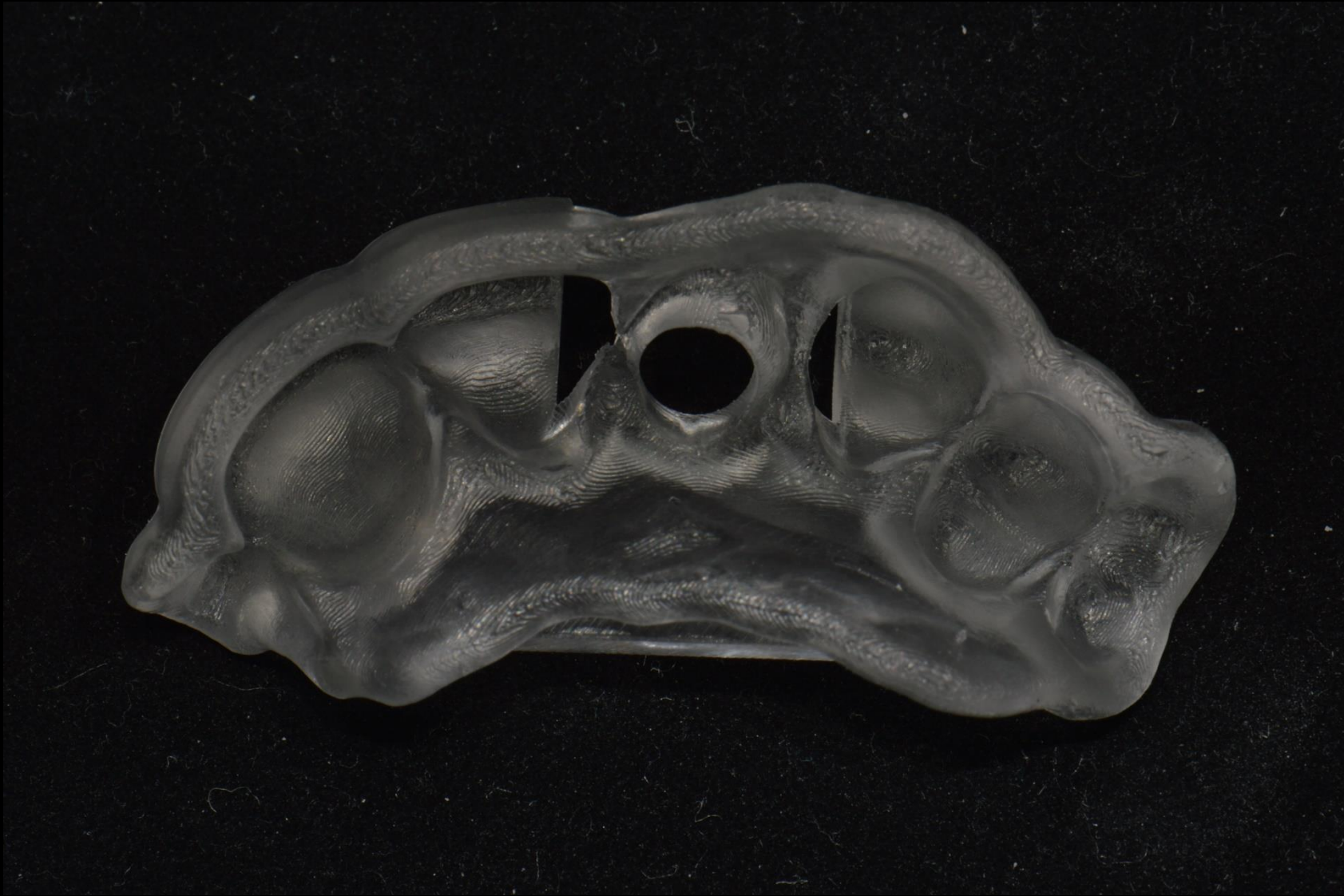# Stent Design



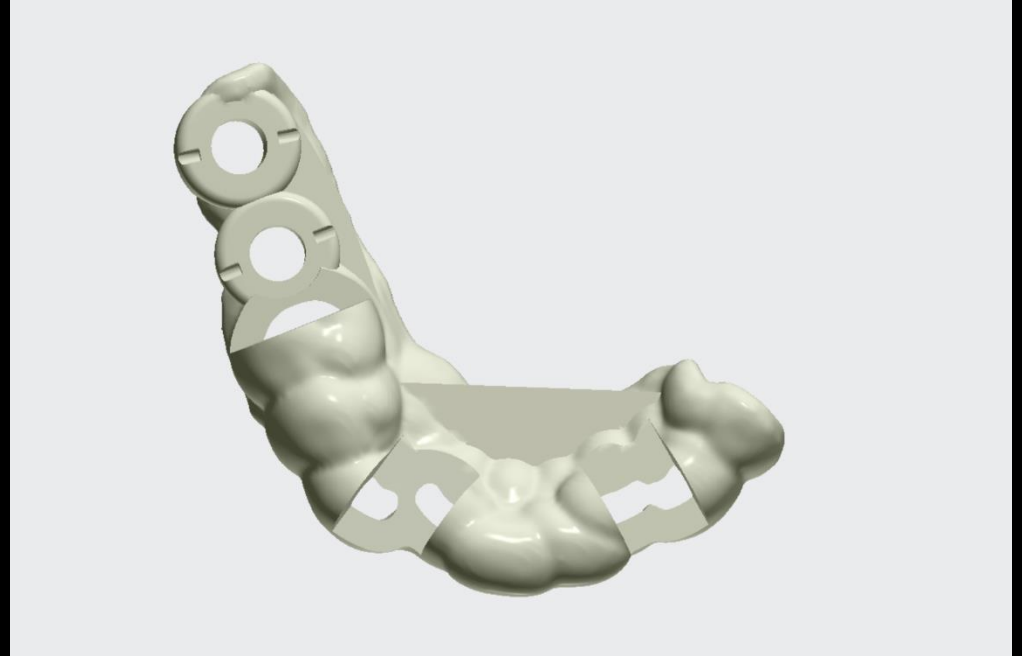
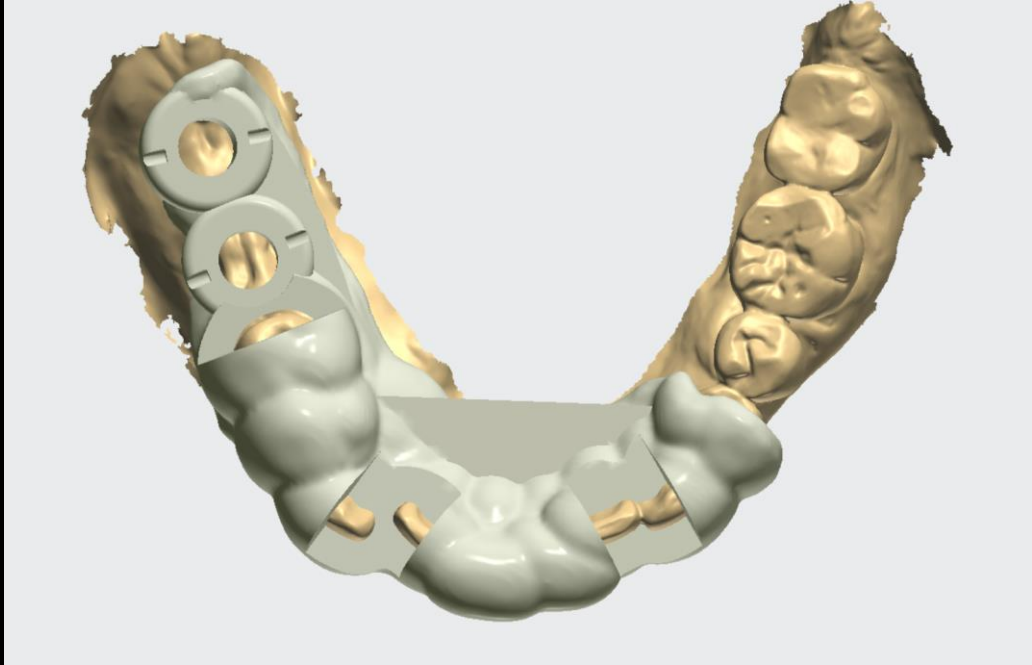
# Stent Design



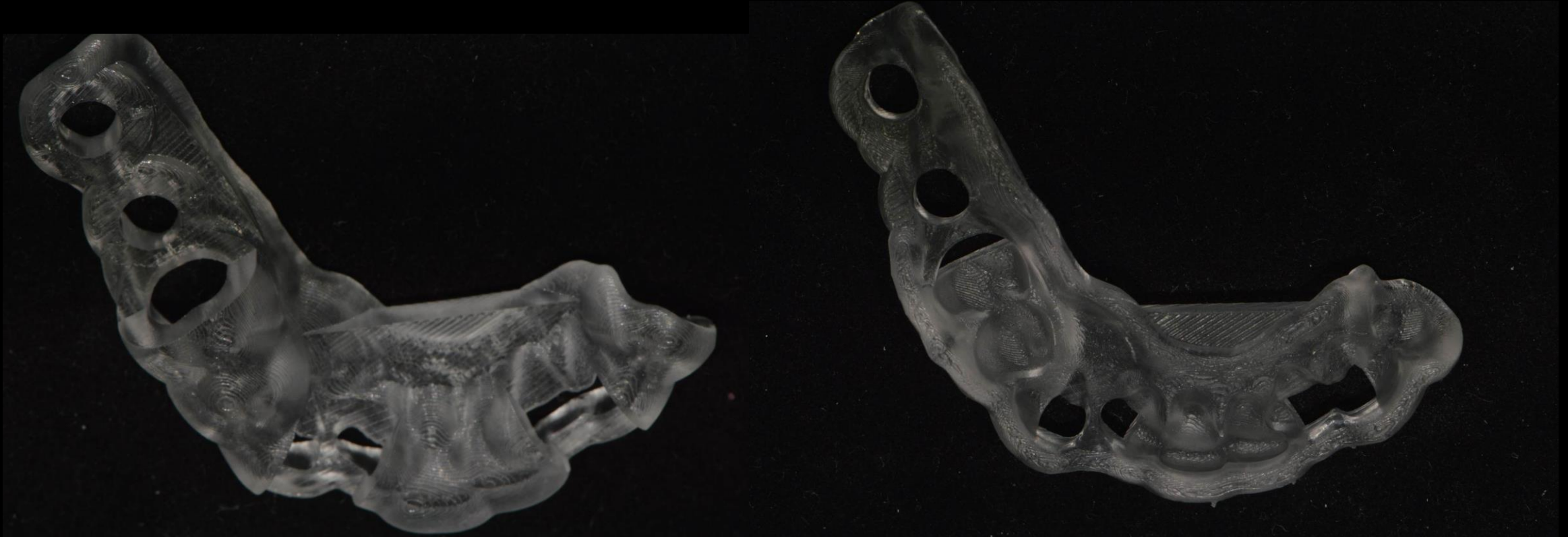
# Stent



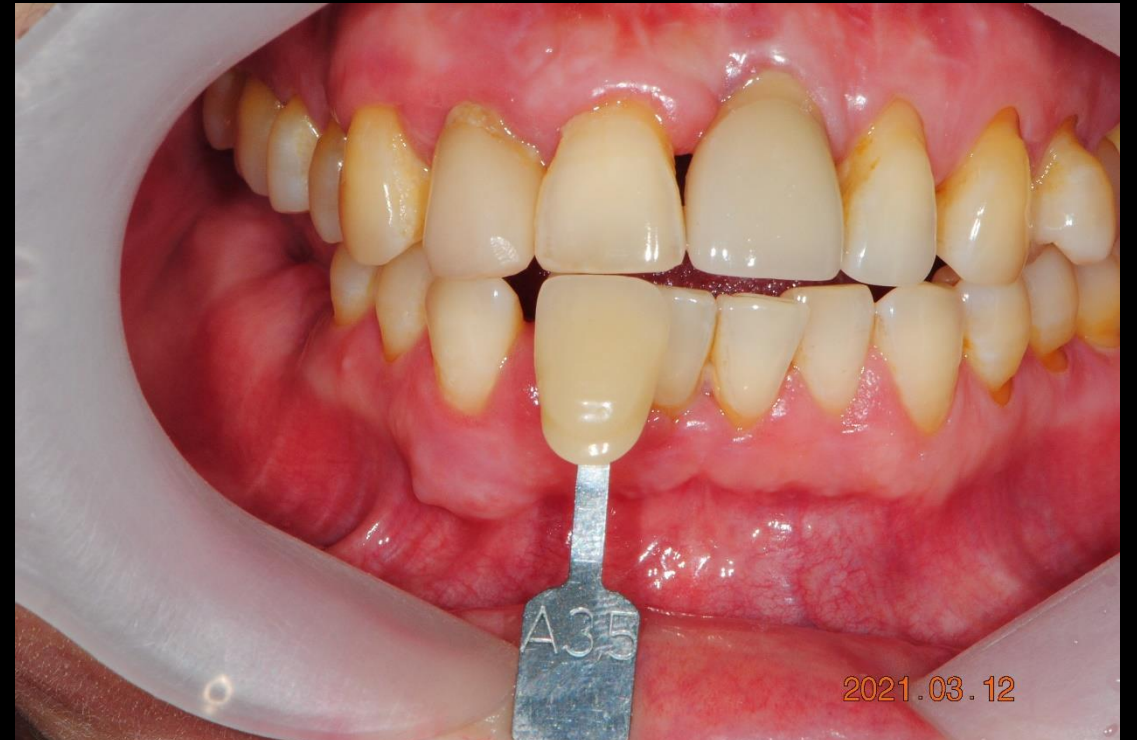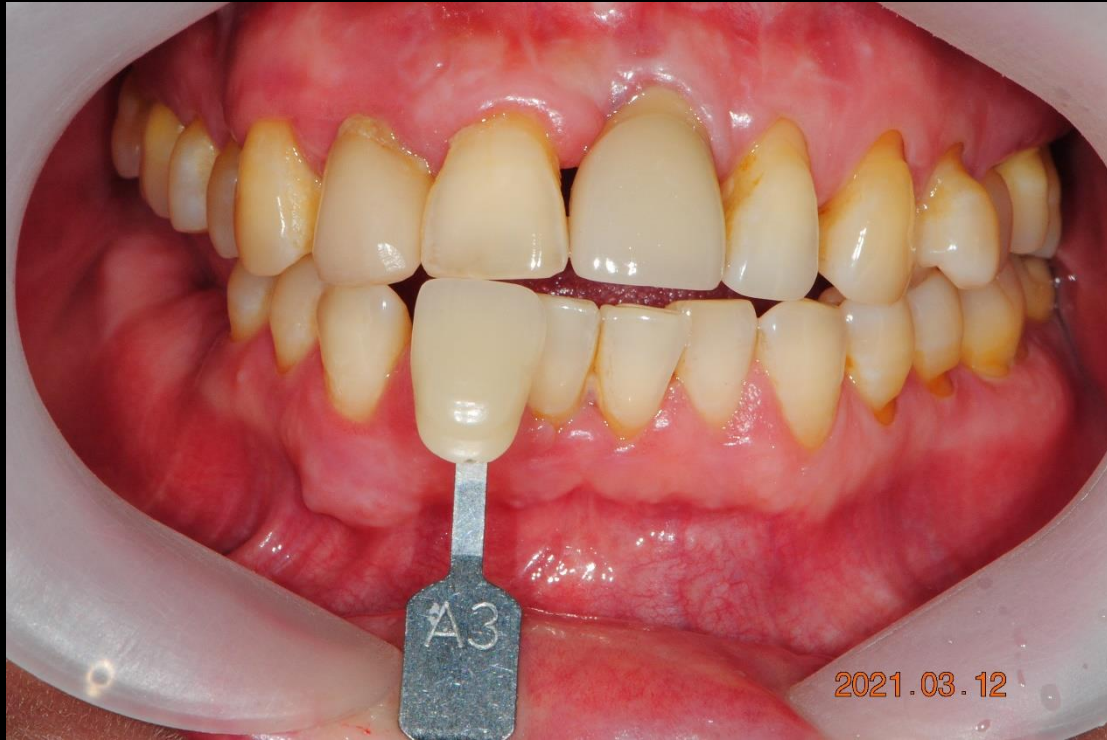# Stent Design



# Stent

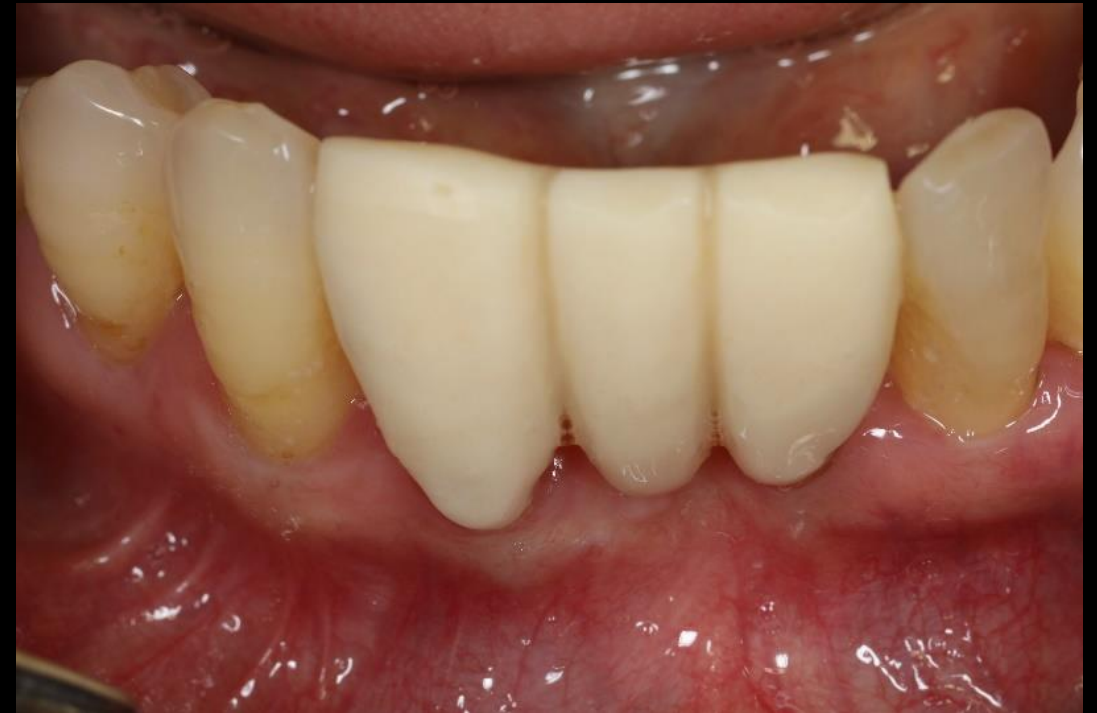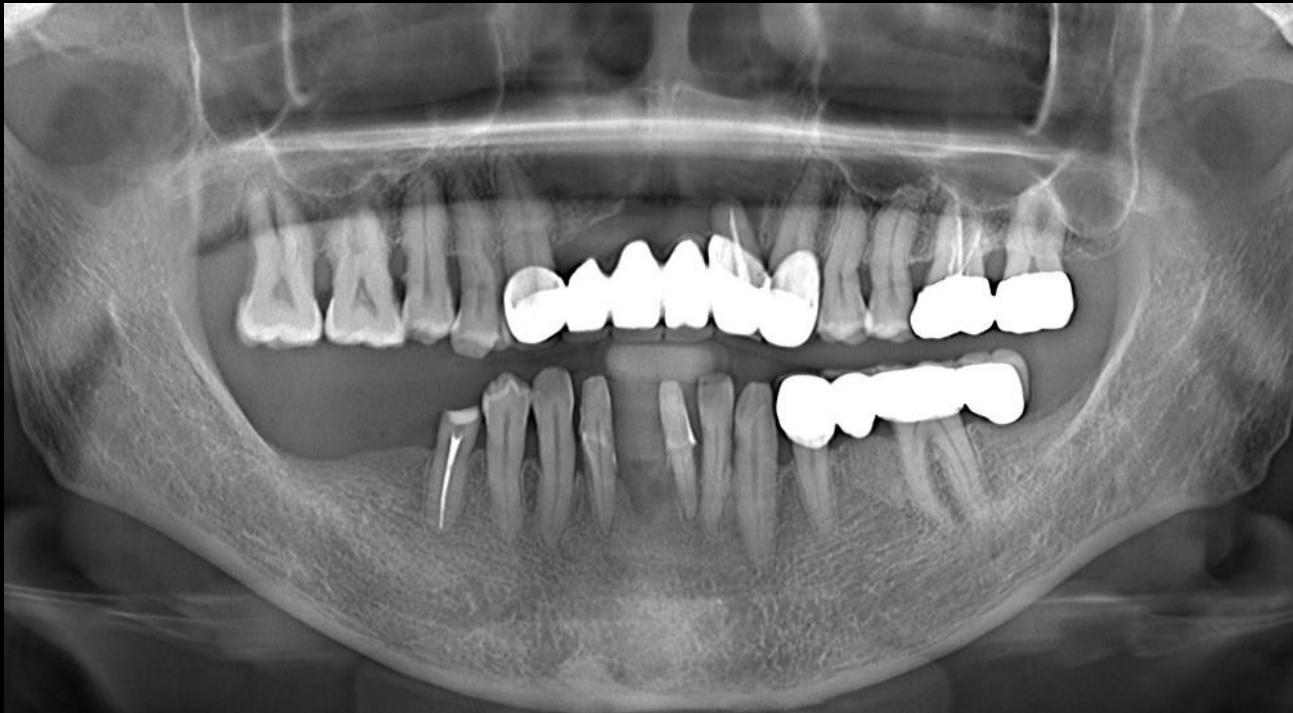


# #12 Shade



**Similar case**

**Immediate implantation & Contour augmentation**

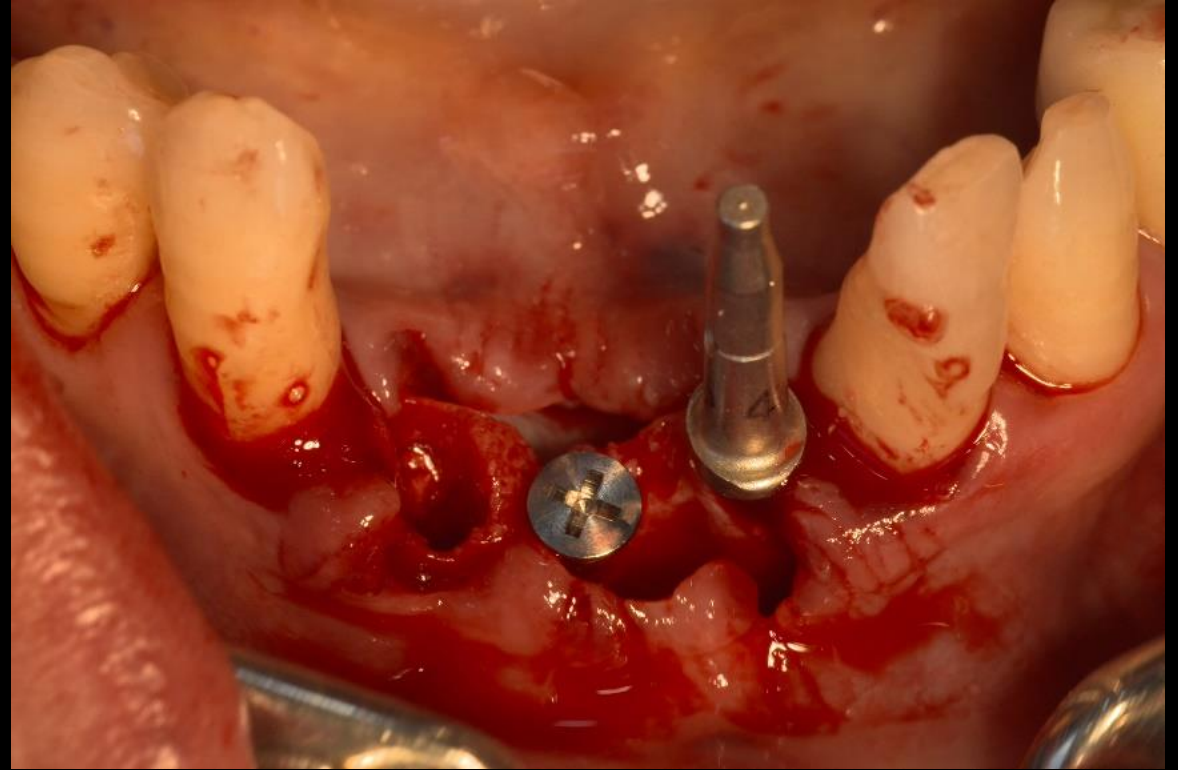
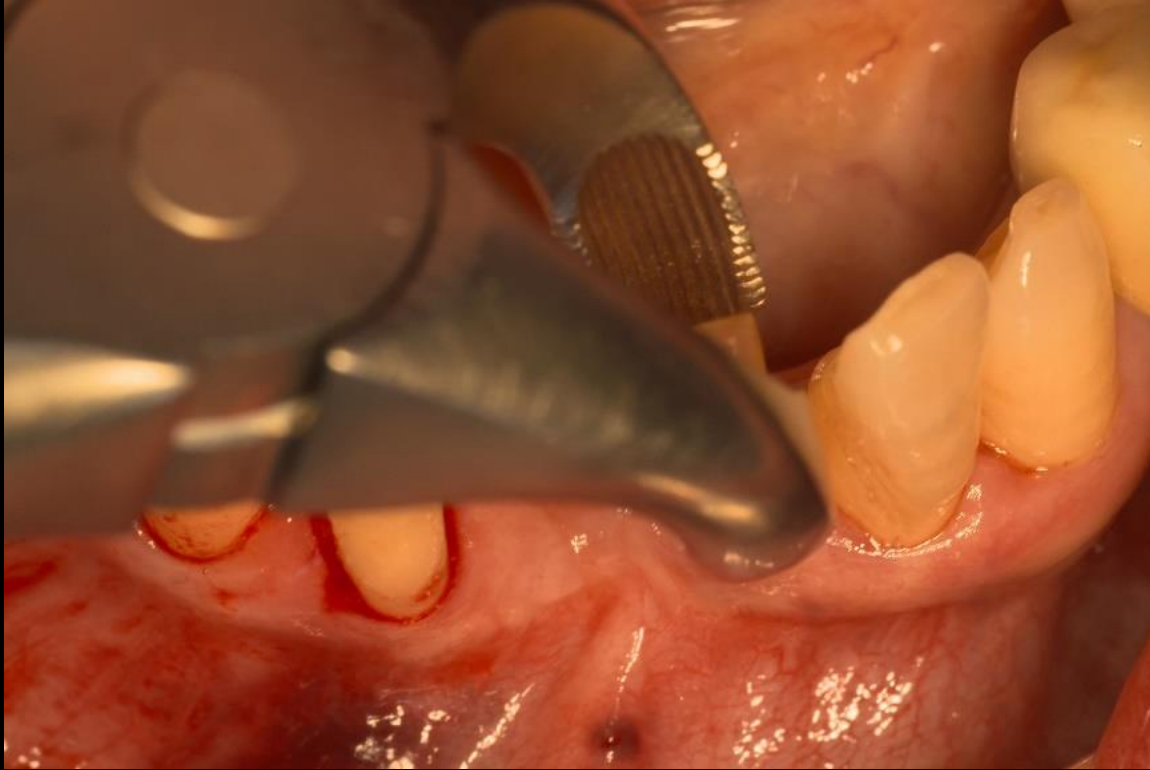


Pre-op (2018-04-30)



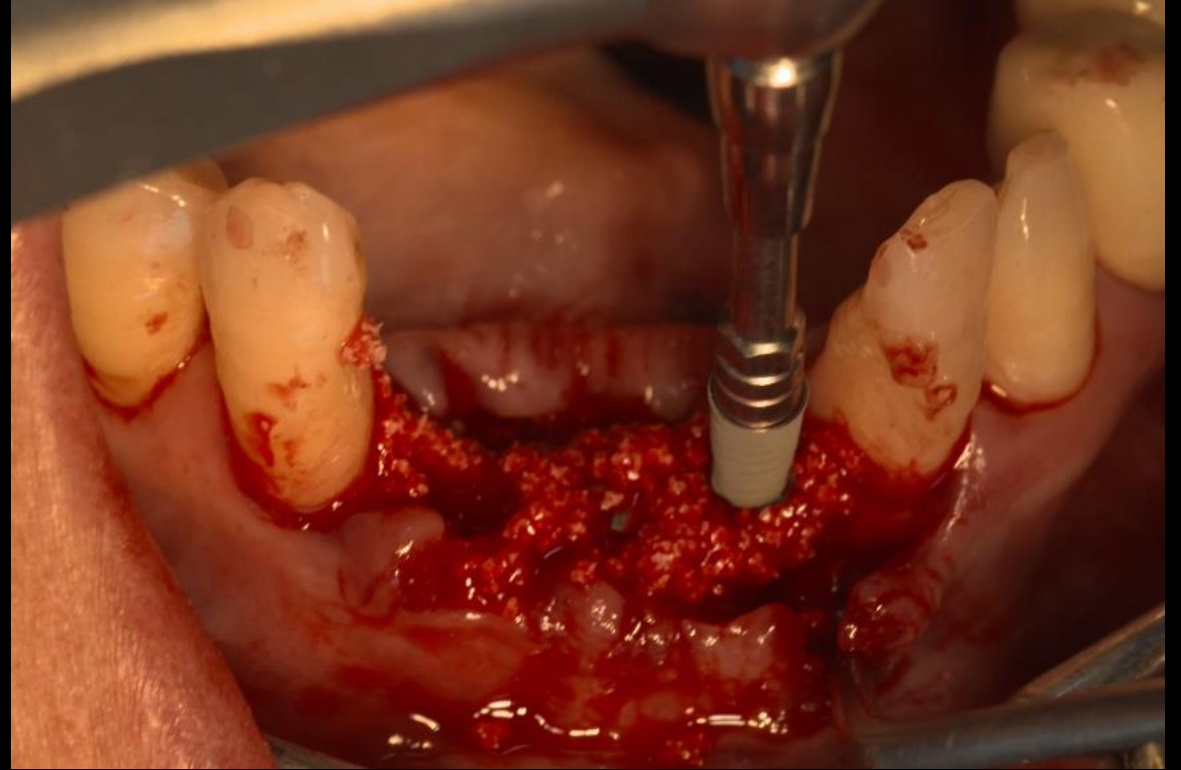
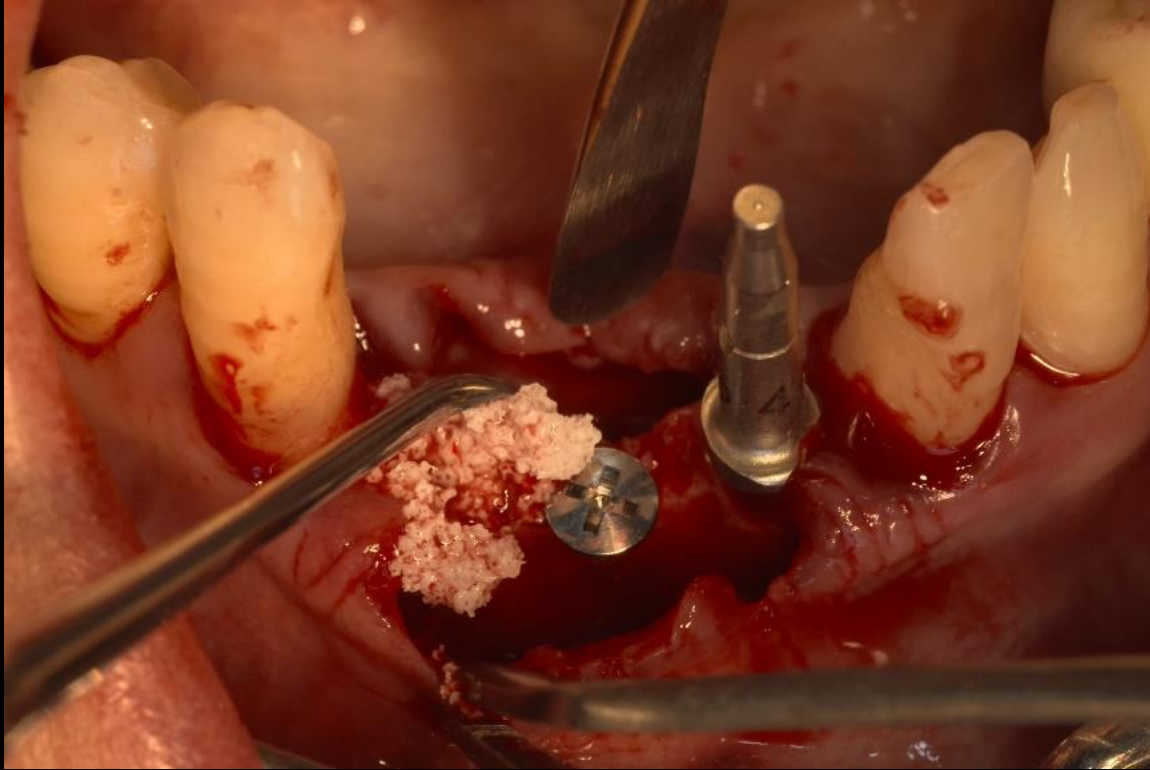
**Similar case**

**Immediate implantation & Contour augmentation**



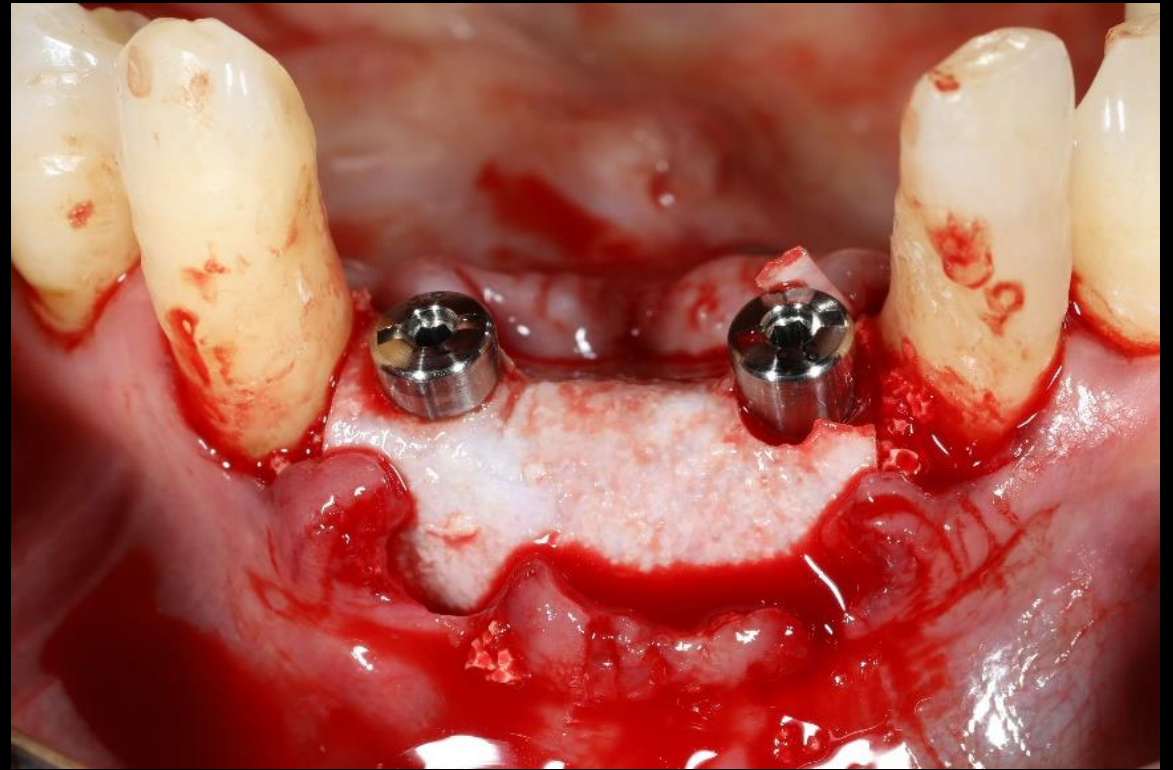
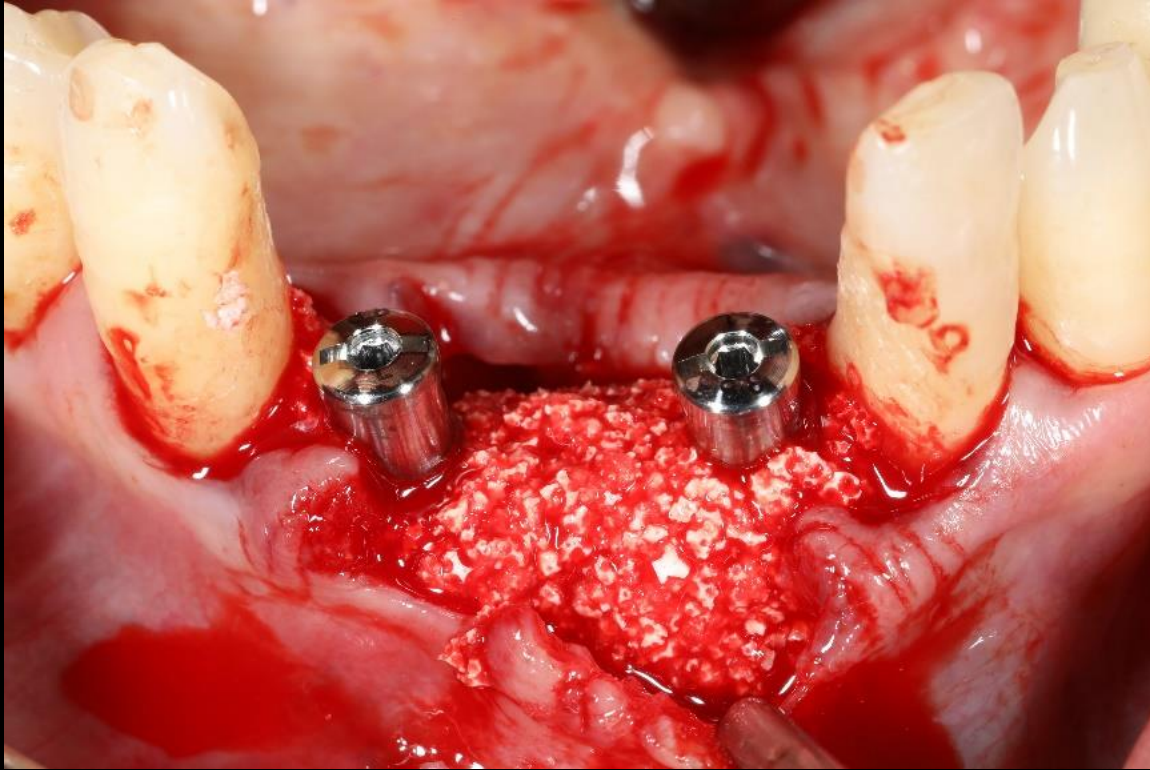
## Similar case

## Immediate implantation & Contour augmentation



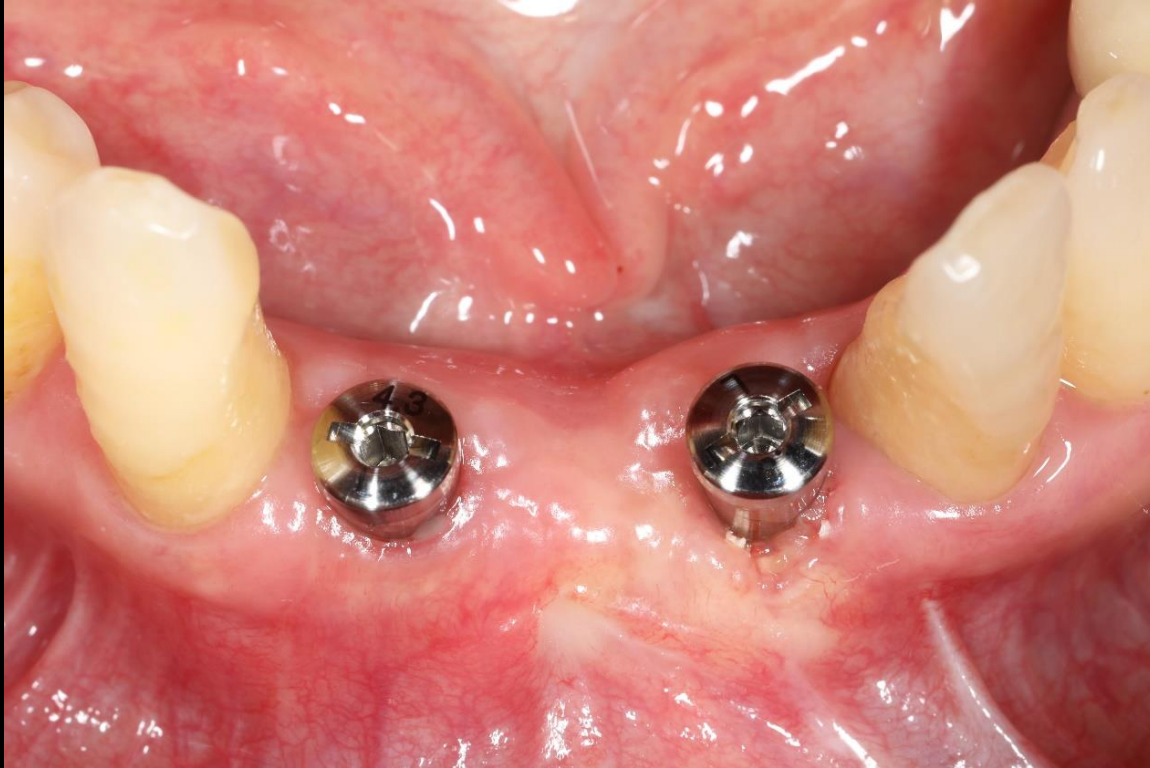**Similar case**

**Immediate implantation & Contour augmentation**

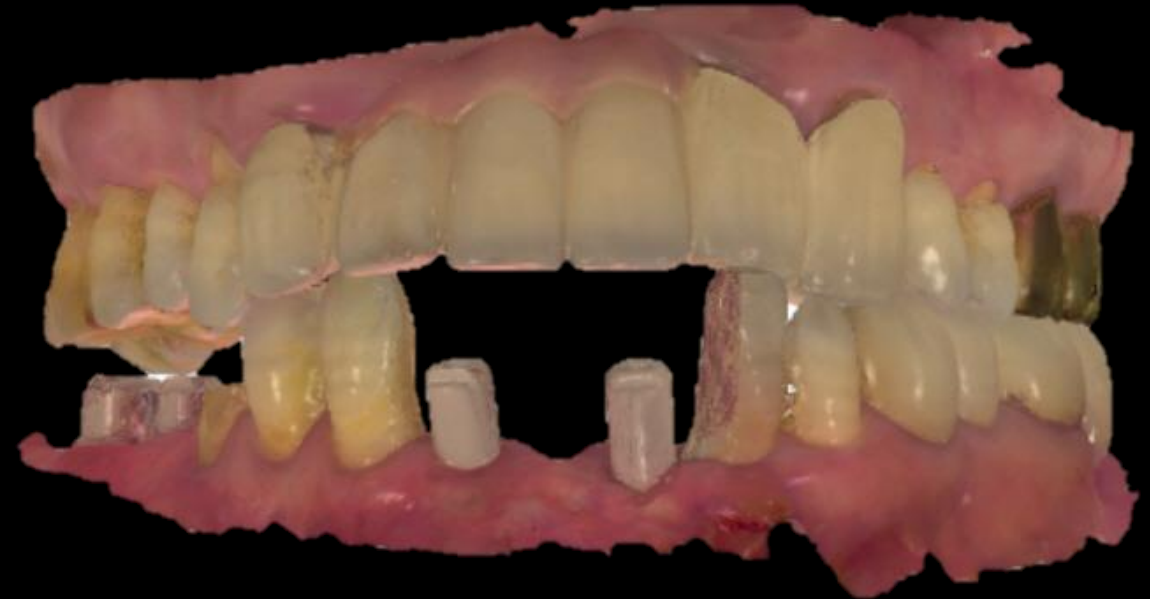

## Similar case

## Immediate implantation & Contour augmentation



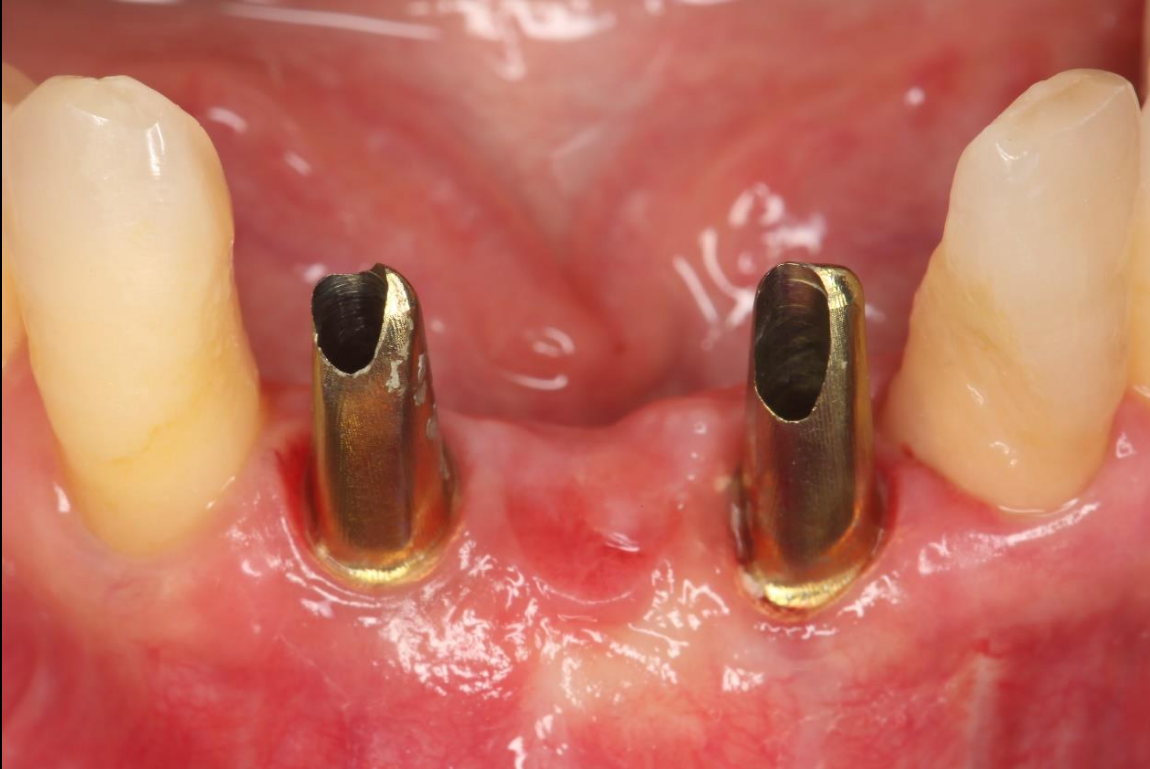Healing : 1 month 2 weeks  
(2018-06-11)



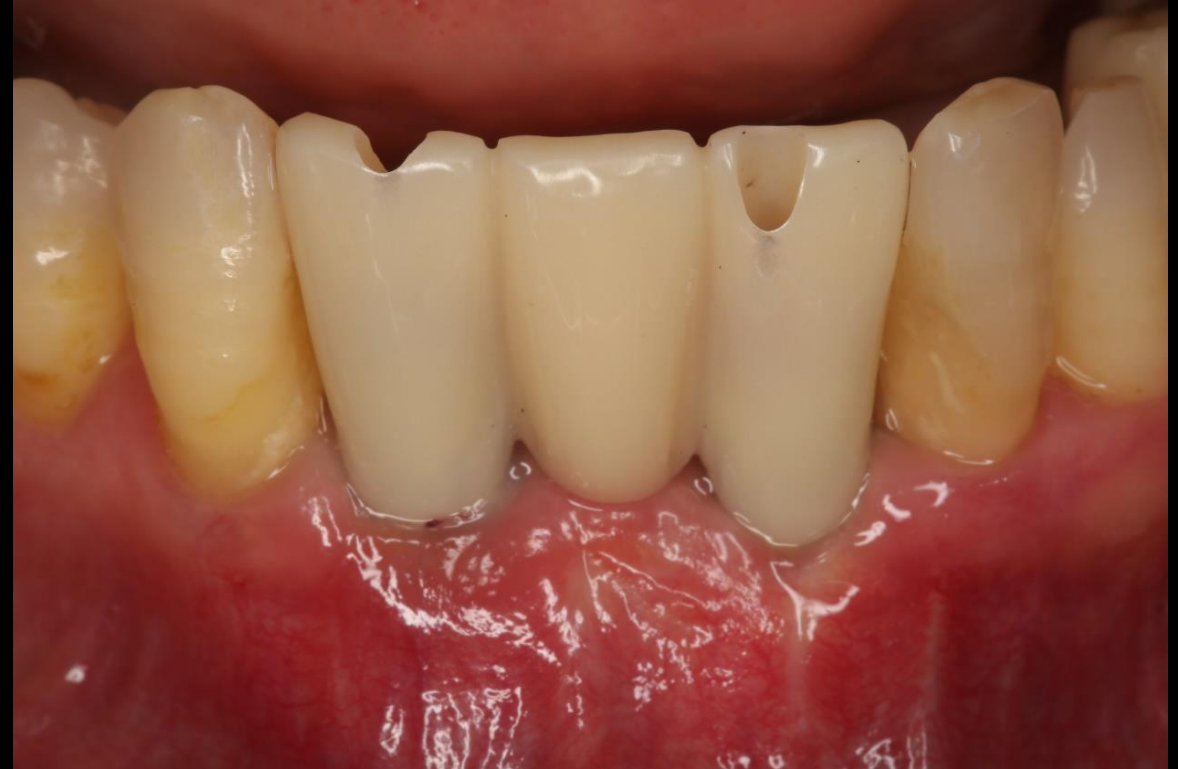Intra Oral Scanning  
(2018-06-11)

**Similar case**

**Immediate implantation & Contour augmentation**



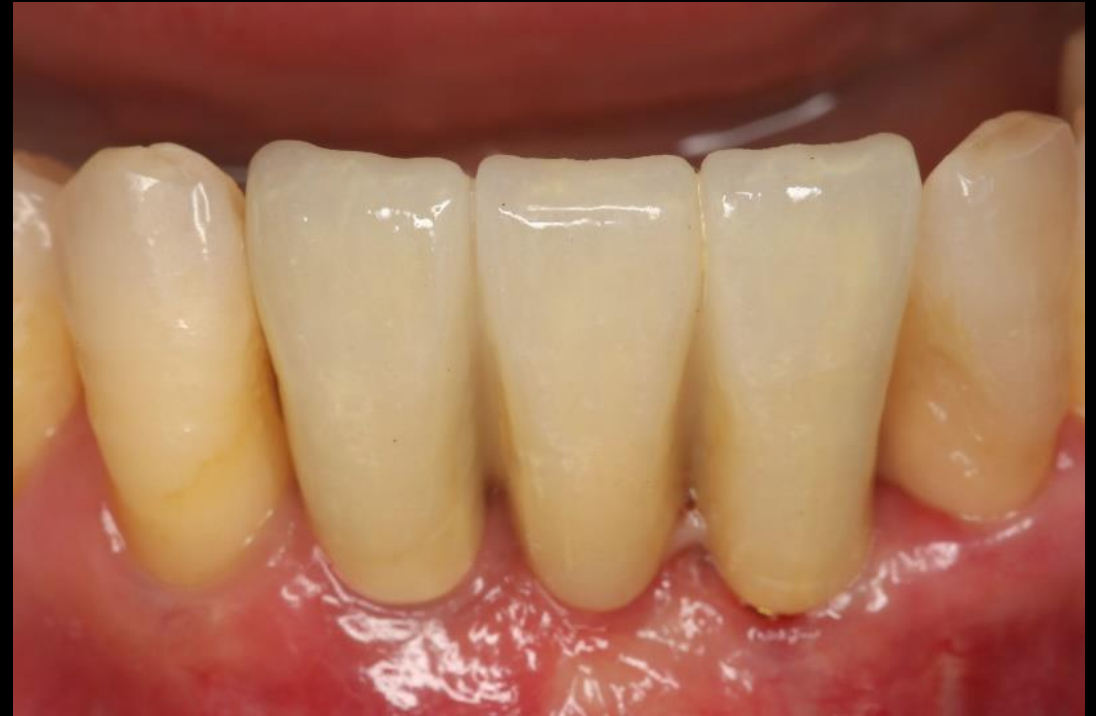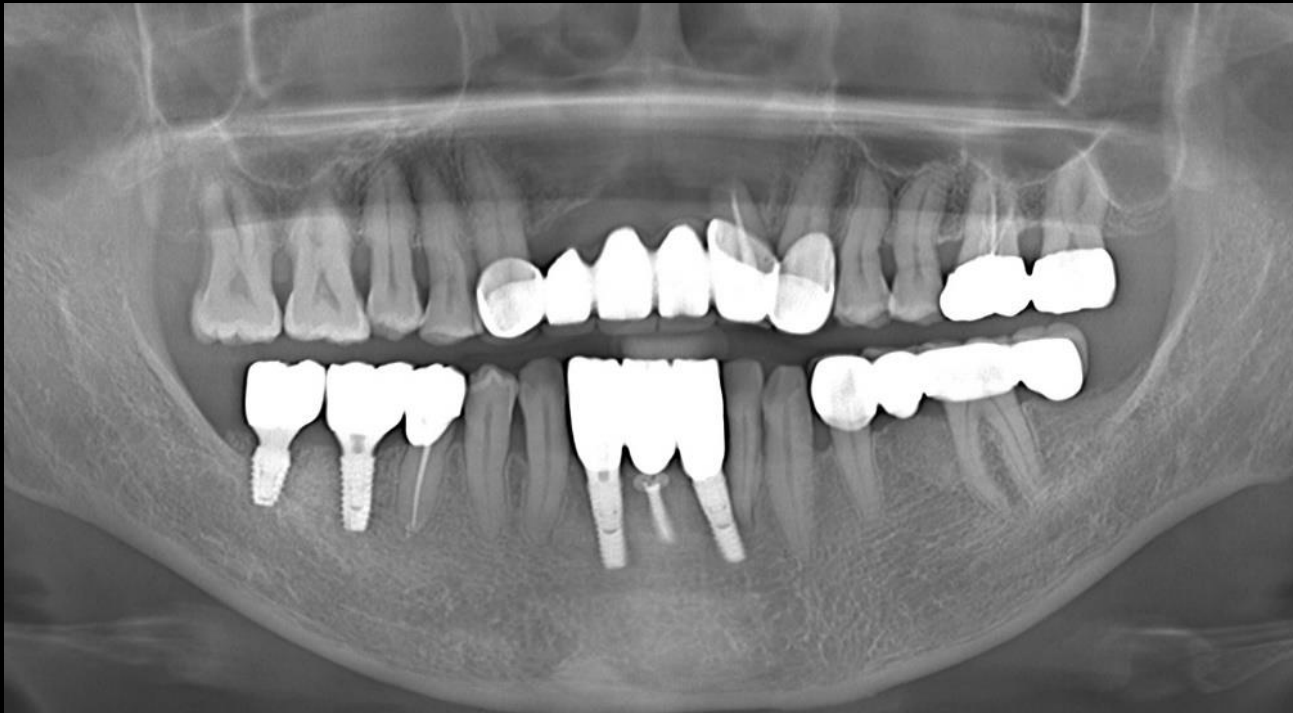**Customized abutment**  
(2018-06-25)



**Provisional restoration**  
(2018-06-25)

**Similar case**

**Immediate implantation & Contour augmentation**



Final prosthesis (2018-09-03)