



LIVE Surgery

Dr. Chang Dong-Wook

2020.02.07 (Fri.)



[Case Preview]

Implantation & GBR on Anterior area
using Dentium Digital Guide

Patient Information

Age : 68y

Sex : Female

Chief Complaint

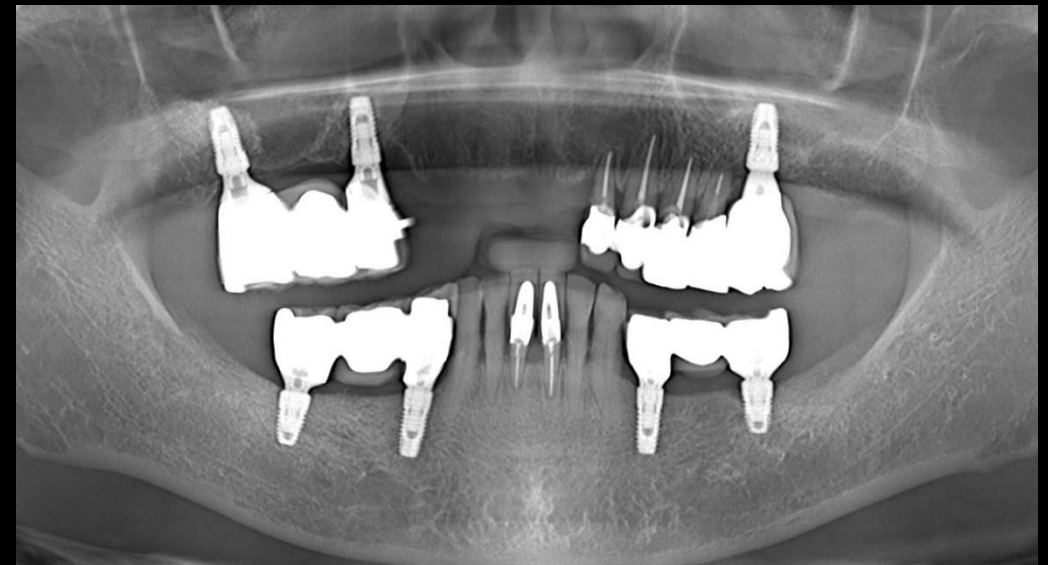
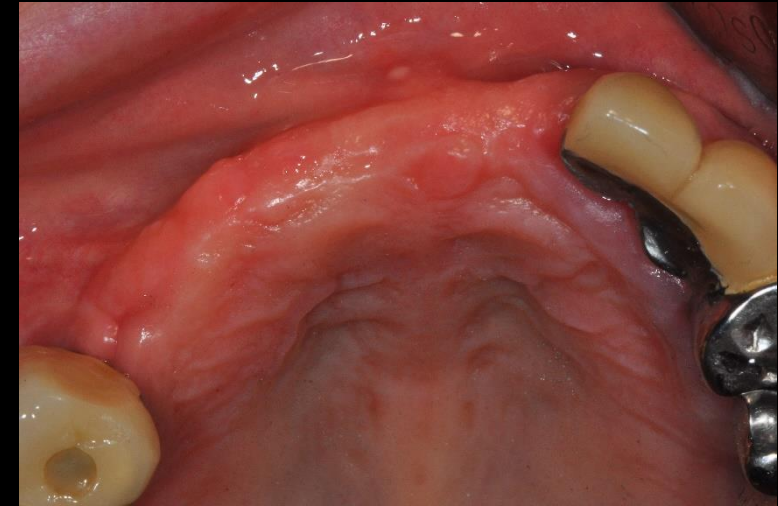
: "#14=#22 Bridge Fracture"

Past Medical History

: N/S

Past Dental History

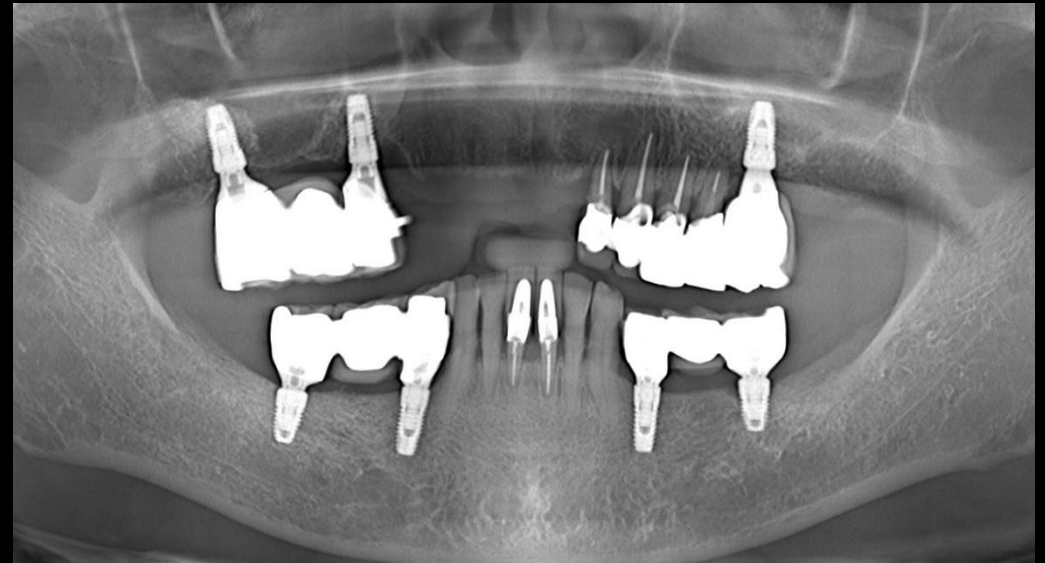
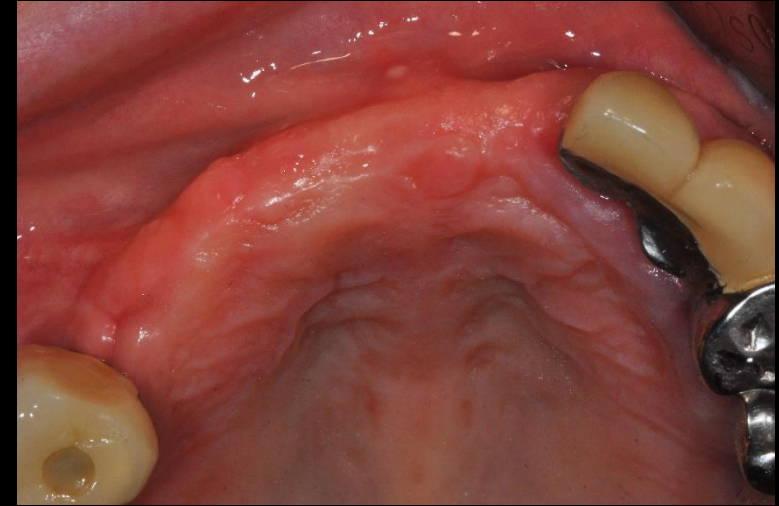
: Removal of #14=#22 Bridge (2019.11)
Extraction #14 (2019.11)



Patient Information

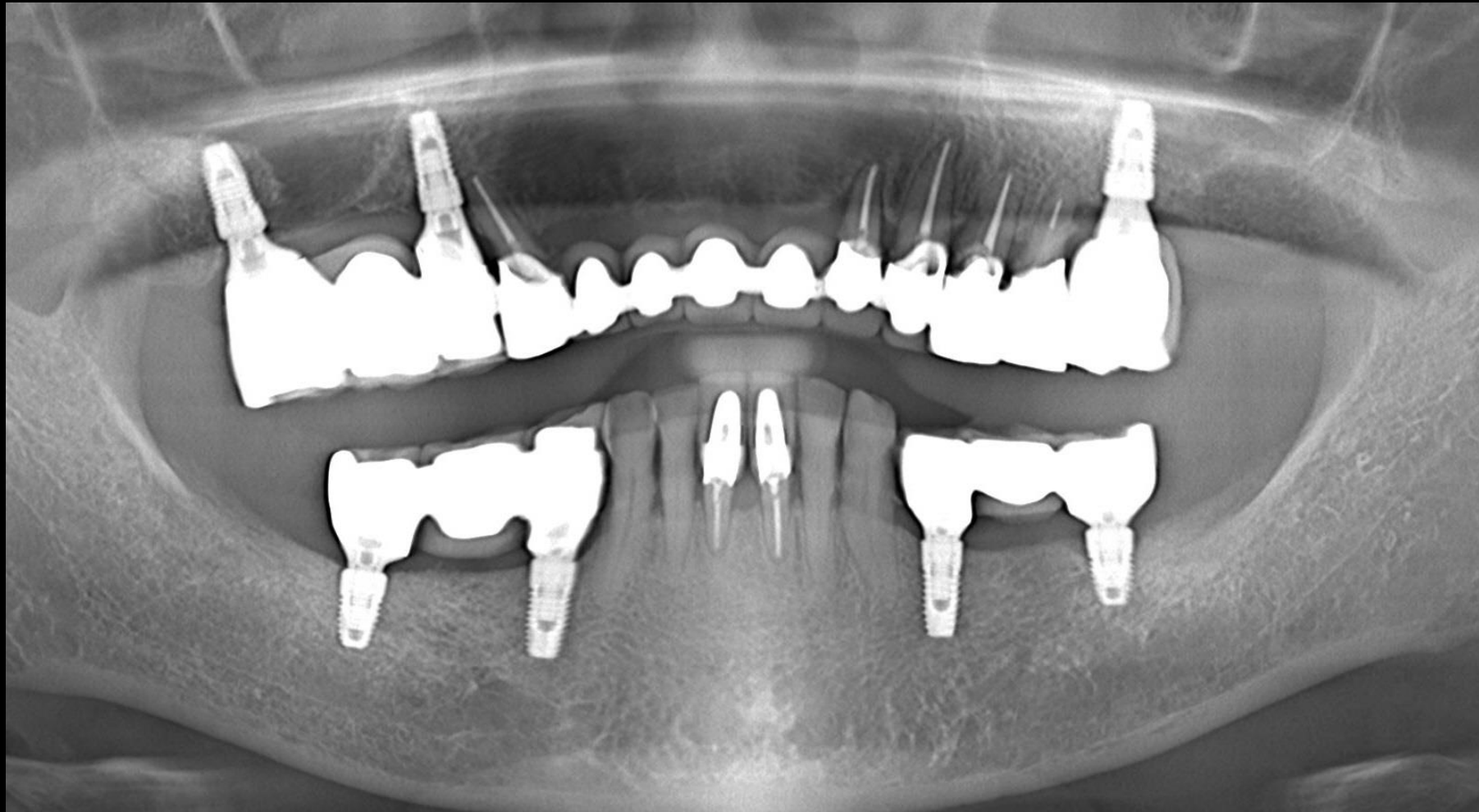
Surgery Plan

- #14, #12, #21 Implantation using Digital Guide
- #14, #12, #21 Ridge Splitting or Ridge Expansion
- GBR : DUK Technique



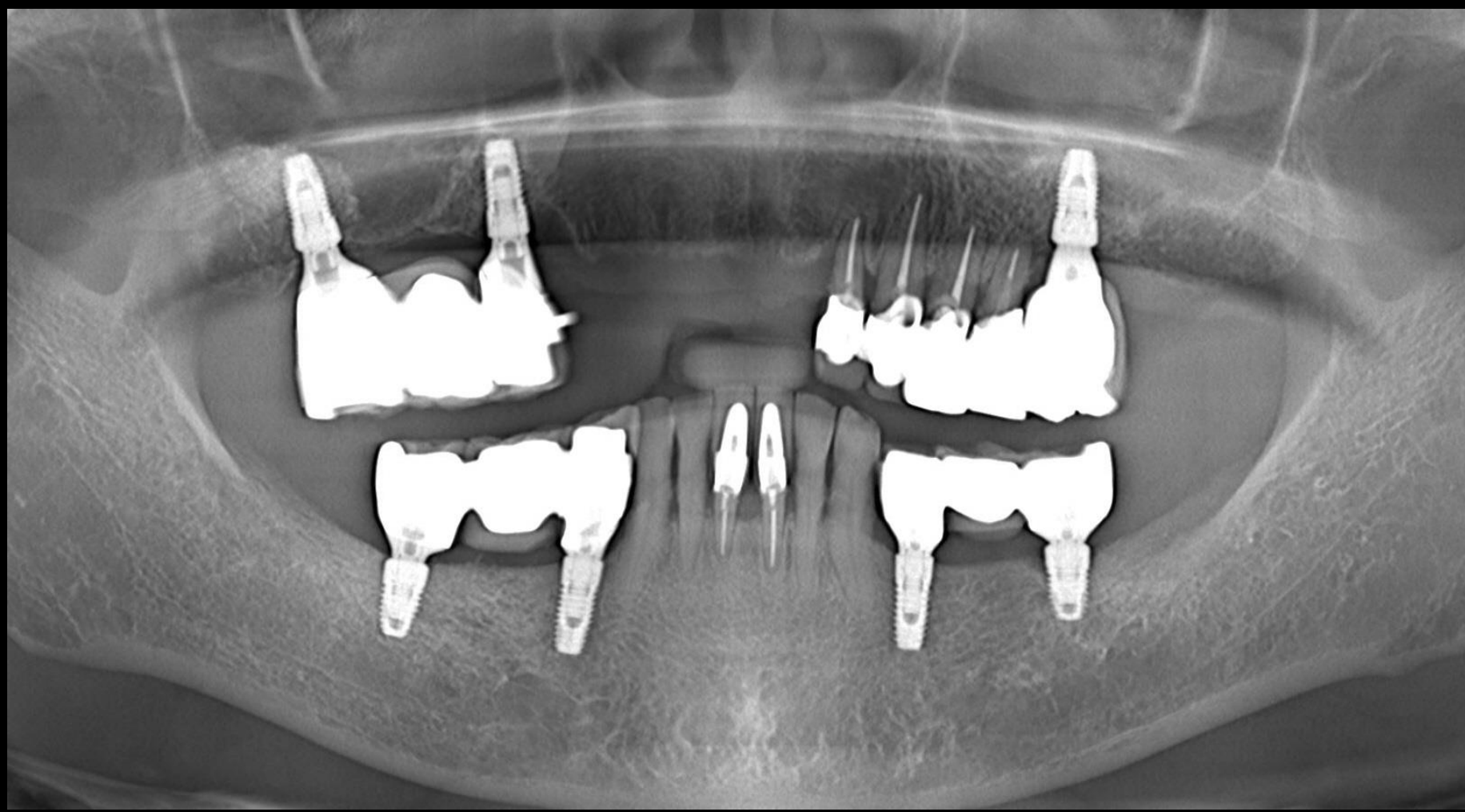
Pt. Lee (68y/F)

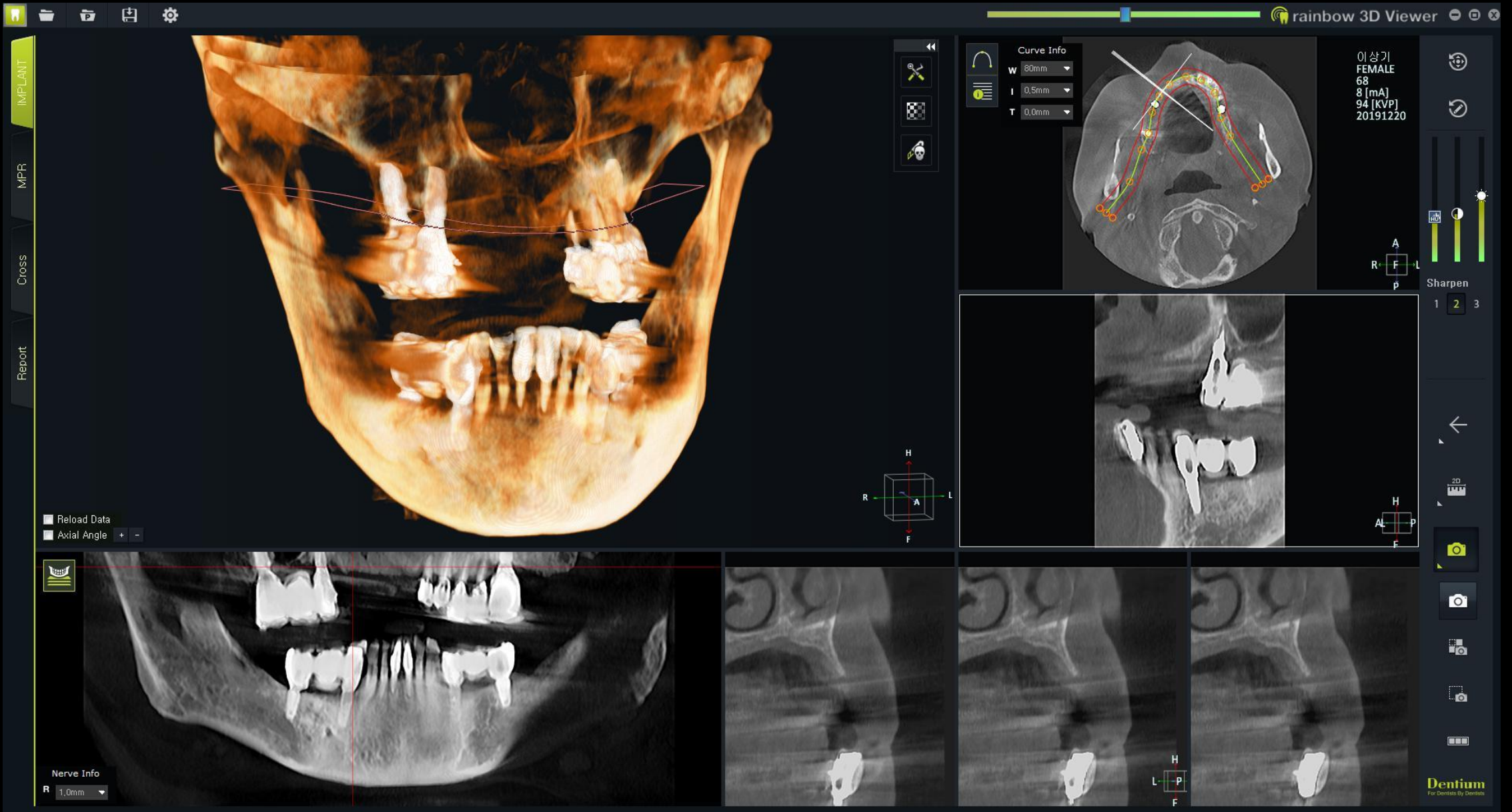
Oral exam (2019-08-21)

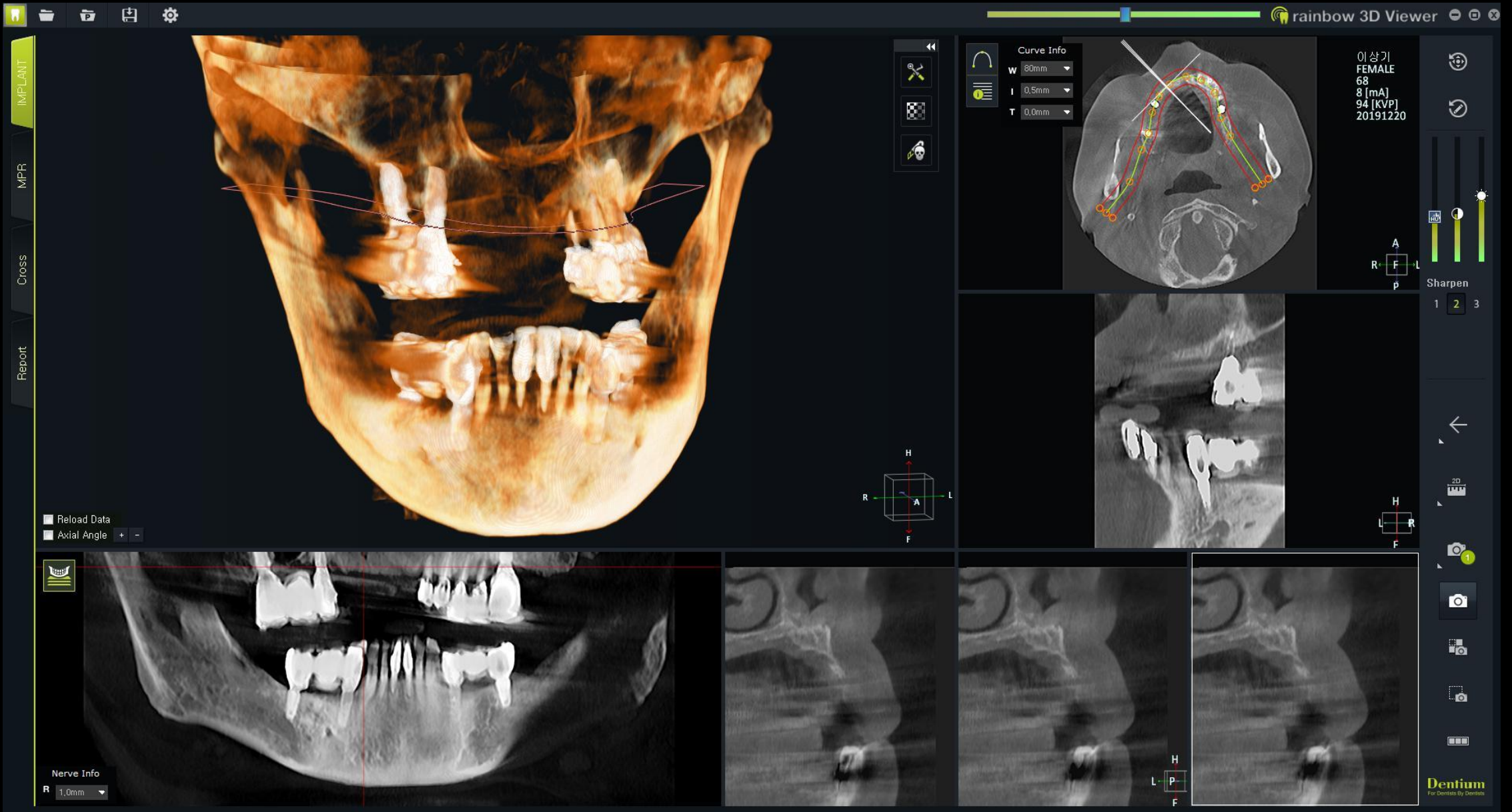


Pt. Lee (68y/F)

Pre-op (2019-11-21)







rainbow 3D Viewer

IMPLANT MPR Cross Report

Curve Info
W 80mm
I 0.5mm
T 0.0mm

이상기
FEMALE
68
8 [mA]
94 [KVP]
20191220

Reload Data
Axial Angle + -

Nerve Info
R 1.0mm

Sharpen 1 2 3

Dentium
For Dentists By Dentists

rainbow 3D Viewer

IMPLANT MPR Cross Report

Curve Info
W 80mm
I 0.5mm
T 0.0mm

이상기
FEMALE
68
8 [mA]
94 [KVP]
20191220

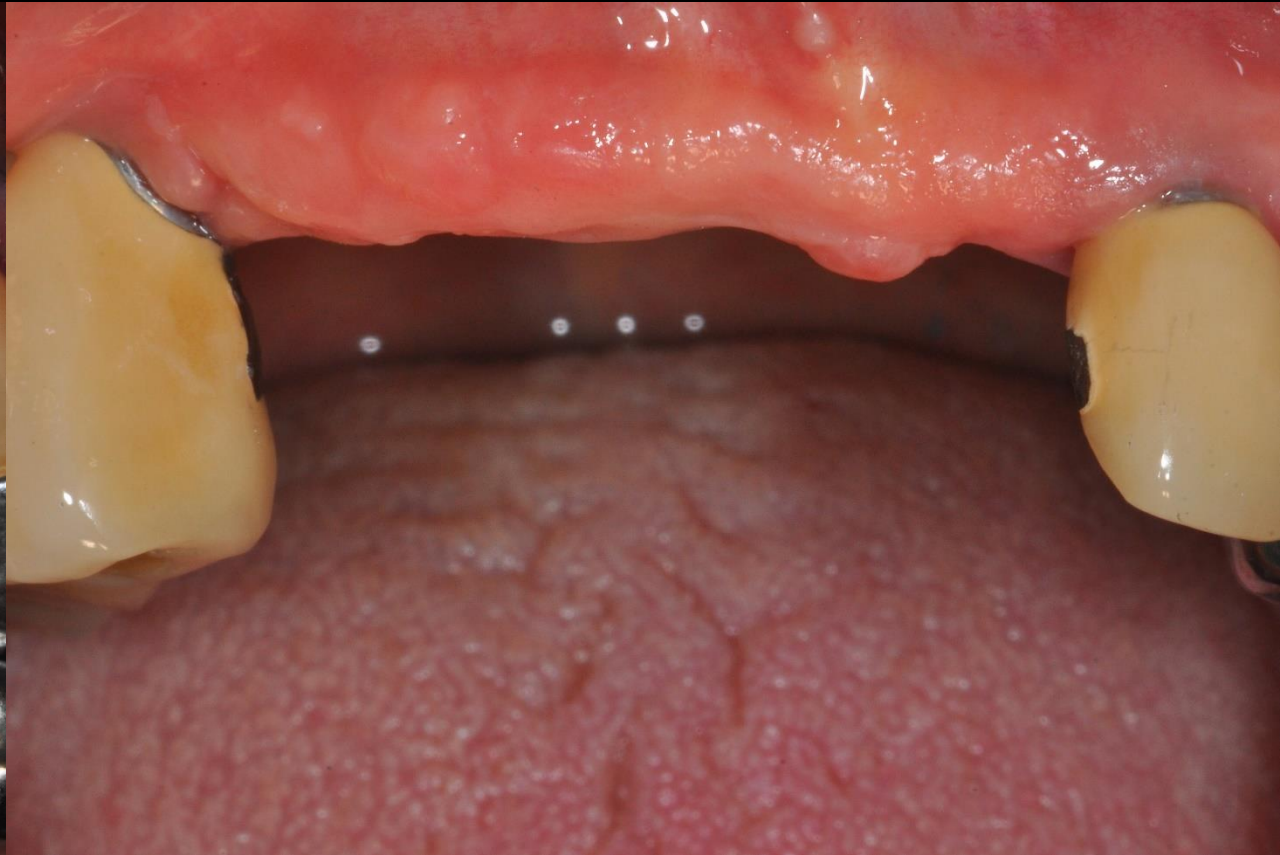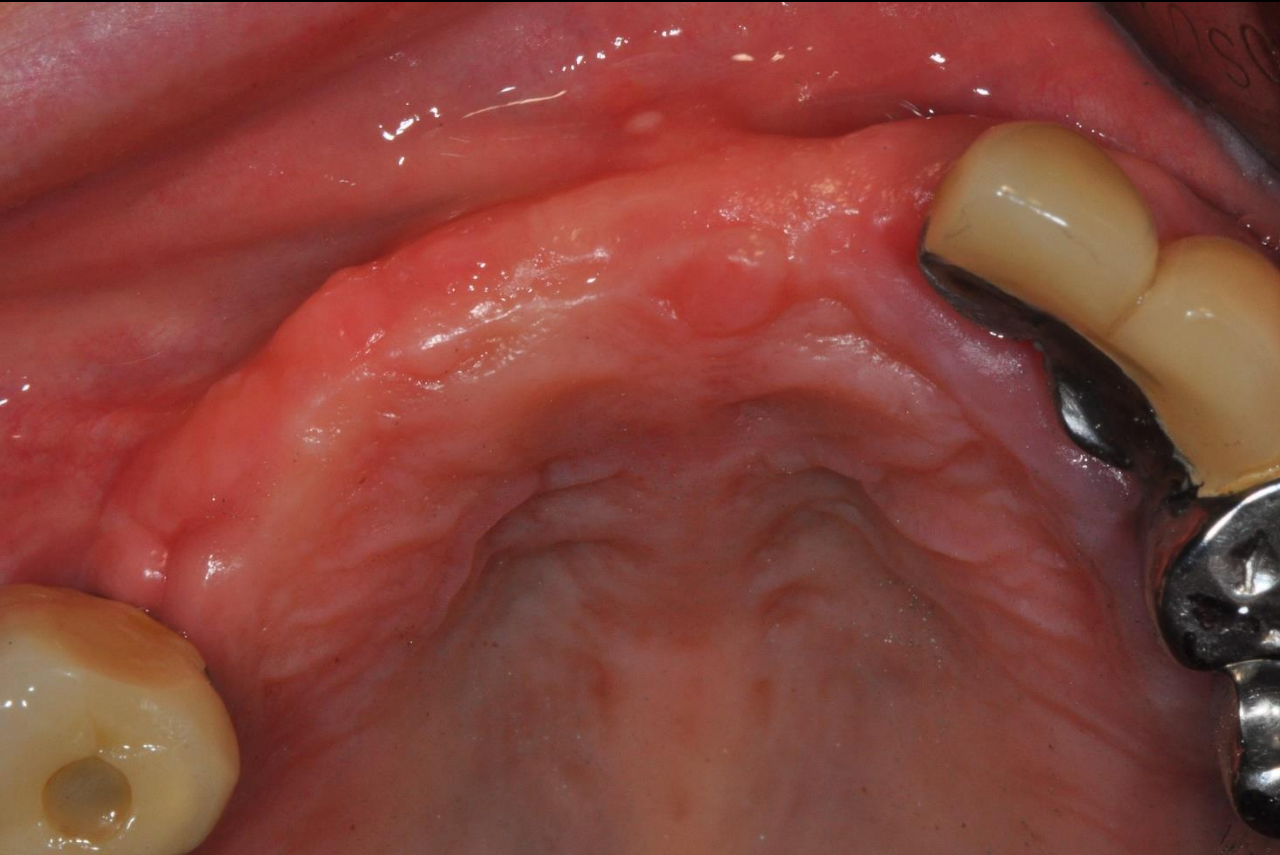
Reload Data
Axial Angle + -

Nerve Info
R 1.0mm

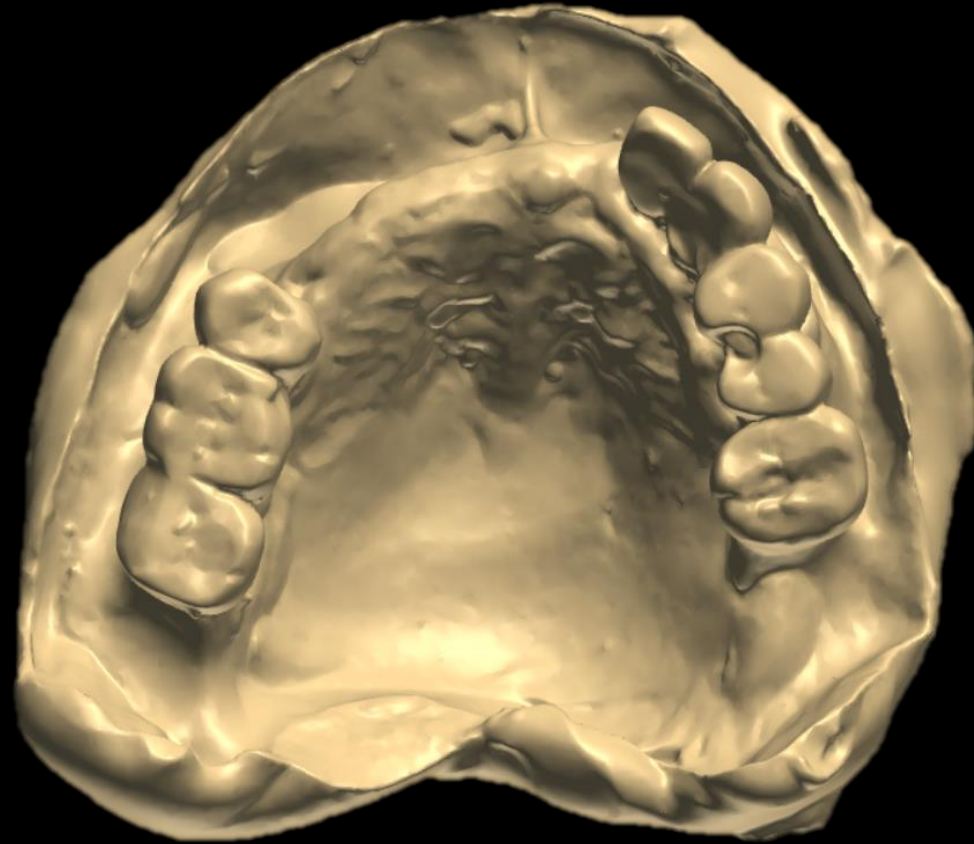
Sharpen 1 2 3

Dentium
For Dentists By Dentists

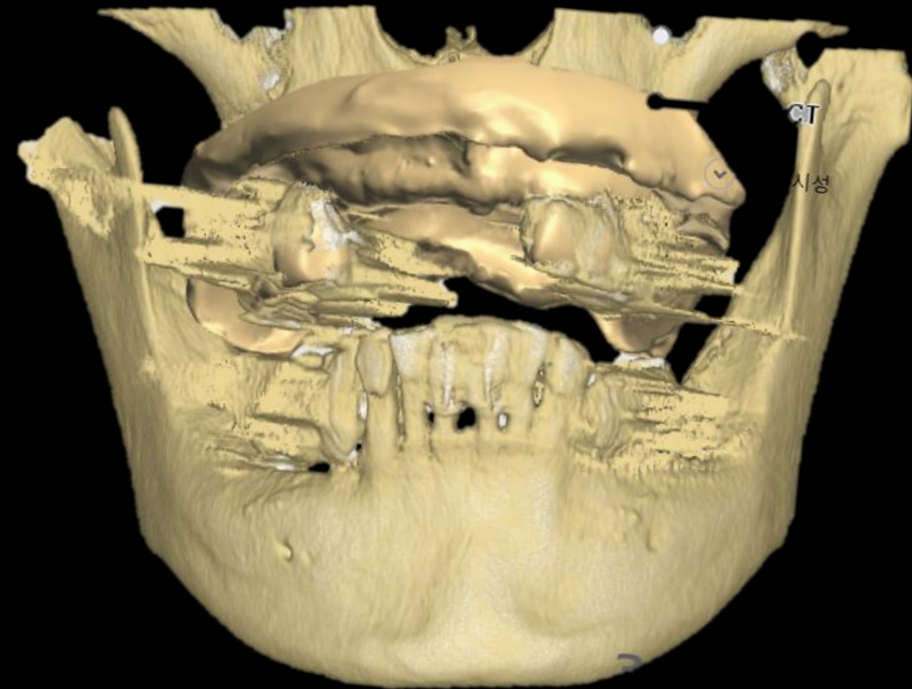
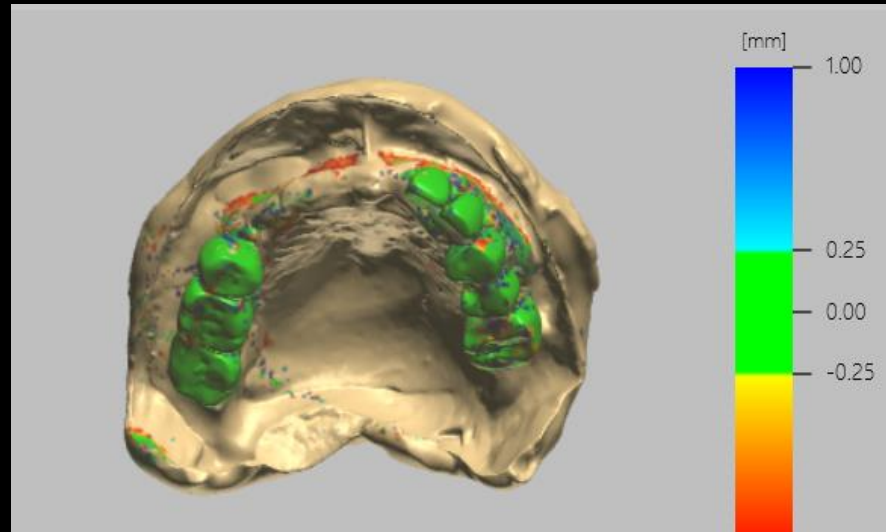
Photo



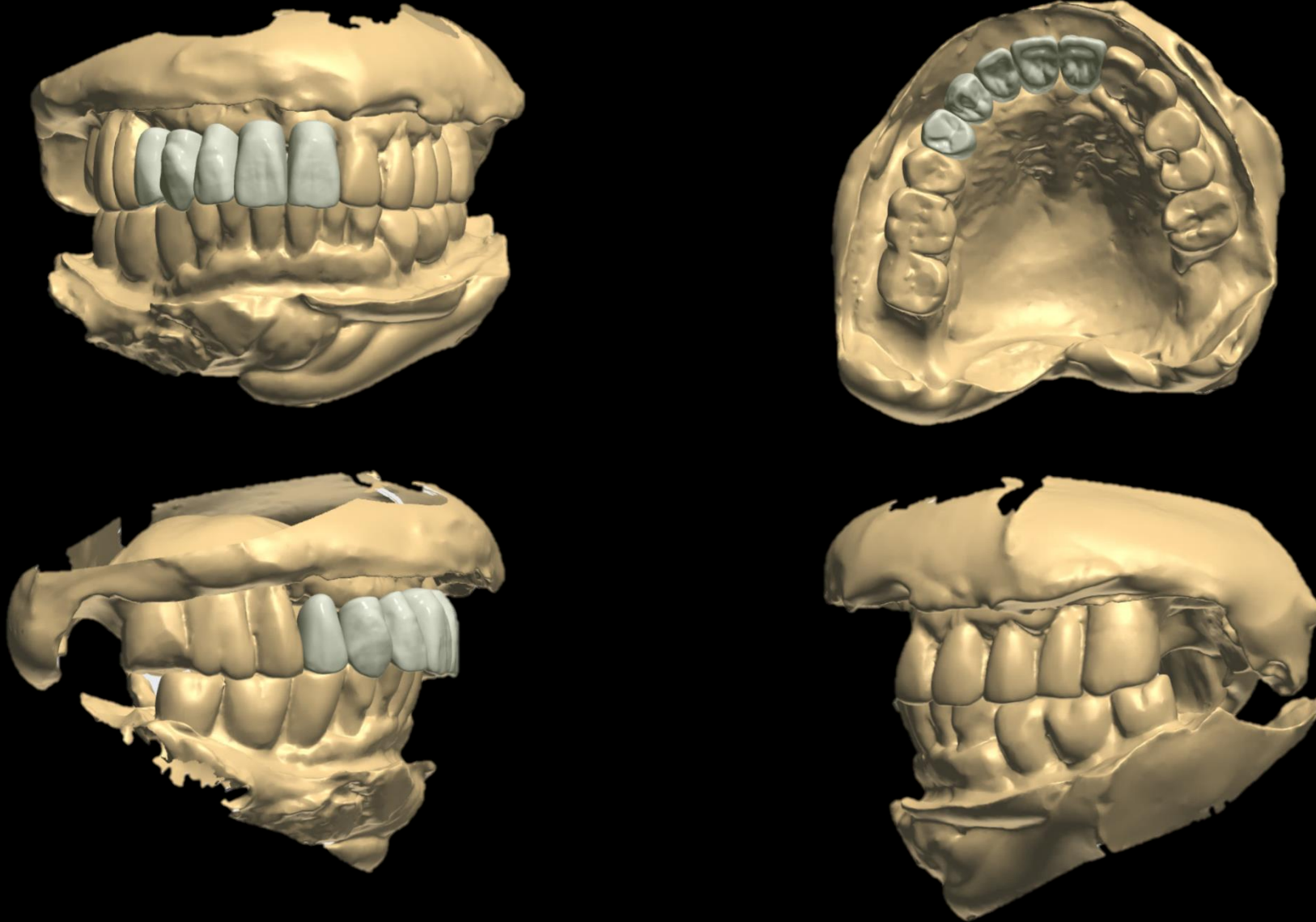
Digital Guide (Model Scanning)



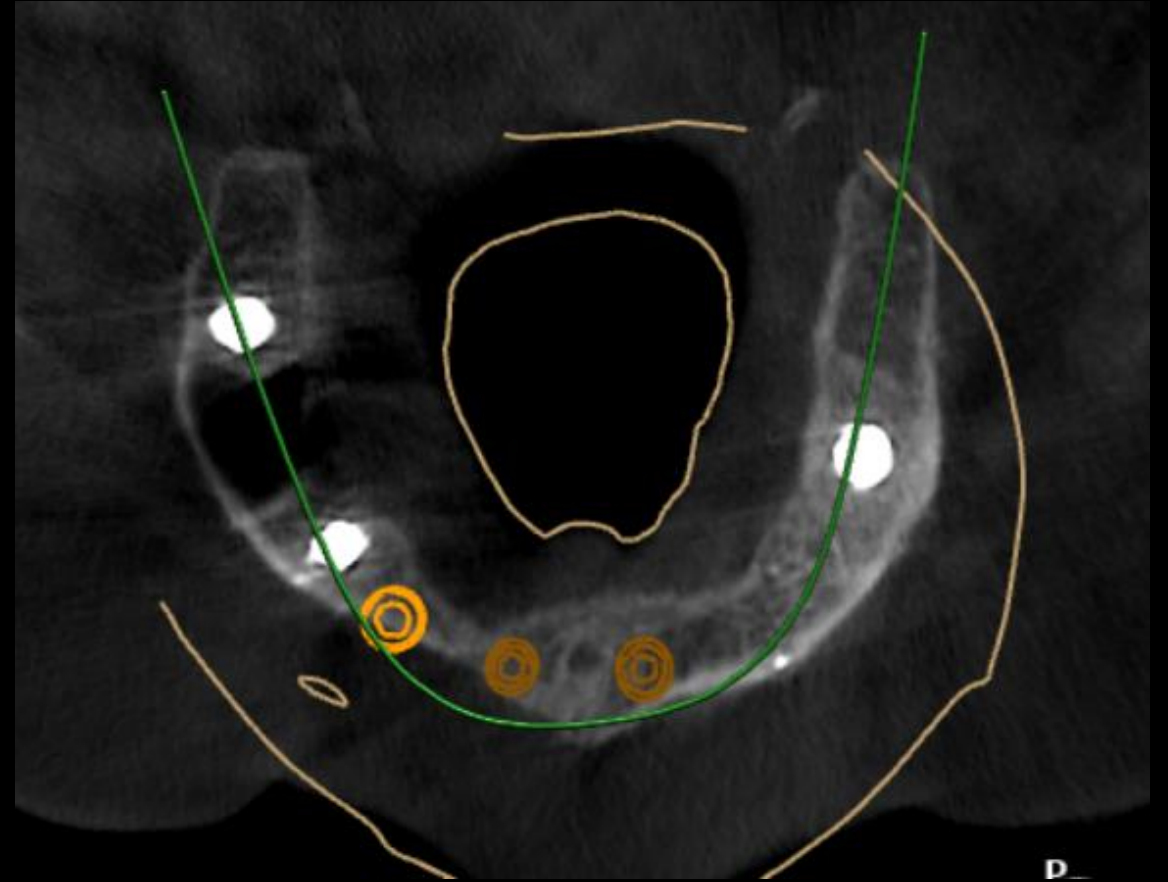
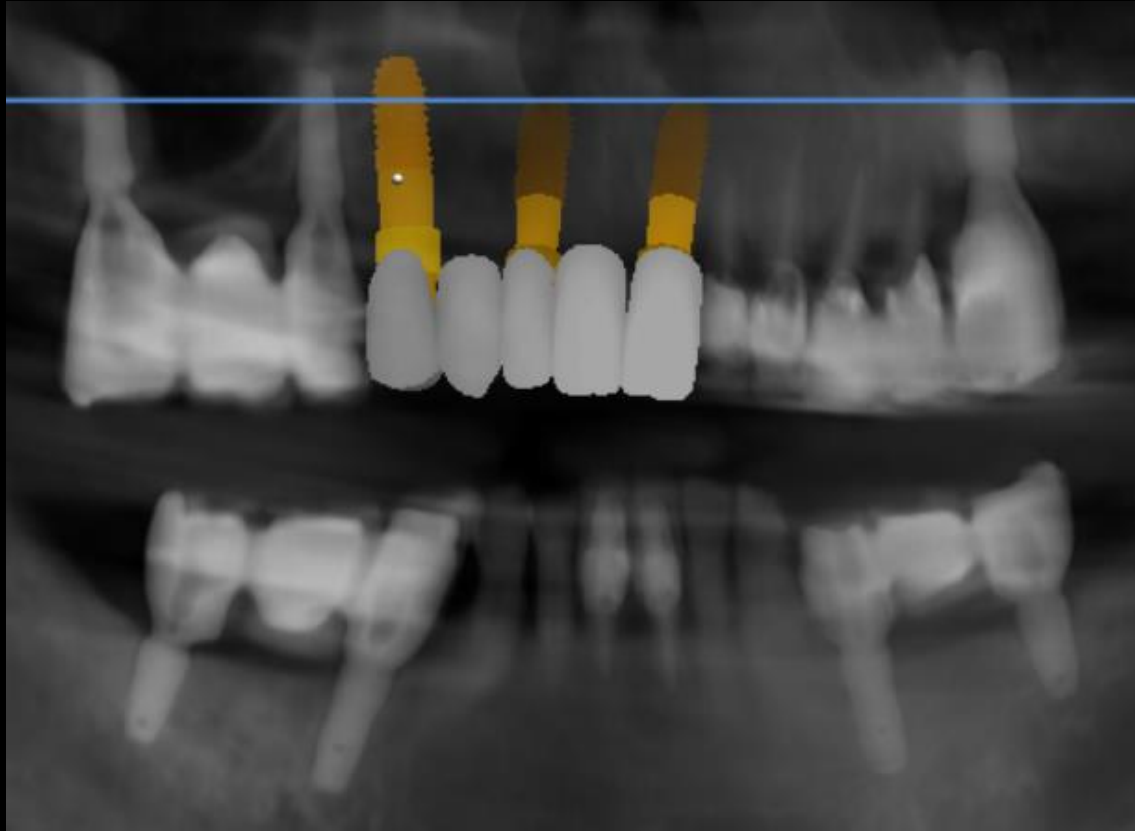Digital Guide (3 Point Merging)



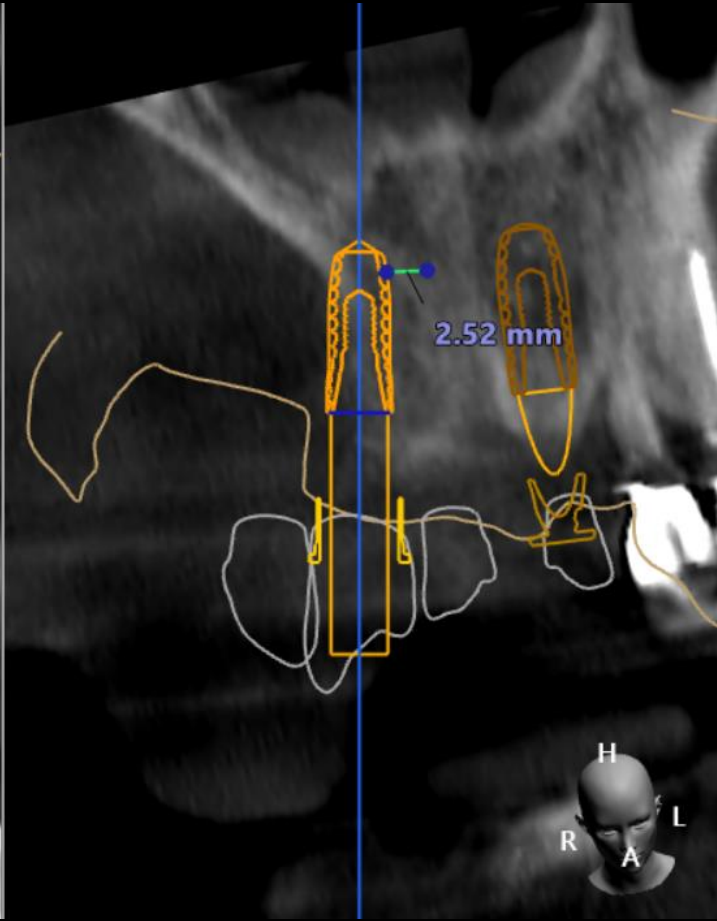
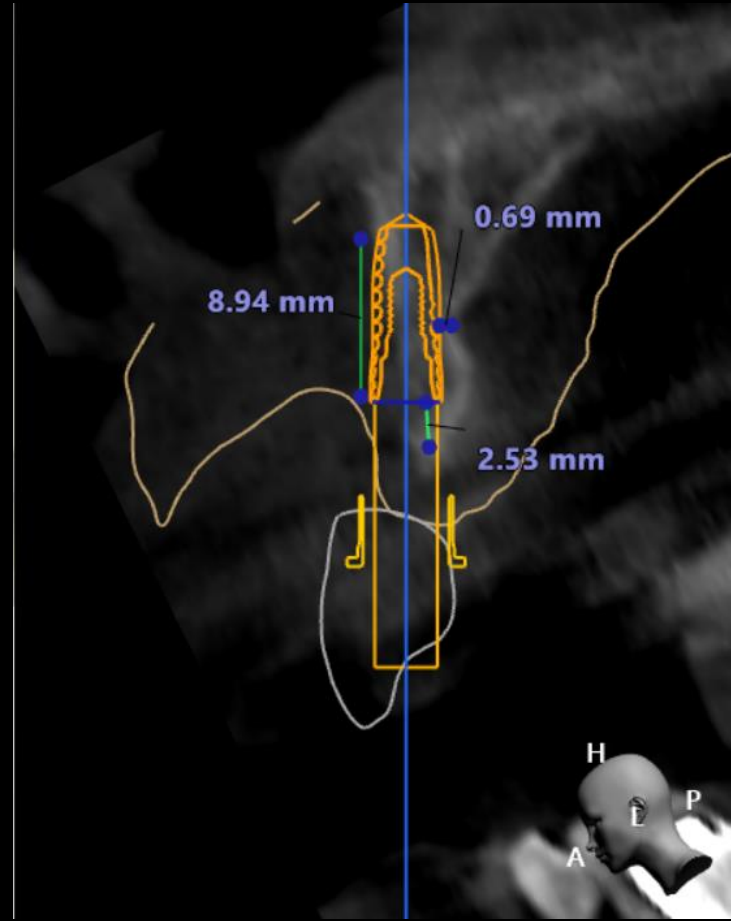
Digital Guide (Crown Design)



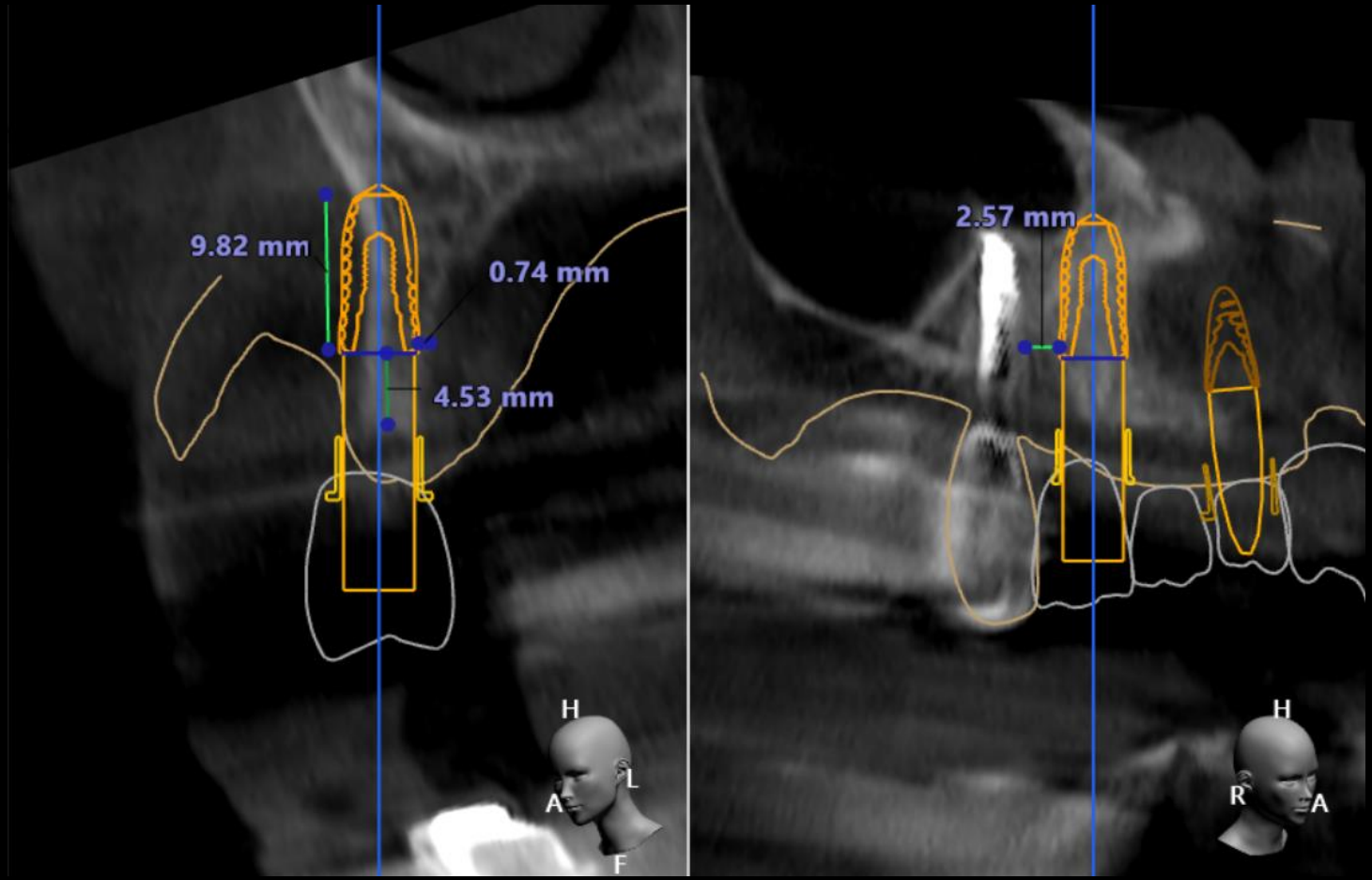
Digital Guide (Implant Planning)



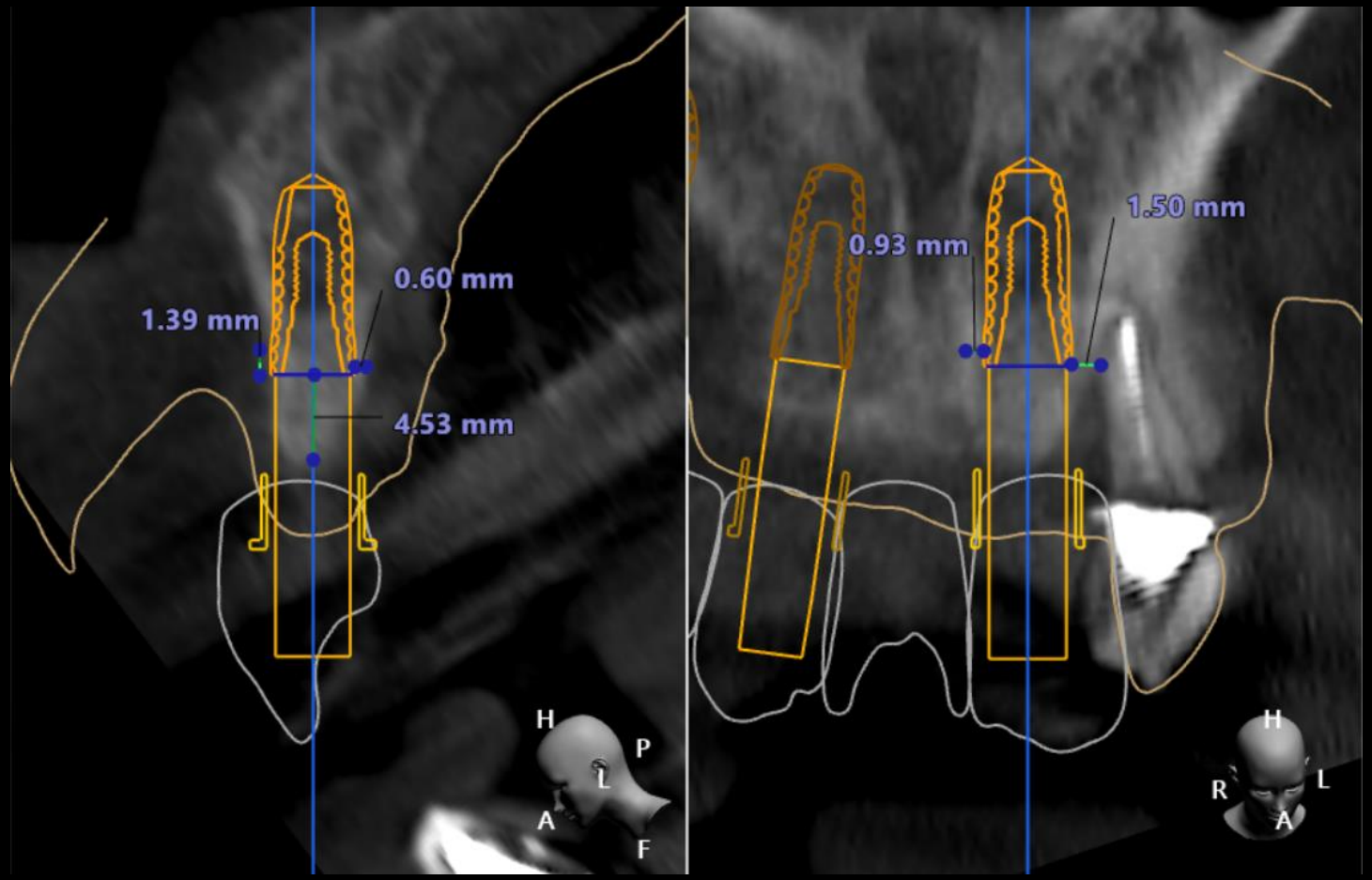
Digital Guide (#12 Implant Planning)



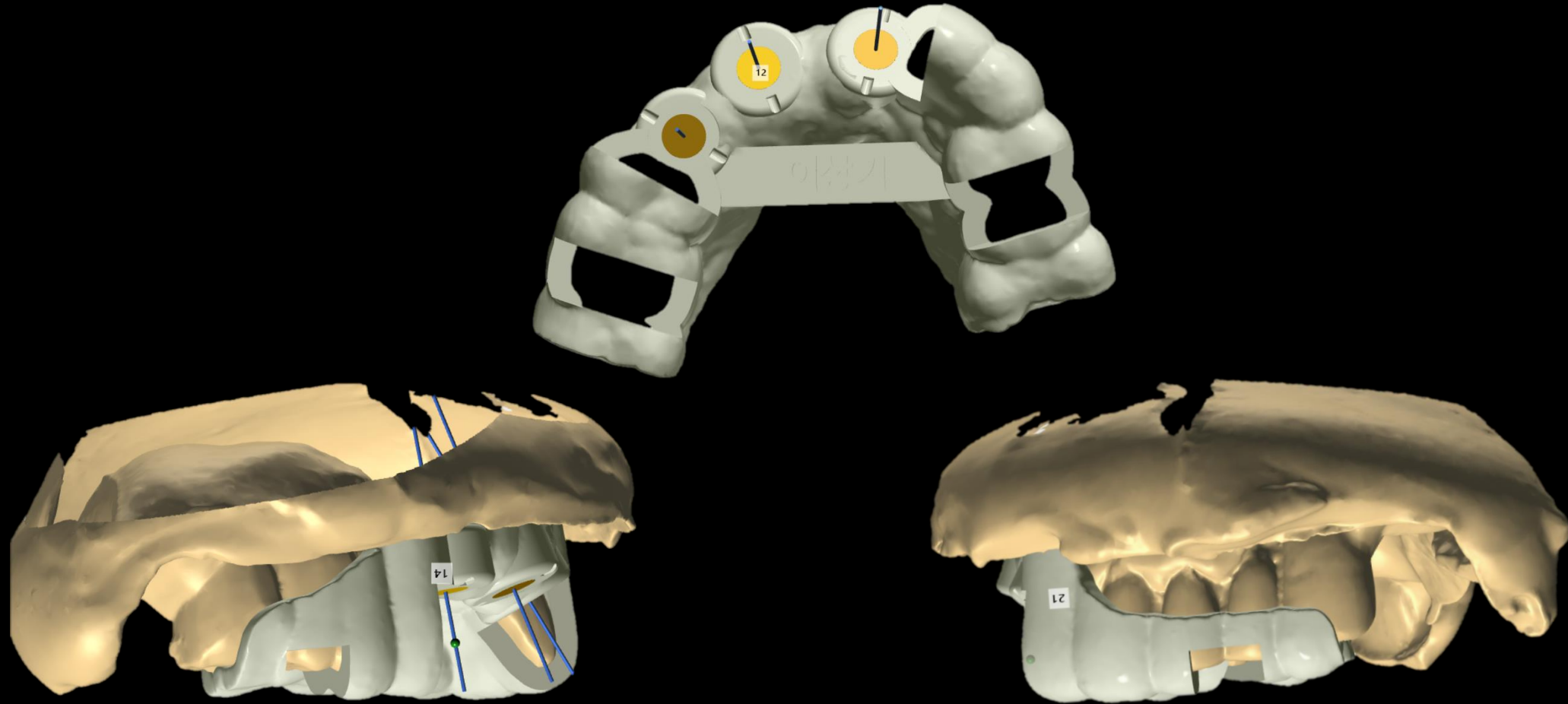
Digital Guide (#14 Implant Planning)



Digital Guide (#21 Implant Planning)

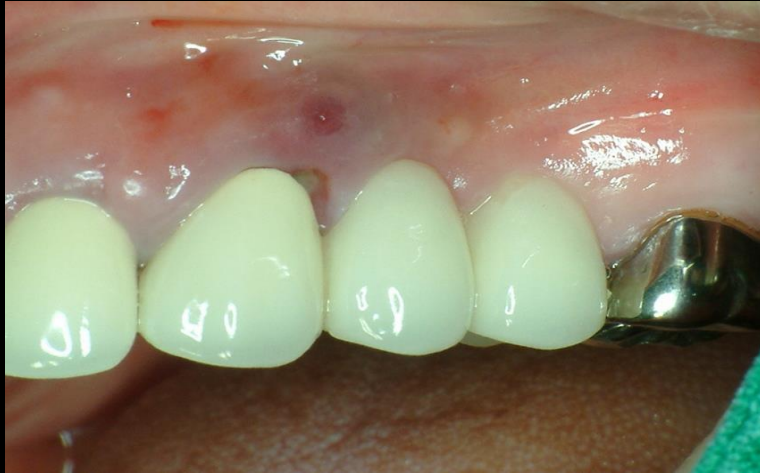

Digital Guide (Stent Design)

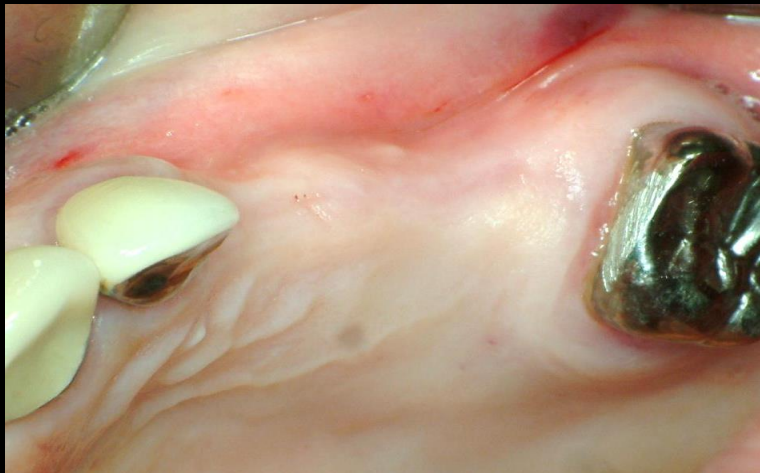
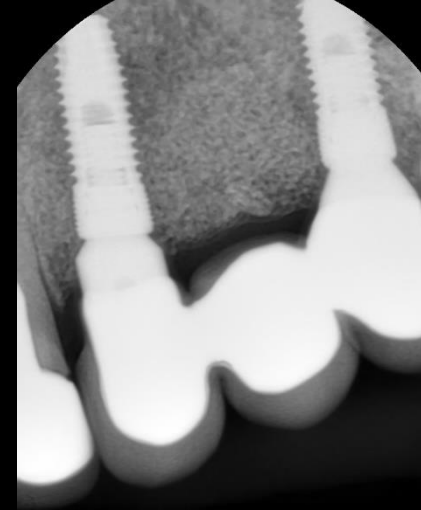


Similar case presentation (1)

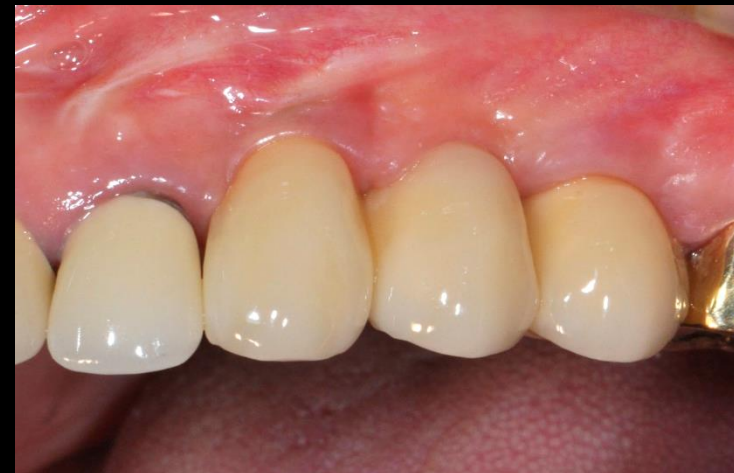- Ridge Splitting & GBR



Oral exam

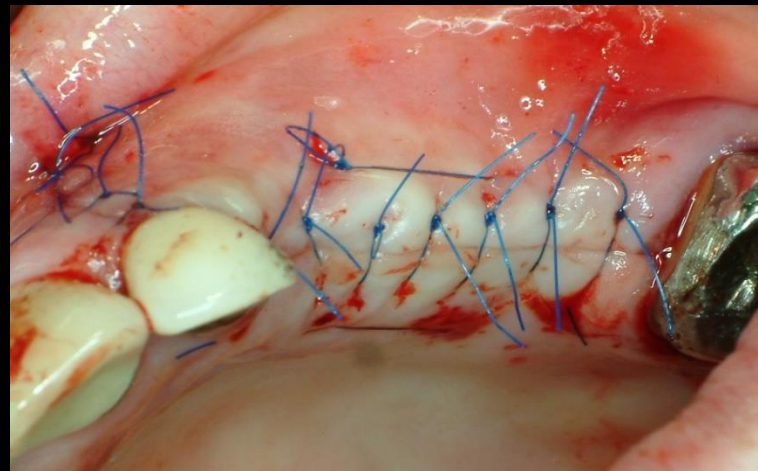
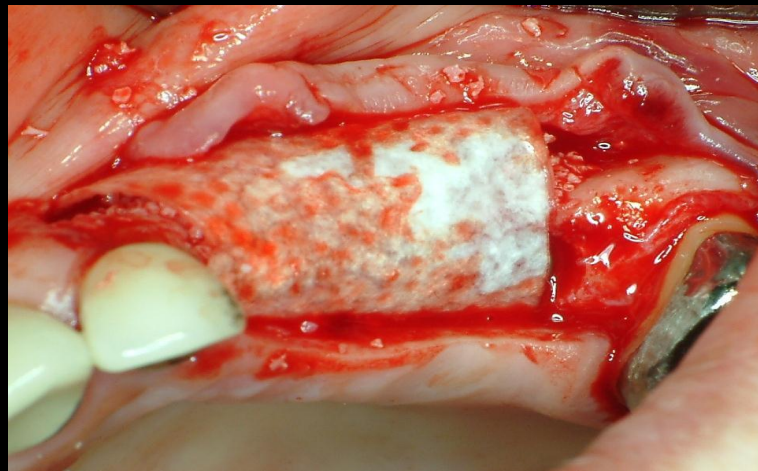
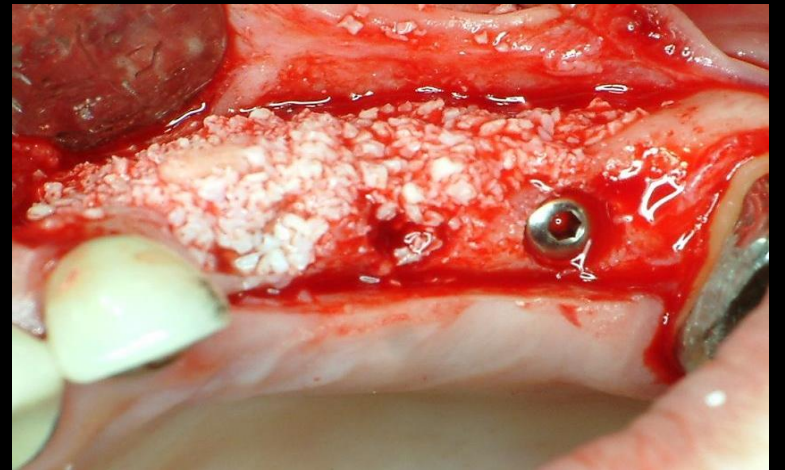
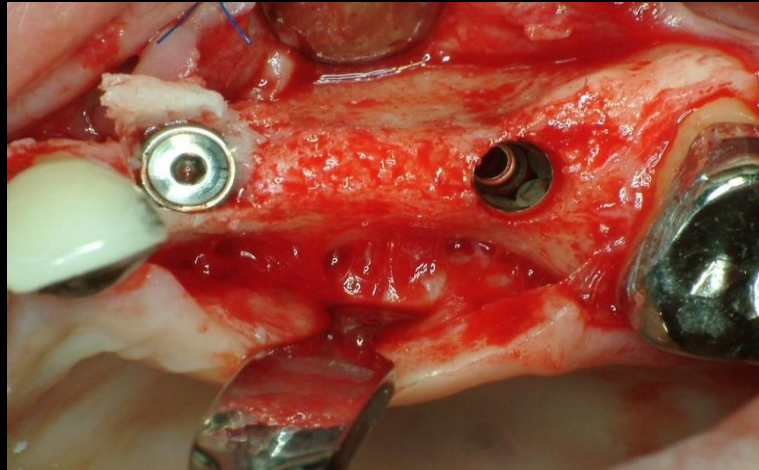
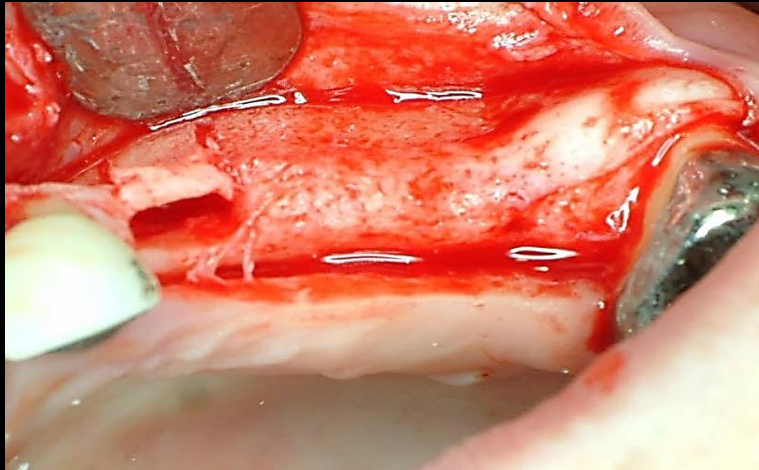


Pre-op



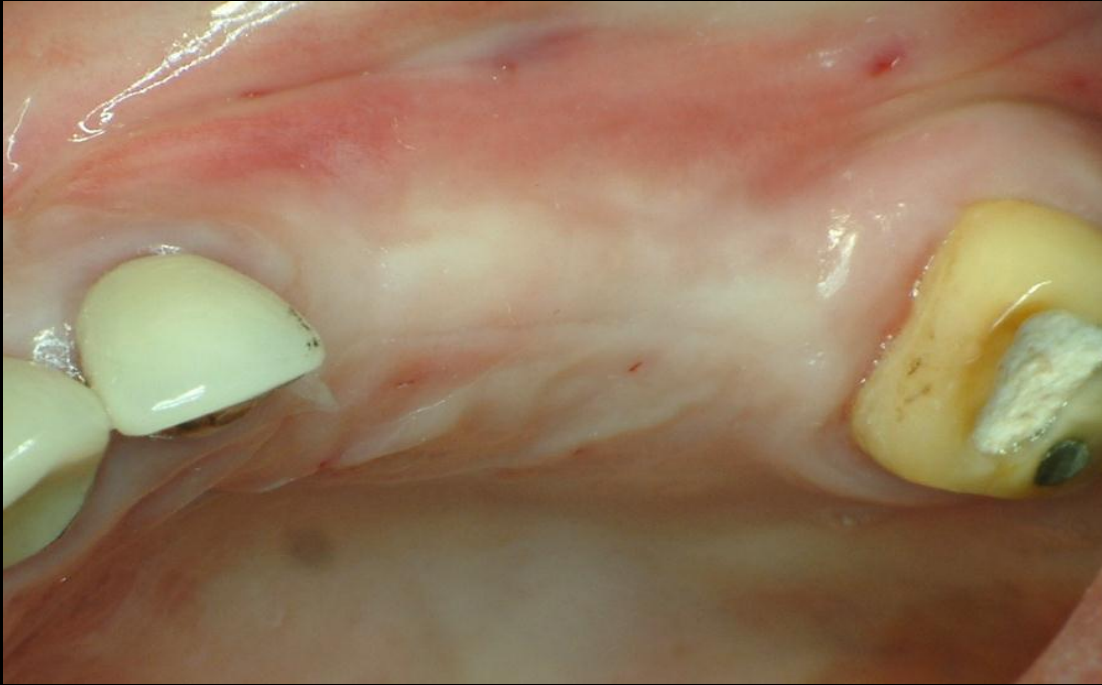
Final prosthesis

Similar case presentation (1) - Ridge Splitting & GBR

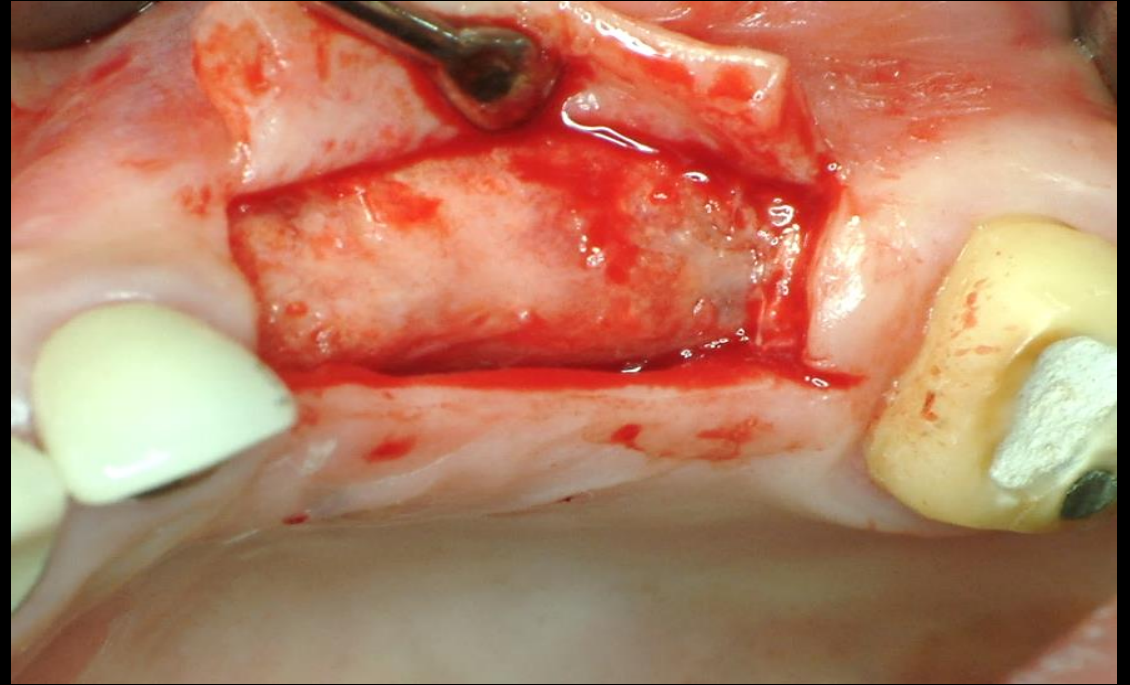


Similar case presentation (1)

- Ridge Splitting & GBR

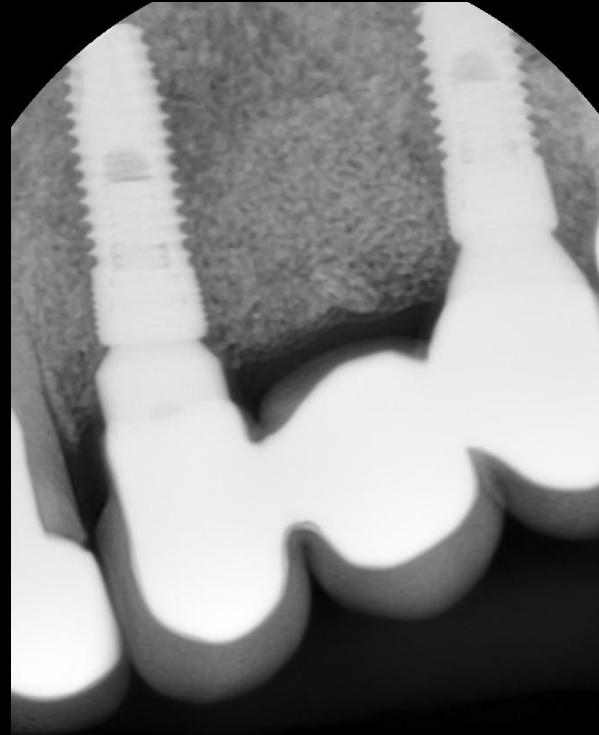
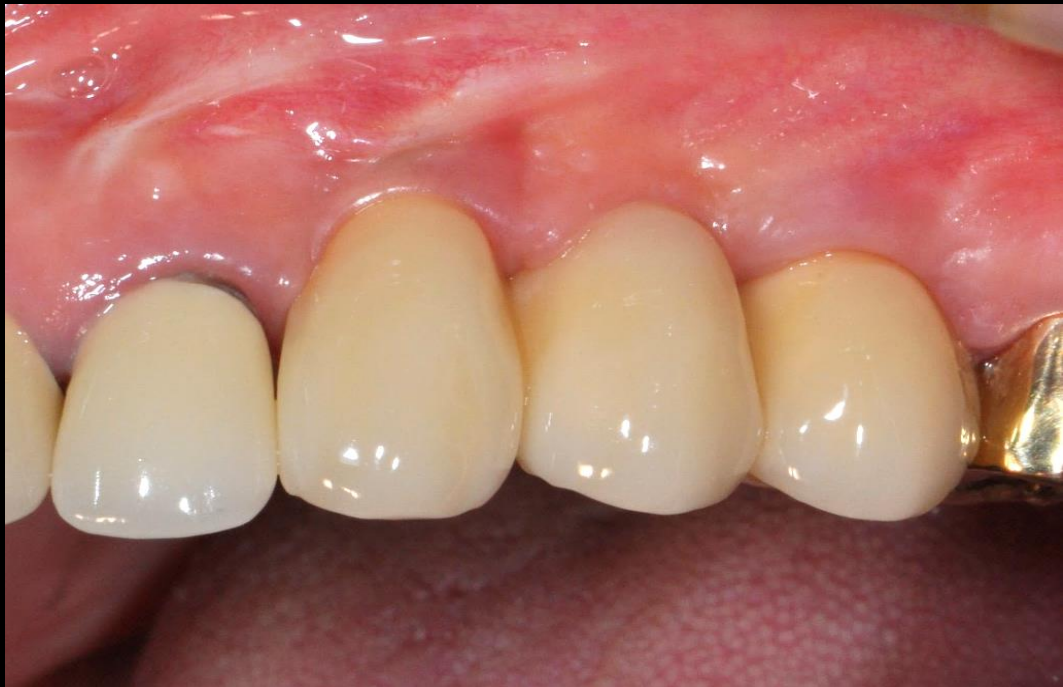
Healing



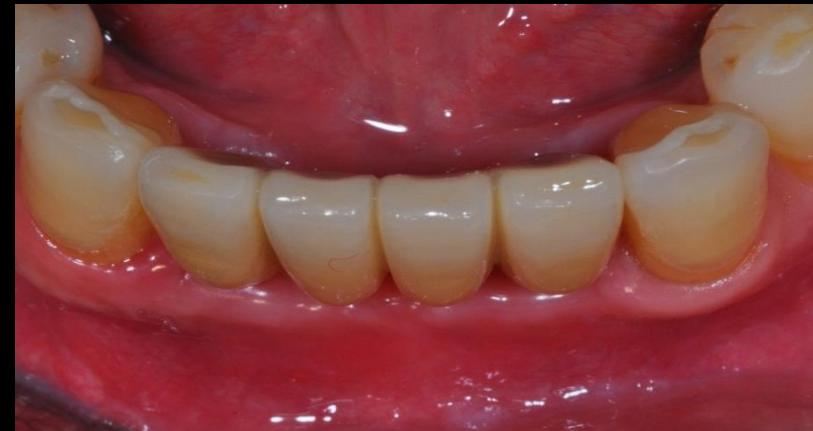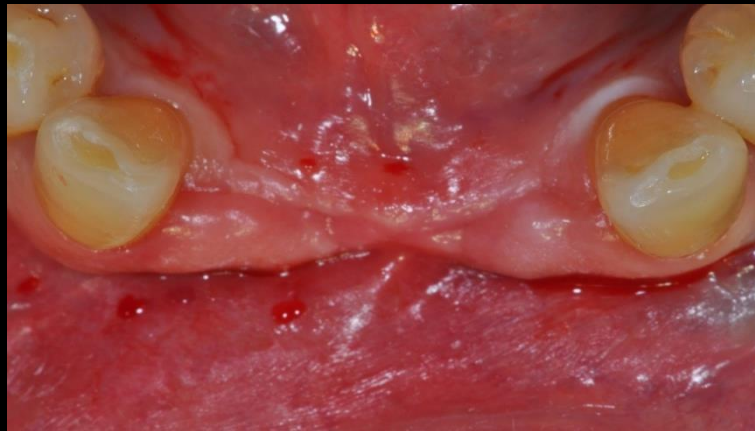
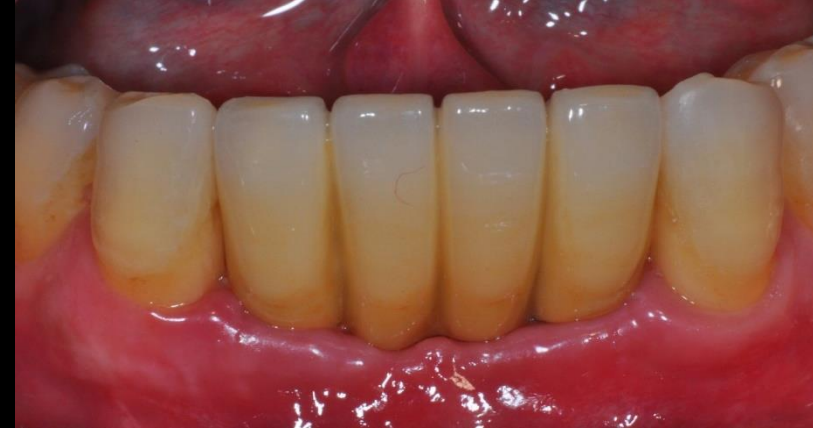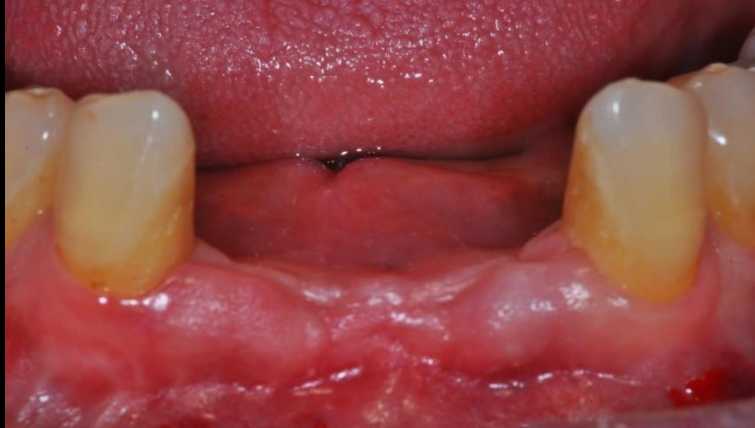Second Stage Surgery

Similar case presentation (1) - Ridge Splitting & GBR



Final Prosthesis

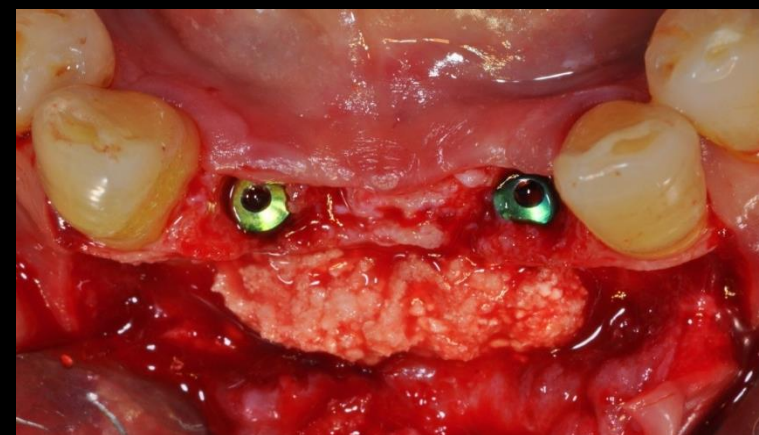
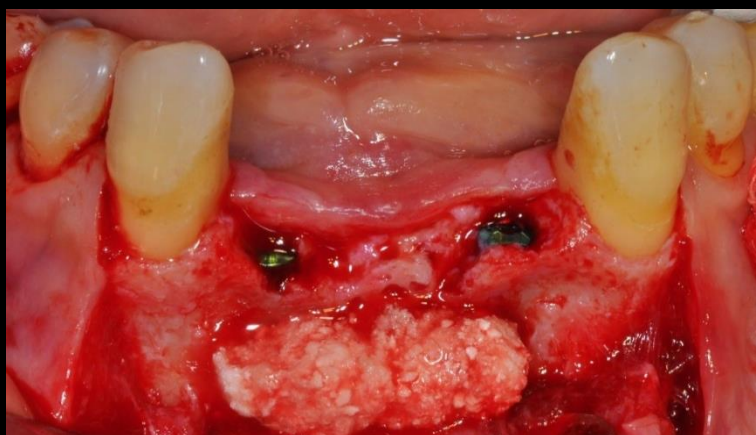
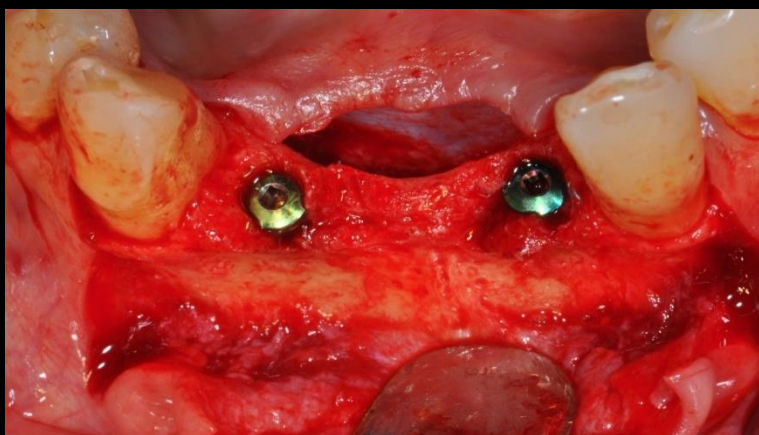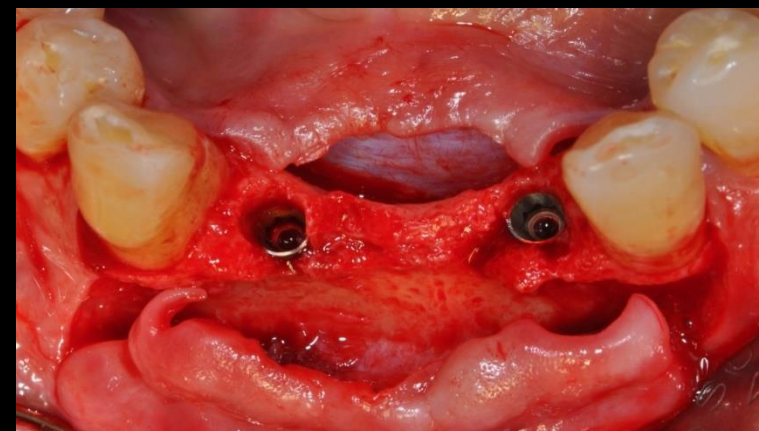
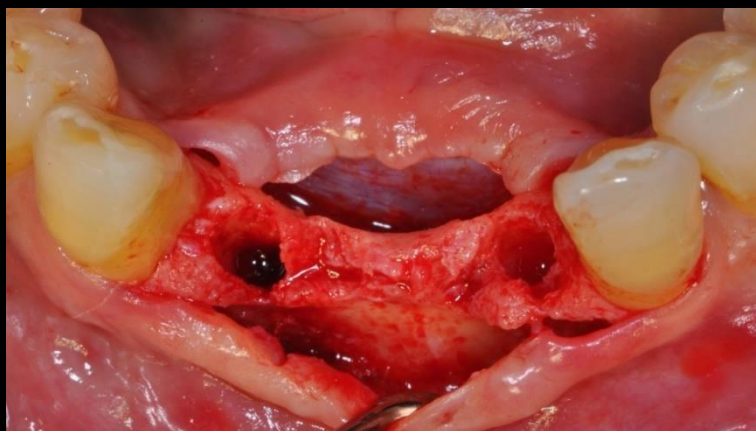
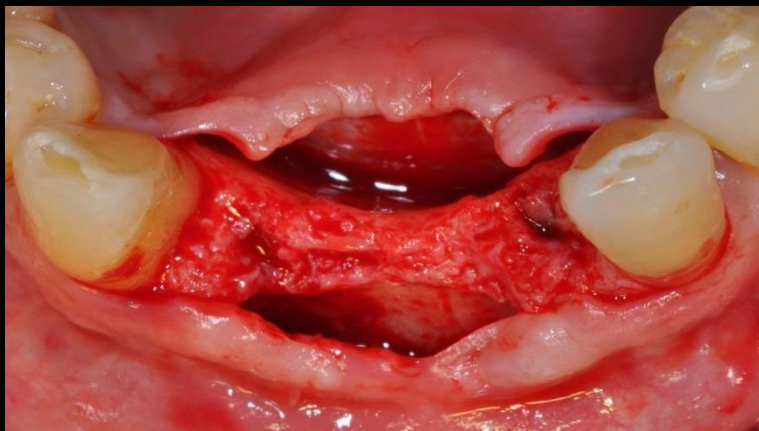
Similar case presentation (2) - DUK Technique



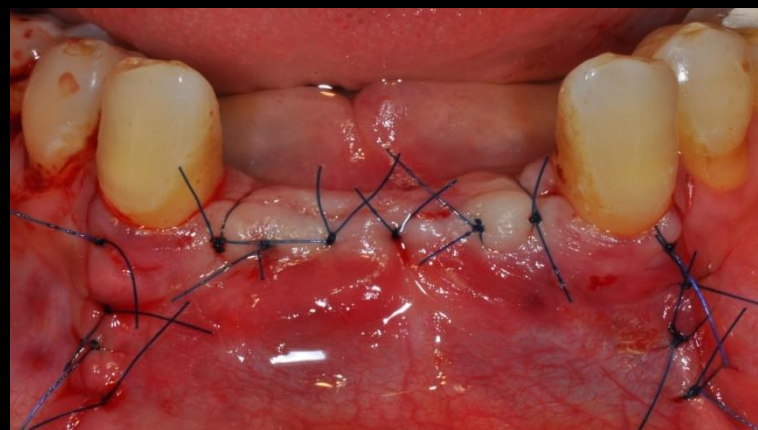
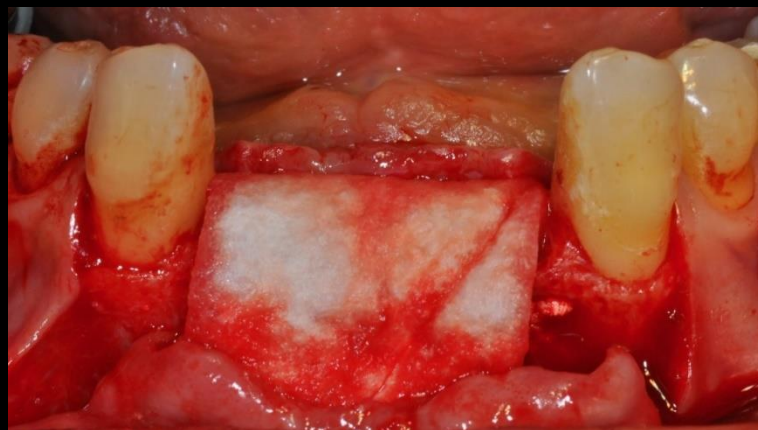
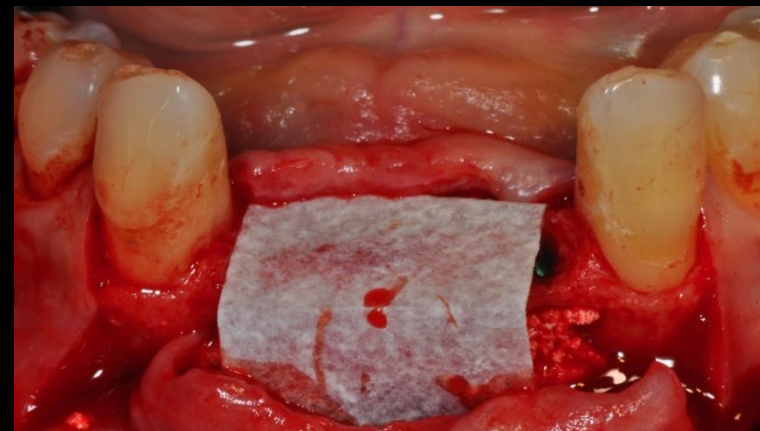
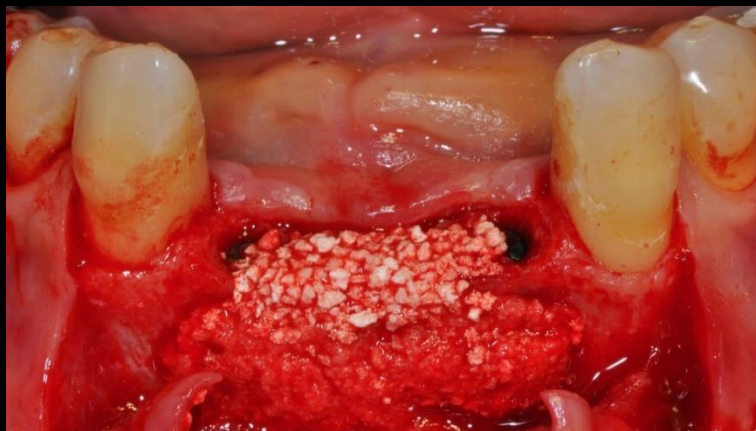
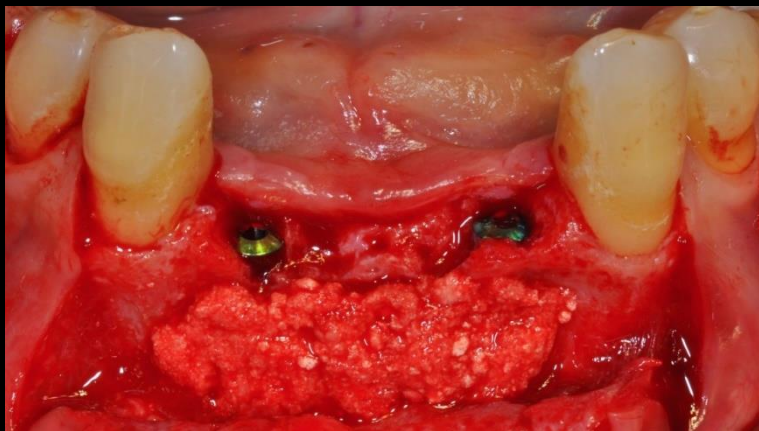
Pre-op

Final prosthesis

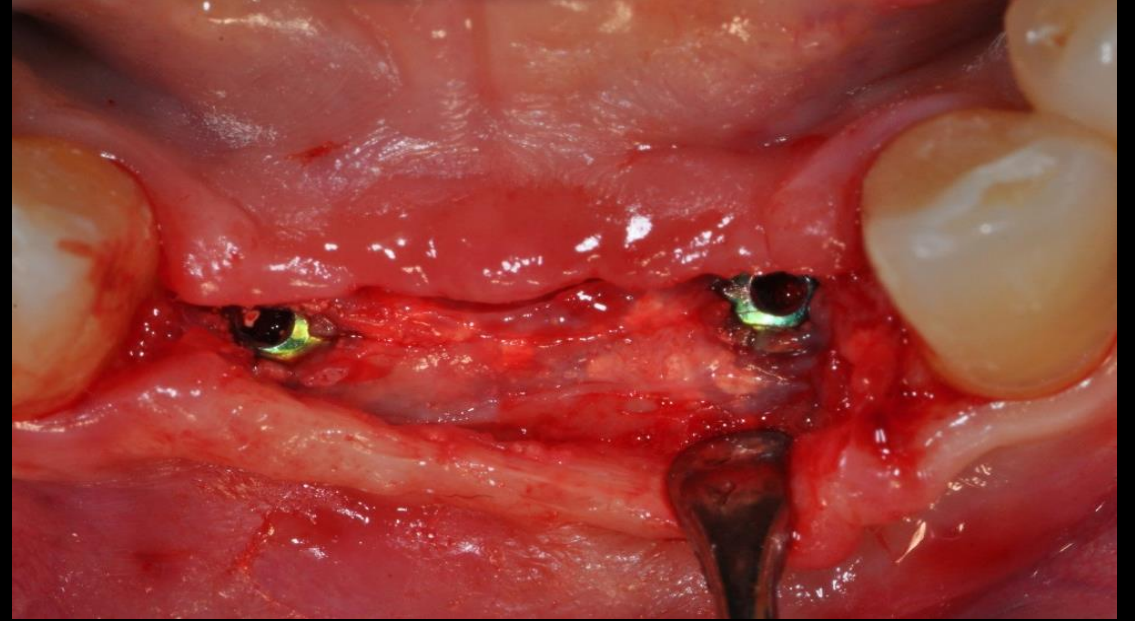
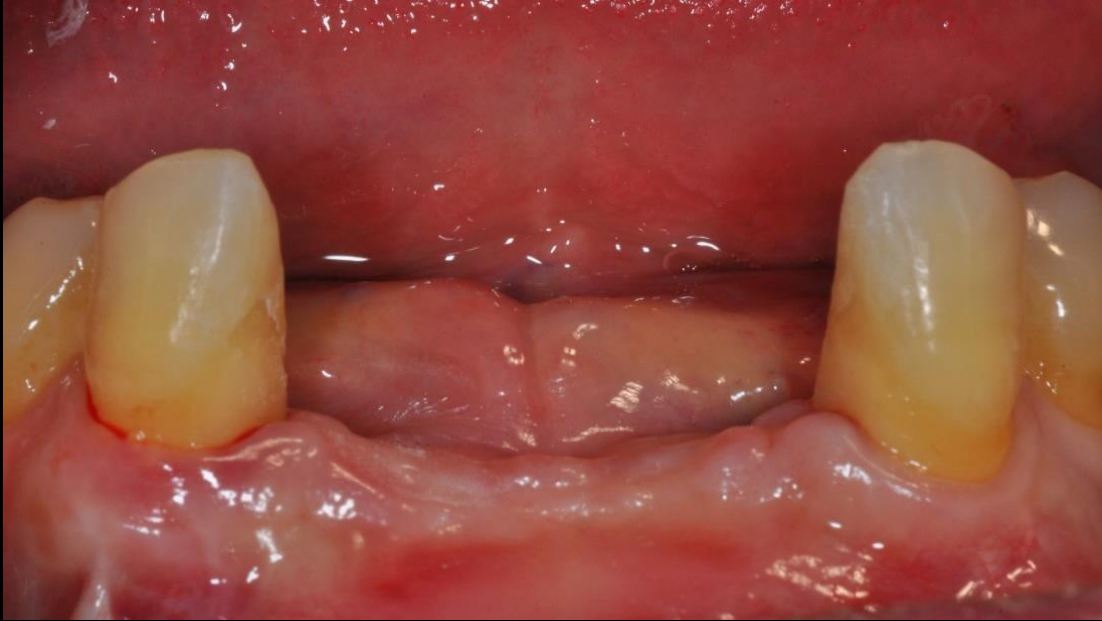Similar case presentation (2) - DUK Technique



Similar case presentation (2) - DUK Technique

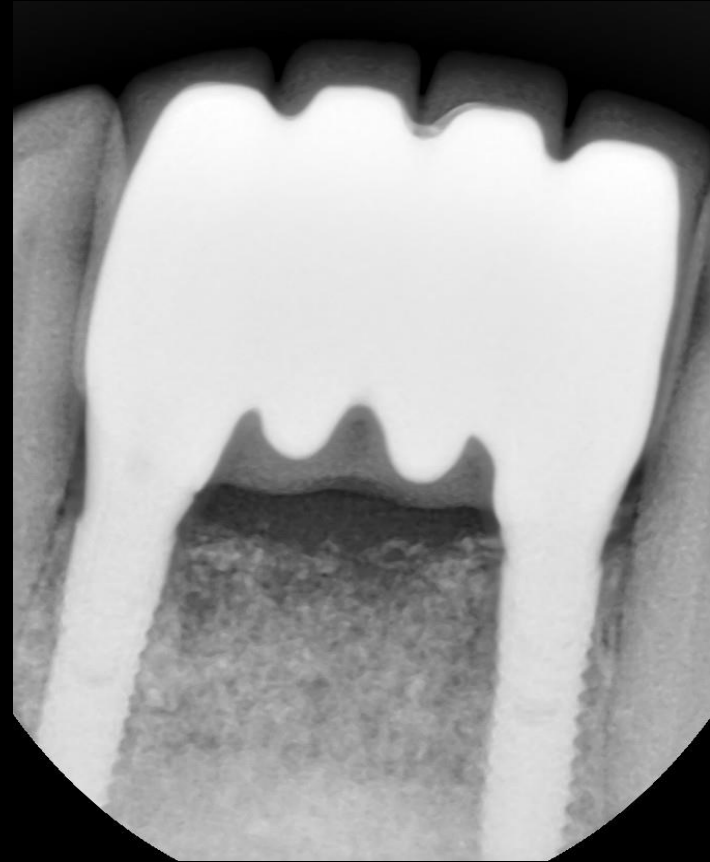
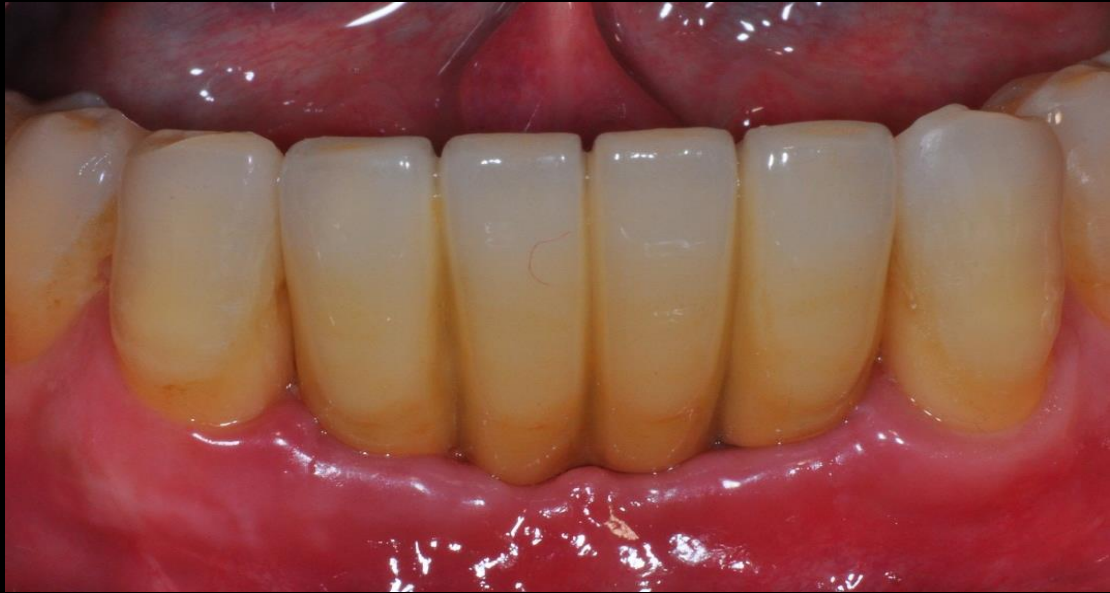
Similar case presentation (2) - DUK Technique



Second Stage Surgery

Similar case presentation (2) - DUK Technique



Final Prosthesis