



LIVE

Surgey

Dr. Dong-Wook Chang

2021.02.19 (FRI.)



[Case Preview]

Digital Guide Implant placement with Sinus elevation

Patient Information

Age : 66

Sex : Female

Chief Complaint :

I want to recover my missing teeth

Past Dental History

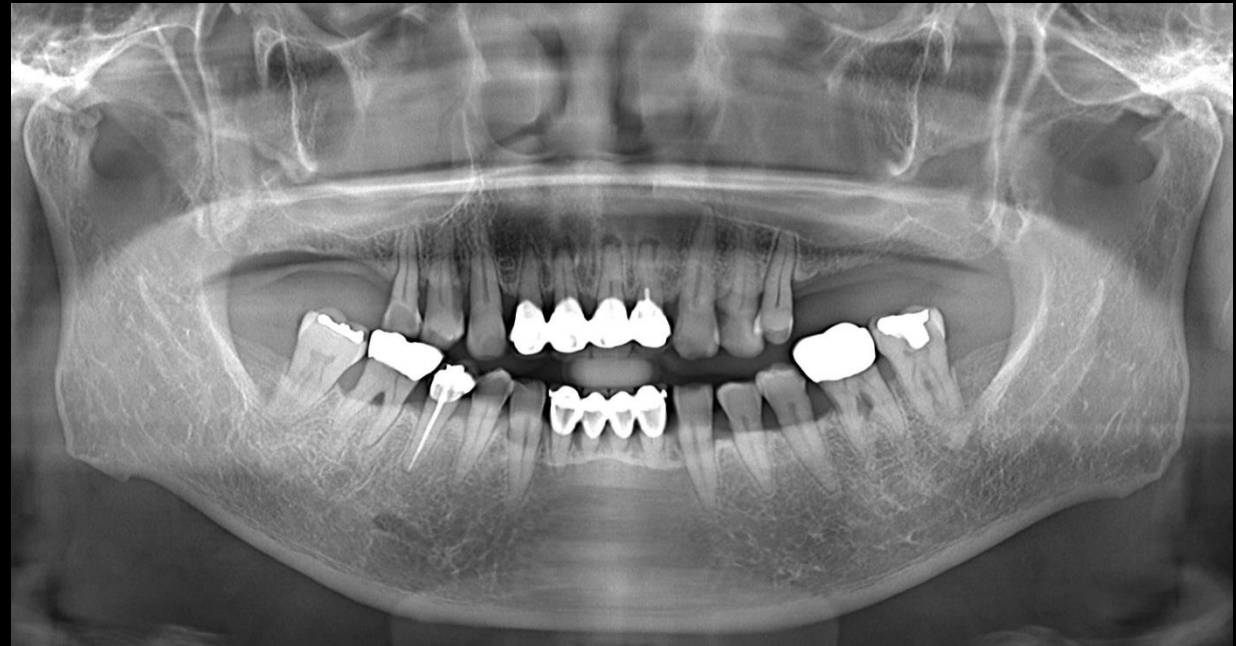
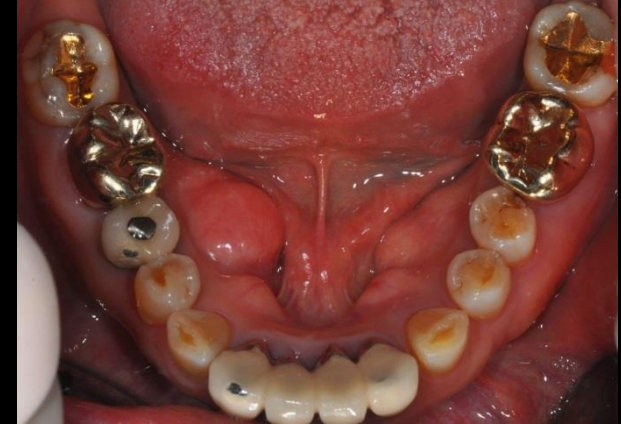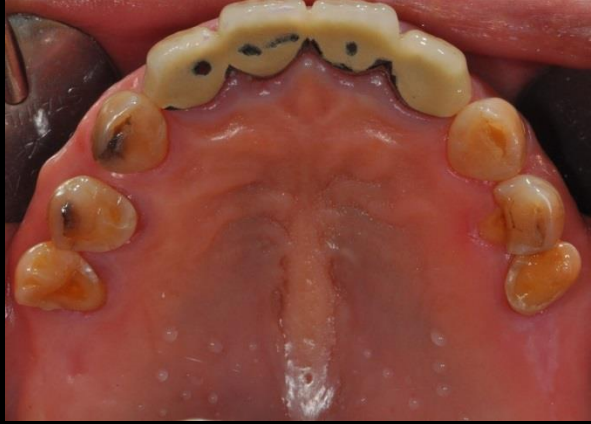N/S

Present illness

periapical lesion on #11,21,22

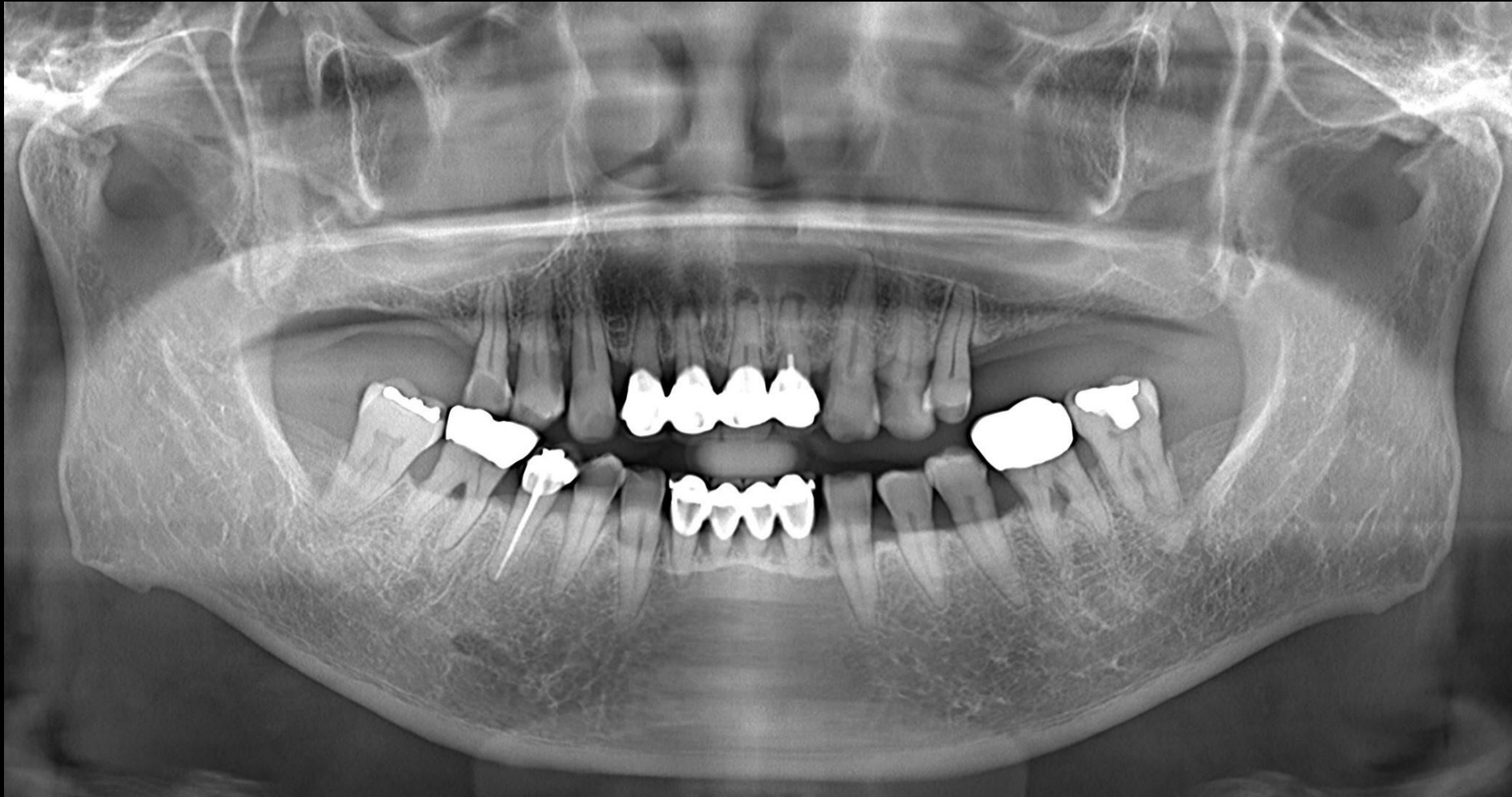Today's Surgery Plan

- # 10 Sinus elevation
(lateral approach)
- #16, 17 Implant placement
with Digital Guide Stent
- Provisional Restoration



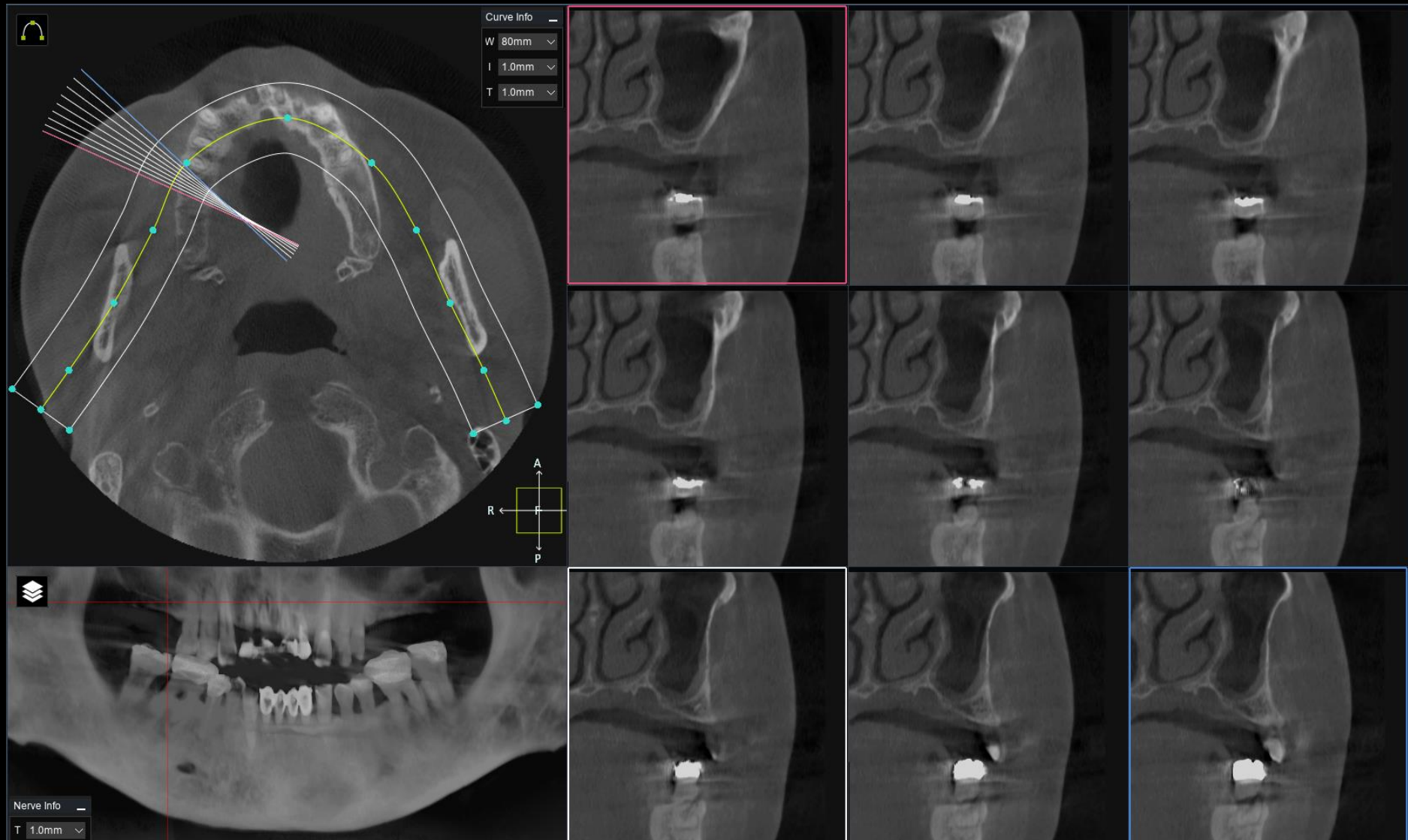
Pt. Kim (66/Female)

Pre-op(2021-01-20)



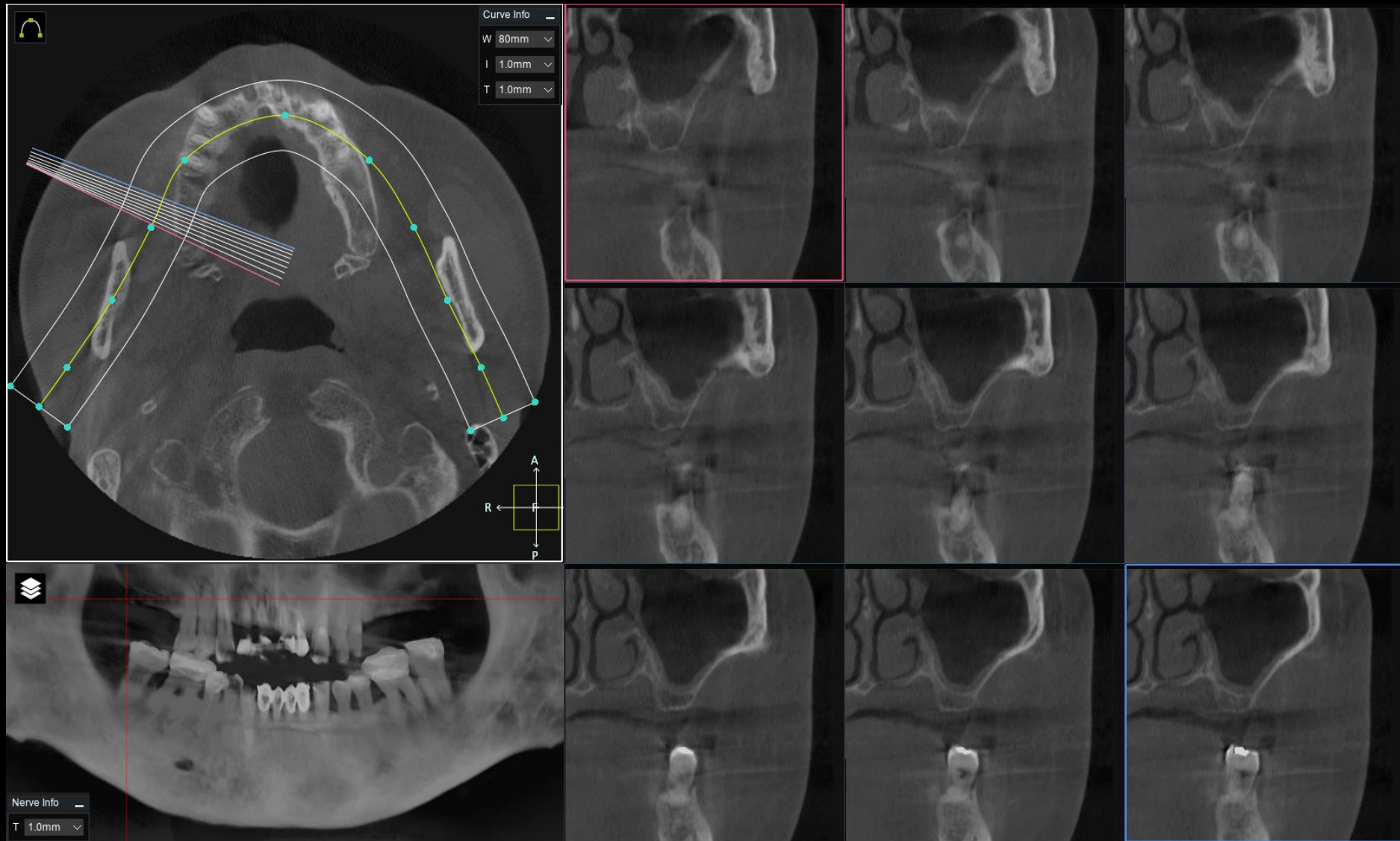
Pt. Kim (66/Female)

#16 Pre-op(2021-01-20)



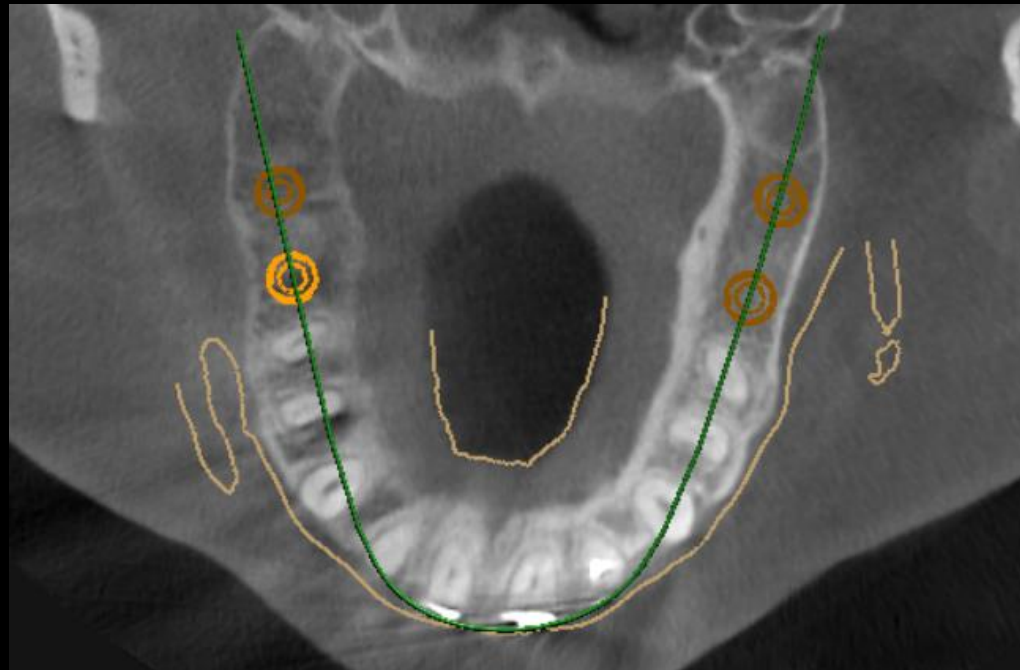
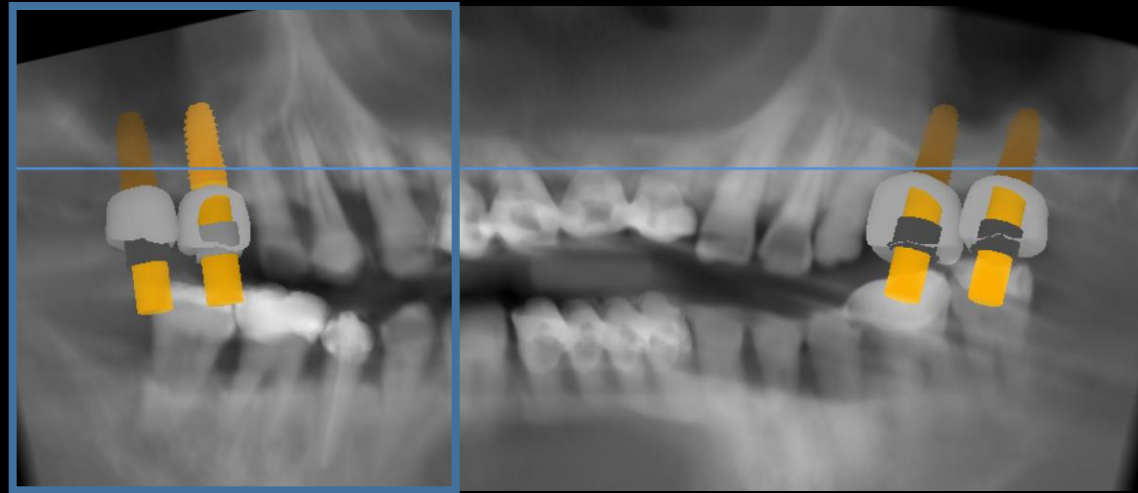Pt. Kim (66/Female)

#17 Pre-op(2021-01-20)



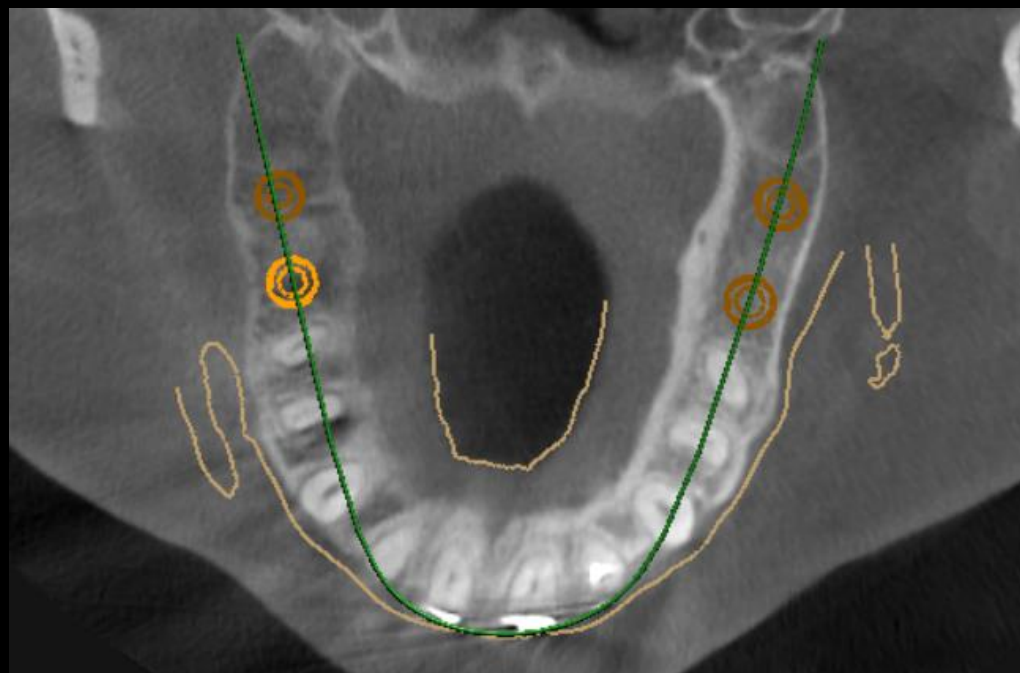
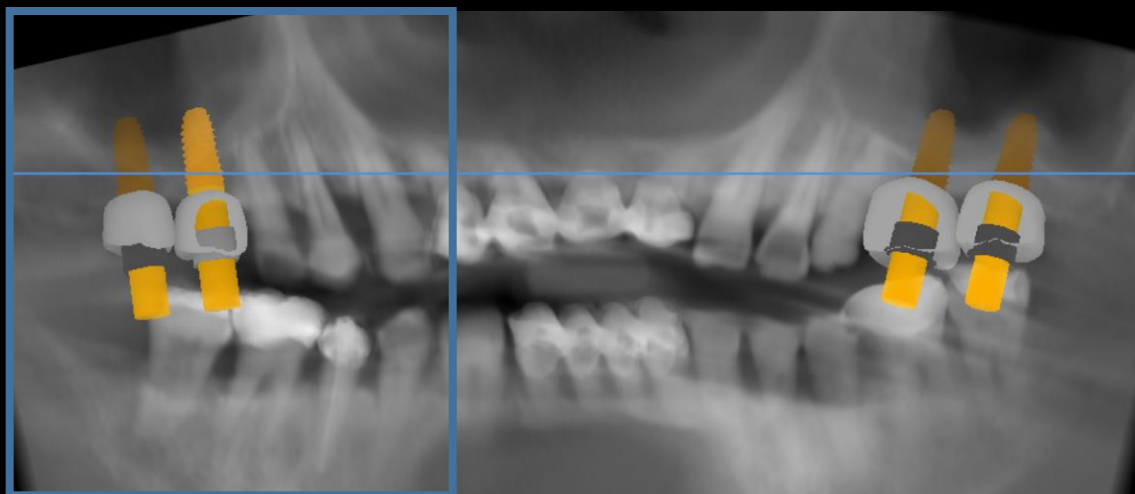Pt. Kim (66/Female)

Pre-op(2021-01-20)



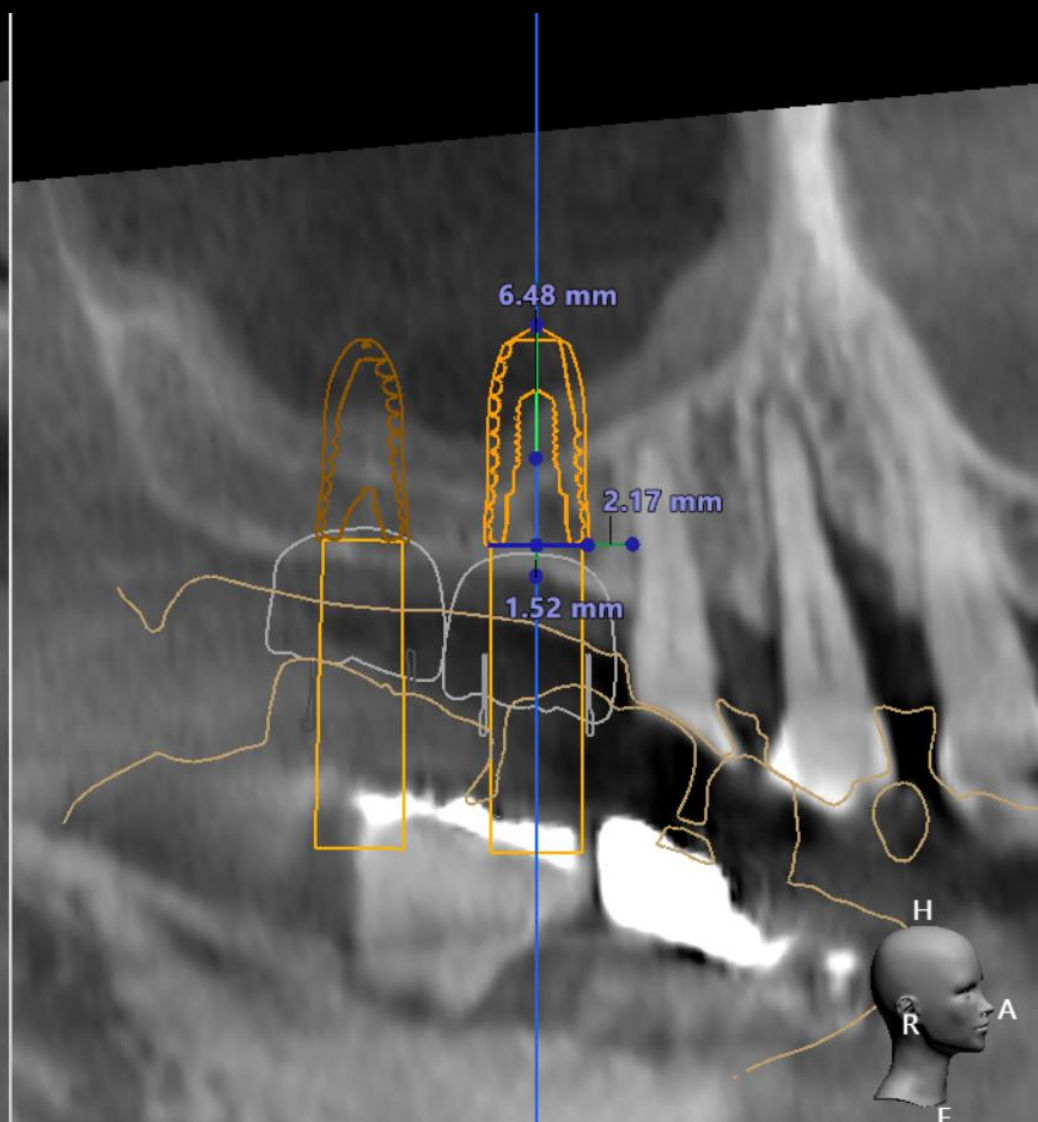
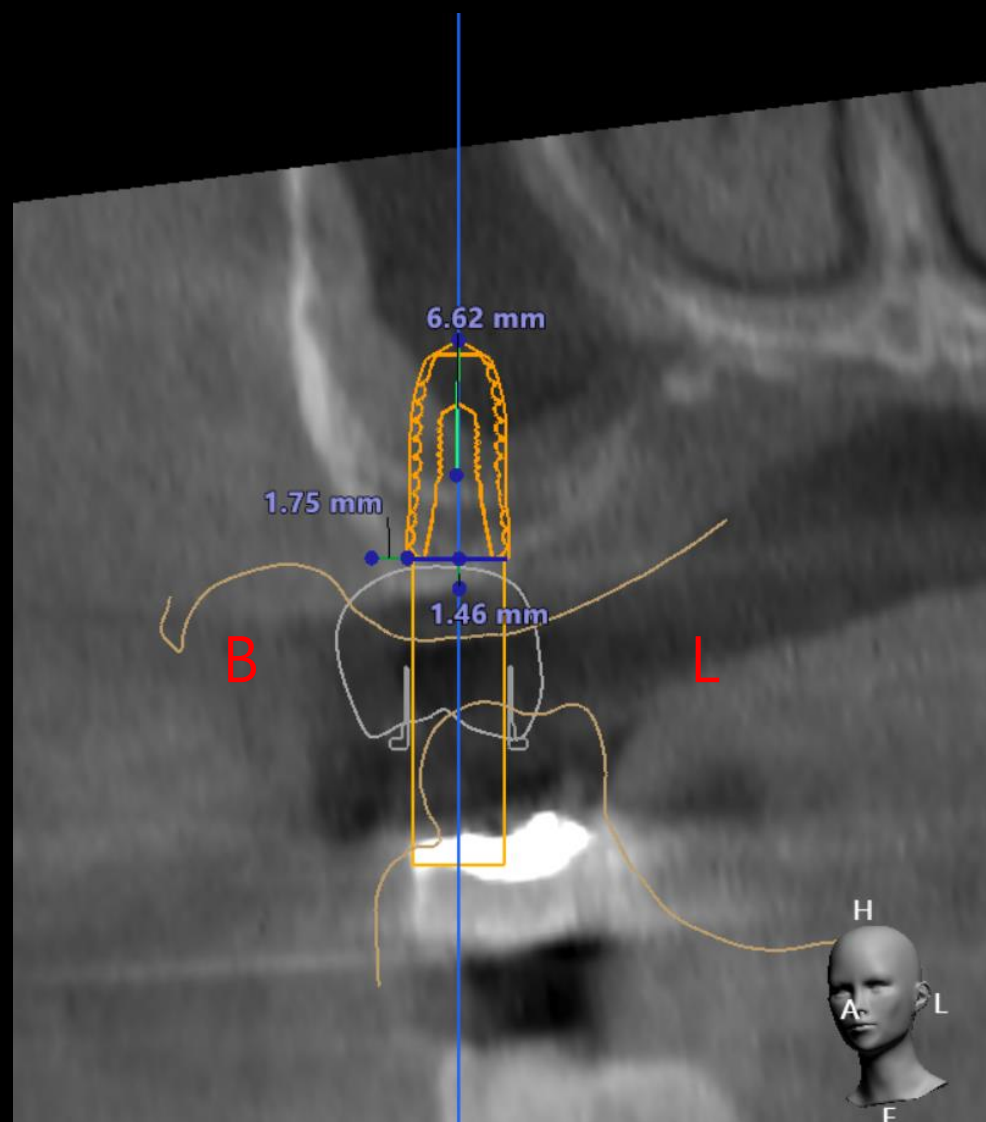
Pt. Kim (66/Female)

Pre-op(2021-01-20)



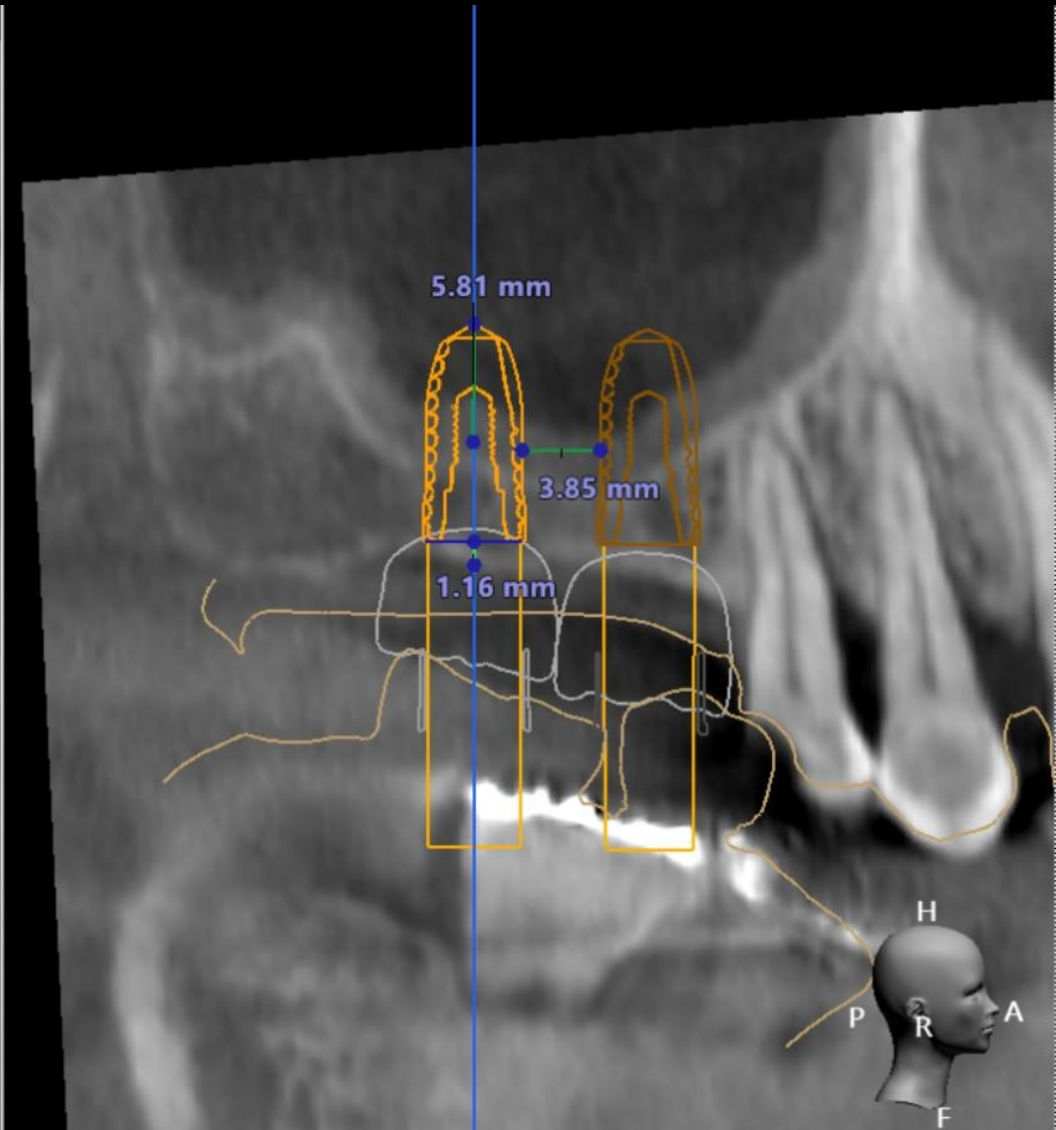
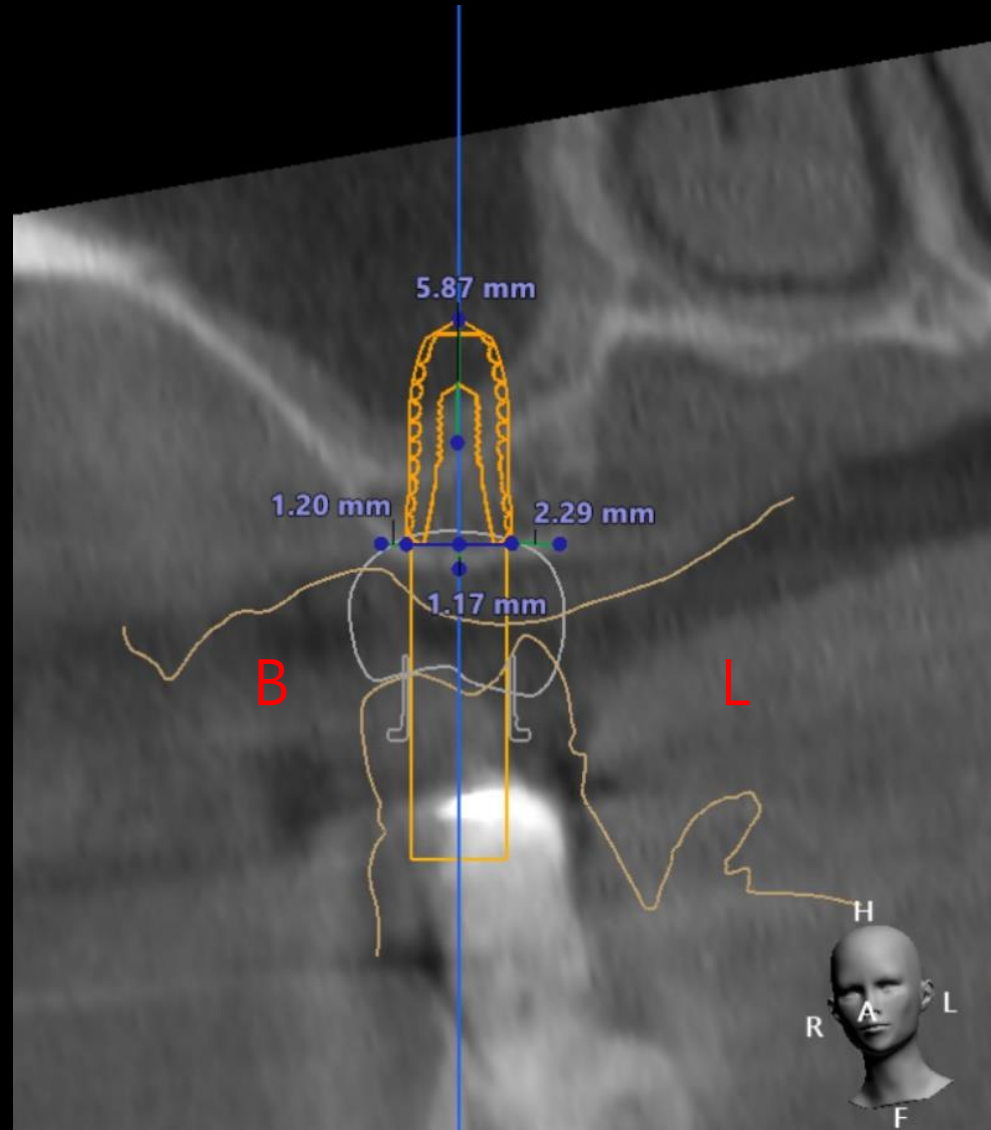
Implant Planning

#16 (4510)

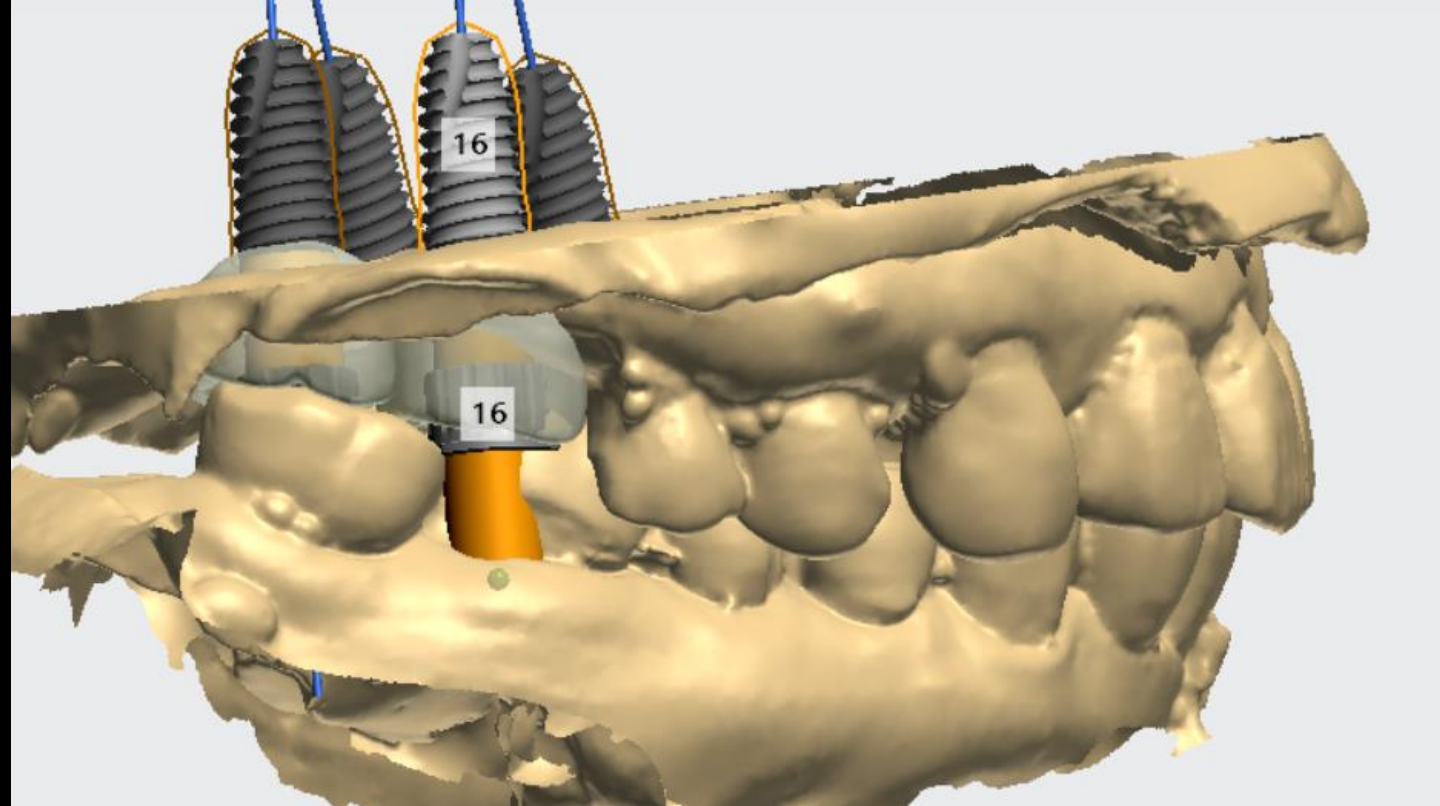


Implant Planning

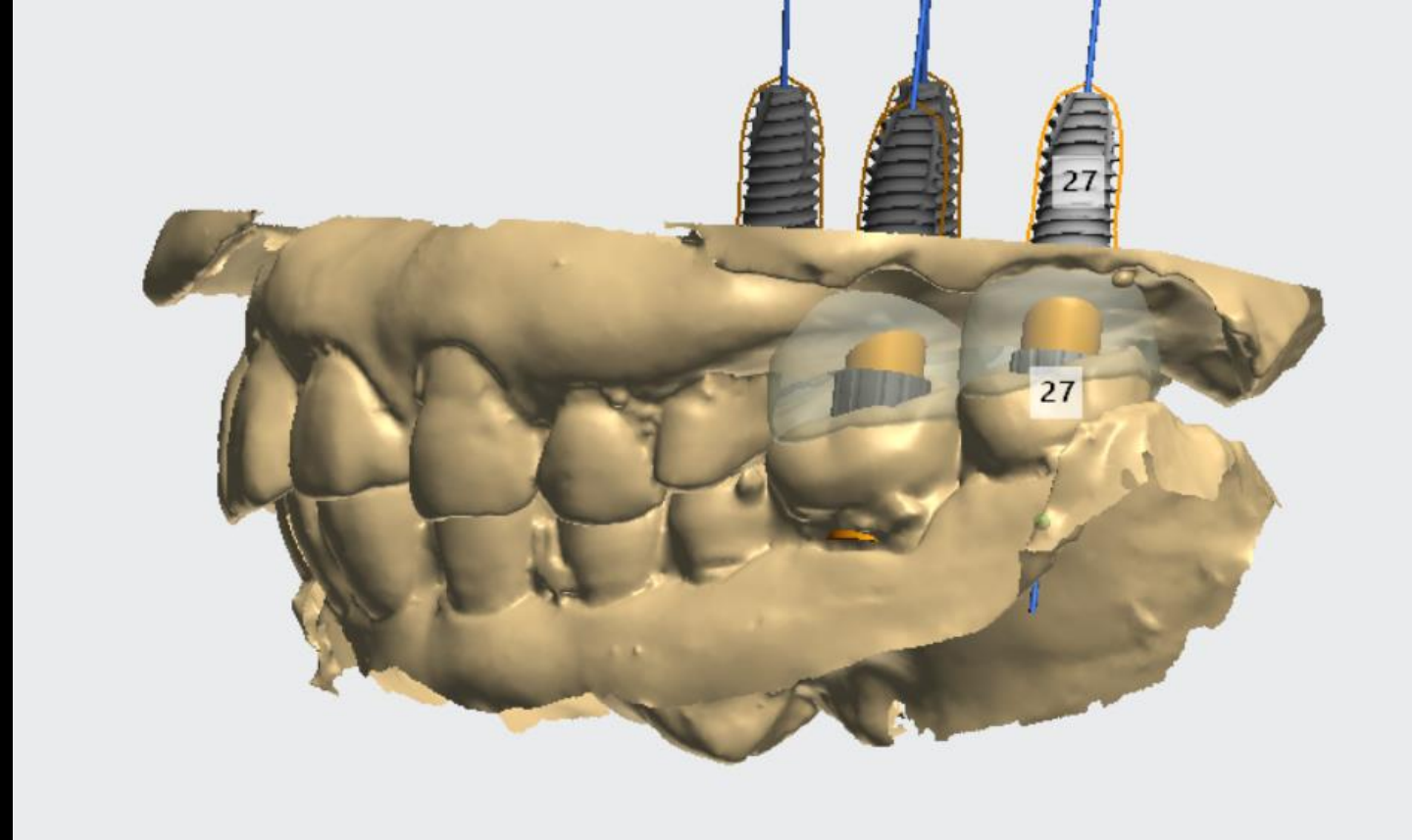
#17 (4510)



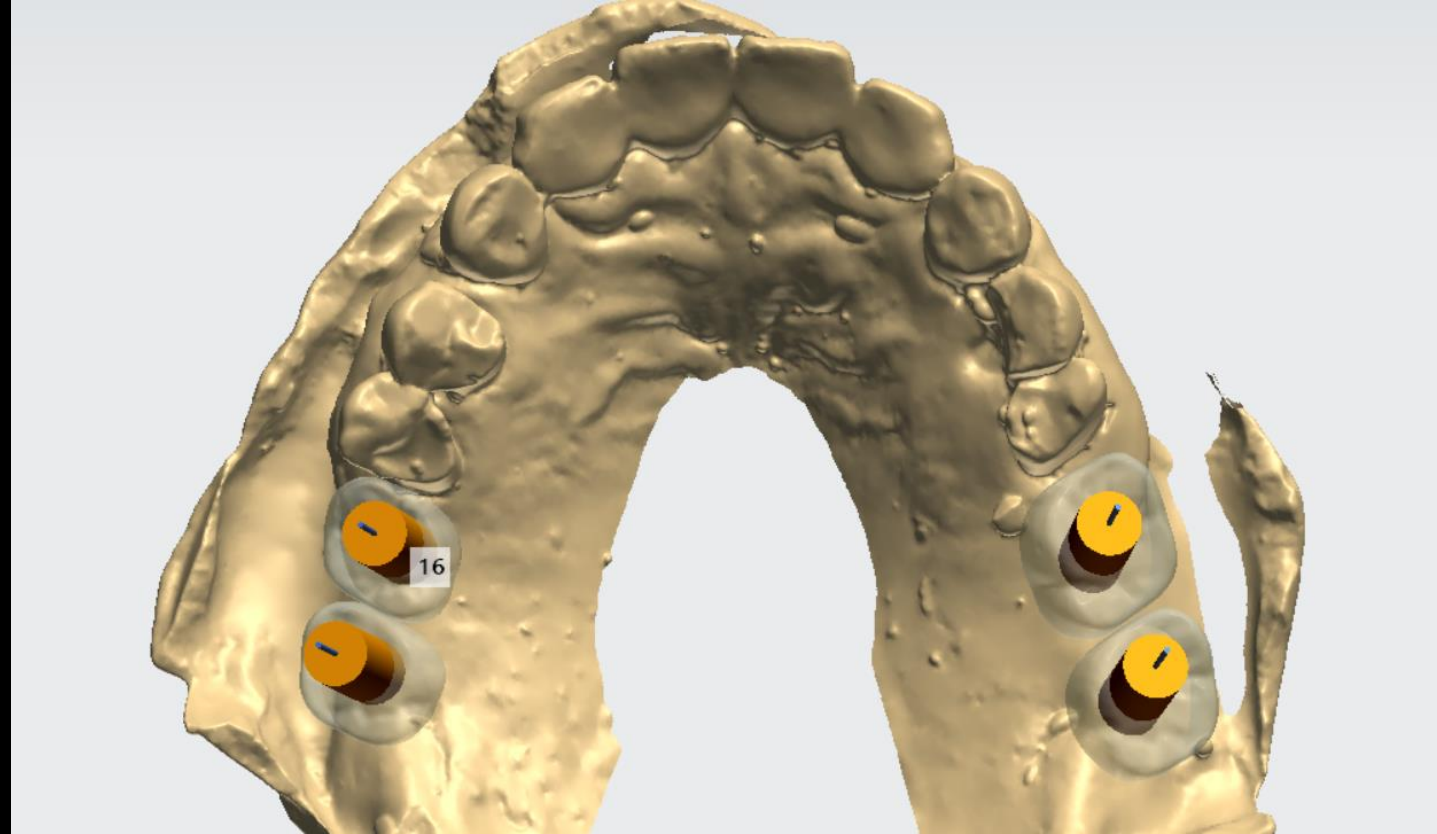
Implant Planning



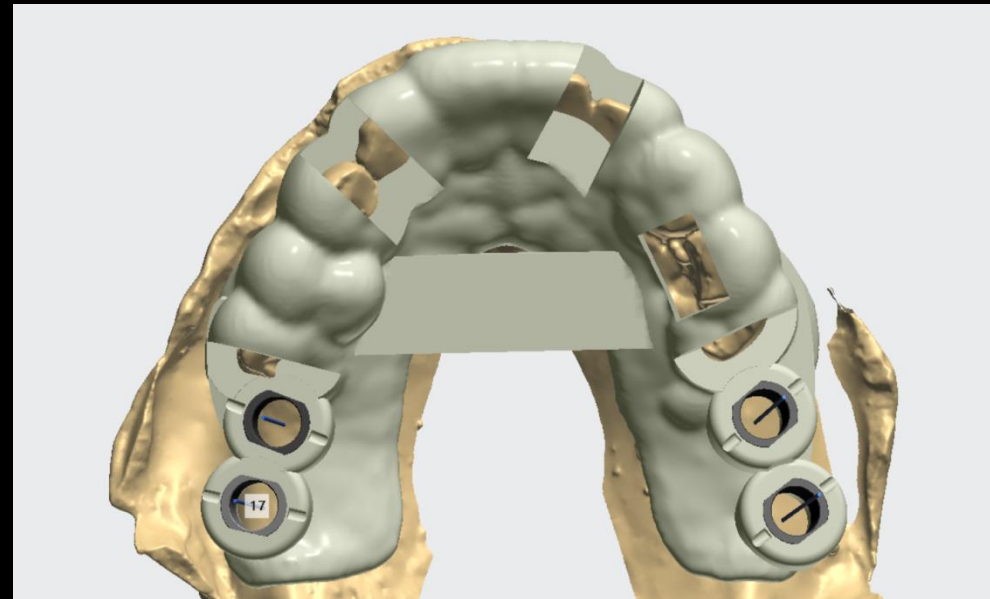
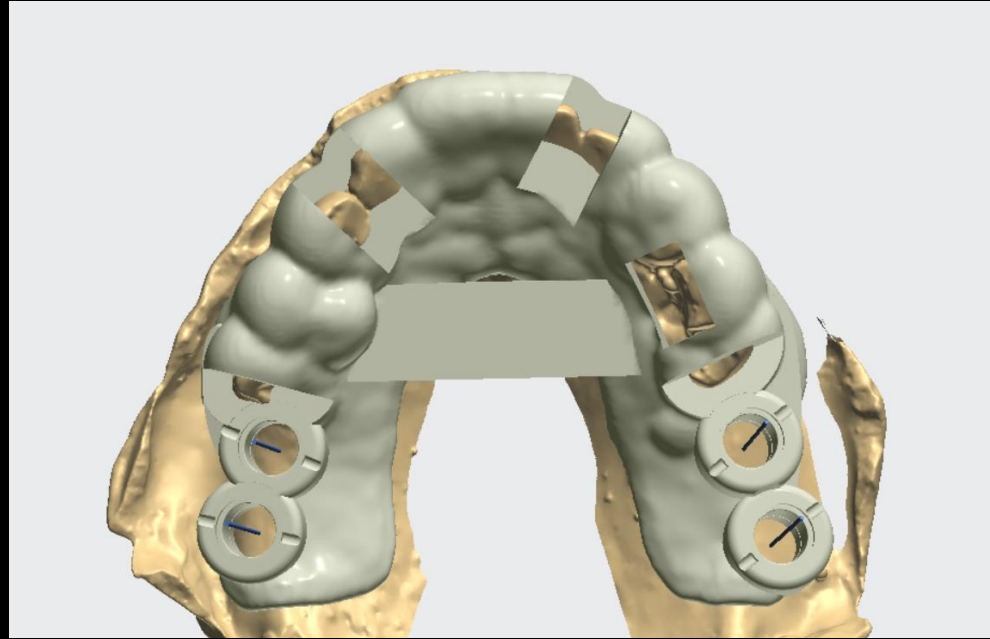
Implant Planning



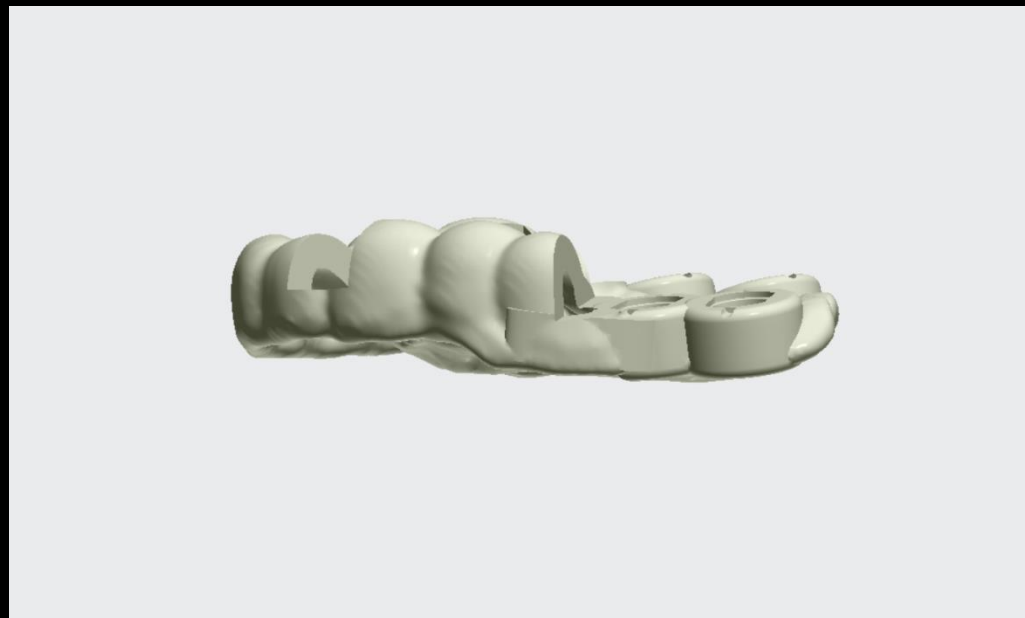
Implant Planning



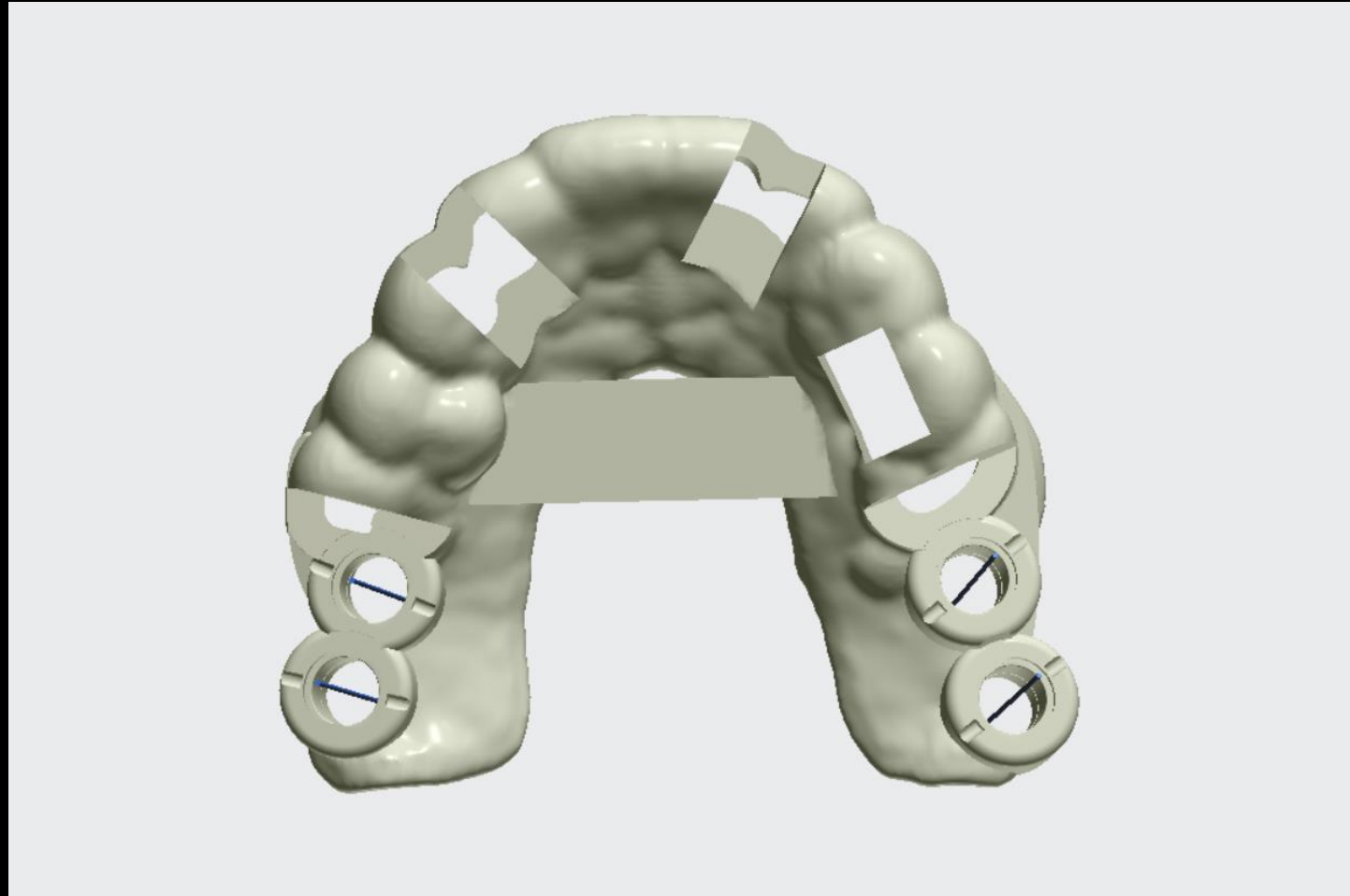
Stent Design



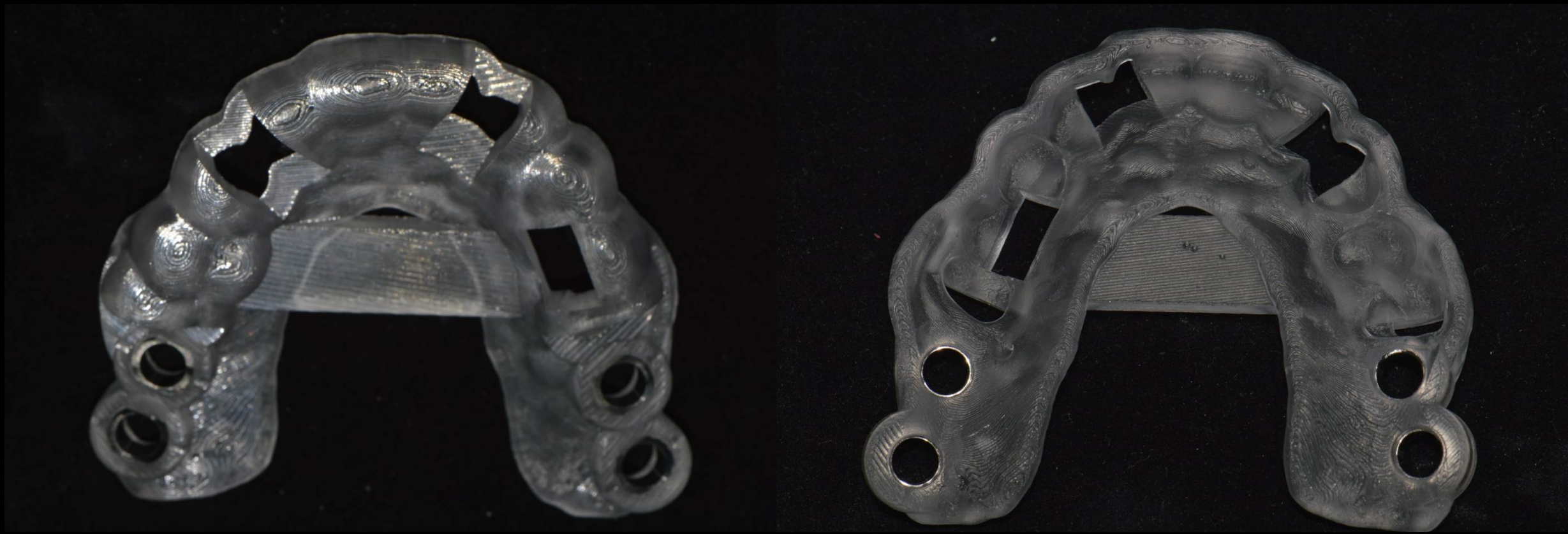
Stent Design



Stent Design

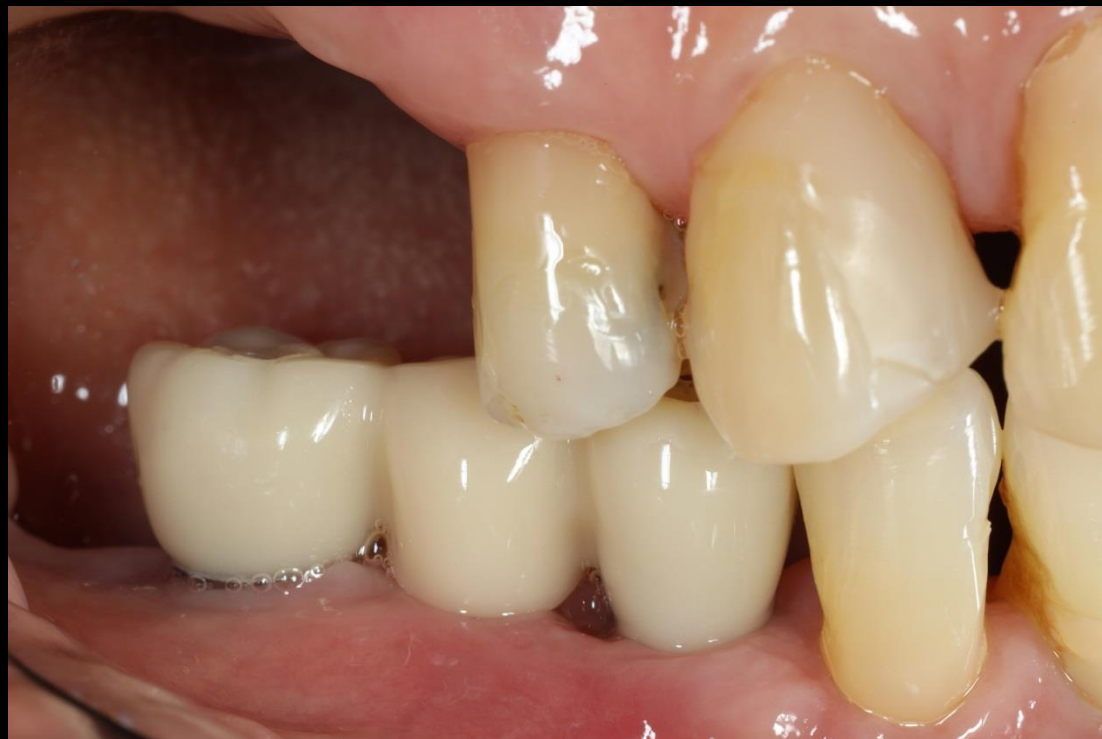

Stent



Similar case presentation(1)

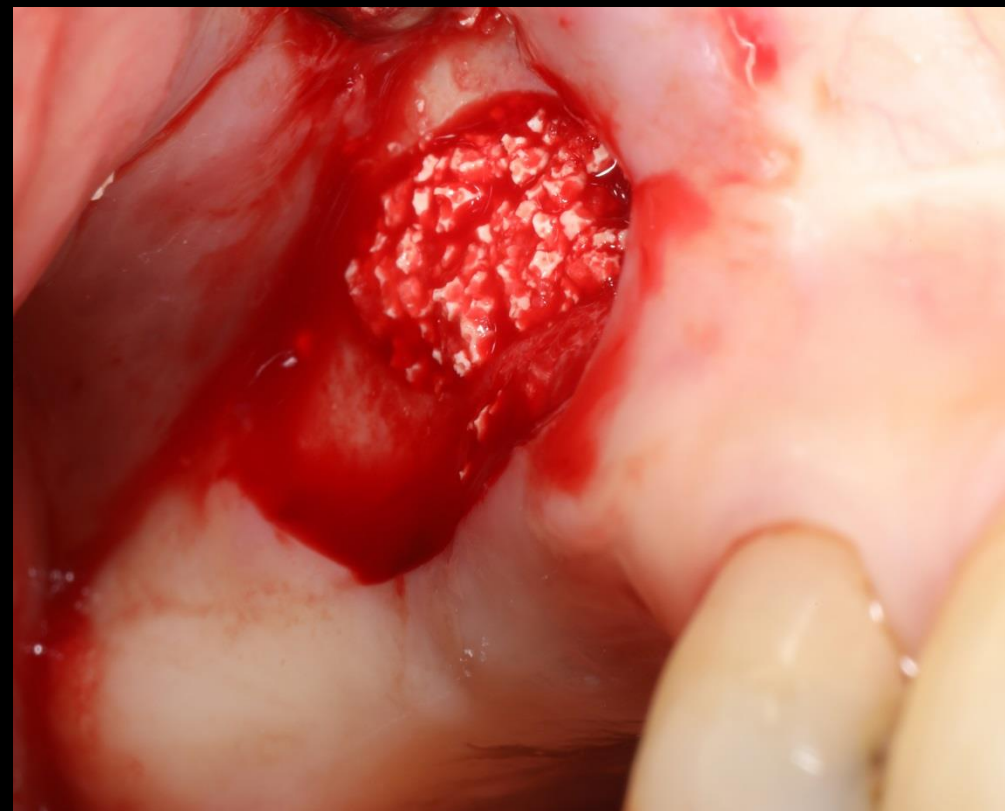
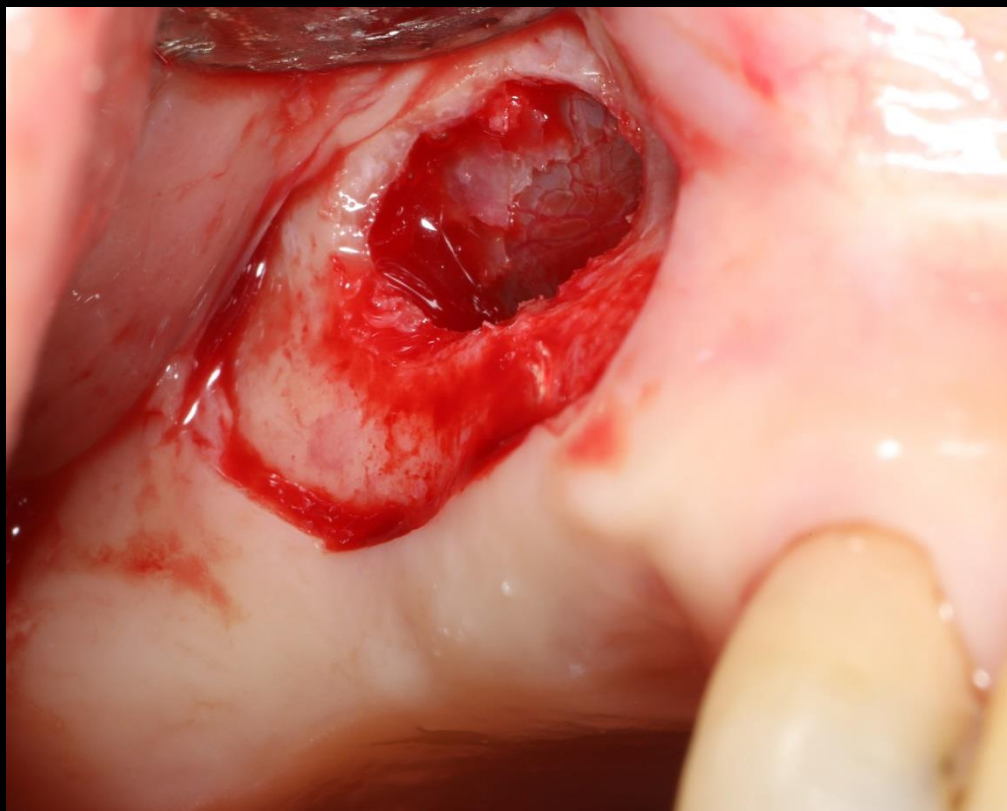
- # 10 Sinus elevation & implant placement



Pre-op

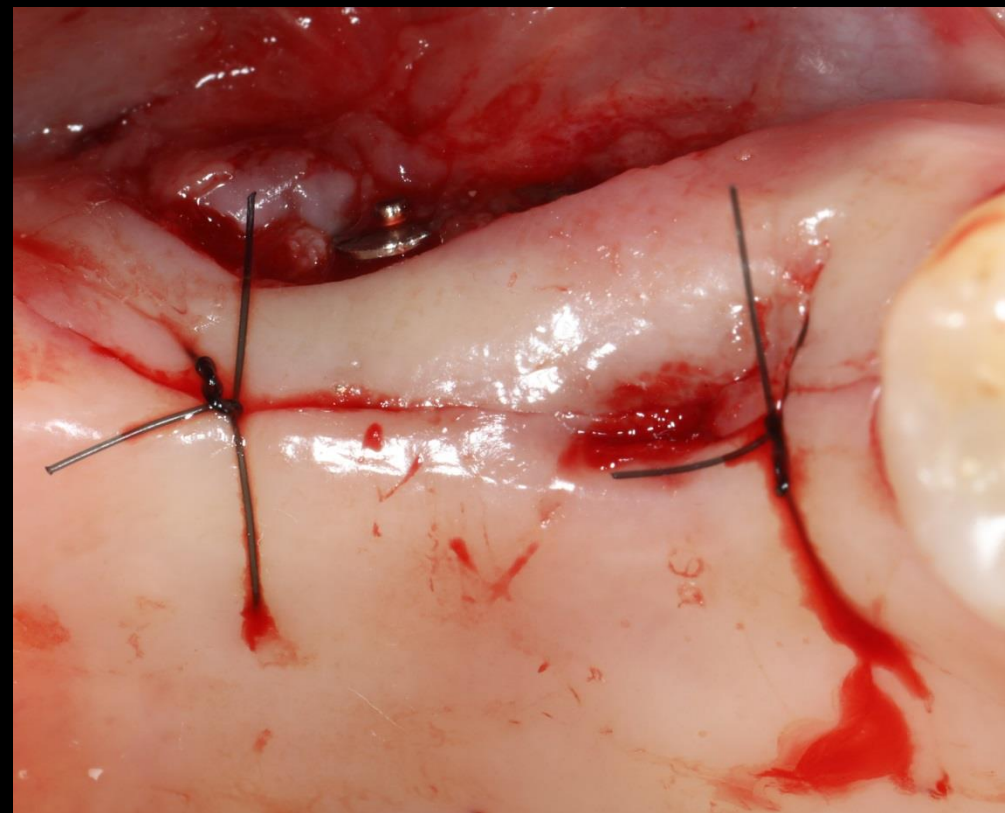
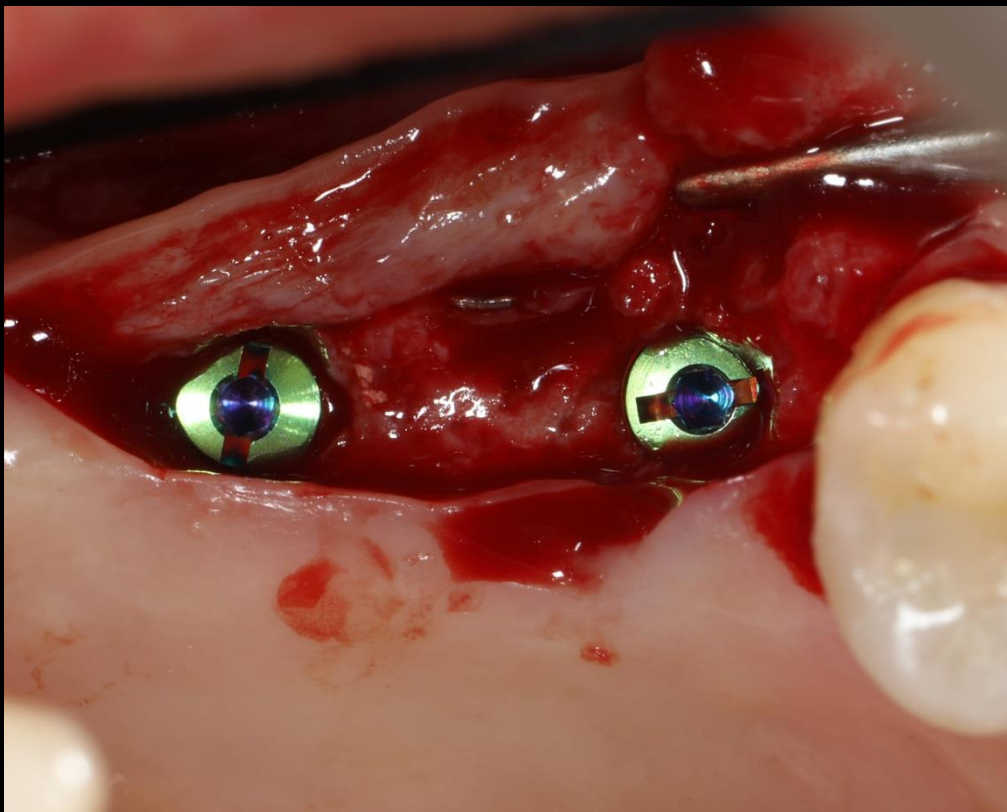
Similar case presentation(1)

- # 10 Sinus elevation & implant placement



Similar case presentation(1)

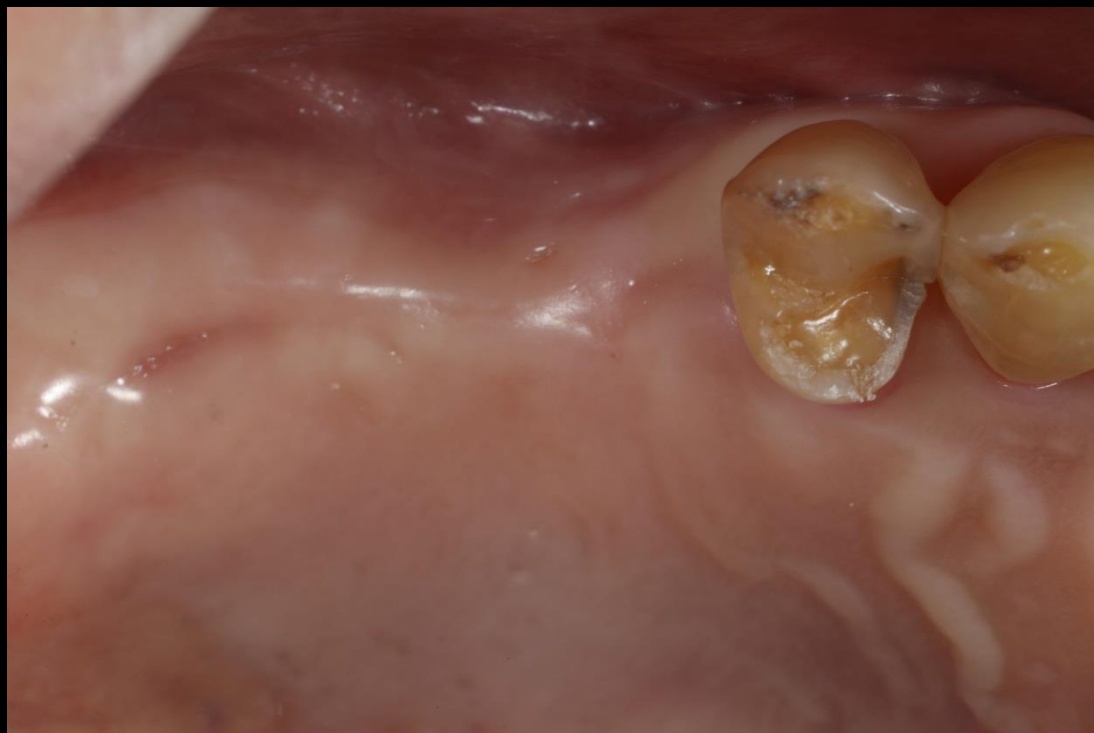- # 10 Sinus elevation & implant placement



Post-op
(2019-09-02)

Similar case presentation(2)

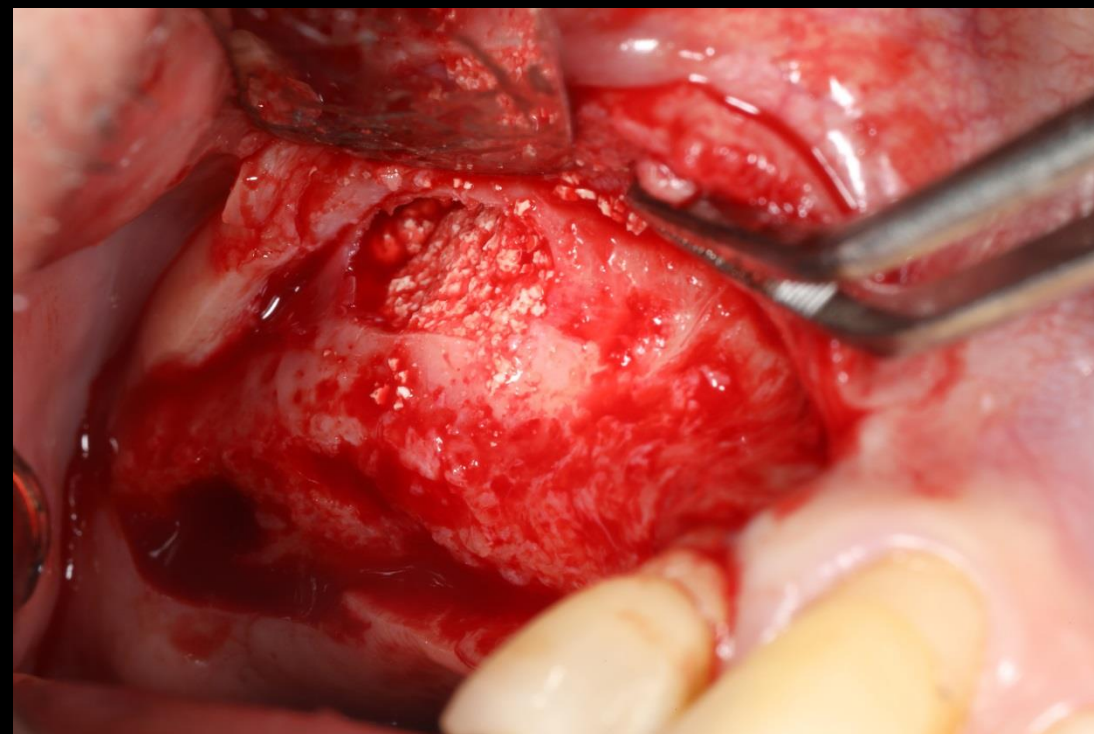
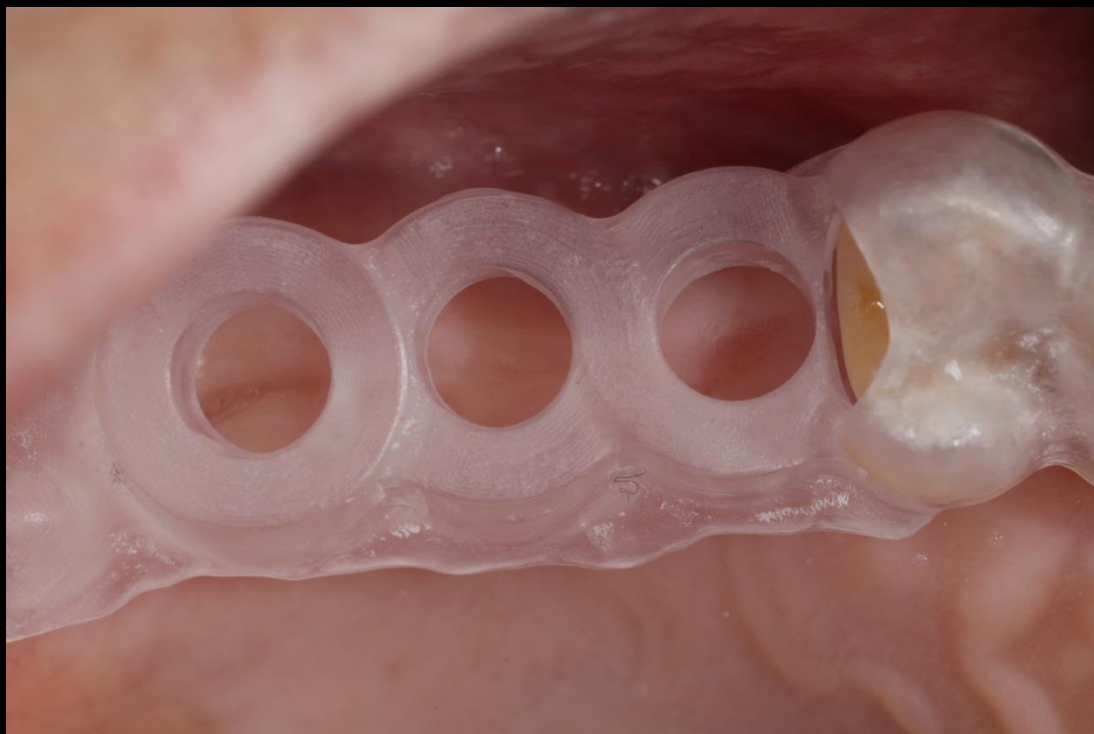
- # 10 Sinus elevation & implant placement



Pre-op

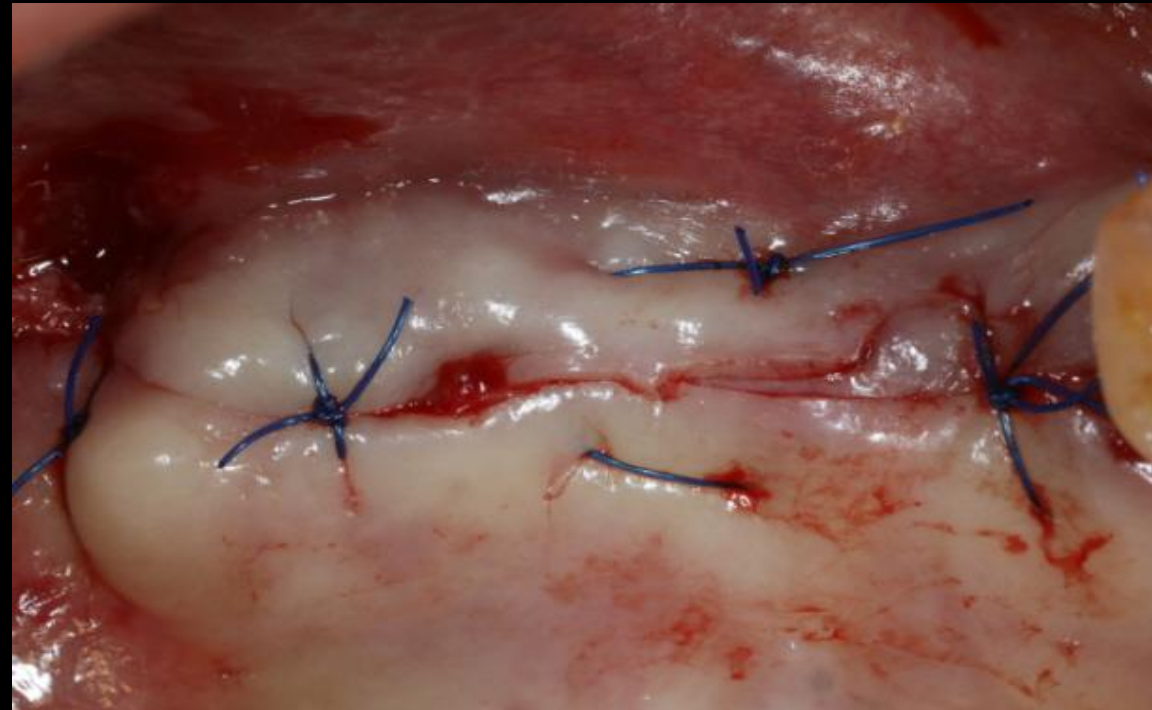
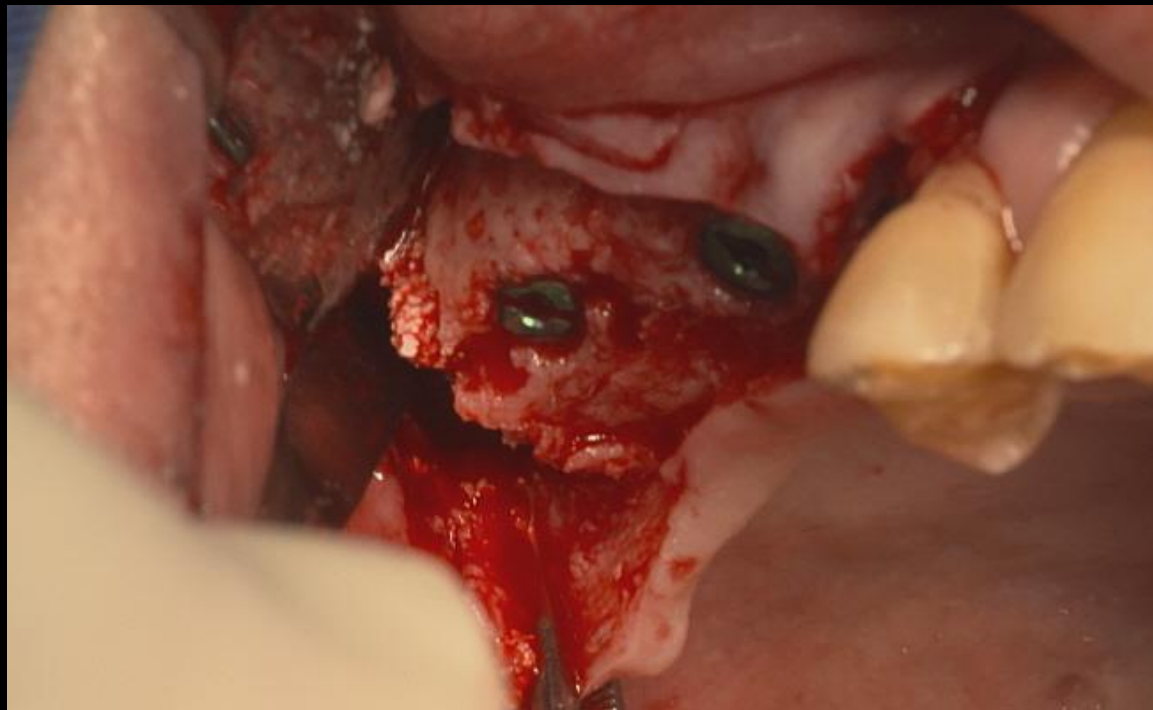
Similar case presentation(2)

- # 10 Sinus elevation & implant placement



Similar case presentation(2)

- # 10 Sinus elevation & implant placement



Post-op
(2020-01-16)