



Surgey

Dr. Kang-Hee Lee

2021.1.22 (FRI.)



[Case Preview]

Full mouth rehabilitation with Dentium Guide

Patient Information

Age : 55

Sex : Male

Chief Complaint :

I can't eat well
because of missing tooth

Past Dental History

Anterior site supernumerary teeth extraction & GBR

10 sinus elevation (2020-11-14)

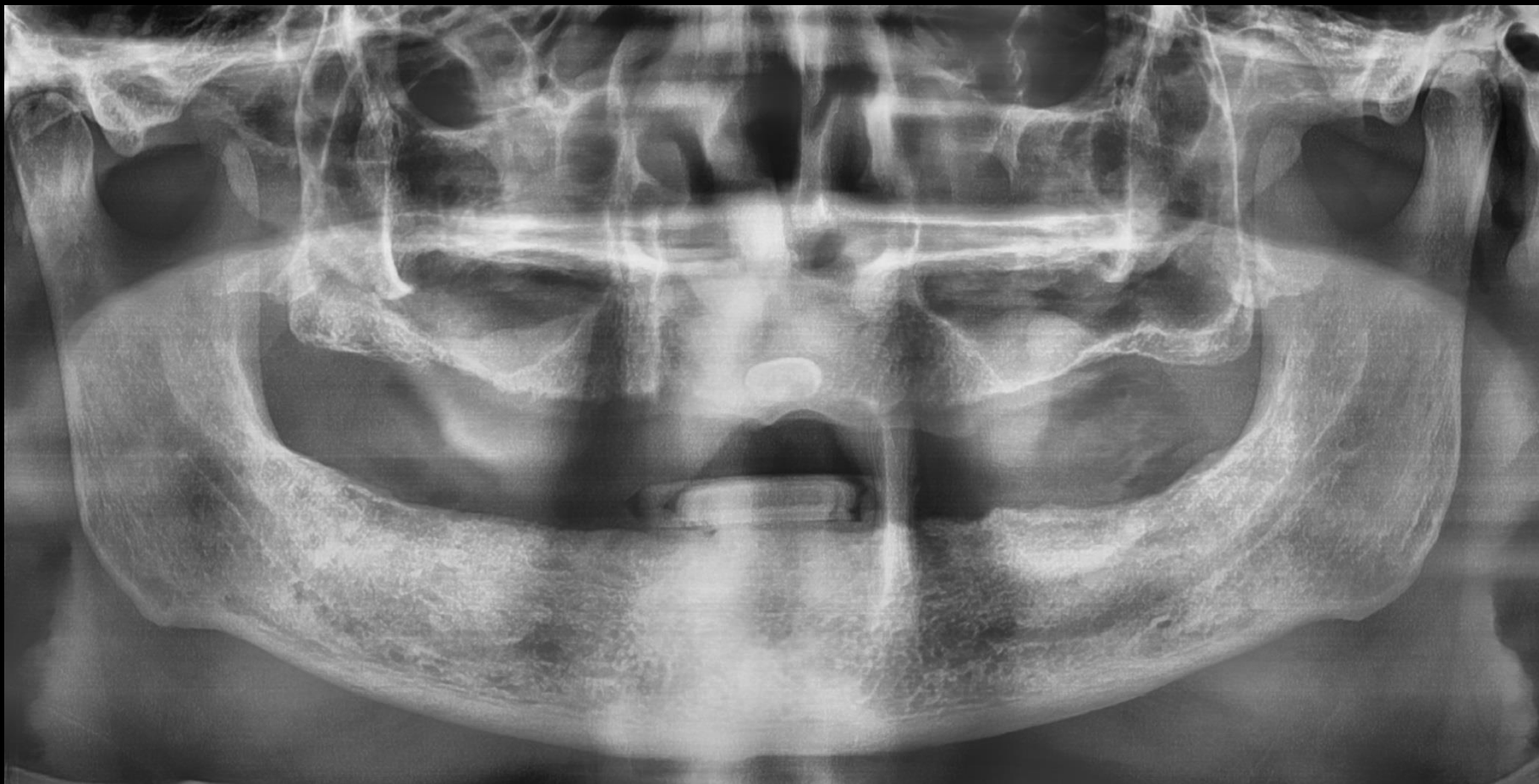20 sinus elevation (2020-11-21)

Past Medical History

N/S

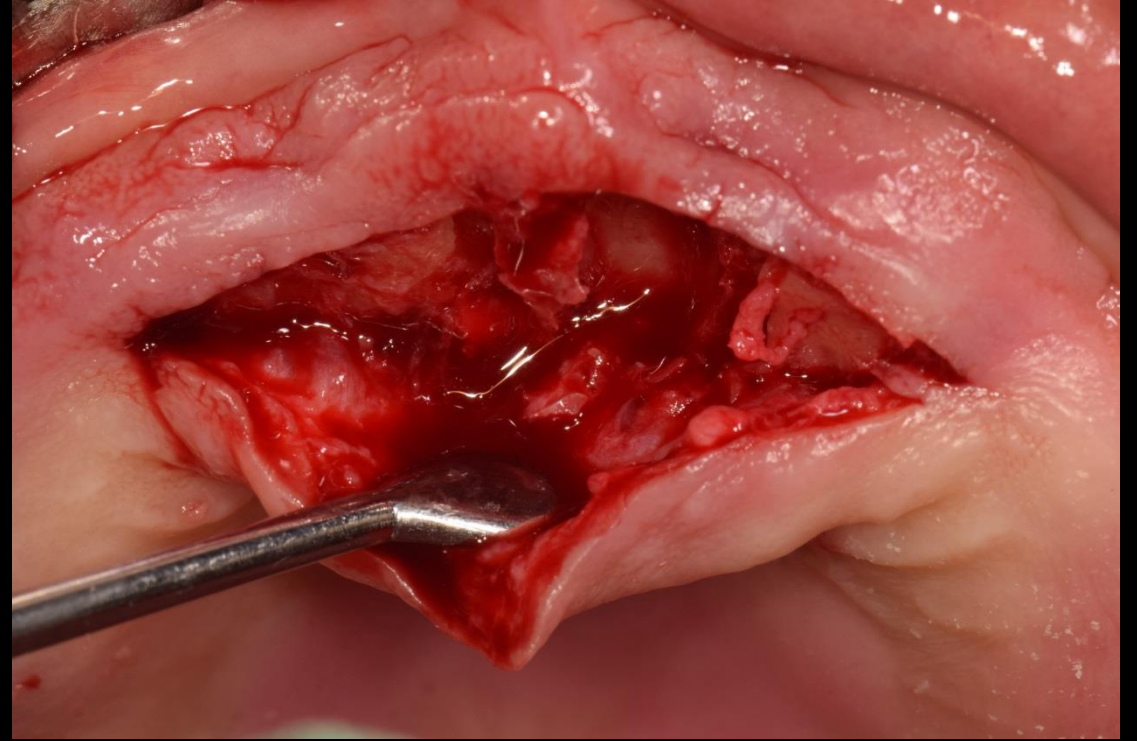
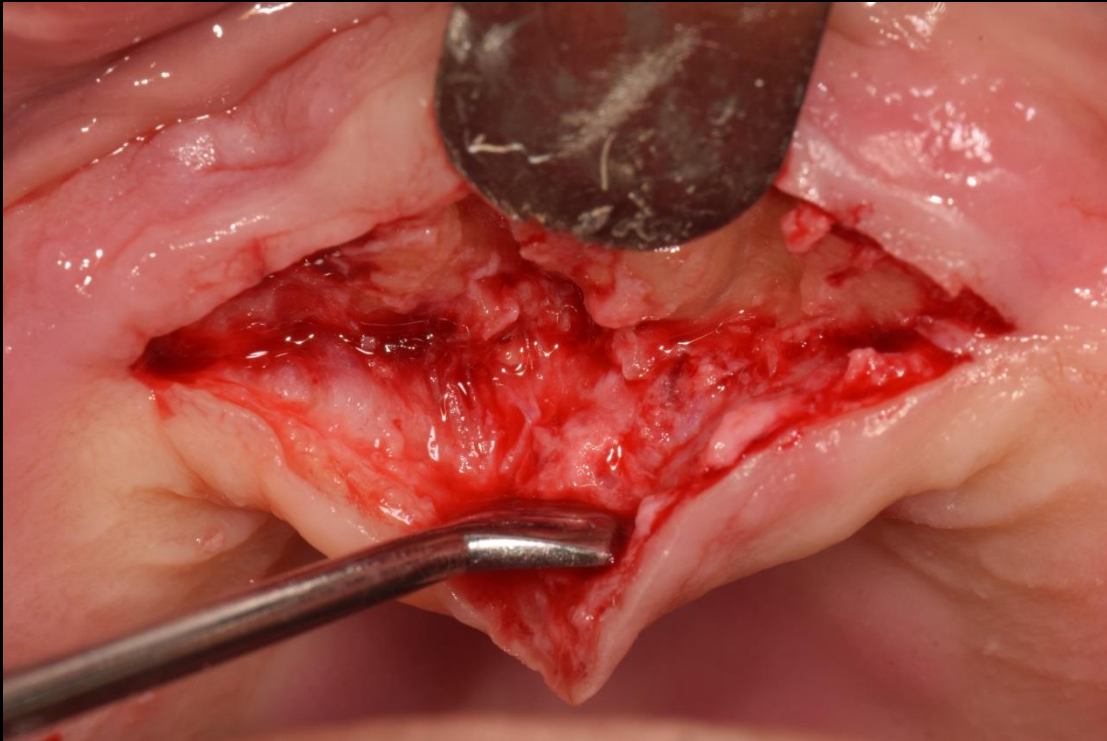
Past dental history

Oral exam (2020-11-03)



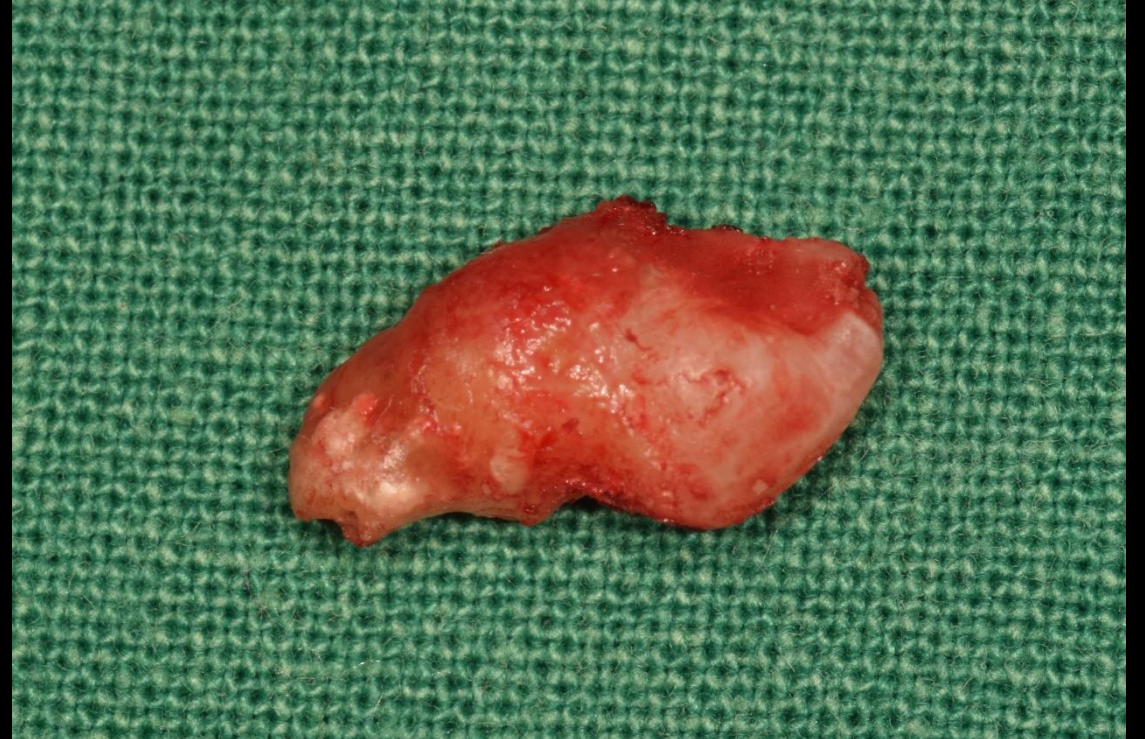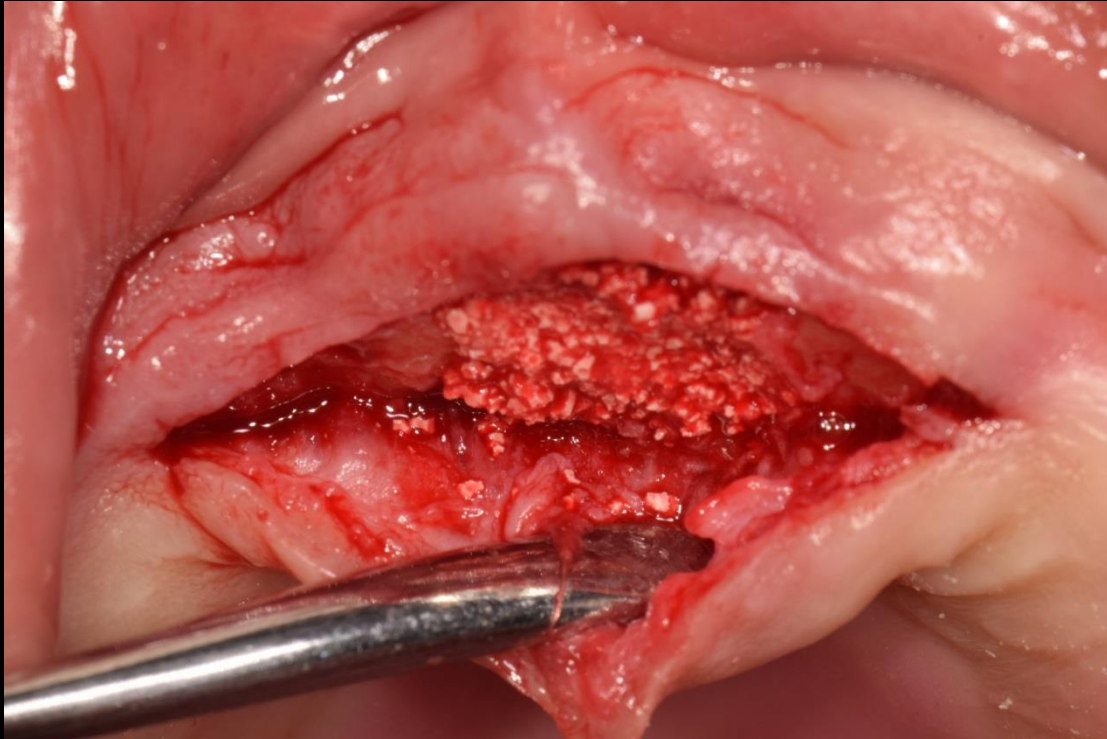
Past dental history

Anterior site Supernumerary teeth extraction & GBR



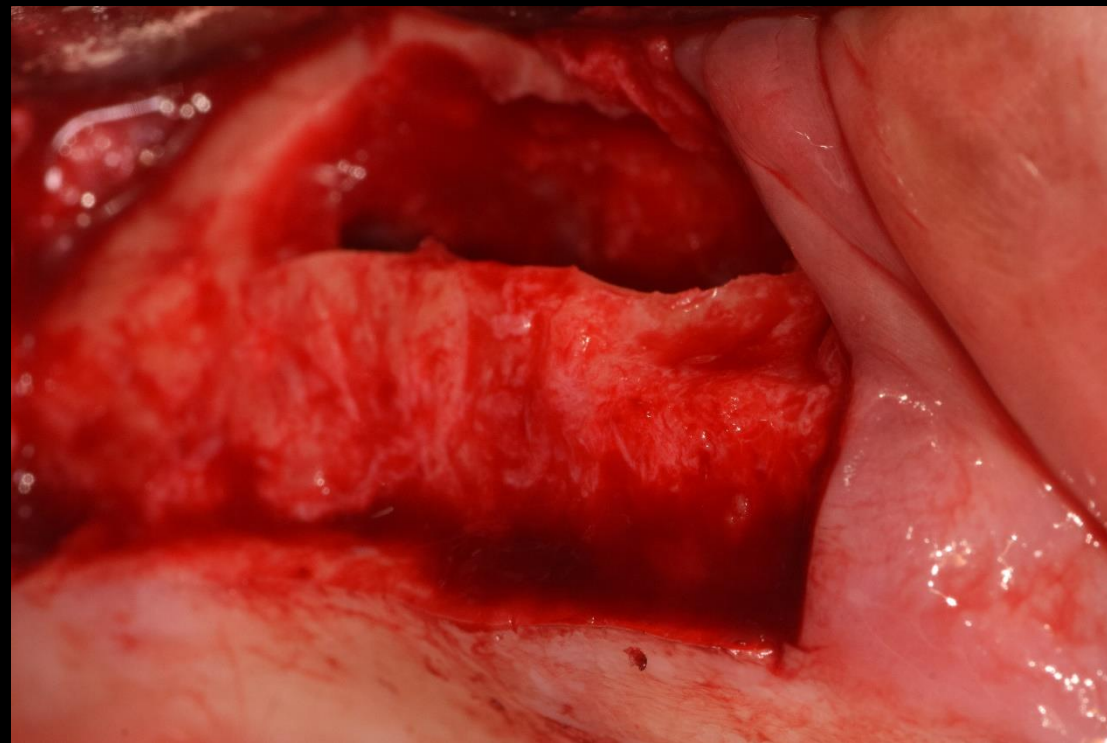
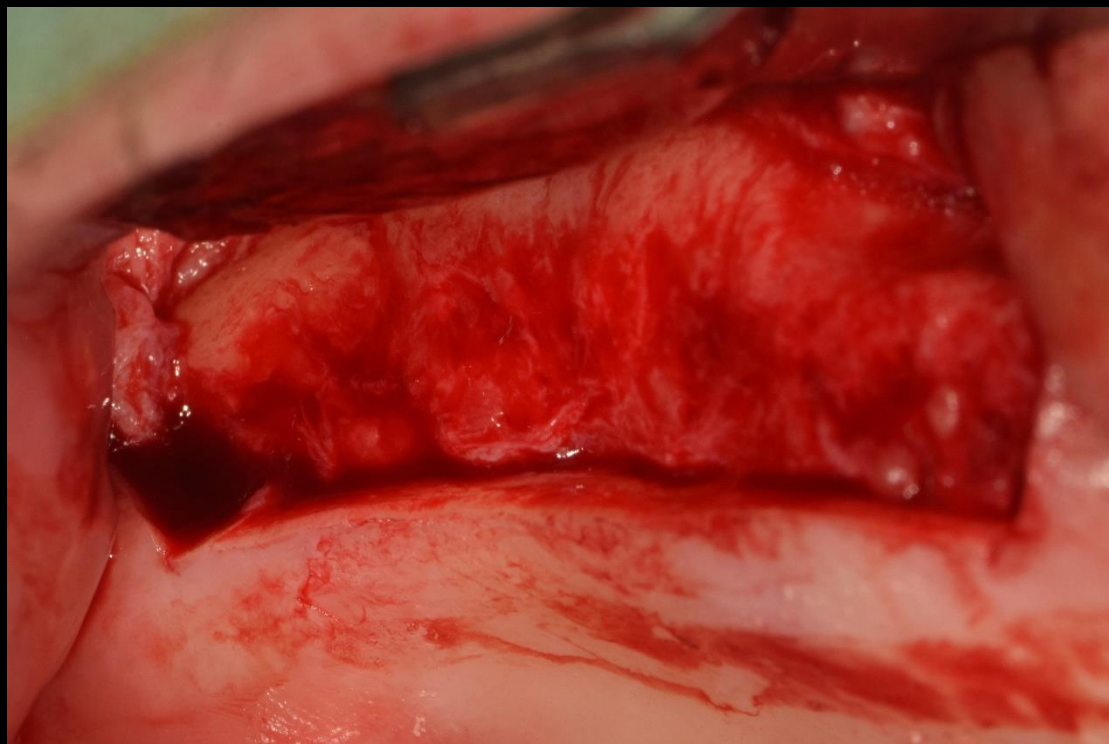
Past dental history

Anterior site Supernumerary teeth extraction & GBR



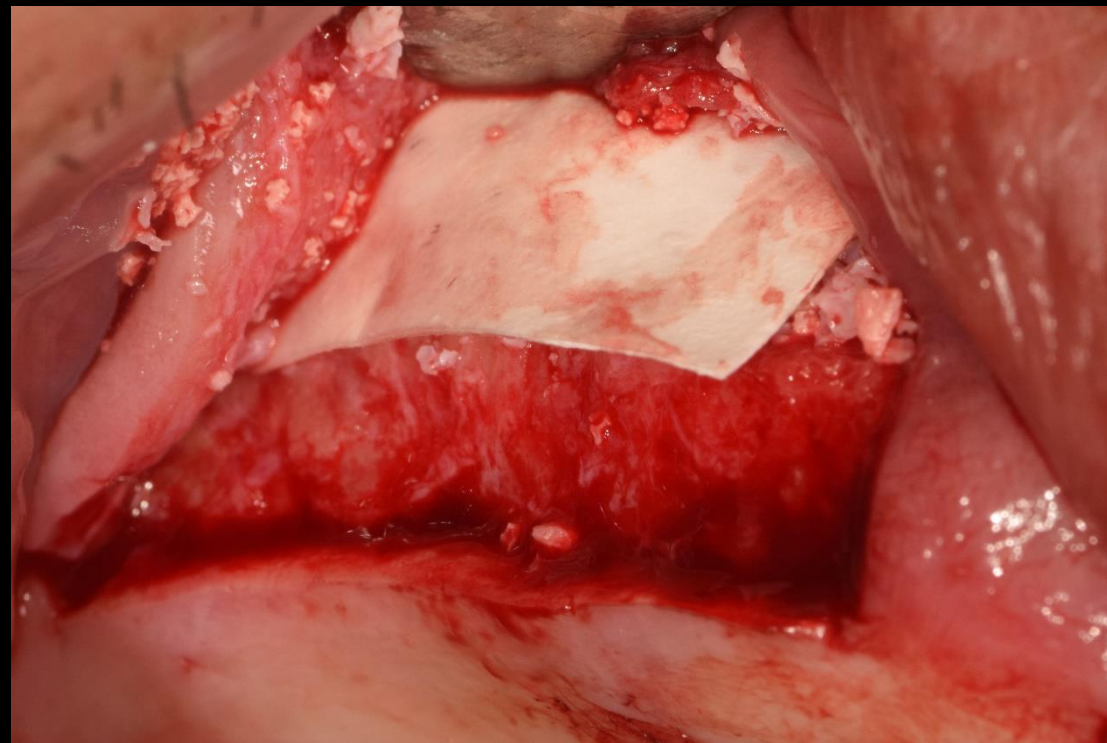
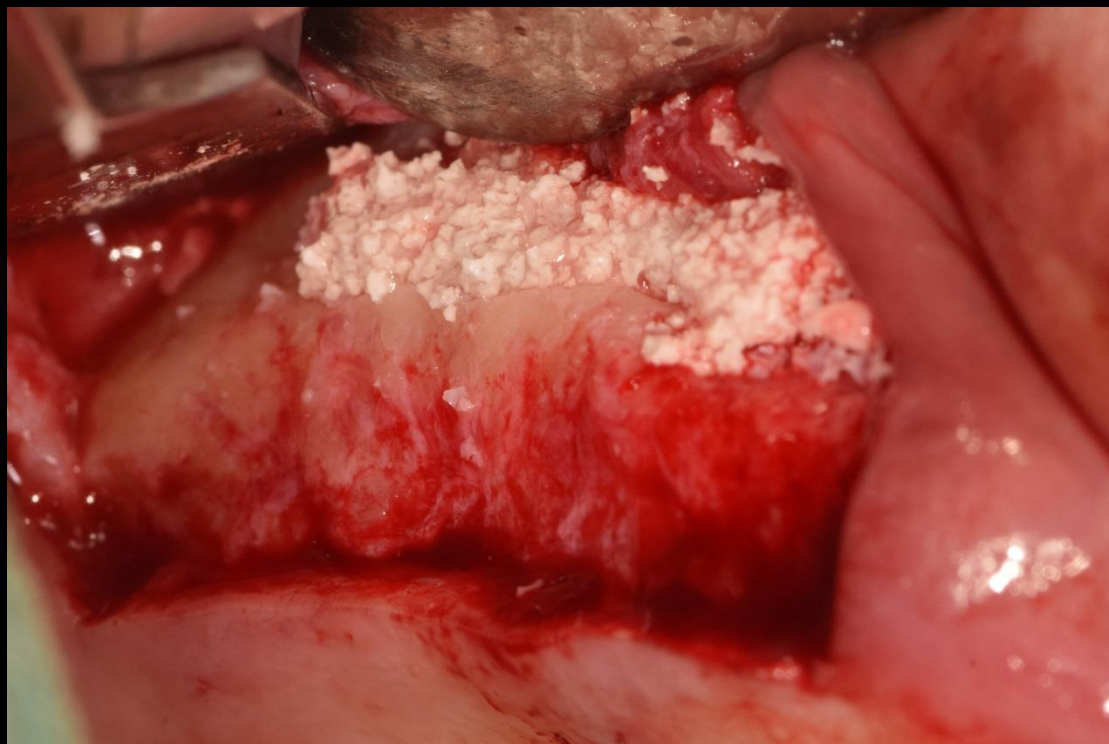Past dental history

#10 Sinus elevation



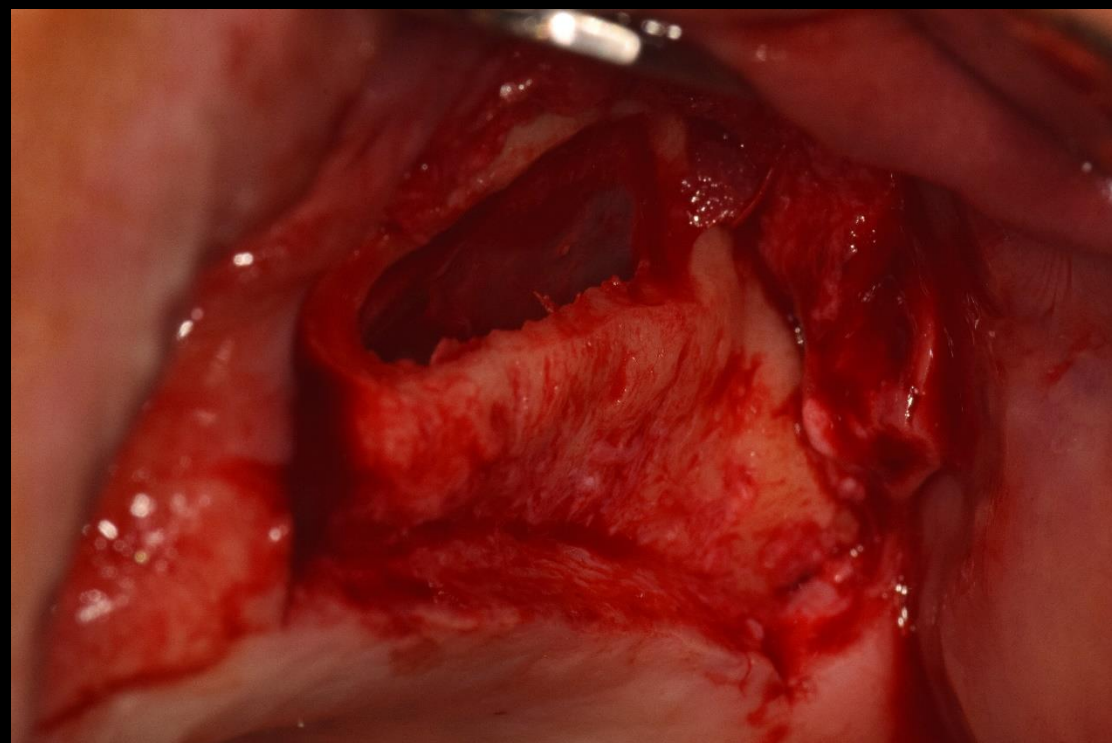
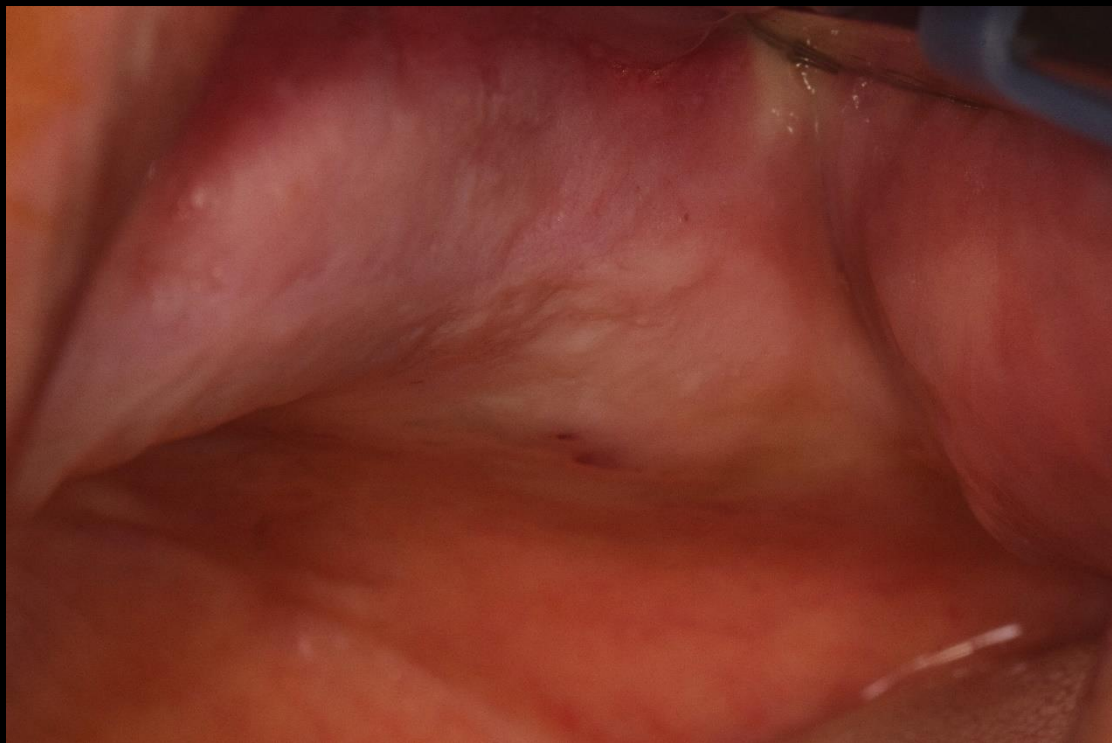Past dental history

#10 Sinus elevation



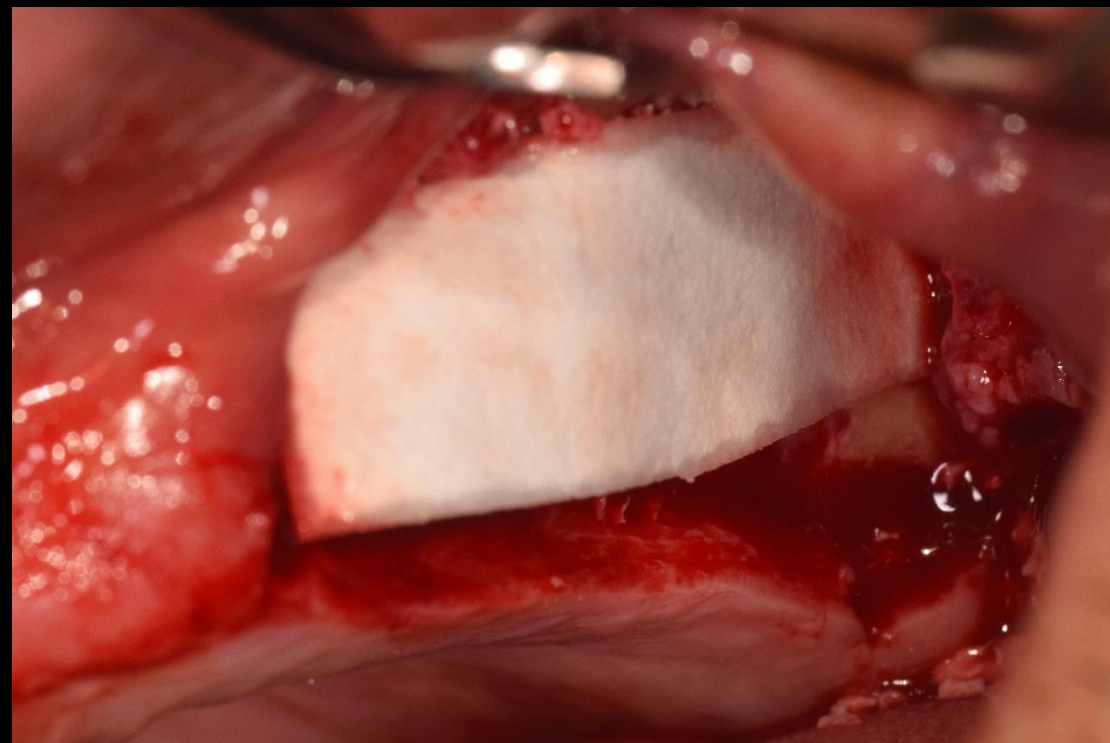
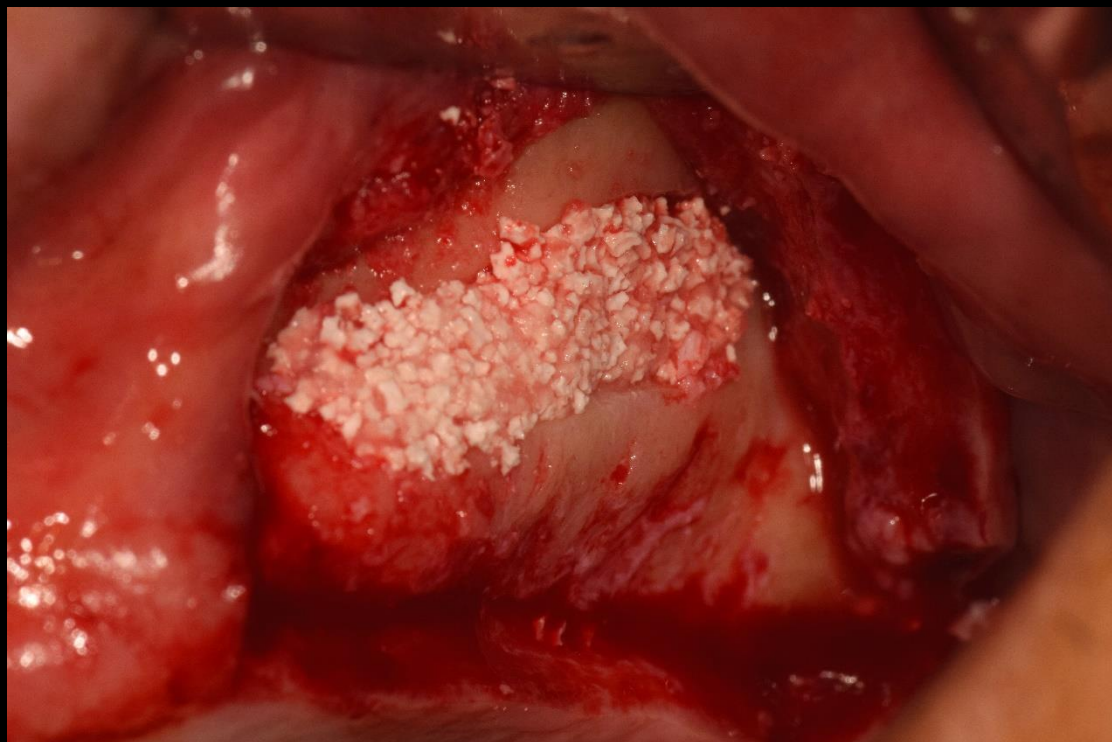
Past dental history

#20 Sinus elevation



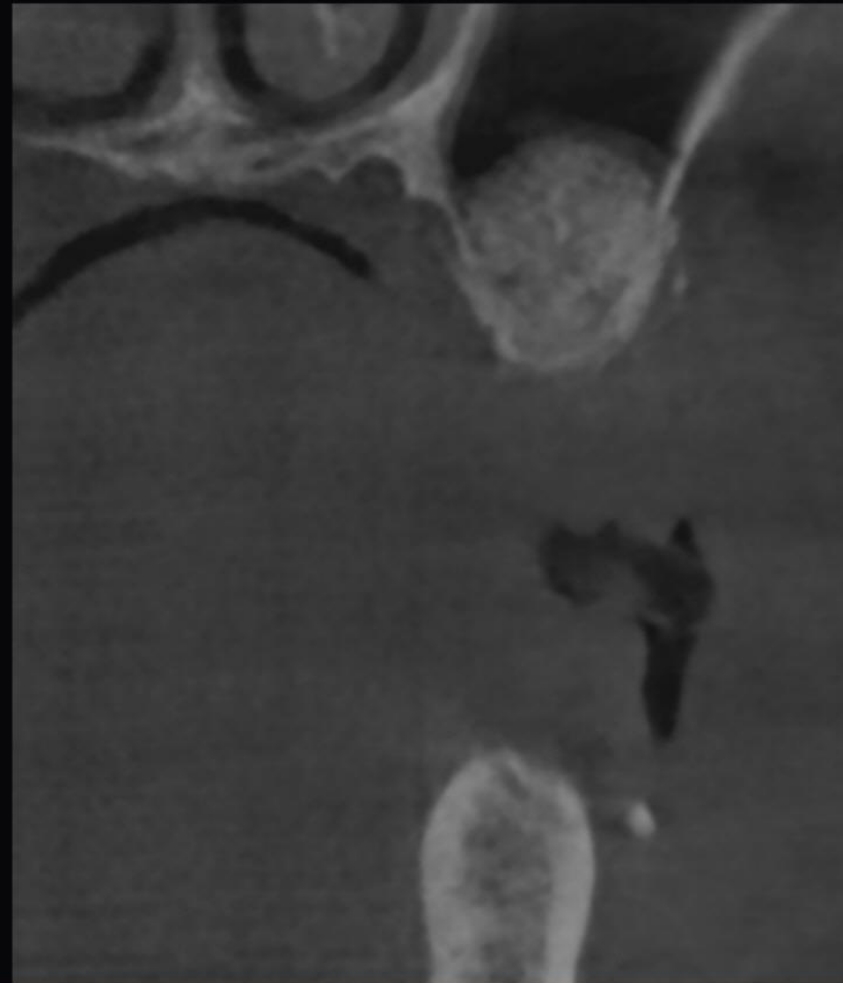
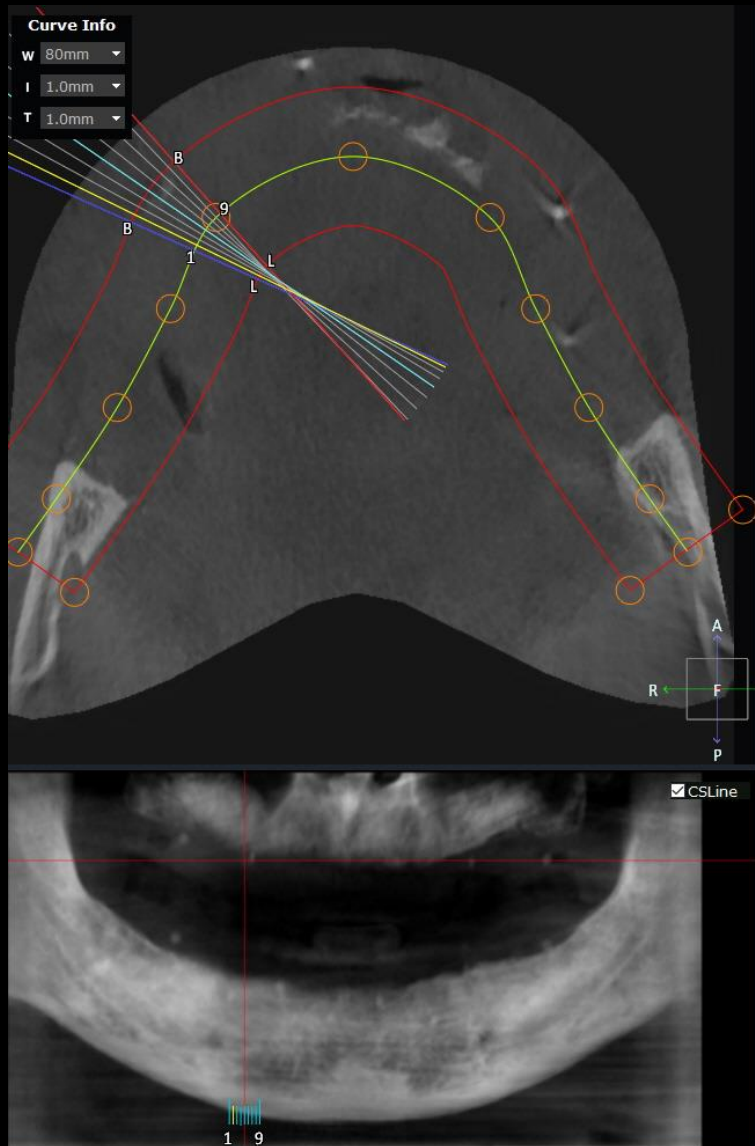
Past dental history

#20 Sinus elevation



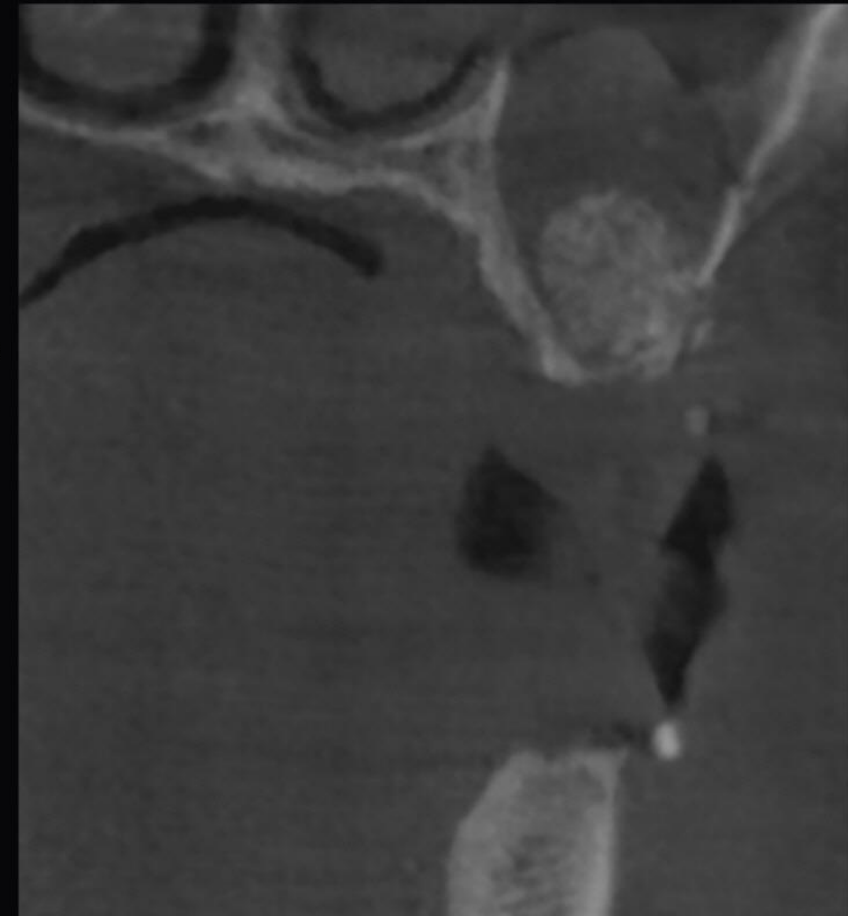
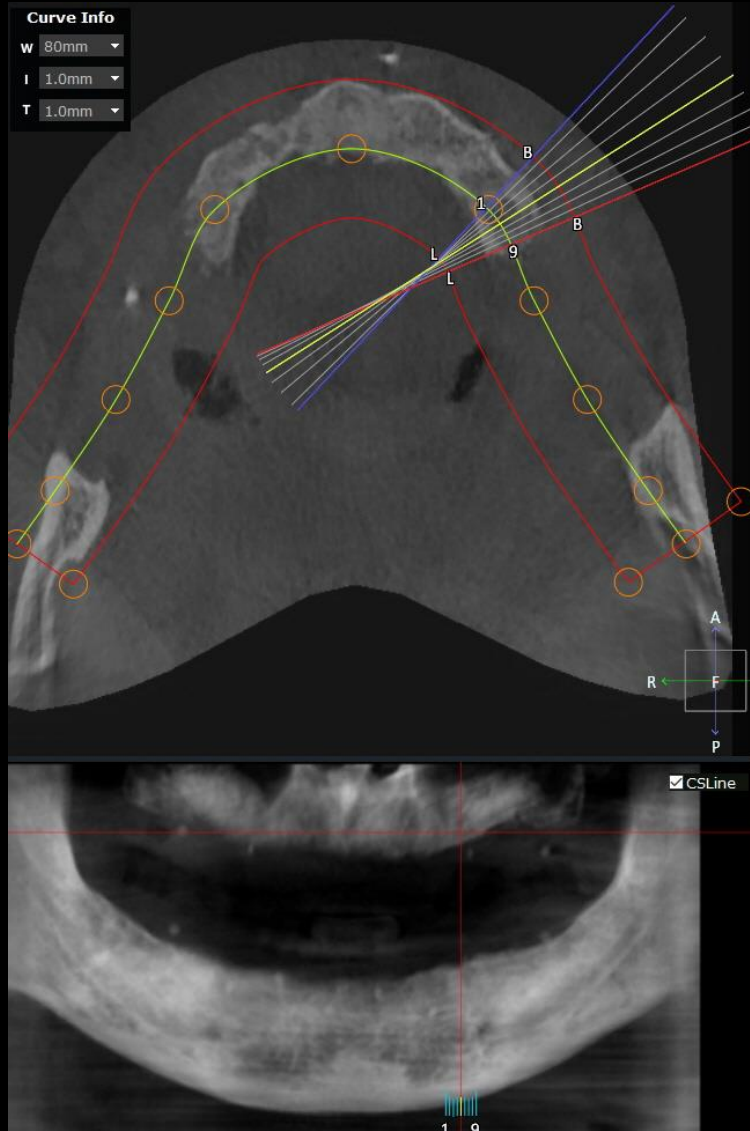
Past dental history

#10 Sinus elevation



Past dental history

#20 Sinus elevation

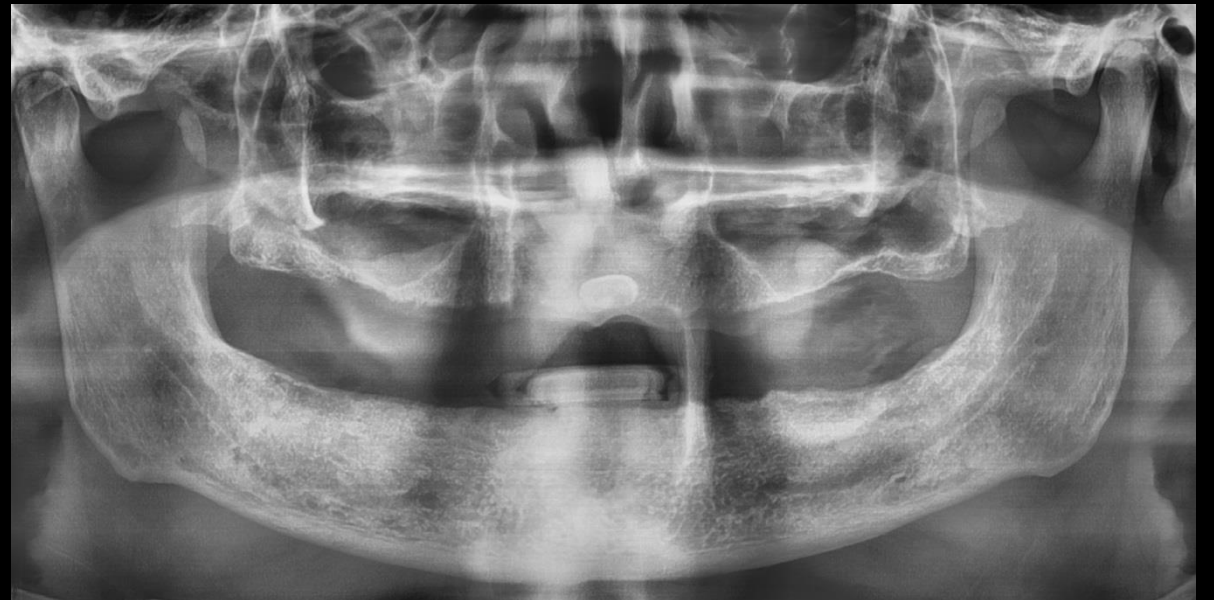
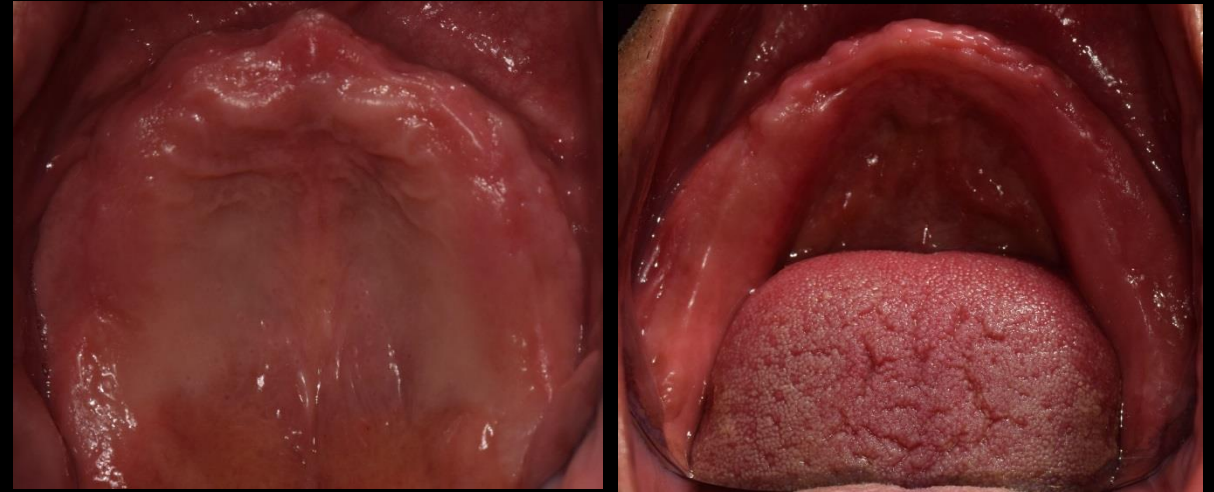
Today's Surgery Plan

12, 13, 14, 16, 17,
22, 23, 24, 26, 27,
33, 34, 36, 37,
43, 44, 46, 47

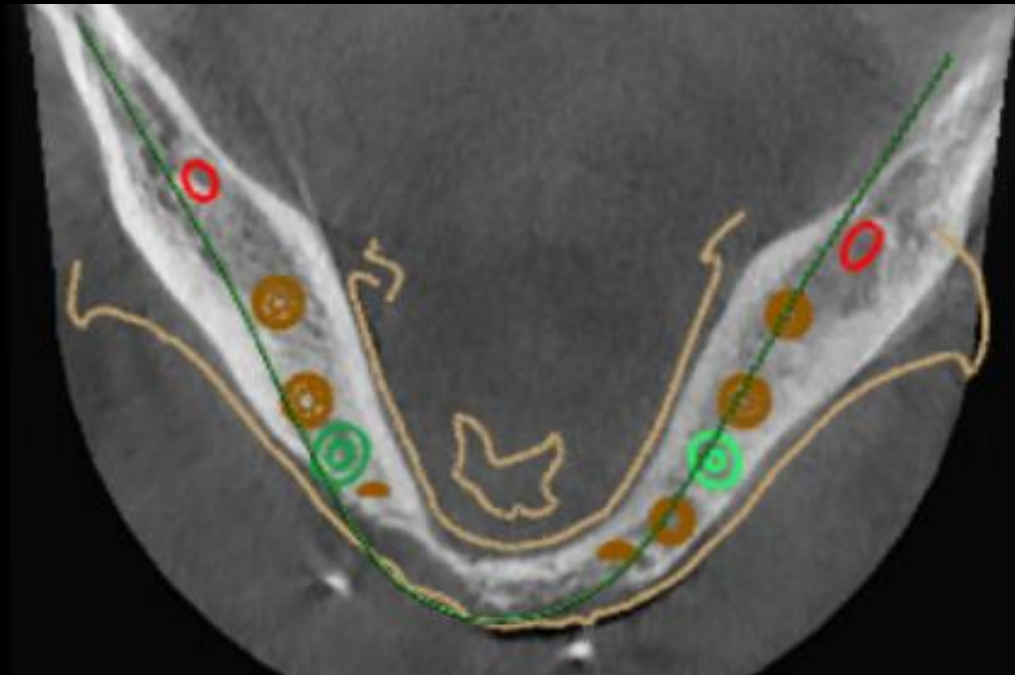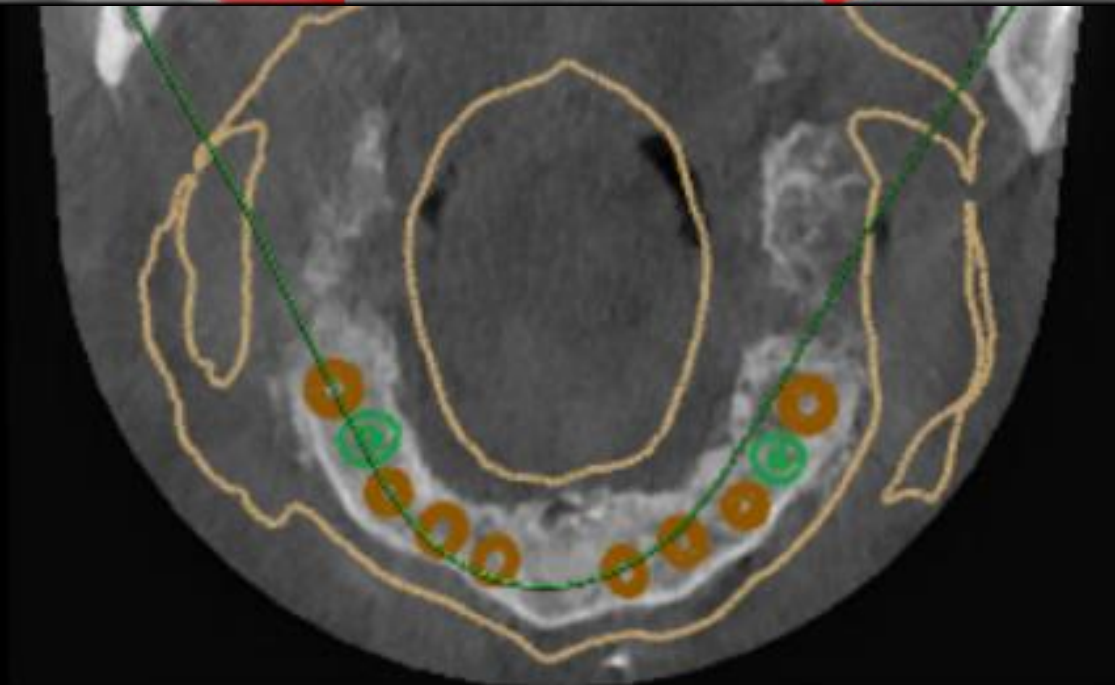
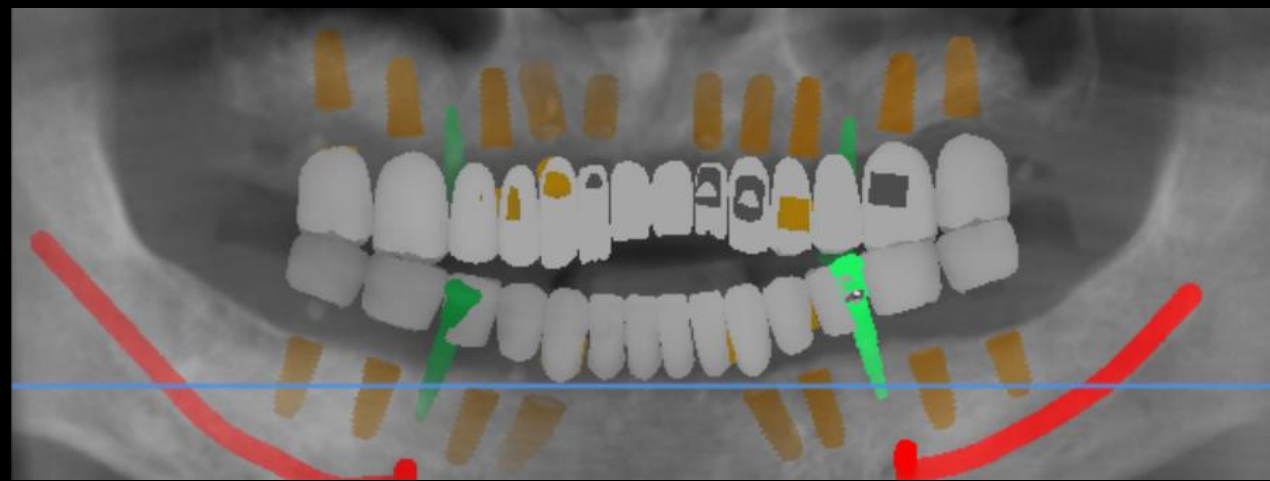
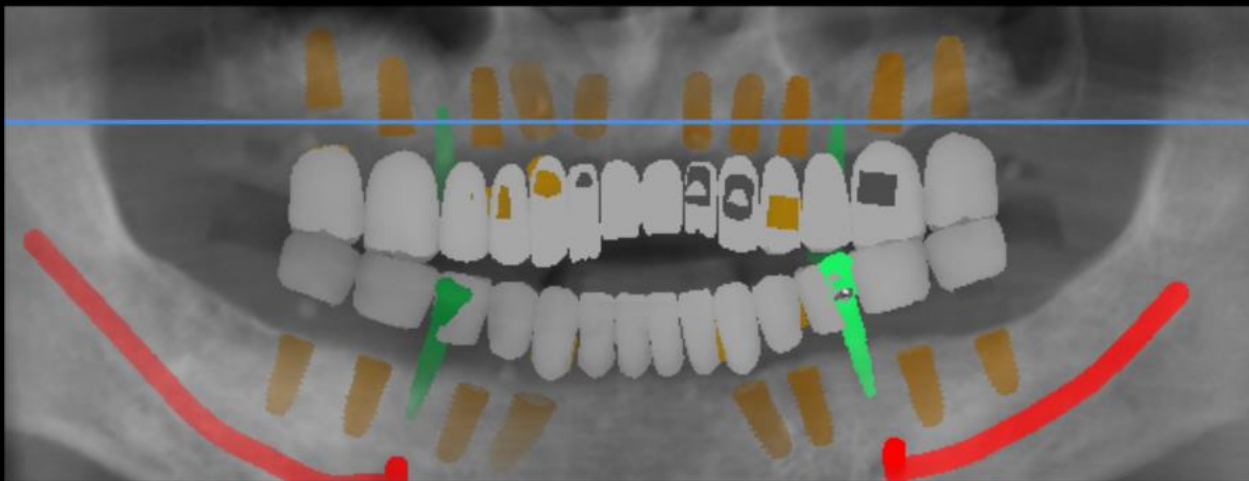
Implant placement
using Dentium Digital Guide

Provisional Restoration



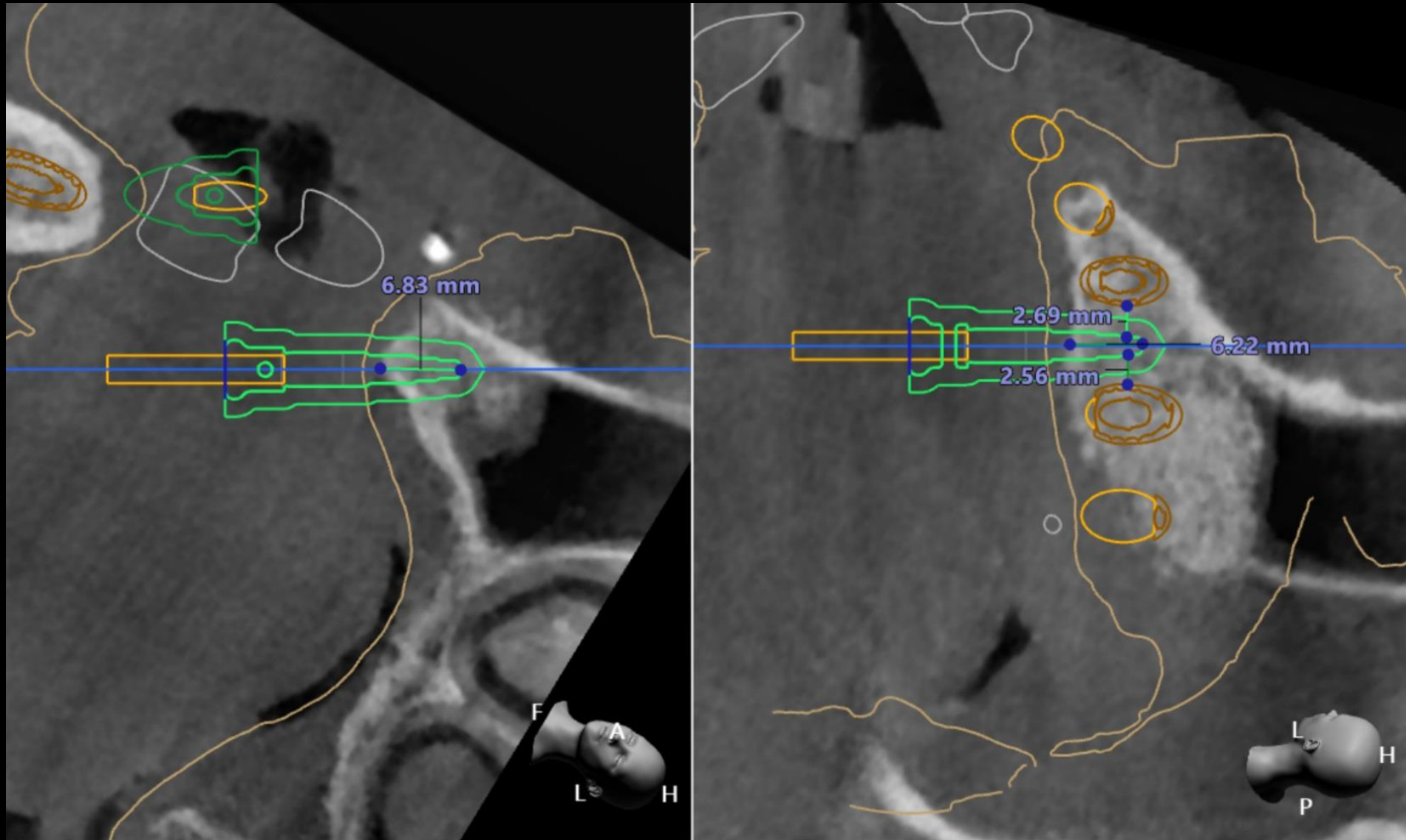
Pt. Park (55/Male)

Pre-op(2021-01-02)



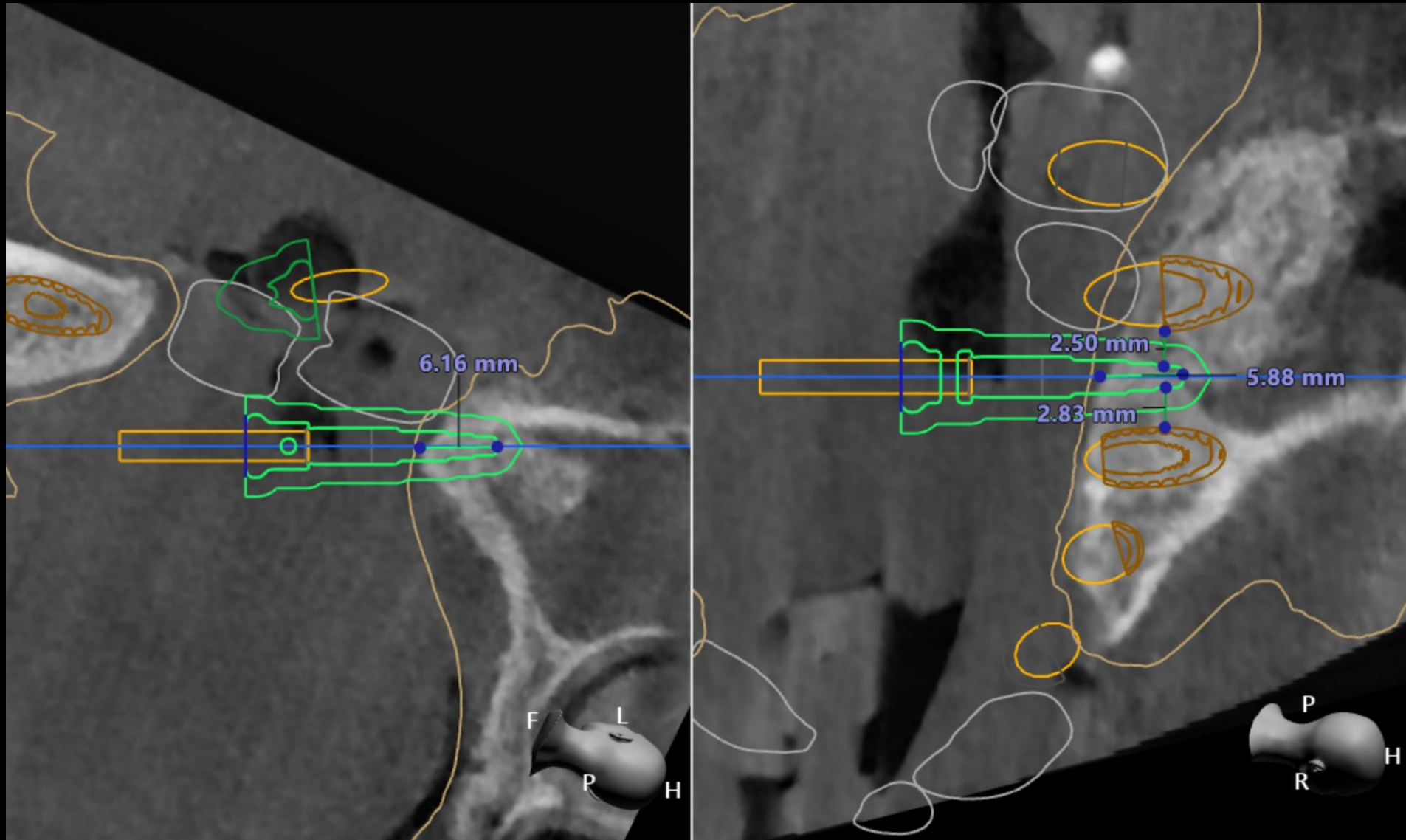
Implant Planning

#15 Anchor Pin(6mm)



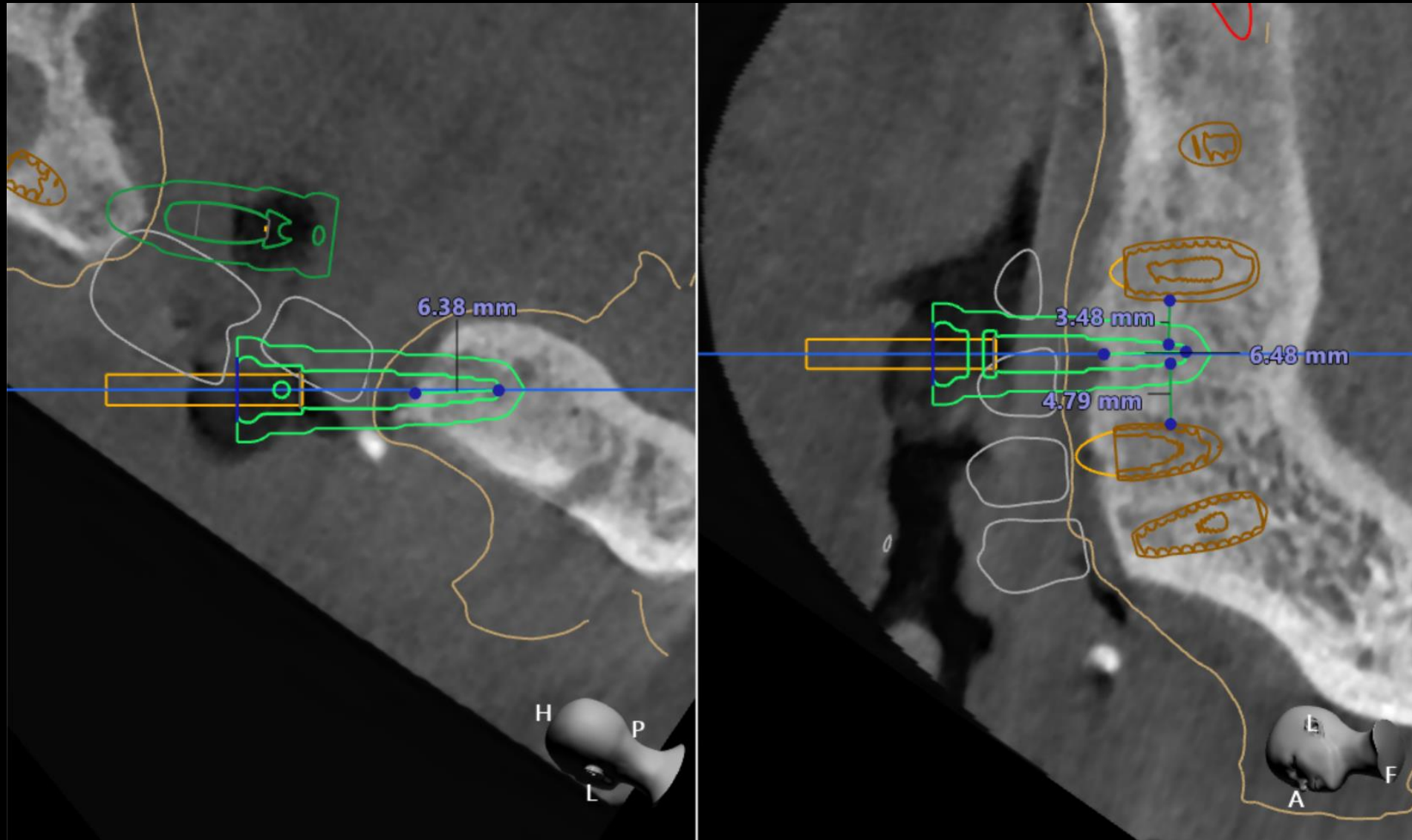
Implant Planning

#25 Anchor Pin(6mm)



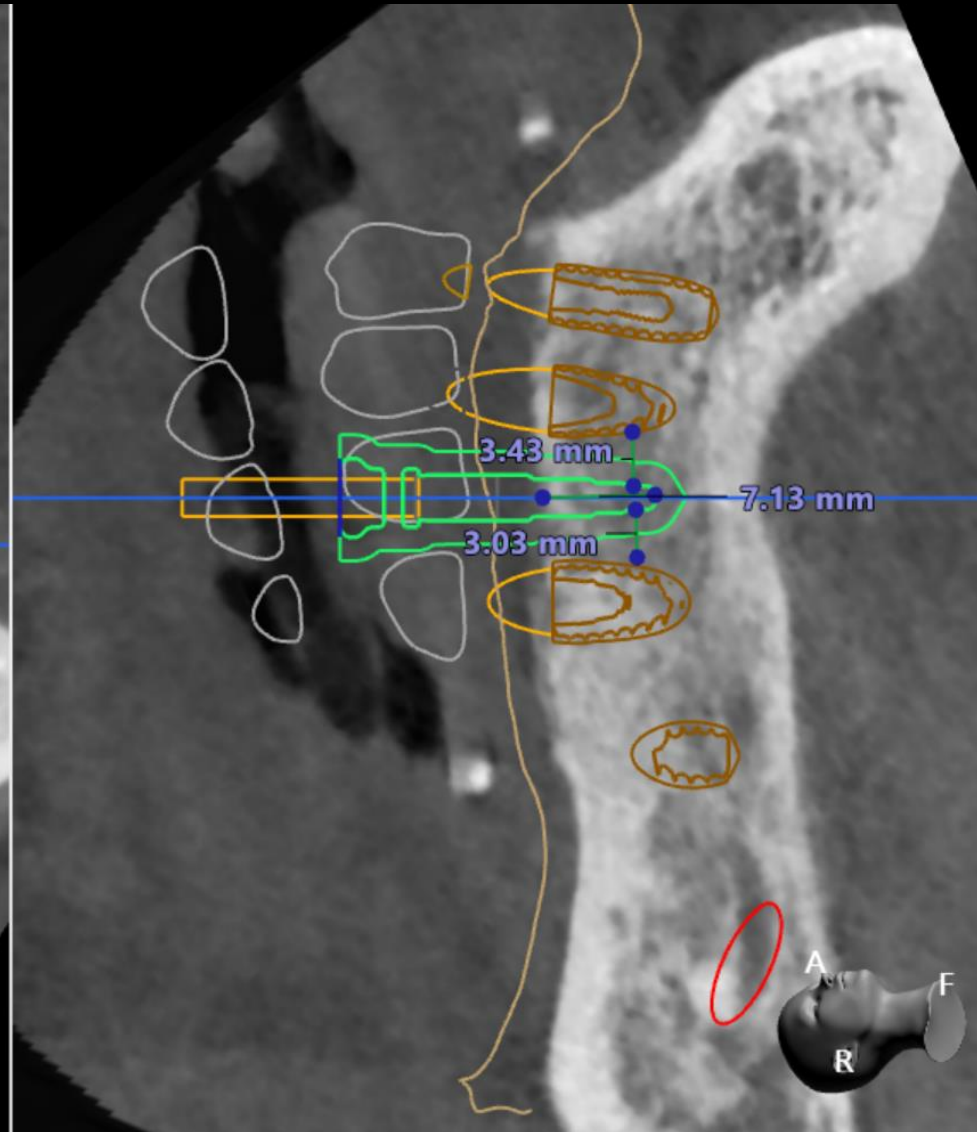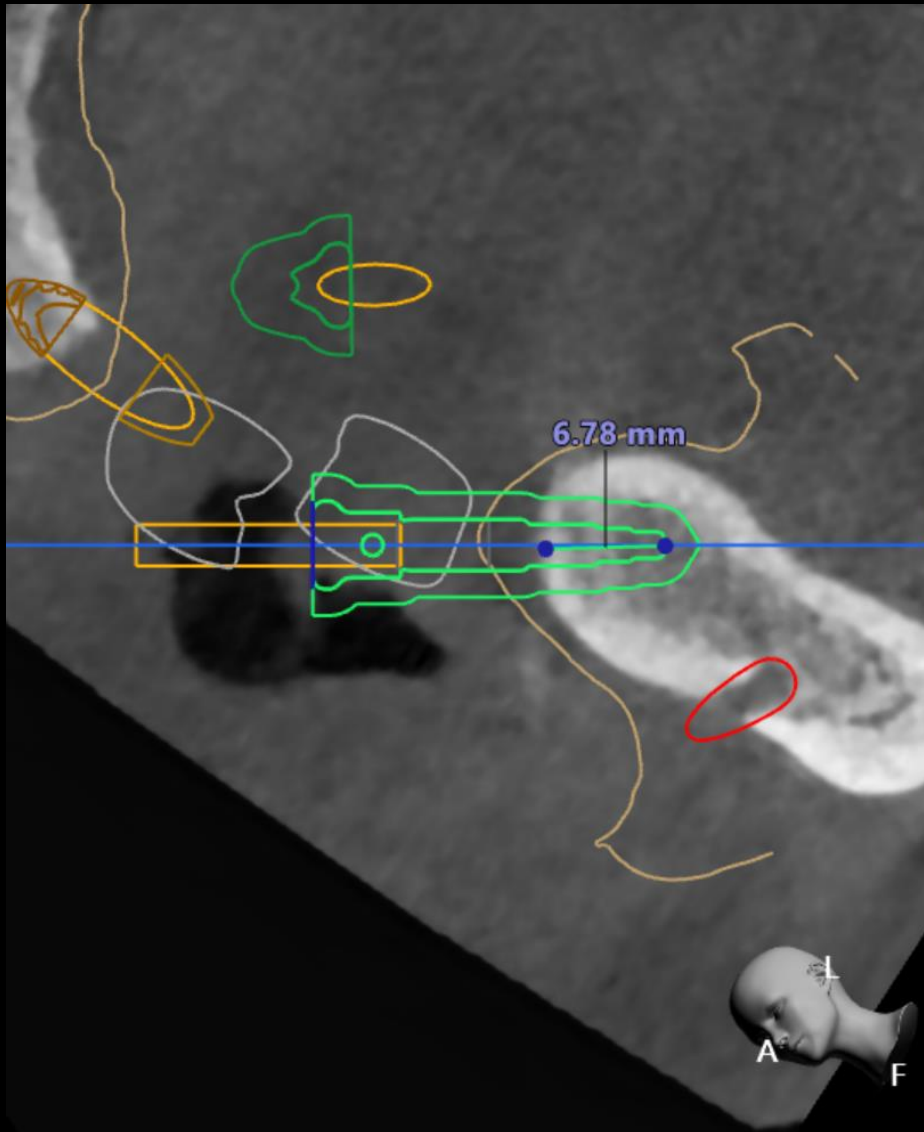
Implant Planning

#35 Anchor Pin(6mm)



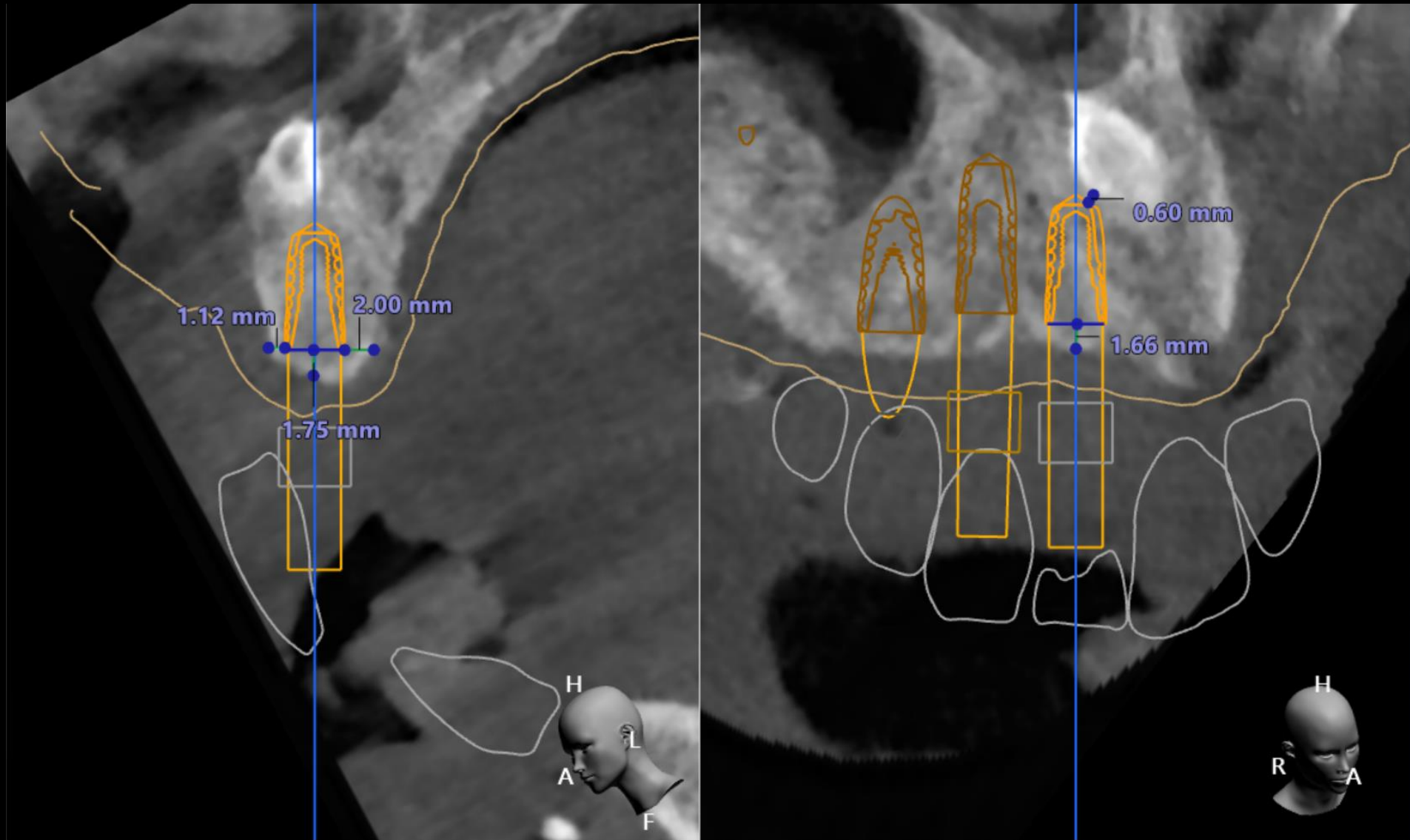
Implant Planning

#45 Anchor Pin(6mm)



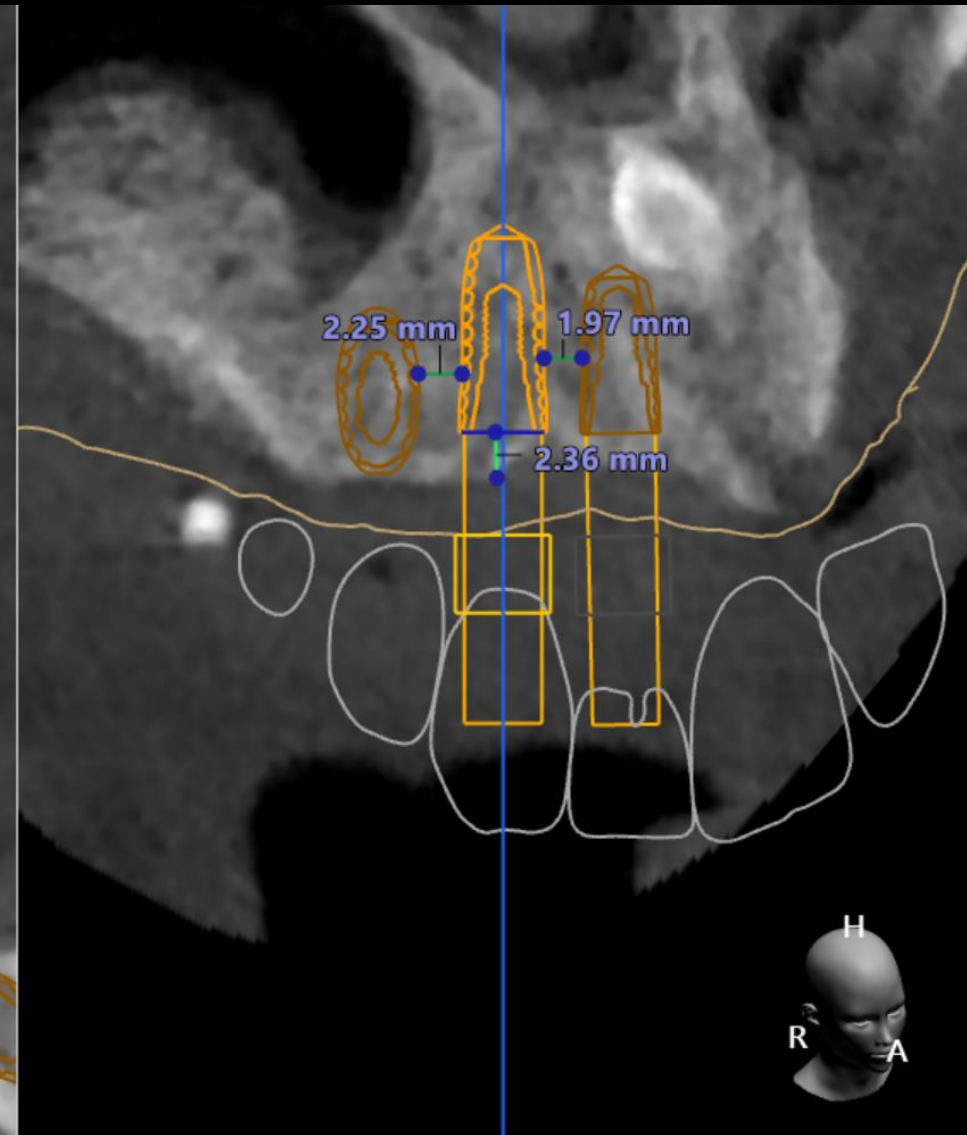
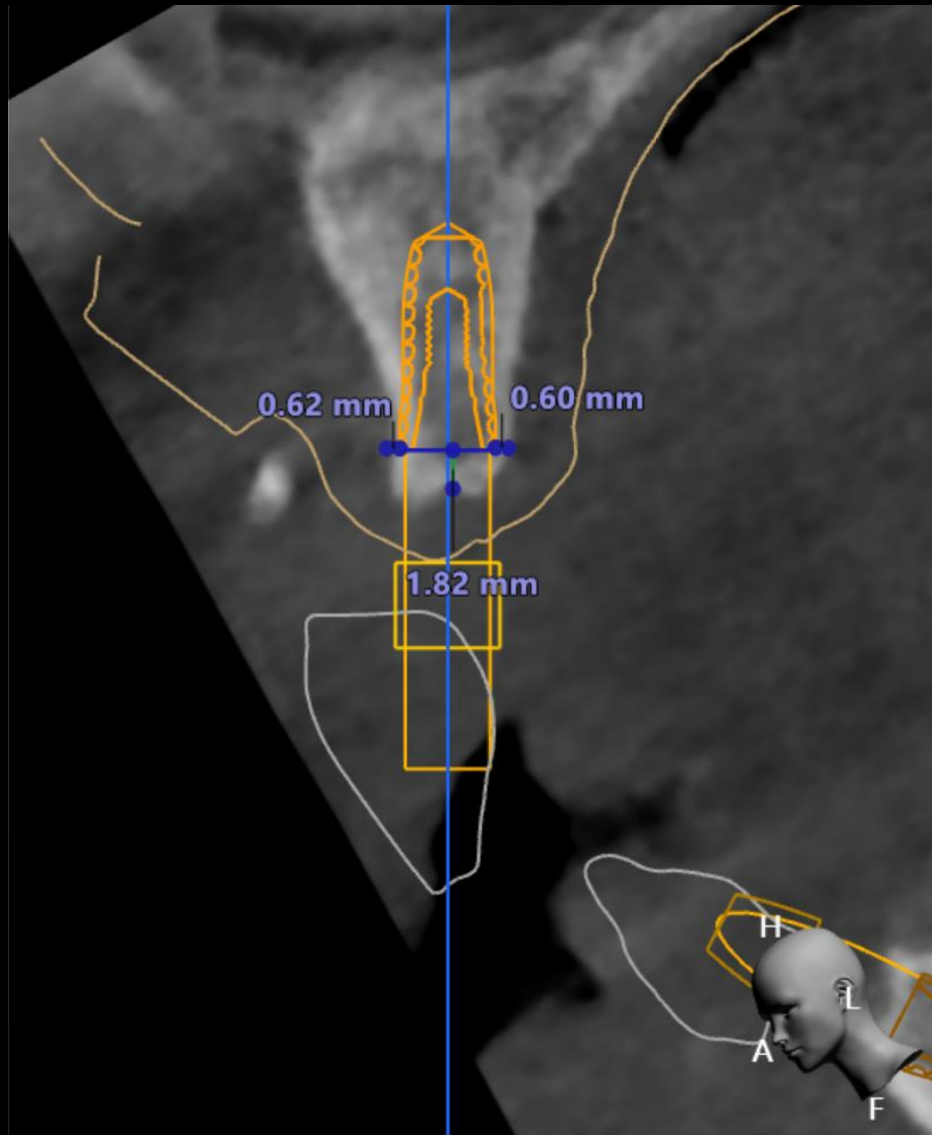
Implant Planning

#12 (3608)



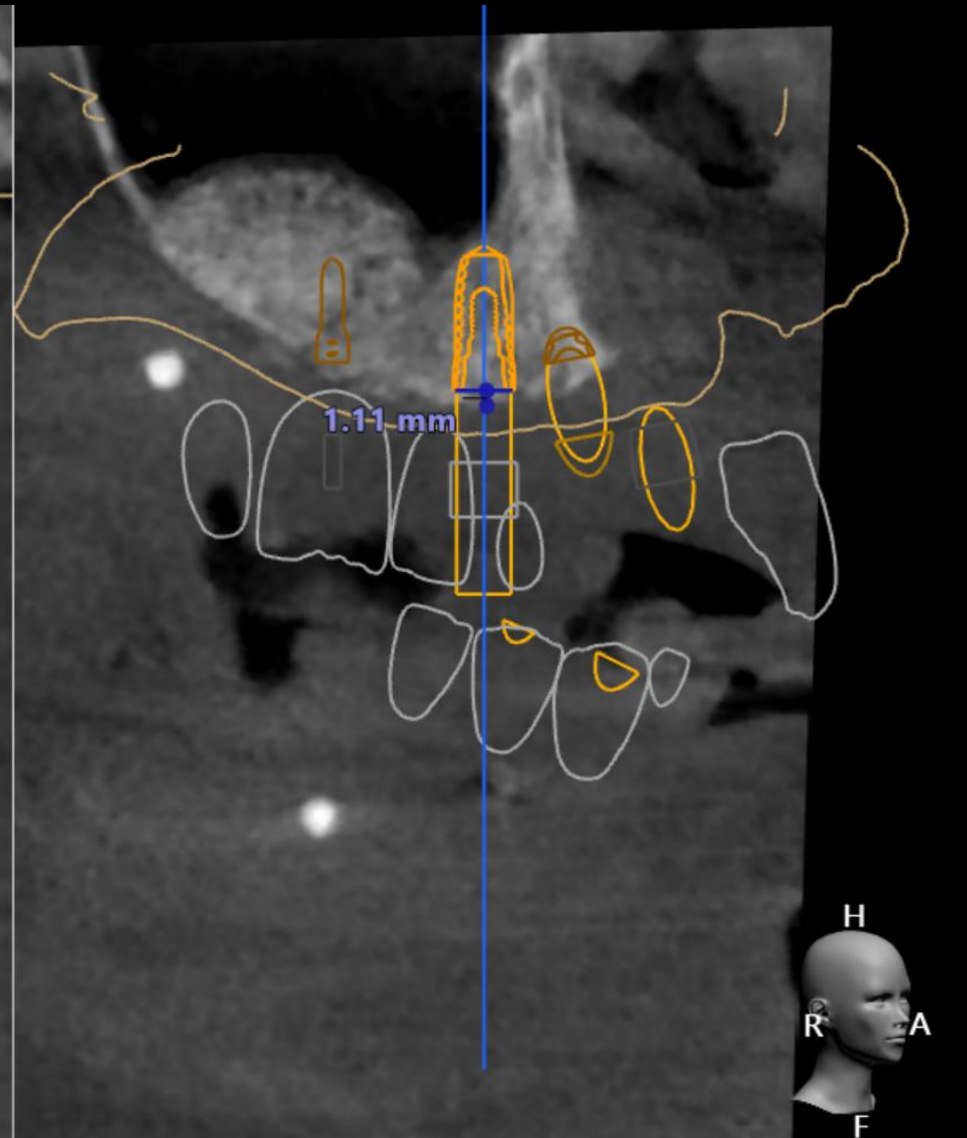
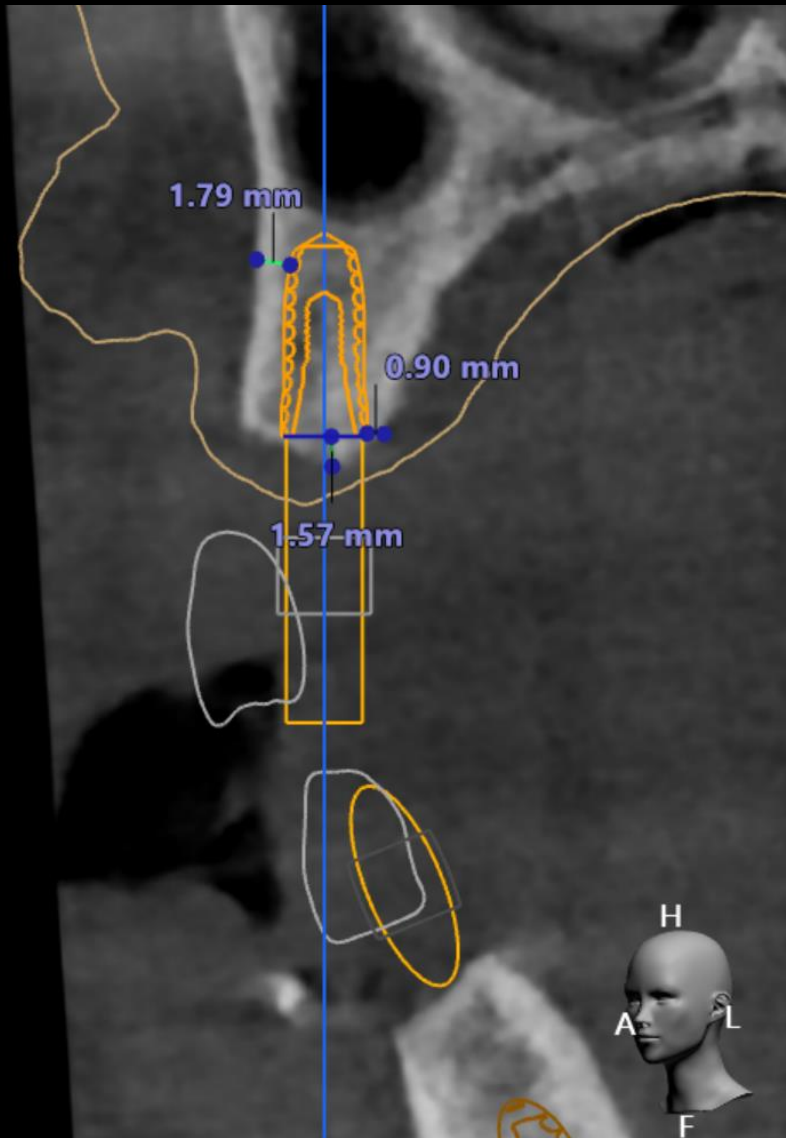
Implant Planning

#13 (4010)



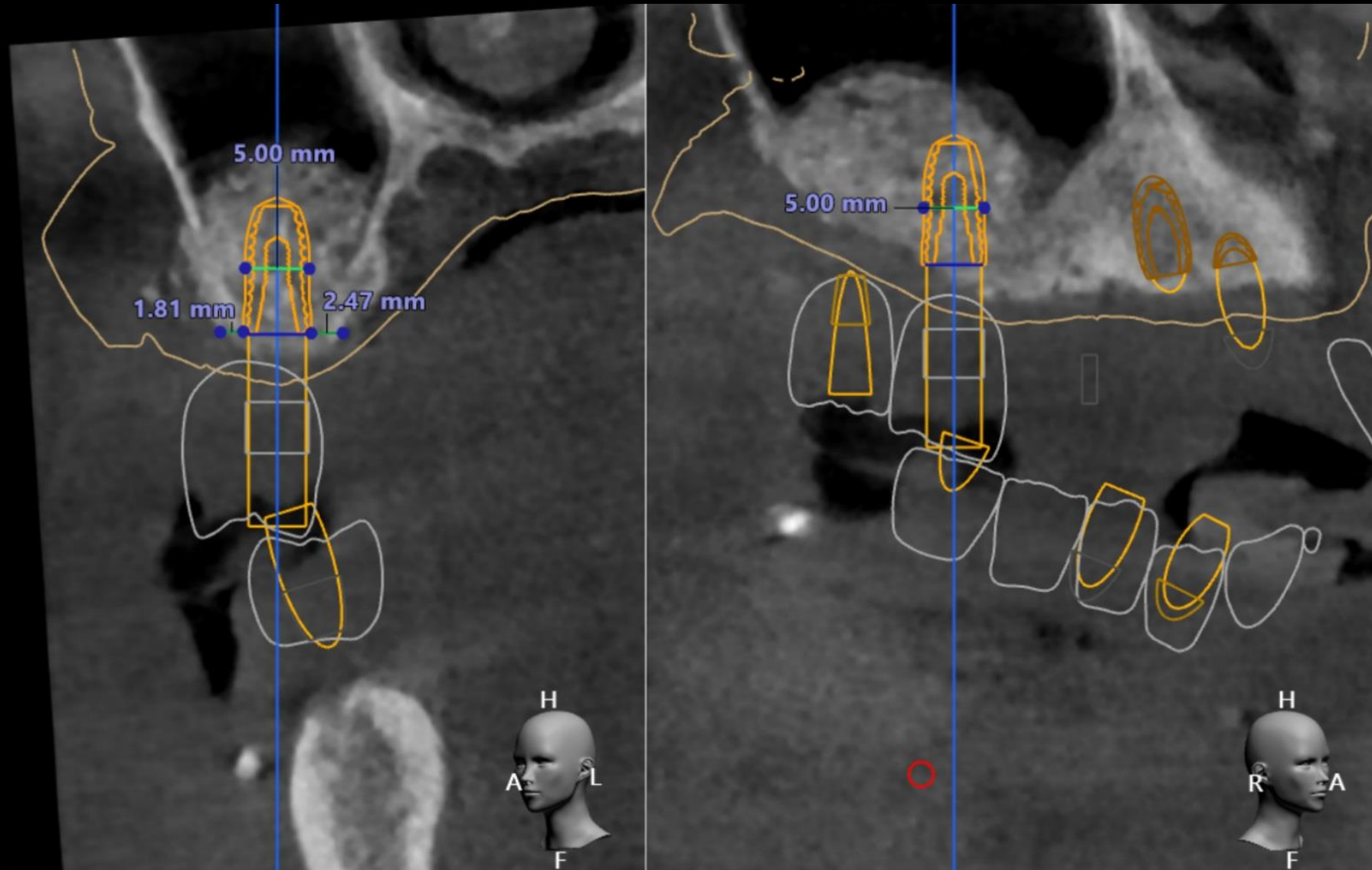Implant Planning

#14 (4010)



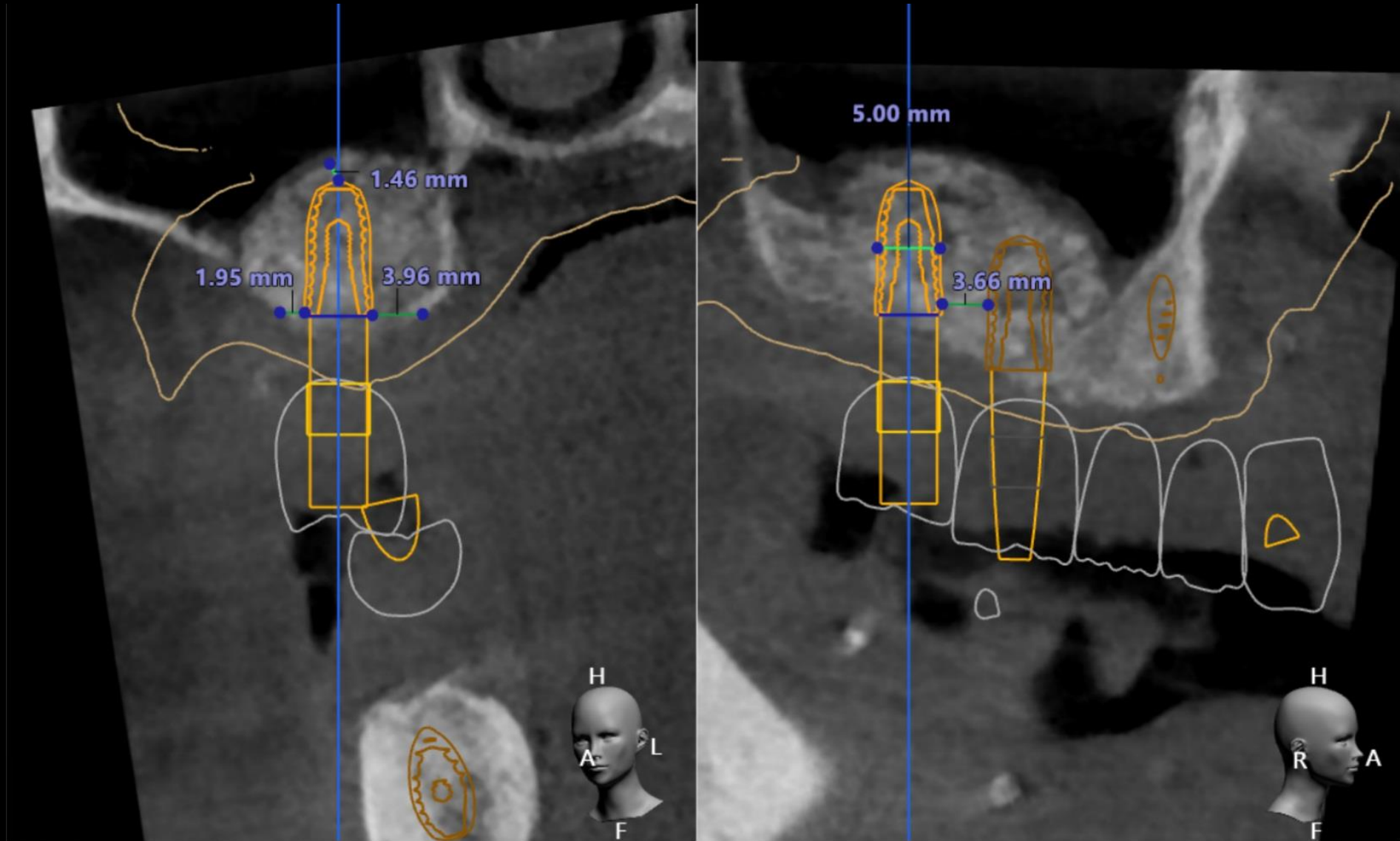
Implant Planning

#16 (5010)



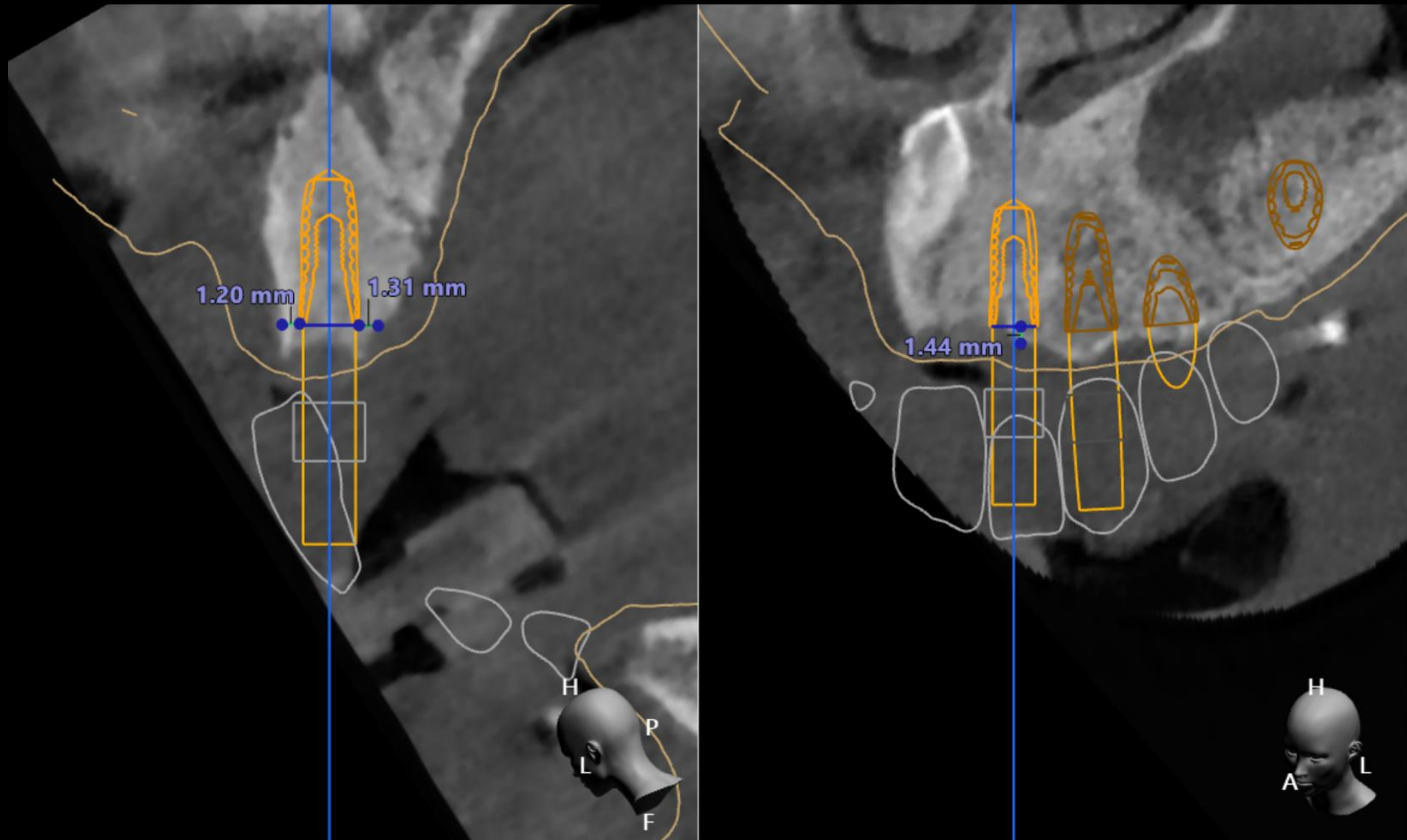
Implant Planning

#17 (5010)



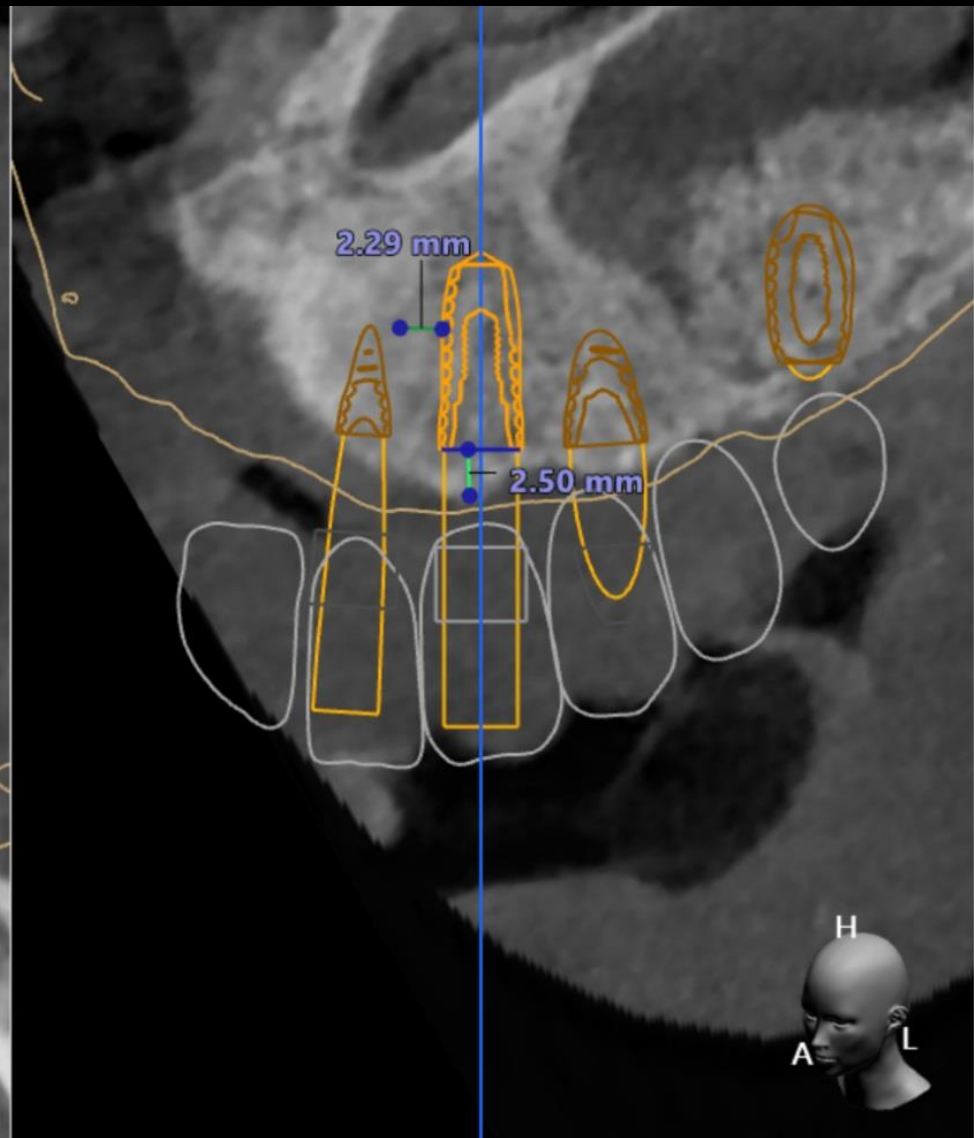
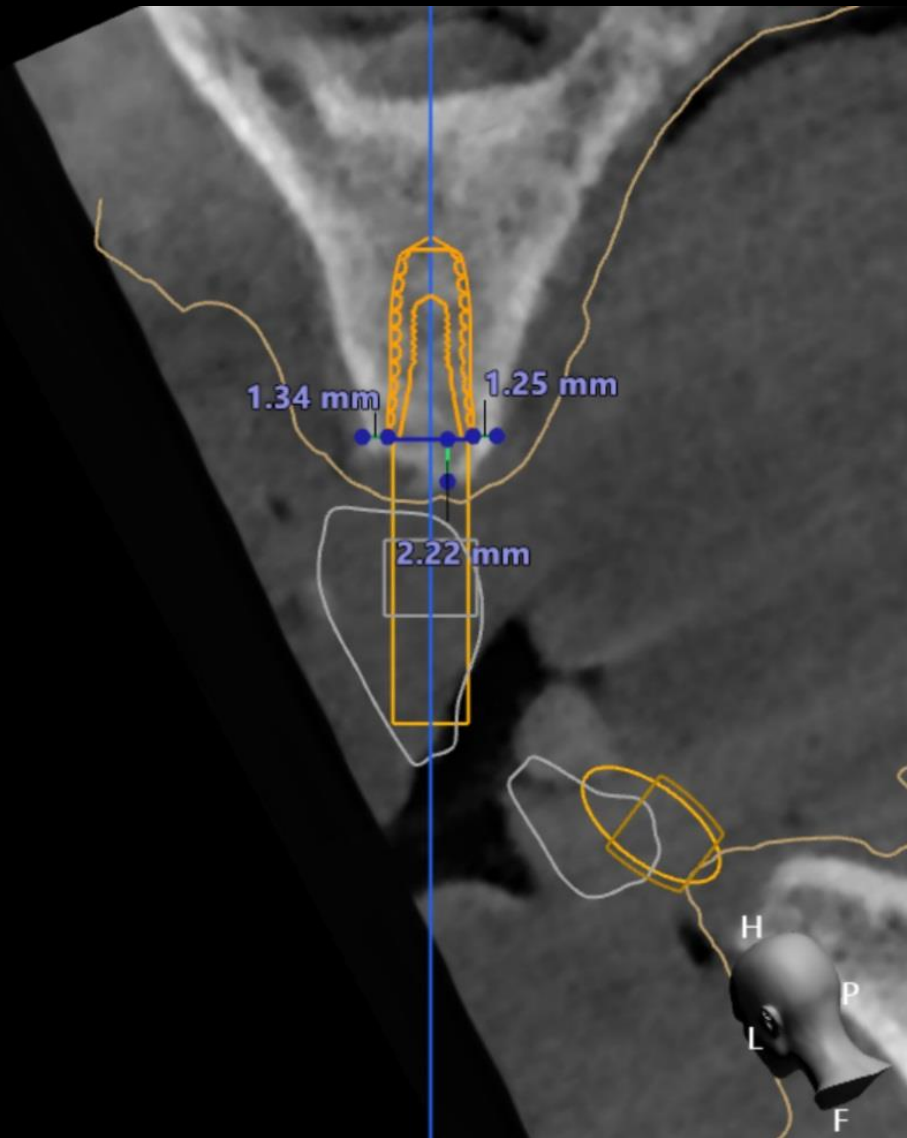
Implant Planning

#22 (3610)



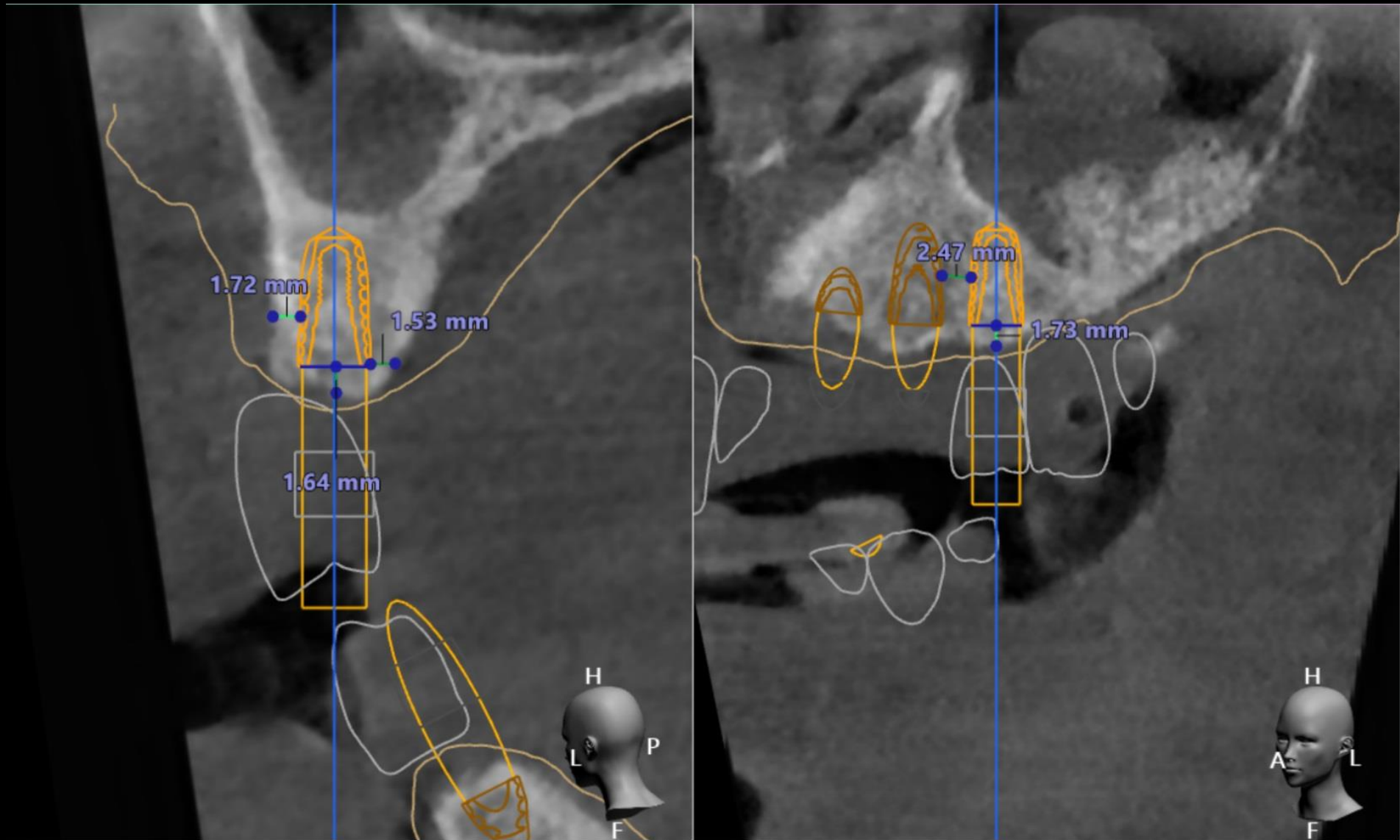
Implant Planning

#23 (4010)



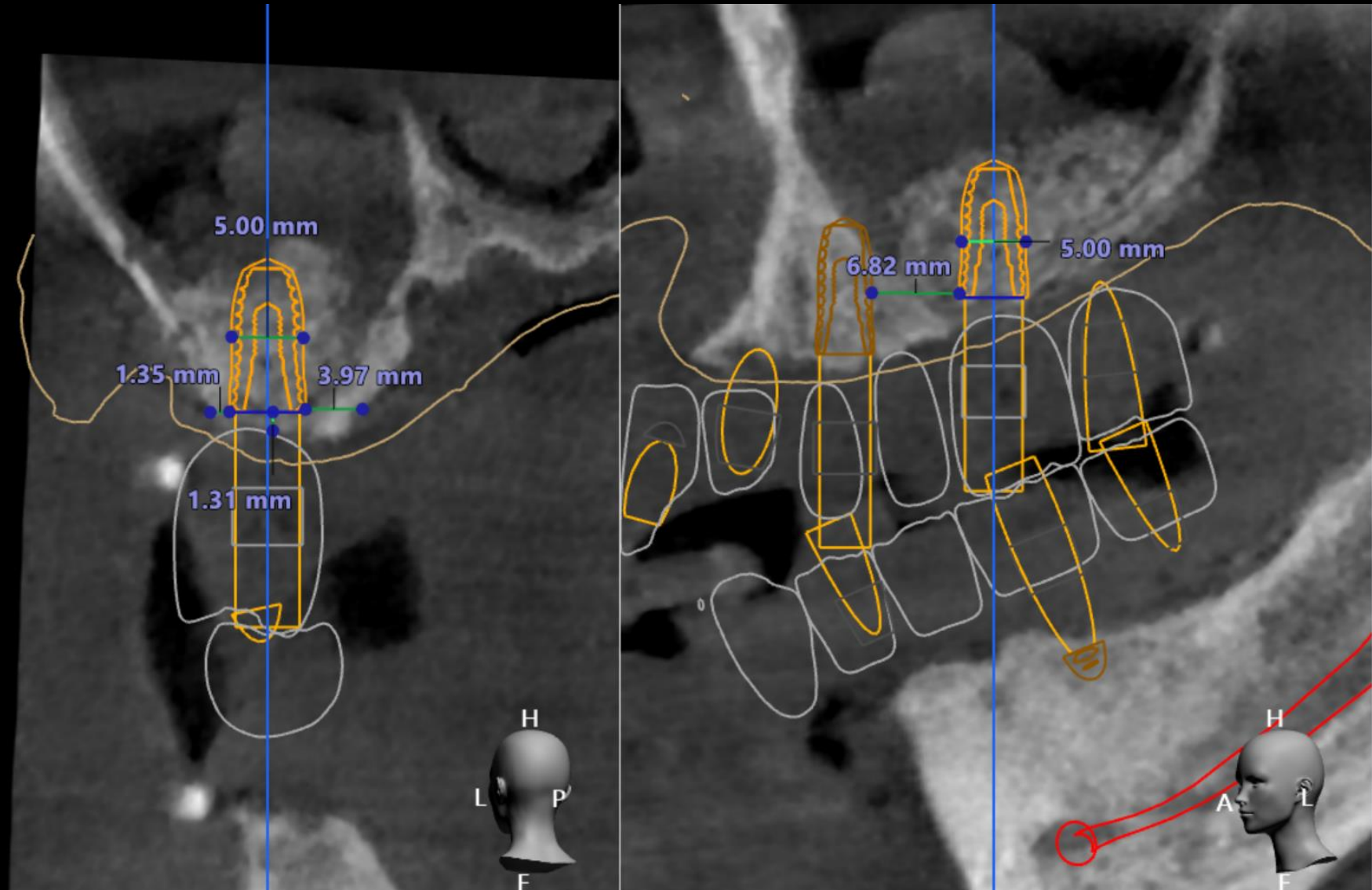
Implant Planning

#24 (4010)



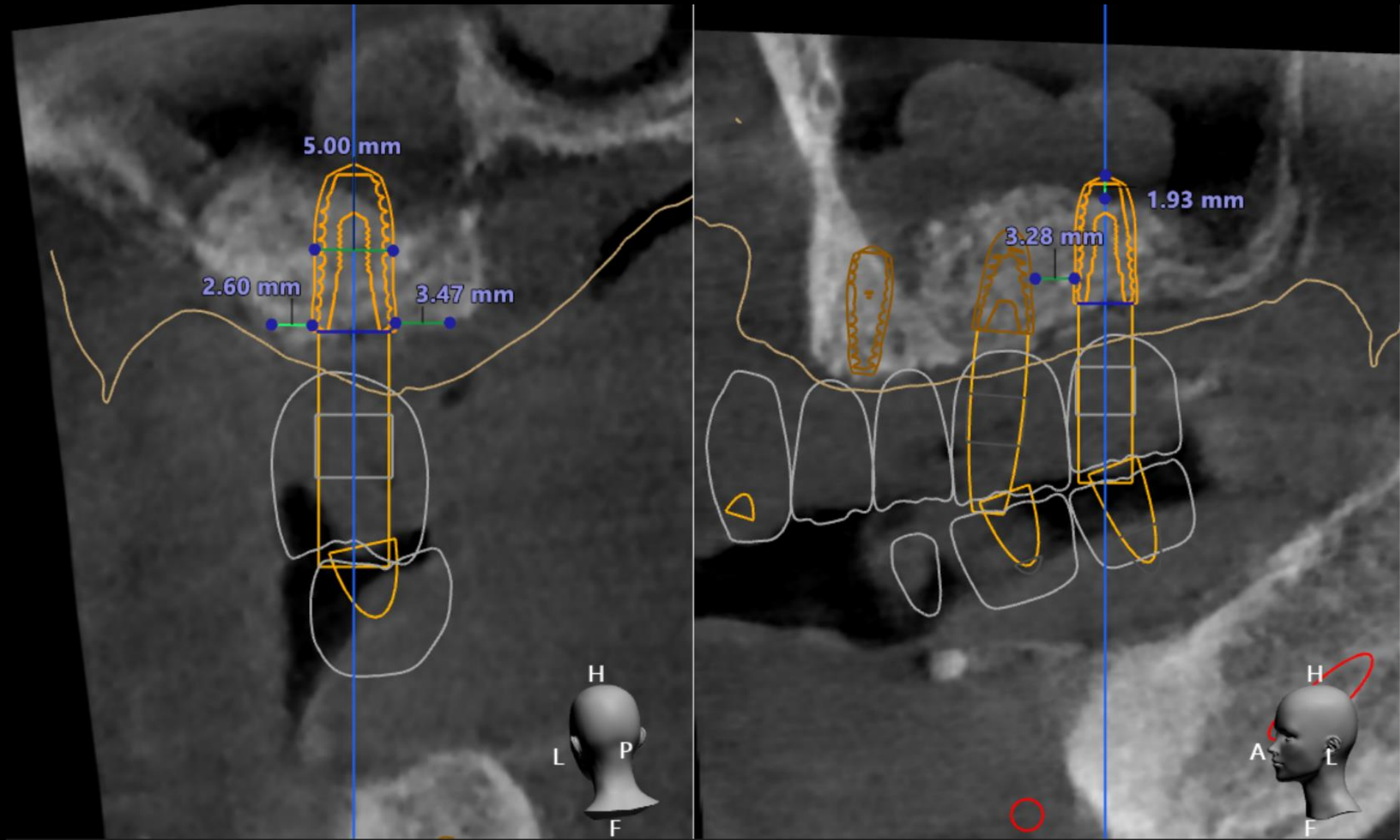
Implant Planning

#26 (5010)



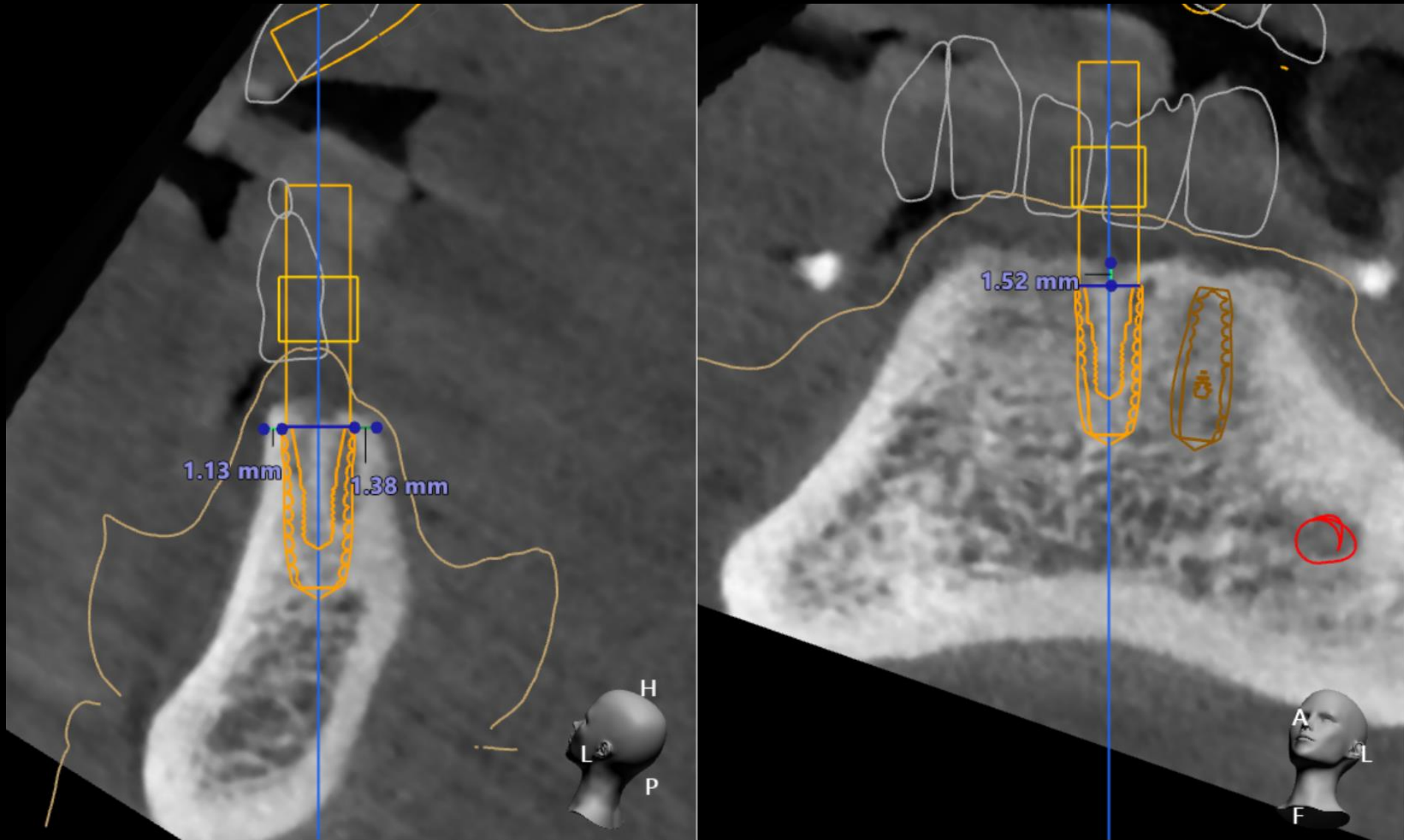
Implant Planning

#27 (5010)




Implant Planning

#33 (4010)



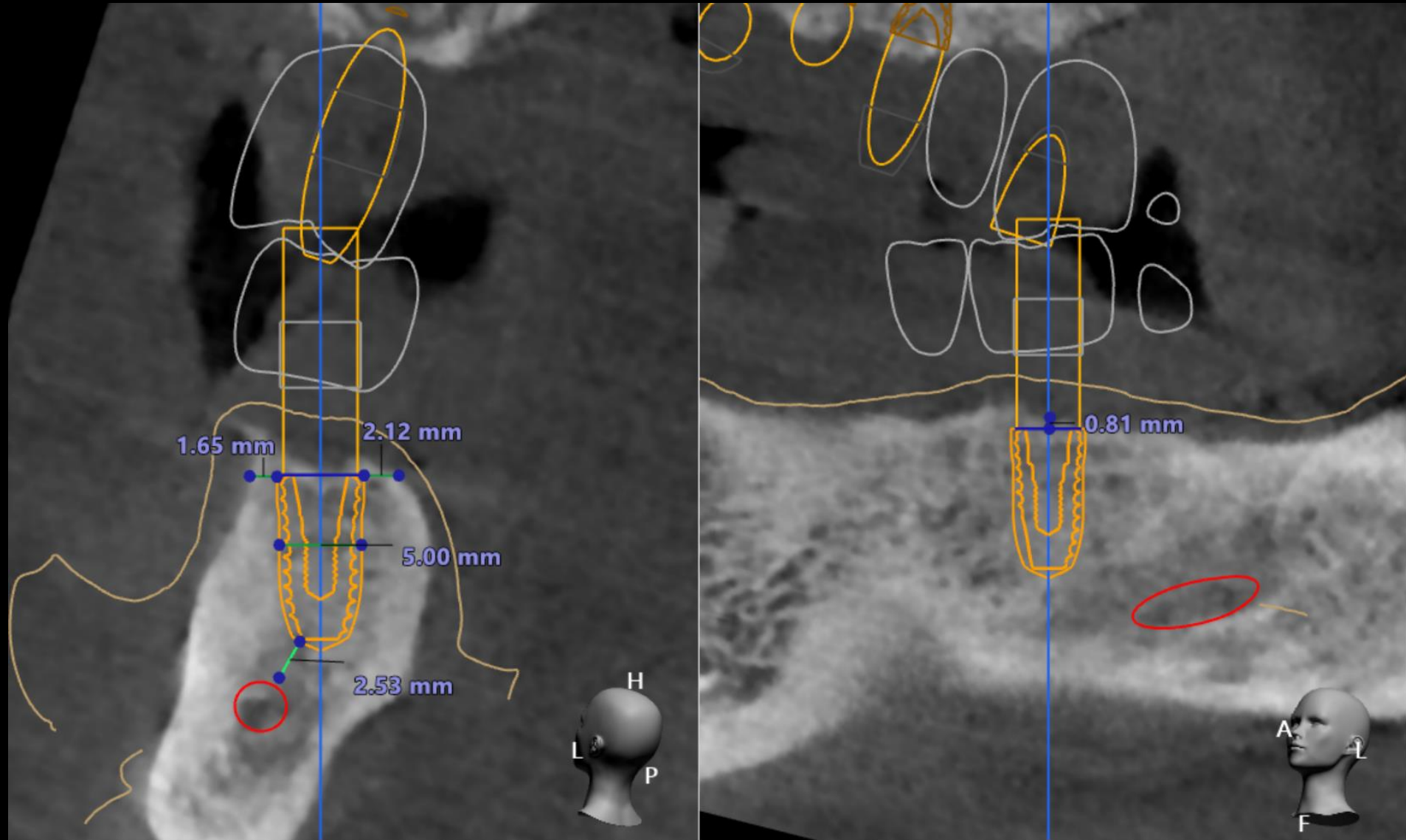
Implant Planning

#34 (4010)



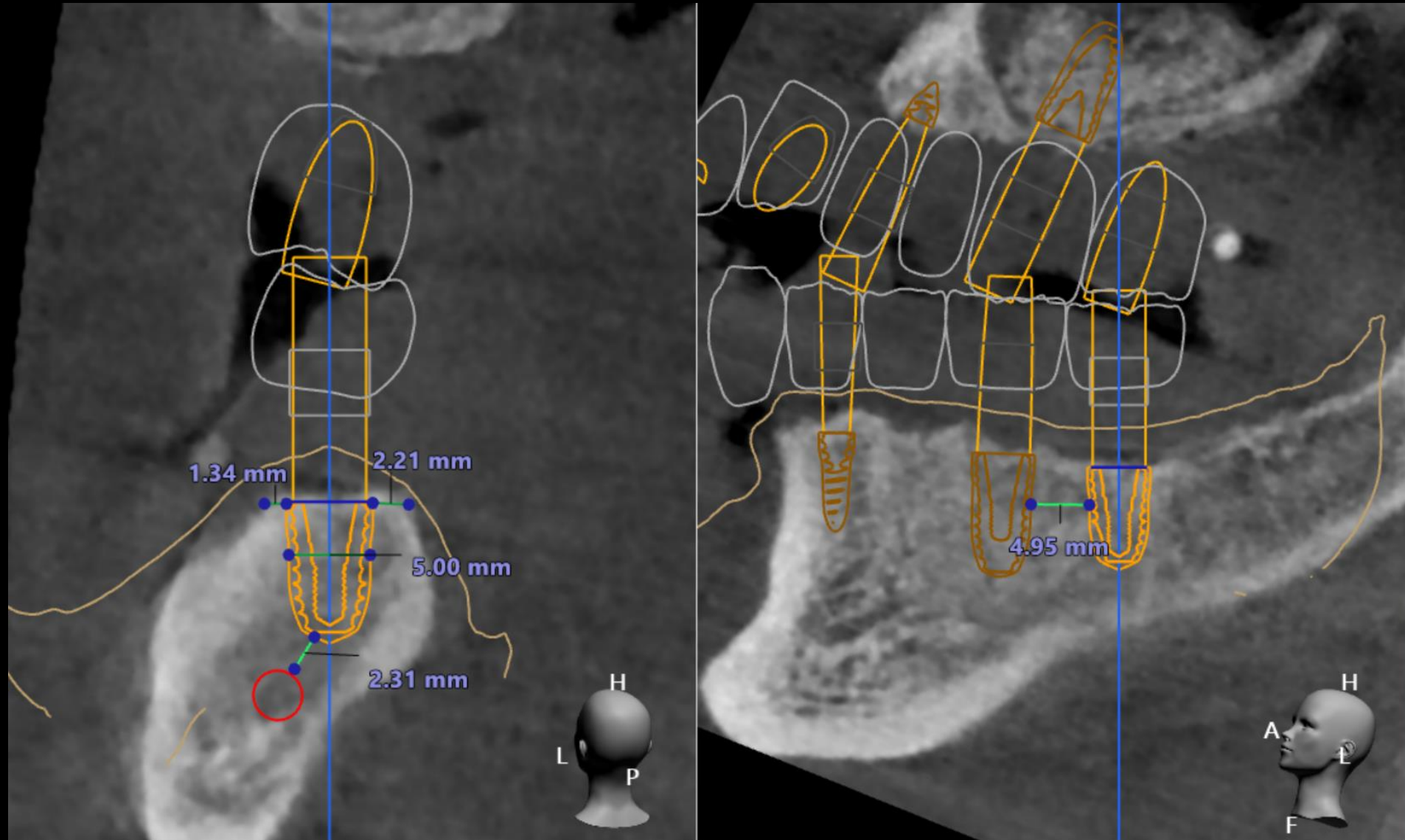
Implant Planning

#36 (5010)




Implant Planning

#37 (5010)



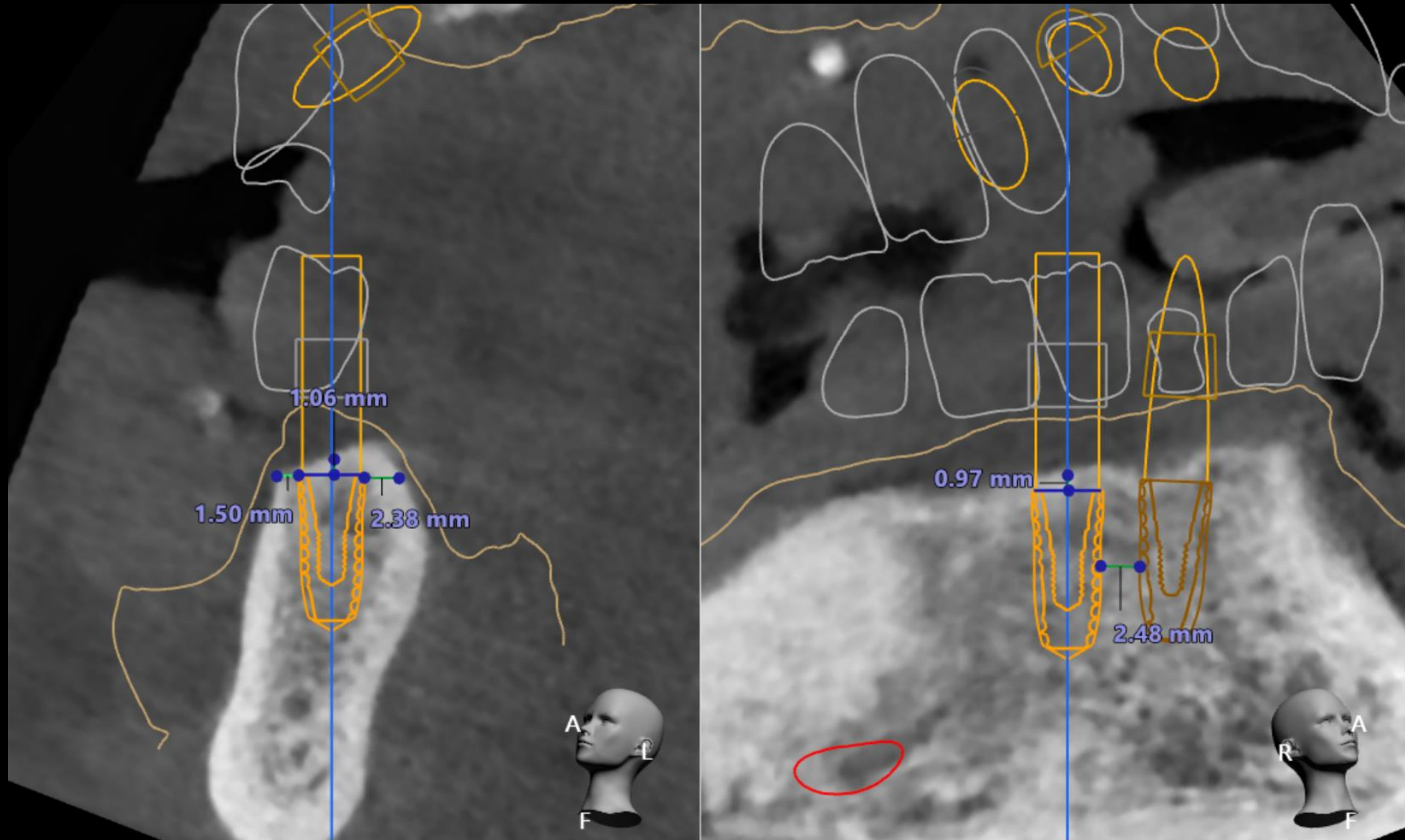
Implant Planning

#43 (4010)



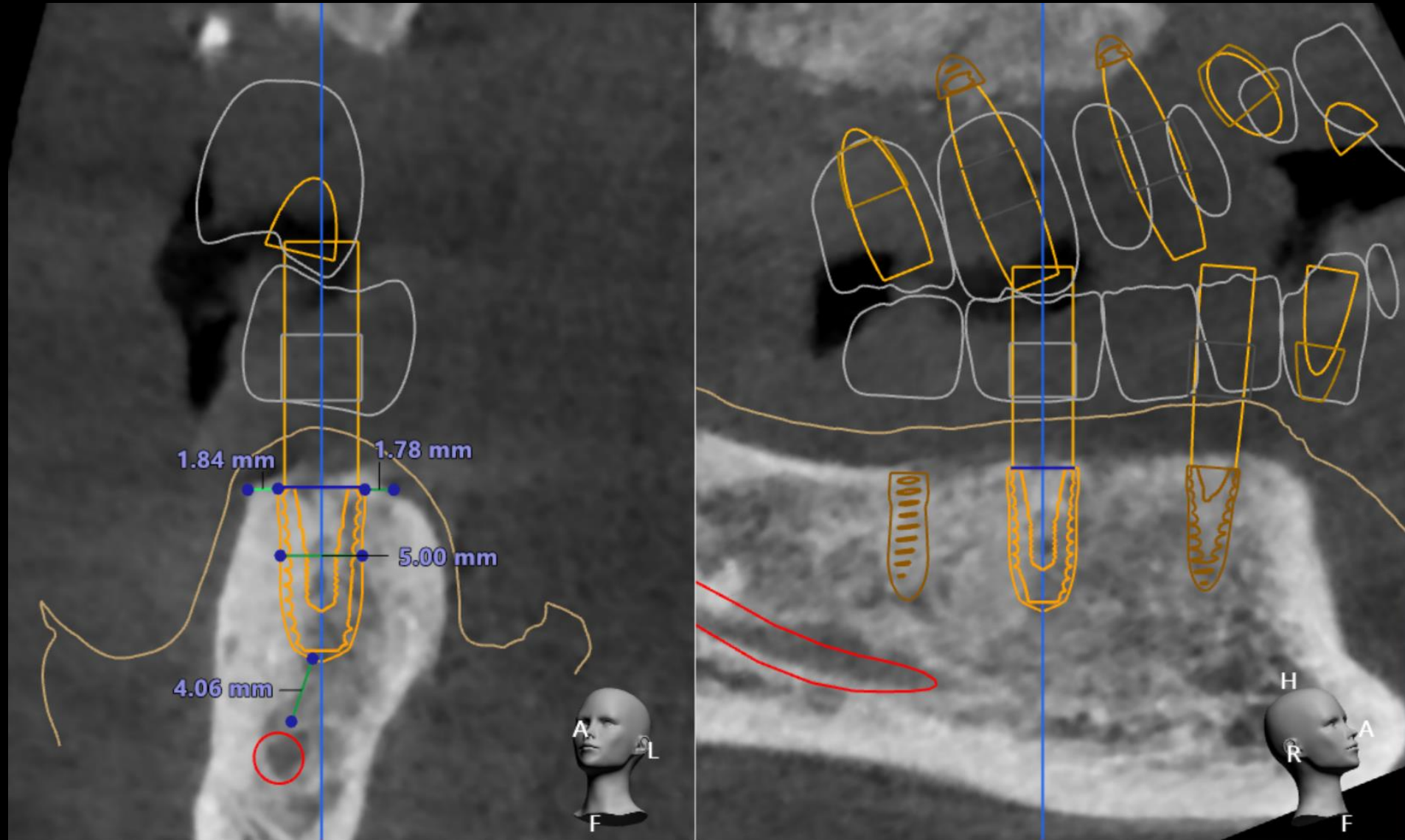
Implant Planning

#44 (4010)



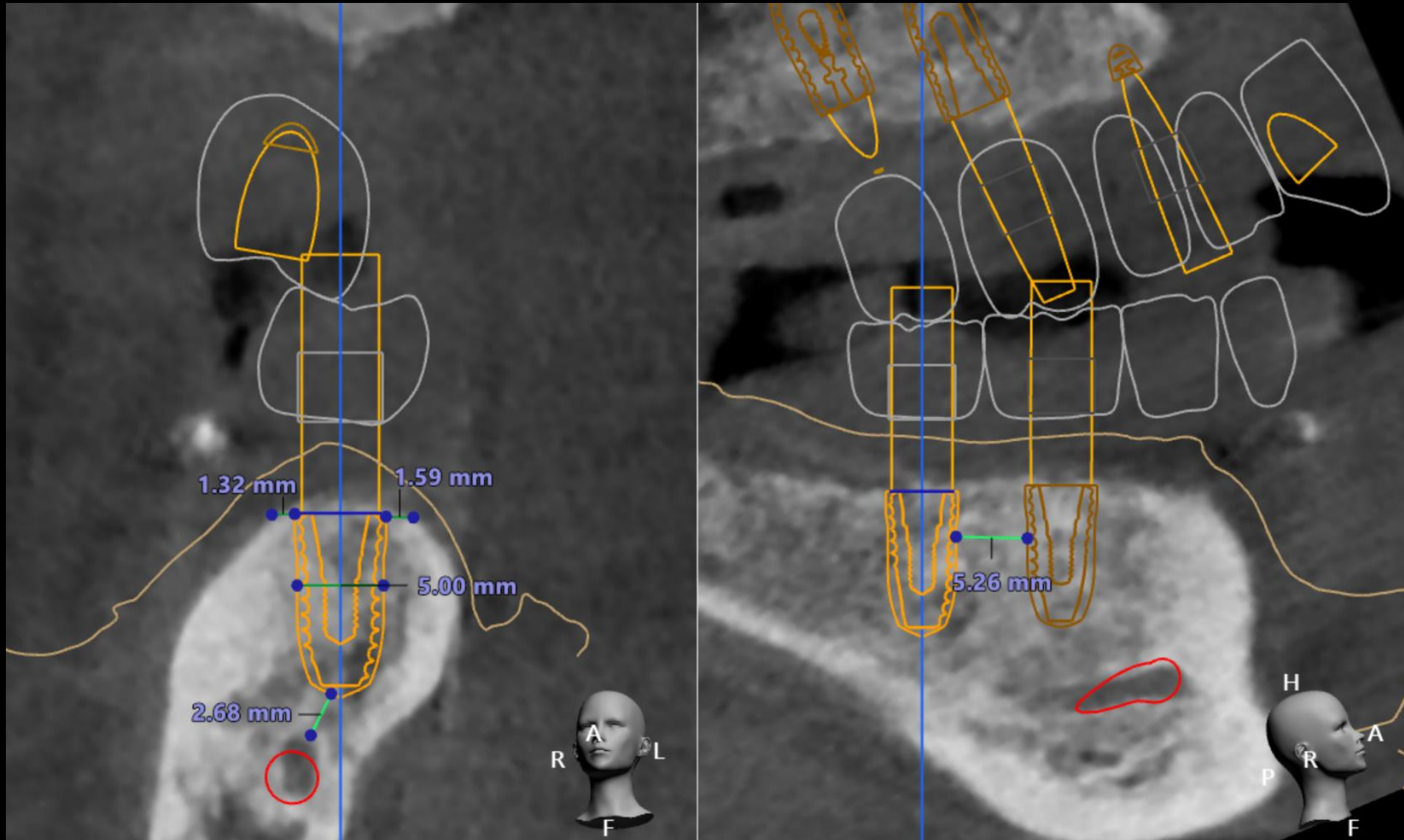
Implant Planning

#46 (5010)

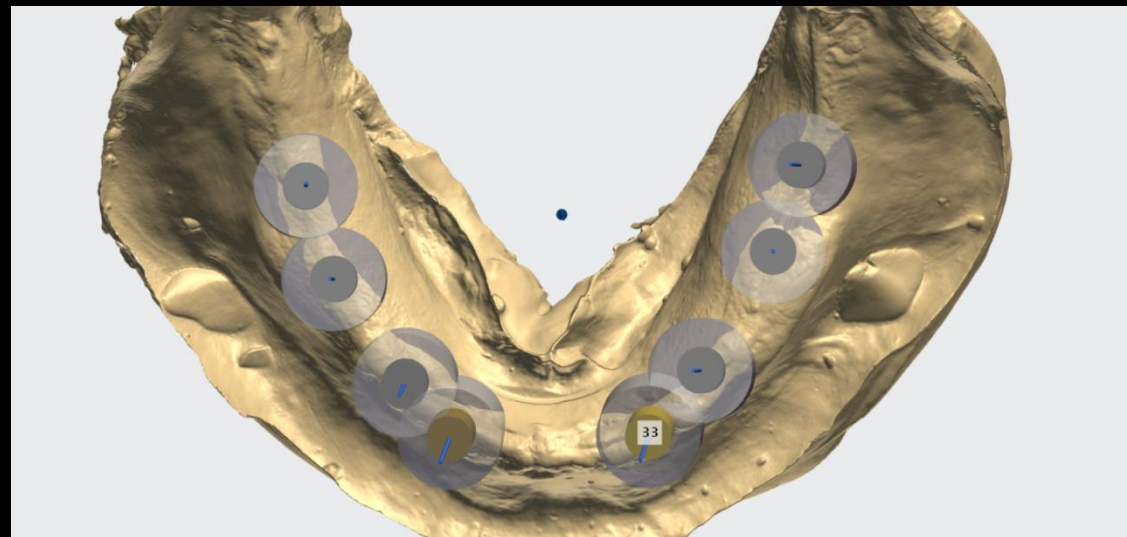
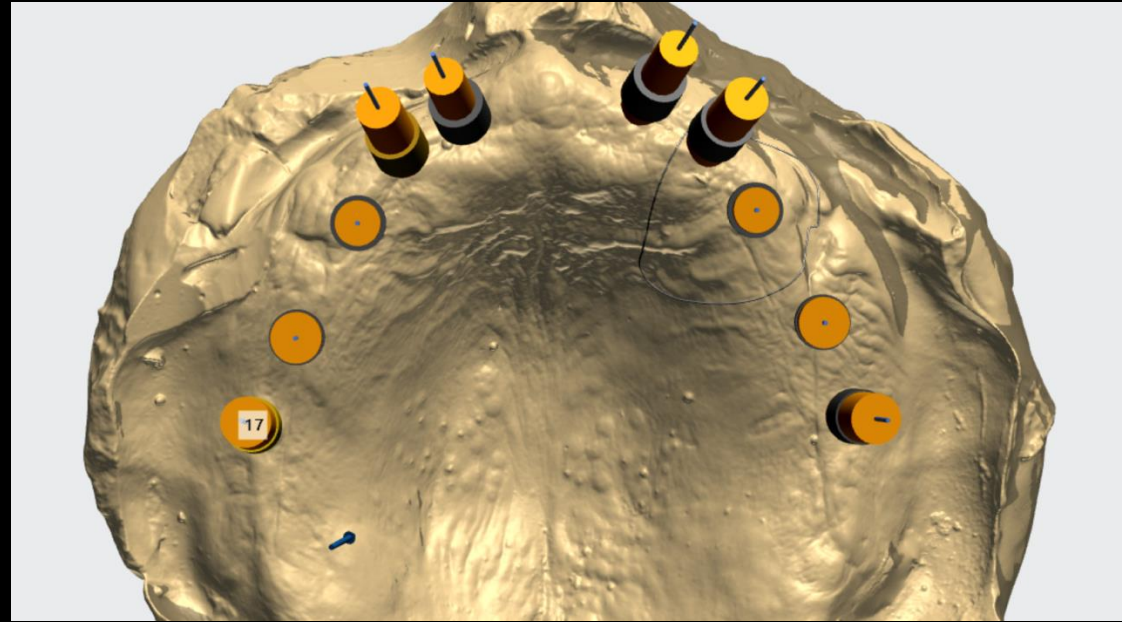


Implant Planning

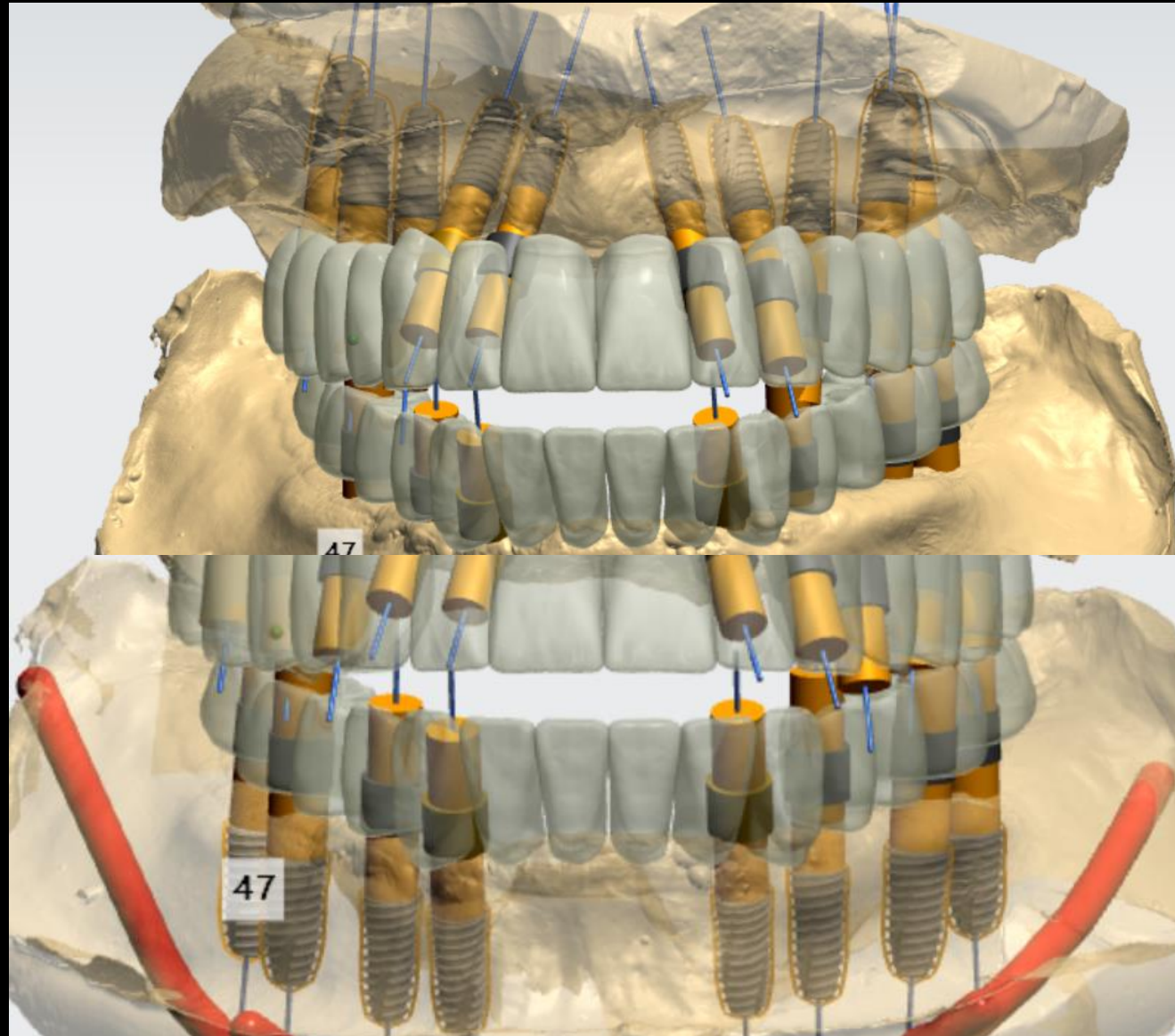
#47 (5010)



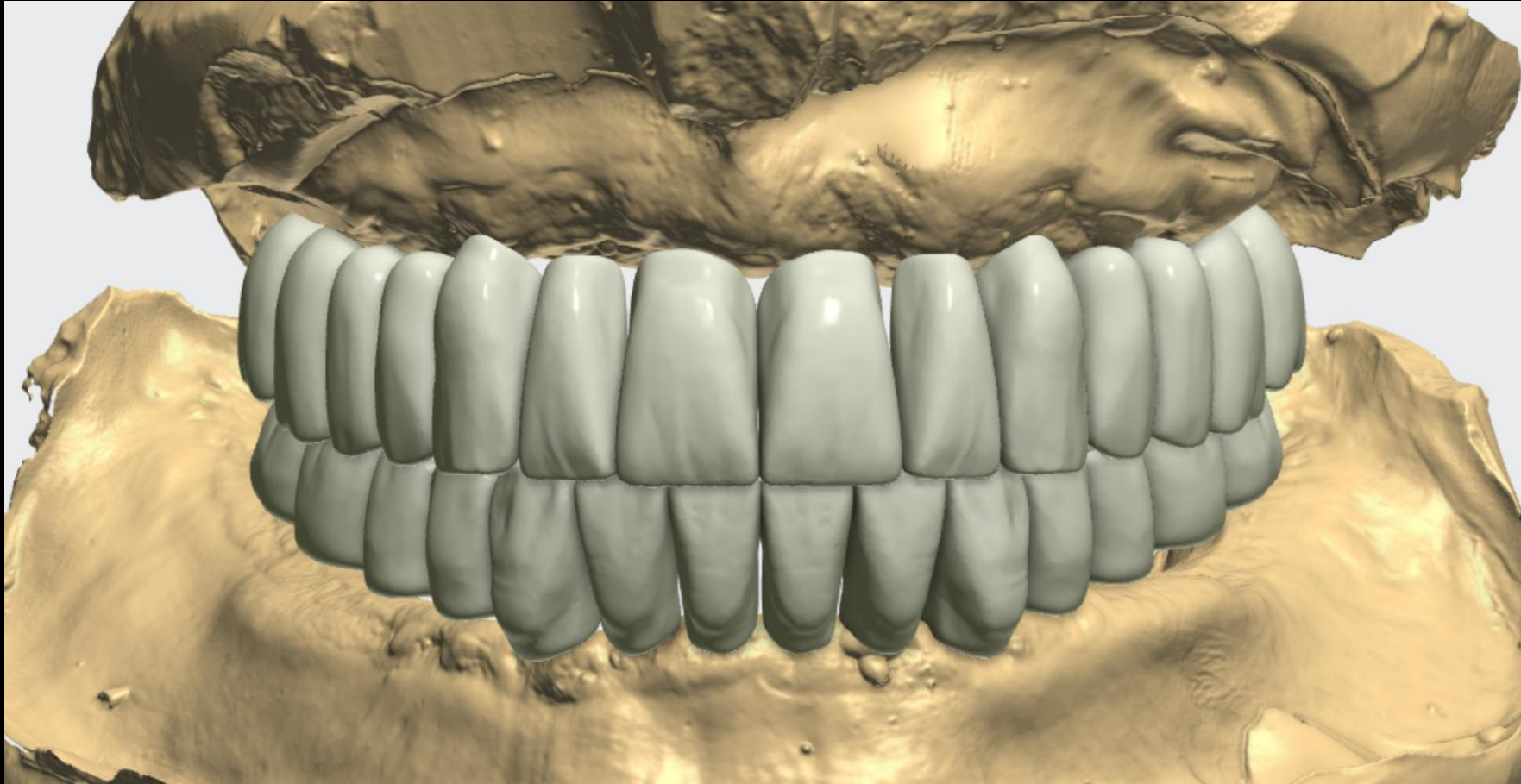
Implant Planning



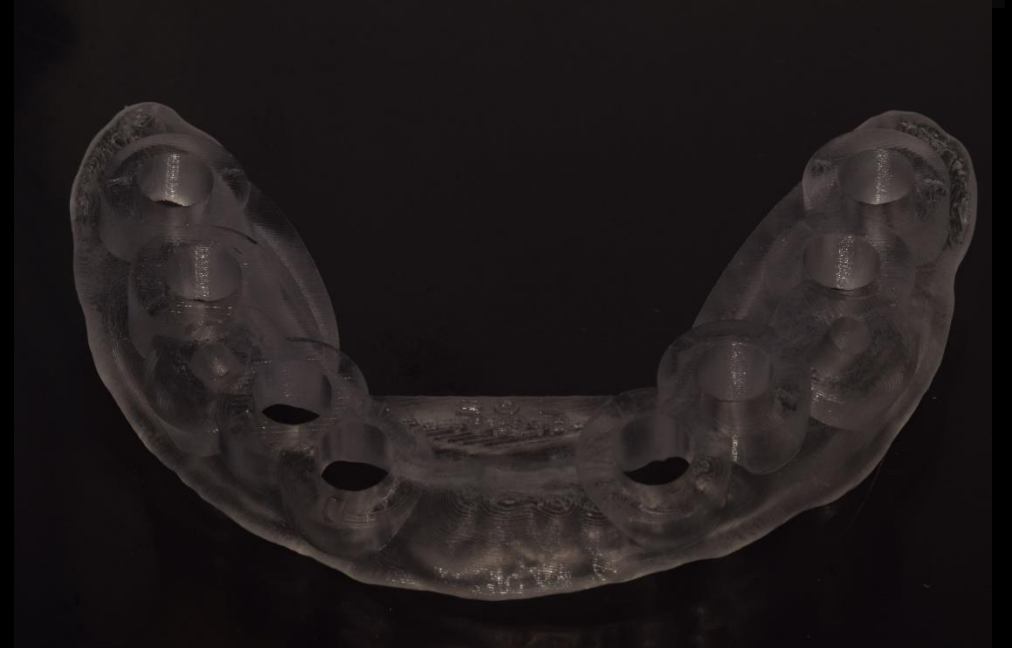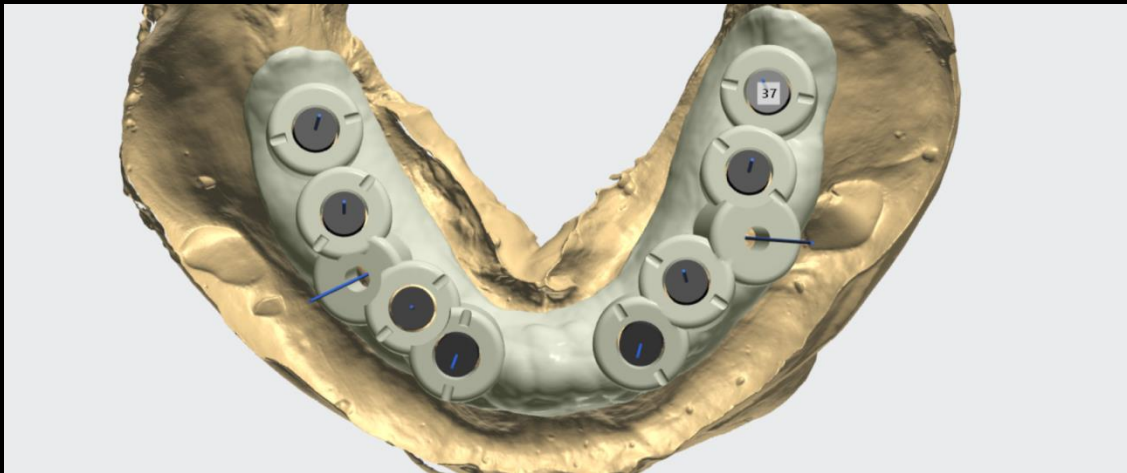
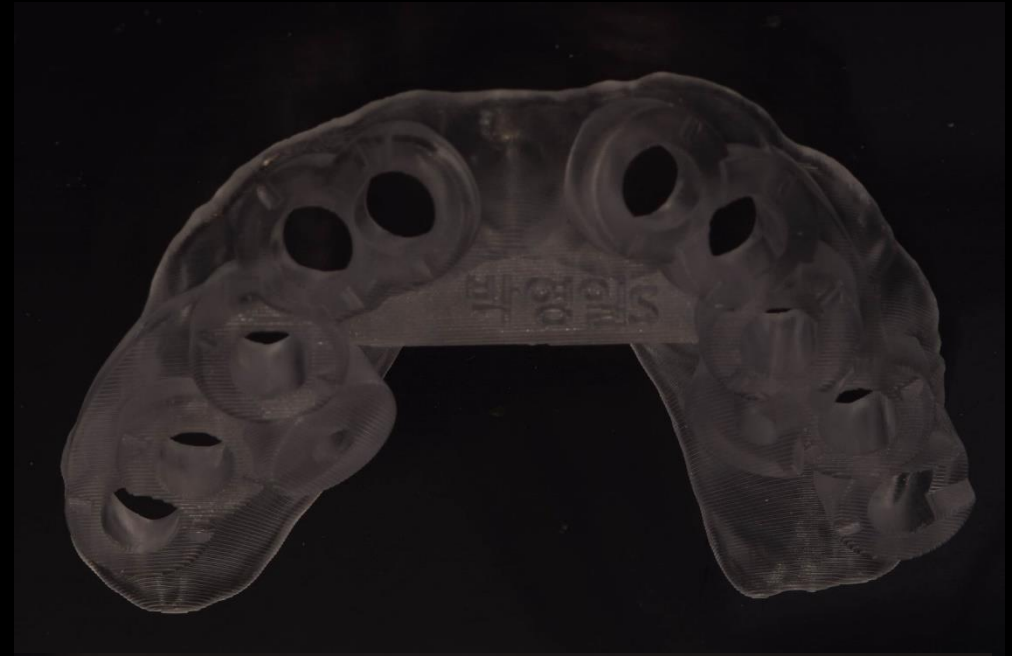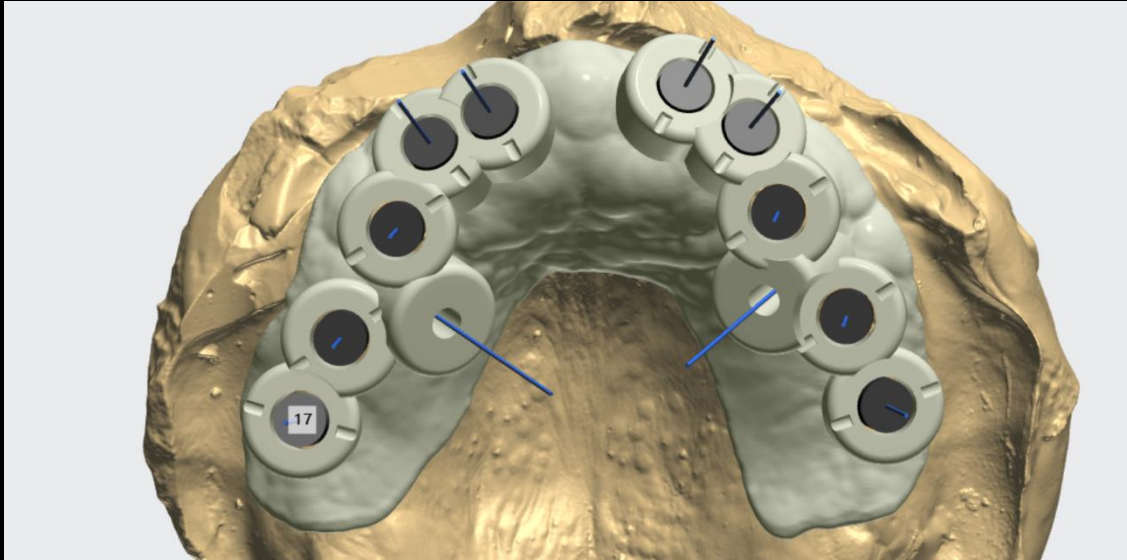
Implant Planning



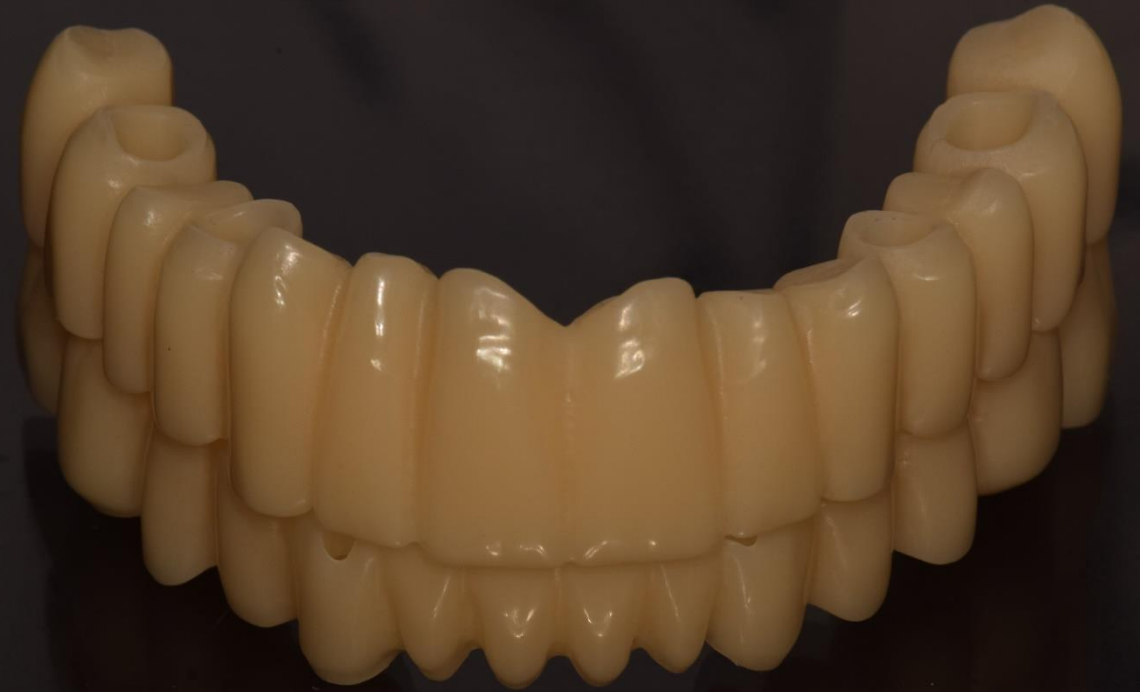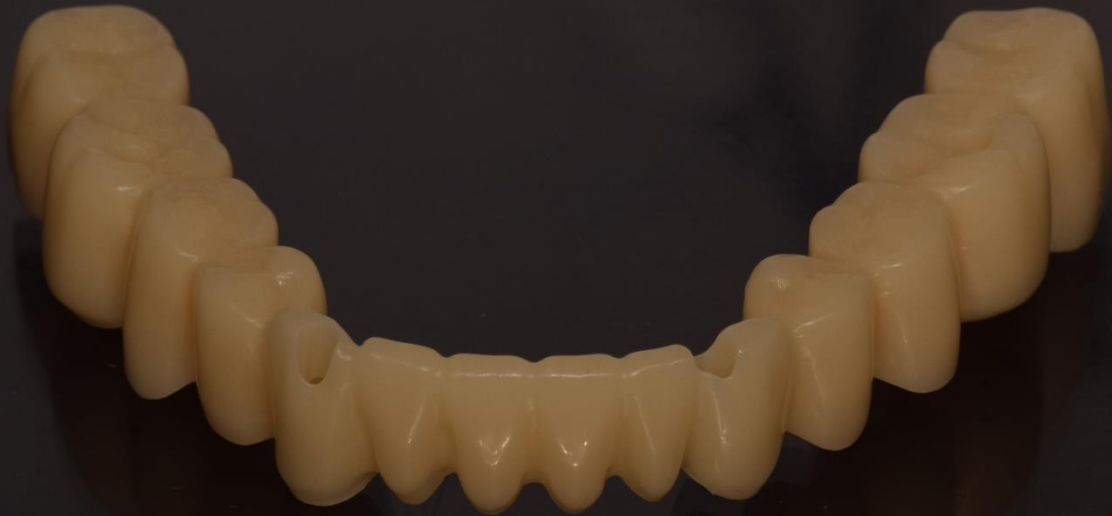Implant Planning



Stent Design

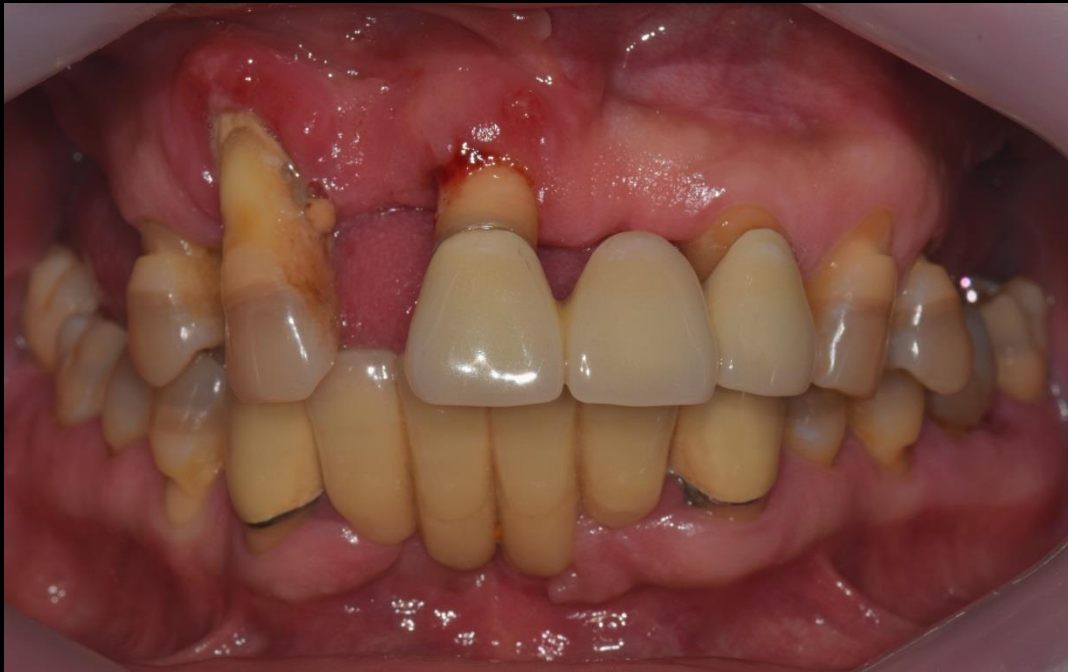

Abutments and temporary bridge

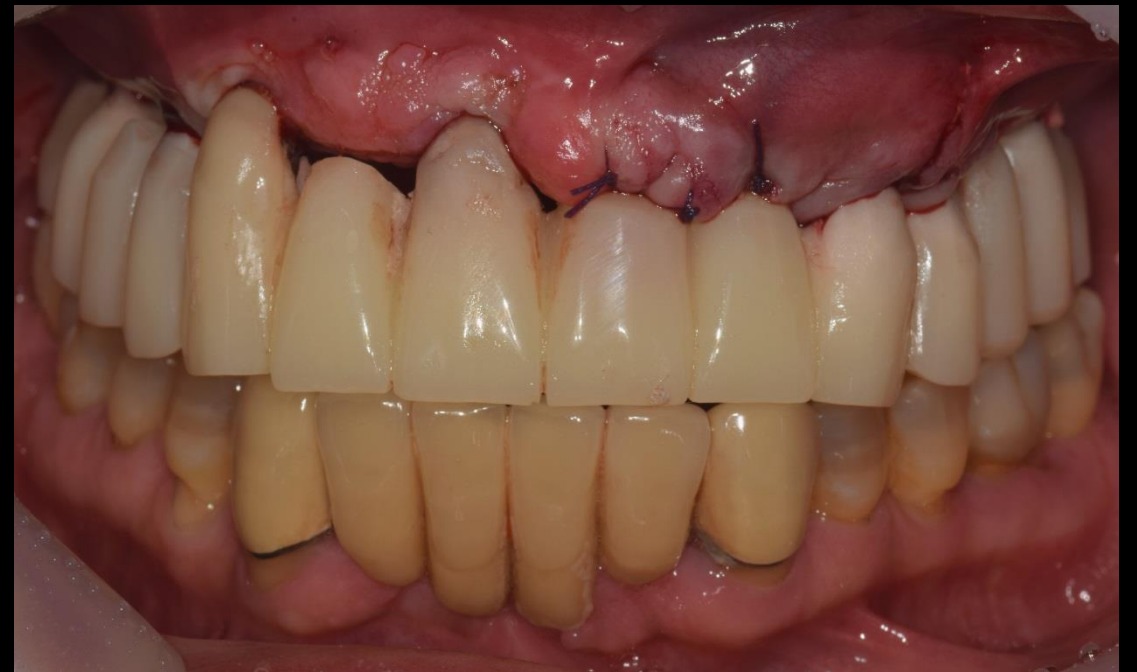

Similar case presentation

Full mouth rehabilitation Using Dentium Digital Guide with immediate prosthesis



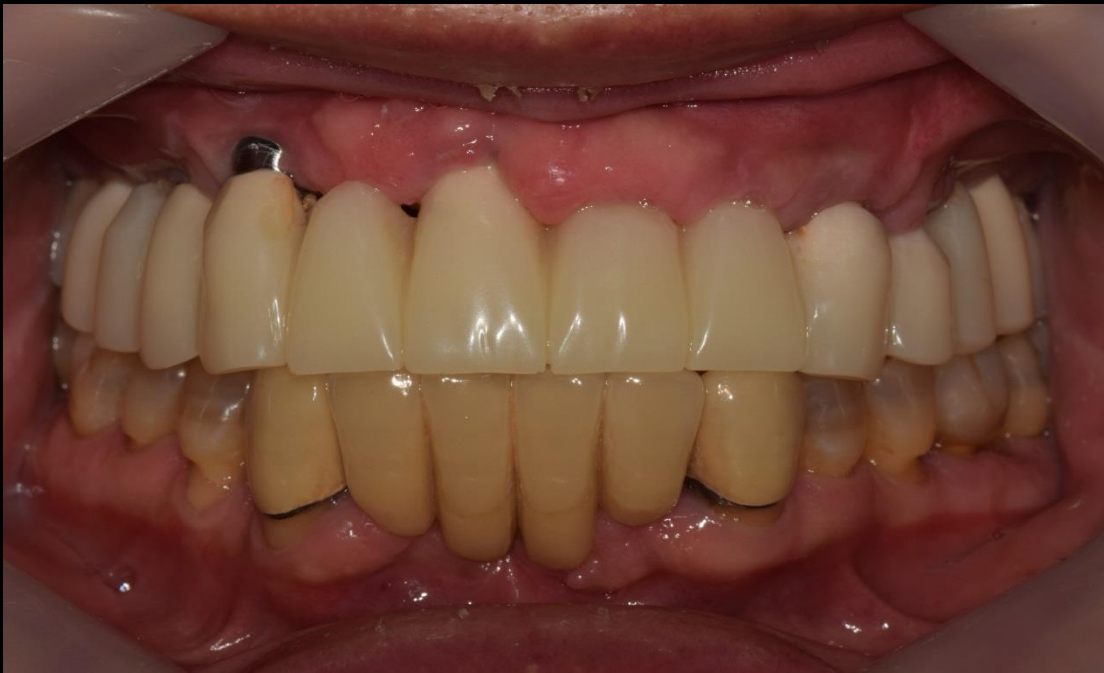Pre-op
(2018-05-02)



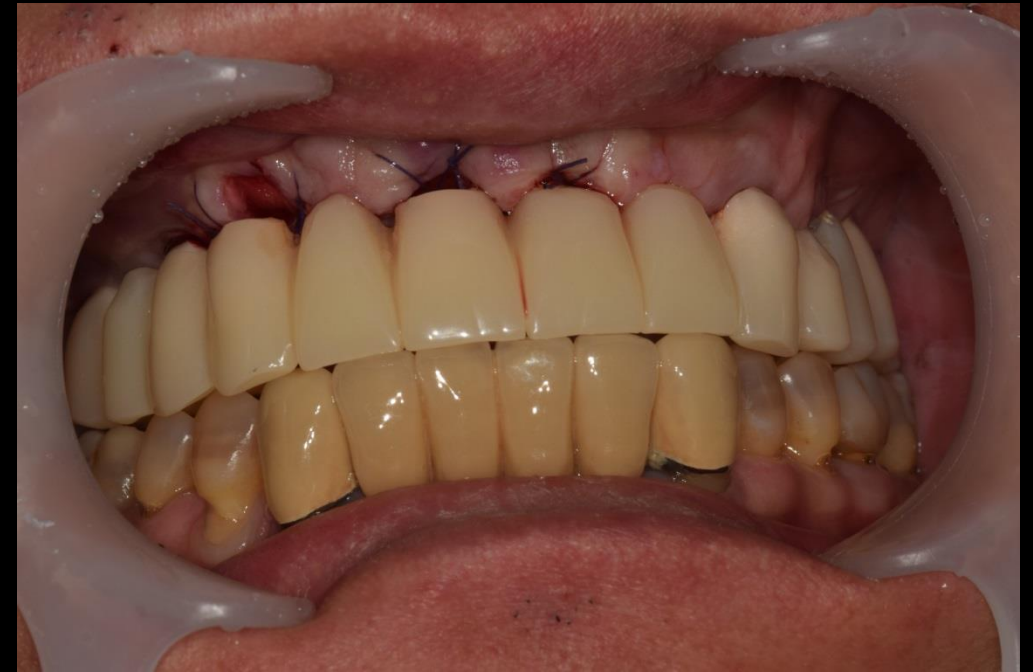Post-op
(2019-01-19)

Similar case presentation

Full mouth rehabilitation Using Dentium
Digital Guide with immediate prosthesis



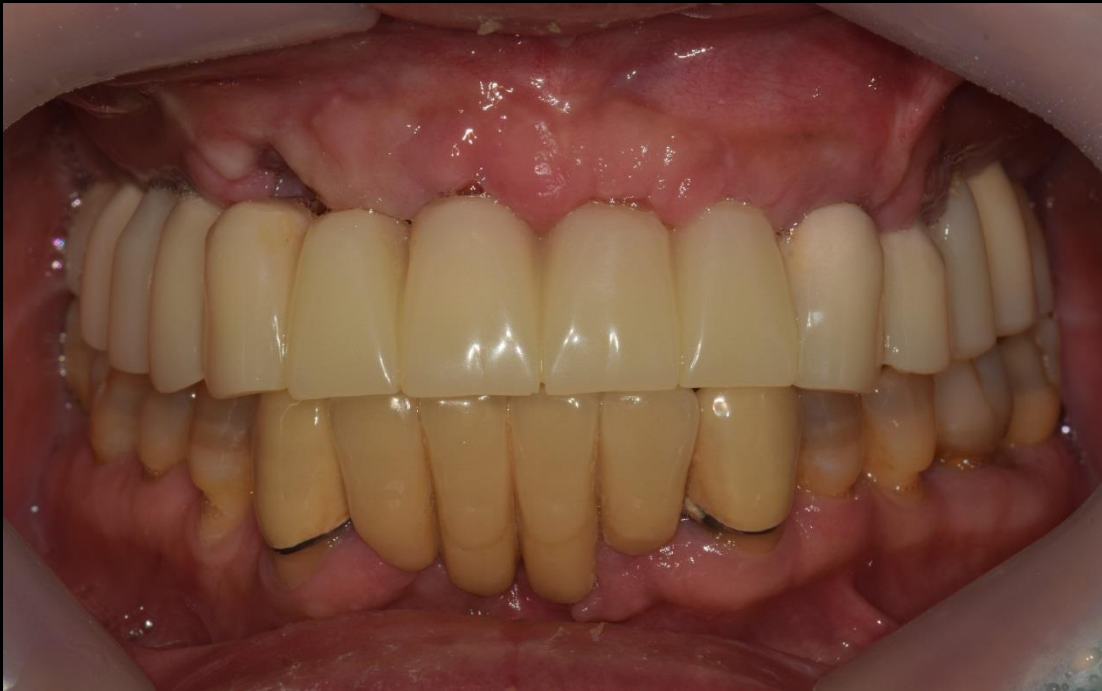Healing : POD 3 M
(2019-04-19)



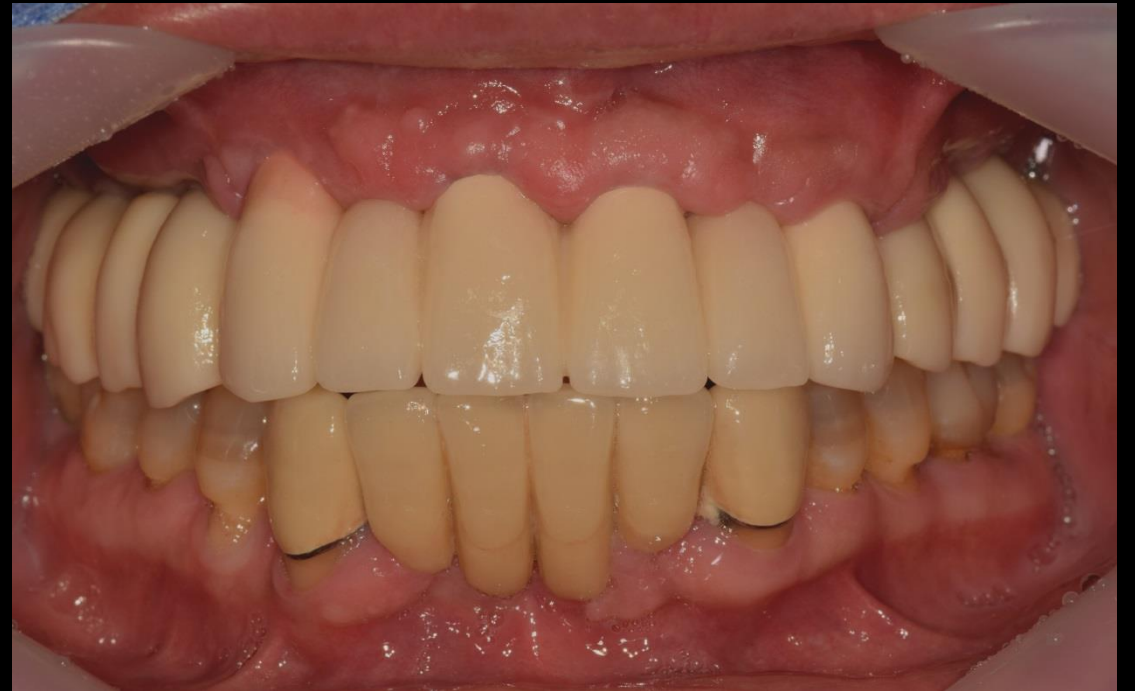Anterior site gingivoplasty
(2019-05-07)

Similar case presentation

Full mouth rehabilitation Using Dentium
Digital Guide with immediate prosthesis

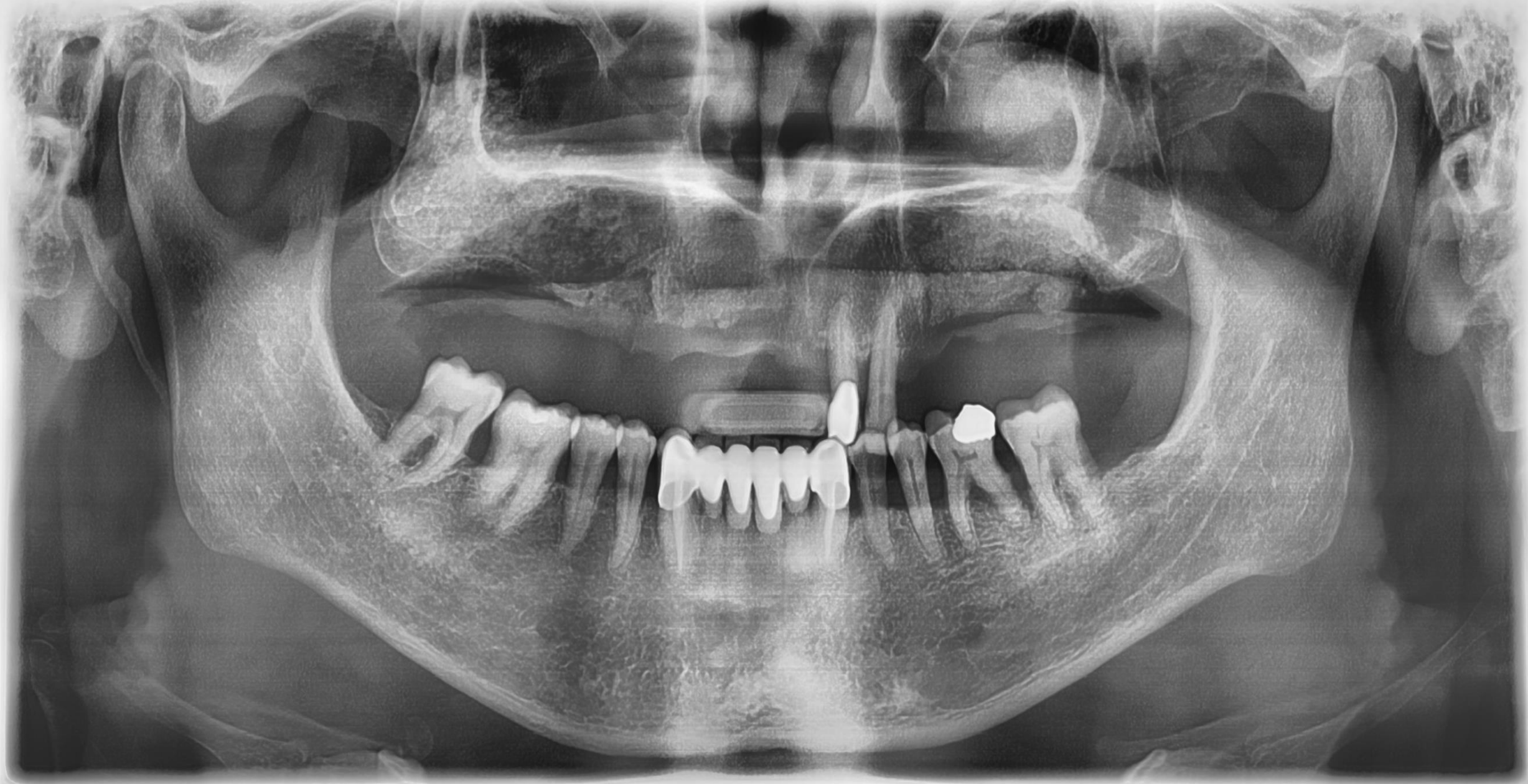


Healing : 2 weeks after gingival surgery
(2019-05-24)



Final prosthesis
(2019-08-05)

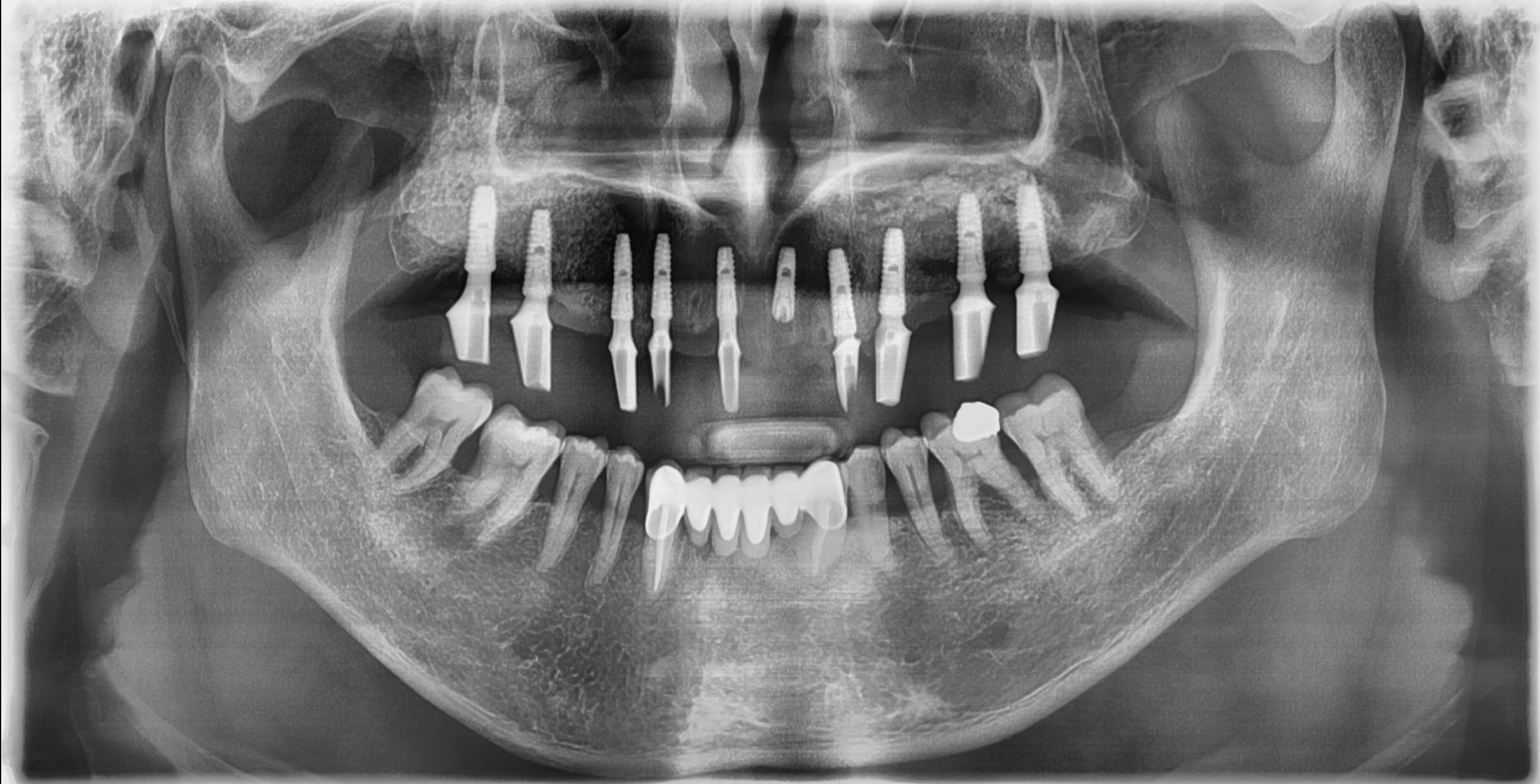post-op



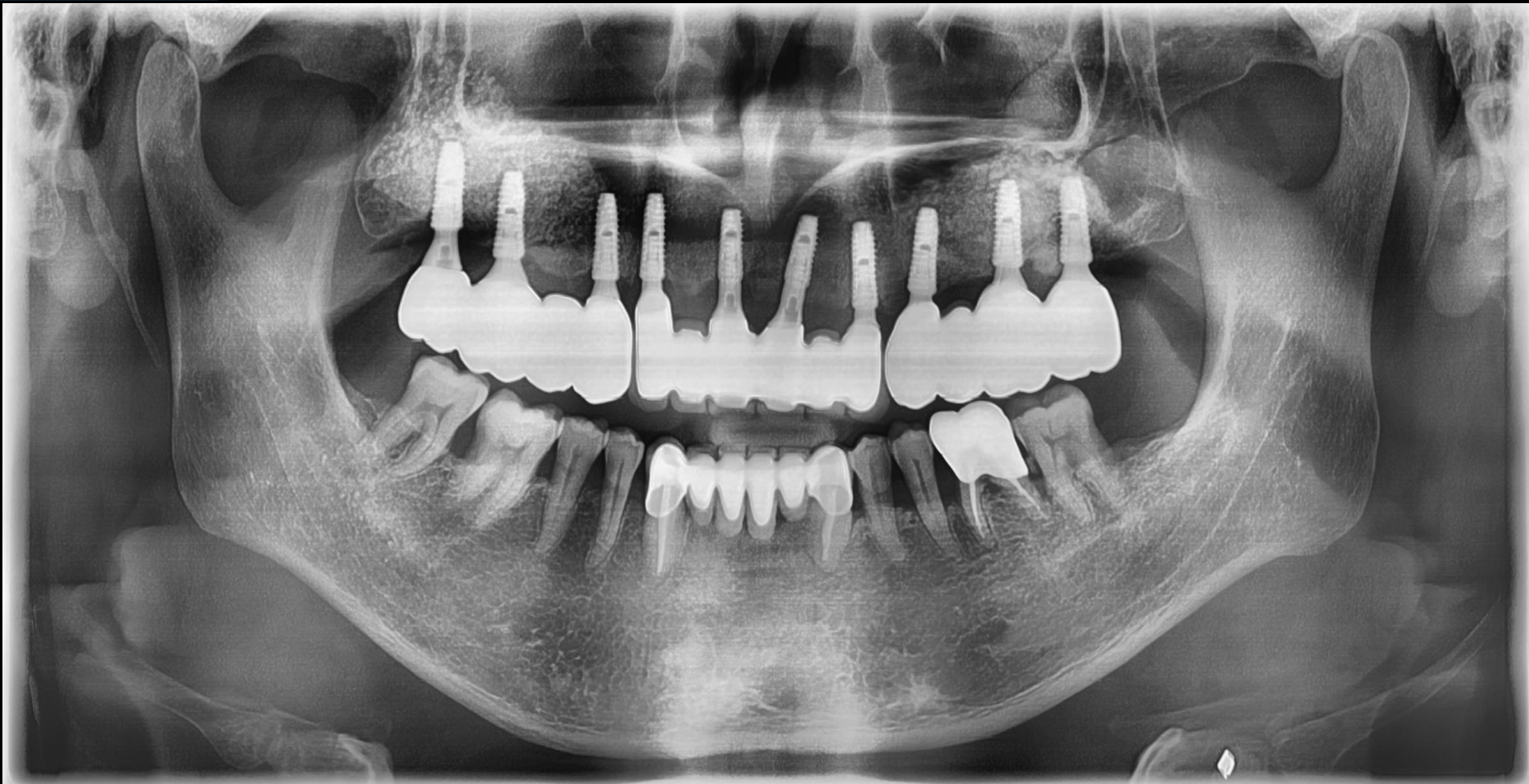PaX-i3D Smart

R

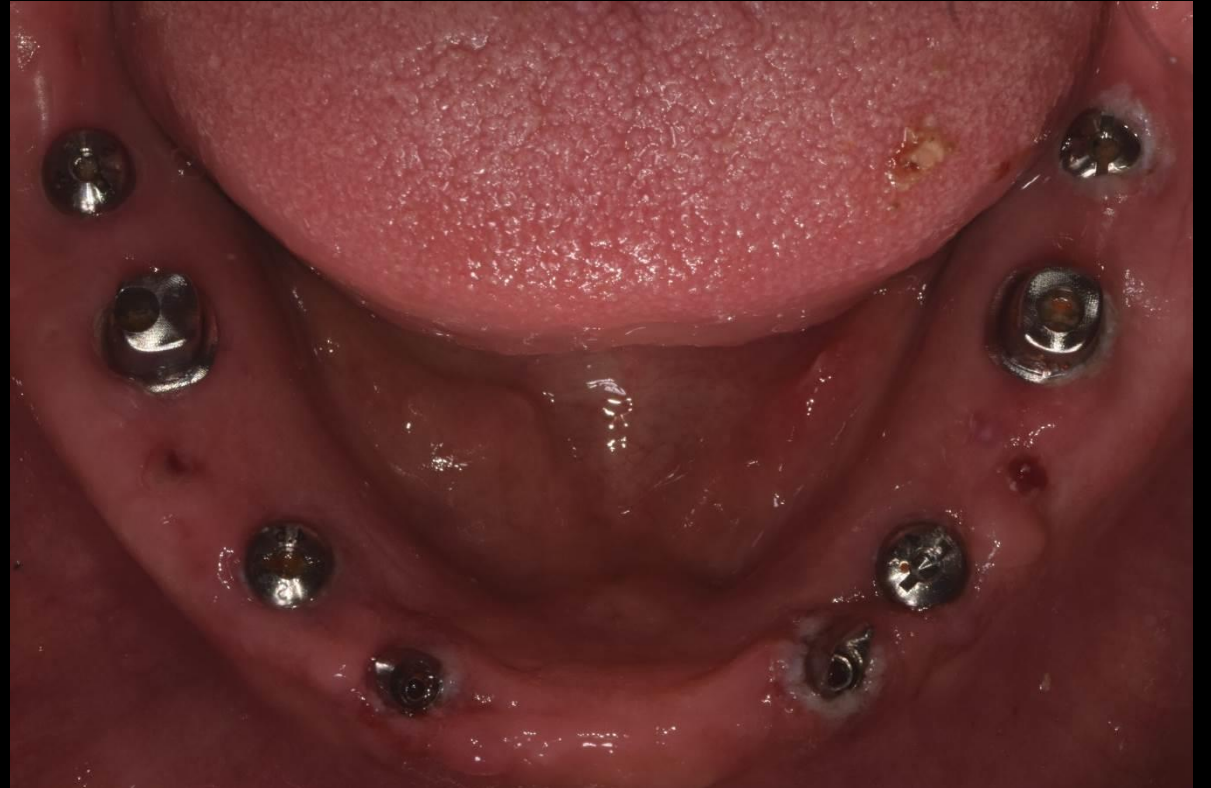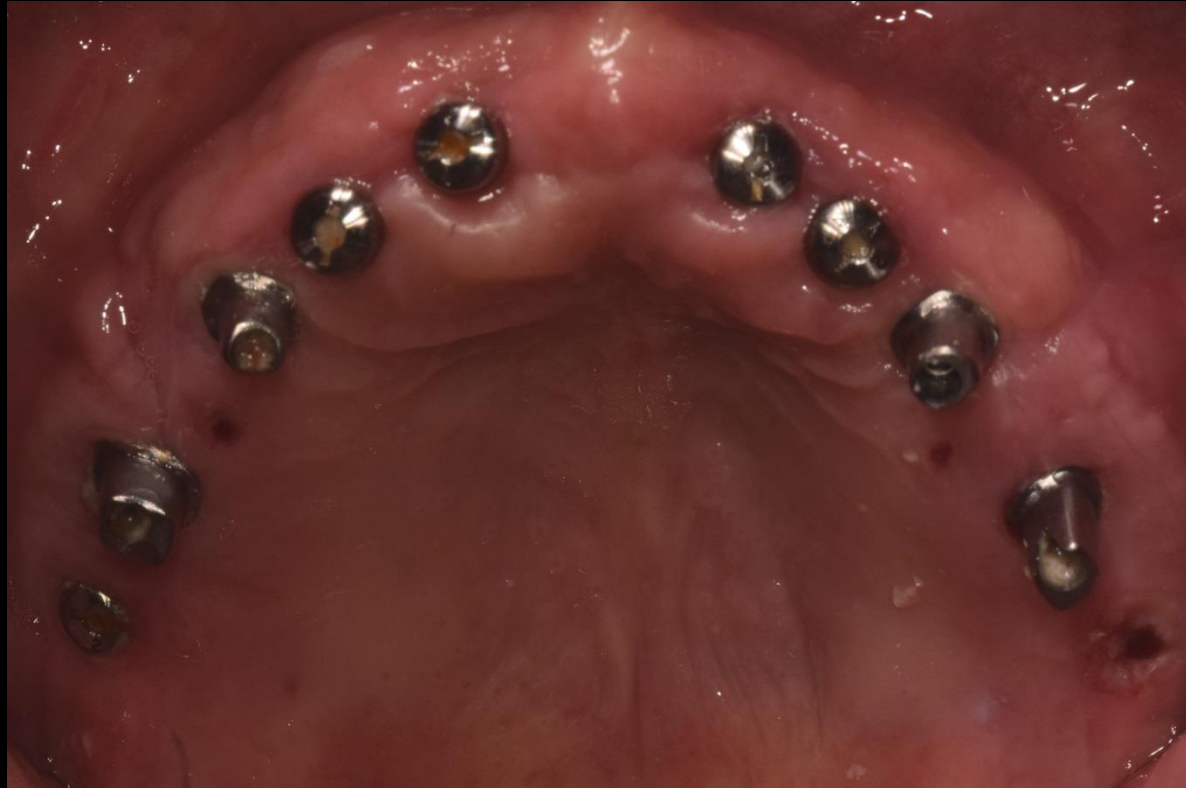post-op



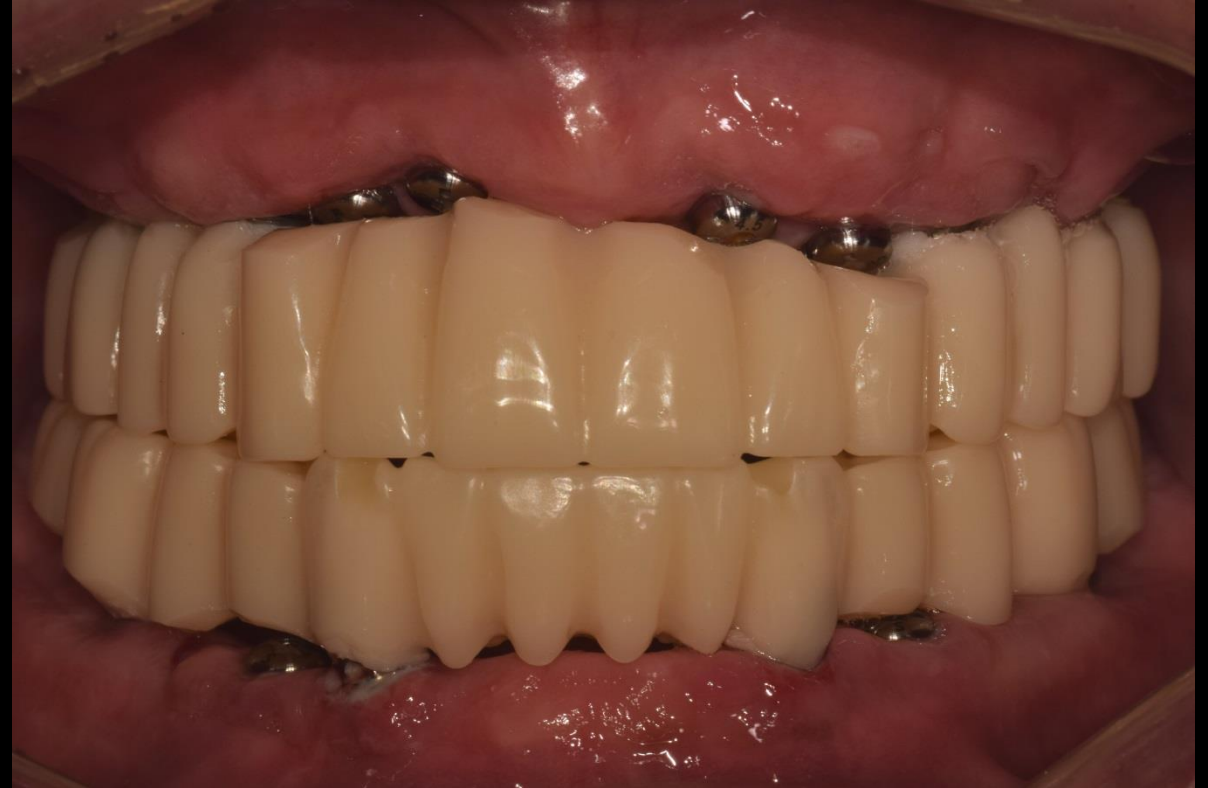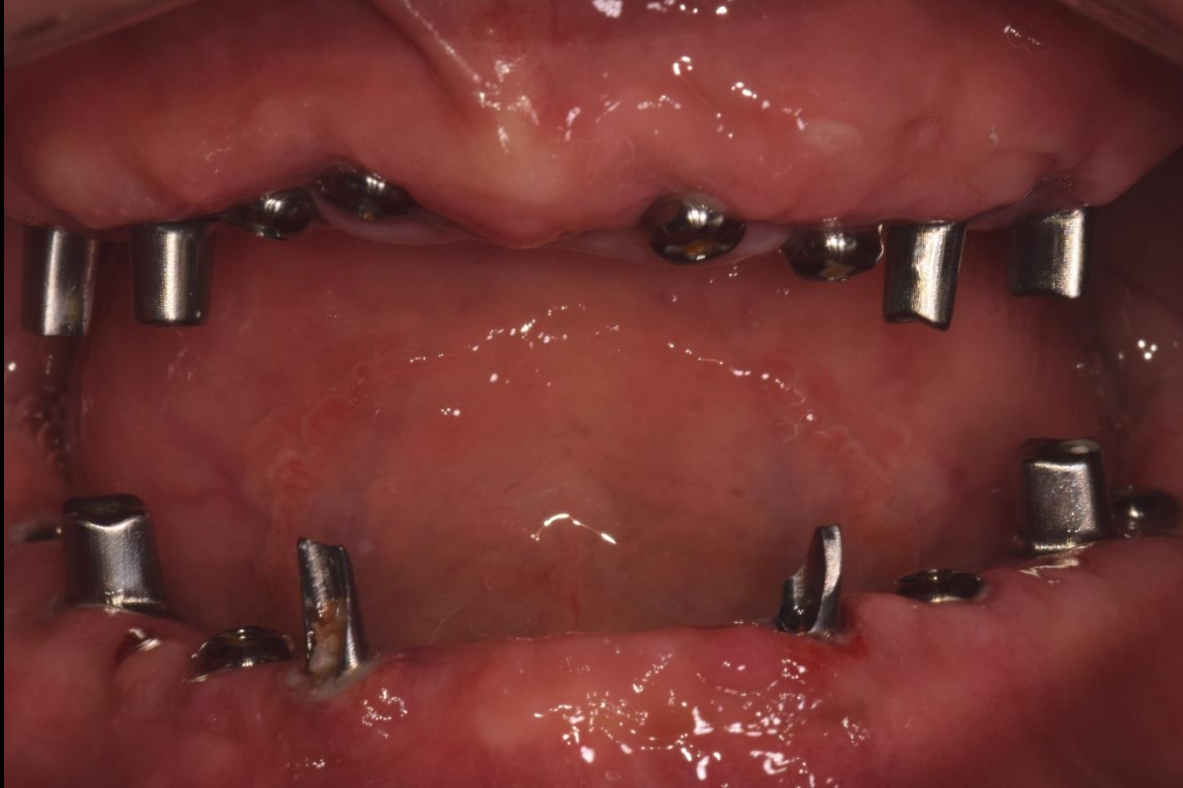post-op



post-op



post-op



post-op

