



**LIVE**

# Surgey

Dr. Root

2020.01.03 (Fri.)



# [Case Preview]

Both maxillary Sinus elevation  
& Implantation using Digital Guide

## Patient Information

**Age** : 59y

**Sex** : Male

### Chief Complaint

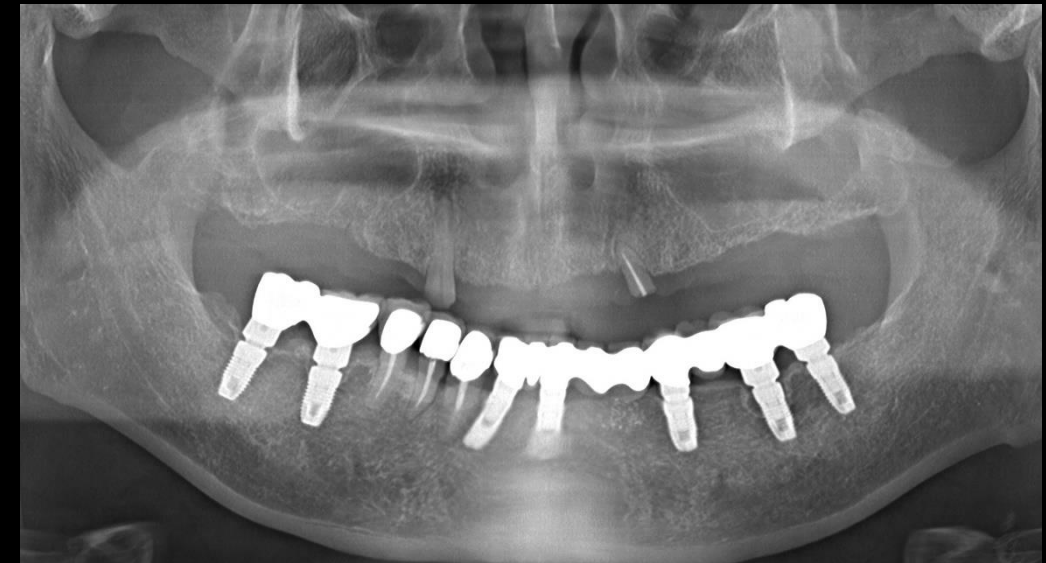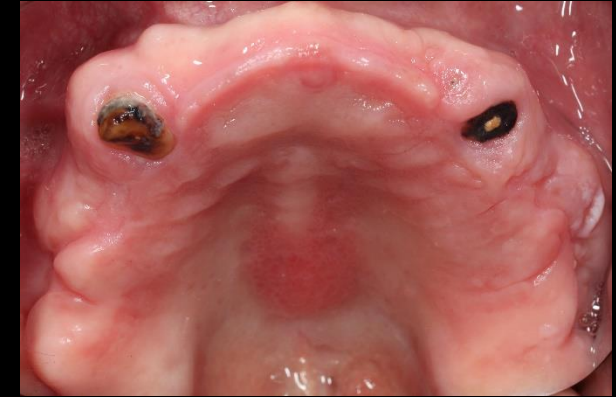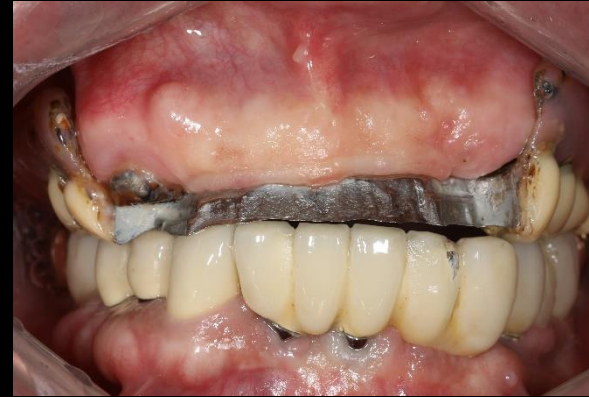: "#13, #23 Tooth Fracture.  
I want an implant surgery consultation"

### Past Medical History

: Hypertension (Do not take medicine)

### Past Dental History

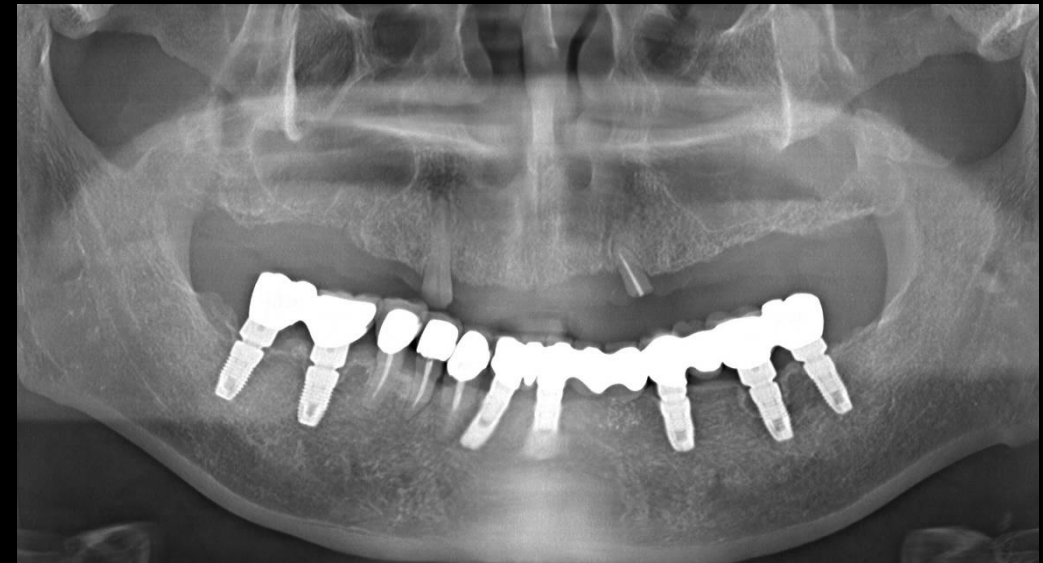
: Extraction Posterior tooth (2002.03.18)  
Anterior : #13=#23 Bridge (2002.05~)  
Posterior : Partial Denture (2002.05~)



# Patient Information

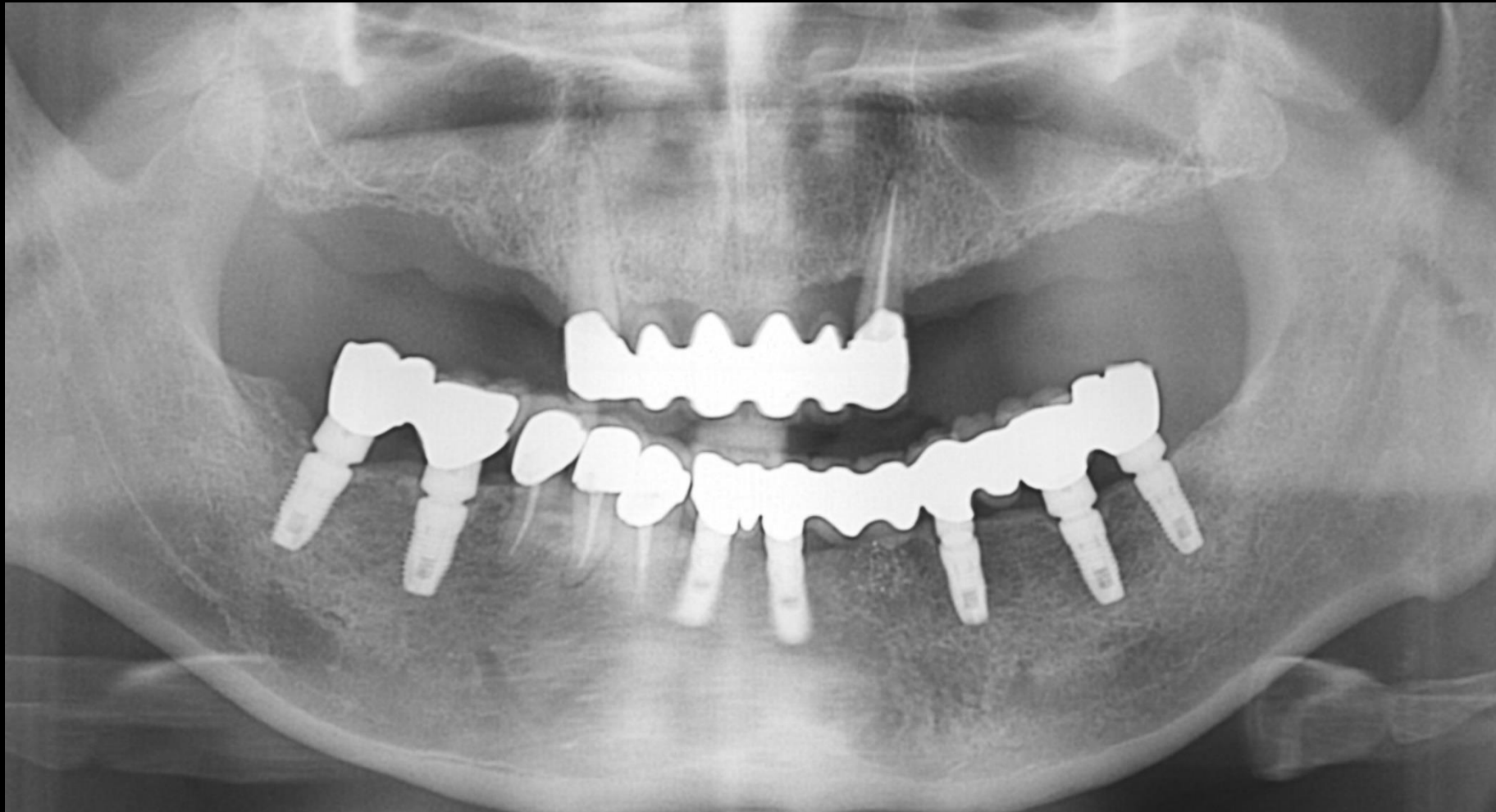## Surgery Plan

- #13,23 Root rest Extraction
- 8 Fixture installation using Milling Digital Guide (#13,14,15,17,23,24,25,27)
- #10 Sinus elevation with Lateral approach
- #20 Removal of Mucocele & Simple Sinus elevation



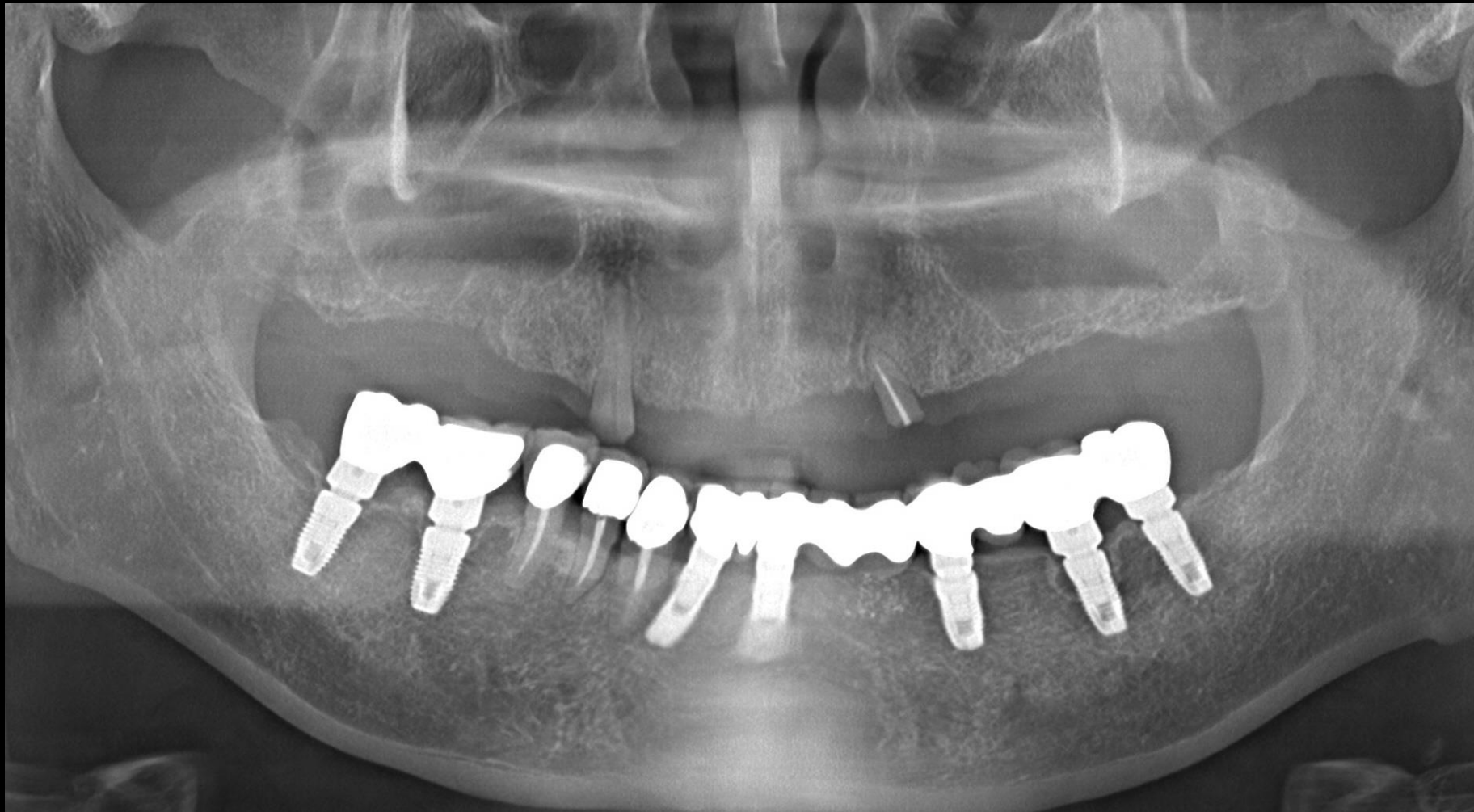
Pt. Kim (59y/M)

Oral exam (2011-02-23)

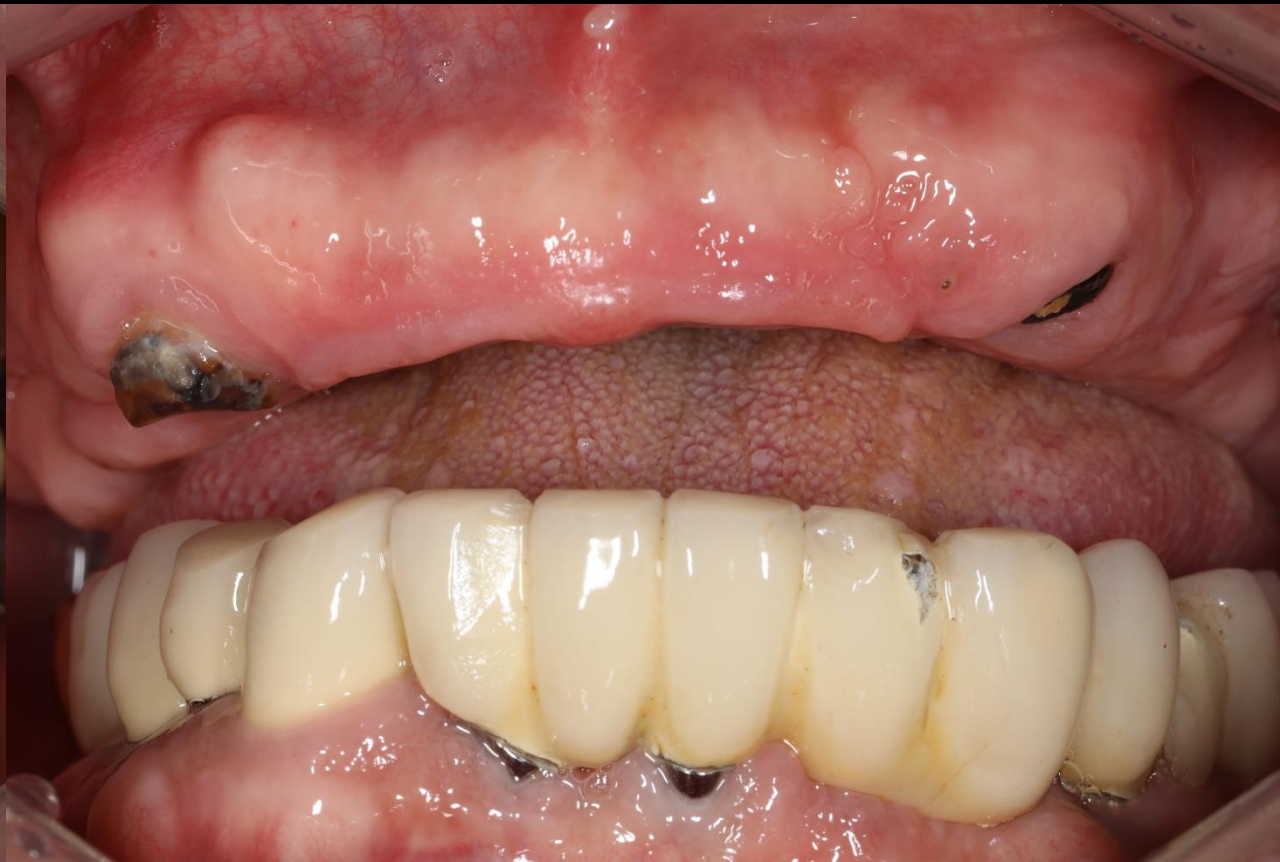
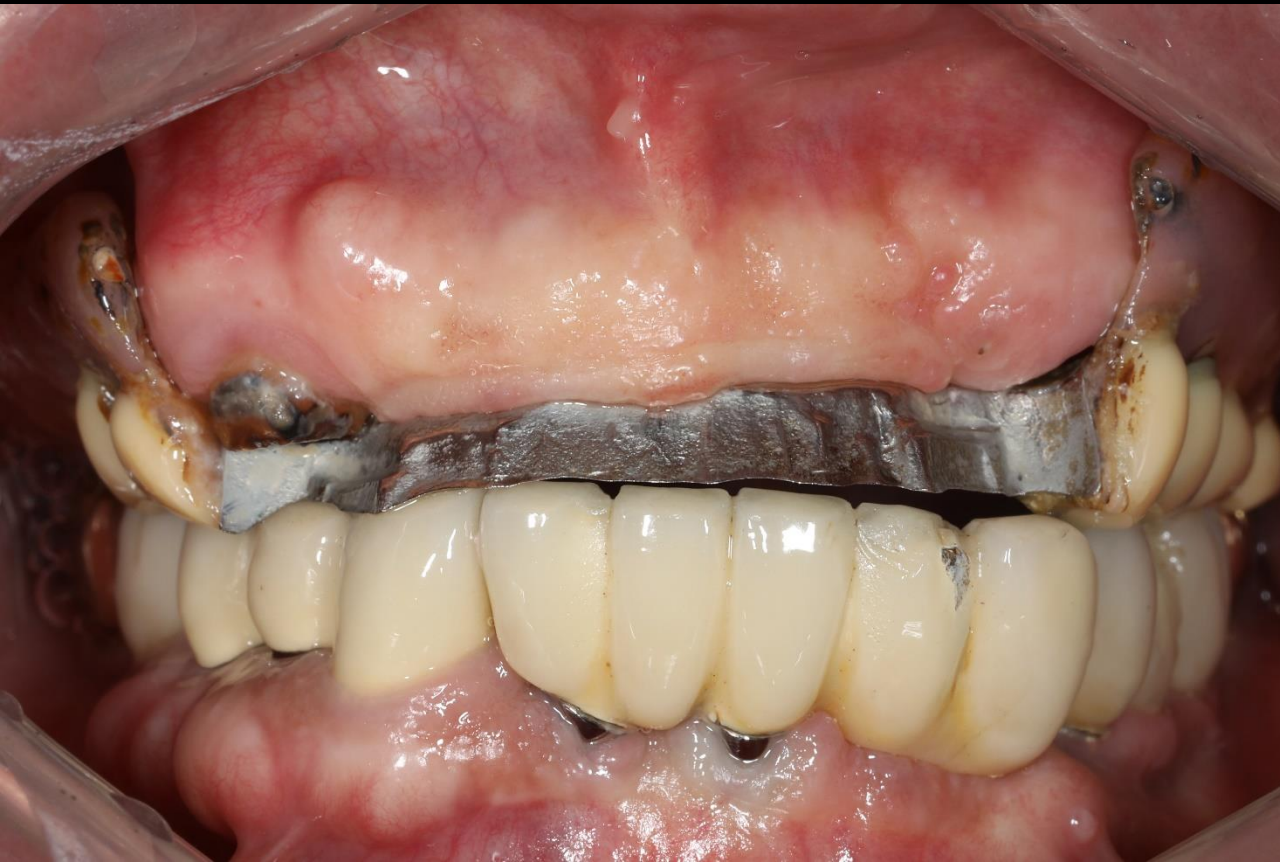
Pt. Kim (59y/M)

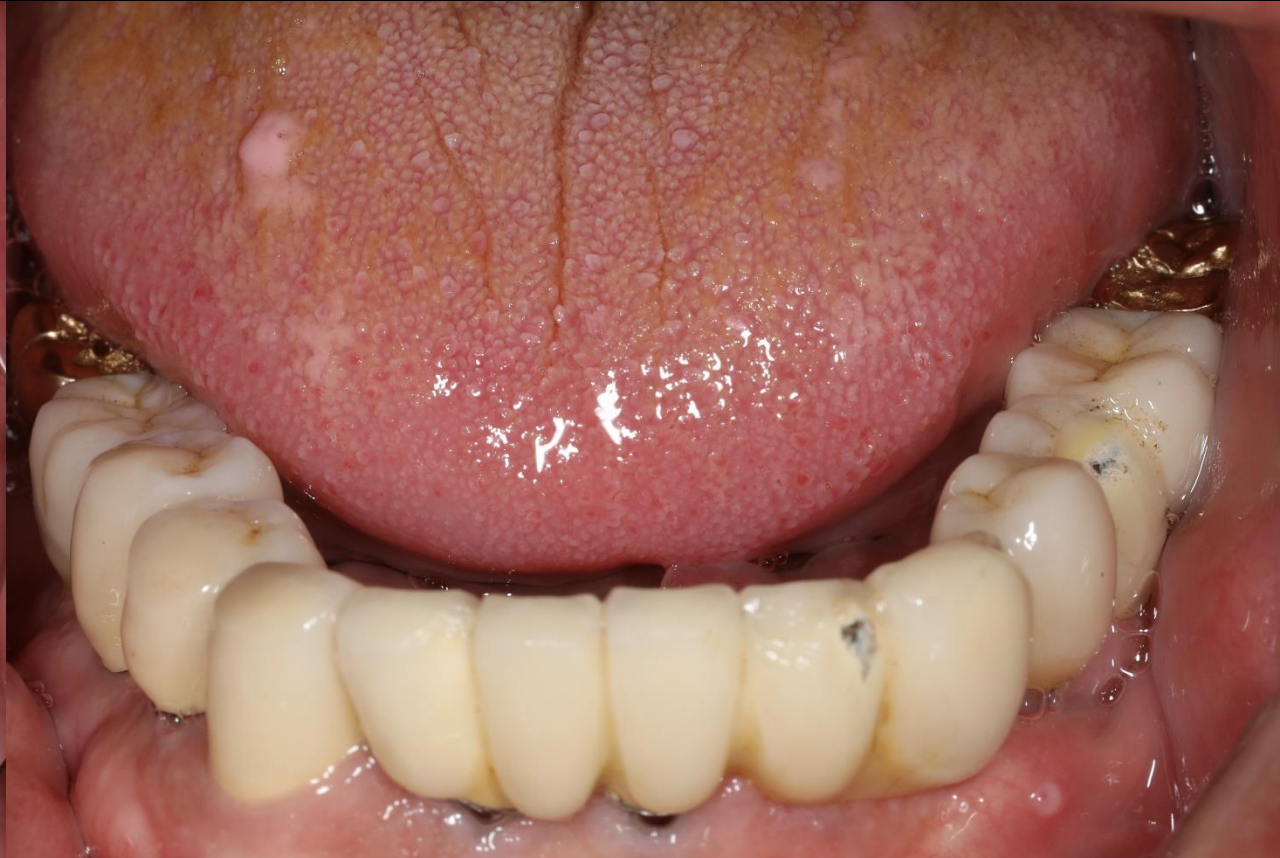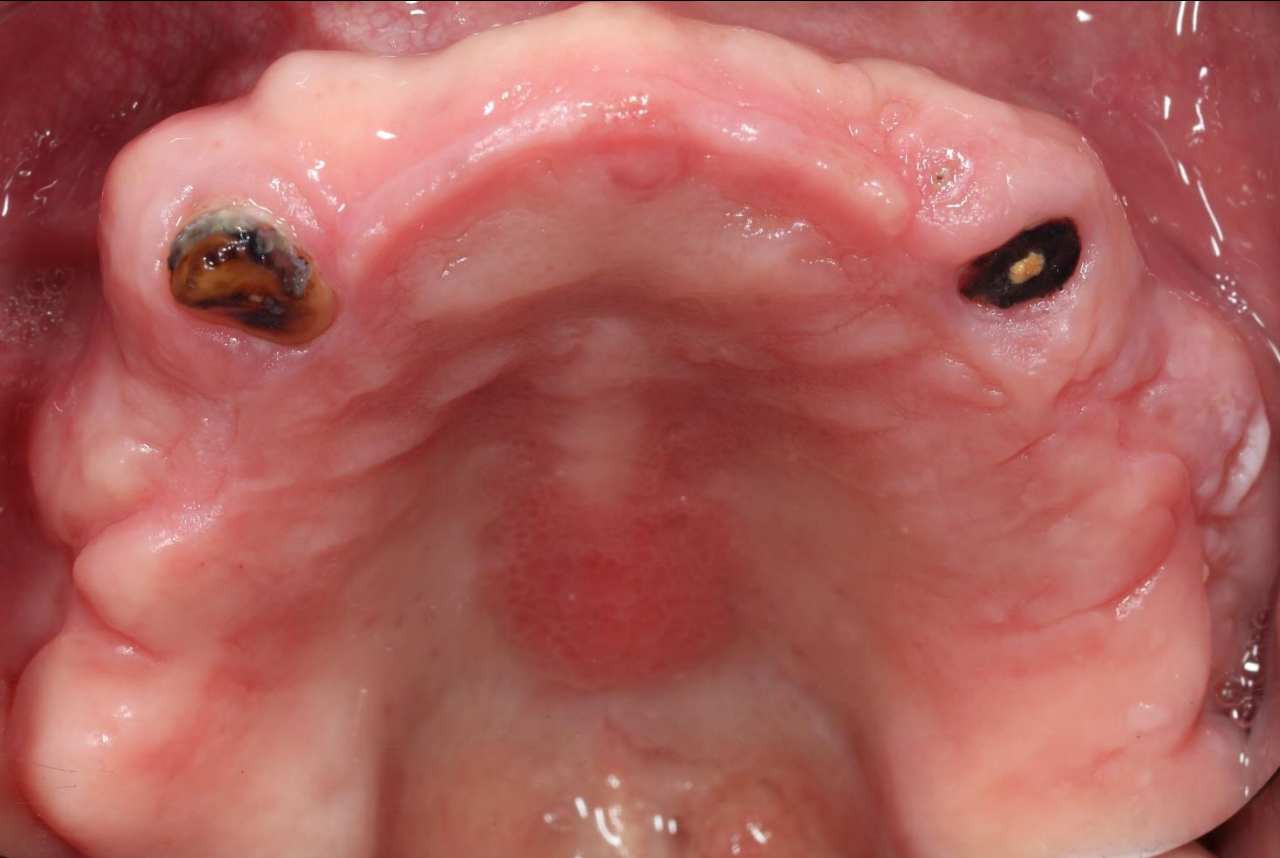Pre-op (2019-12-12)



# Initial Photo

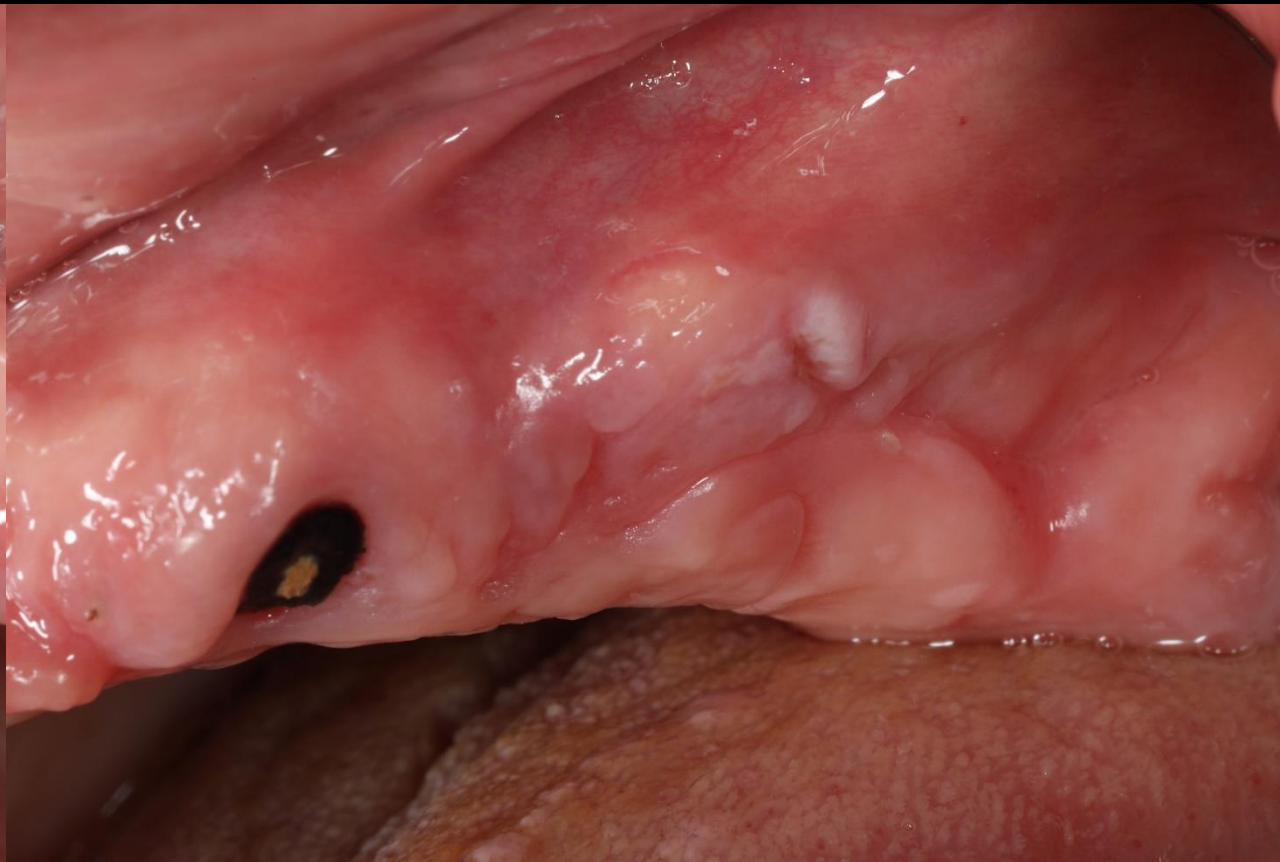
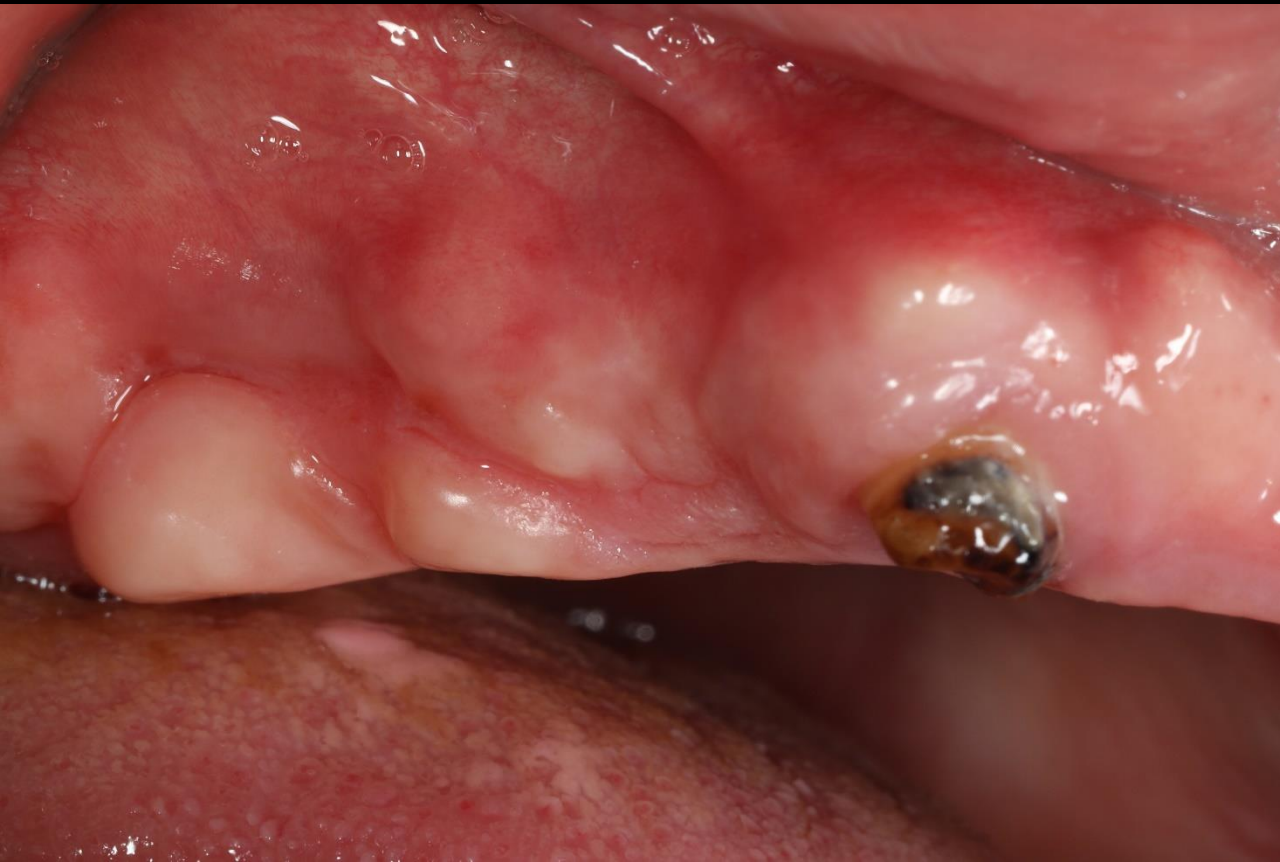
# Initial Photo

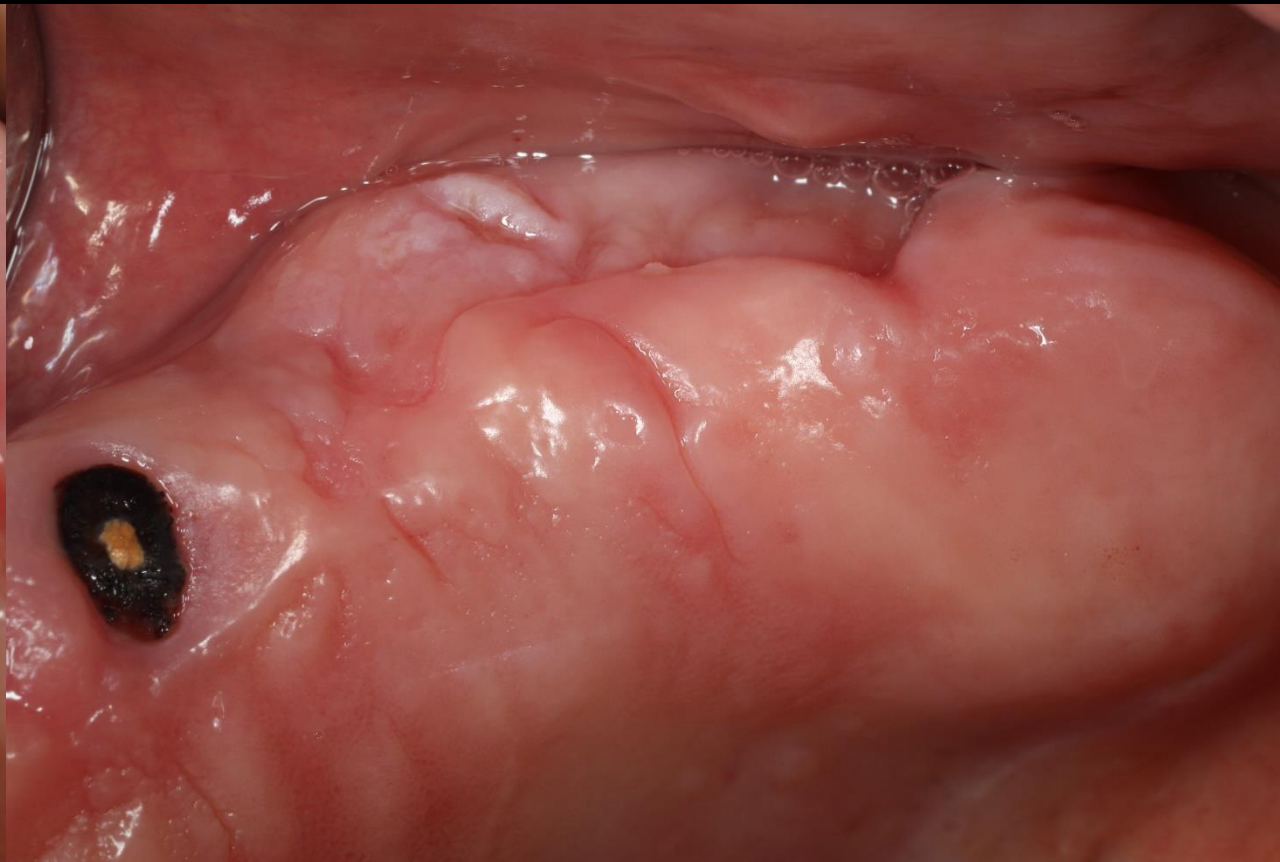
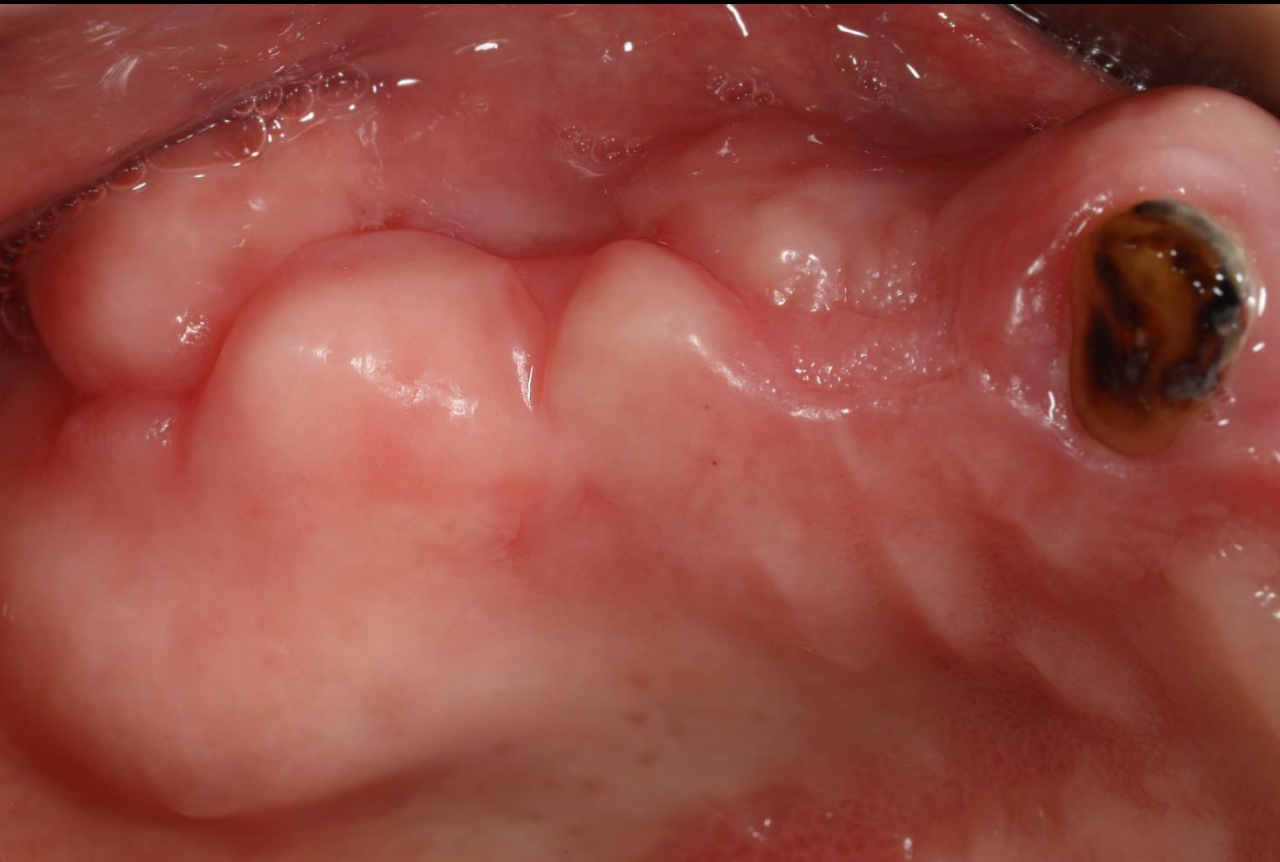



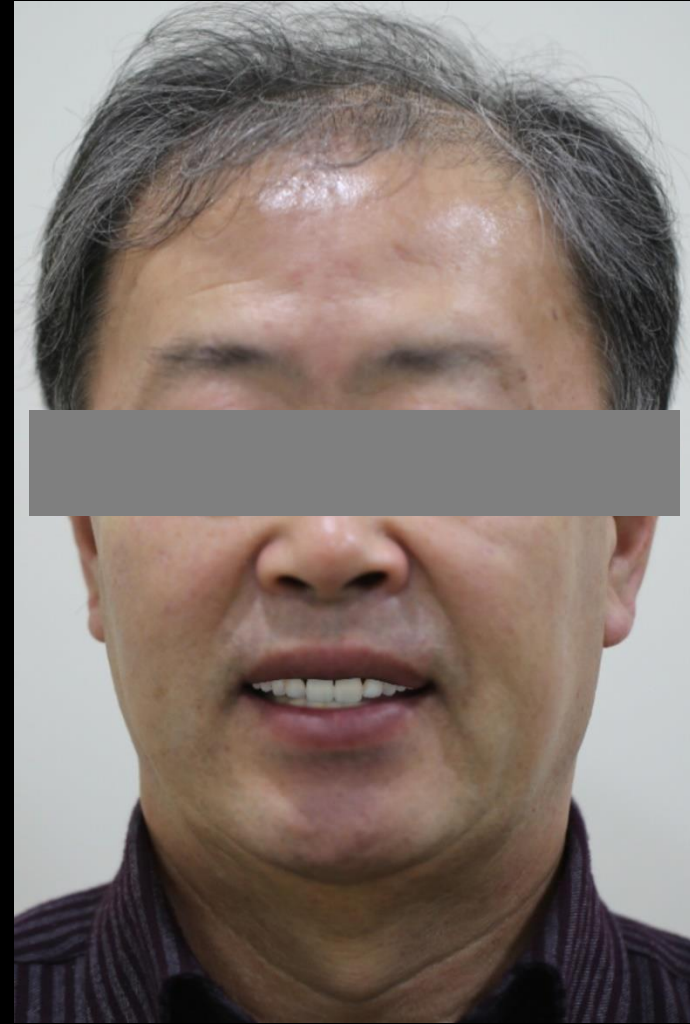
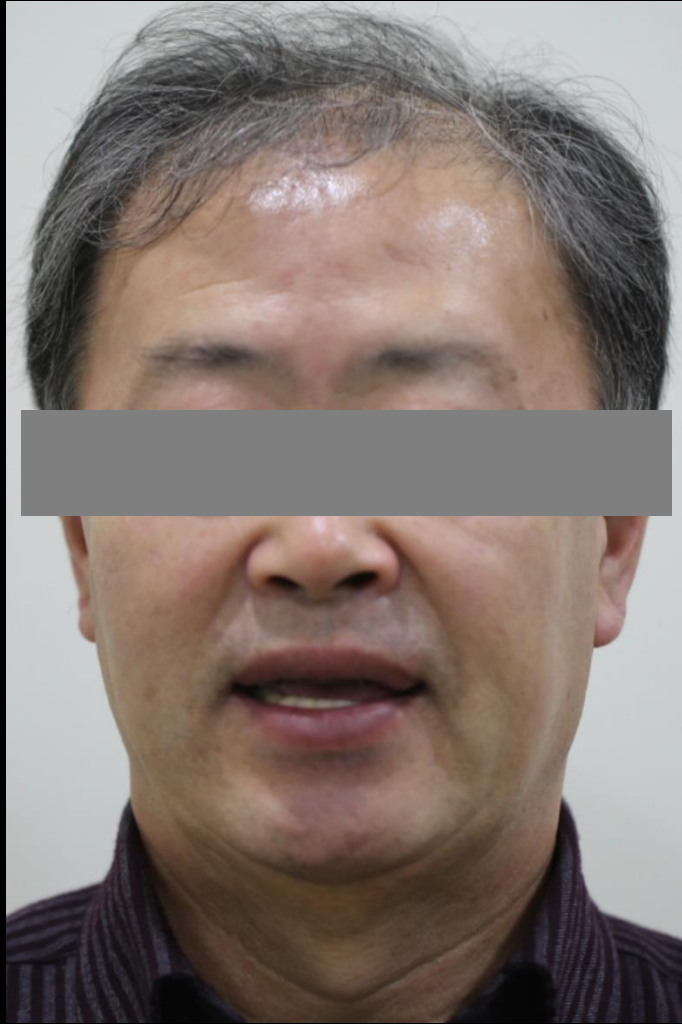
# Initial Photo



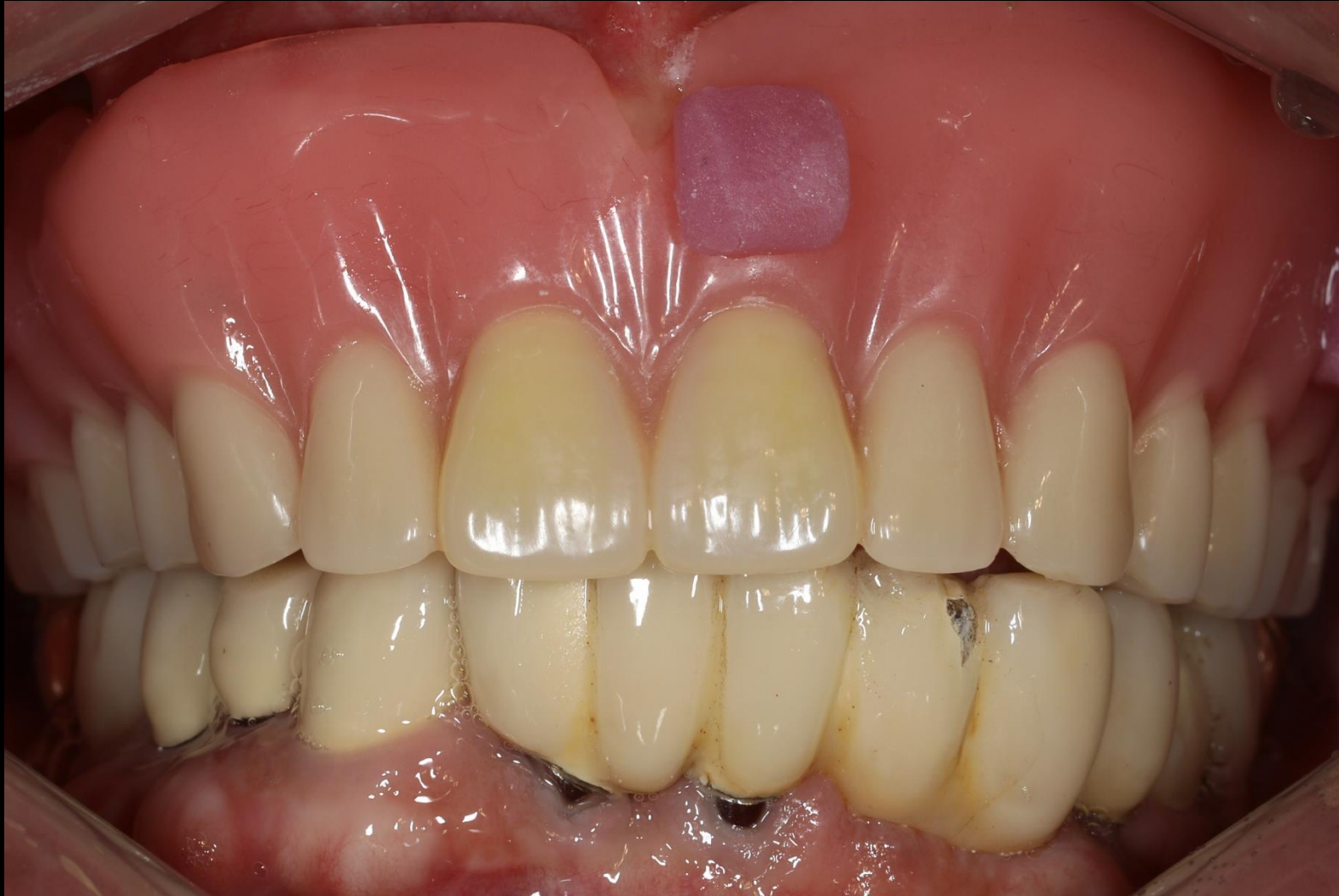# Initial Photo



# Smile Design




# Denture (Resin marker) adaptation




rainbow 3D Viewer

IMPLANT  
MPR  
Cross  
Report




Curve Info  
W 80mm  
I 0.5mm  
T 0.0mm


김기홍  
MALE  
19710905  
59  
8 [mA]  
94 [kVp]  
CT




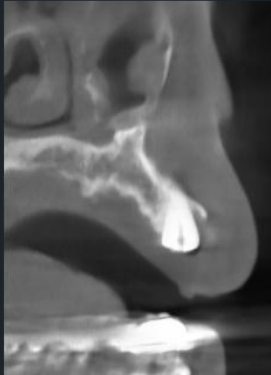

H  
A  
R  
F  
P



H  
A  
R  
F



Nerve Info  
R 1.0mm



H  
A  
R  
F

Dentium  
For Dentists By Dentists

rainbow 3D Viewer

IMPLANT MPR Cross Report

Curve Info  
W 80mm  
I 0.5mm  
T 0.0mm

김기홍  
MALE  
19710905  
59  
8 [mA]  
94 [kVp]  
CT

H A  
R F L  
P

H  
P R A  
F

H  
R F  
F

Nerve Info  
R 1.0mm

Dentium  
For Dentists By Dentists

rainbow 3D Viewer

IMPLANT MPR Cross Report

Curve Info  
W 80mm  
I 0.5mm  
T 0.0mm

김기홍  
MALE  
19710905  
59  
8 [mA]  
94 [kVp]  
CT

H A  
R F L

H  
P R A  
F

H  
P R  
F

Nerve Info  
R 1.0mm

Dentium  
For Dentists By Dentists





rainbow 3D Viewer

IMPLANT MPR Cross Report

Curve Info  
W 80mm  
I 0.5mm  
T 0.0mm

김기흥  
MALE  
19710905  
59  
8 [mA]  
94 [kVP]  
CT

Nerve Info  
R 1.0mm

Dentium  
For Dentists By Dentists

The image displays a comprehensive 3D dental implant planning software interface. The central focus is a 3D model of a patient's skull and jaw, rendered in a semi-transparent orange color, showing the placement of multiple dental implants. To the right, a circular CT scan view shows the cross-section of the jaw with red and yellow lines indicating the implant paths. Below this, several smaller rectangular windows provide different views of the implants, including sagittal and coronal sections. The interface includes a top toolbar with icons for file operations and a settings gear. A vertical sidebar on the left contains navigation buttons for 'IMPLANT', 'MPR', 'Cross', and 'Report'. A 'Curve Info' panel on the right lists parameters: W (80mm), I (0.5mm), and T (0.0mm). A patient information panel on the far right lists: 김기흥, MALE, 19710905, 59, 8 [mA], 94 [kVP], and CT. At the bottom left, a 'Nerve Info' panel shows 'R 1.0mm'. The Dentium logo is visible in the bottom right corner.

rainbow 3D Viewer

IMPLANT MPR Cross Report

Curve Info  
W 80mm  
I 0.5mm  
T 0.0mm

김기홍  
MALE  
19710905  
59  
8 [mA]  
94 [kVP]  
CT

IMPLANT

Nerve Info  
R 1.0mm

Dentium  
For Dentists By Dentists

rainbow 3D Viewer

IMPLANT MPR Cross Report

Curve Info  
W 80mm  
I 0.5mm  
T 0.0mm

김기홍  
MALE  
19710905  
59  
8 [mA]  
94 [kVp]  
CT

Nerve Info  
R 1.0mm

Dentium  
For Dentists By Dentists

rainbow 3D Viewer

IMPLANT MPR Cross Report

Curve Info  
W 80mm  
I 0.5mm  
T 0.0mm

김기용  
MALE  
19710905  
59  
8 [mA]  
94 [kVp]  
CT

H A L P  
F

H A L P  
F

H A L P  
F

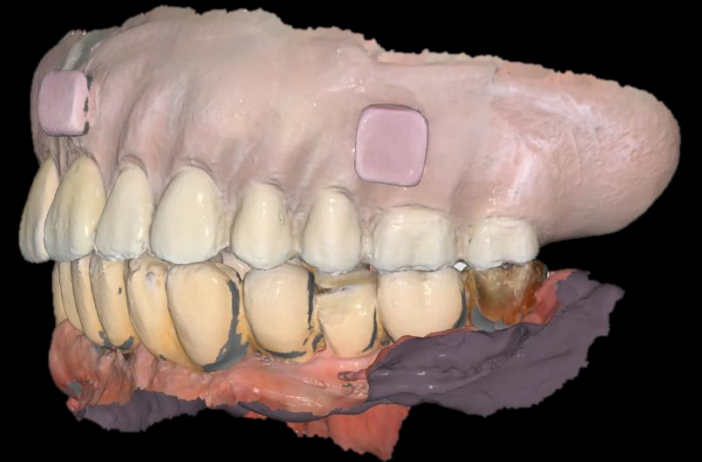
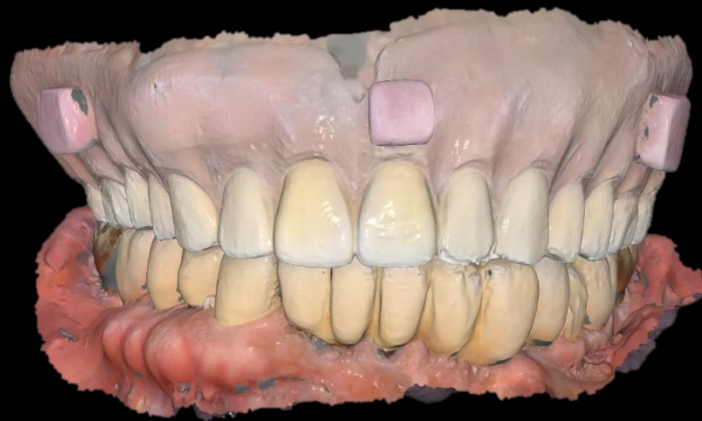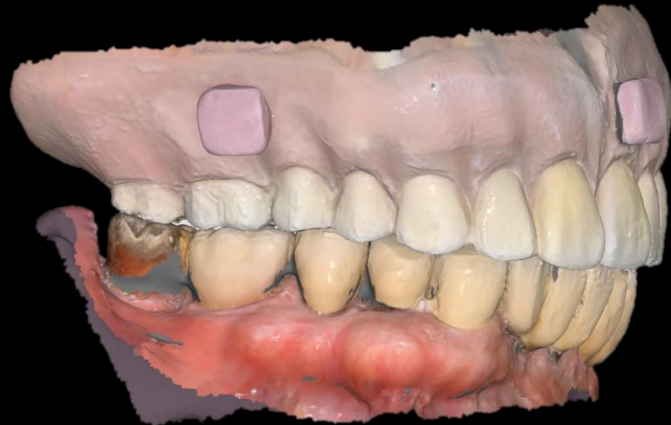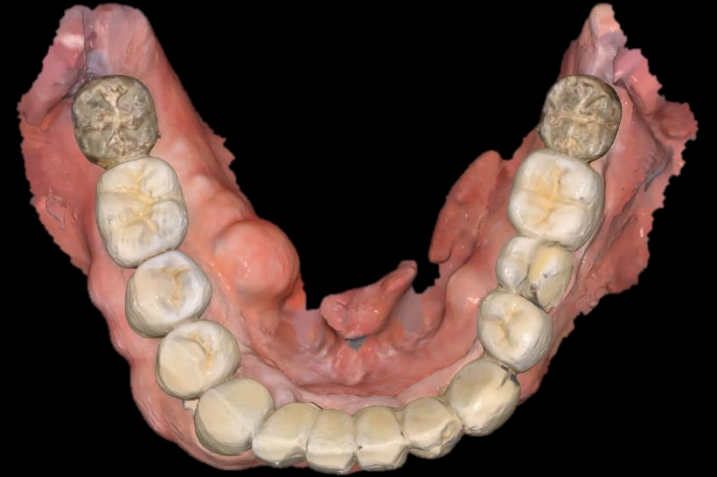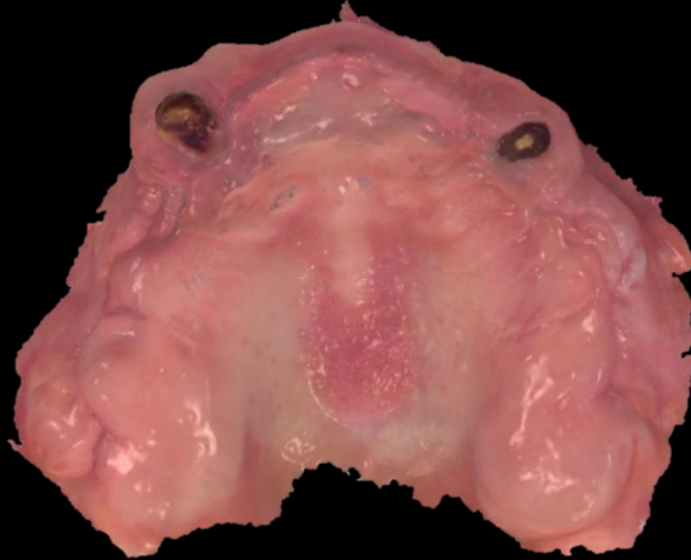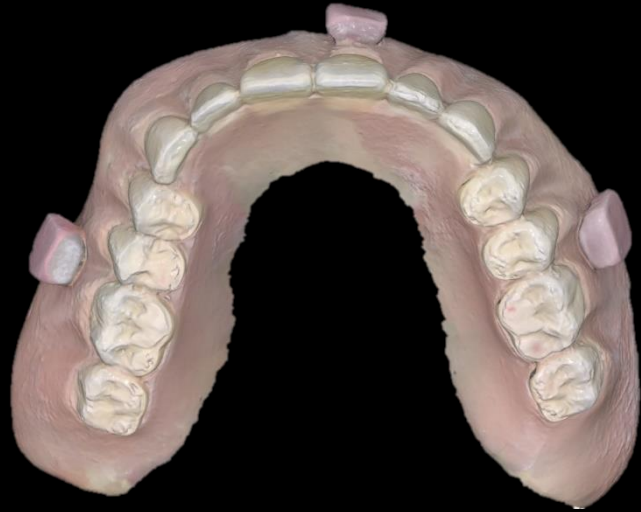H A L P  
F

H A L P  
F

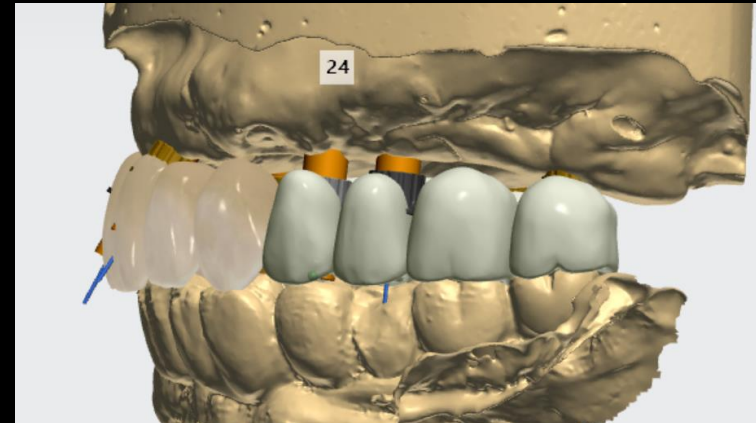
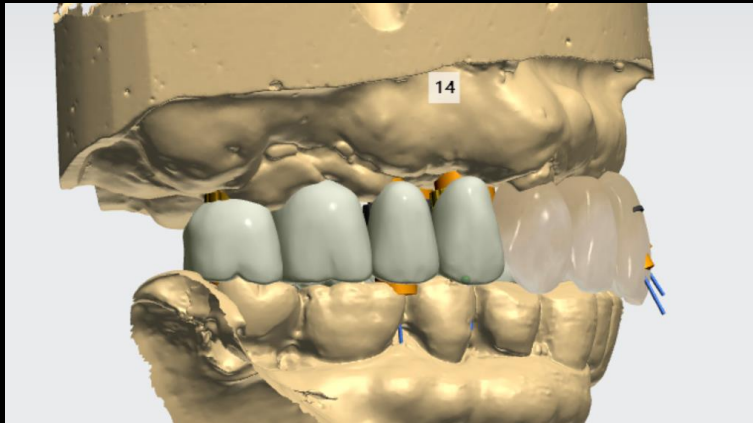
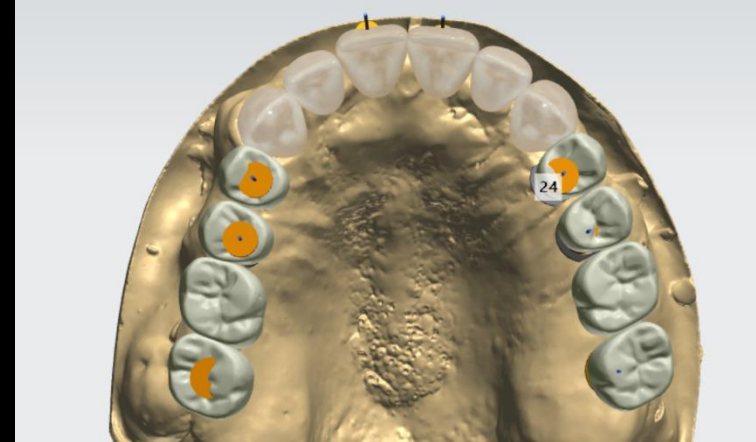
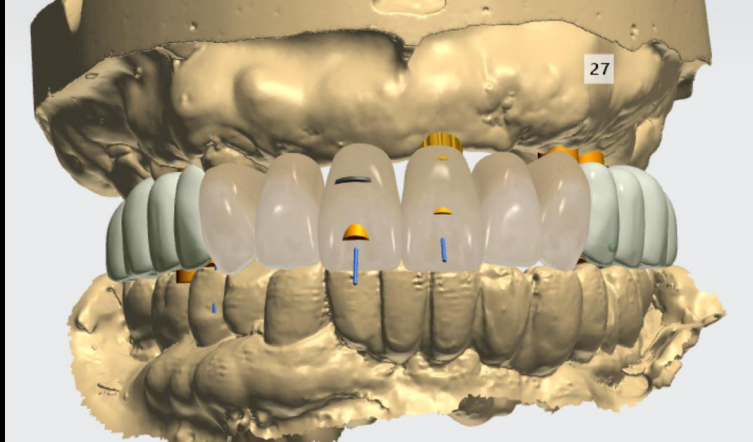
Nerve Info  
R 1.0mm

Dentium  
For Dentists By Dentists

# Intra Oral Scanning

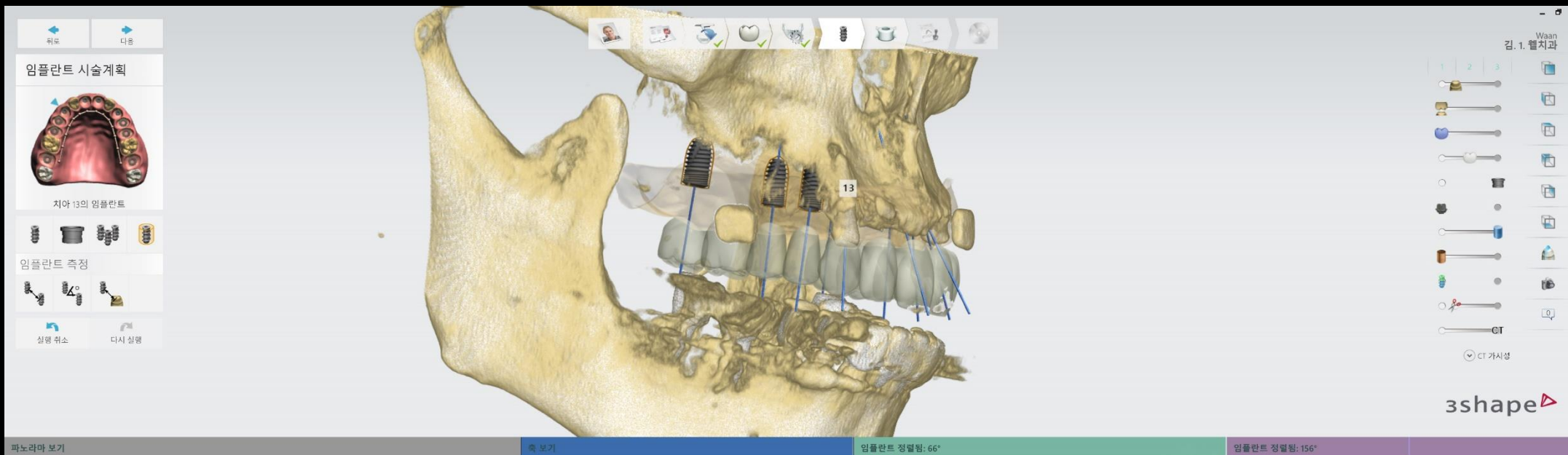


# Digital Guide (Set-up)



# Digital Guide (#13 Implant Planning)

4311

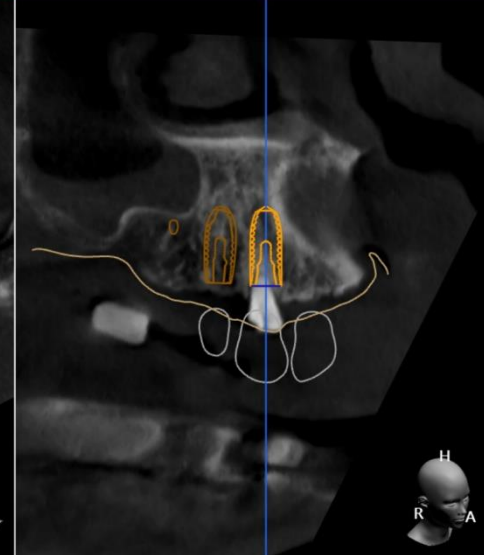
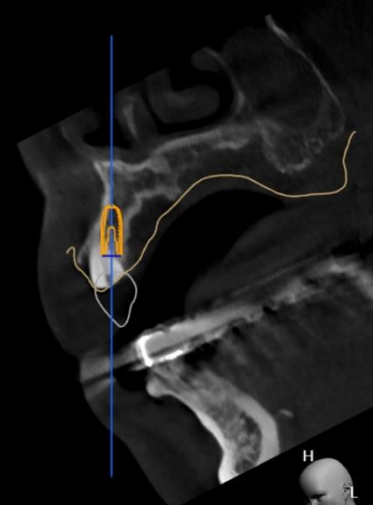
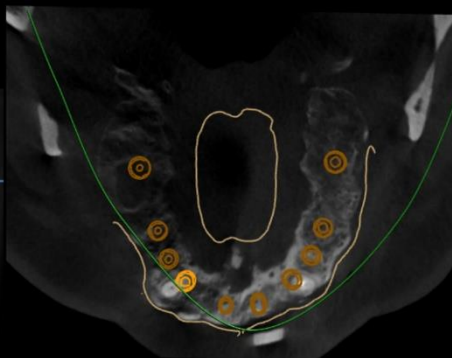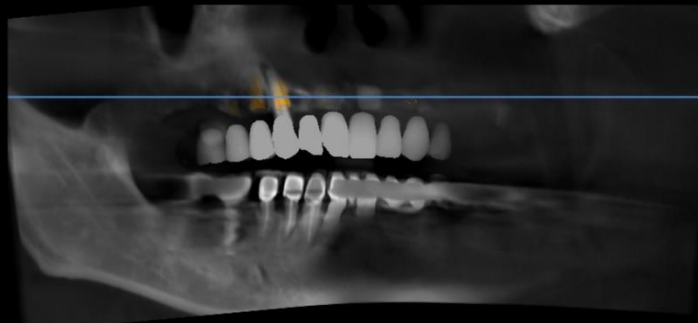


파노라마 보기

축 보기

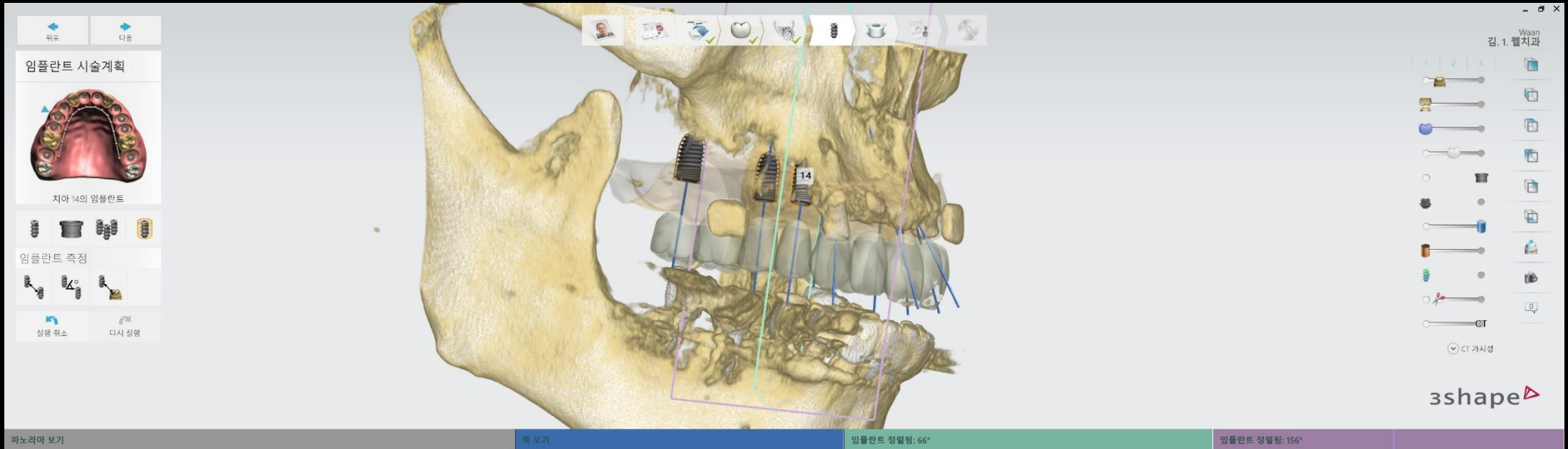
임플란트 정렬됨: 66°

임플란트 정렬됨: 156°



# Digital Guide (#14 Implant Planning)

4311

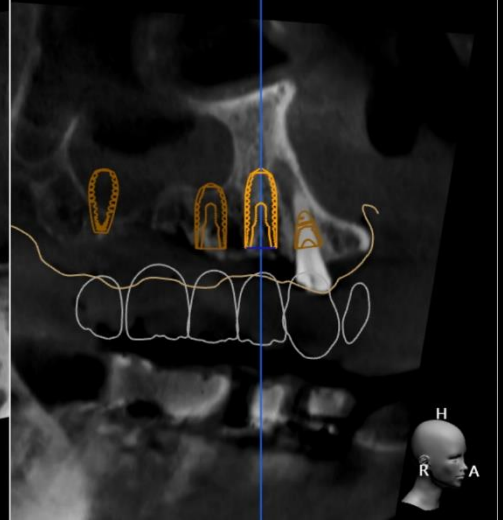
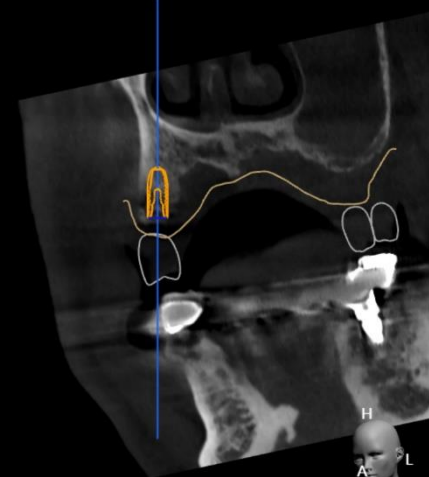
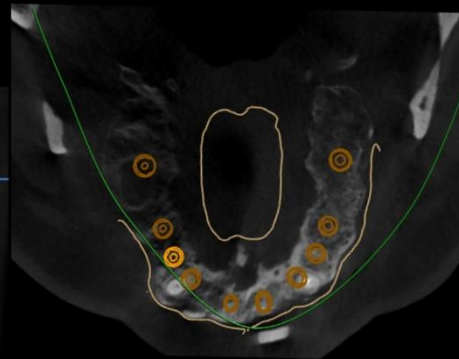
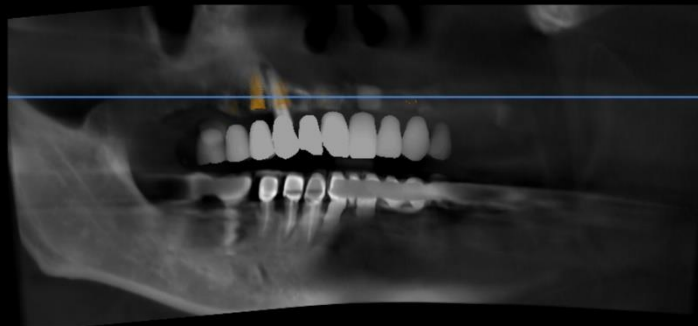


파노라마 보기

축 보기

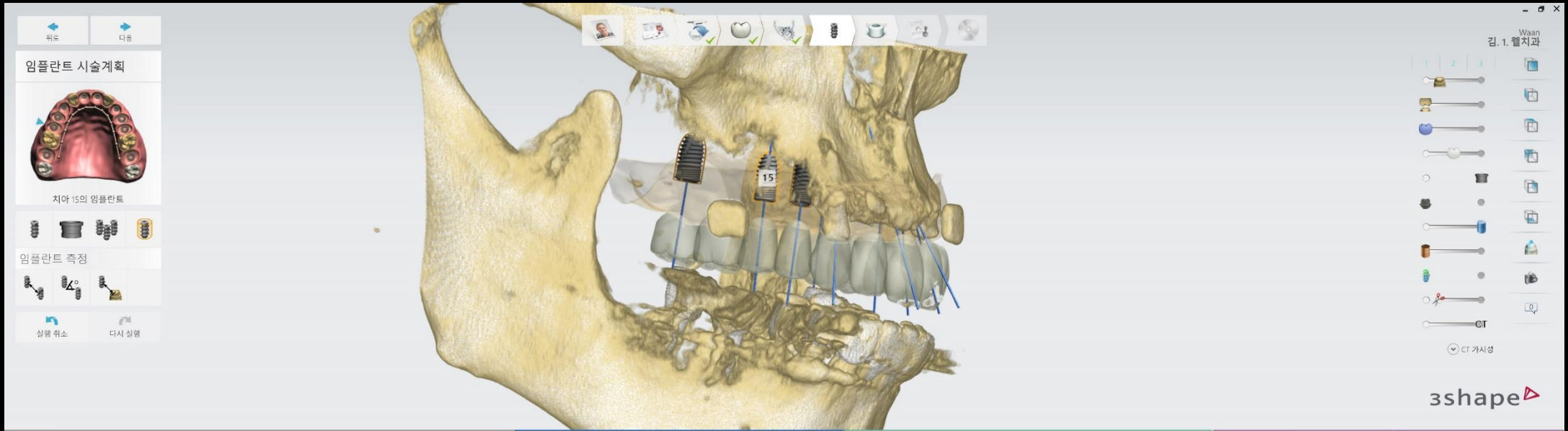
임플란트 정렬됨: 66°

임플란트 정렬됨: 156°





# Digital Guide (#15 Implant Planning)

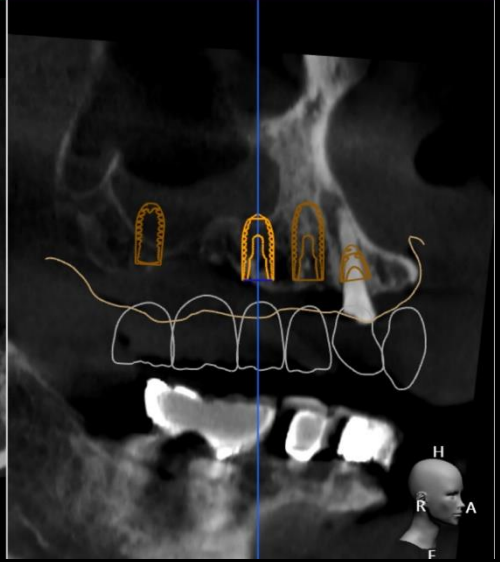
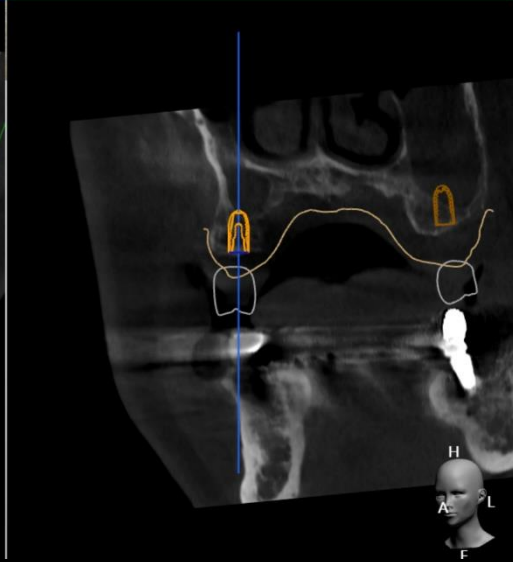
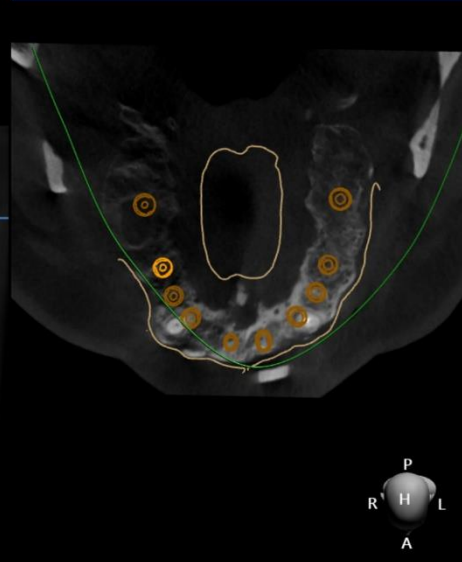
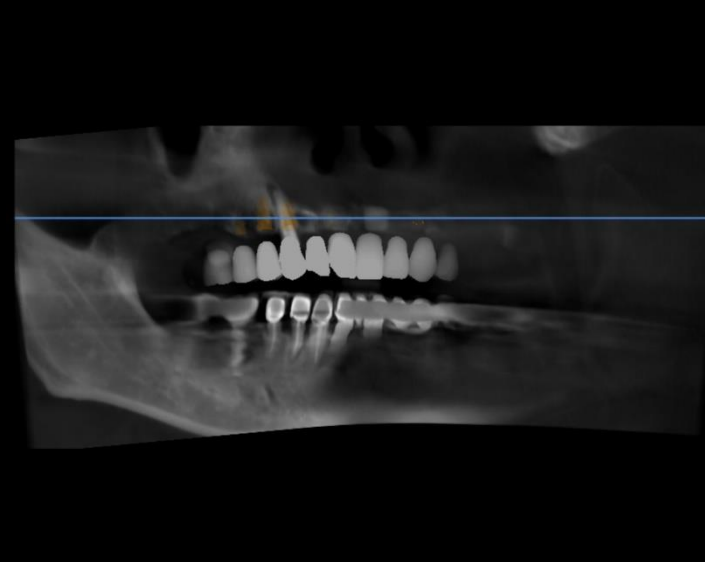


파노라마 보기

축 보기

임플란트 정렬됨: 66°

임플란트 정렬됨: 156°



# Digital Guide (#17 Implant Planning)

5009

뒤로 다음

임플란트 시술계획

치아 17의 임플란트

임플란트 측정

실링 취소 다시 실링

Waan 김. 1. 열치과

비밀성 영록

CT 가시성

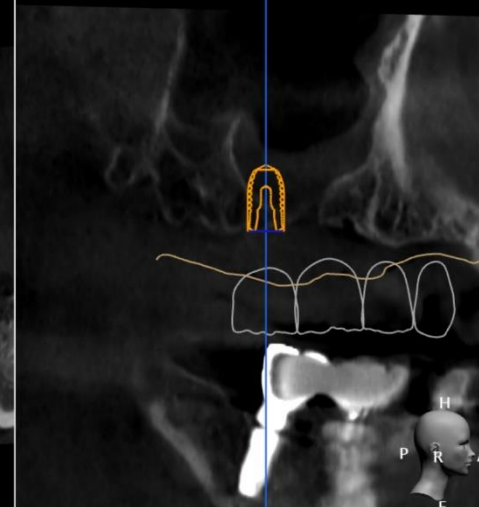
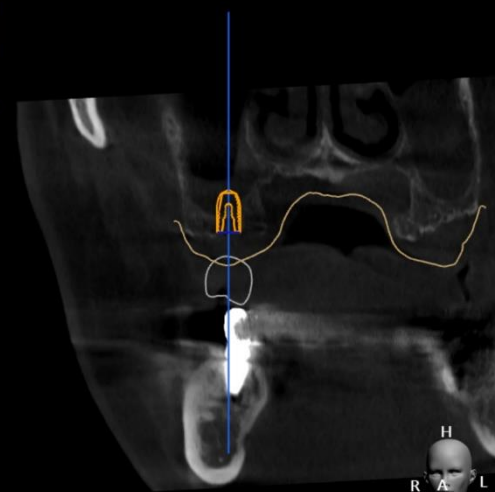
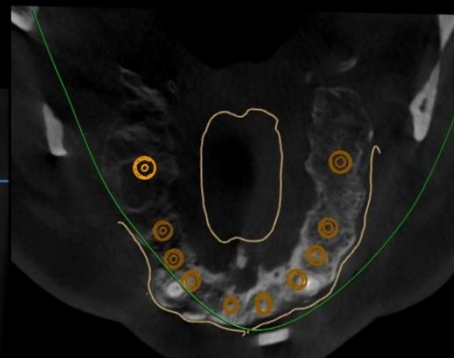
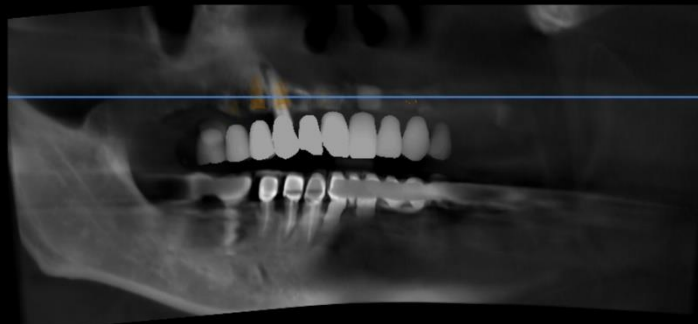
3shape

파노라마 보기

축 보기

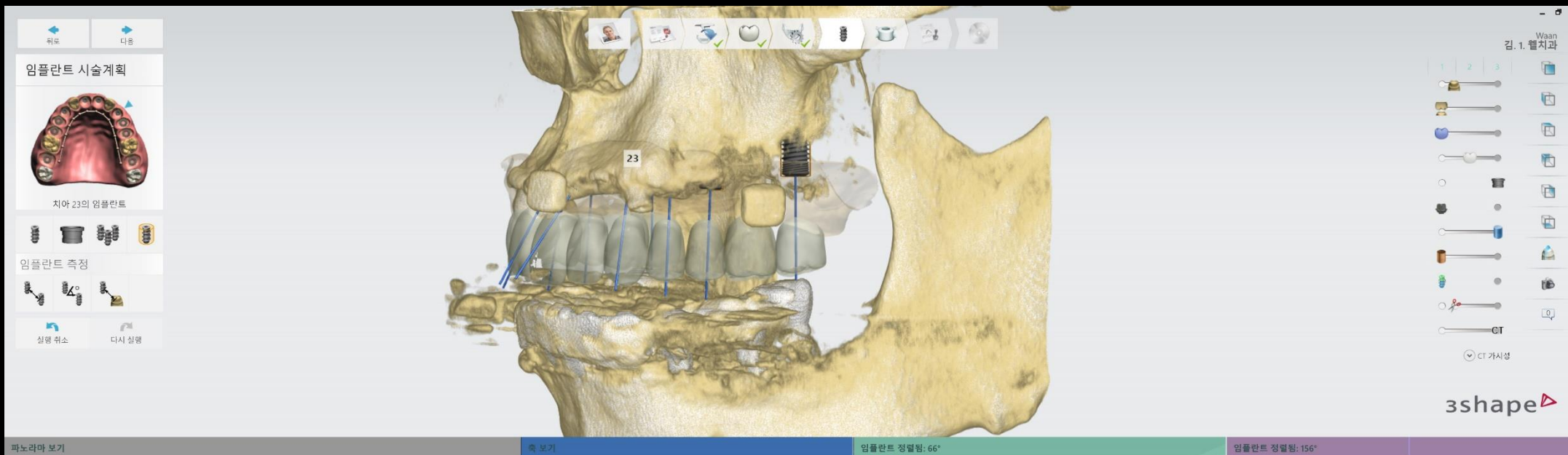
임플란트 정렬됨: 66°

임플란트 정렬됨: 156°



# Digital Guide (#23 Implant Planning)

4311

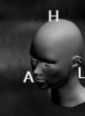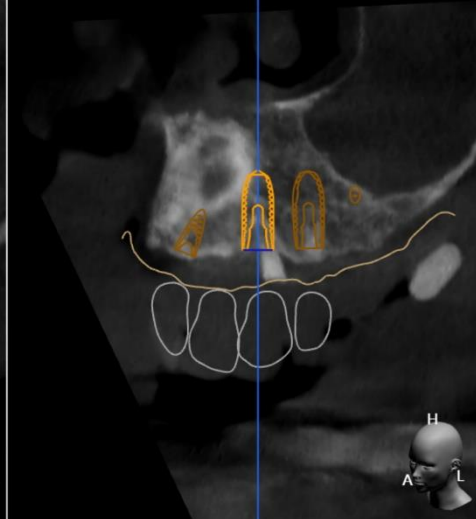
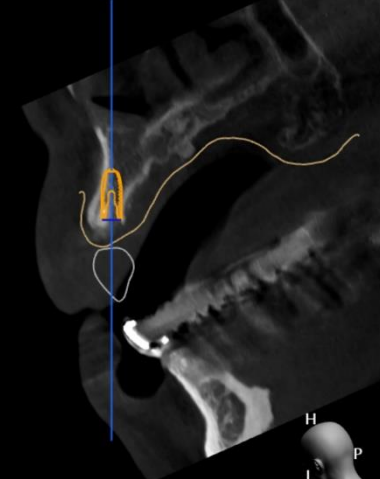
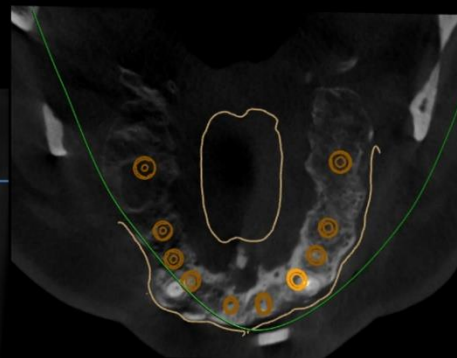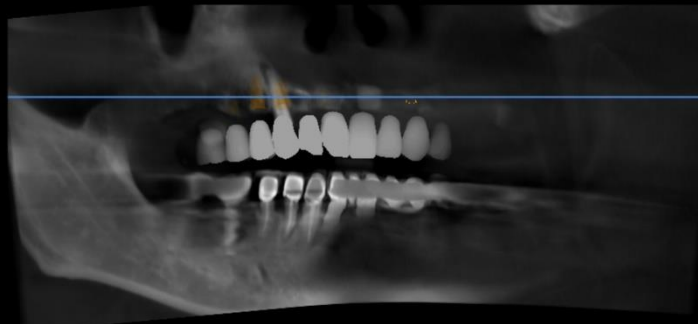


파노라마 보기

축 보기

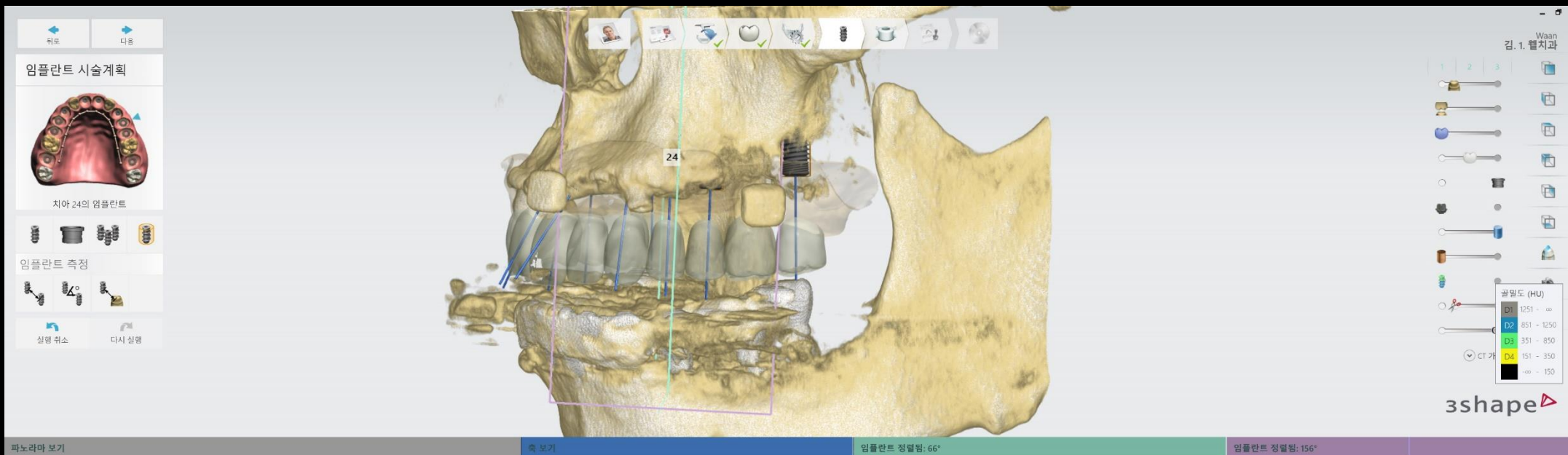
임플란트 정렬됨: 66°

임플란트 정렬됨: 156°

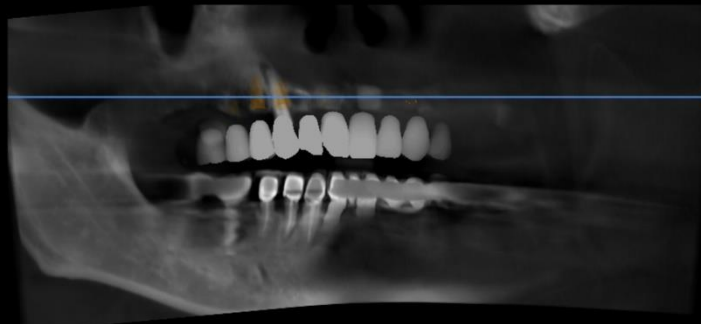


# Digital Guide (#24 Implant Planning)

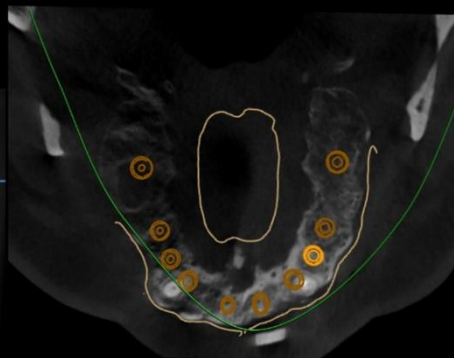4311



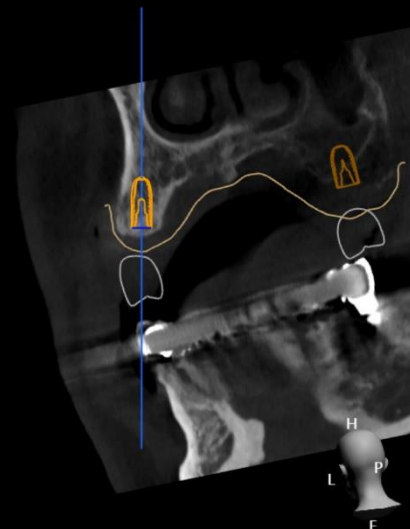
파노라마 보기



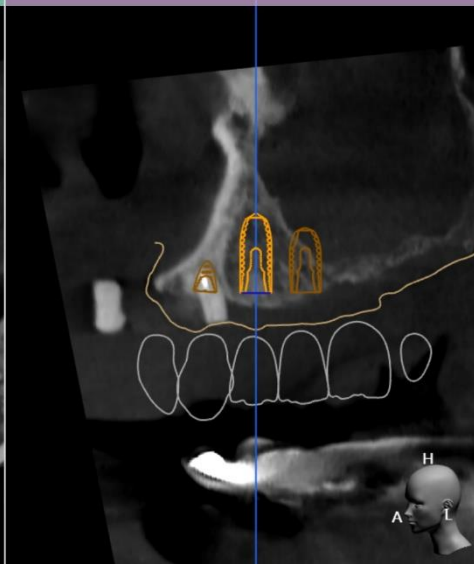
축 보기



임플란트 정렬됨: 66°



임플란트 정렬됨: 156°



# Digital Guide (#25 Implant Planning)

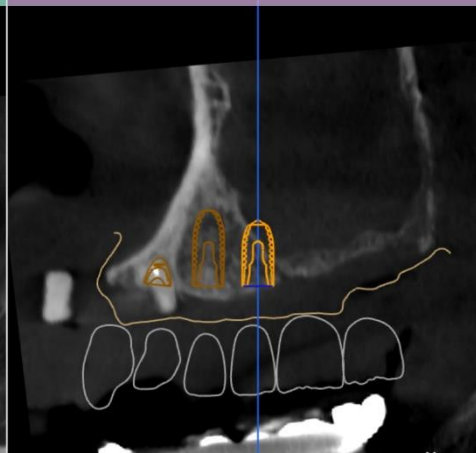
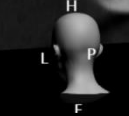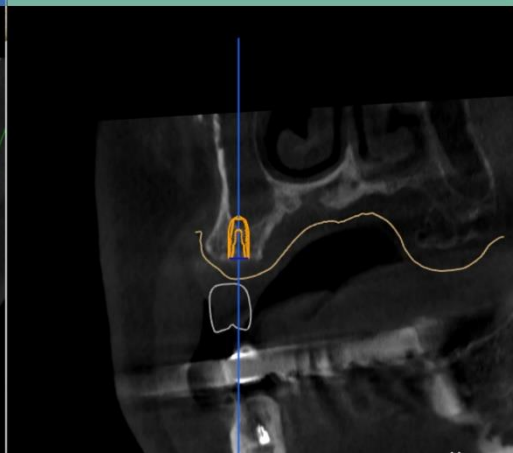
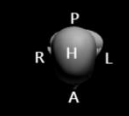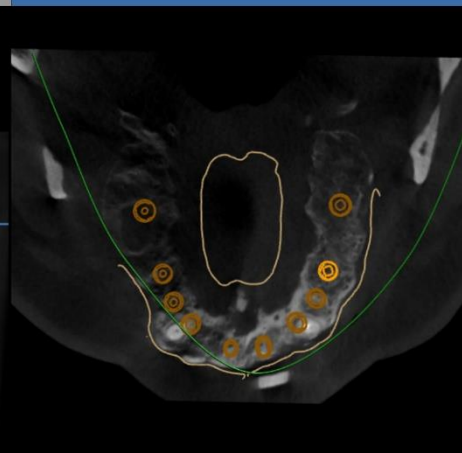
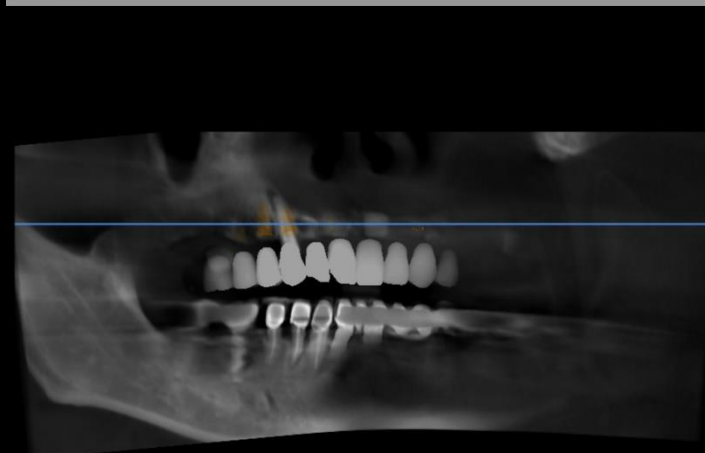
The main interface shows a 3D model of a patient's maxilla and mandible. A specific implant site is highlighted with a blue line and labeled '25'. The software includes a left sidebar with navigation buttons (뒤로, 다음) and a menu for '임플란트 시술계획' (Implant Surgery Planning). This menu contains a 3D model of the dental arch, a list of '치아 25의 임플란트' (Implant for tooth 25), and various implant options. A right sidebar contains a toolbar with icons for different implant types and a 'CT 가져오기' (Load CT) button. The 3Shape logo is visible in the bottom right corner.

파노라마 보기

축 보기

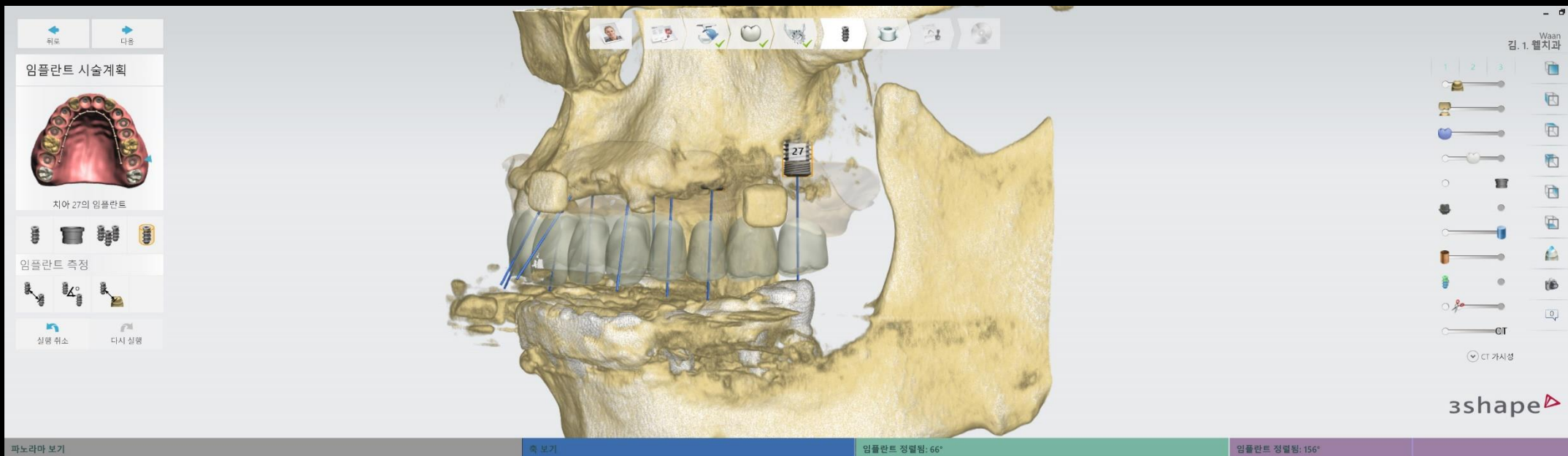
임플란트 정렬됨: 66°

임플란트 정렬됨: 156°



# Digital Guide (#27 Implant Planning)

5009

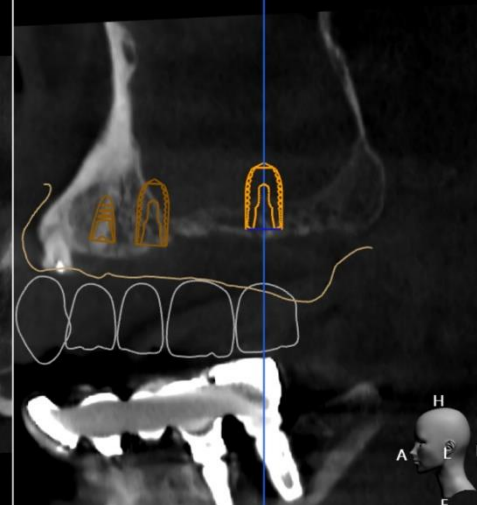
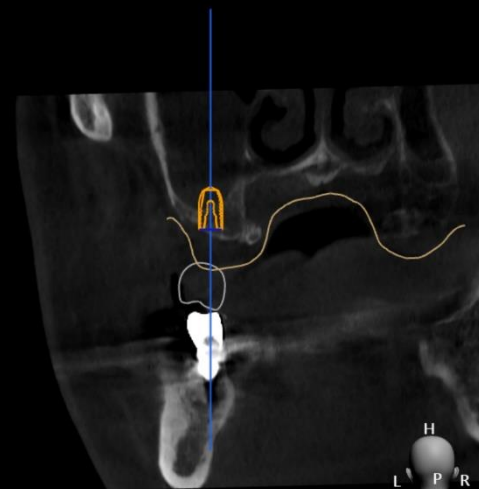
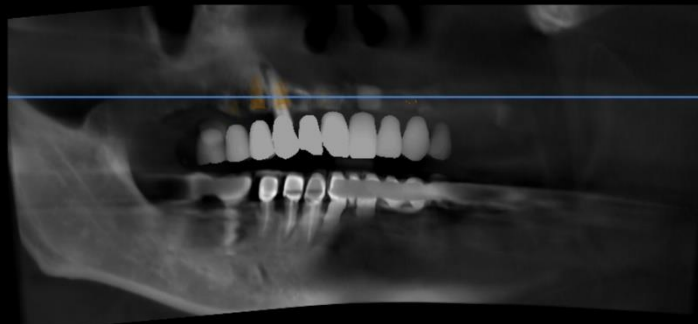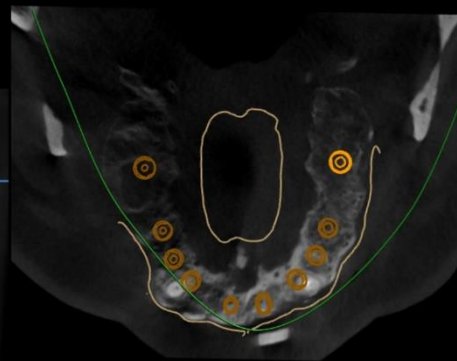


파노라마 보기

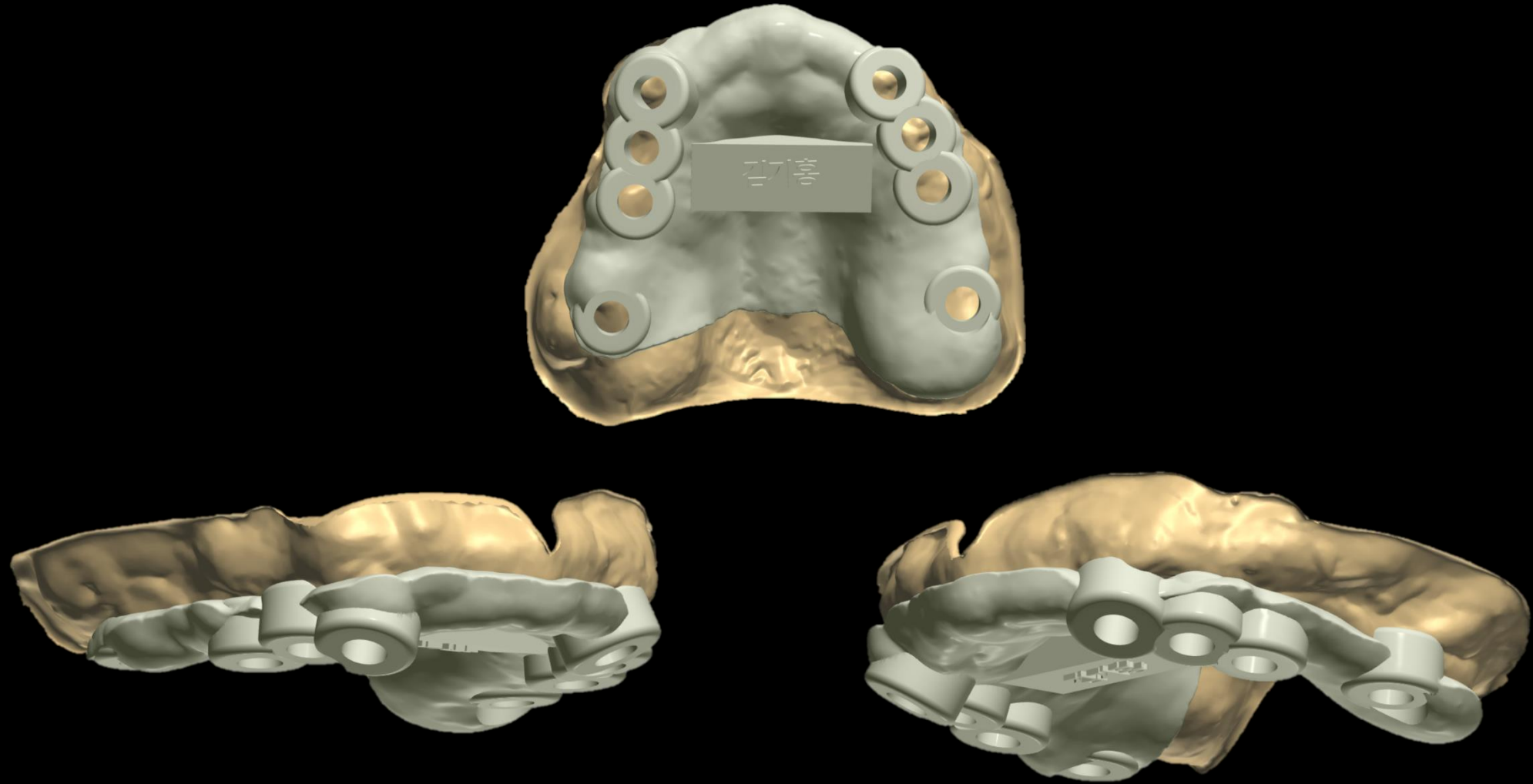
축 보기

임플란트 정렬됨: 66°

임플란트 정렬됨: 156°

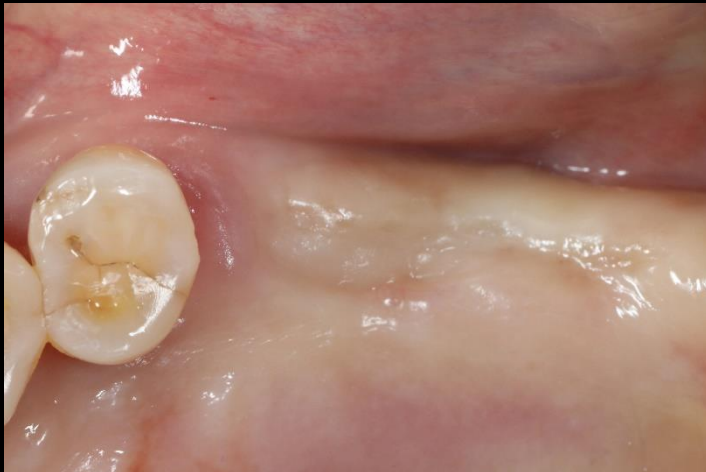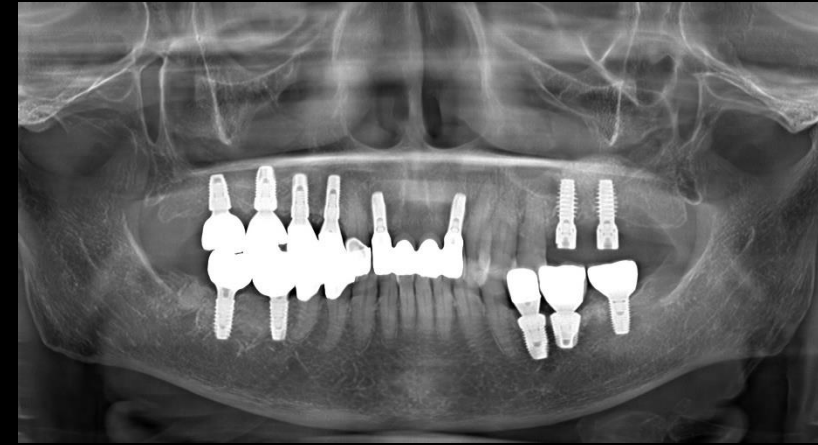

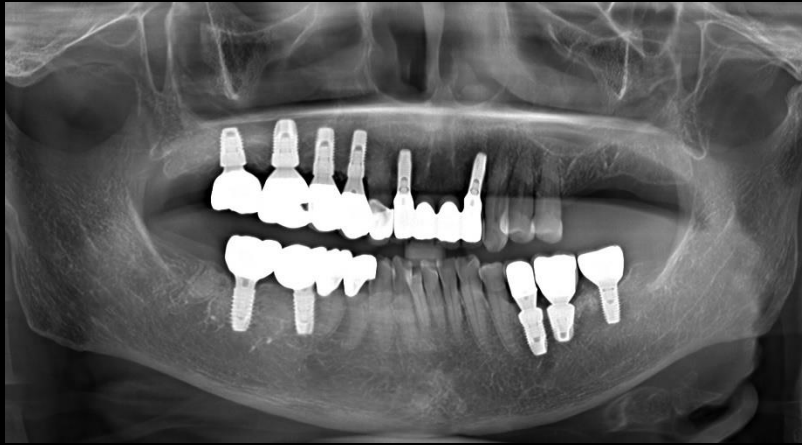
# Digital Guide (Stent Design)

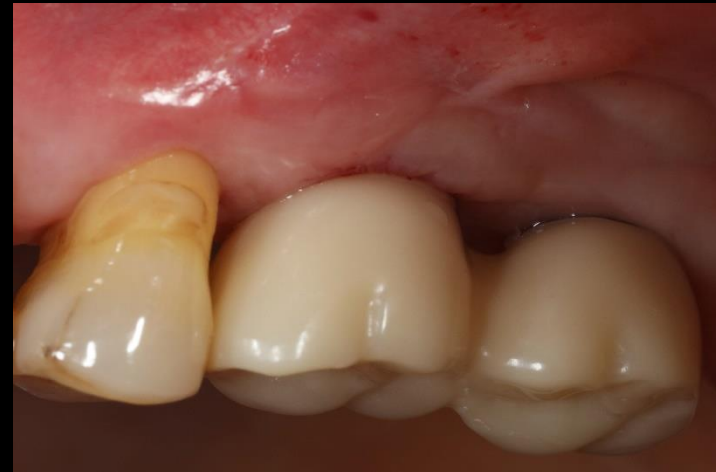

# Similar case presentation (1)

- Simple Sinus elevation & Implantation



Pre-op (2019-08-12)

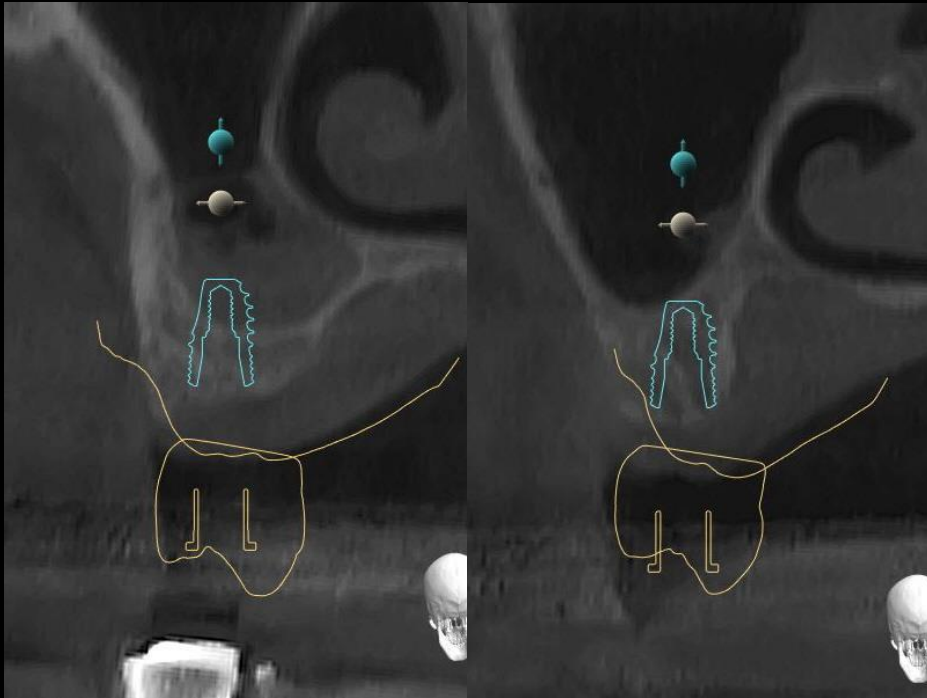


Provisional restoration (2019-11-11)

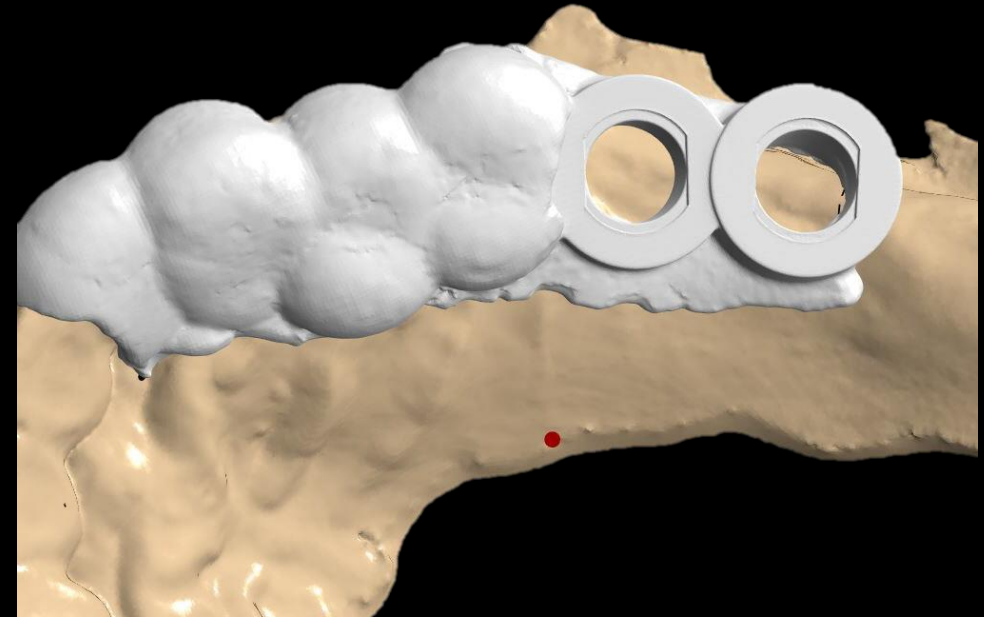


# Similar case presentation (1)

- Simple Sinus elevation & Implantation



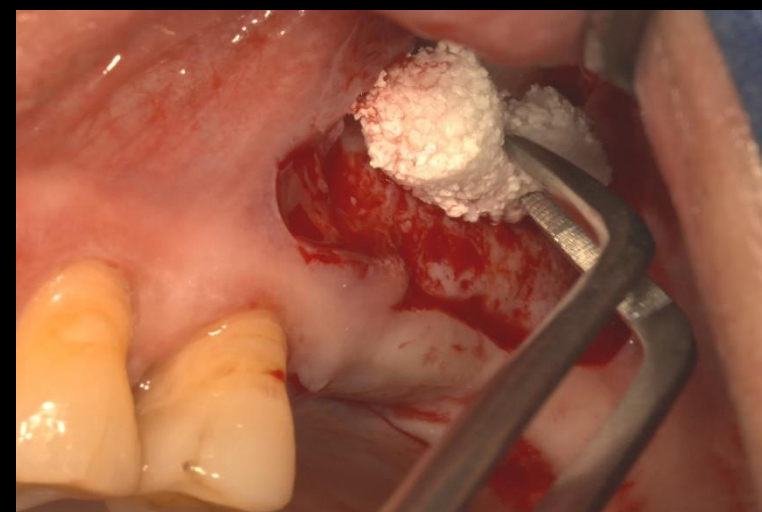
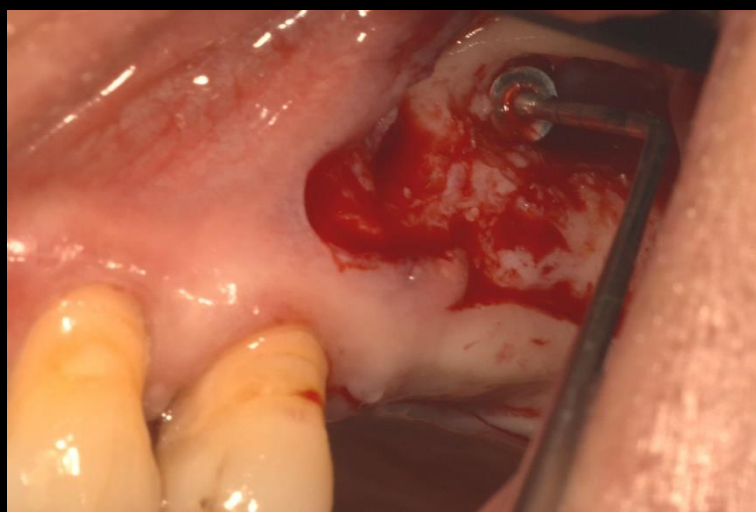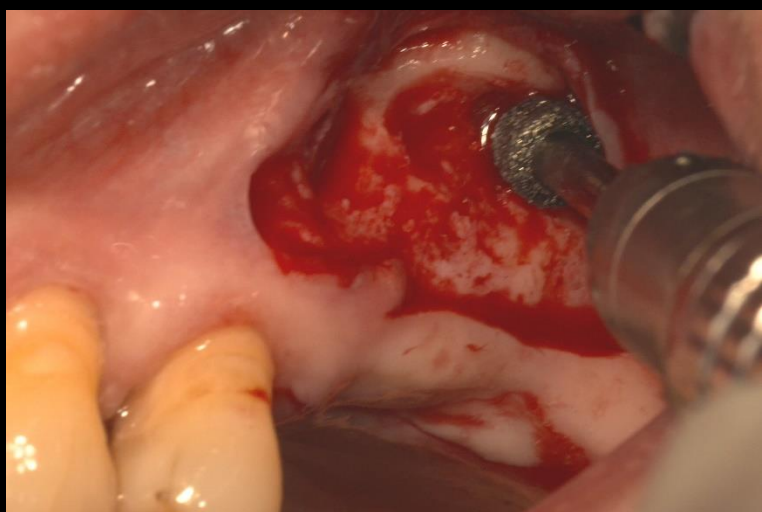
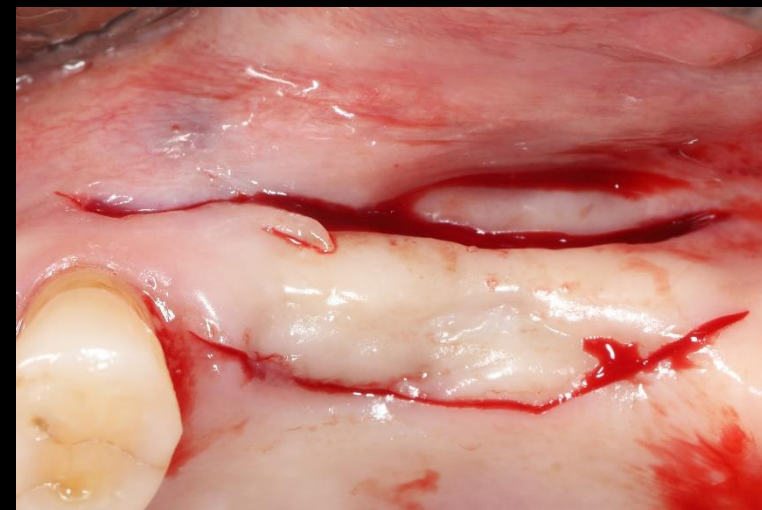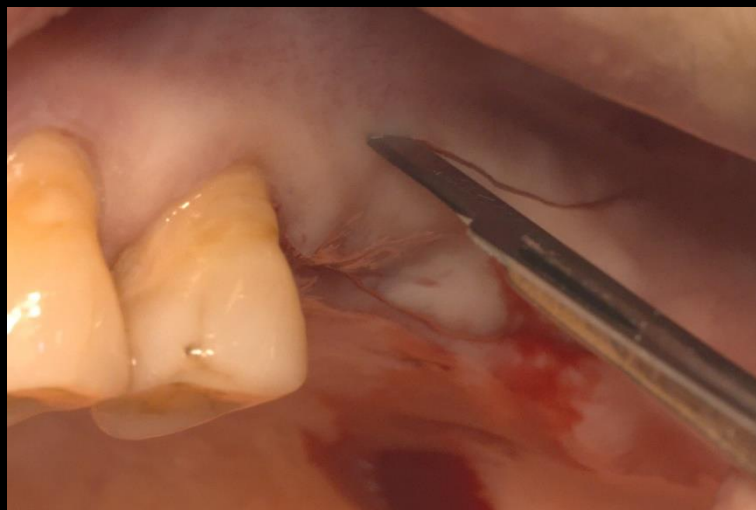
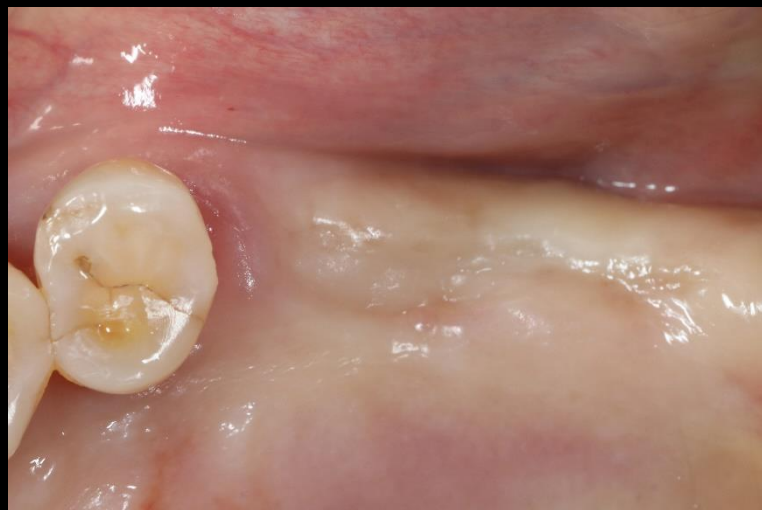Implant Planning



Stent Design

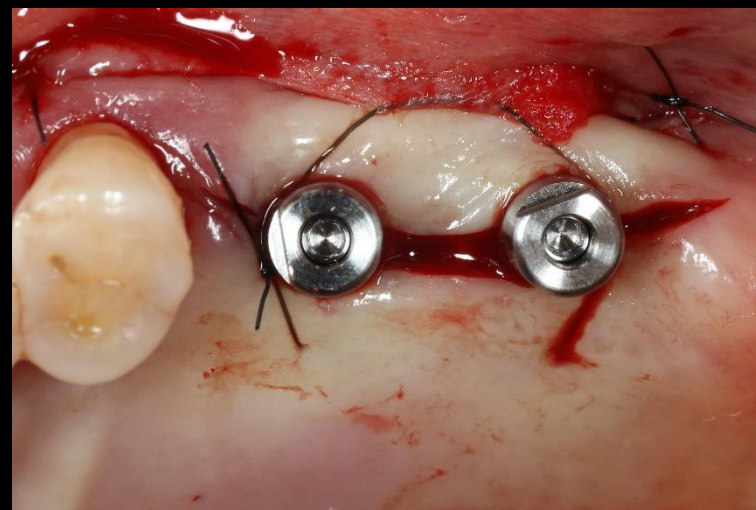
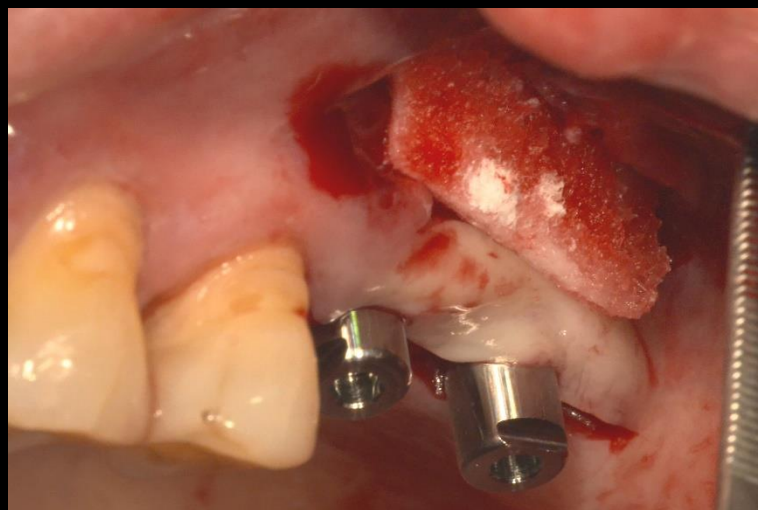
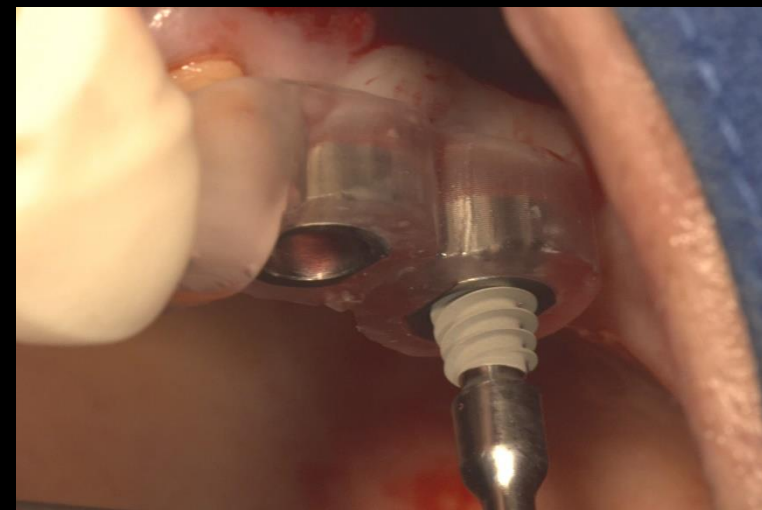
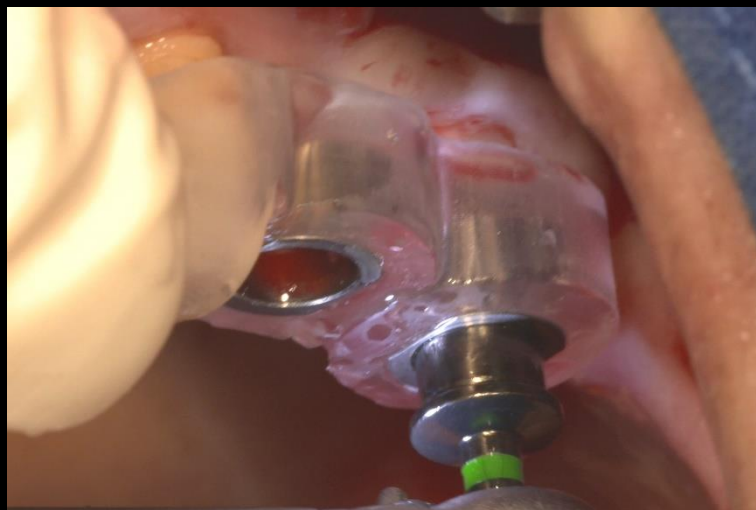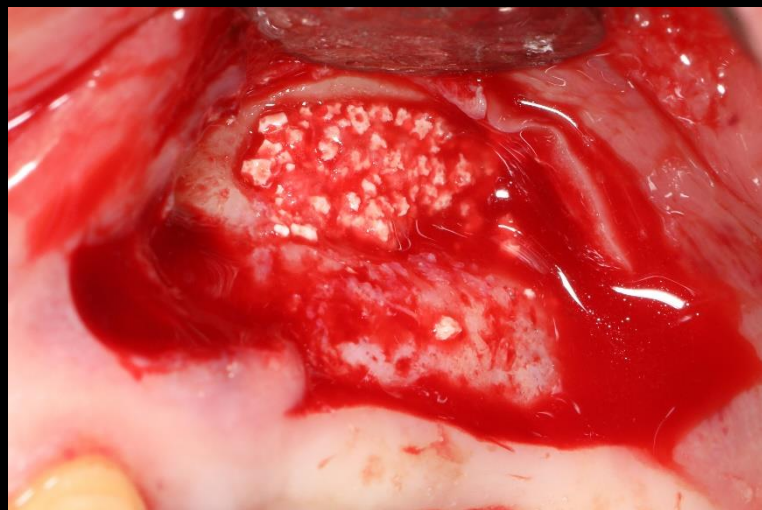
# Similar case presentation (1)

- Simple Sinus elevation & Implantation



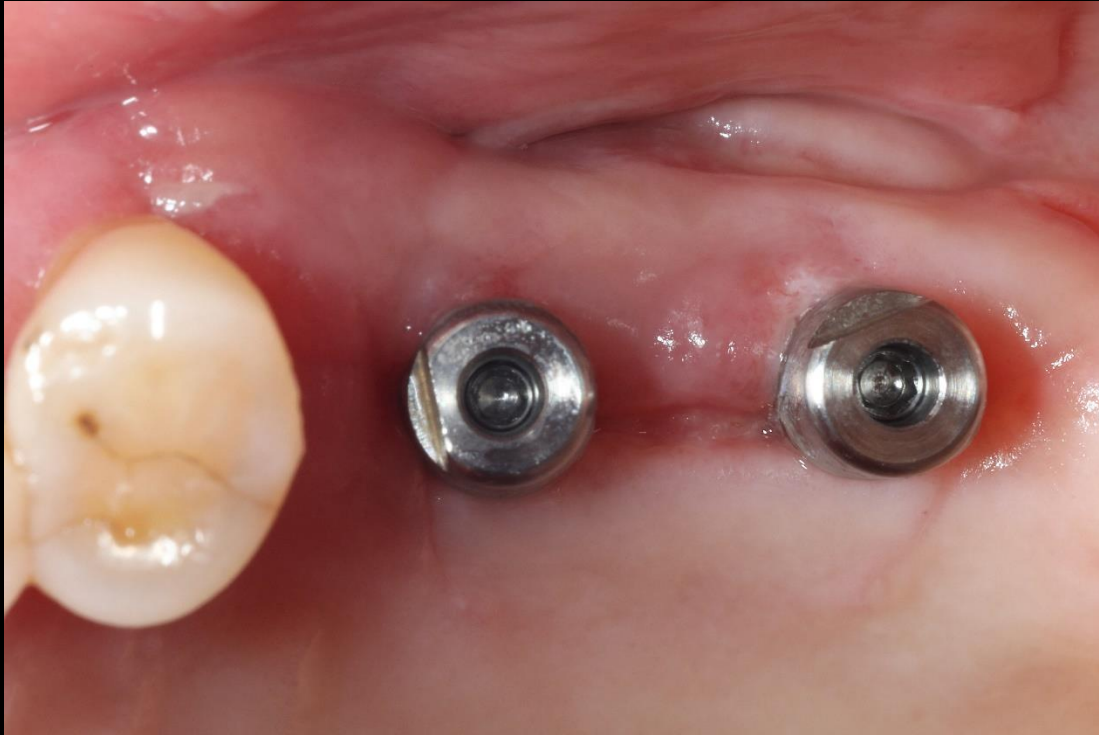# Similar case presentation (1)

- Simple Sinus elevation & Implantation

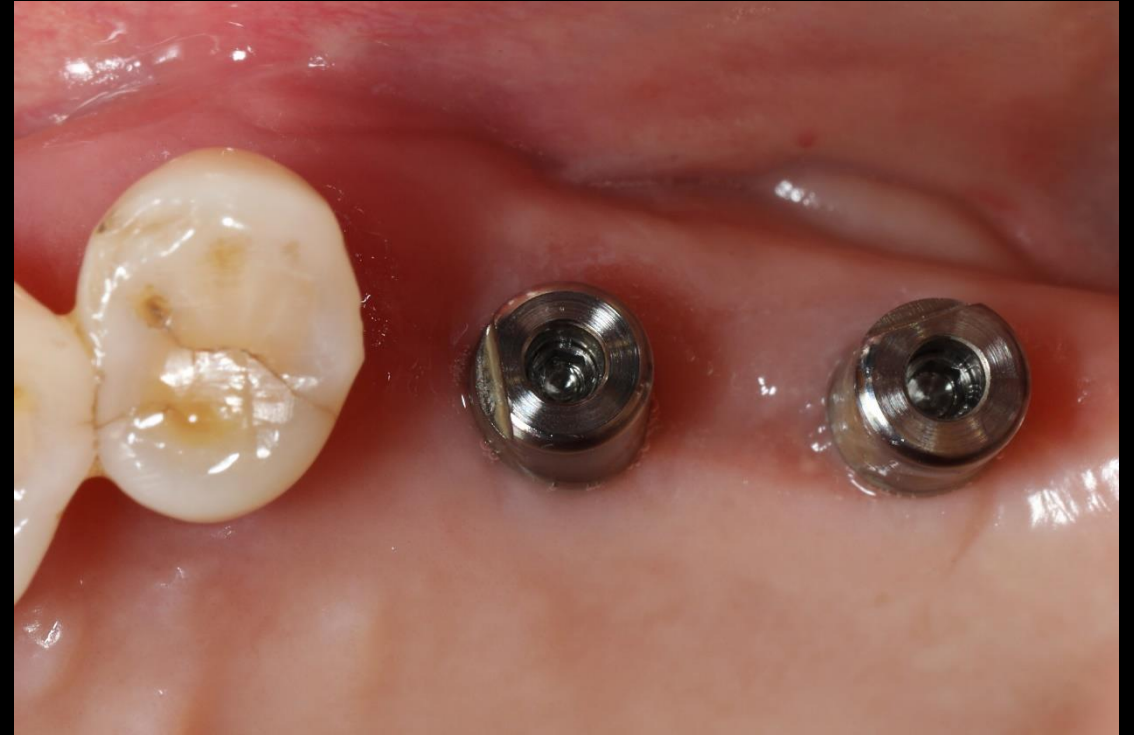

## Similar case presentation (1)

- Simple Sinus elevation & Implantation



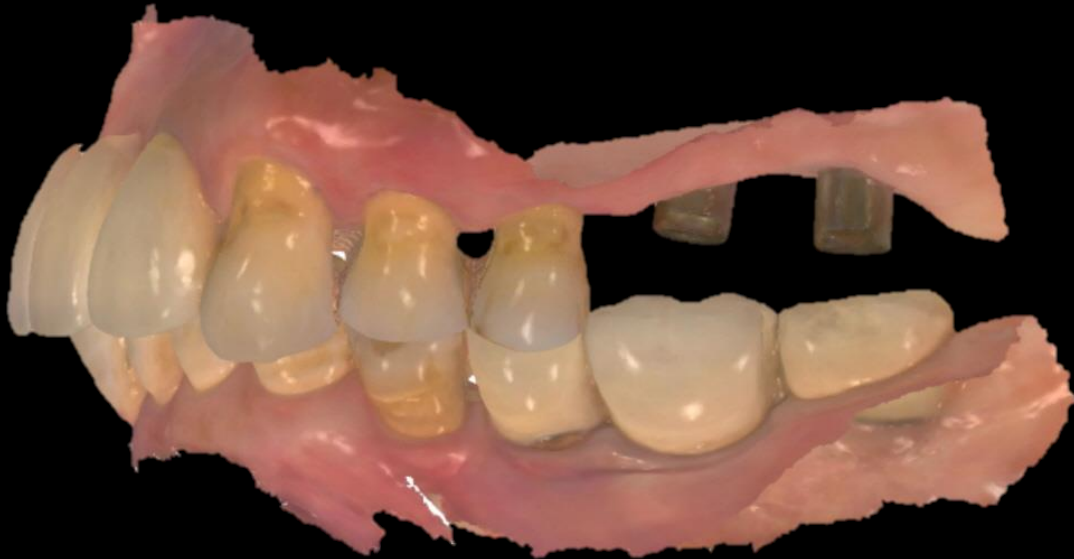Healing : 2 weeks  
(2019-08-26)



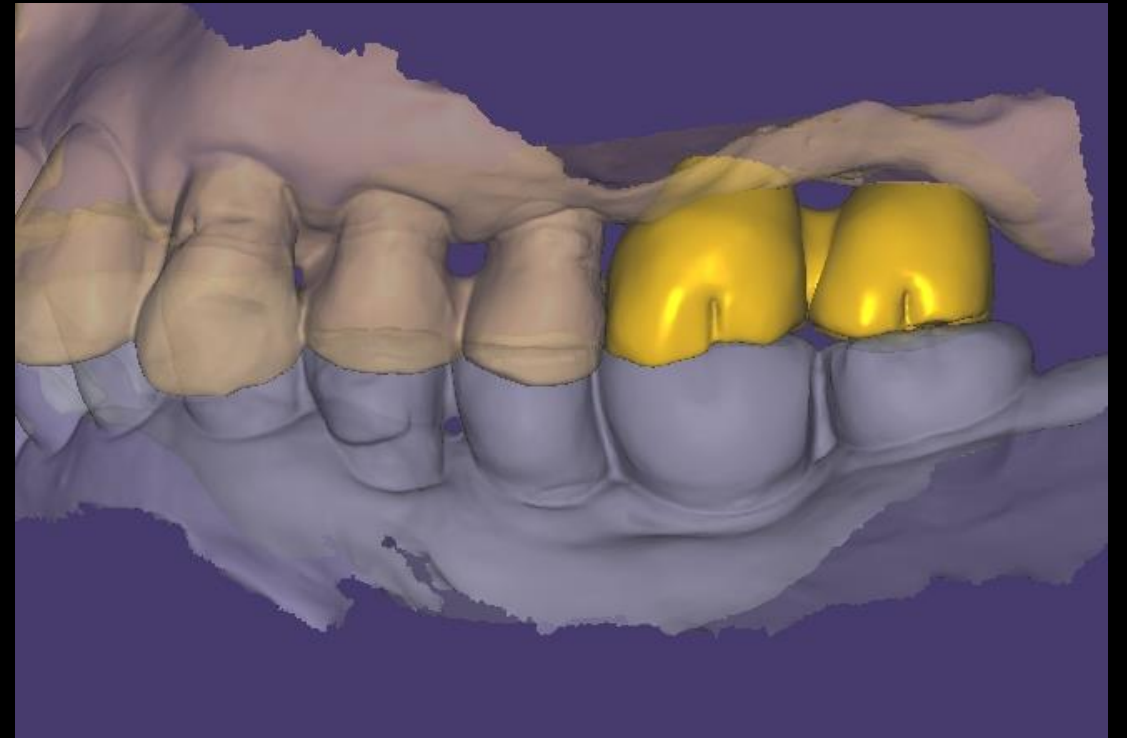
Healing : 1 month  
(2019-09-09)

## Similar case presentation (1)

- Simple Sinus elevation & Implantation



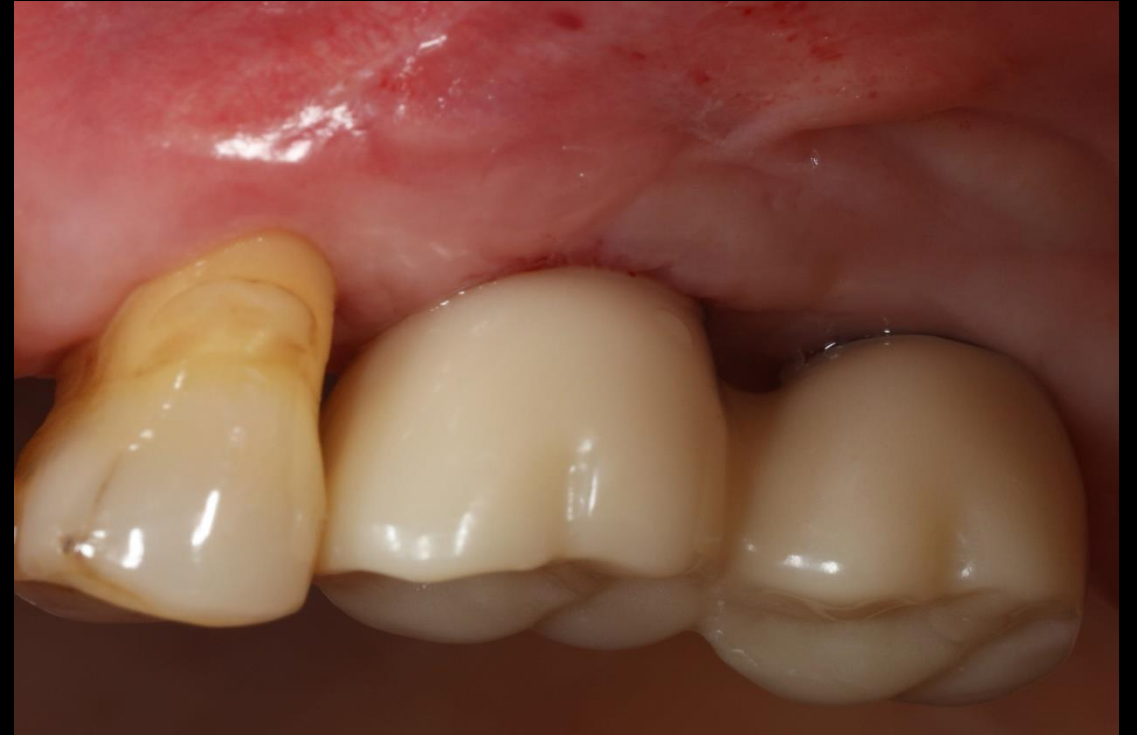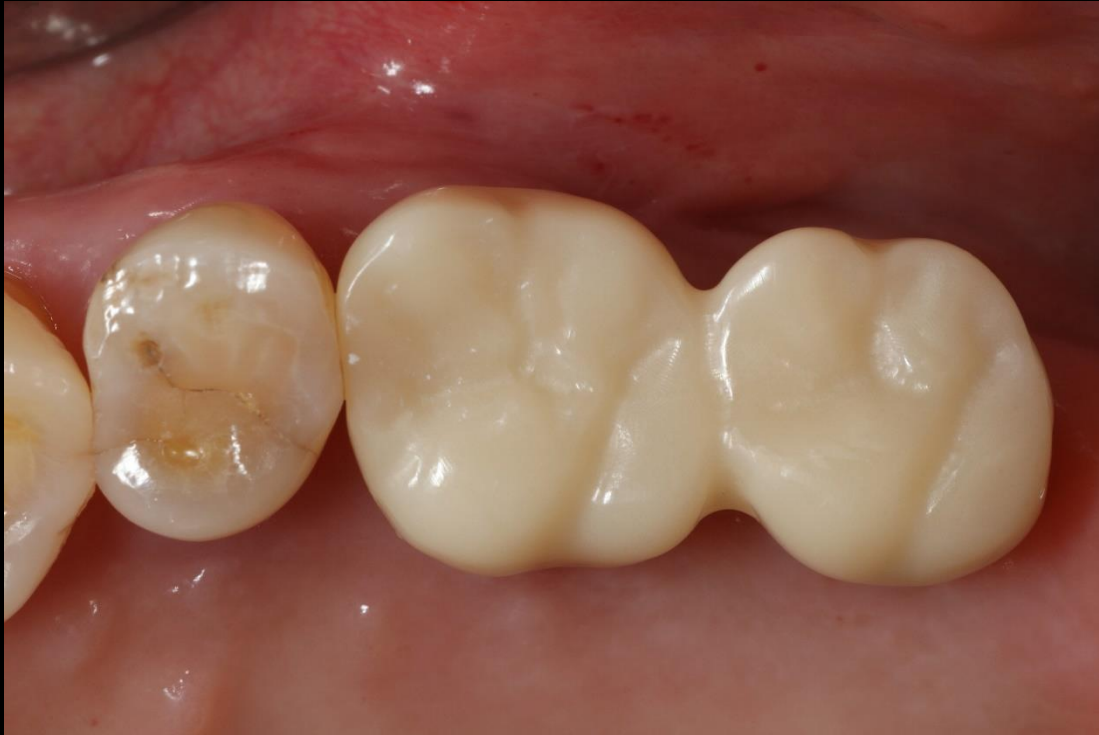Intra Oral Scanning



CAD  
(Provisional restoration)

## Similar case presentation (1)

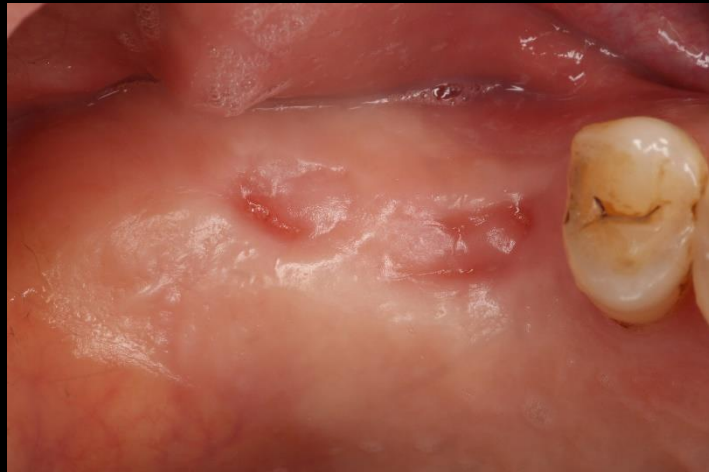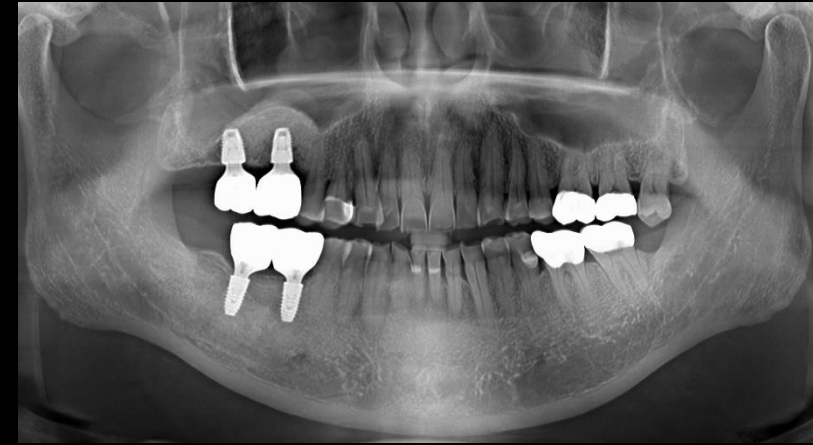
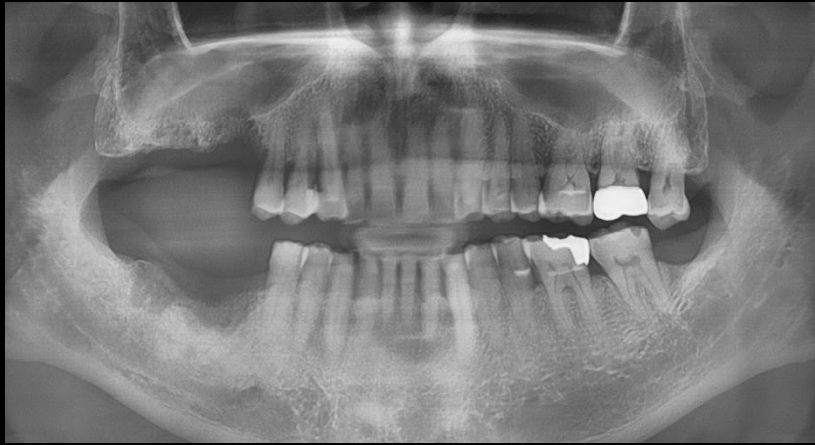
- Simple Sinus elevation & Implantation



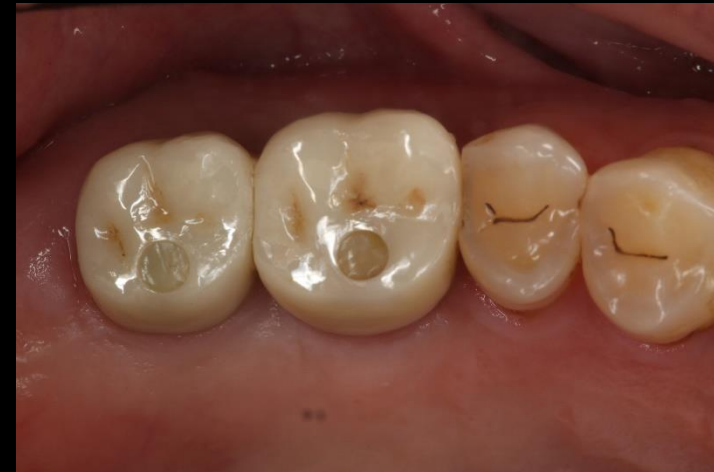Provisional restoration  
(2019-11-11)

## Similar case presentation (2)

- Sinus elevation & Removal of Mucocele



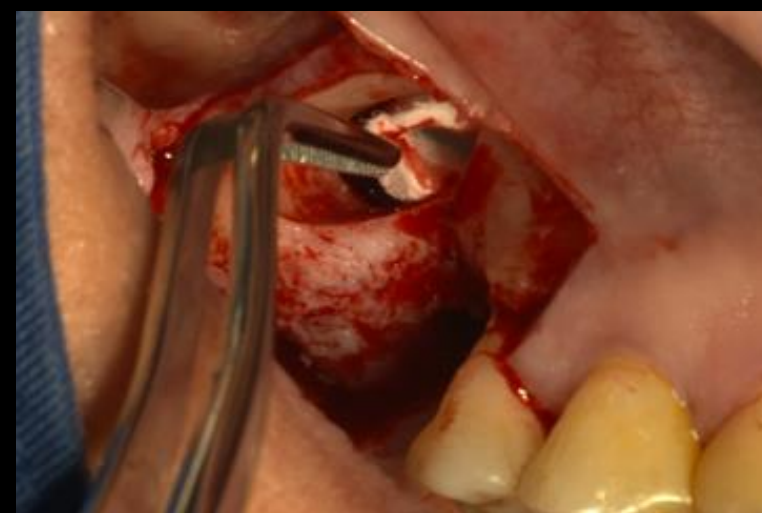
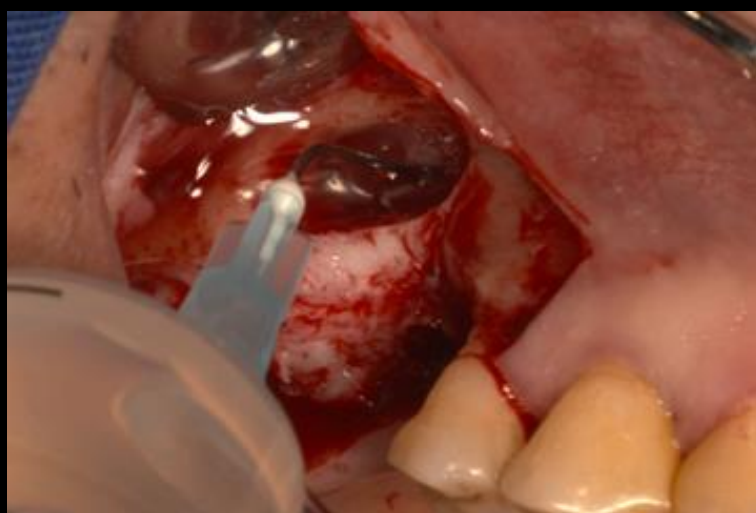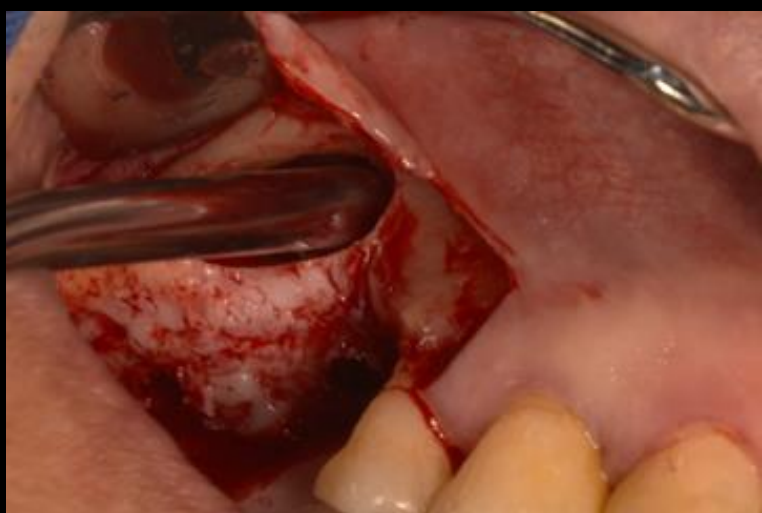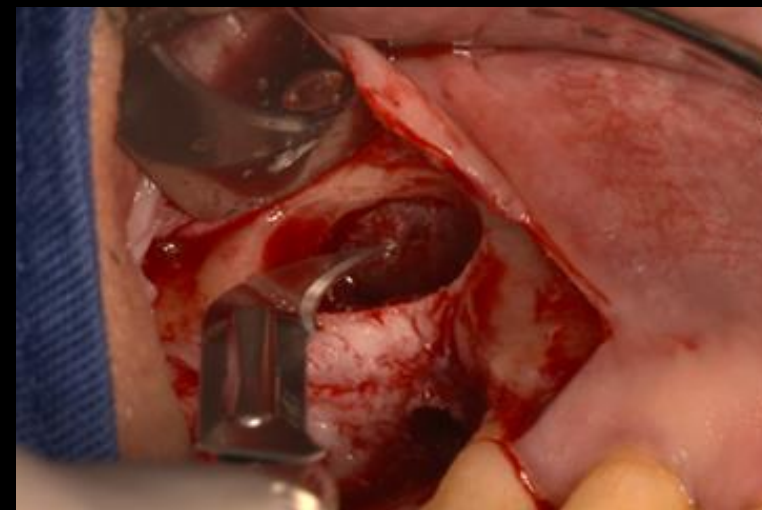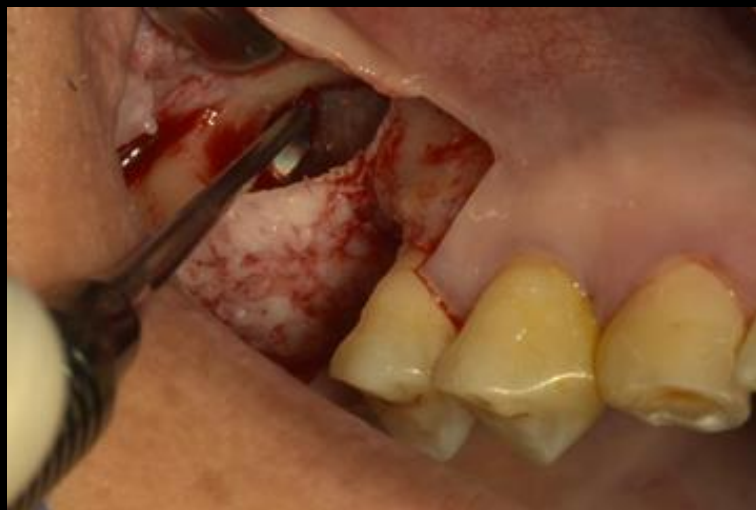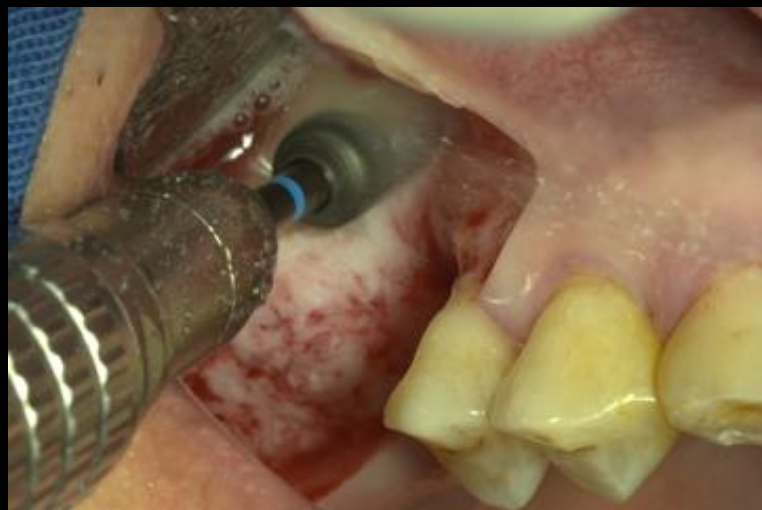
Pre-op (2016-09-21)



Follow up : 2 years 5 months(2019-08-27)

## Similar case presentation (2)

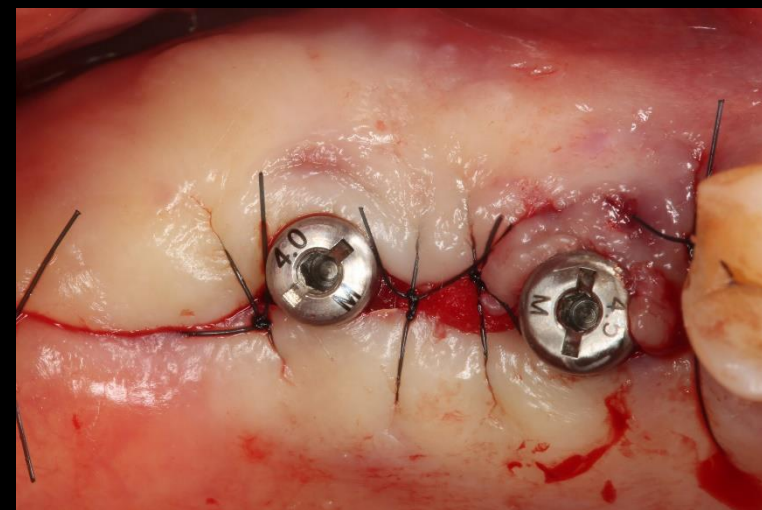
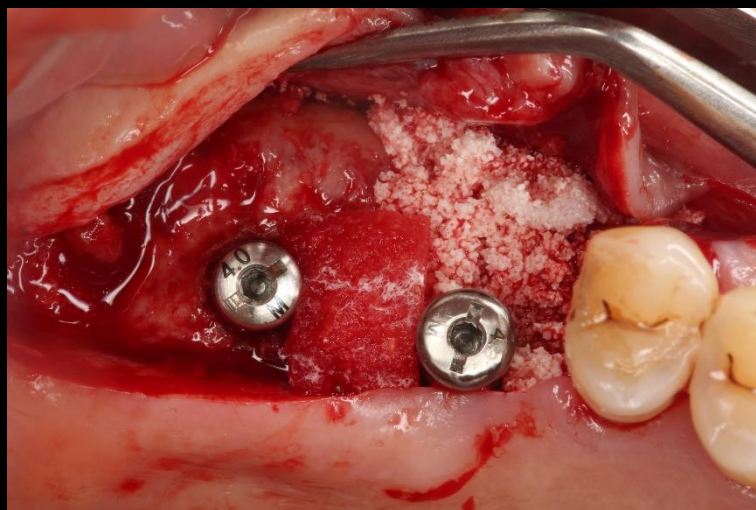
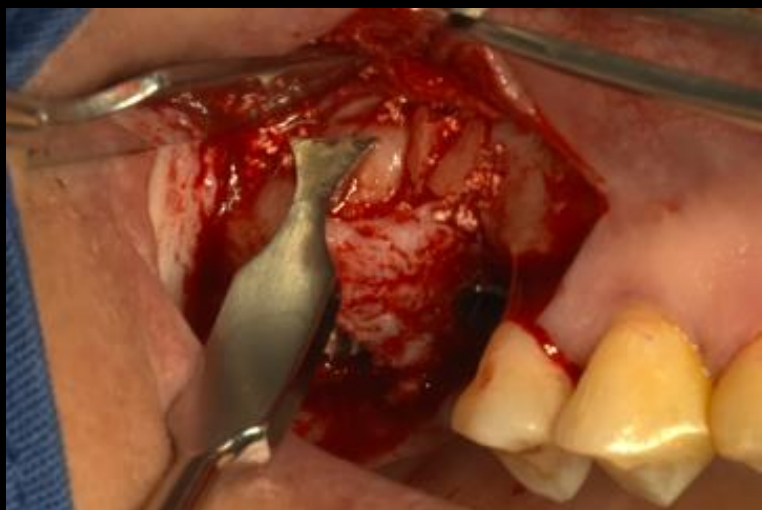
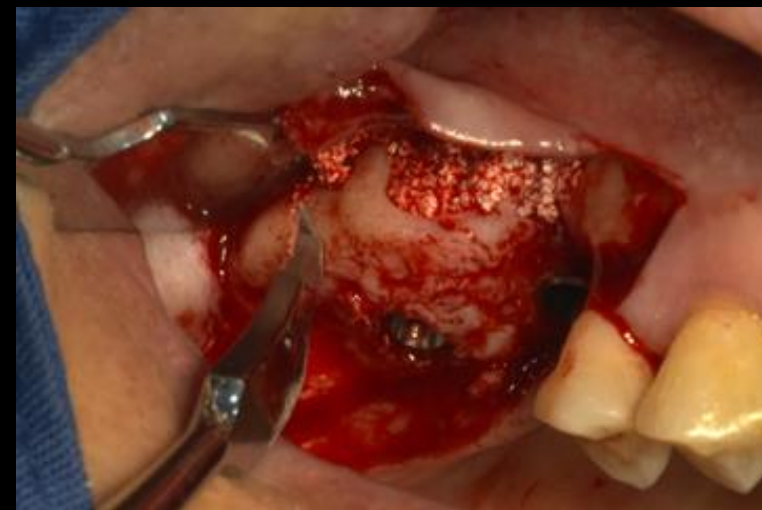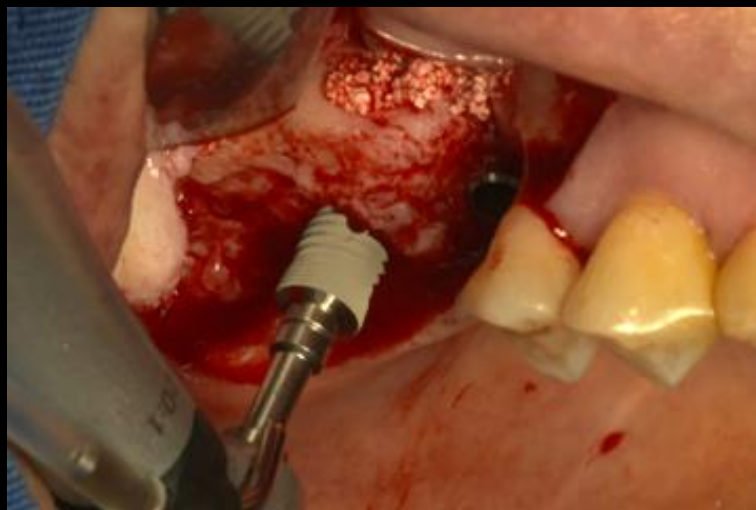
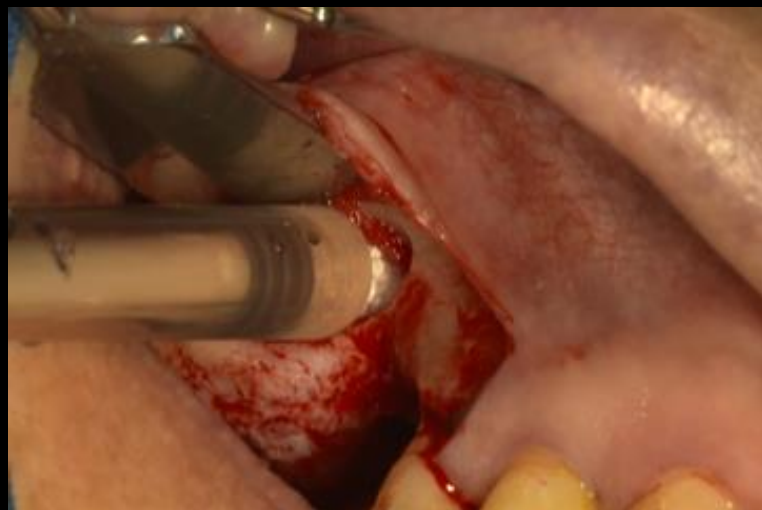
- Sinus elevation & Removal of Mucocele





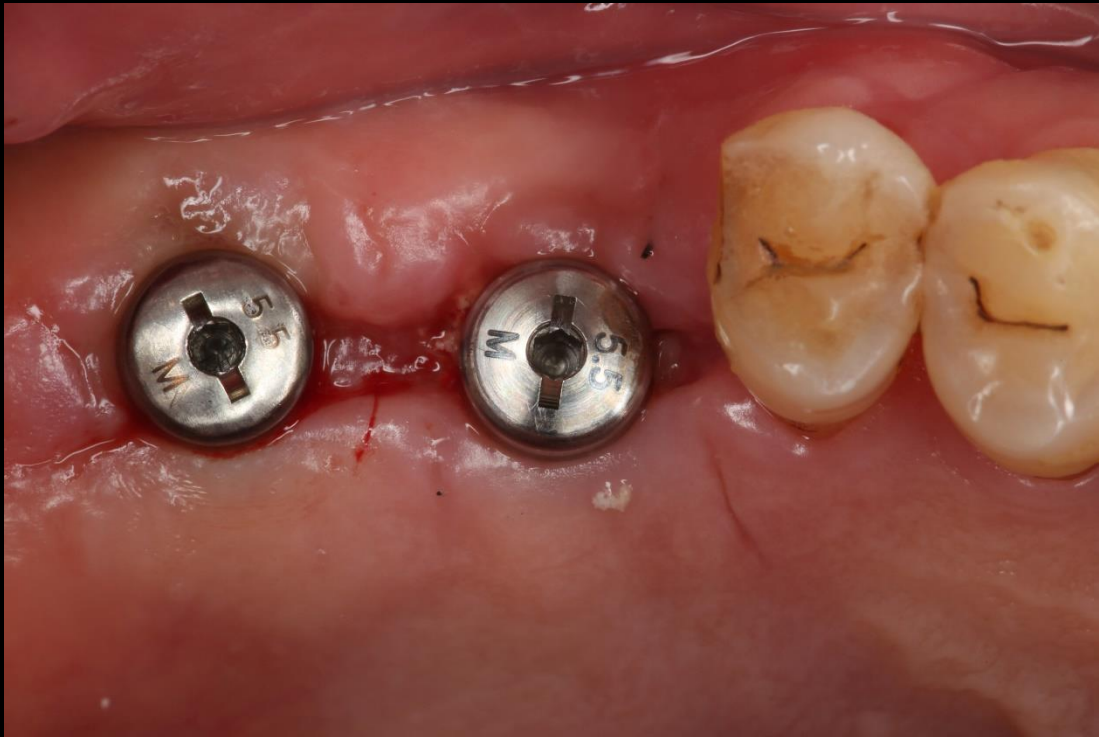## Similar case presentation (2)

- Sinus elevation & Removal of Mucocele

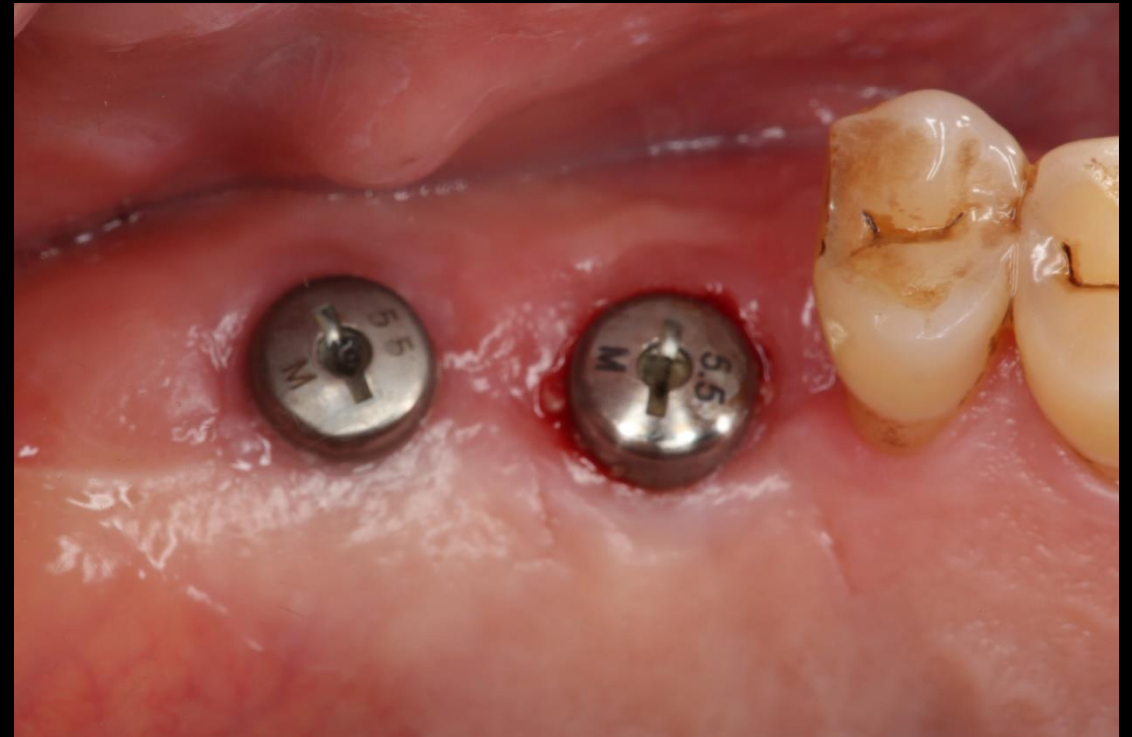

## Similar case presentation (2)

- Sinus elevation & Removal of Mucocele



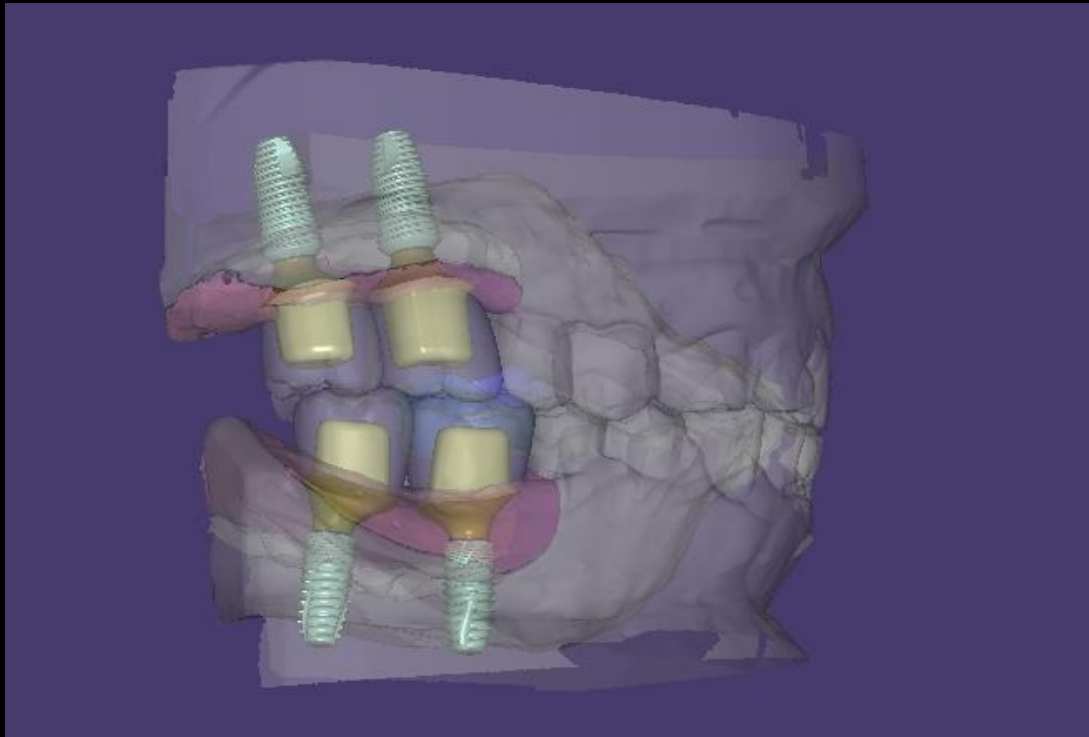
Healing : 2 weeks  
(2016-10-05)



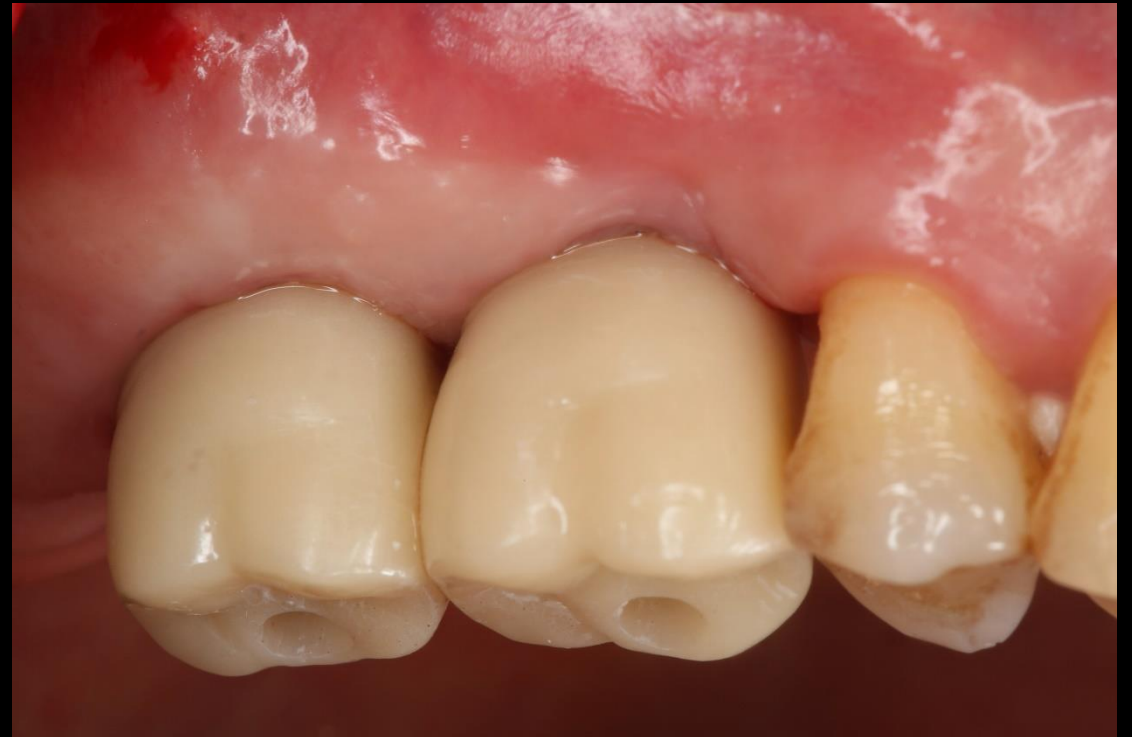Healing : 2 months 2 weeks  
(2016-12-07)

## Similar case presentation (2)

- Sinus elevation & Removal of Mucocele



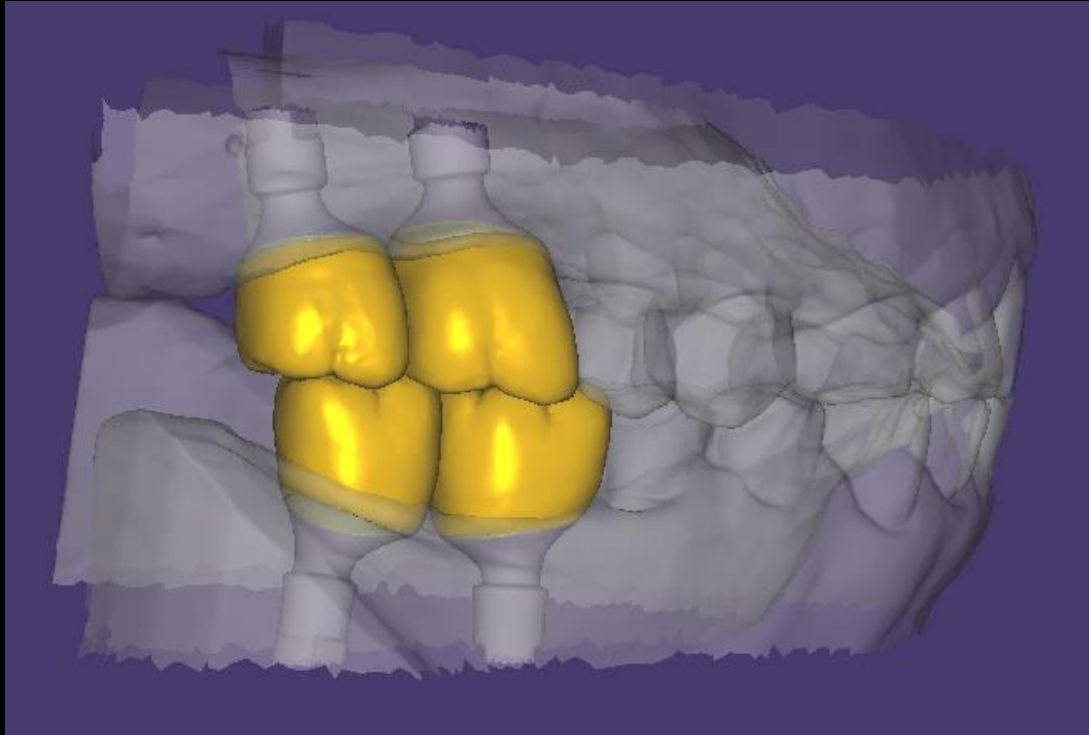
CAD (Provisional restoration)



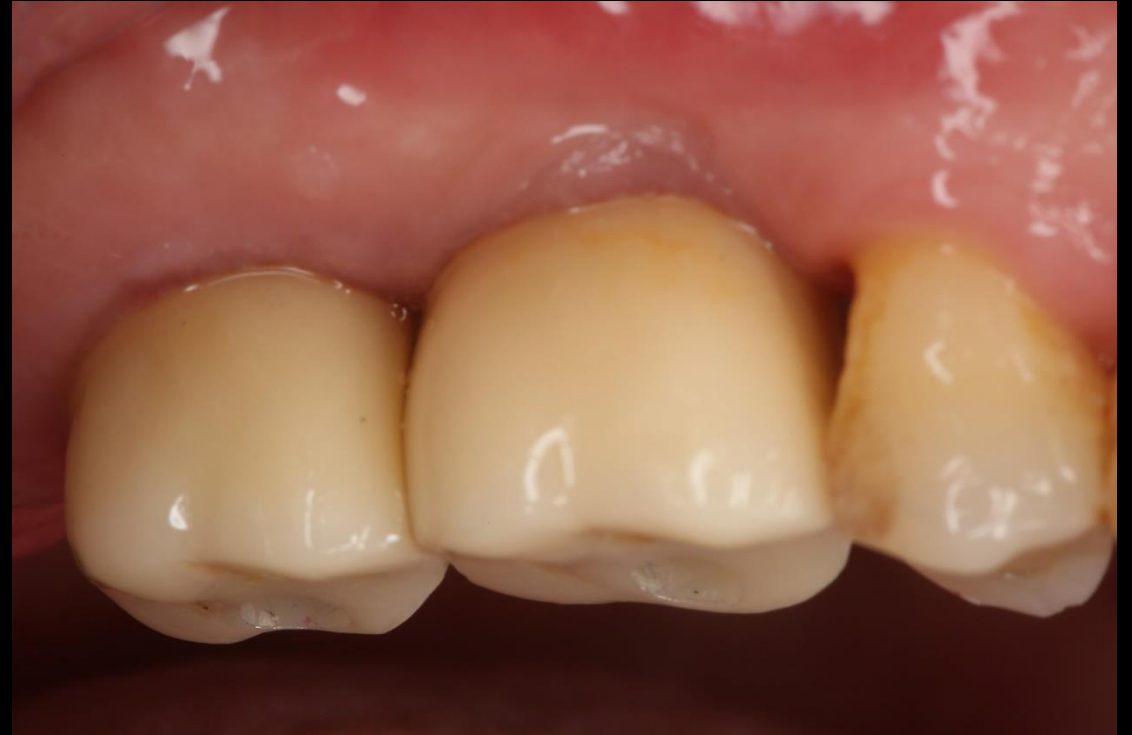Provisional restoration  
(2016-12-26)

## Similar case presentation (2)

- Sinus elevation & Removal of Mucocele



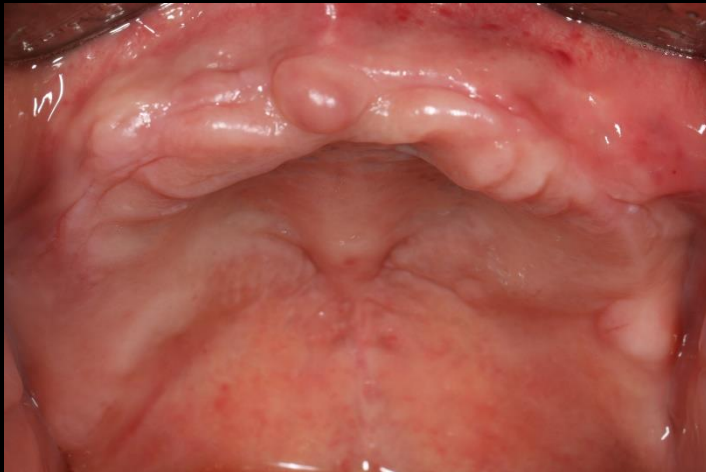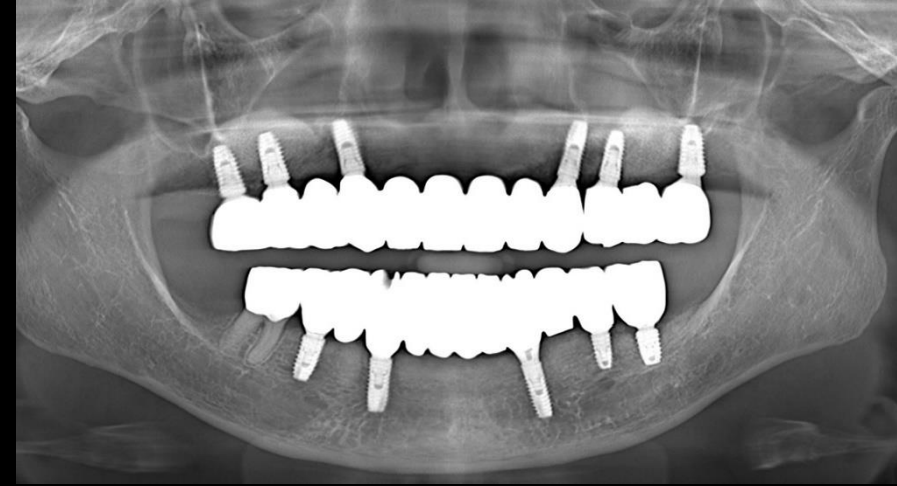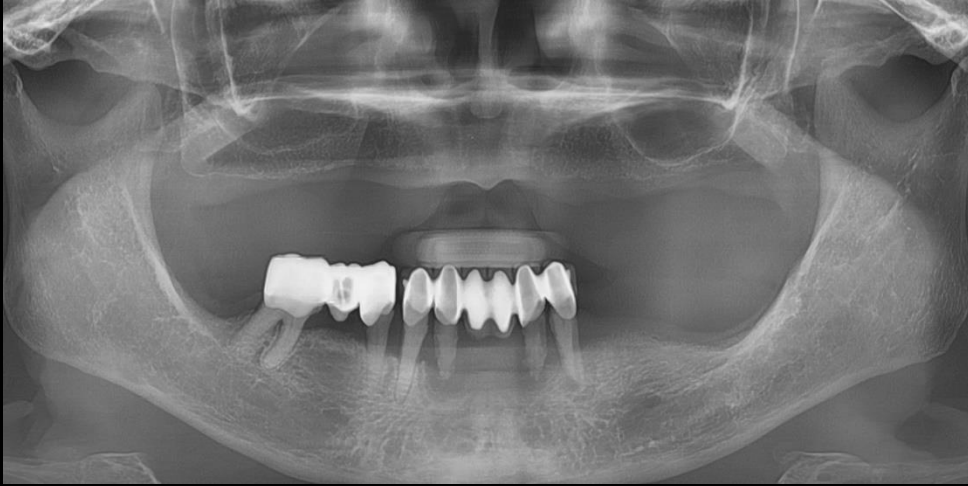
CAD (Final prosthesis)



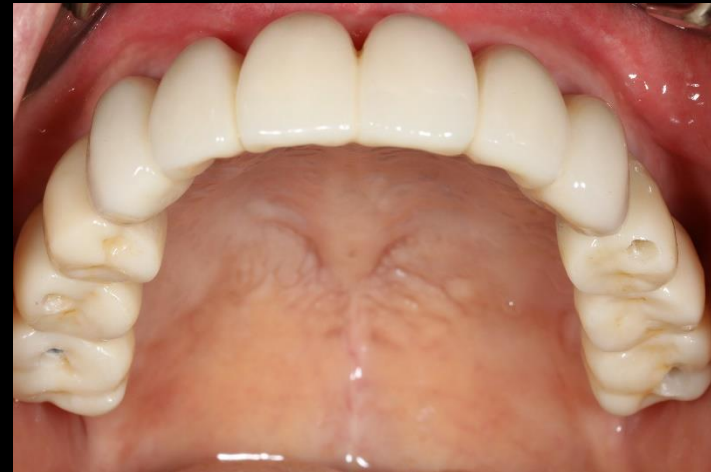Final prosthesis  
(2017-03-04)

## Similar case presentation (3)

- Sinus elevation using OSTEON™ 3 Collagen & Implantation on Full mouth case



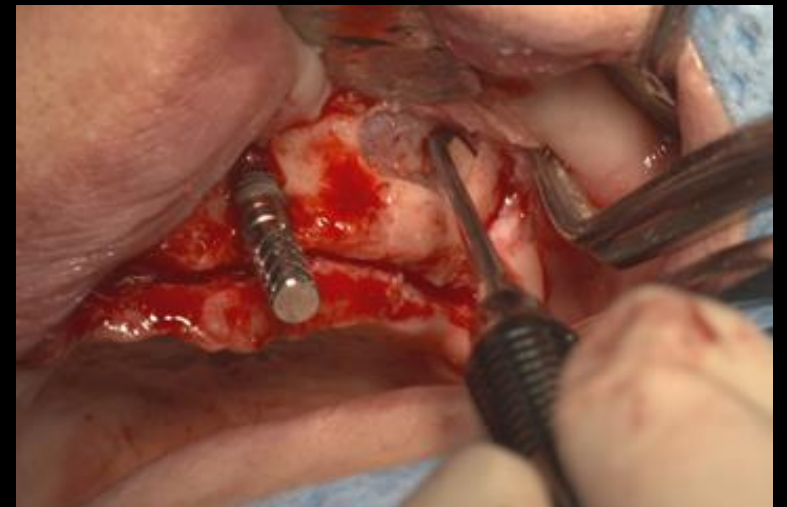
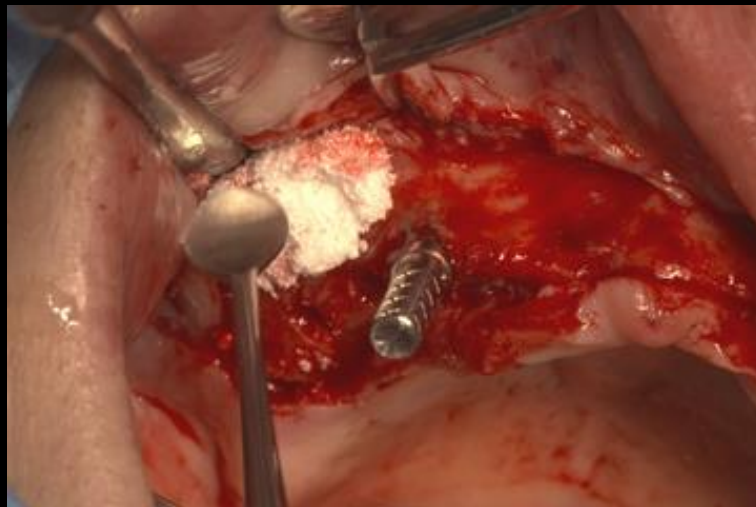
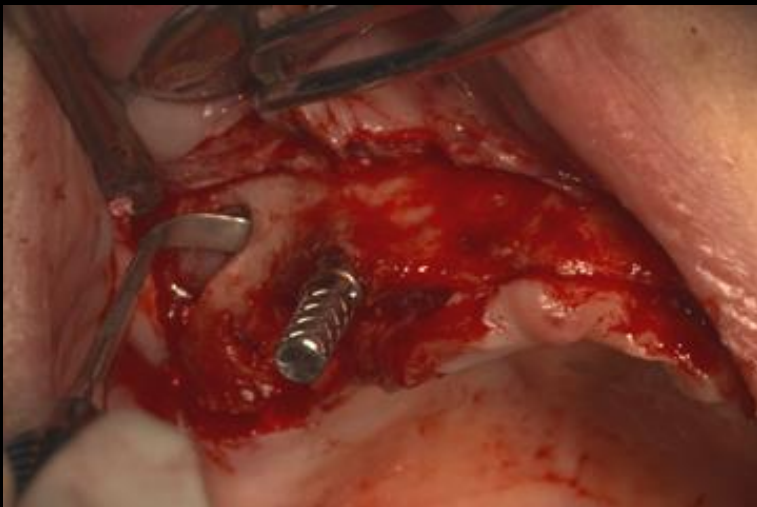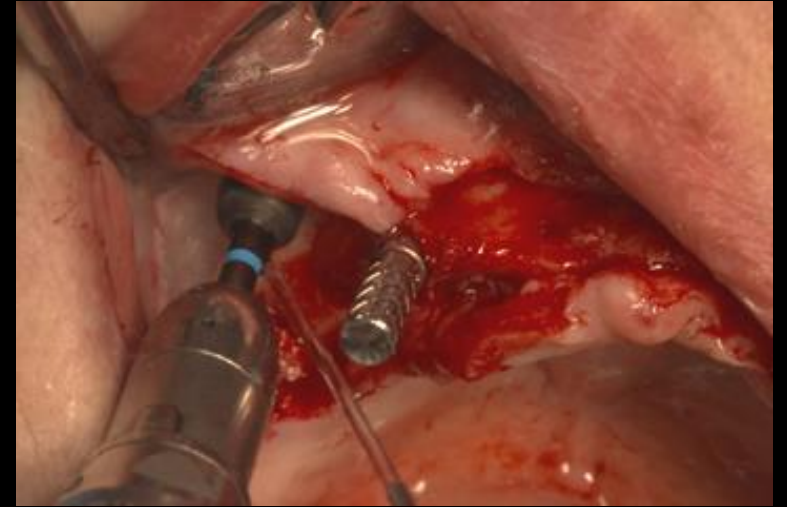
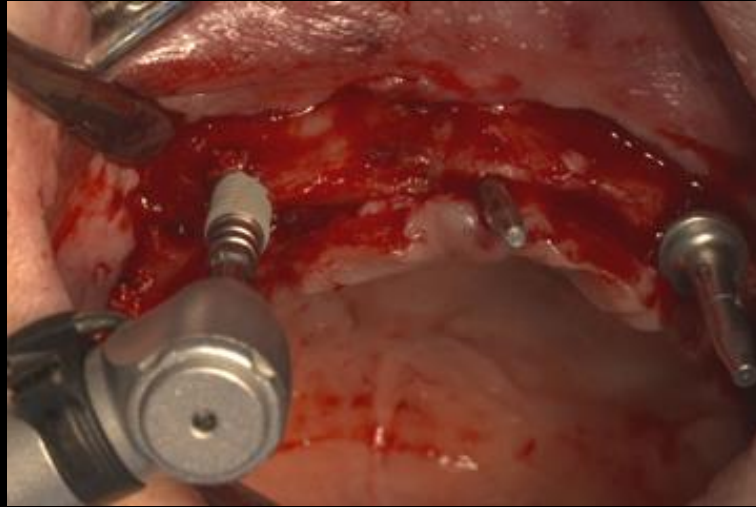
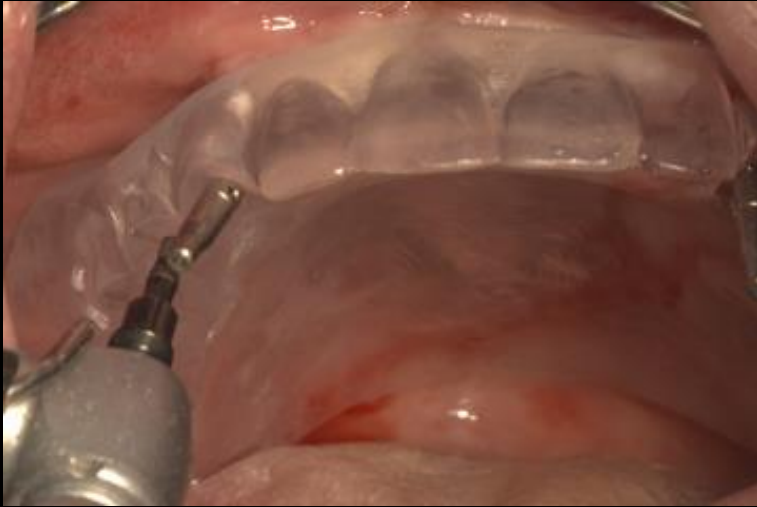
Pre-op (2017-02-10)



Final prosthesis (2018-07-20)

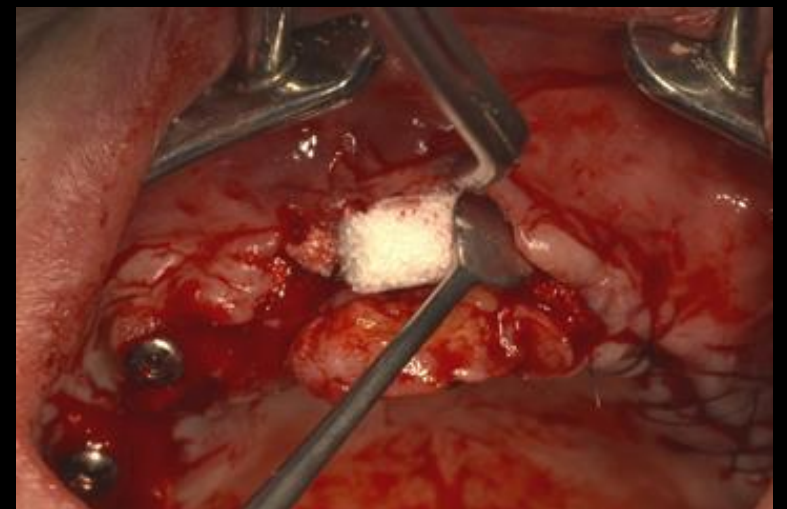
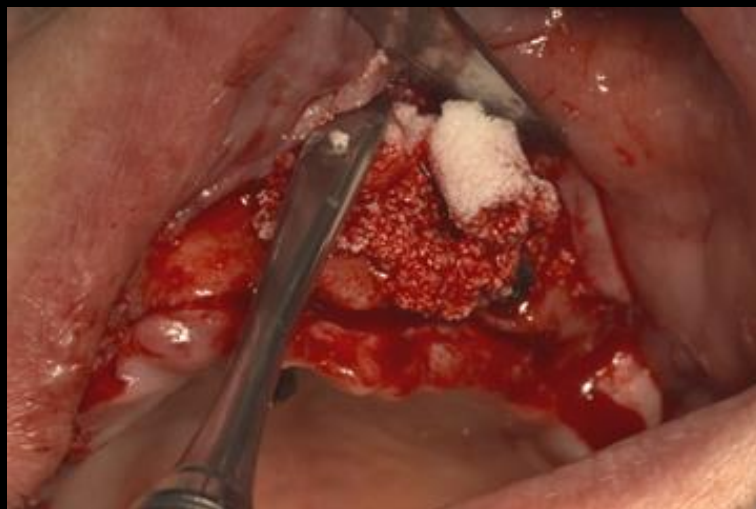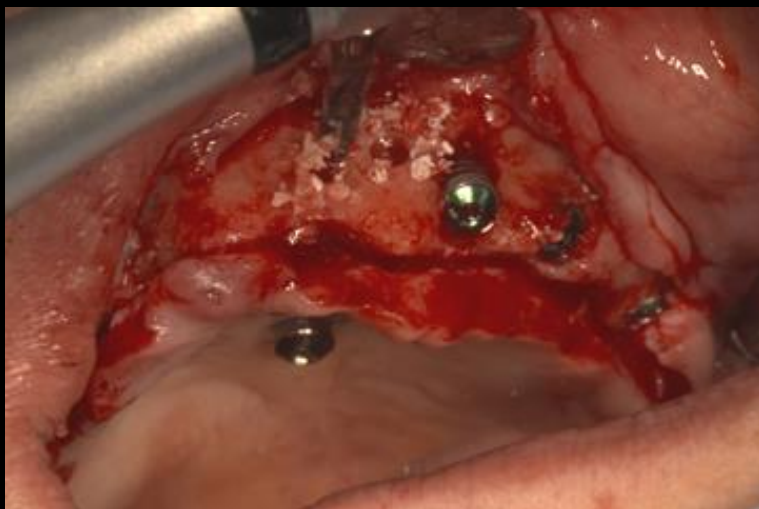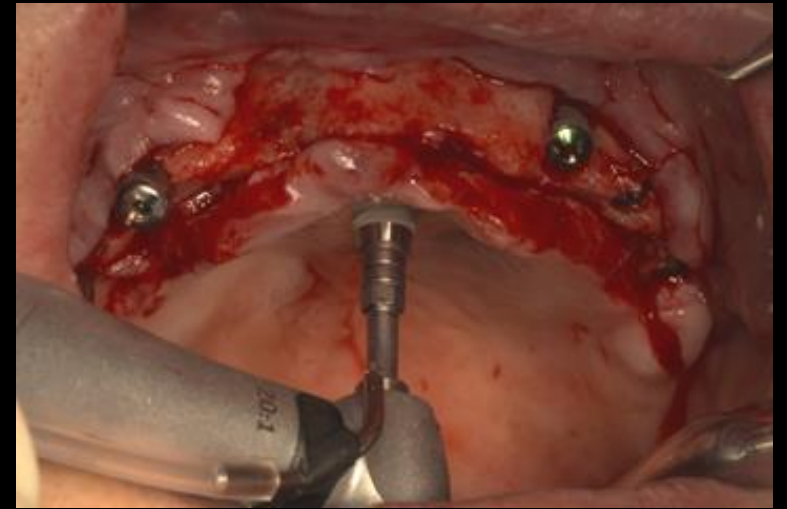
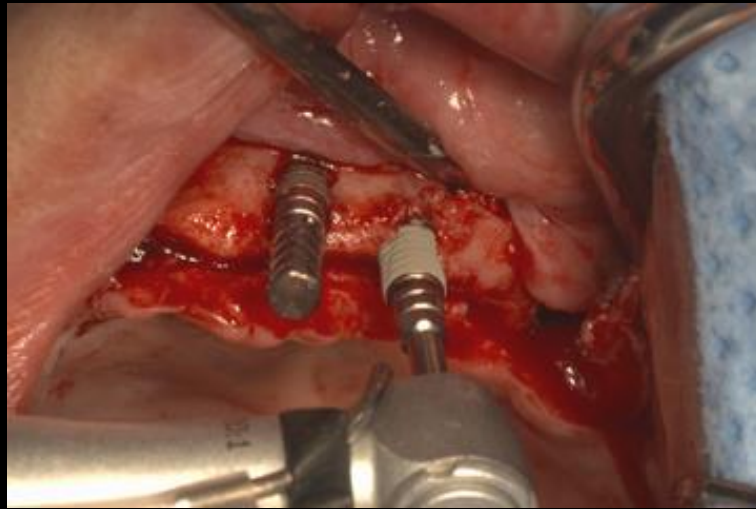
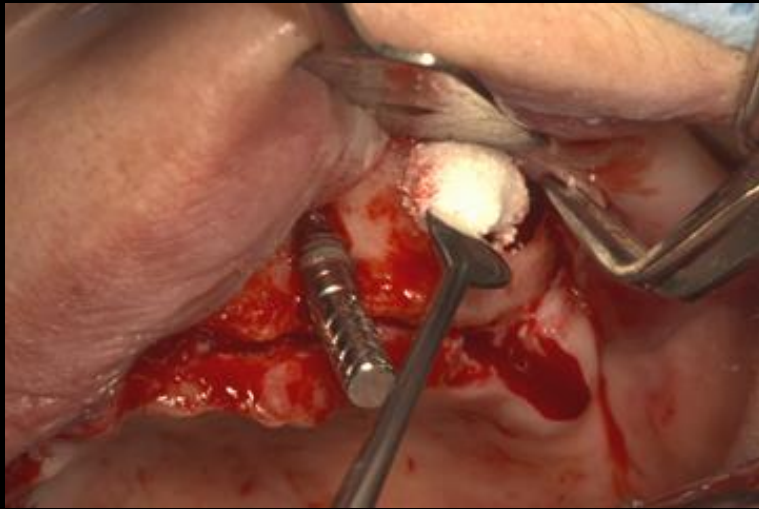
## Similar case presentation (3)

- Sinus elevation using OSTEON™ 3 Collagen & Implantation on Full mouth case



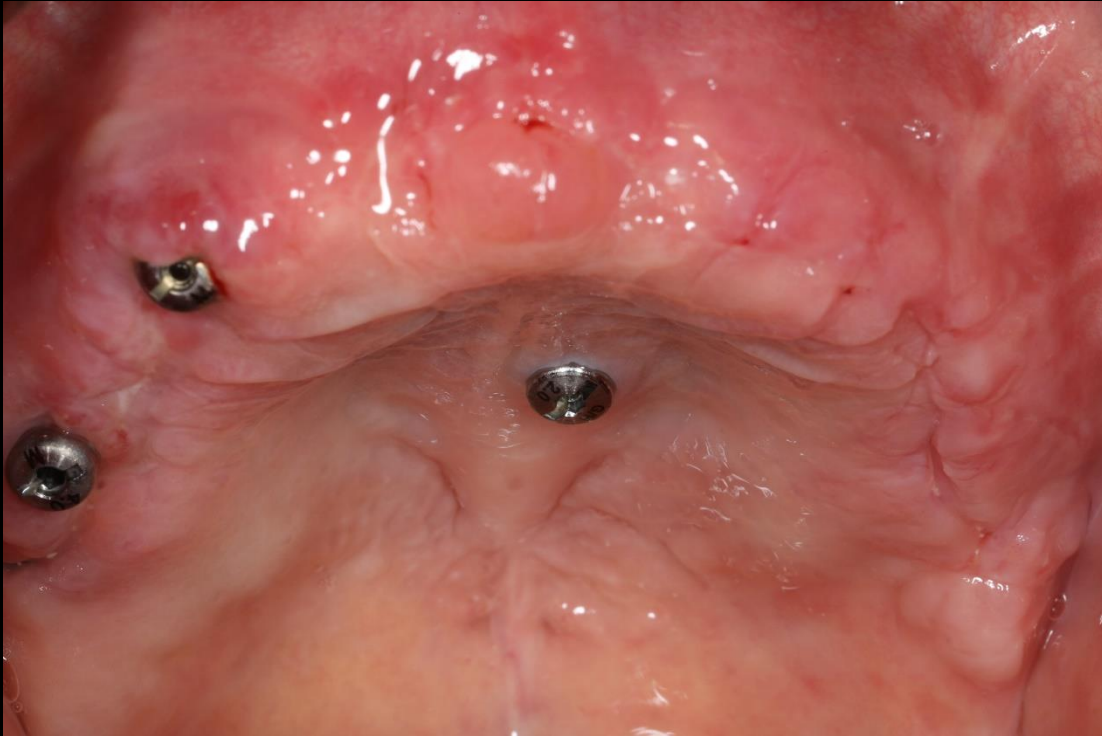
## Similar case presentation (3)

- Sinus elevation using OSTEON™ 3 Collagen & Implantation on Full mouth case

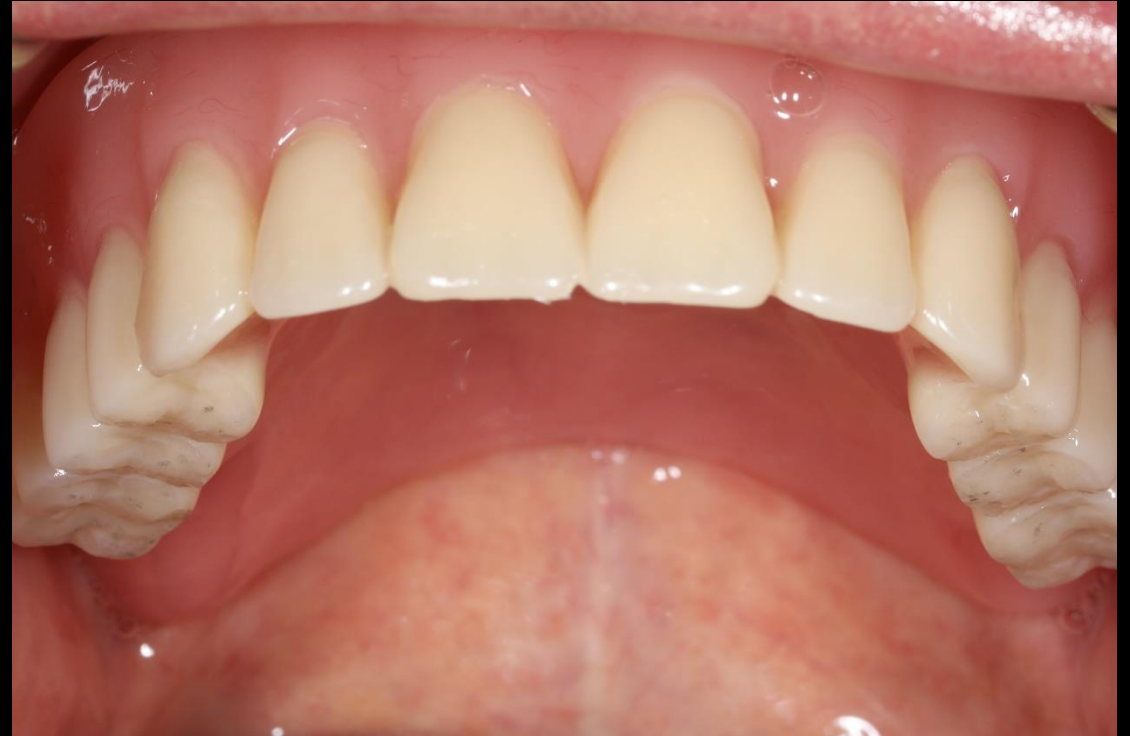

## Similar case presentation (3)

- Sinus elevation using OSTEON™ 3 Collagen & Implantation on Full mouth case



Healing : 3 weeks  
(2017-03-09)

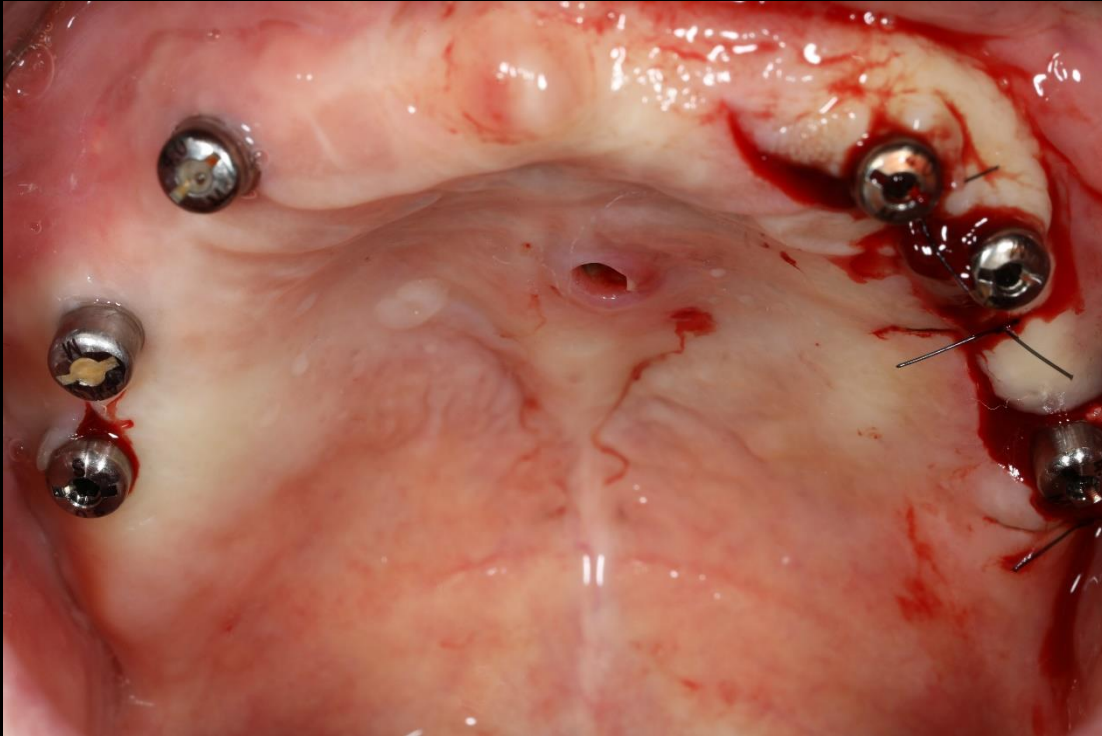


Temporary Denture  
(2017-04-12)

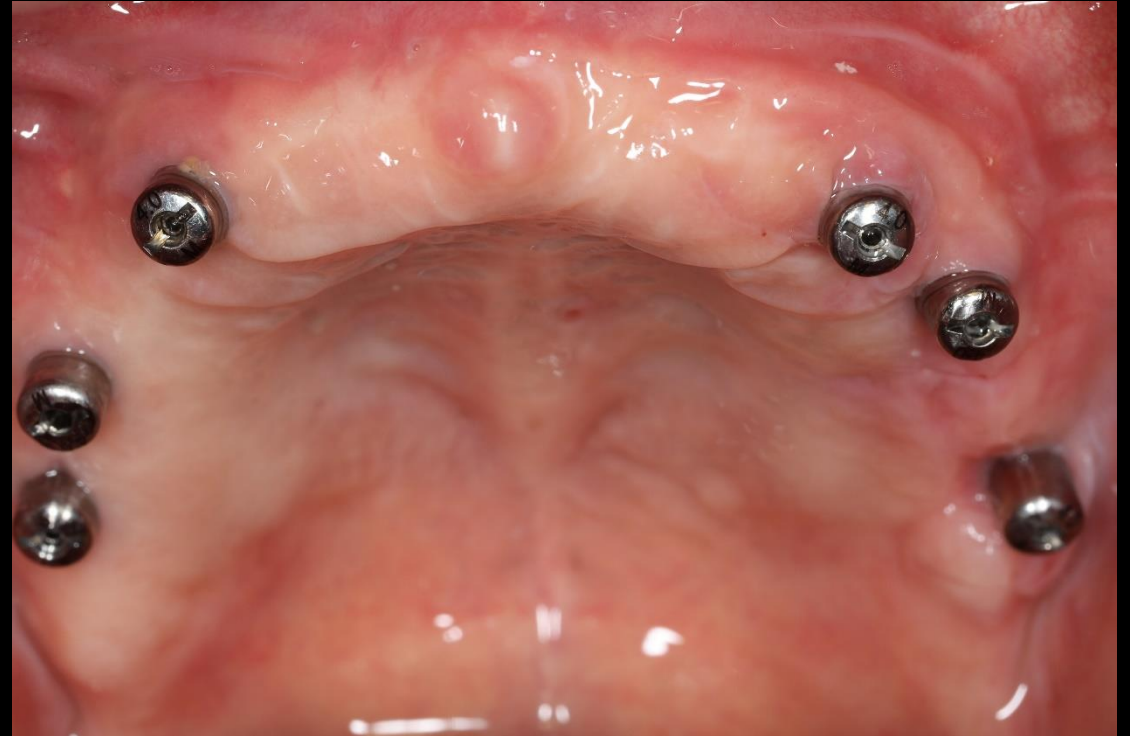


## Similar case presentation (3)

- Sinus elevation using OSTEON™ 3 Collagen & Implantation on Full mouth case



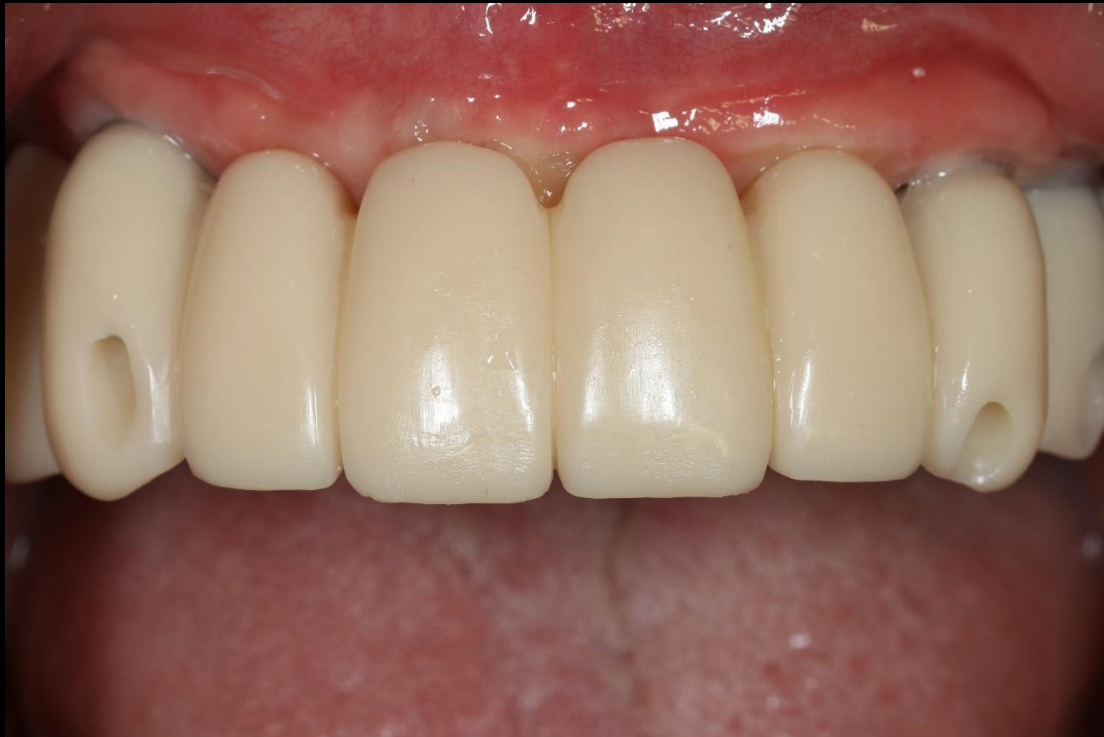Second stage surgery  
/ Removal of Maxilla implant  
(2017-12-07)



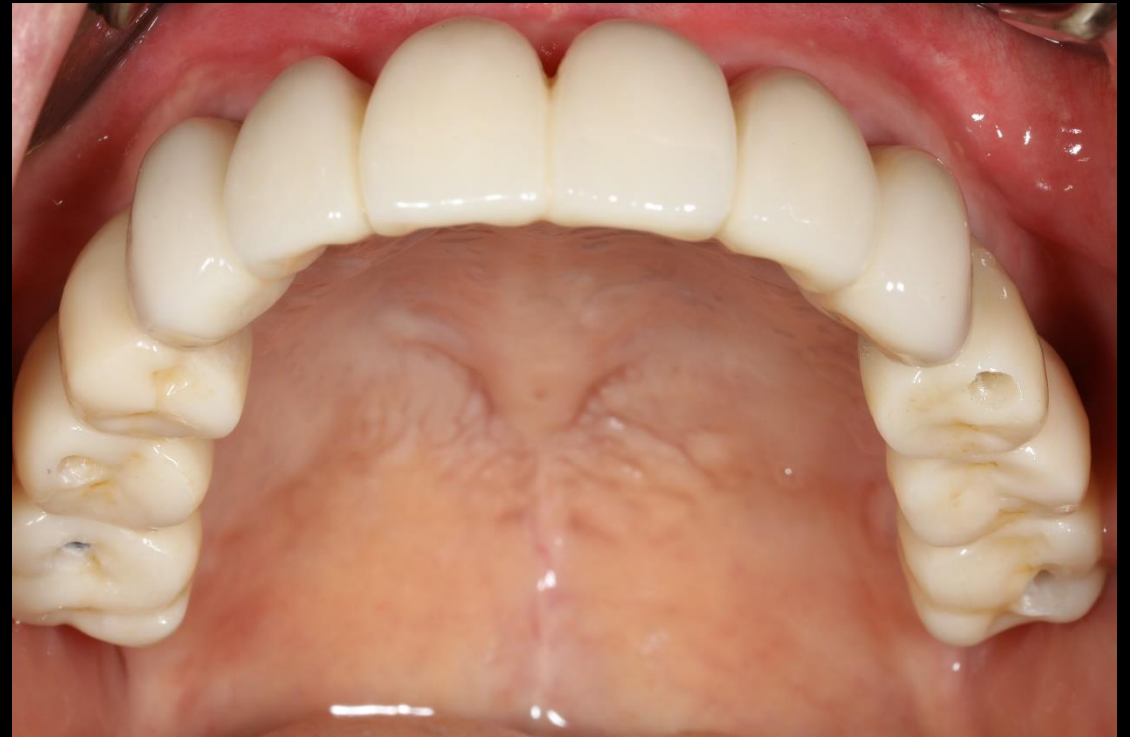Healing : 2 weeks (After S.S.S.)  
(2017-12-21)

## Similar case presentation (3)

- Sinus elevation using OSTEON™ 3 Collagen & Implantation on Full mouth case



Provisional restoration  
(2018-01-26)



Final prosthesis  
(2018-07-20)