



LIVE

Surgery

Prof. Jung-Chul Park

2020.11.20 (Fri.)



[Case Preview]

Multiple implant placement with crestal approach
utilizing autogenous bone chips

Patient Information

Age : 77

Sex : Male

Chief Complaint

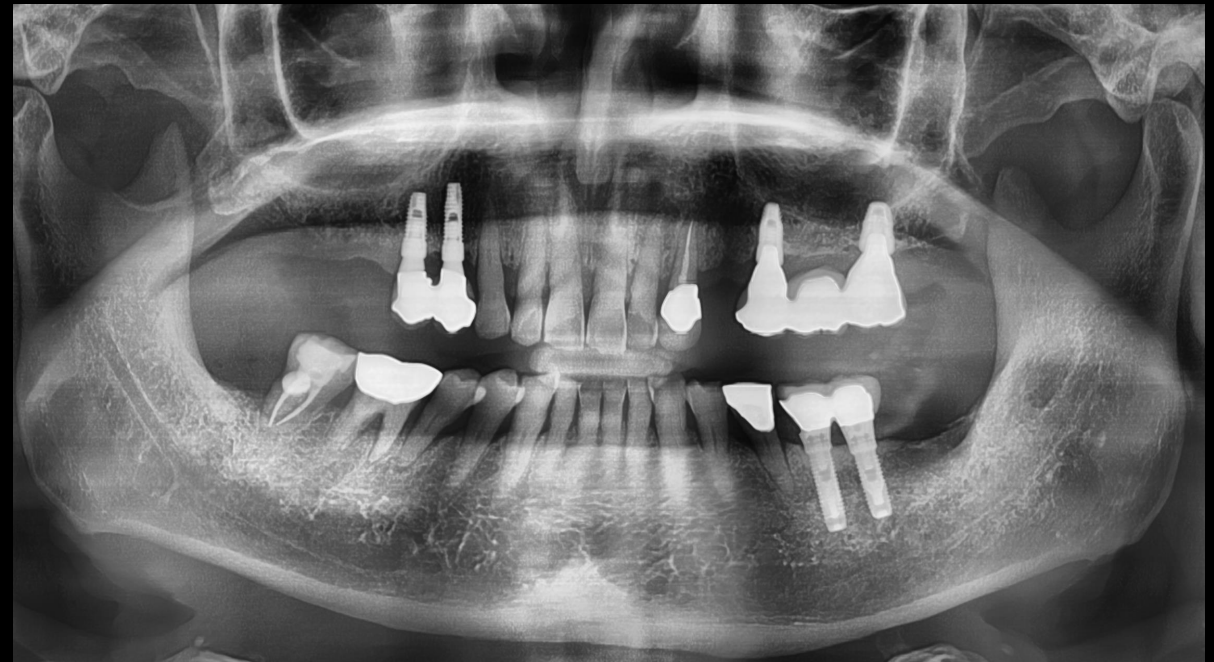
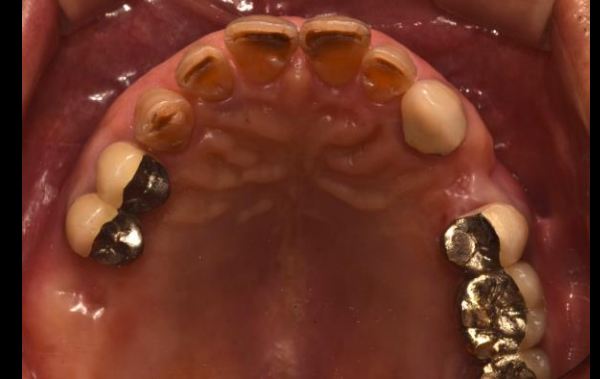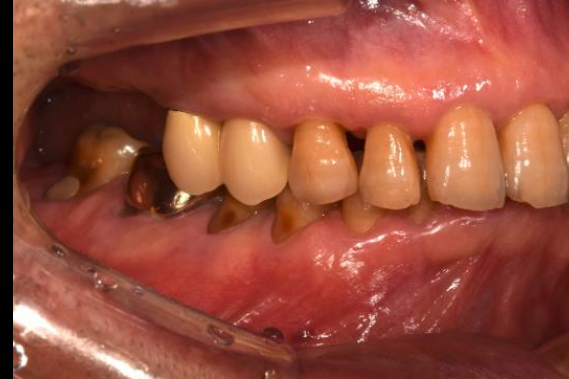: I want to recover my missing teeth
on #16, 17, 24

Past Medical History

: HTN, DM (Controlled)

Past Dental History

: Extraction #16, 17



Patient Information

Surgery Plan

- #16 Simple implant placement
- #17 Sinus Lifting utilizing autogenous bone & Dentium regeneration materials

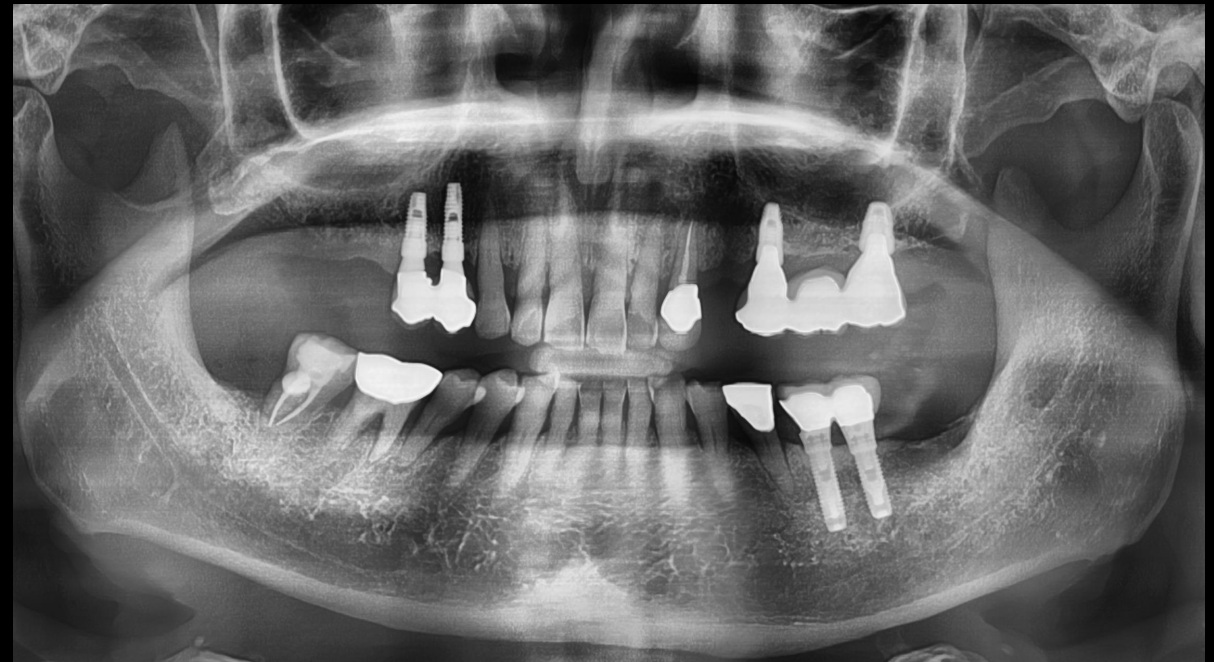
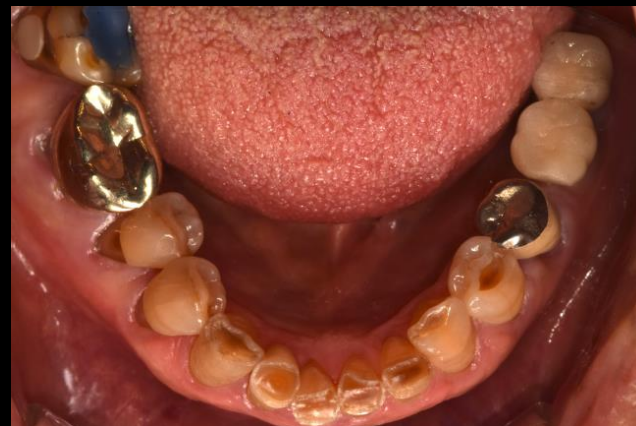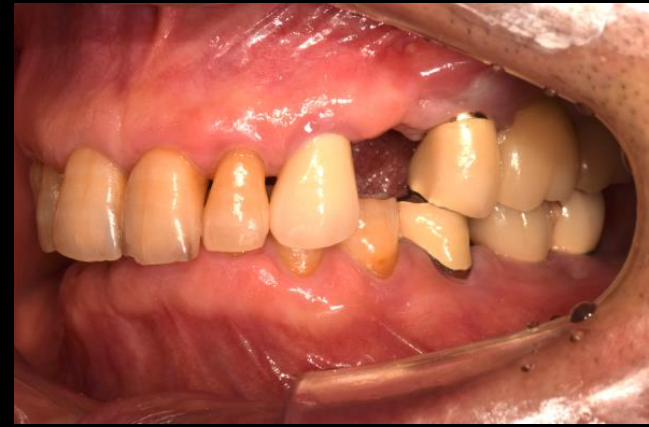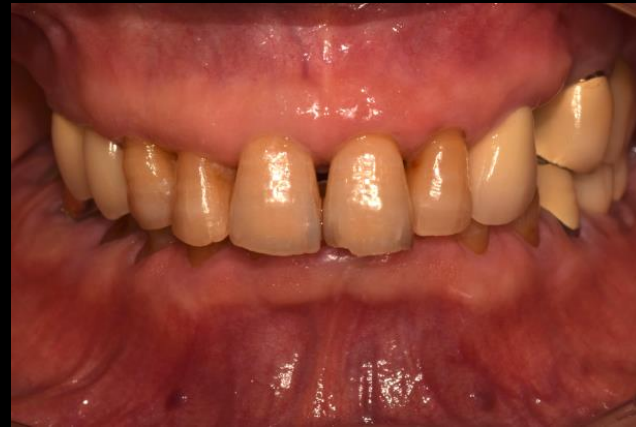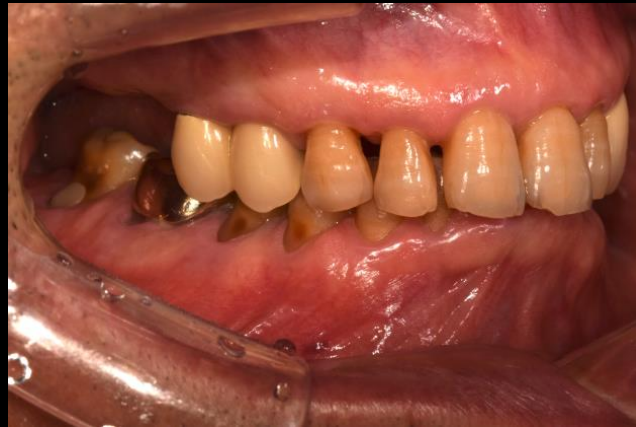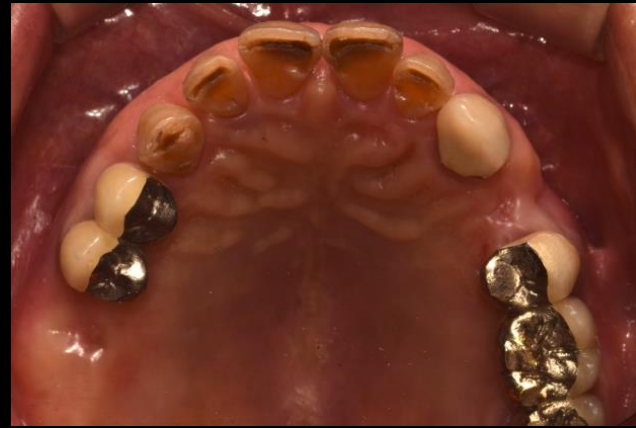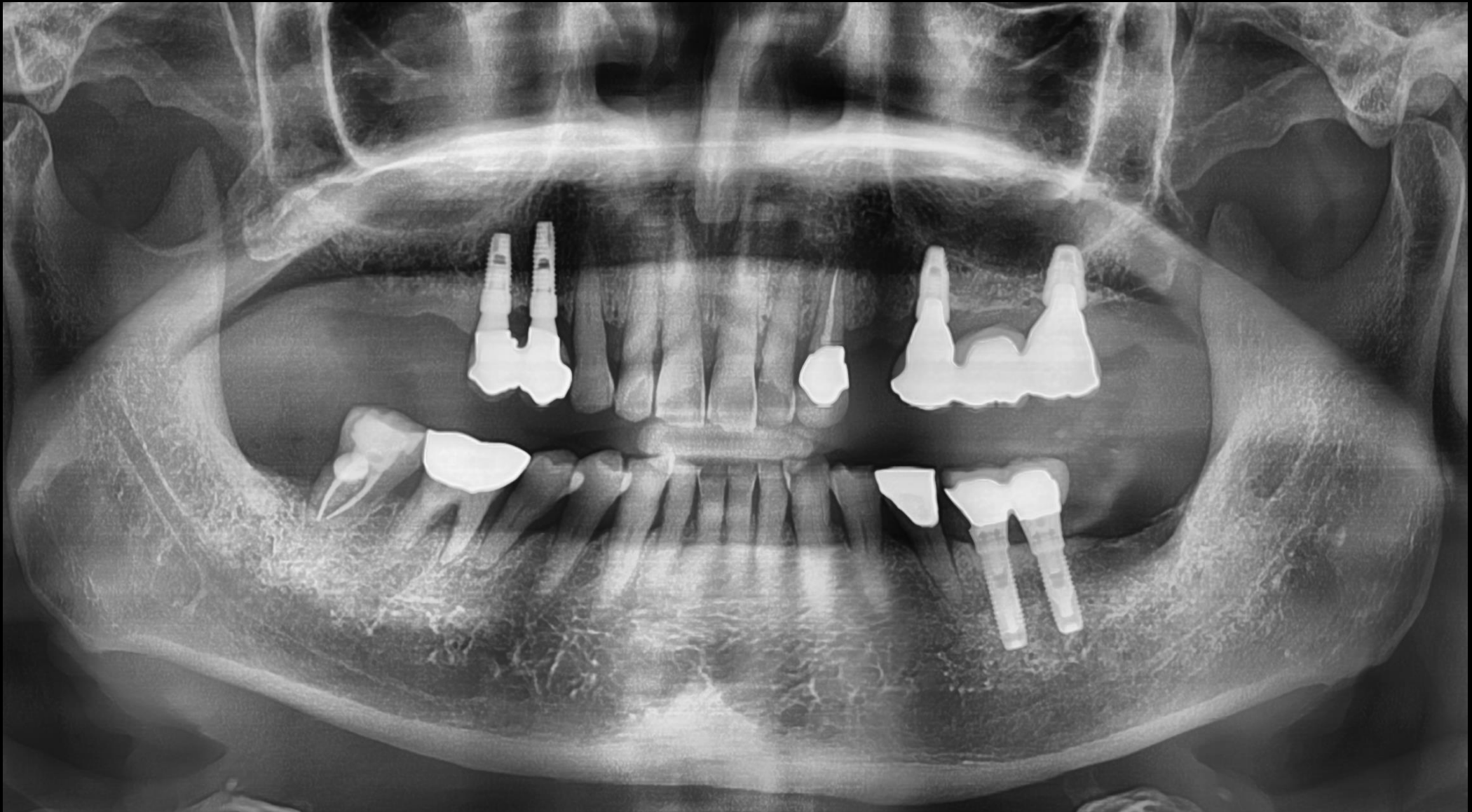


Photo (Pre-op)



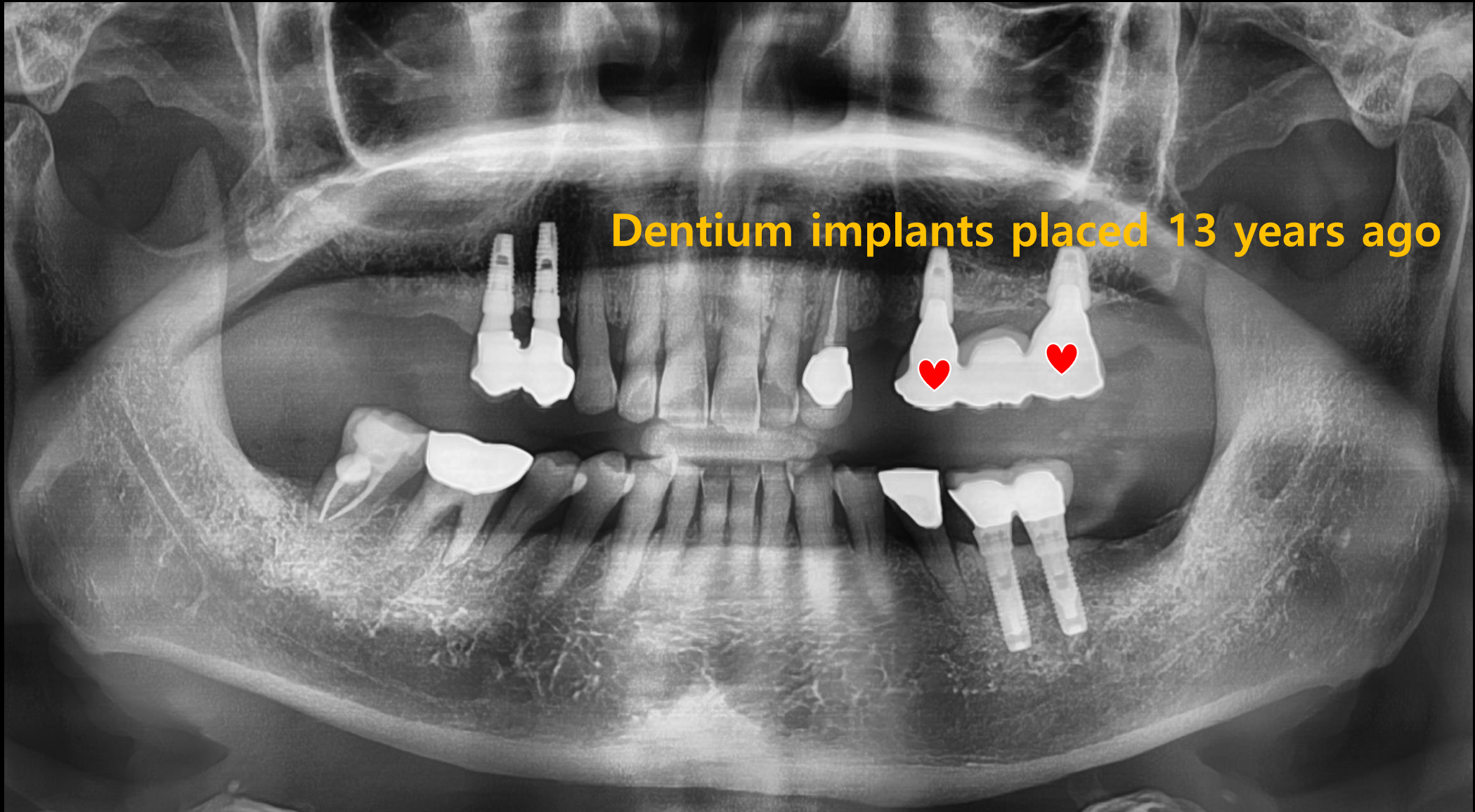
Pt. SYP (77/Male)

Pre-op (2020-10-06)



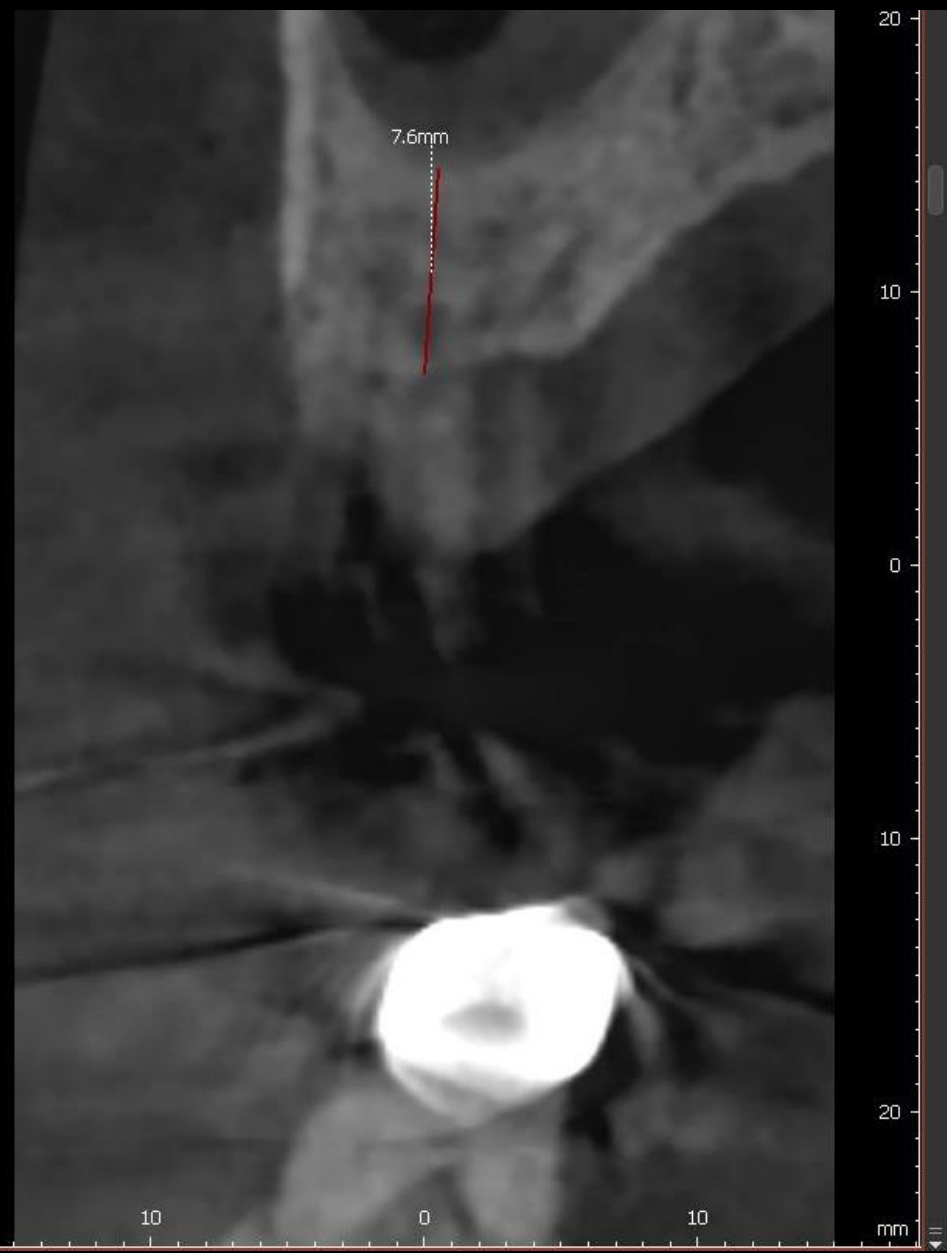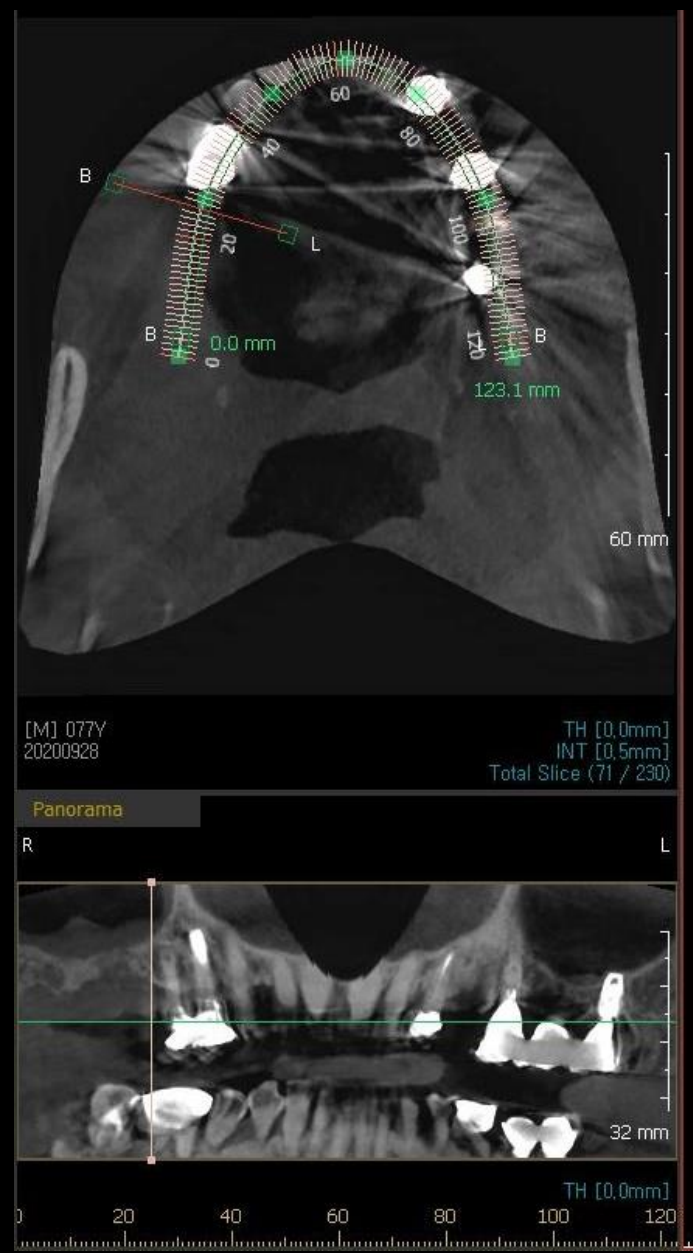
Pt. SYP (77/Male)

Pre-op (2020-10-06)



Pt. SYP (77/Male)

#16 Pre-op (2020-10-06)



Pt. SYP (77/Male)

#17 Pre-op (2020-10-06)

