



# Surgergy

Dr. Young-Keun Hyun

2021.11.19 (FRI.)



# [Case Preview]

Lower Anterior Implant placement With Minimalism  
(Flapless surgery with NTI and Pin Guide)



# Patient Information

**Age** : 54

**Sex** : Male

## Chief Complaint

: I want to fix my lower anterior missing tooth

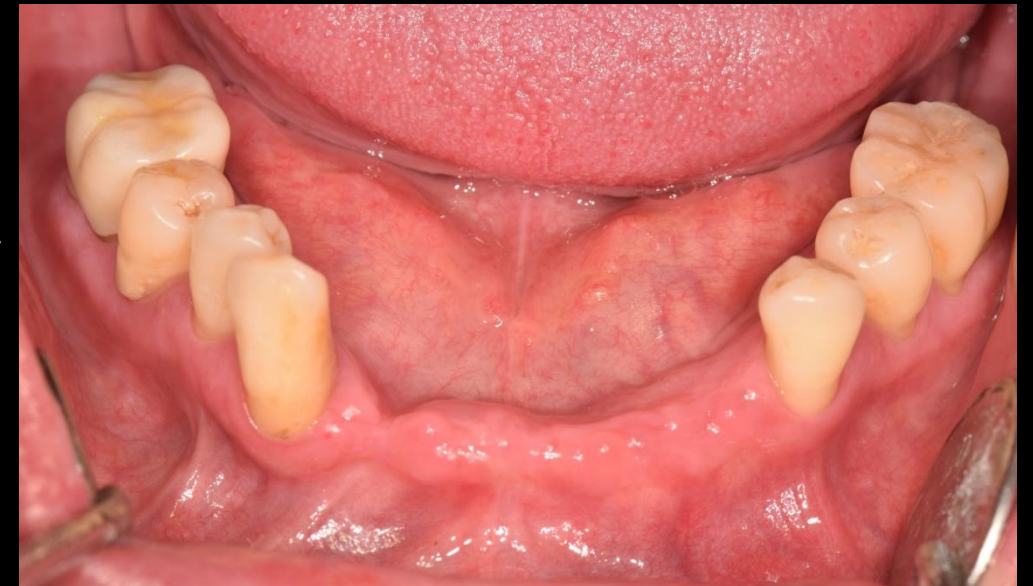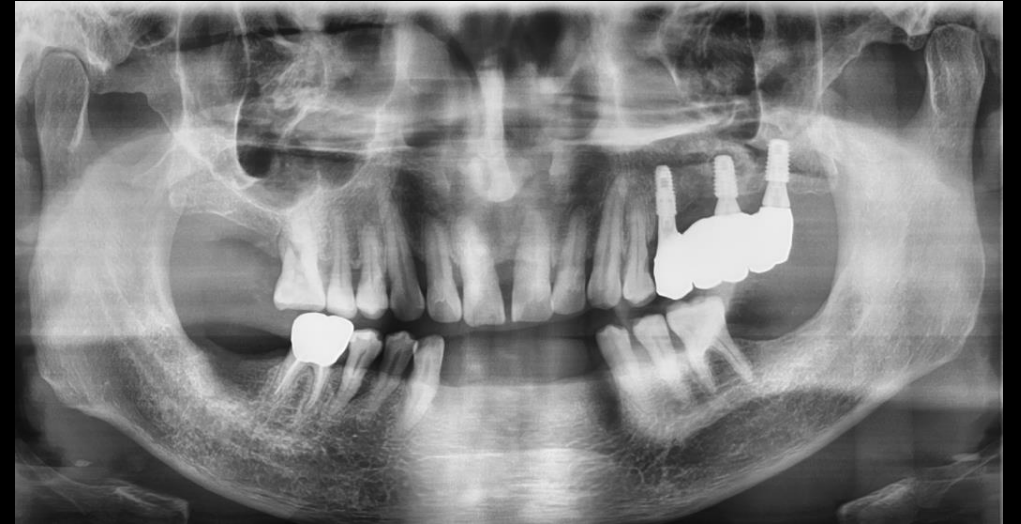I hate painful surgery

## Past Dental History

: 3 Implantation with Sinus Graft on the left posterior area

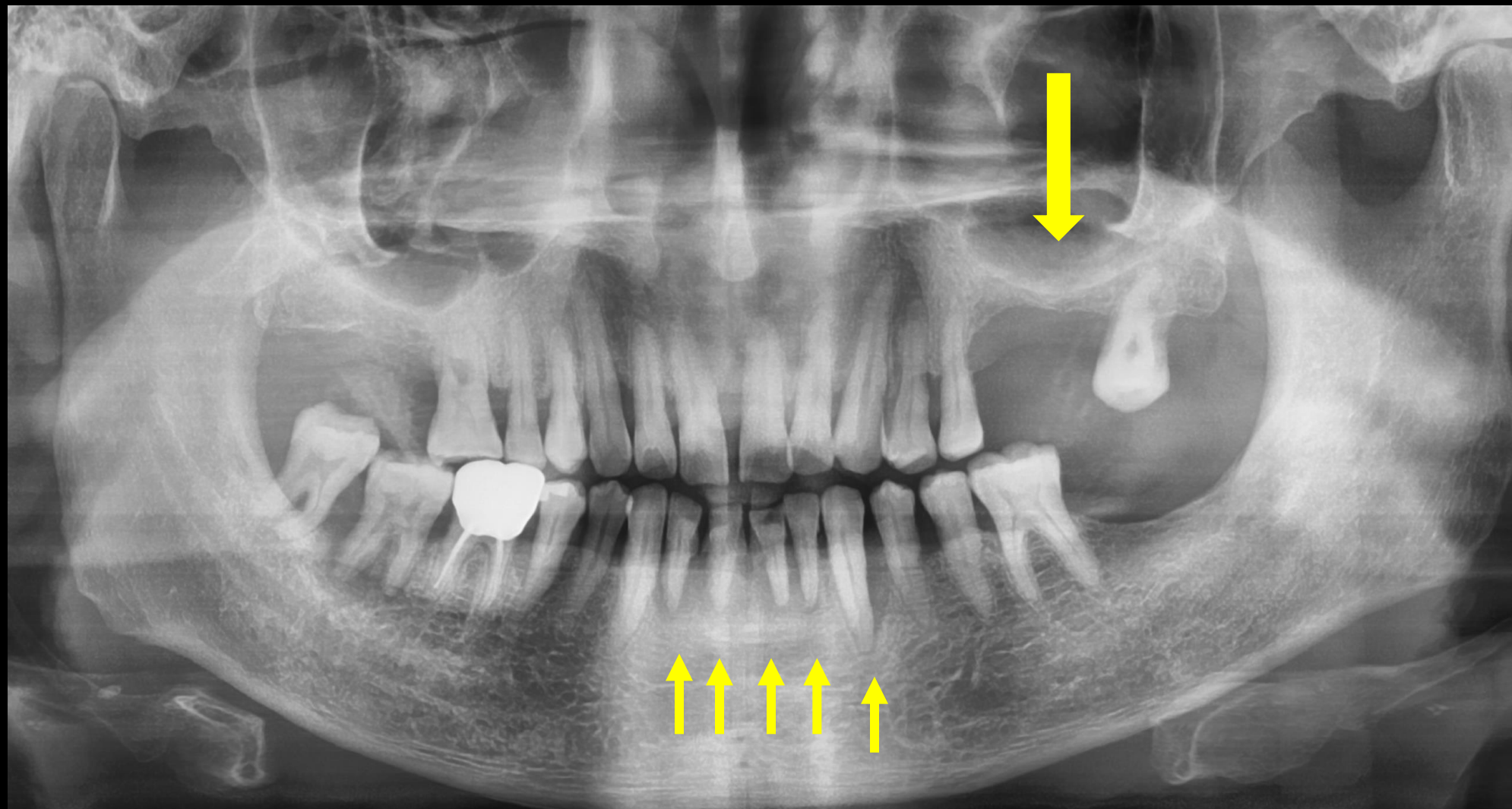
## Past Medical History

: N/S

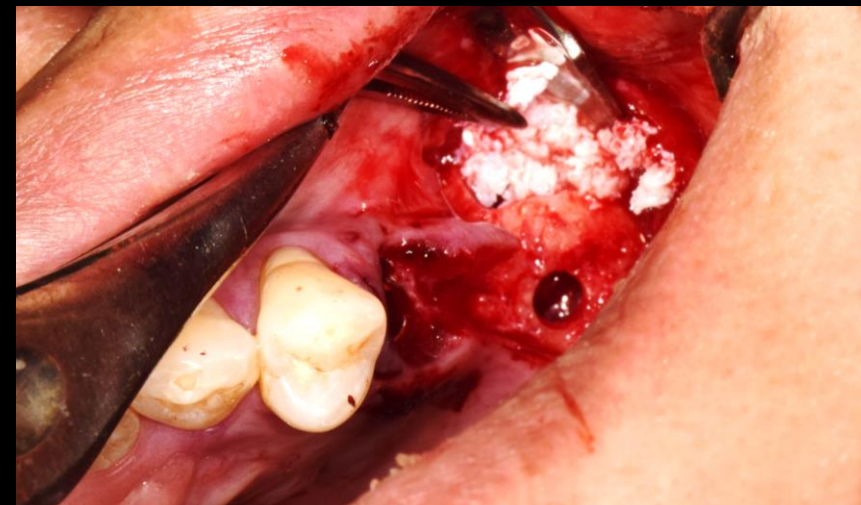
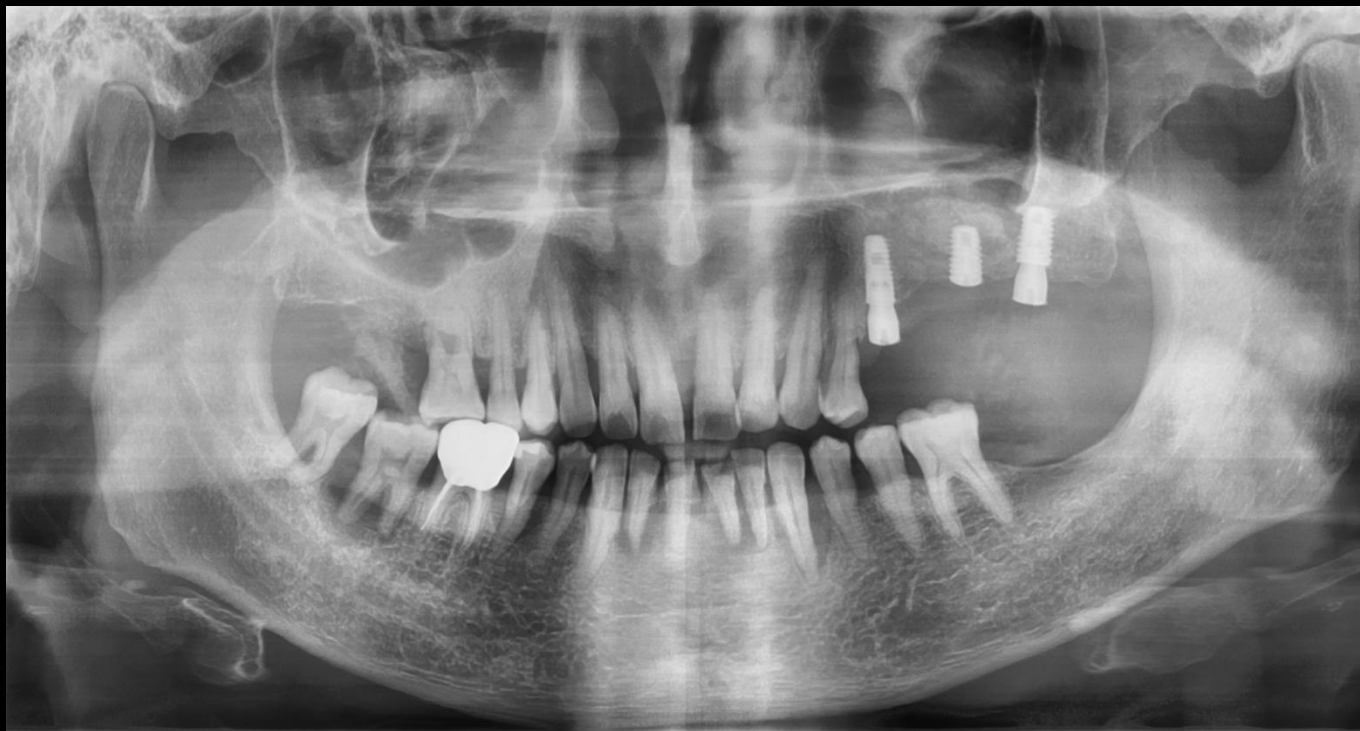
# Past dental history

Oral exam (2021-04-02)



# Past dental history

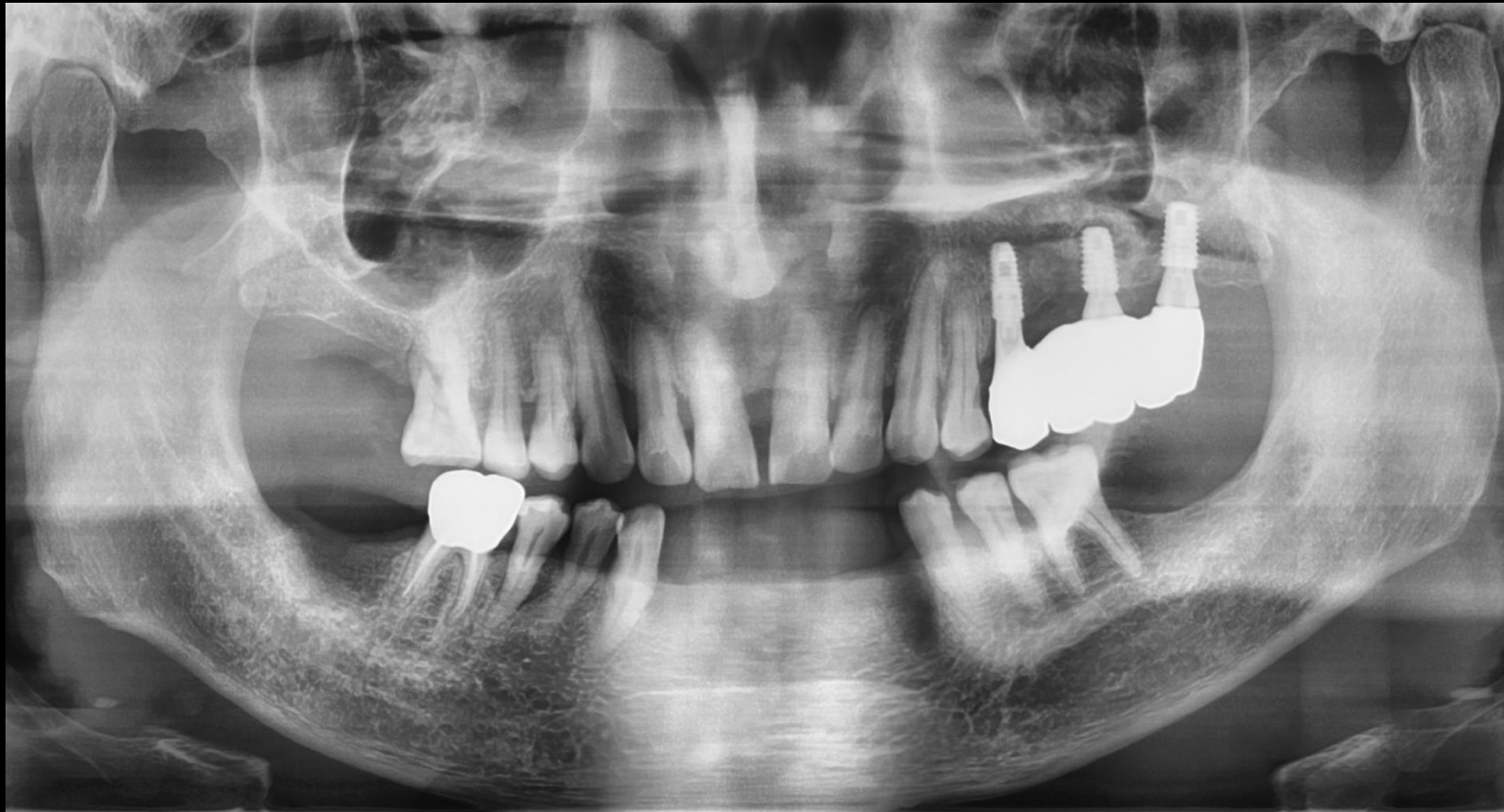


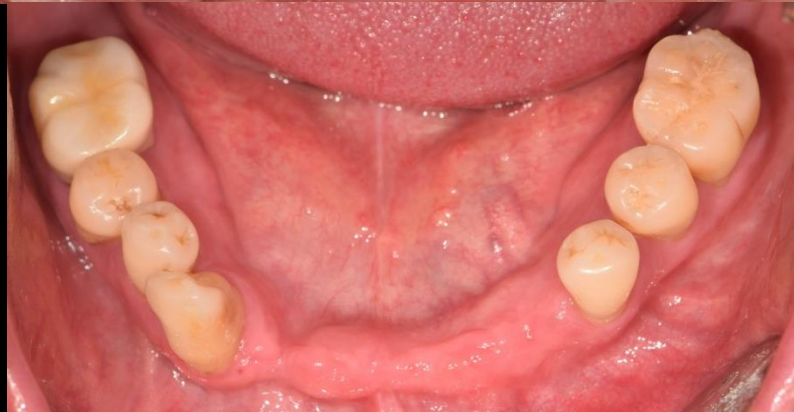
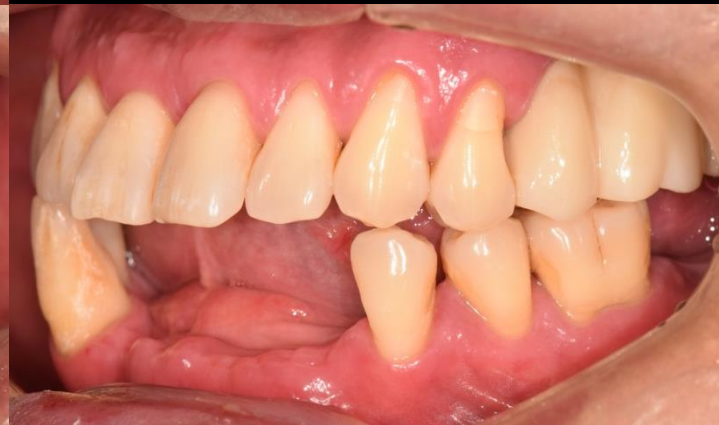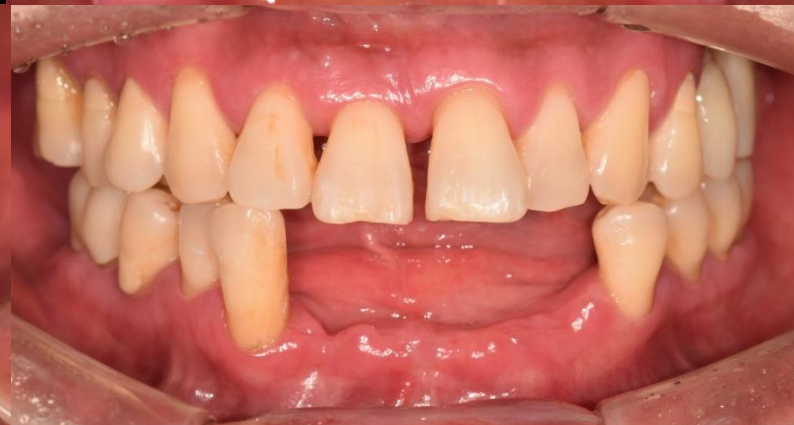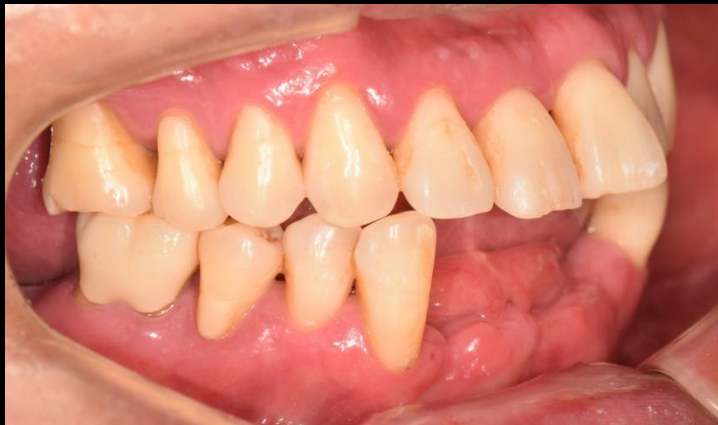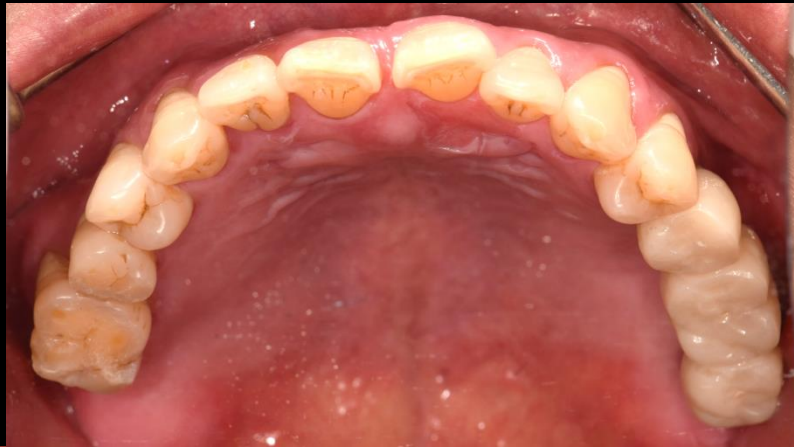## Past dental history

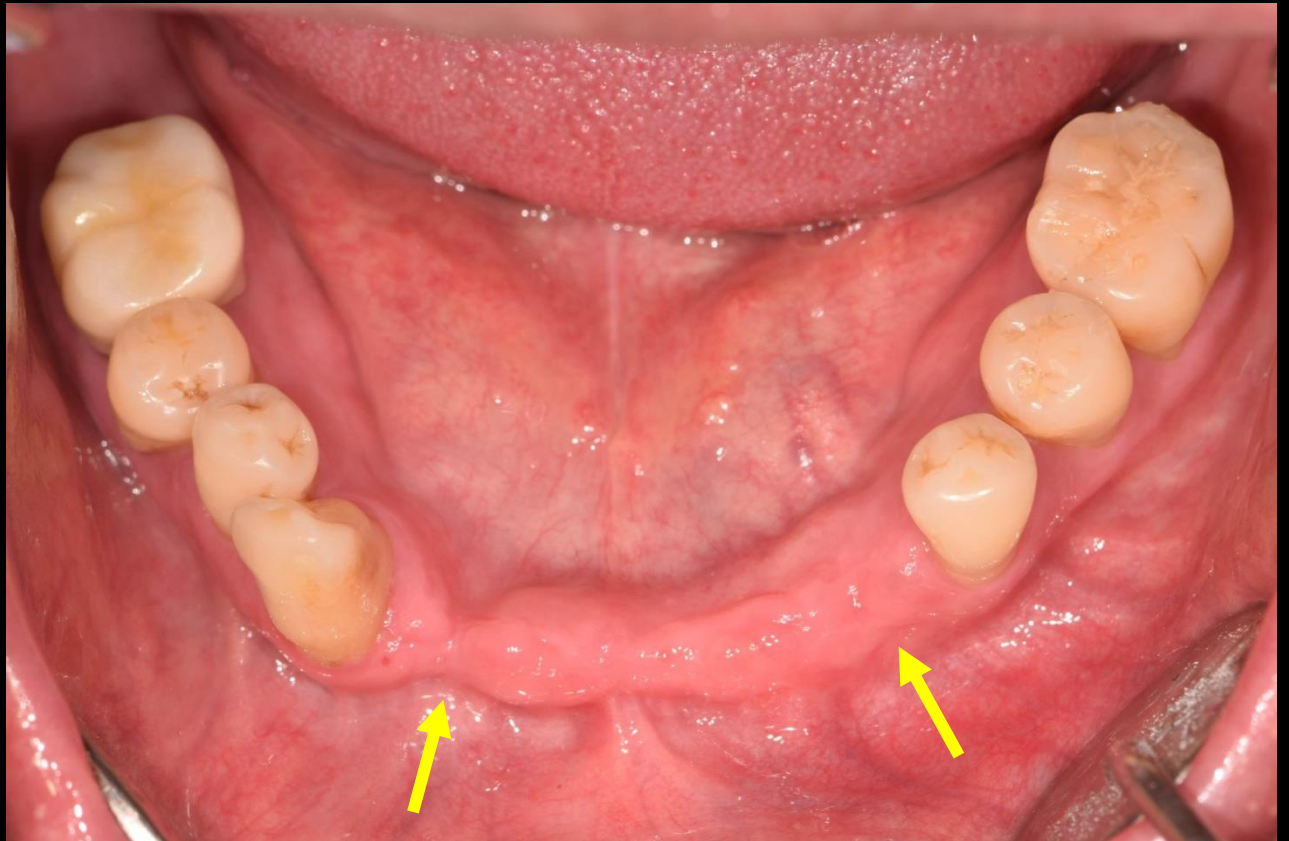
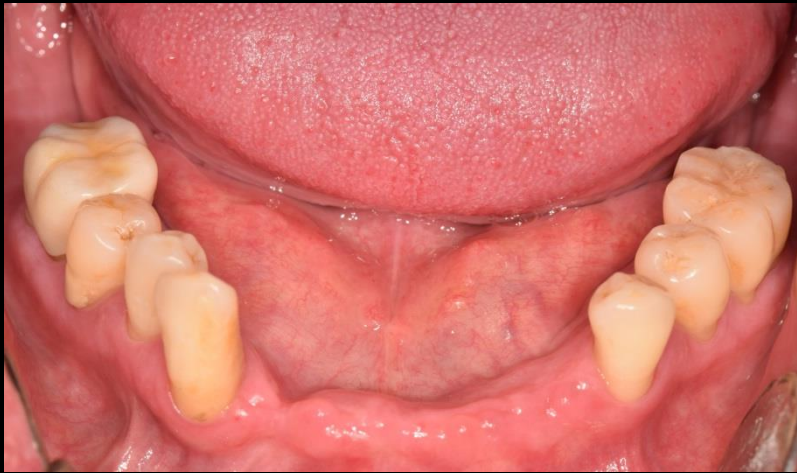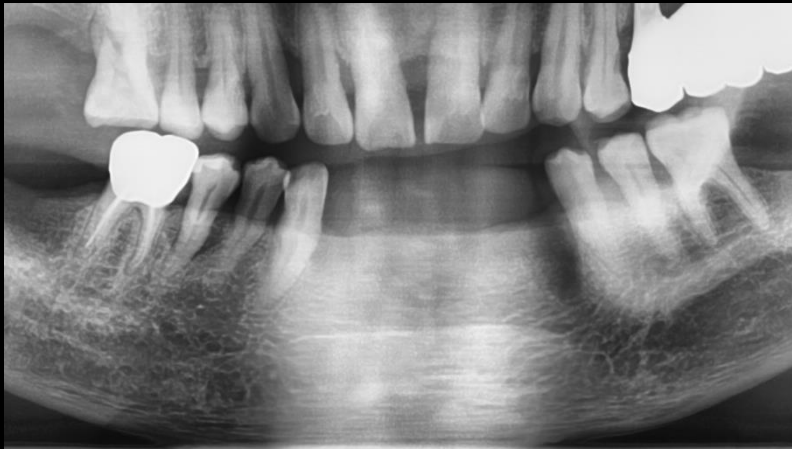- Extraction # 41, 42, 47, 31, 32, 33

(2021- 09-02)





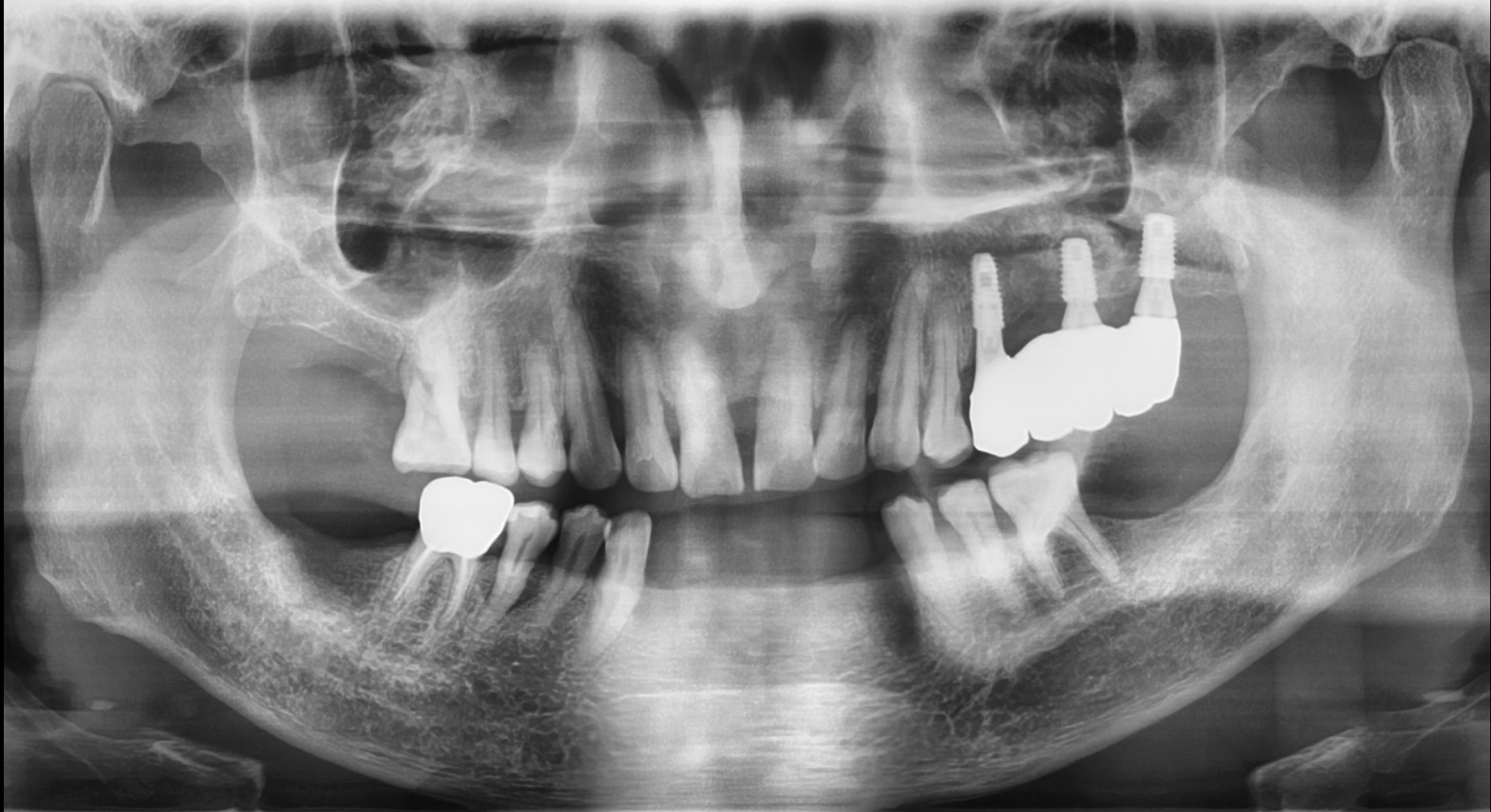



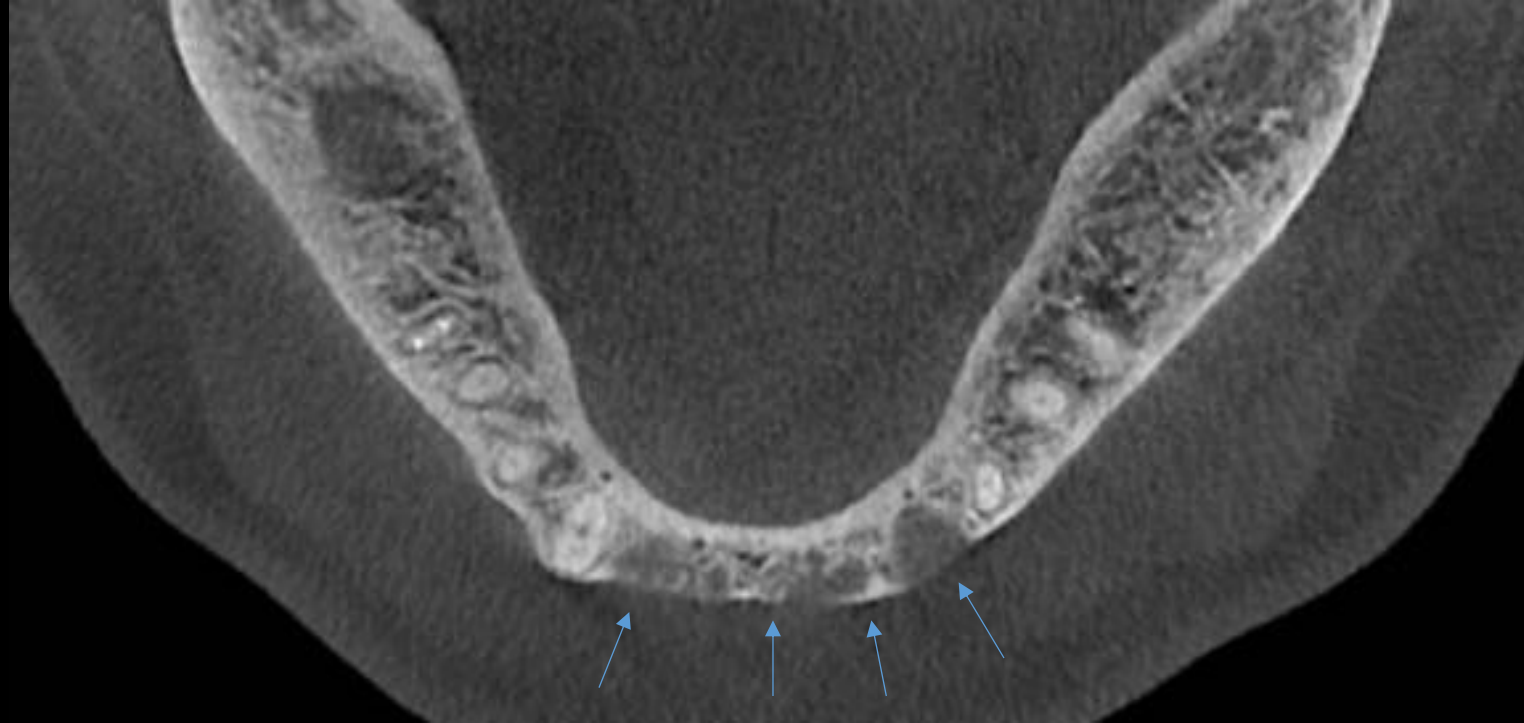


# Today's Surgery Plan

(2021-10-22)

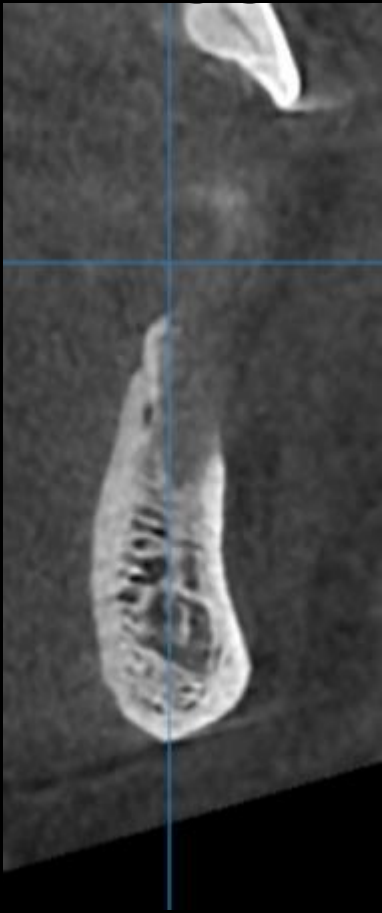
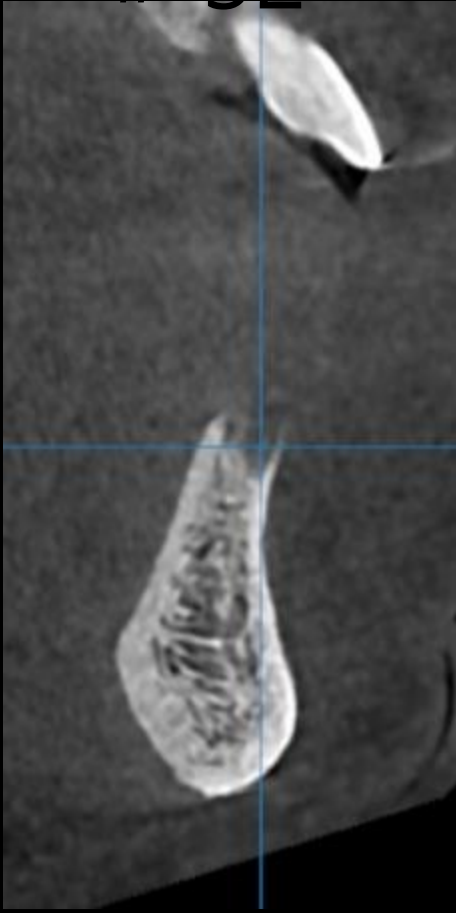
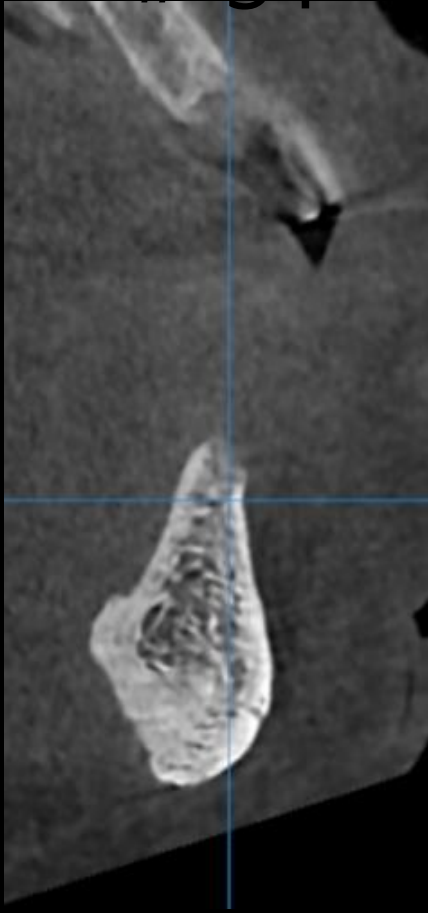
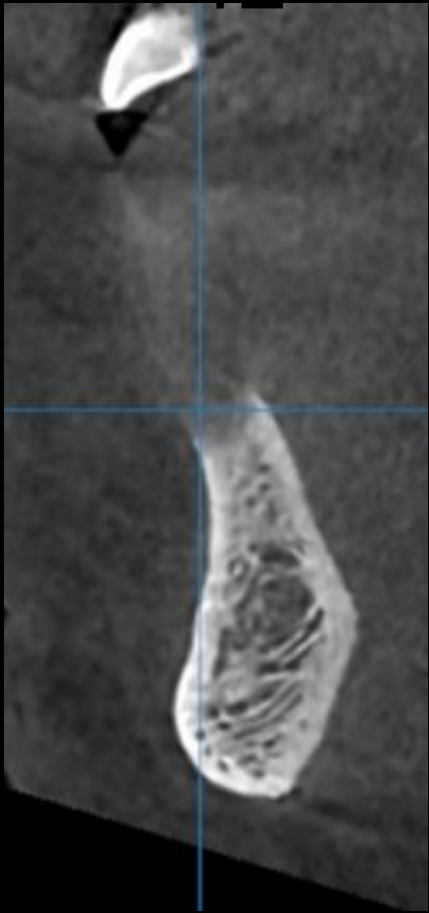


# Today's Surgery Plan





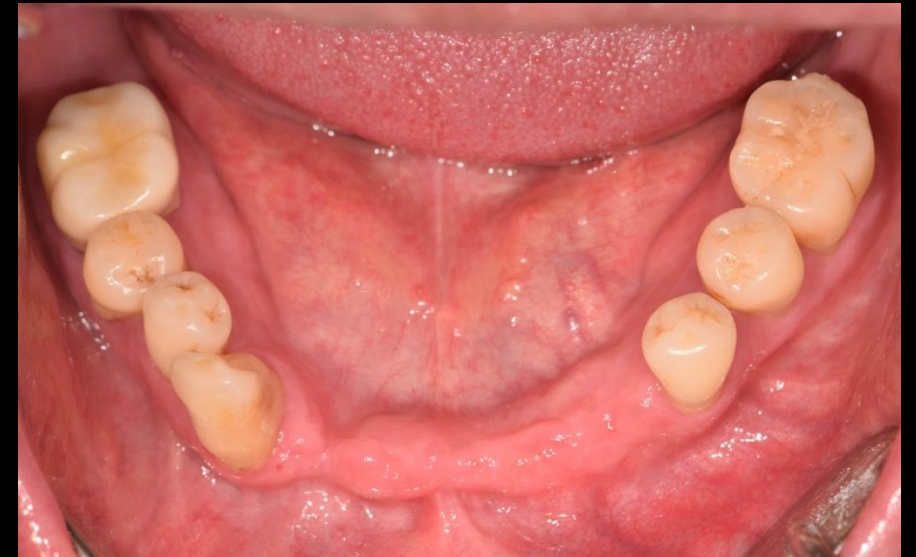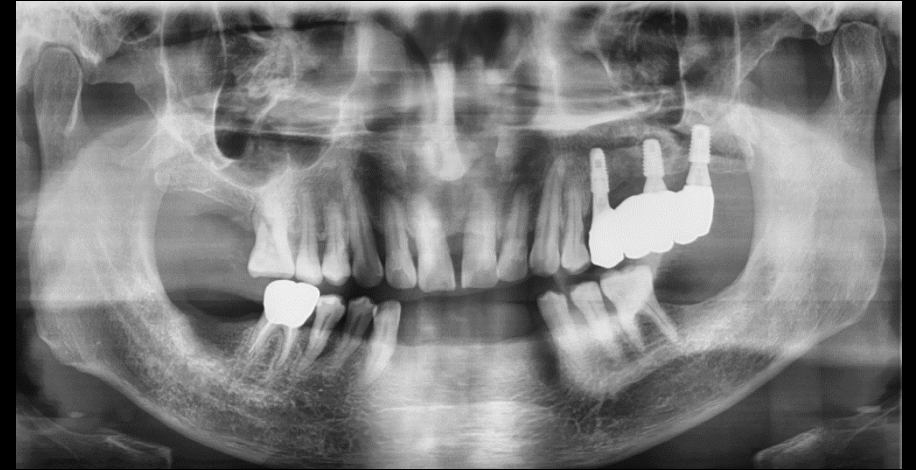
# Today's Surgery Plan



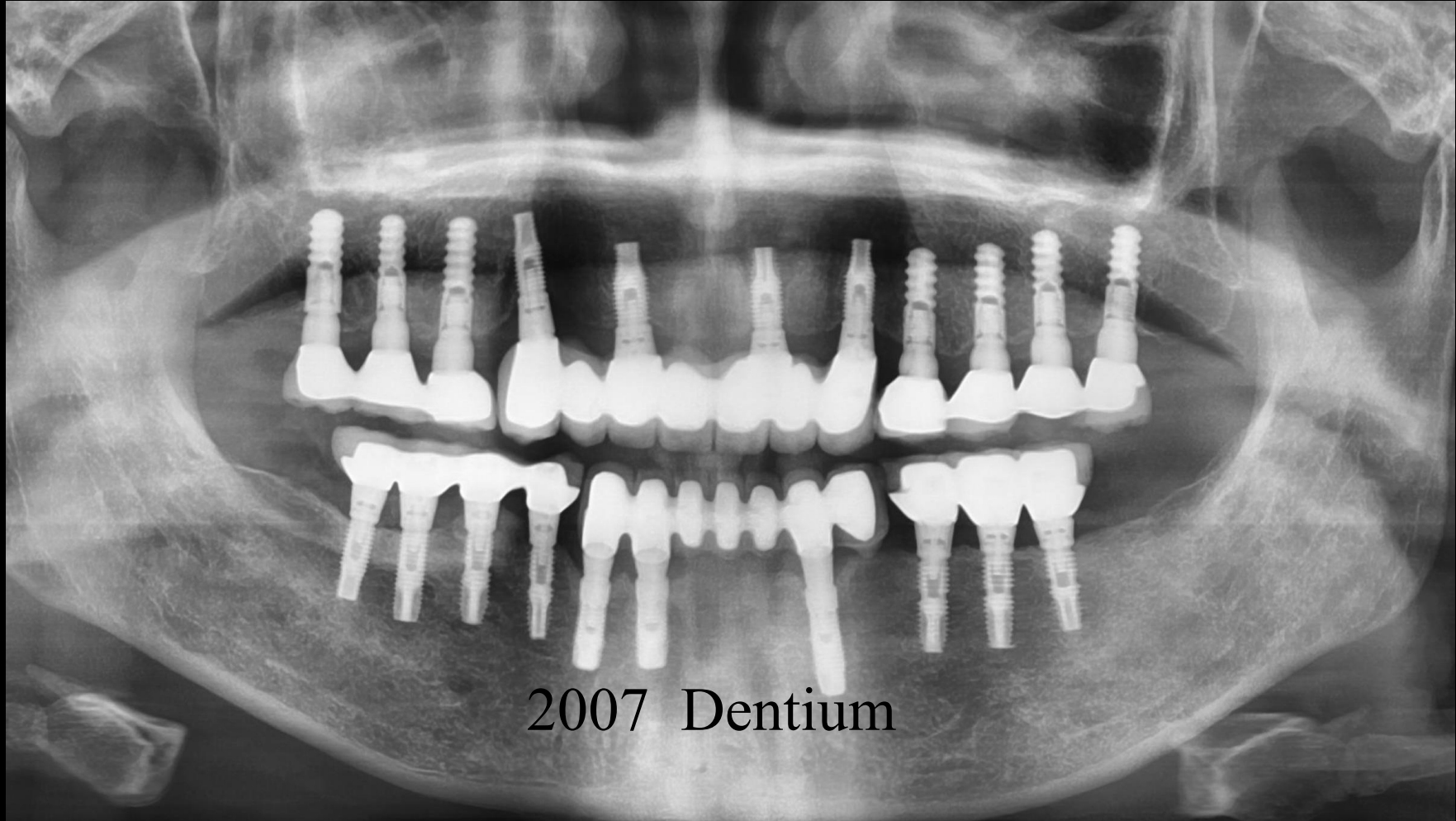# Today's Surgery Plan

#42, 31, 32

- implant Placement
- Bone graft or without Bone graft



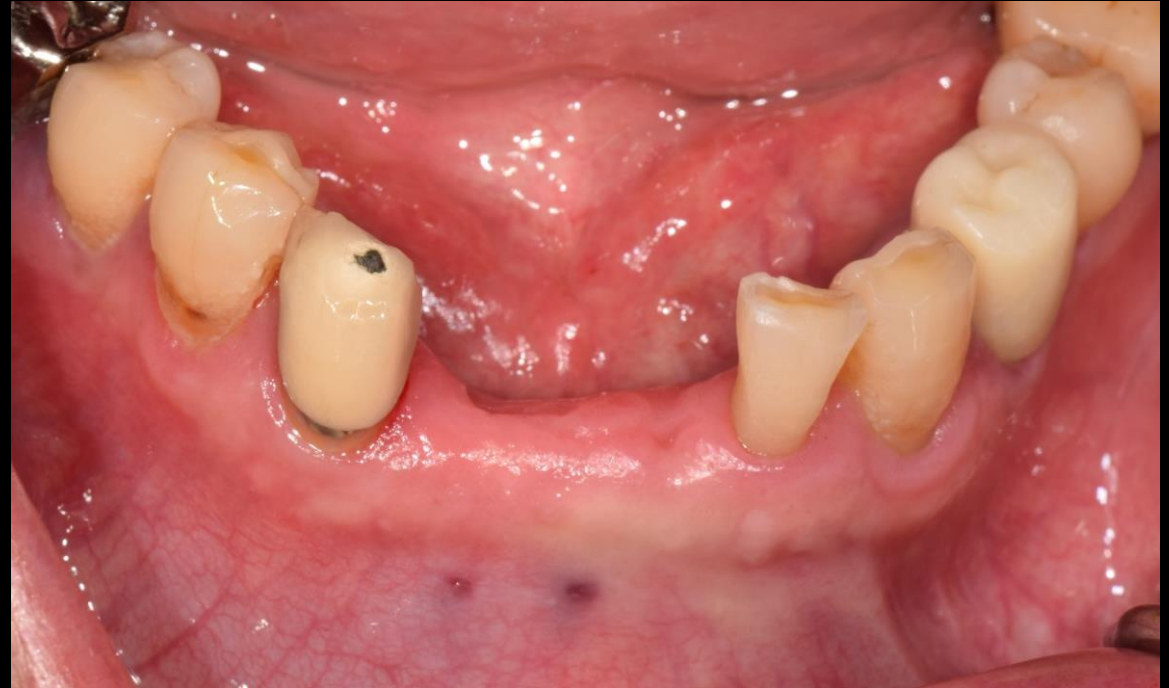
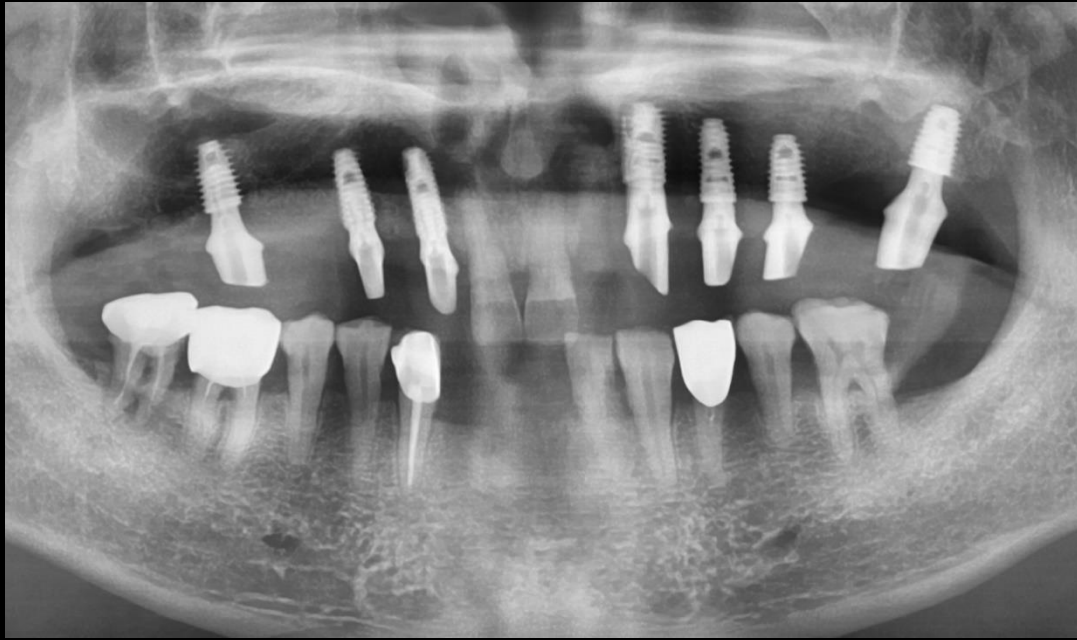




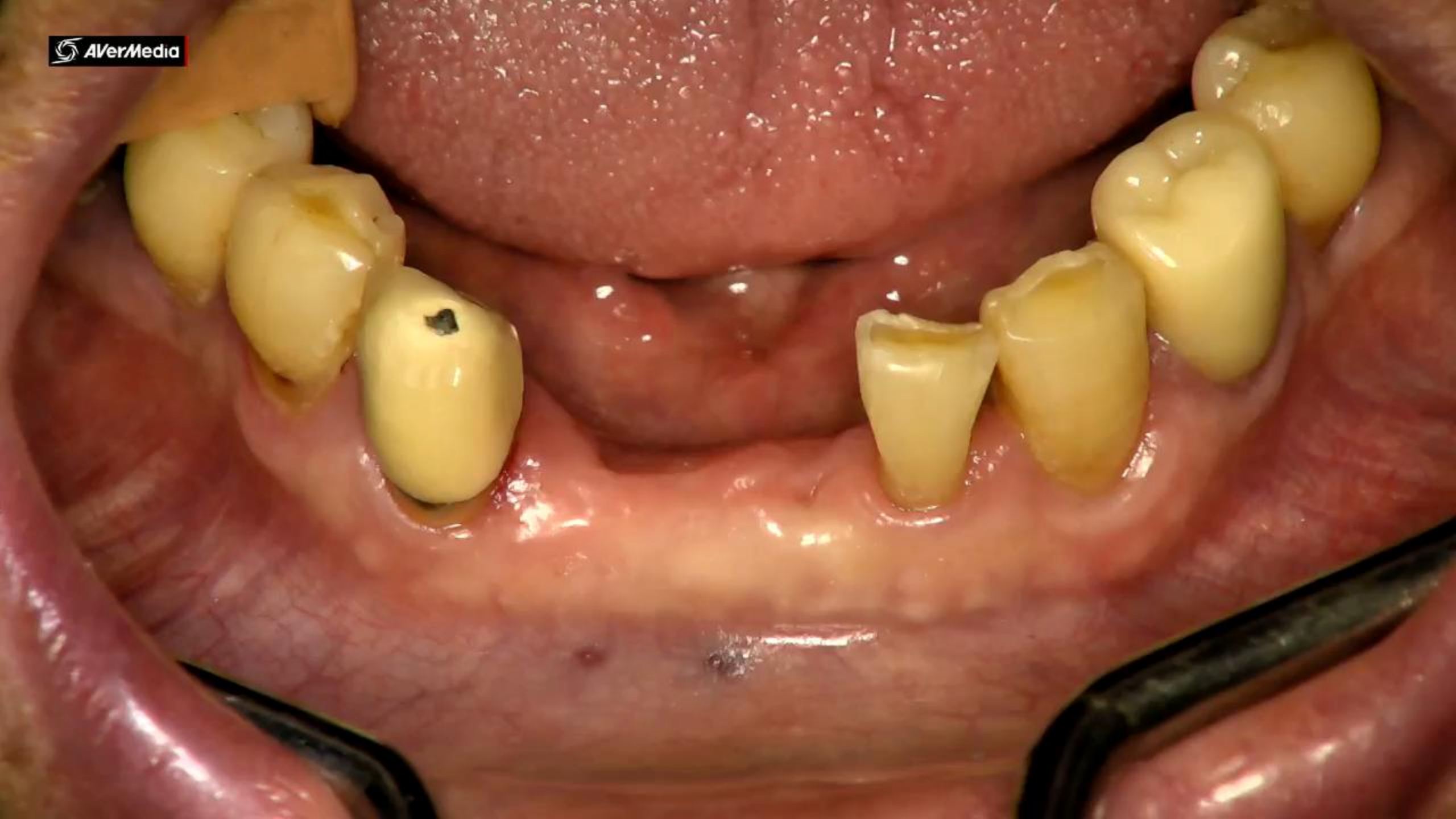2007 Dentium

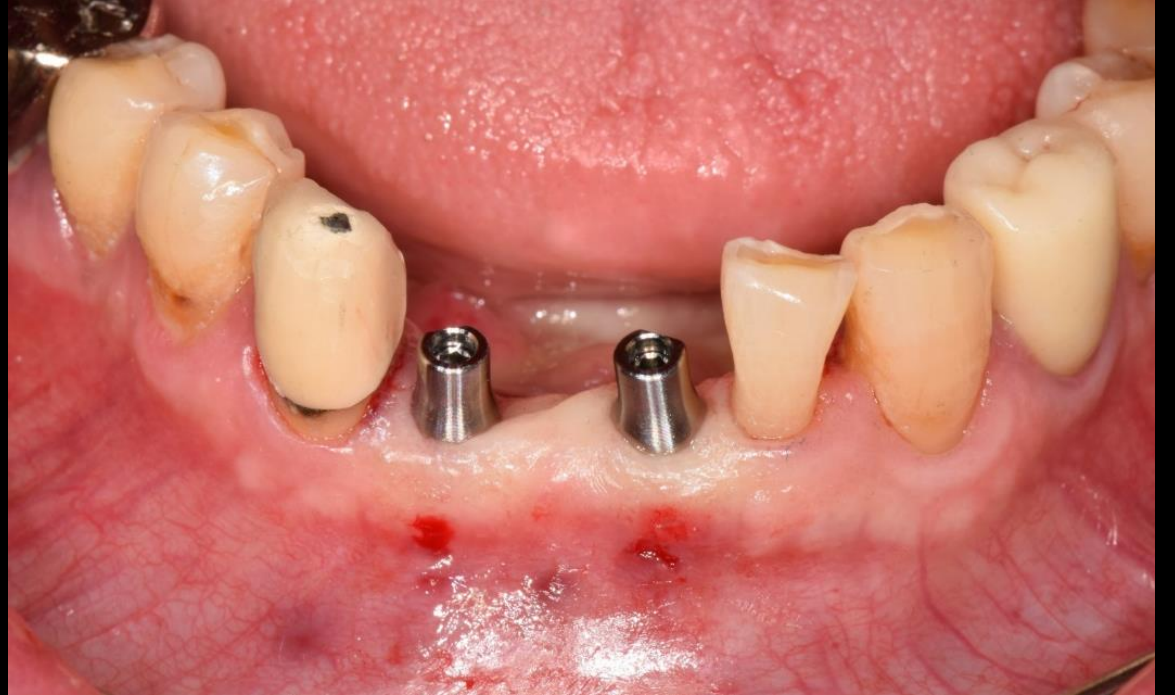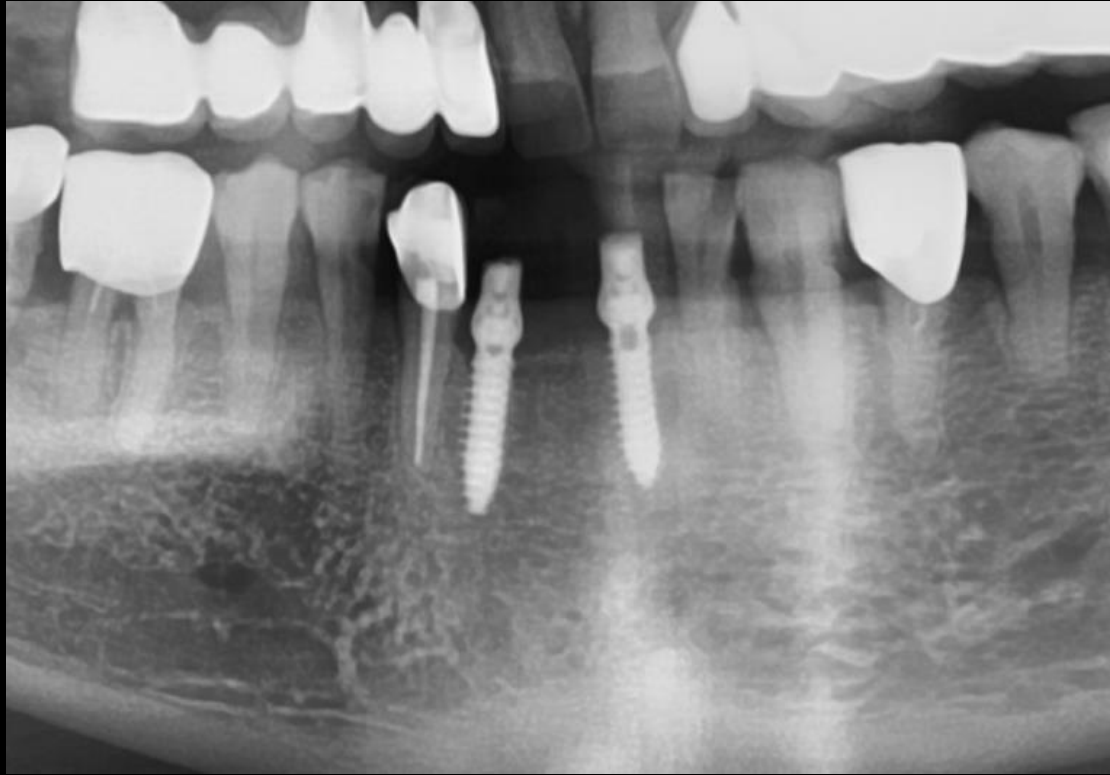
**Similar case**

**Implant placement with Pin Guide**

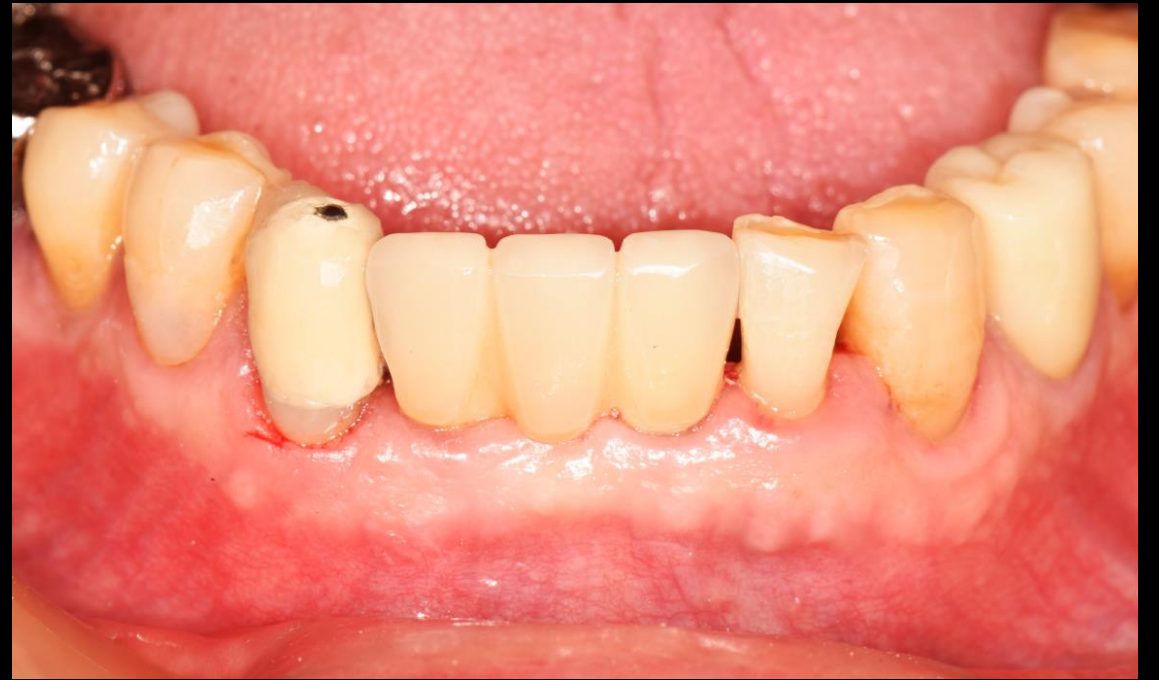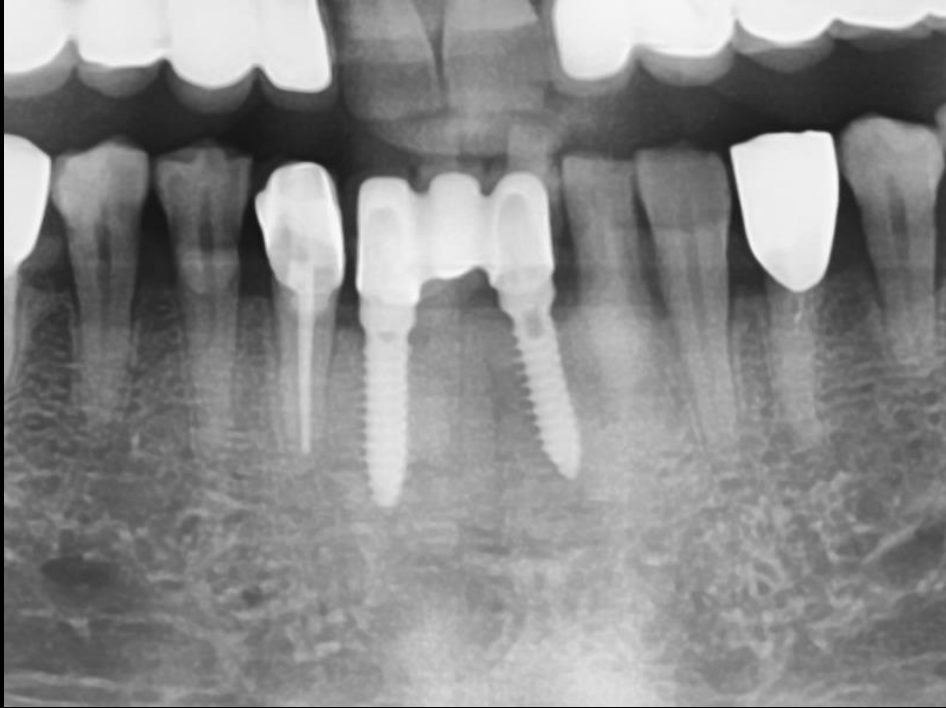


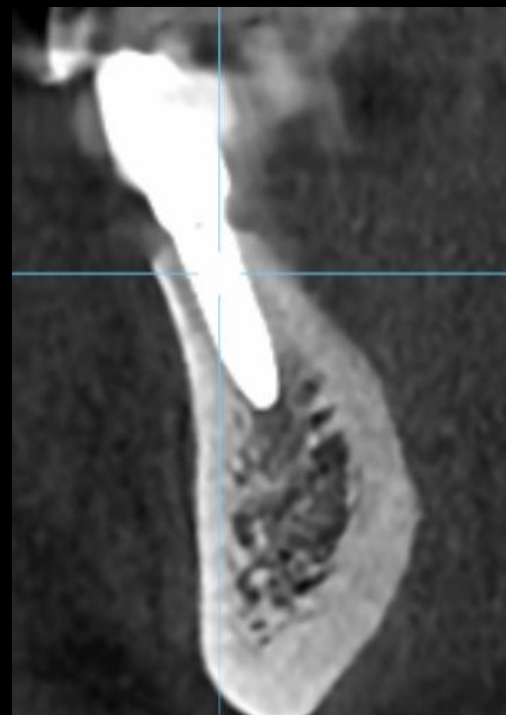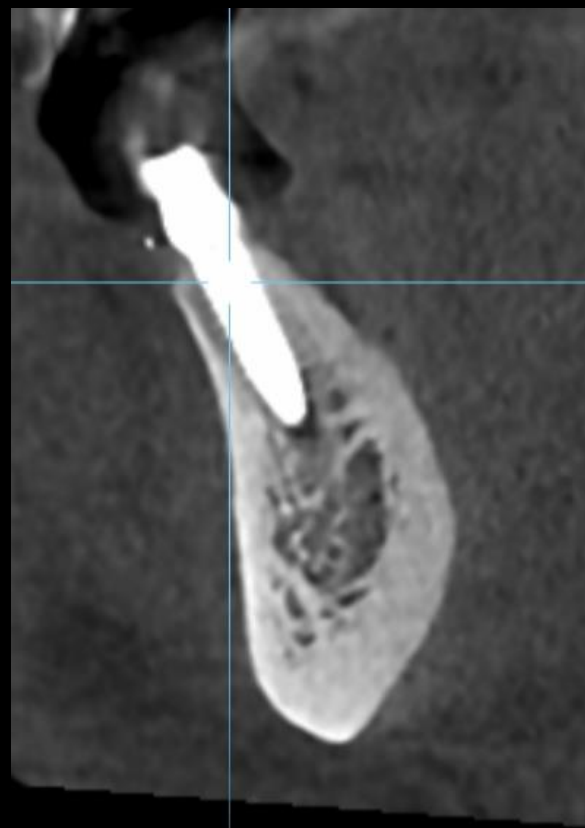
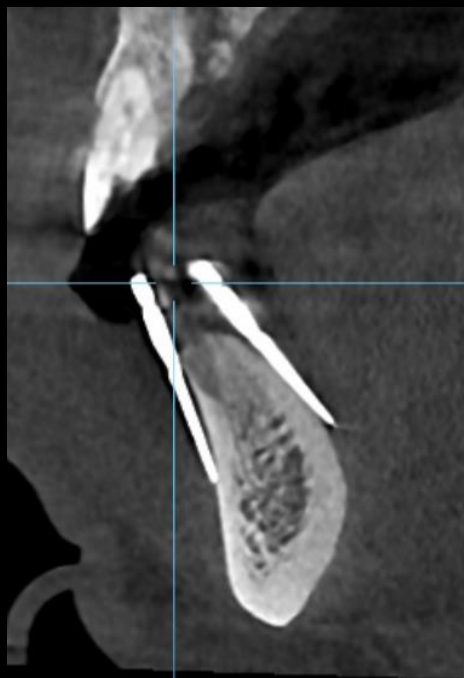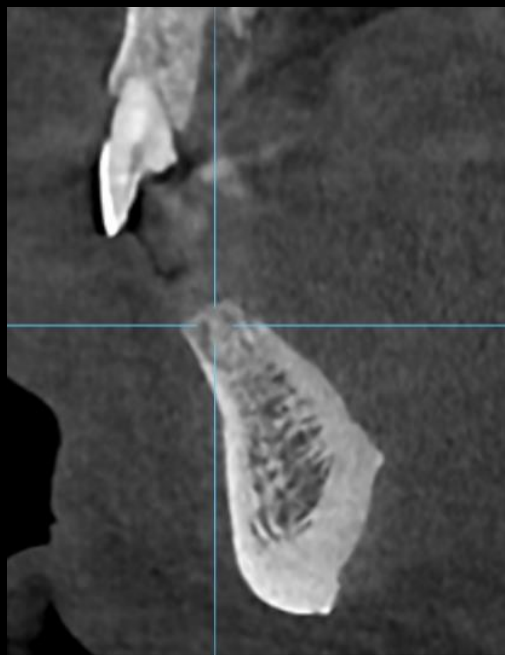


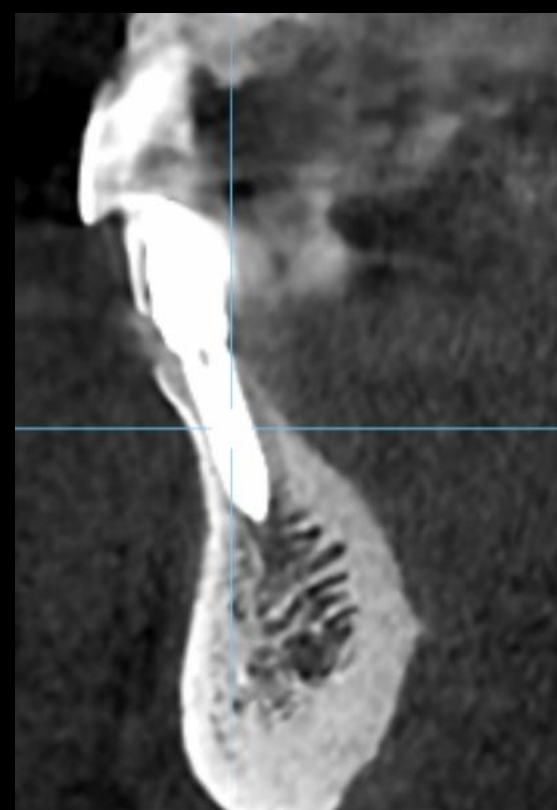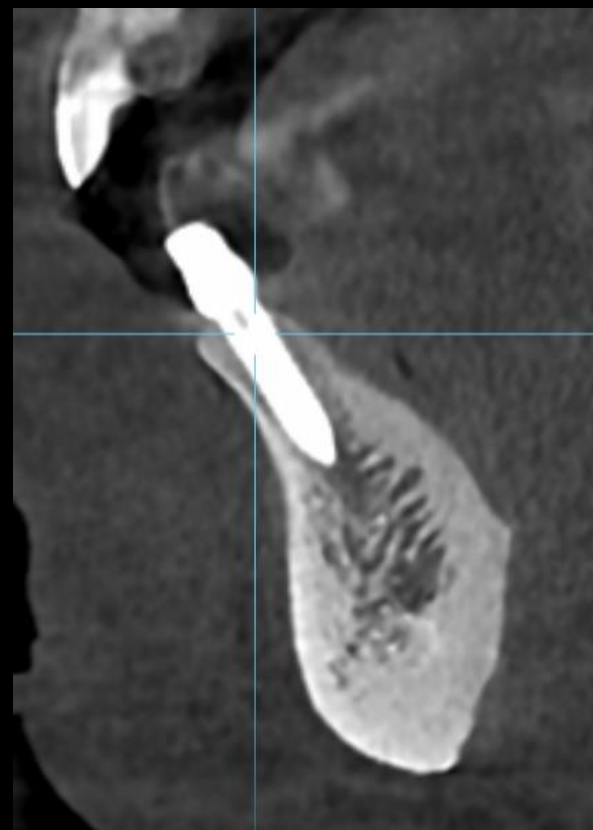
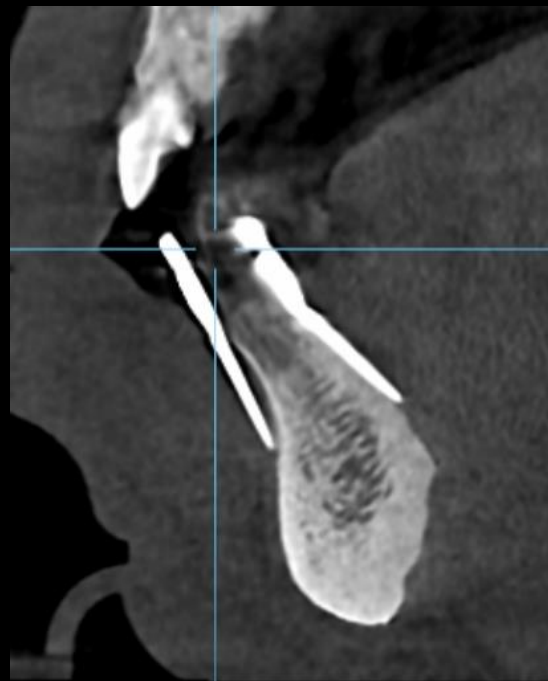
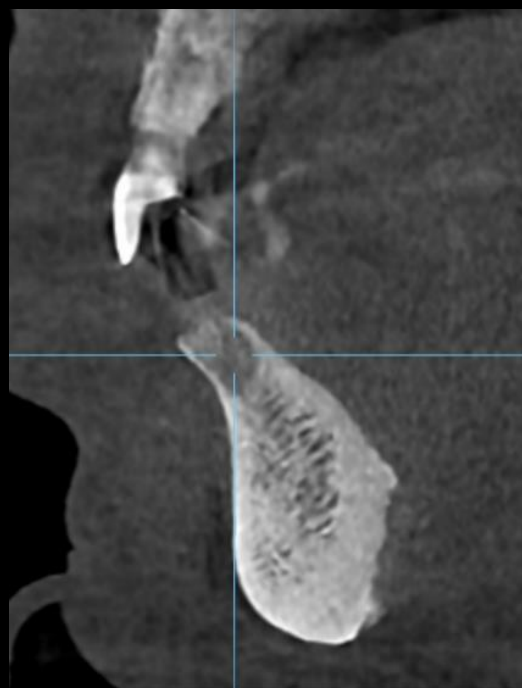










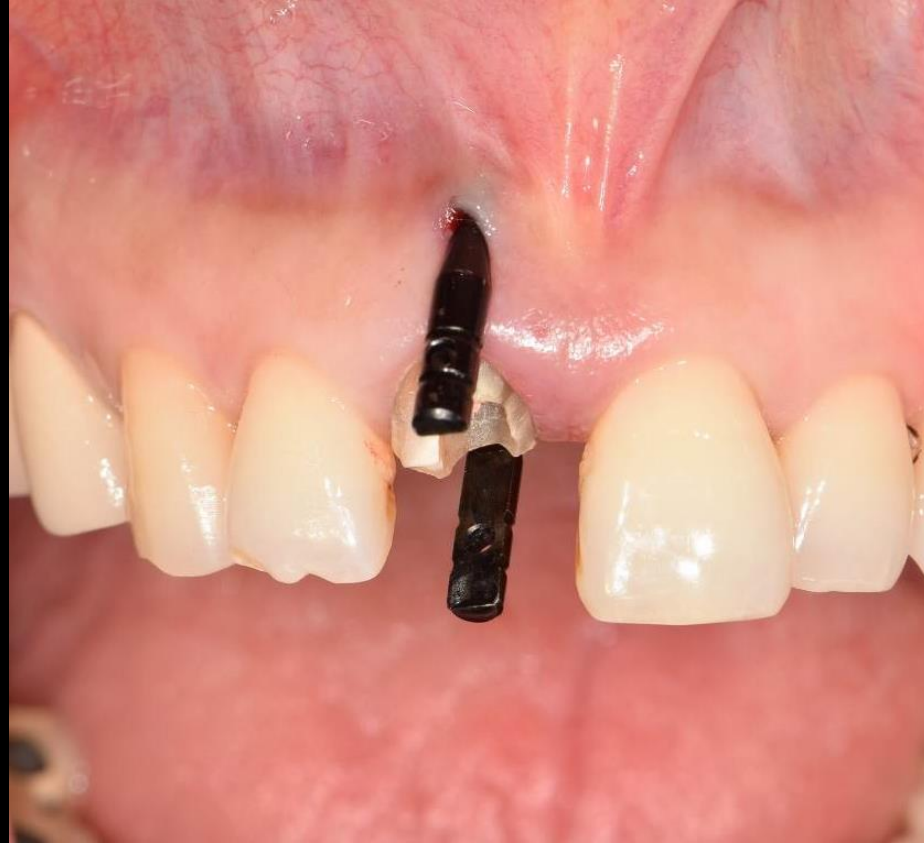



## WHAT IS THE PIN GUIDE SURGERY ?



# WHAT IS THE PIN GUIDE SURGERY ?





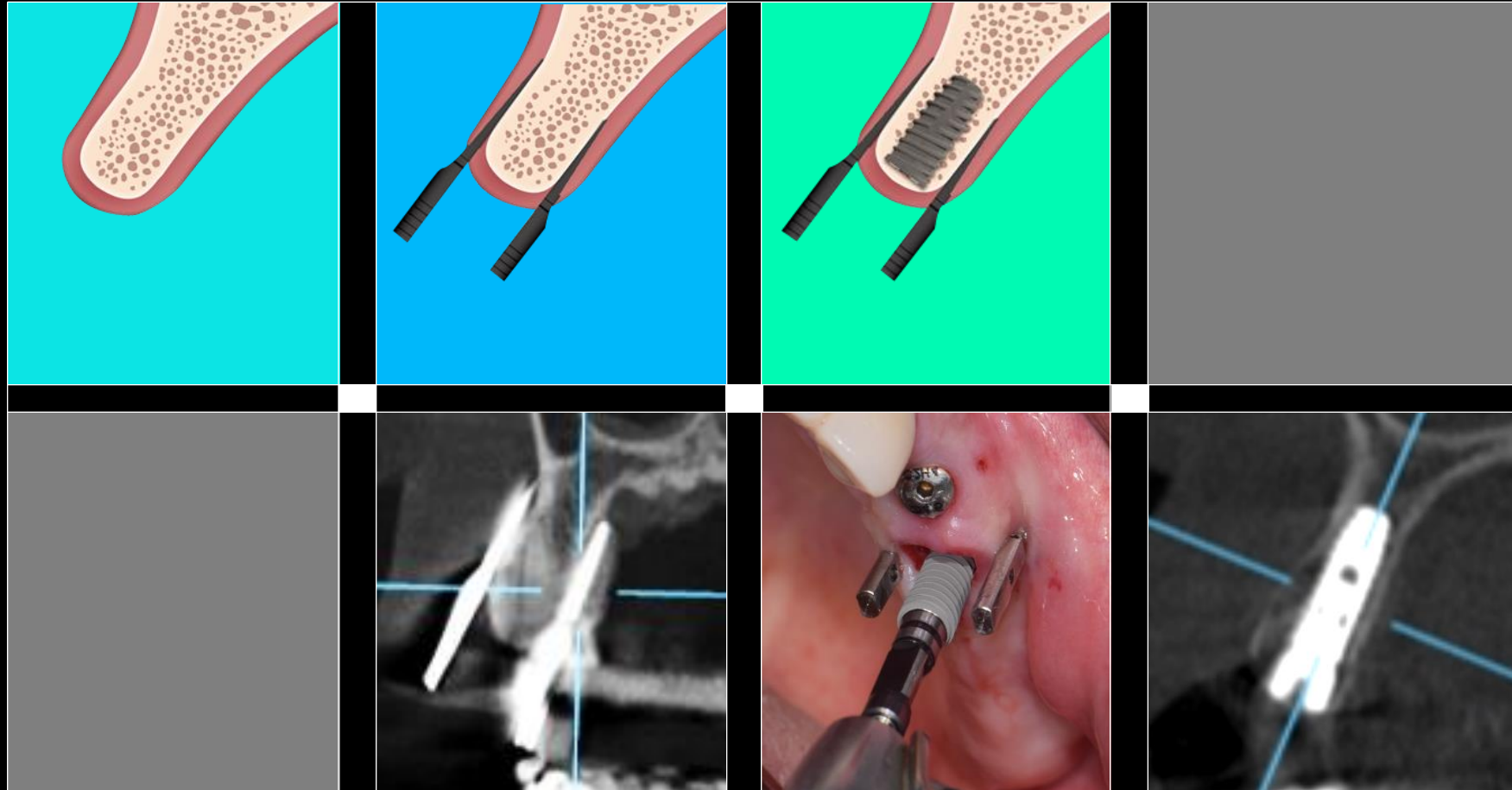
**DRILLING**



**IMPLANTATION**



# WHAT IS THE PIN GUIDE SURGERY ?



## BONE SHAPE

