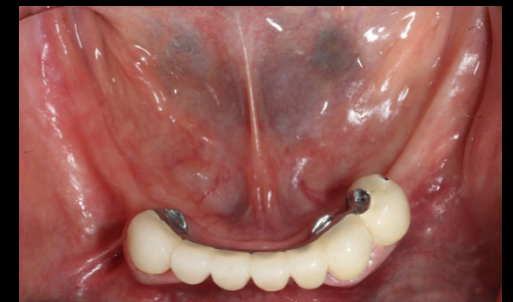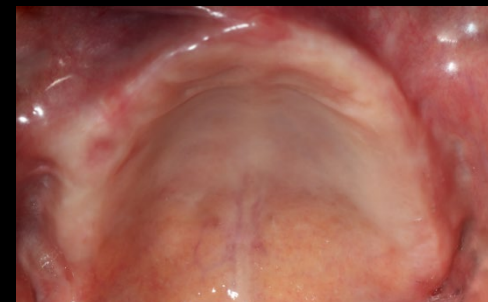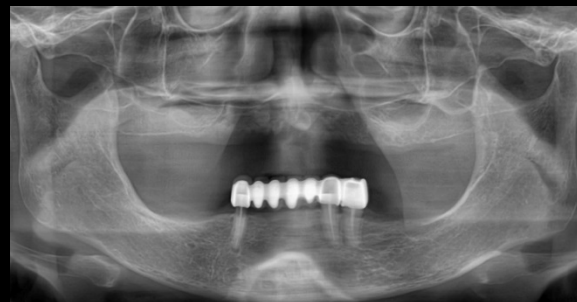




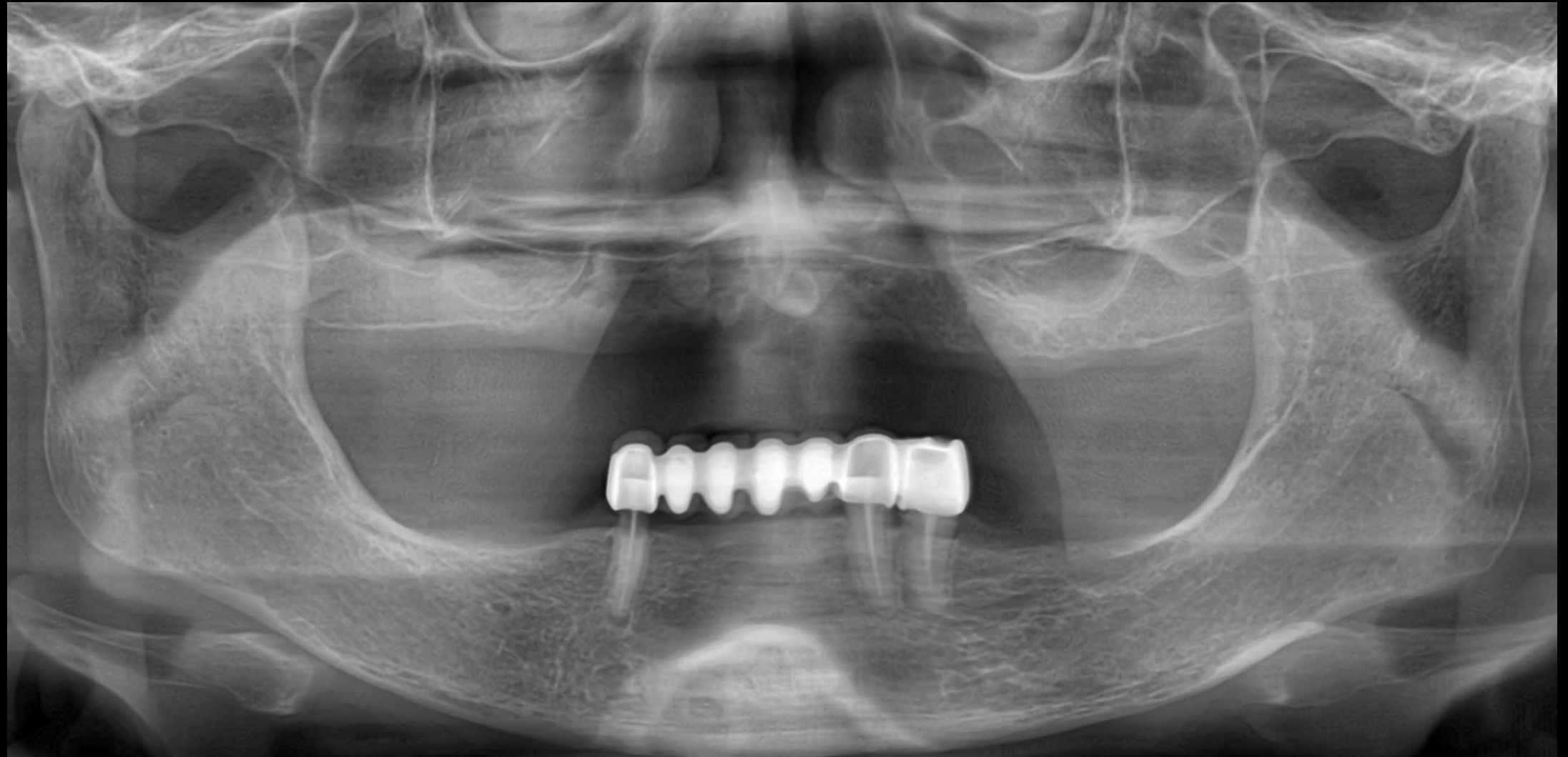
# Implant-Supported Fixed Prosthesis in the Edentulous Maxilla

Dr. SM Chung  
2021.11.5 (Fri)

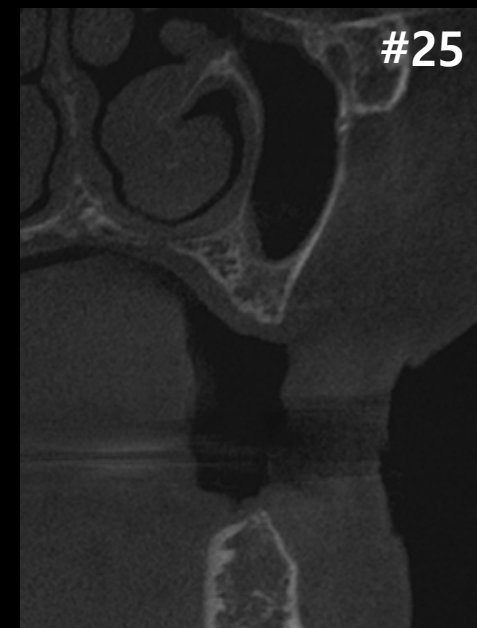
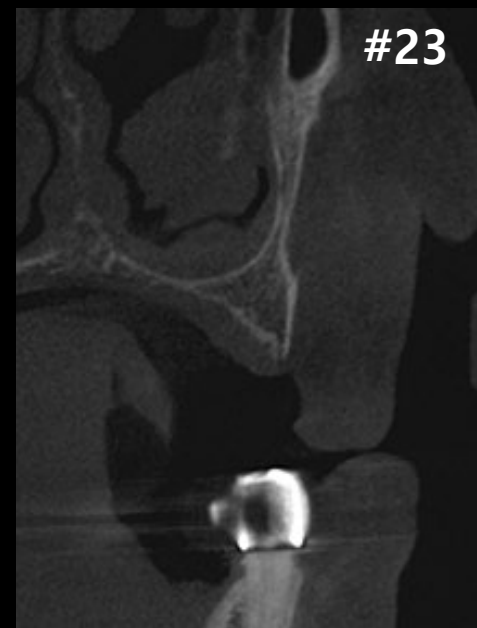
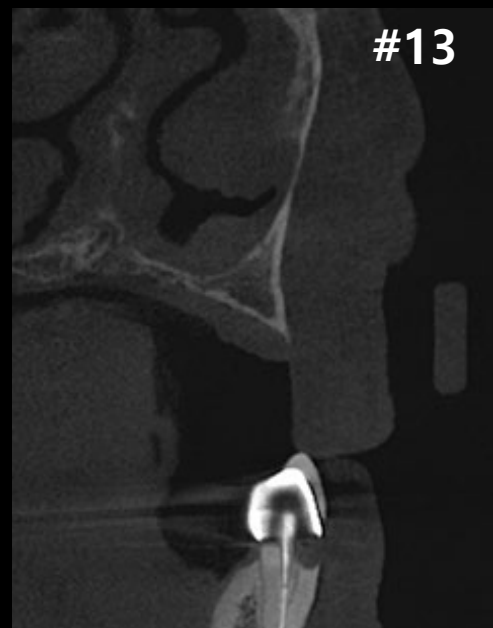
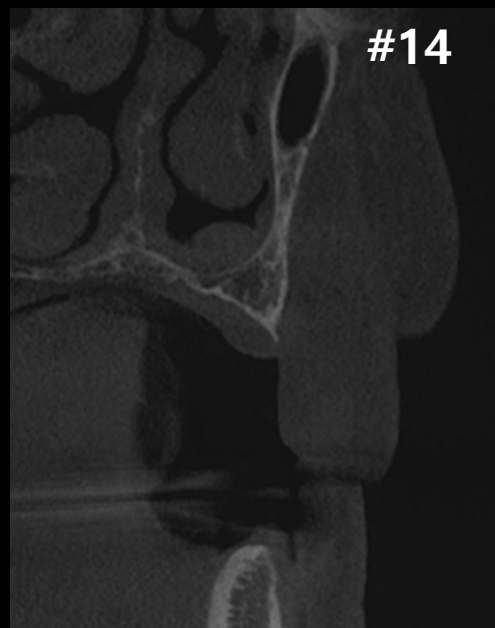


72yrs / Female

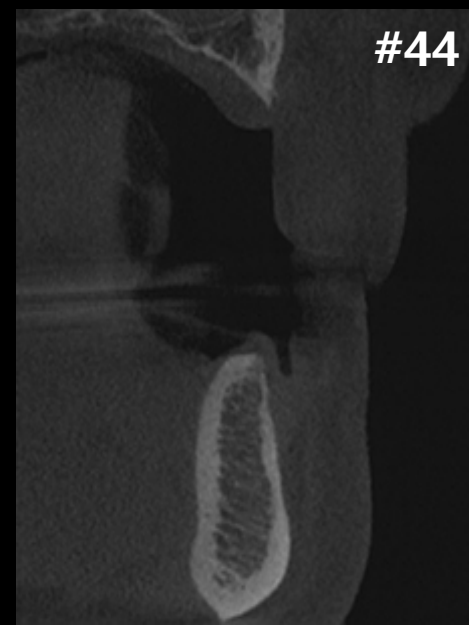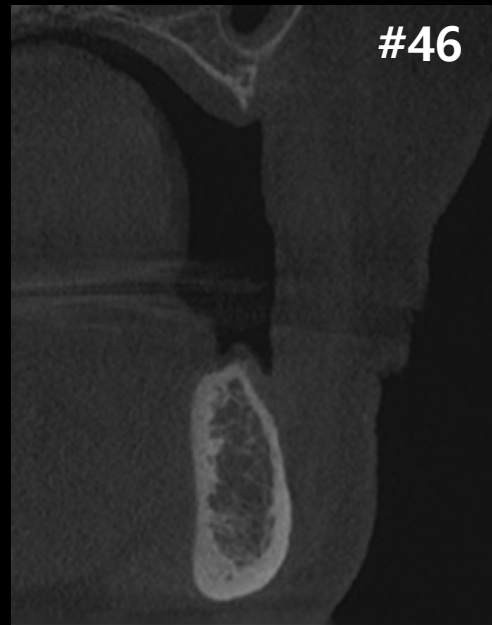
Pre-op (2021-10-20)



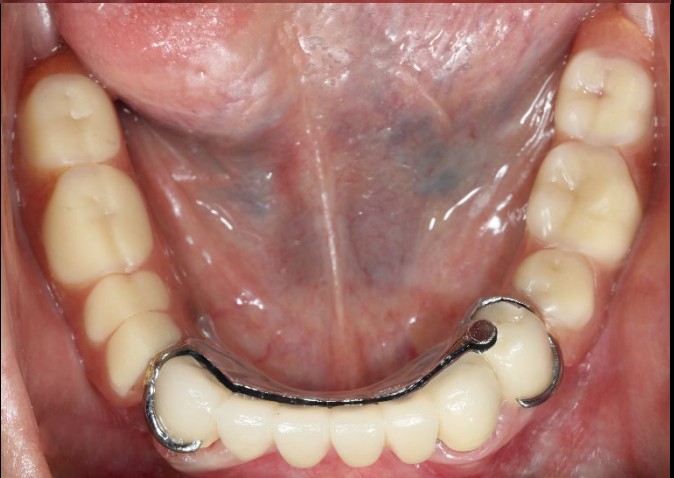
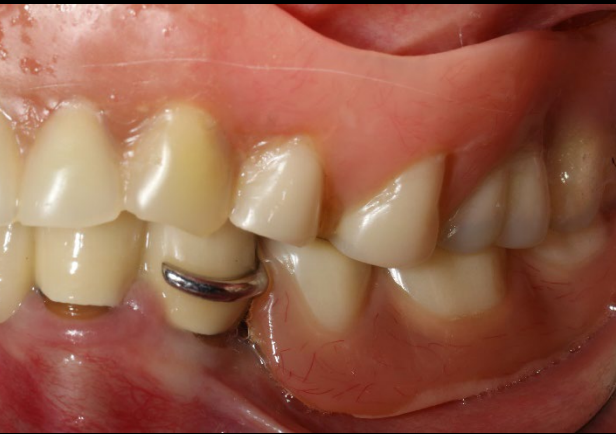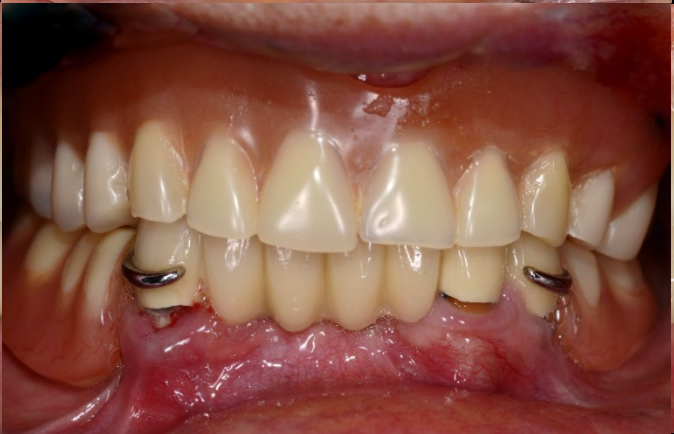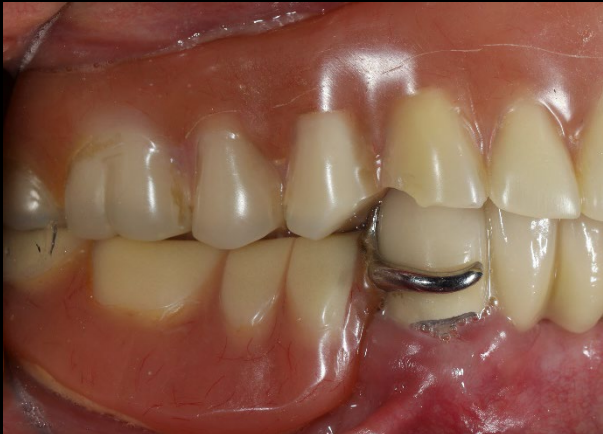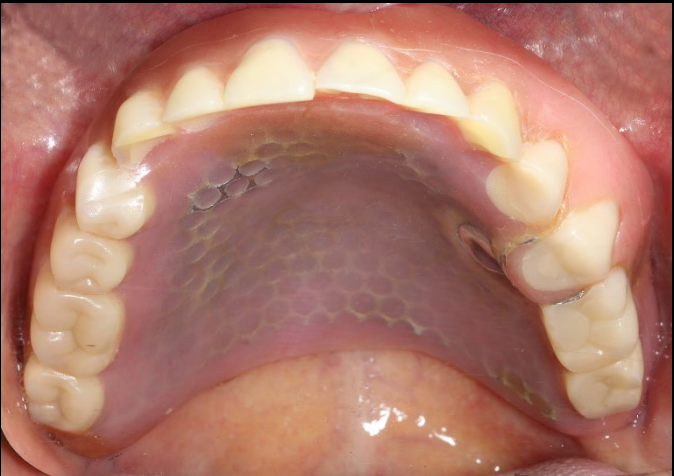
Pre-op (2021-10-20)



Pre-op (2021-10-20)

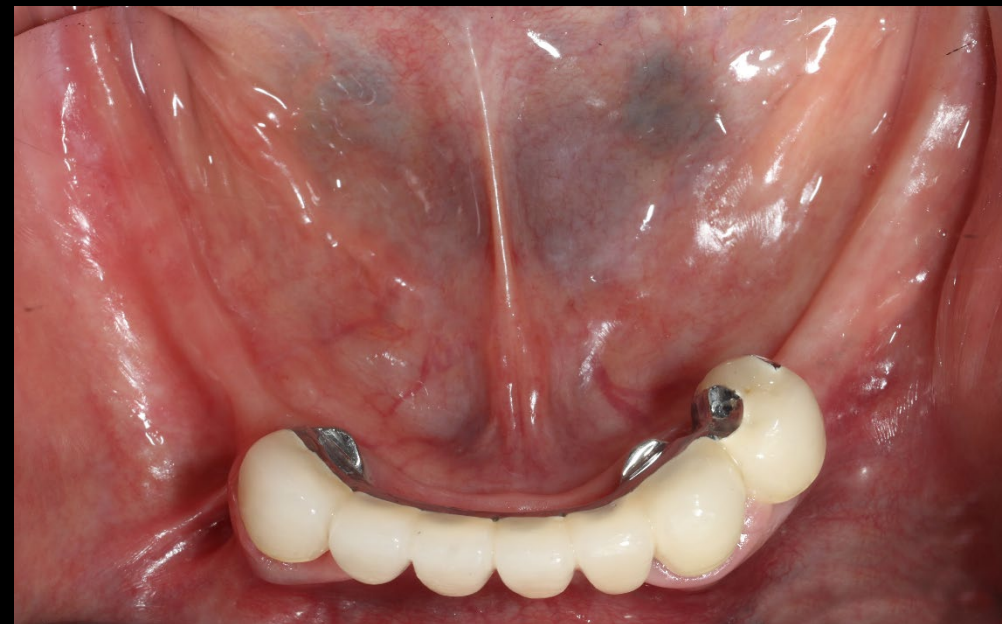
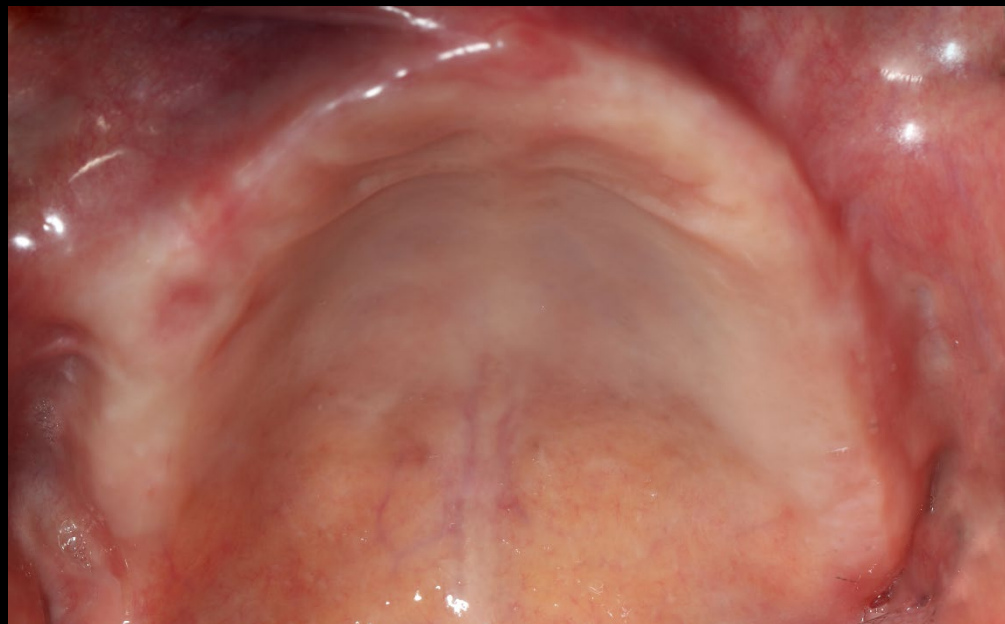

Oral-exam

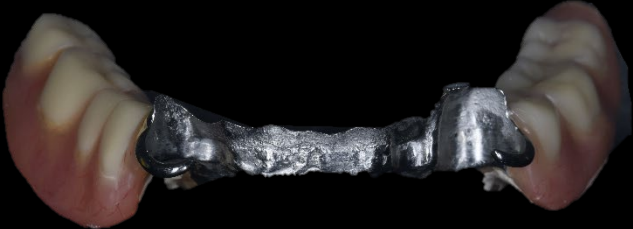
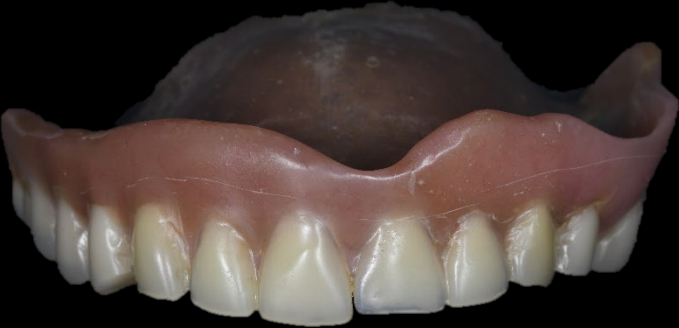


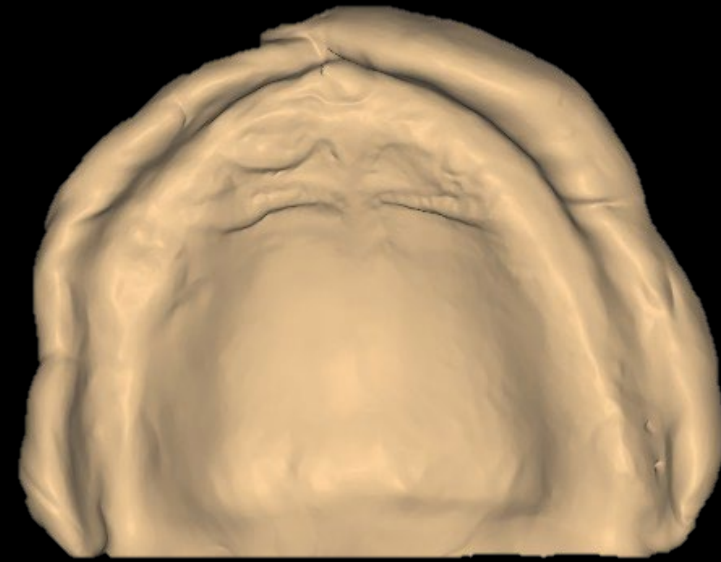
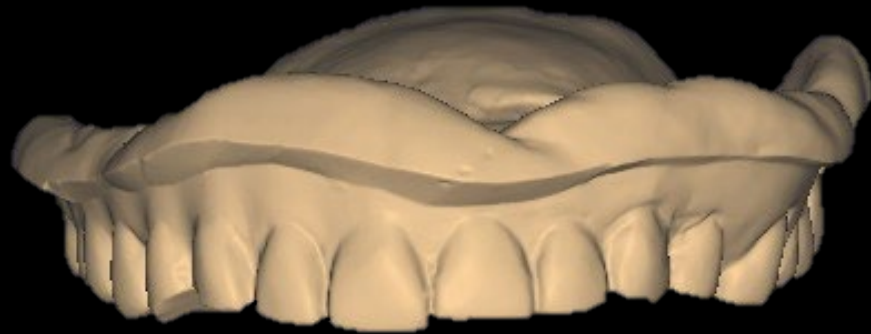Oral-exam



Old-denture

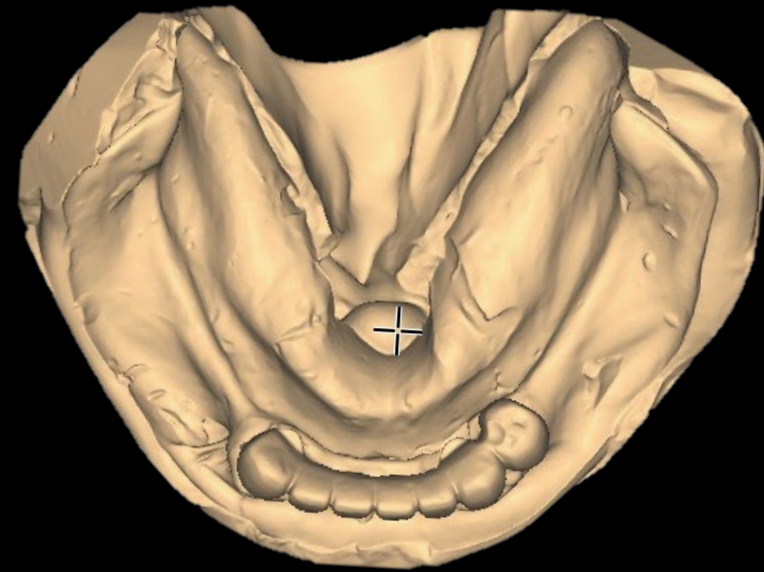
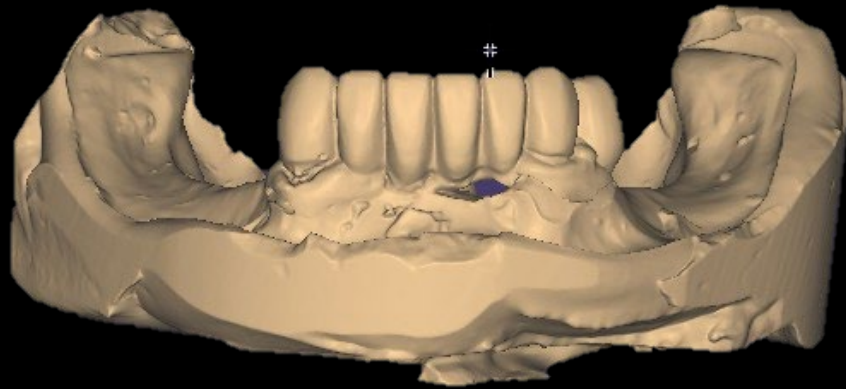


# Maxillar Denture Scan

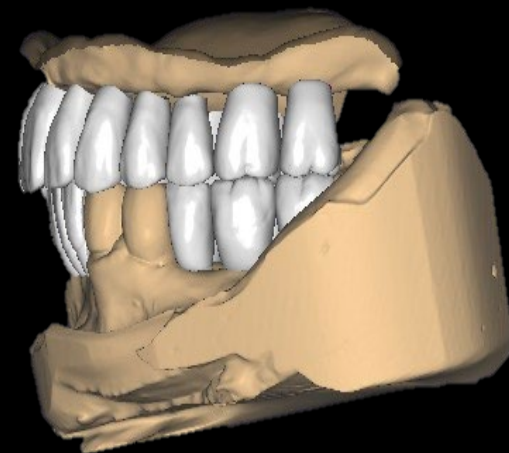
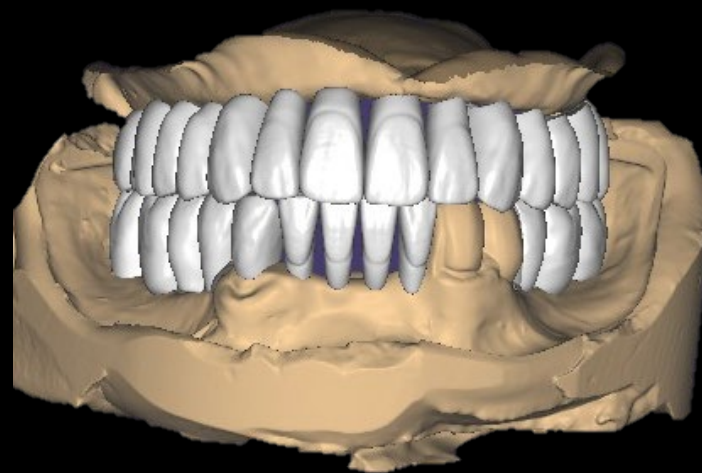
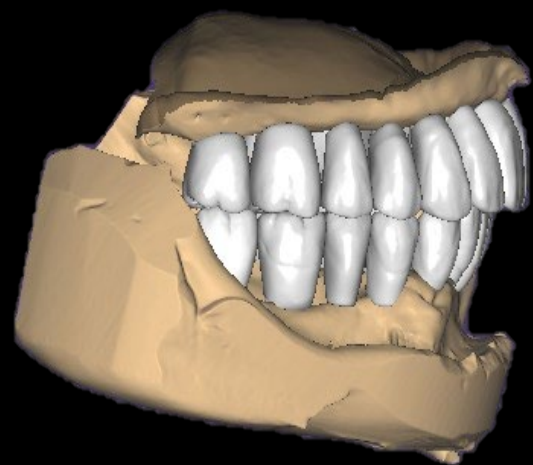




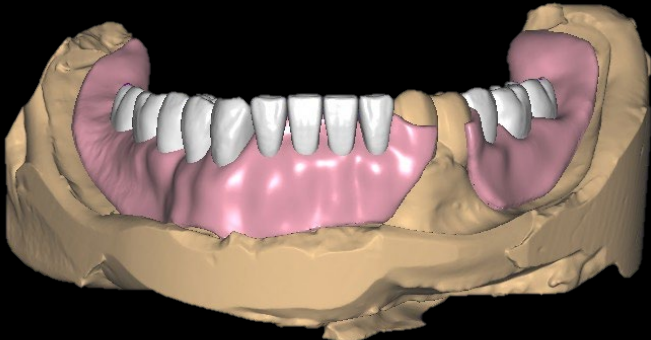
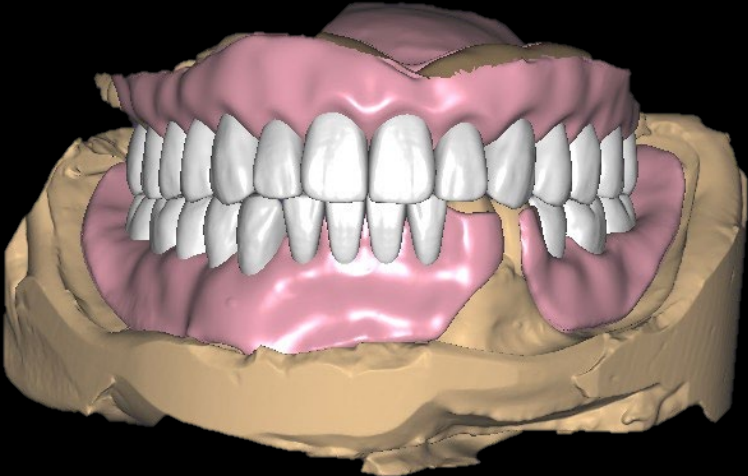
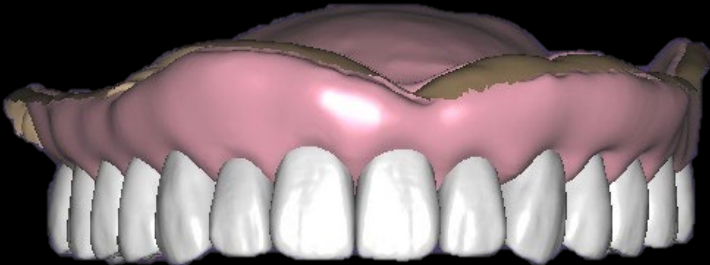
# Mandible Cast-model Scan



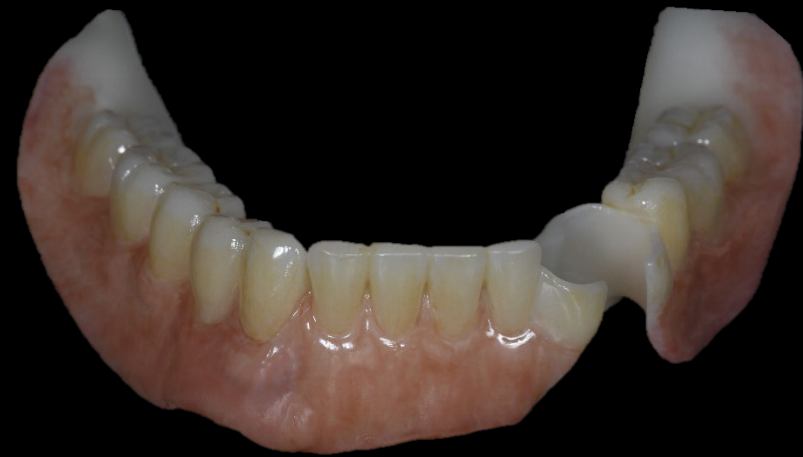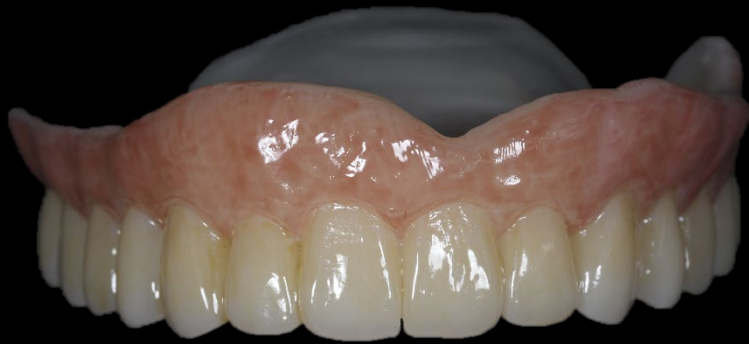Virtual set-up



3D Printing denture Design

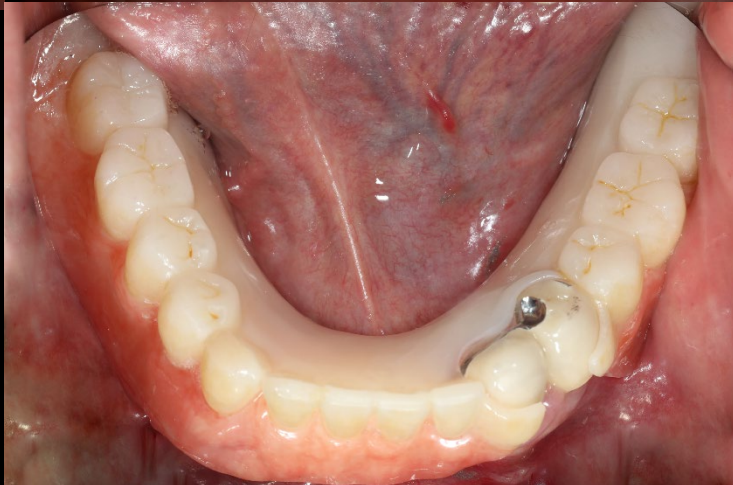
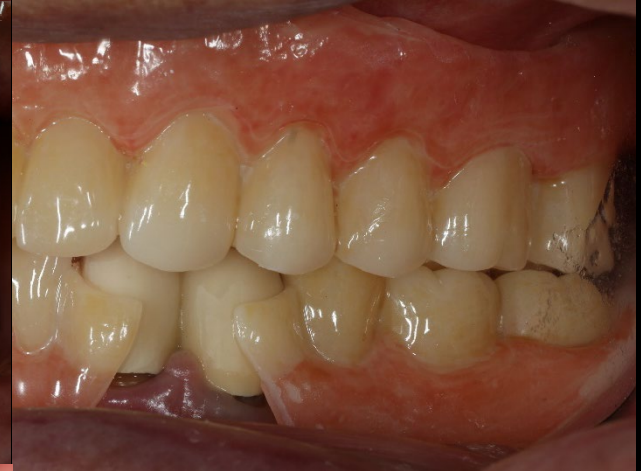
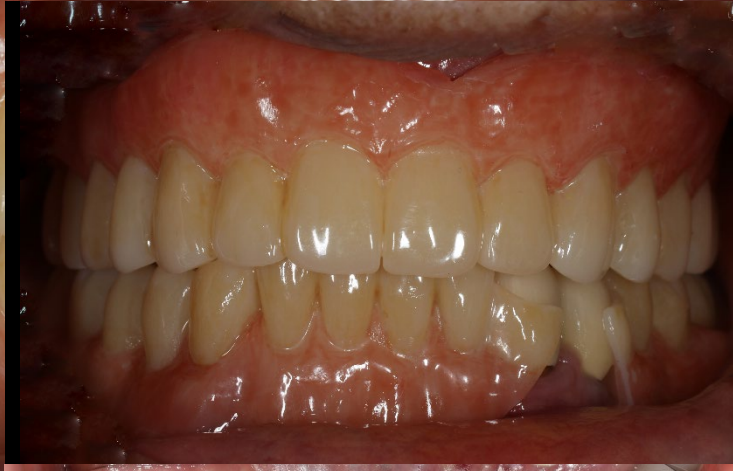
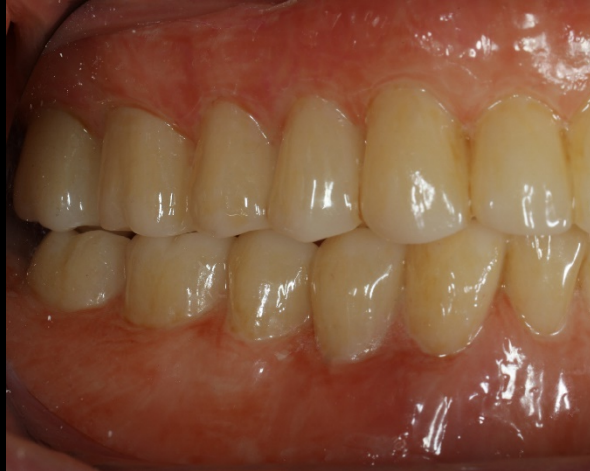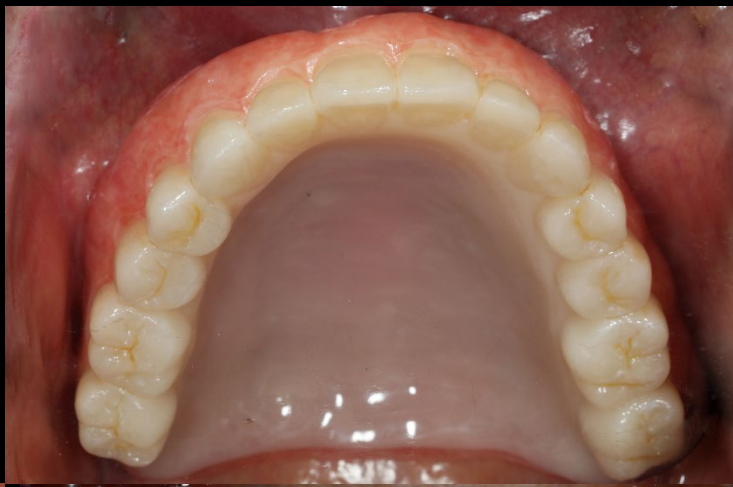3D Printing Denture (2021-10-29)



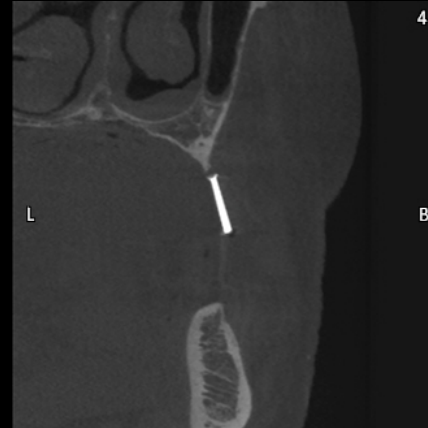
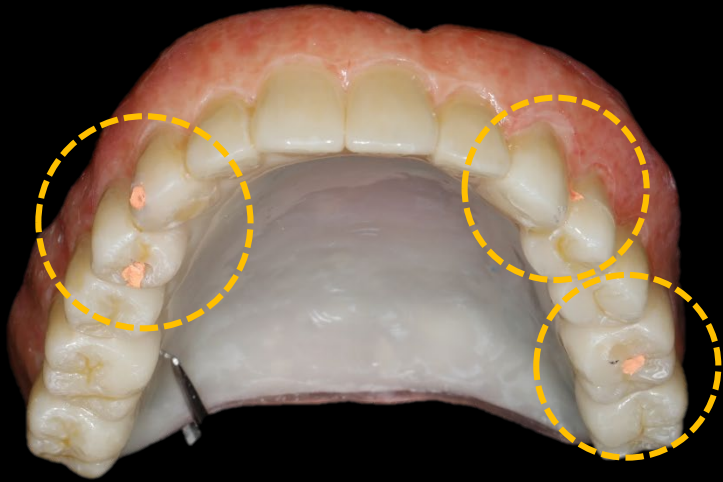


**3D Printing Denture Delivery  
(2021-10-29)**

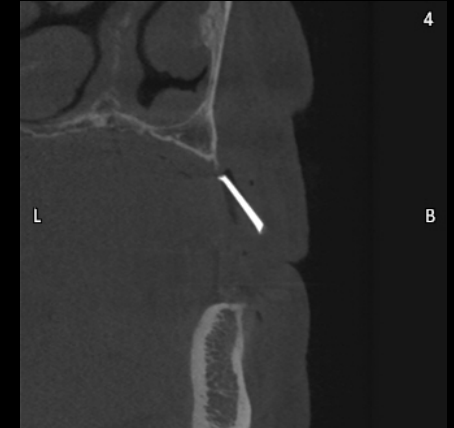



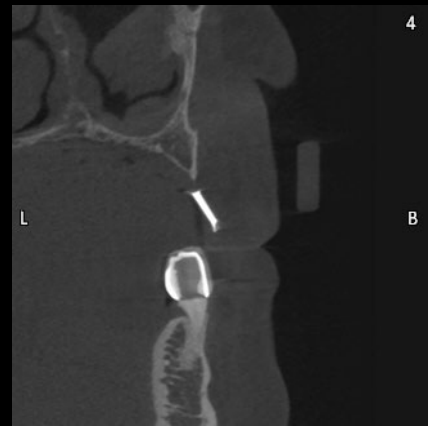
# GP cone marking & CT taking (2021-11-03)



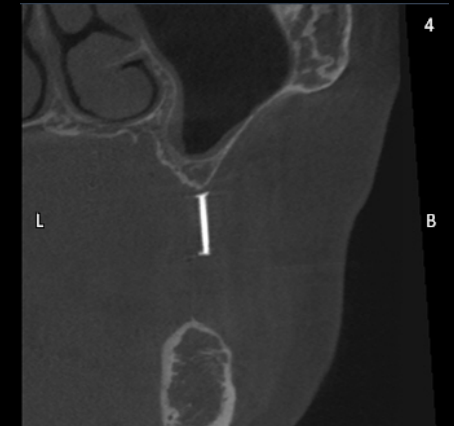#14



#13

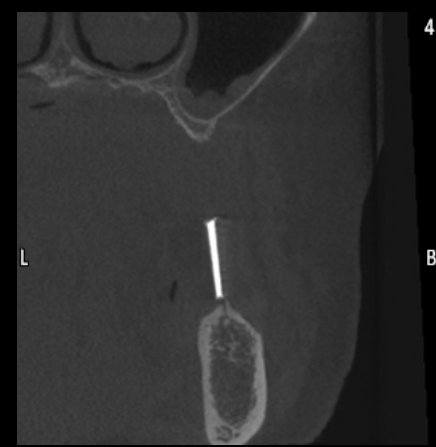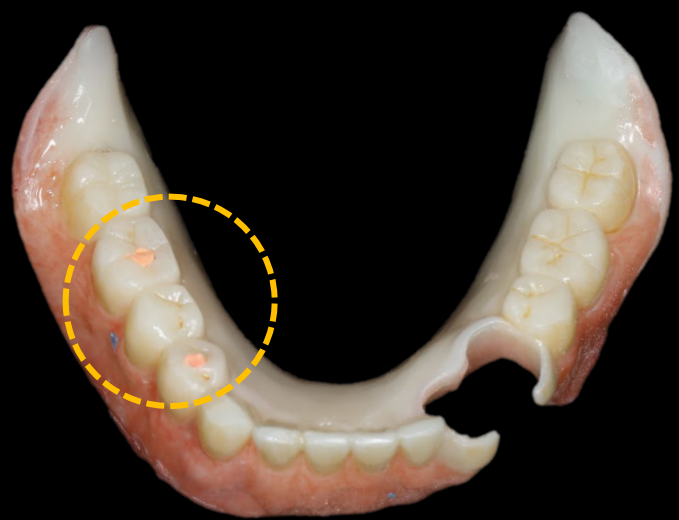


#23

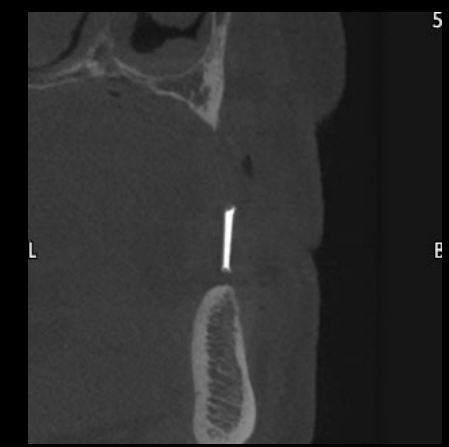

#25

# GP cone marking & CT taking (2021-11-03)

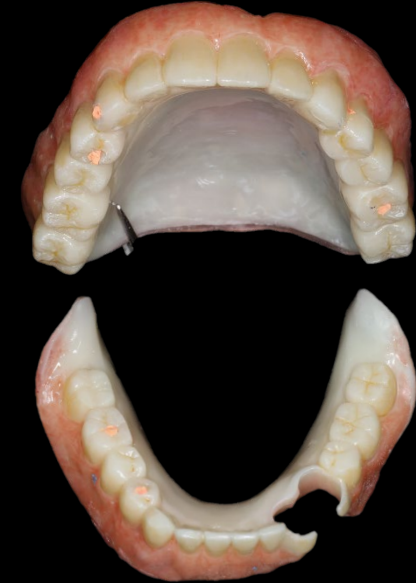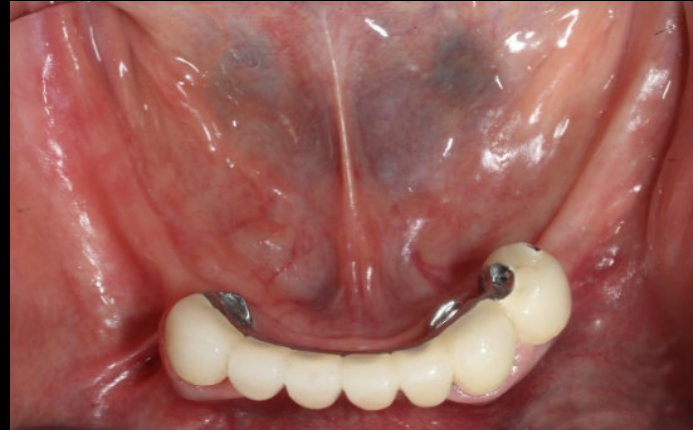
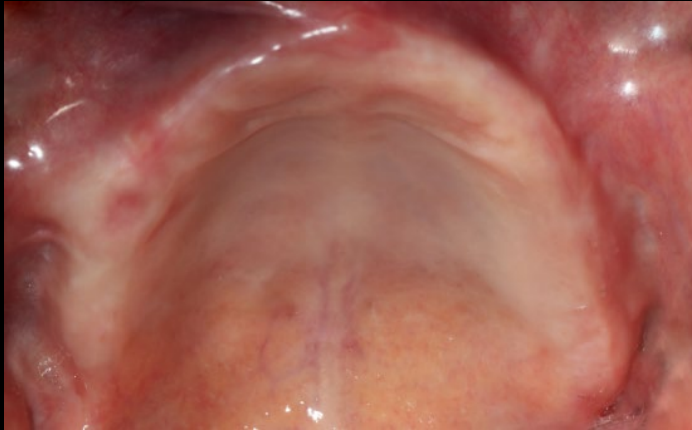


#46



#44

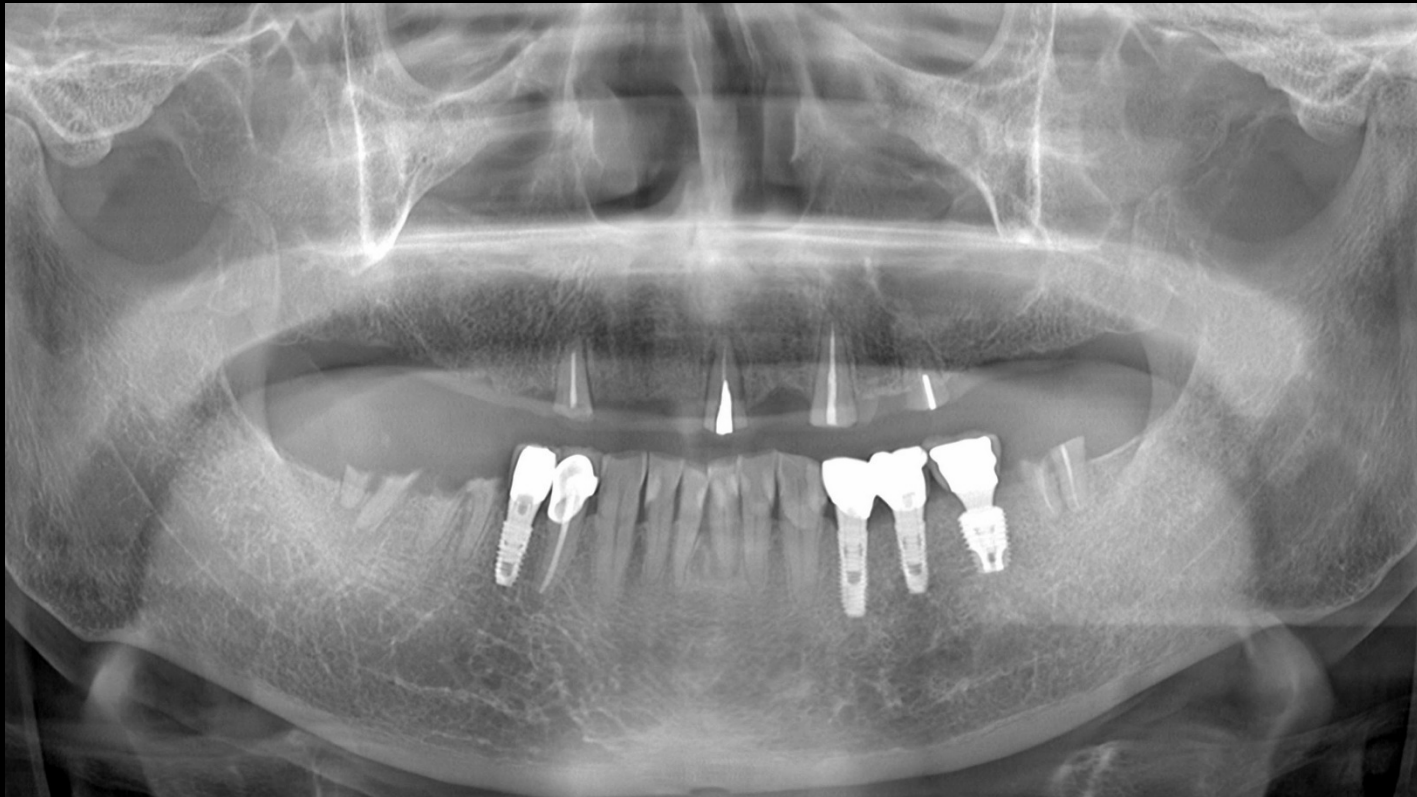## Surgery Plan (#14,13,23,25,44,46)



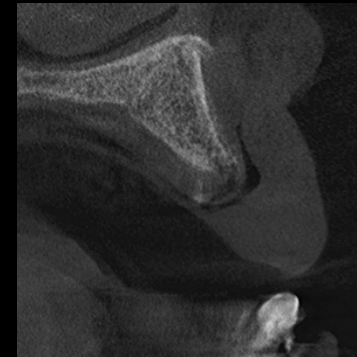- #14,13,23,25,44,46 Implantation with bright Implant using 3D Printing denture

# Similar case 1

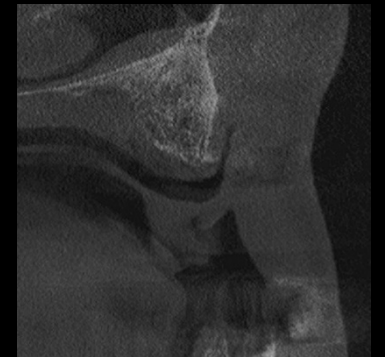# Full arch Rehabilitation on Maxilla



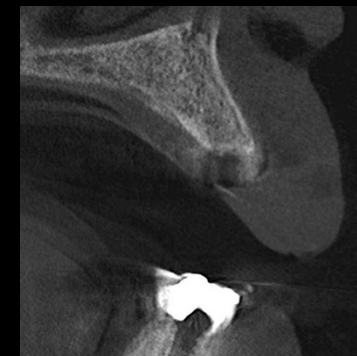Pre-op



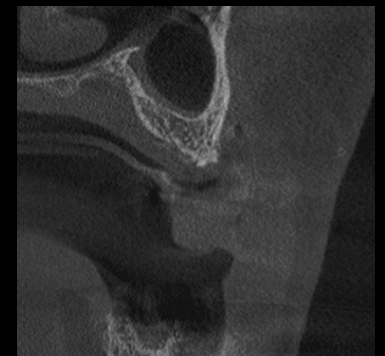#12



#15



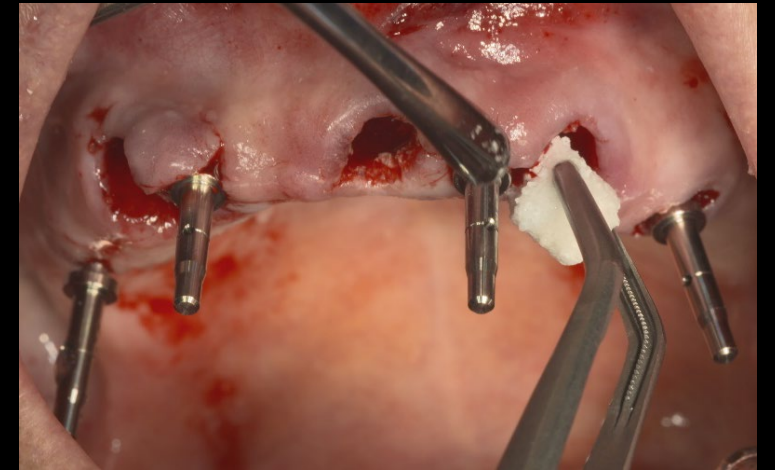
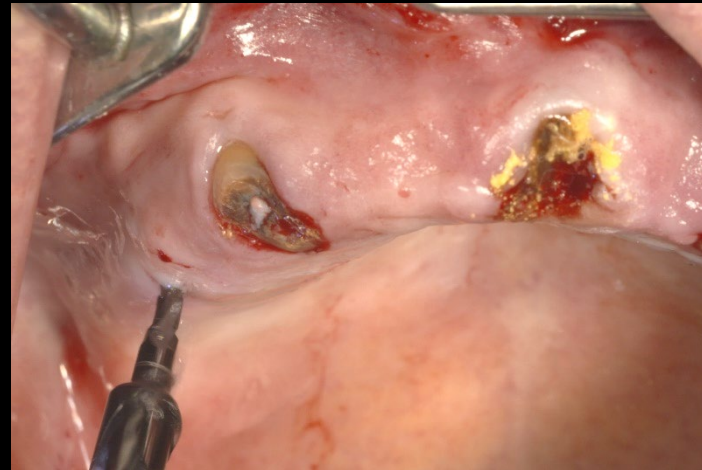
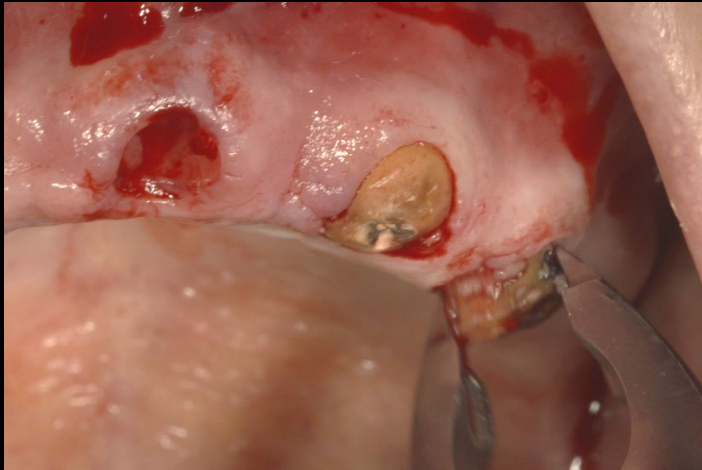
#22



#25

## Similar case 1

## Full arch Rehabilitation on Maxilla

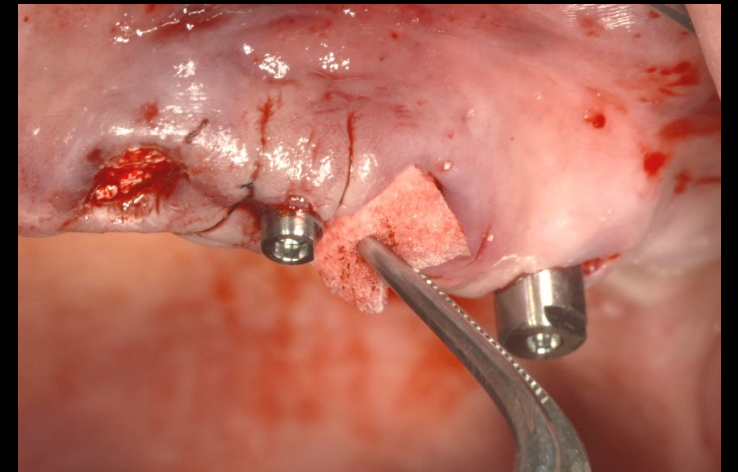
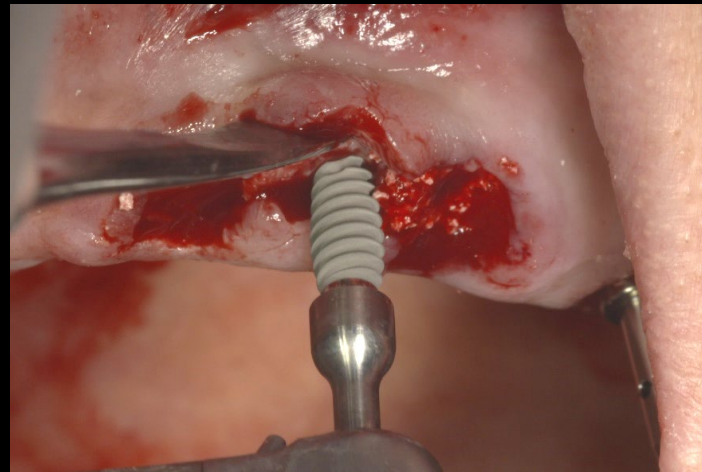
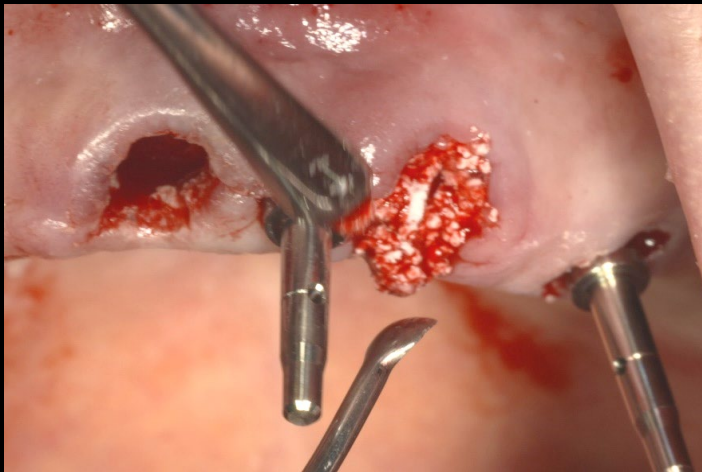


Surgery



## Similar case 1

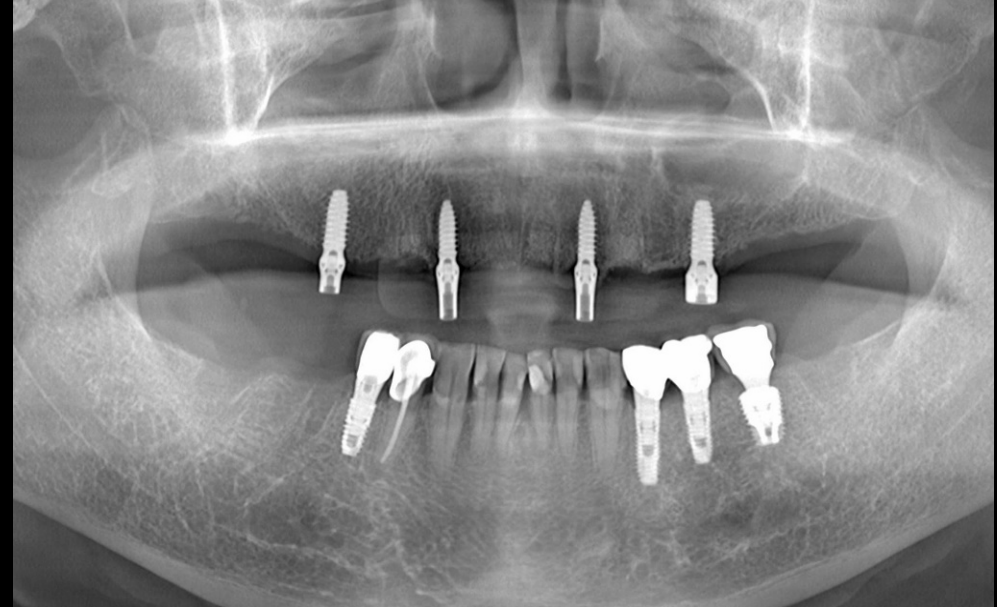
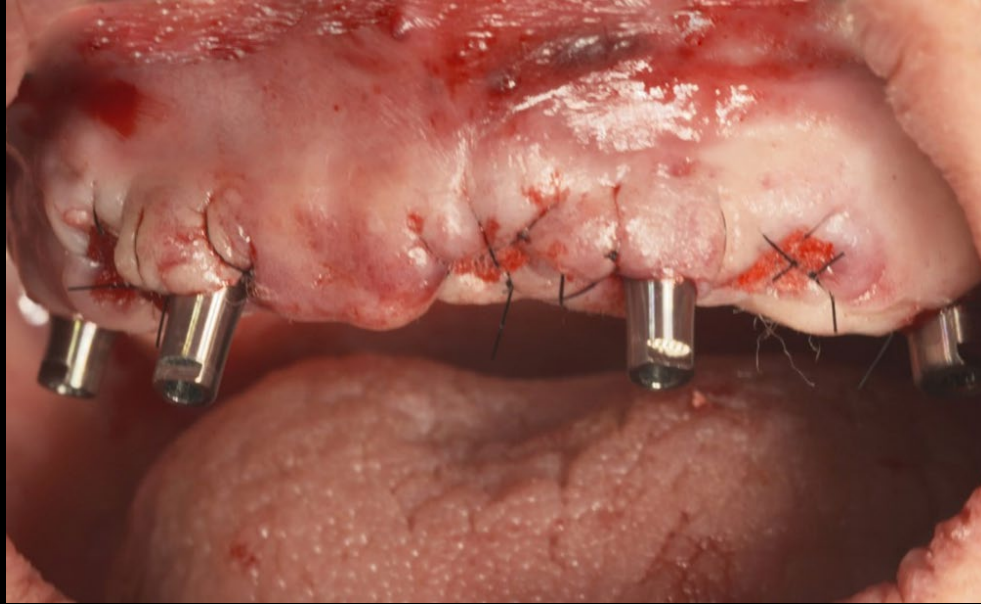
## Full arch Rehabilitation on Maxilla



Surgery (NTI 383509)

## Similar case 1

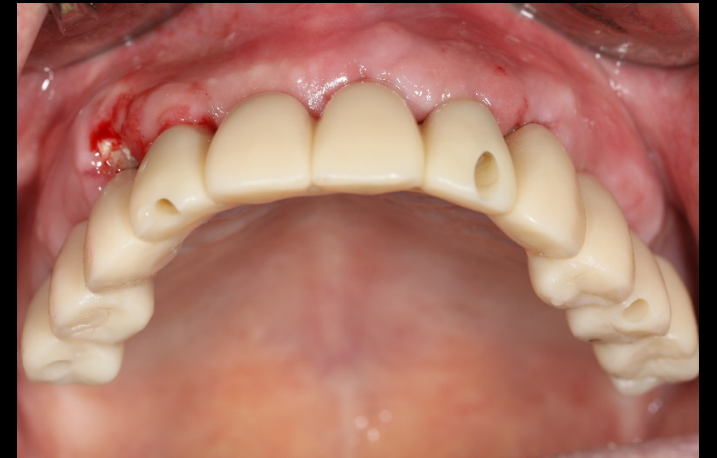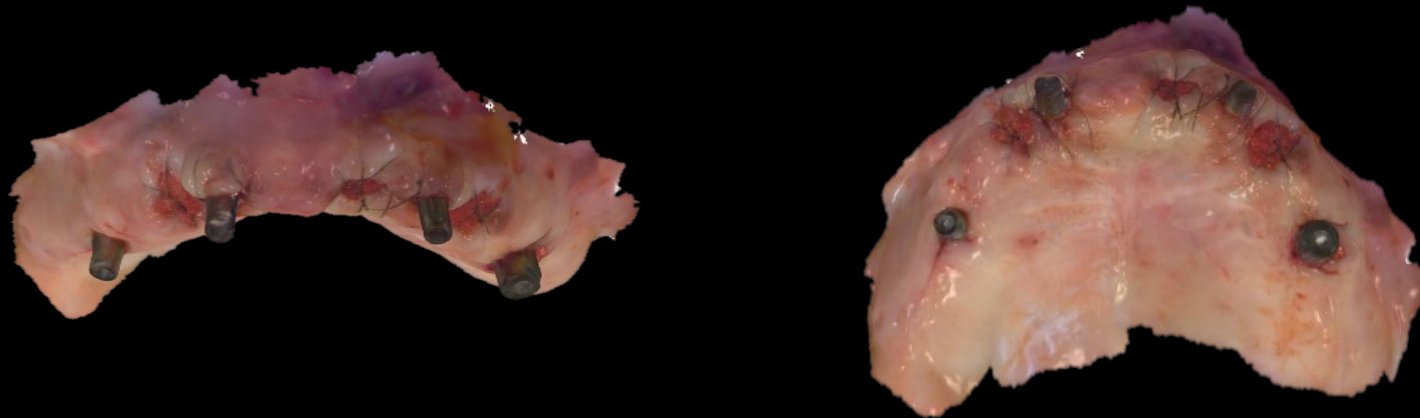
## Full arch Rehabilitation on Maxilla



Post-op

## Similar case 1

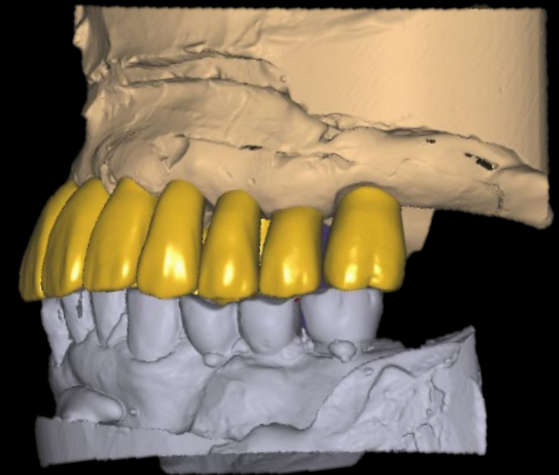
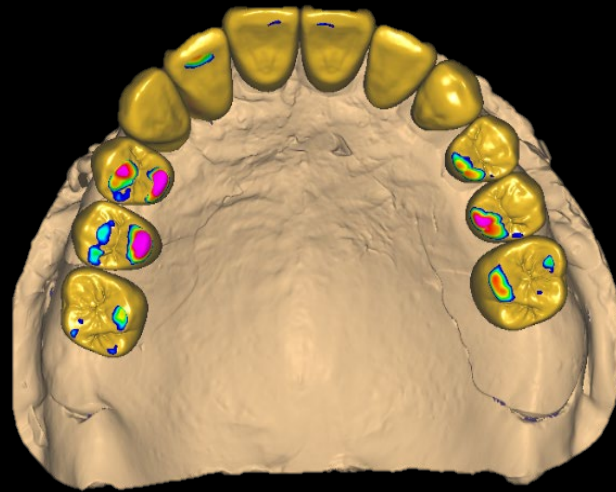
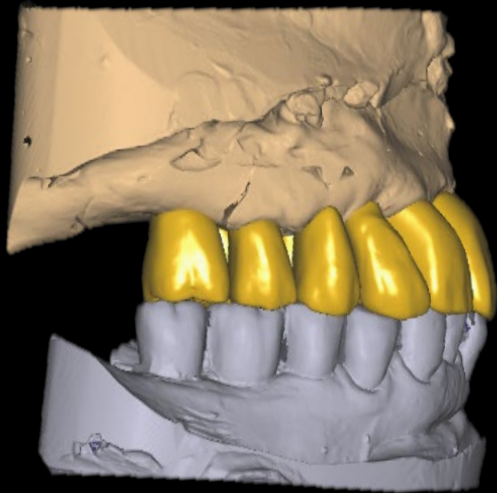
## Full arch Rehabilitation on Maxilla



Intra-oral Scan / Temporary restoration

## Similar case 1

## Full arch Rehabilitation on Maxilla

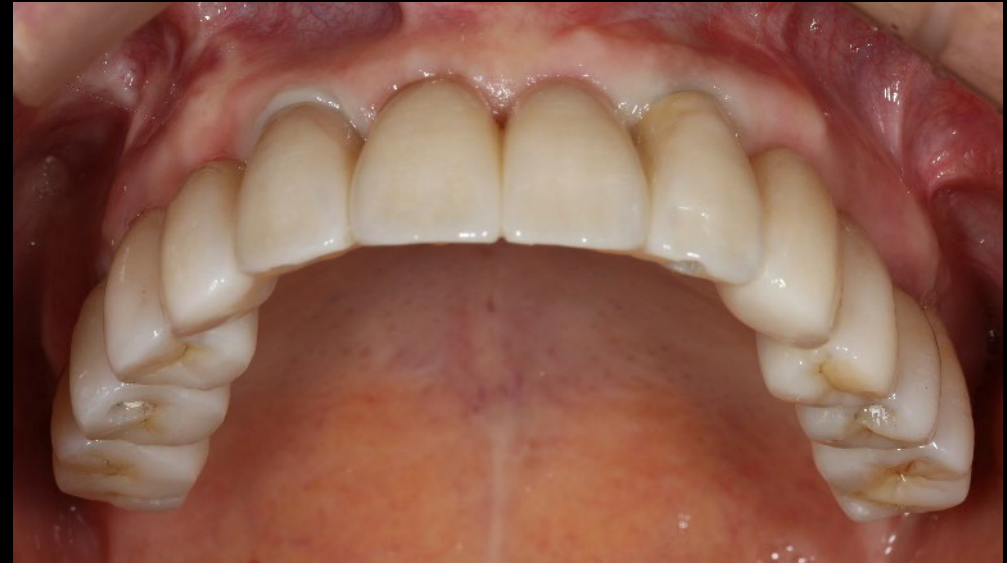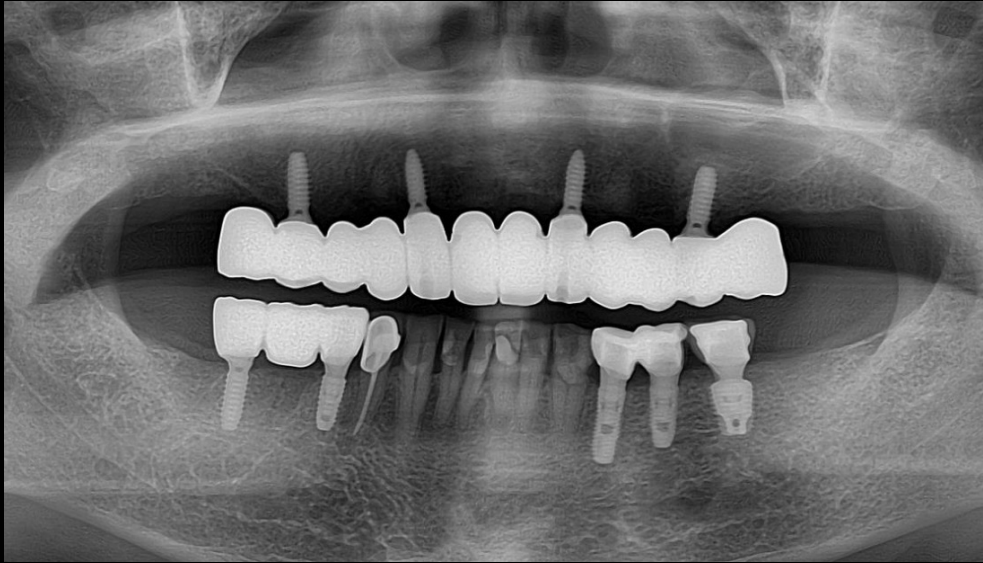


CAD design (Final Prosthesis)



## Similar case 1

## Full arch Rehabilitation on Maxilla

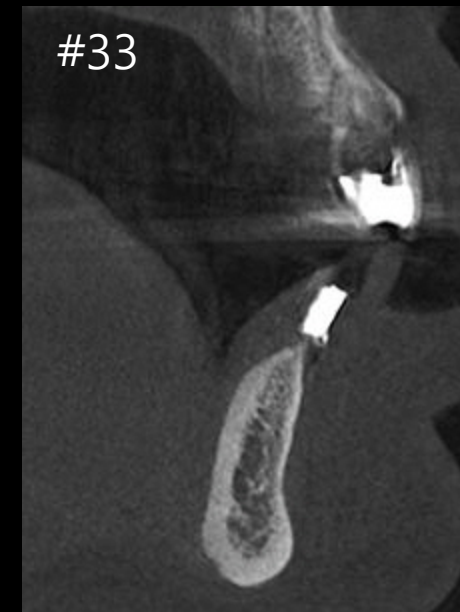
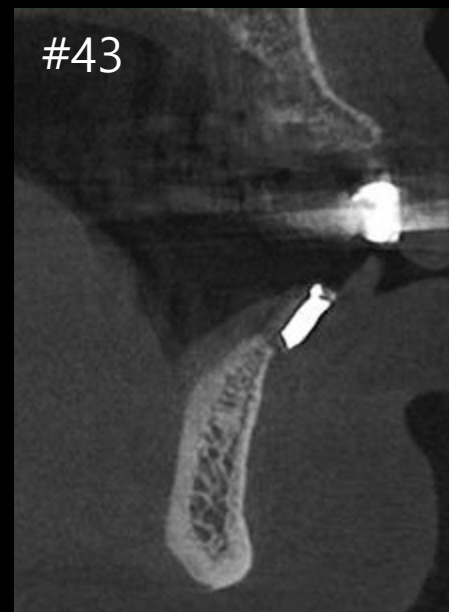
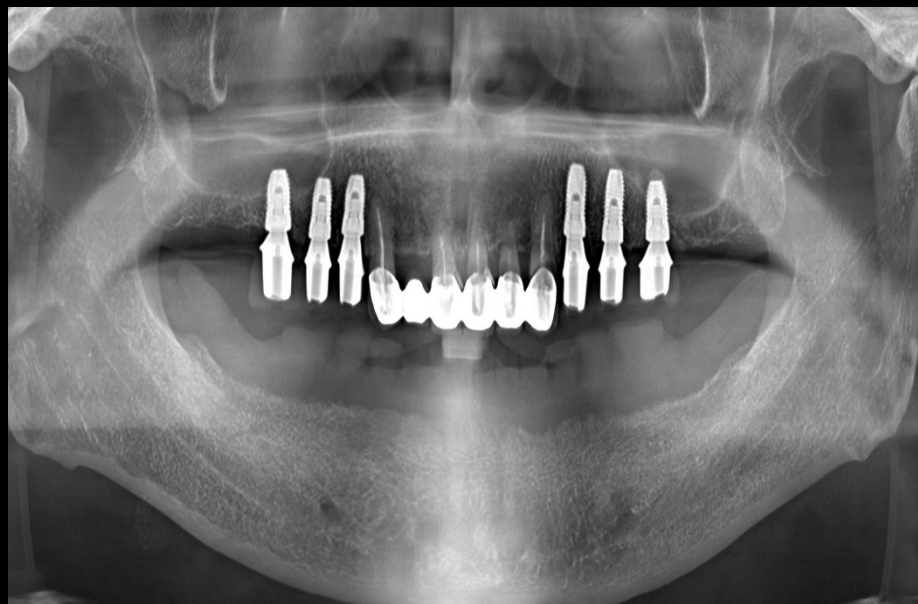


Final prosthesis



## Similar case 2

Simple implantation in Narrow ridge with bright Tissue Level

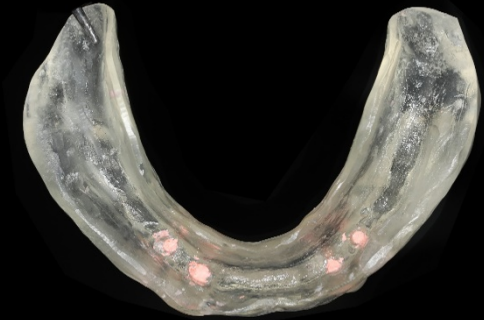
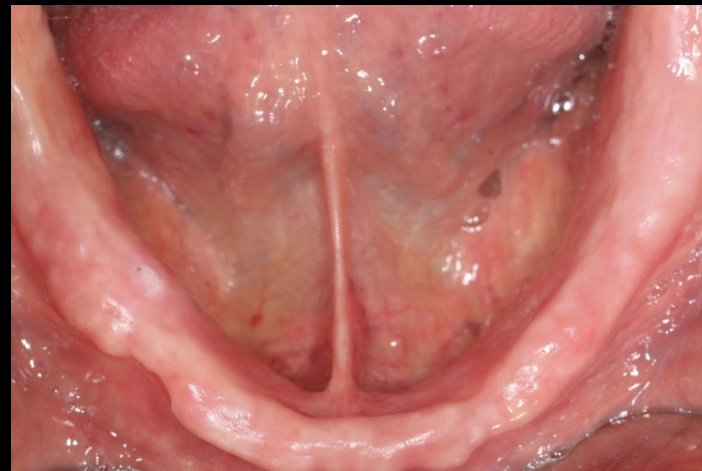
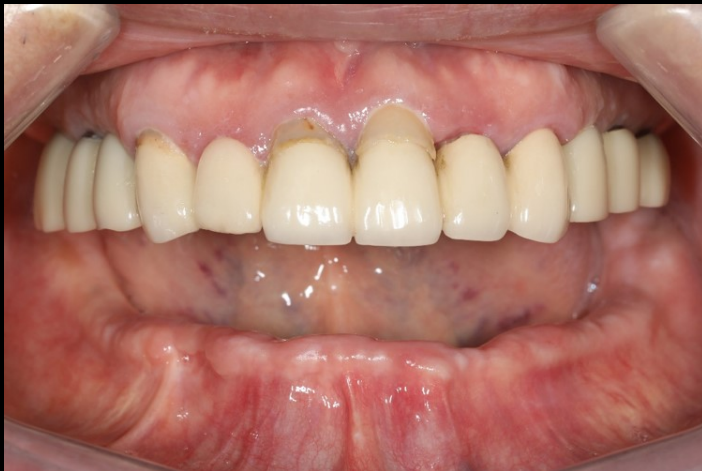
With Radiographic guide

Pre-op

## Similar case 2

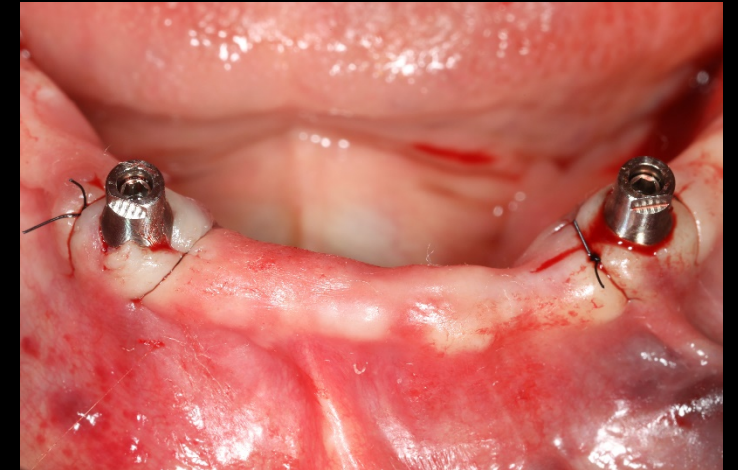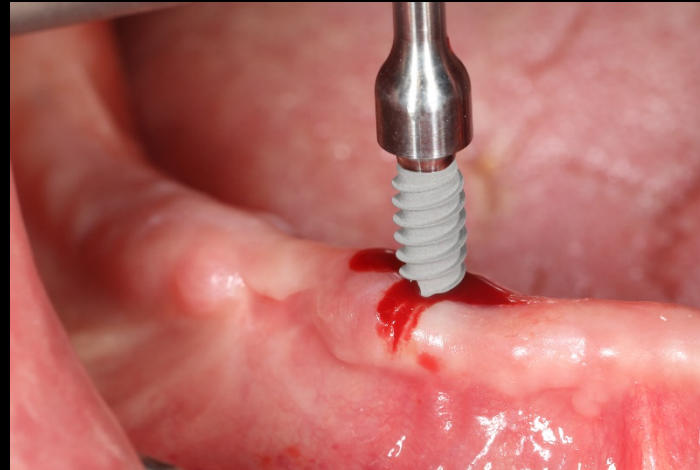
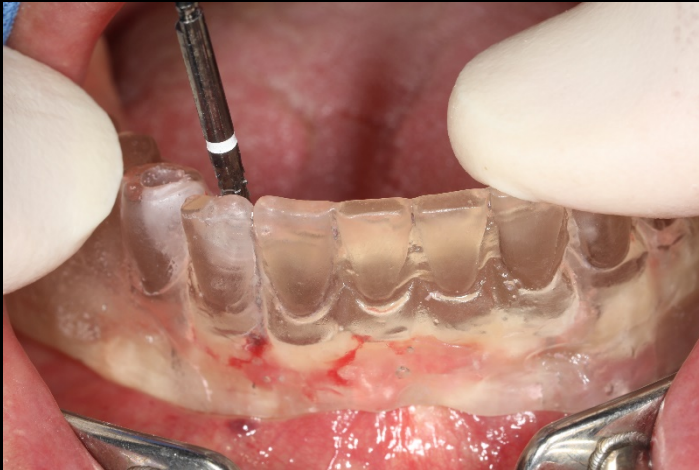Simple implantation in Narrow ridge with bright Tissue Level



Pre-op / Radiographic stent (GP cone)

## Similar case 2

Simple implantation in Narrow ridge with bright Tissue Level

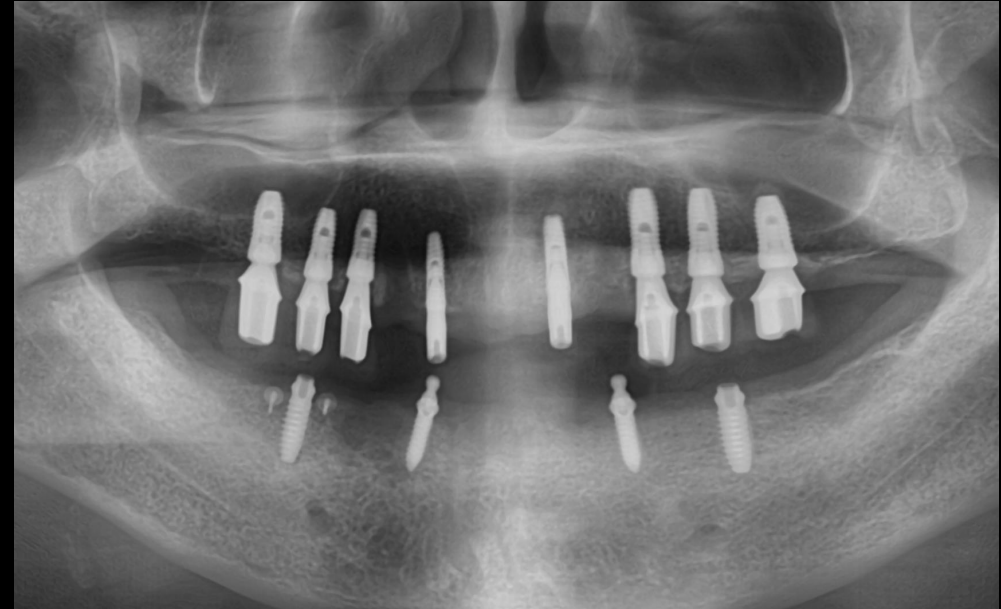
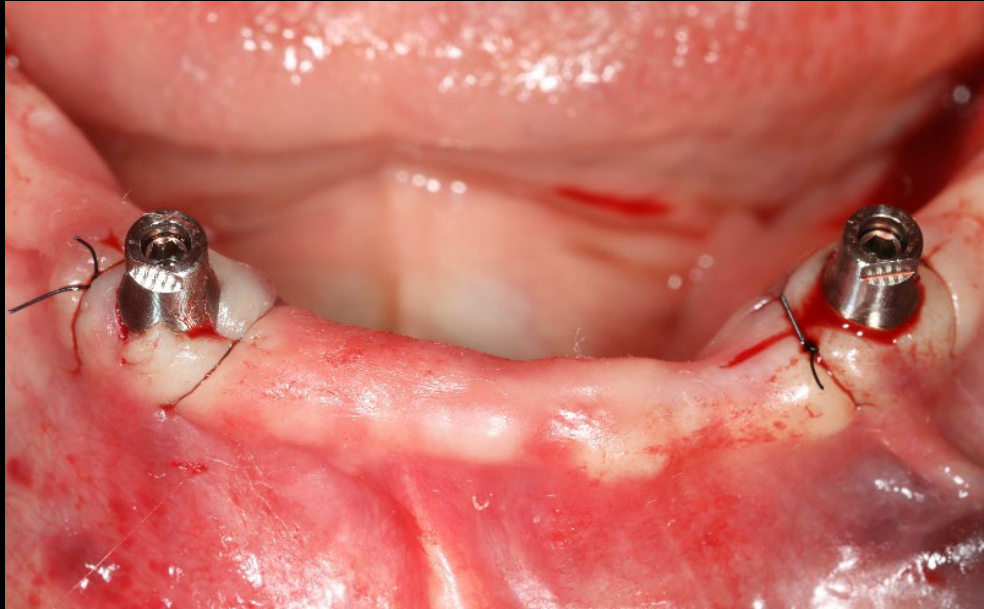

Surgery (NTI383009)



## Similar case 2

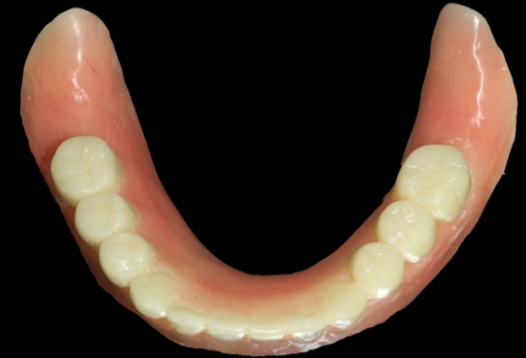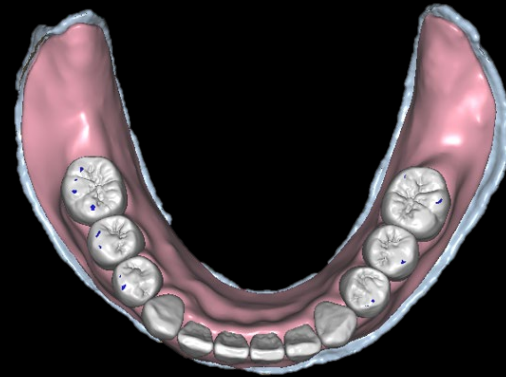
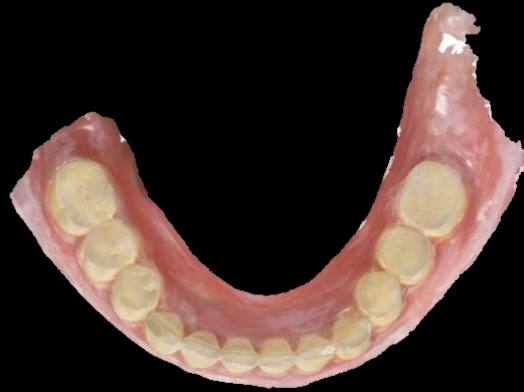Simple implantation in Narrow ridge with bright Tissue Level



Post-op

## Similar case 2

Simple implantation in Narrow ridge with bright Tissue Level

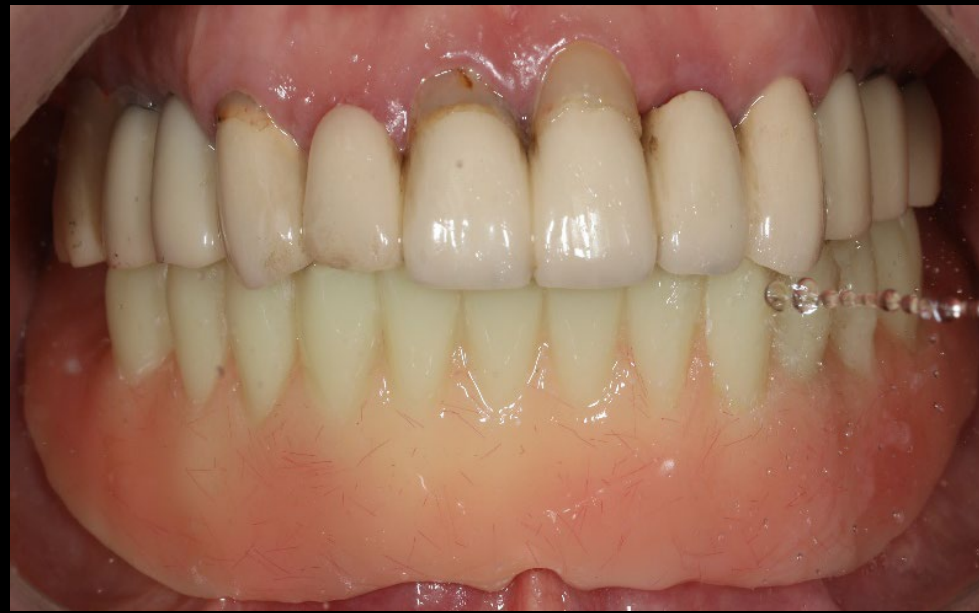
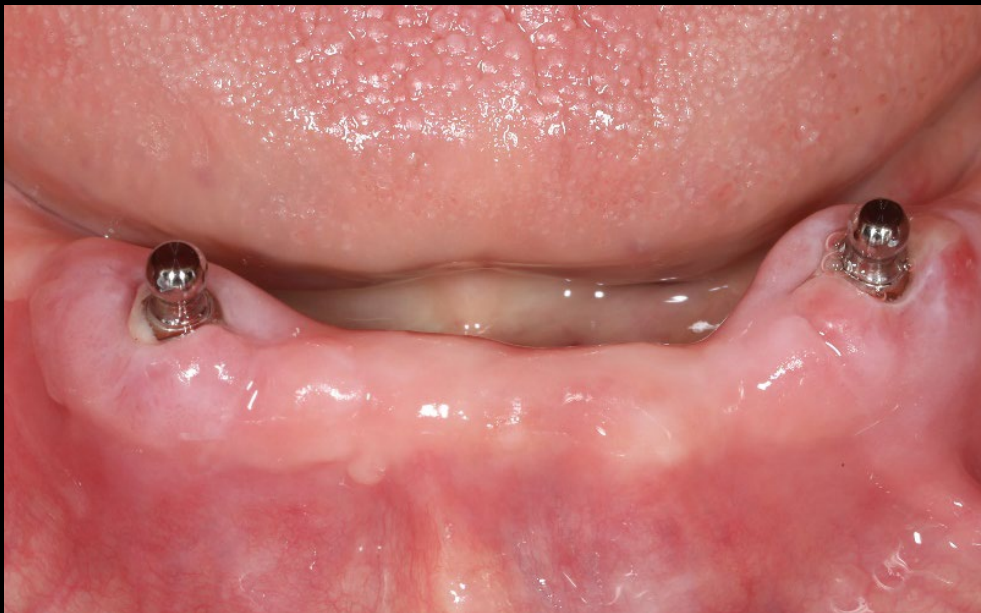
Intra-oral scanning / Denture design / 3D printing denture



## Similar case 2

Simple implantation in Narrow ridge with bright Tissue Level



Ball abutment / Temporary denture