



Surgergy

Dr. Dong-Wook Chang

2020.10.23 (Fri.)



[Case Preview]

Digital Guide Implant placement
with GBR & Ridge Splitting on Anterior area

Patient Information

Age : 72

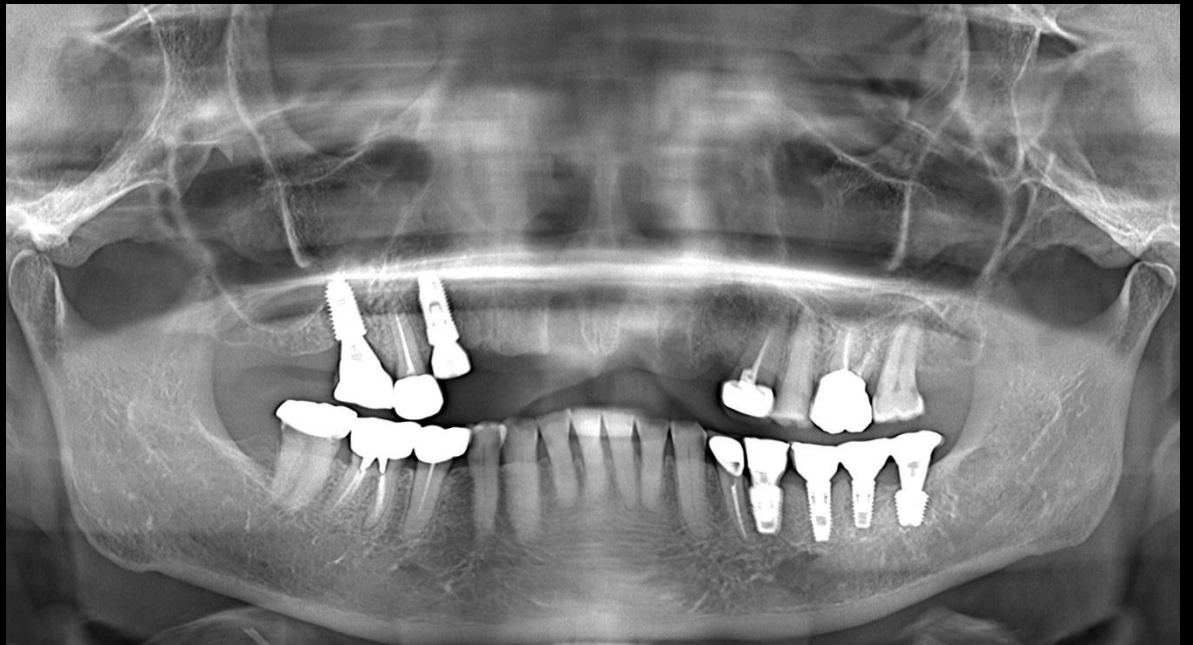
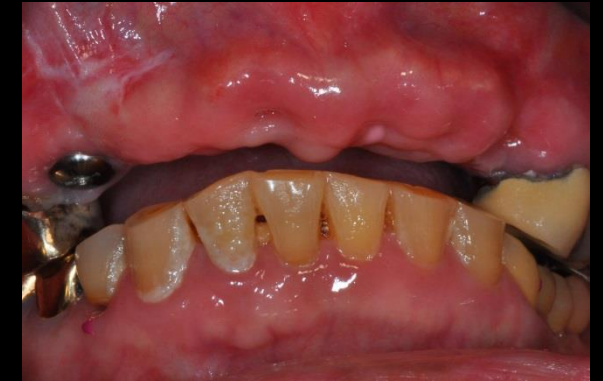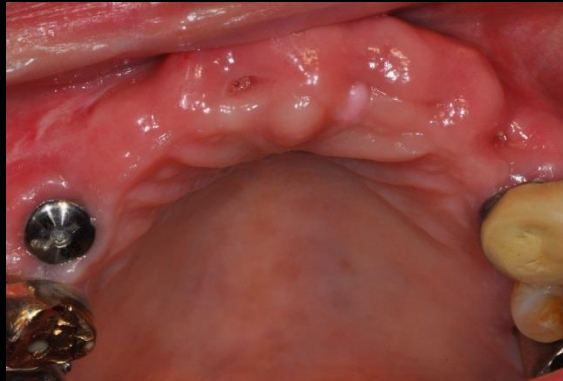
Sex : Female

Chief Complaint

: My teeth and old prosthesis are moving.

Past Dental History

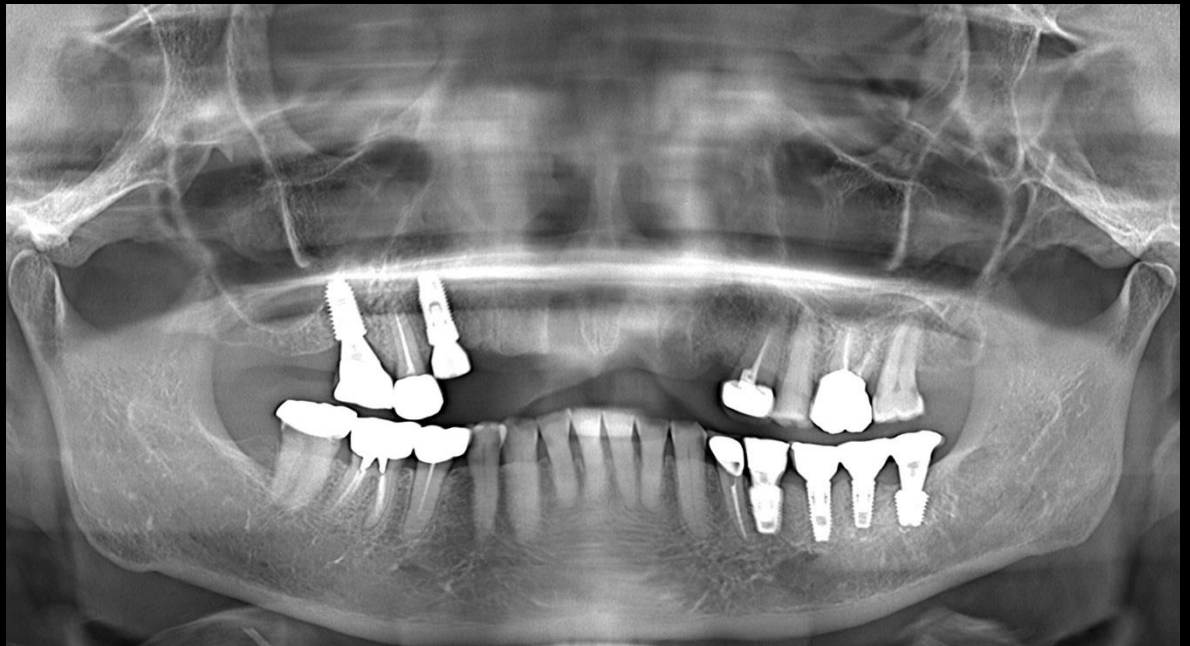
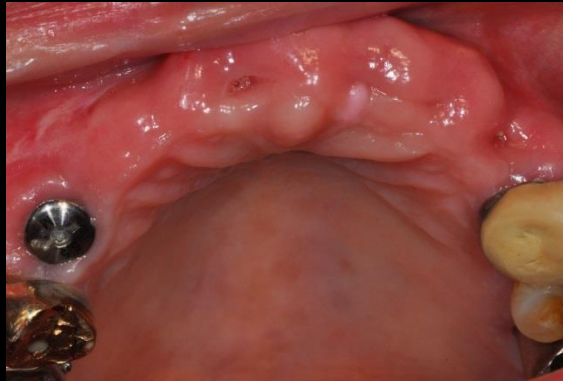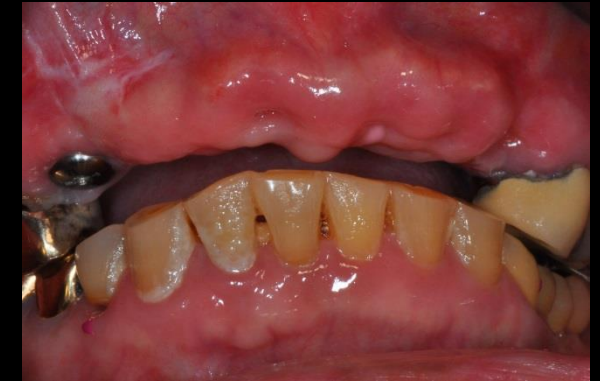
- #13-23 Tooth Extraction (2 months ago)



Patient Information

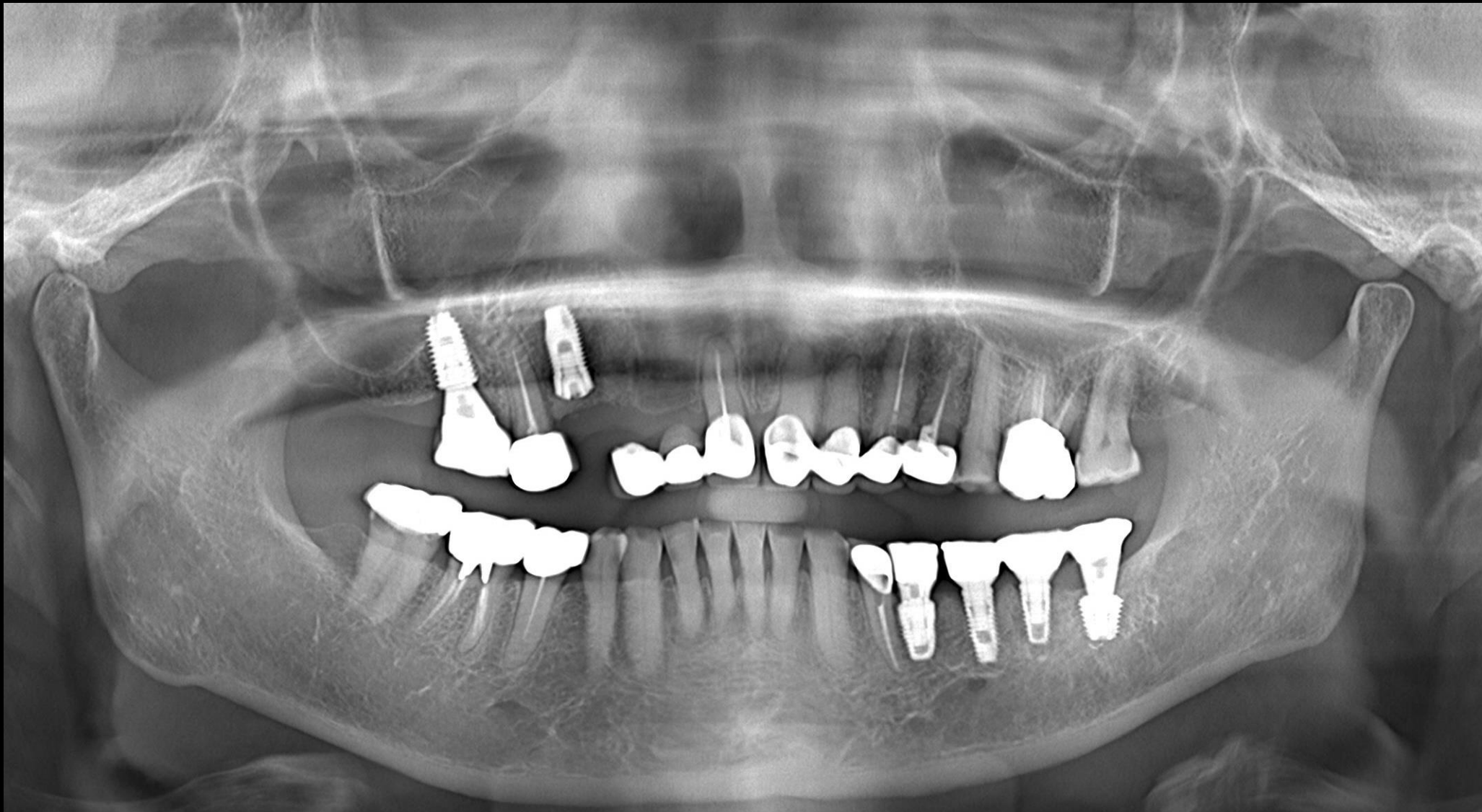
Surgery Plan

- #12, 13, 21, 23 Implant placement using Digital Guide
- #12-23 GBR : DUK Technique
- #12-23 Ridge Splitting using RS Kit



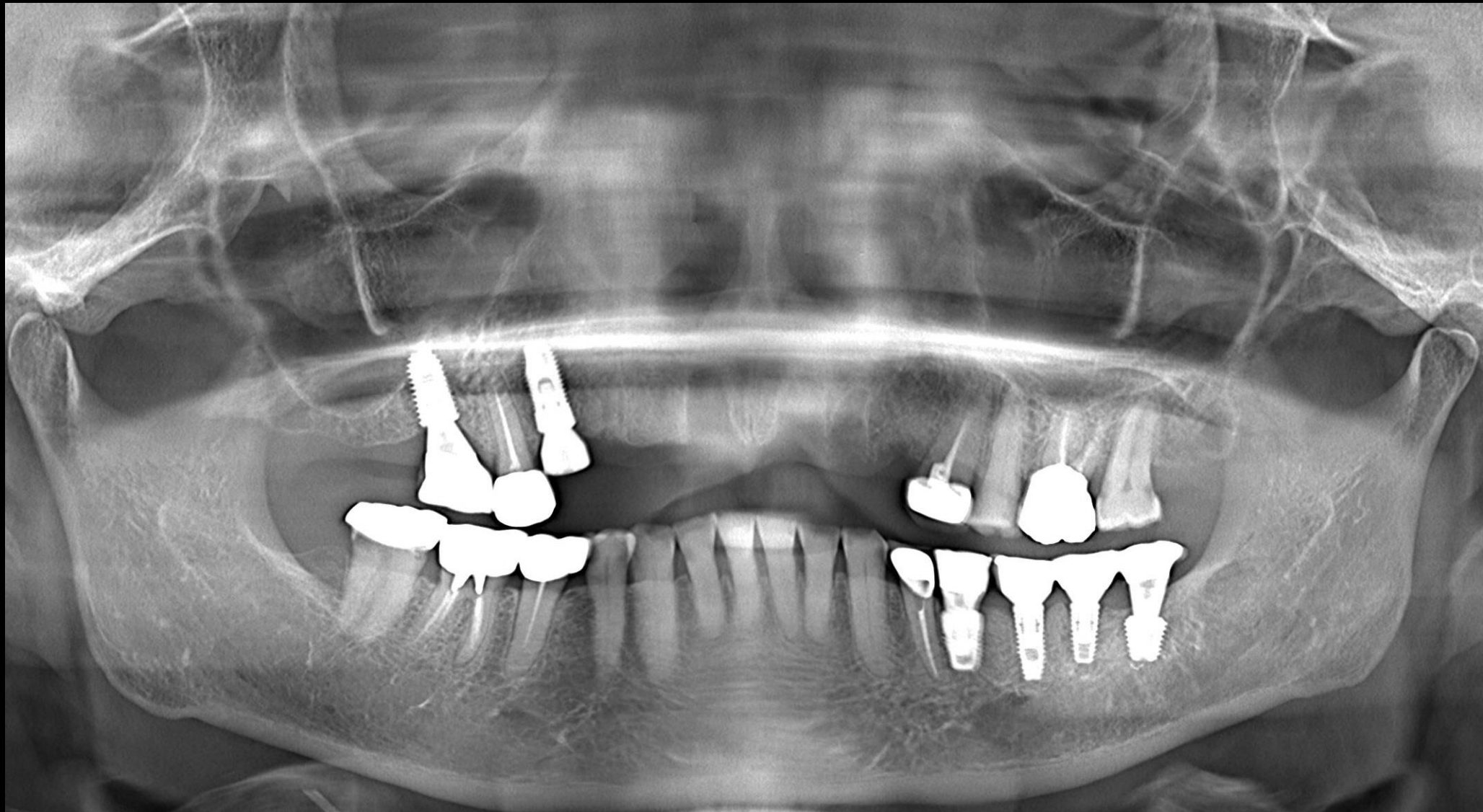
Pt. COJ (72/Female)

Oral exam (2020-08-26)



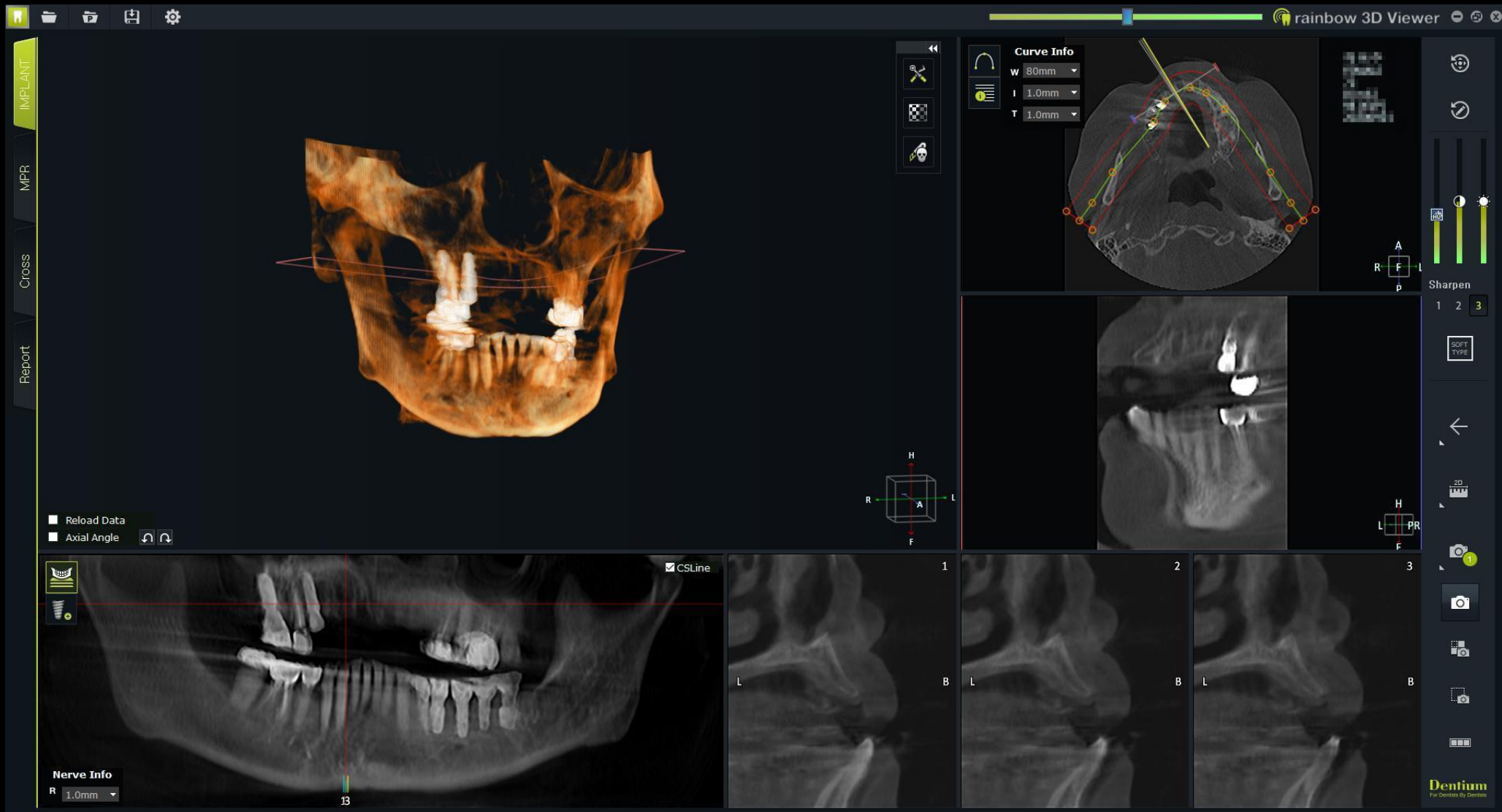
Pt. COJ (72/Female)

Pre-op (2020-09-21)



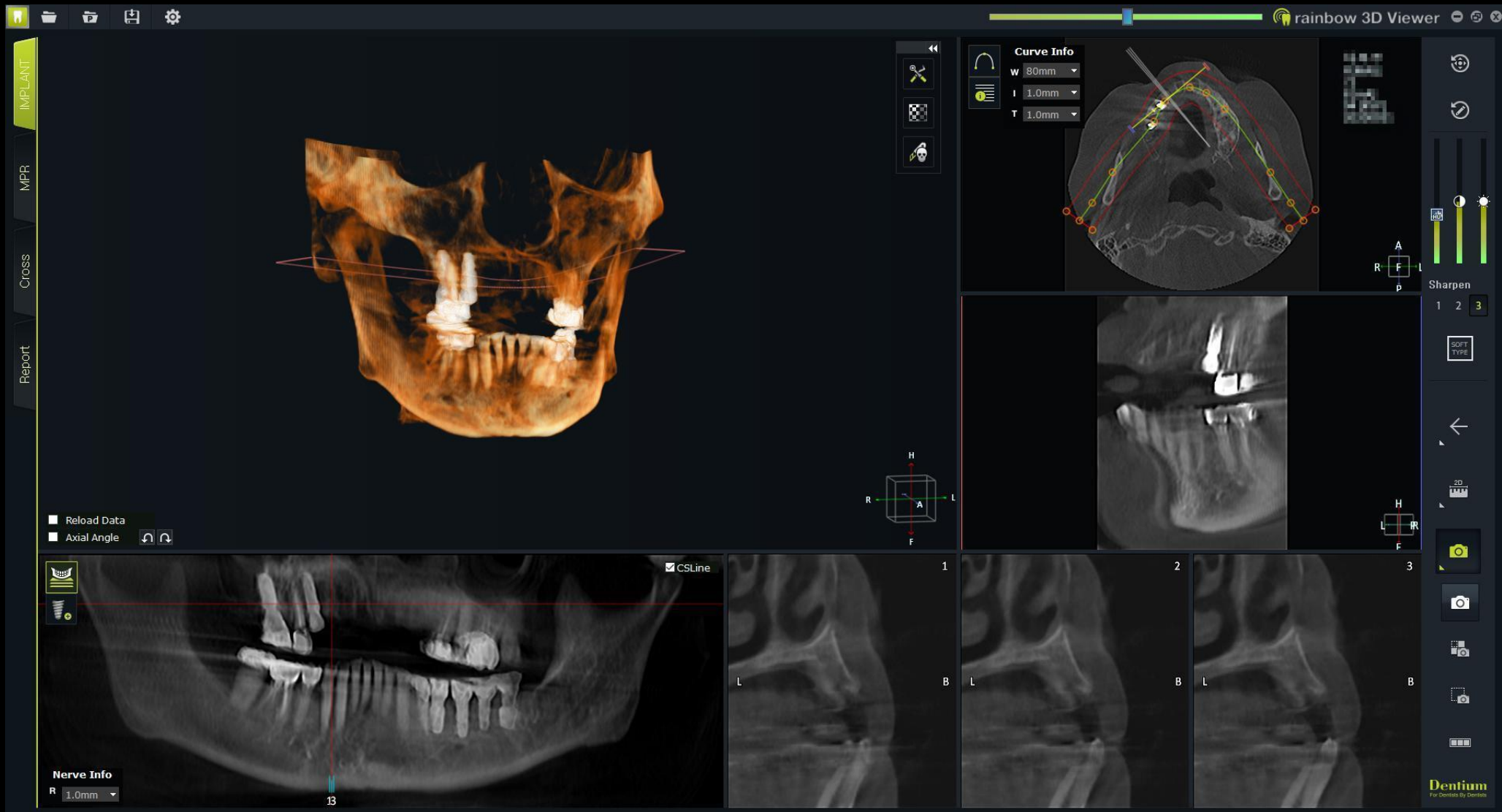
Pt. COJ (72/Female)

#12 Pre-op (2020-09-21)



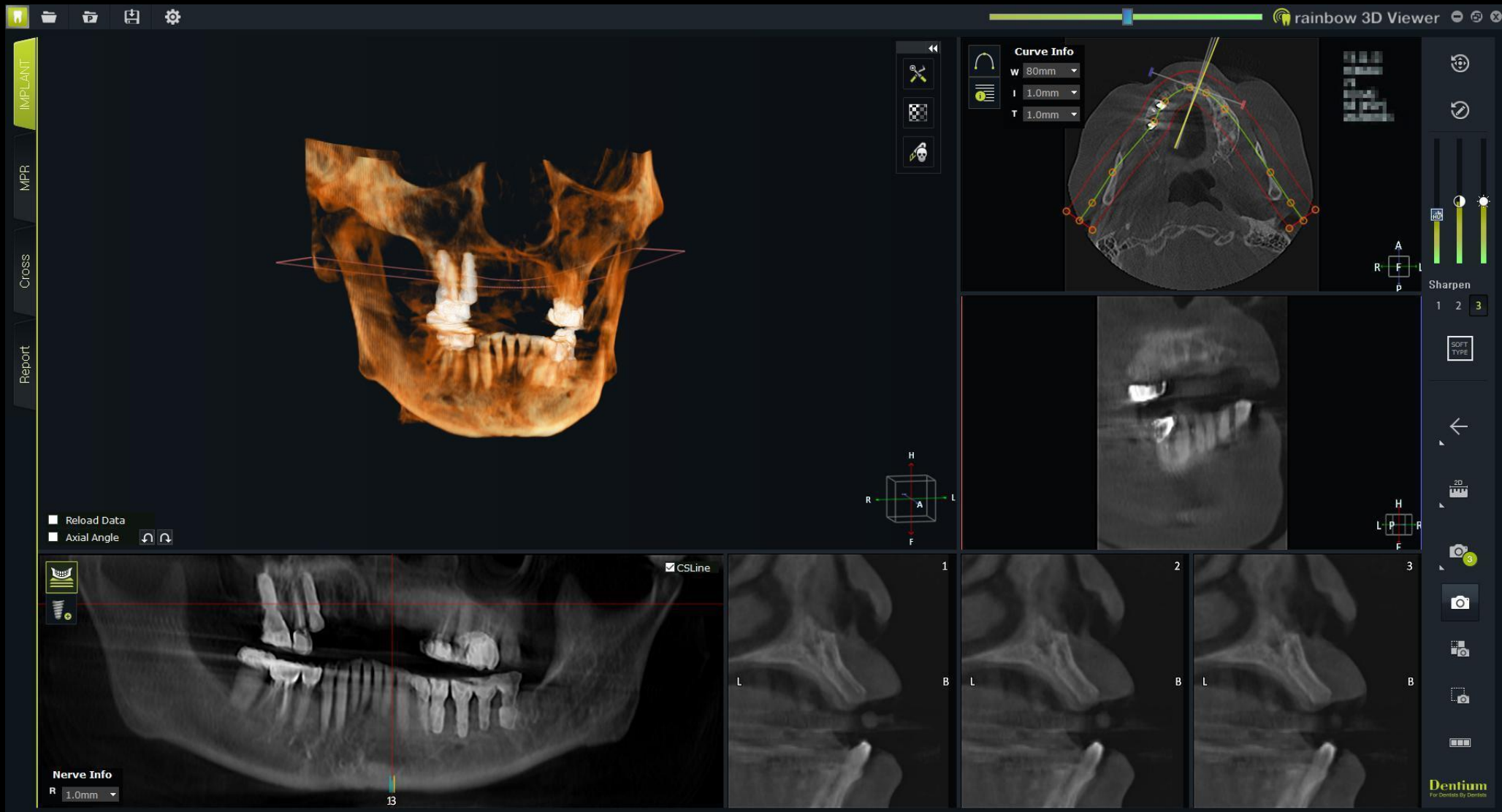
Pt. COJ (72/Female)

#13 Pre-op (2020-09-21)



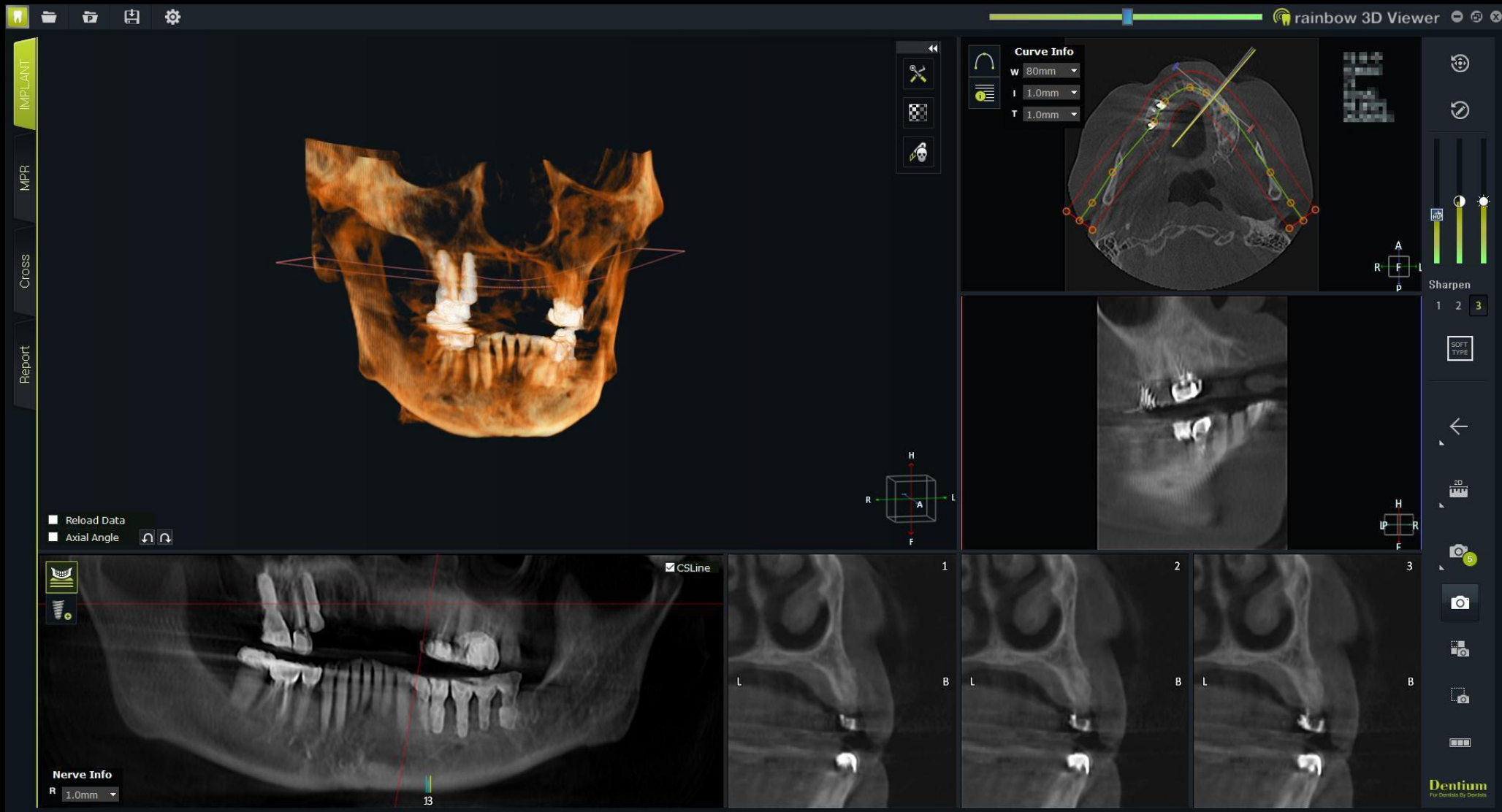
Pt. COJ (72/Female)

#21 Pre-op (2020-09-21)

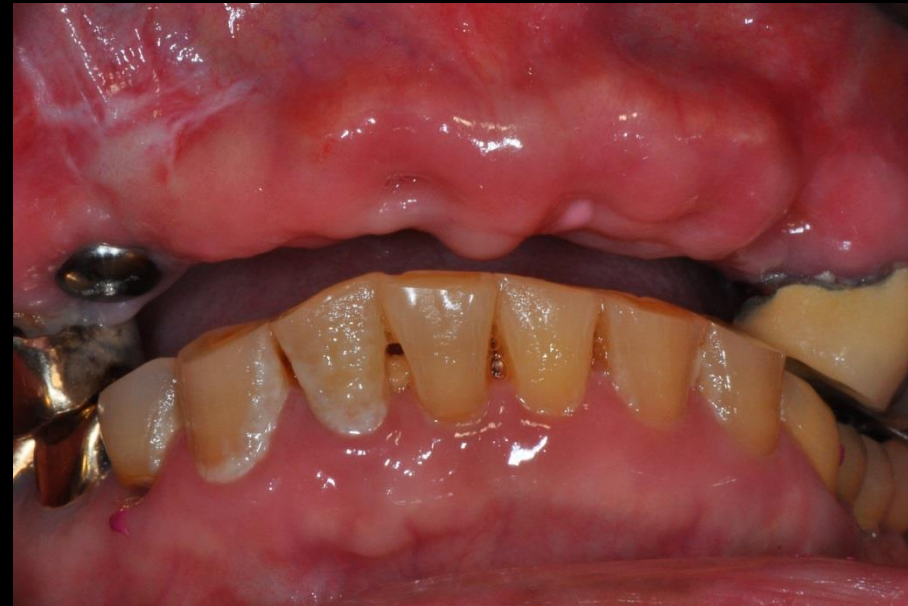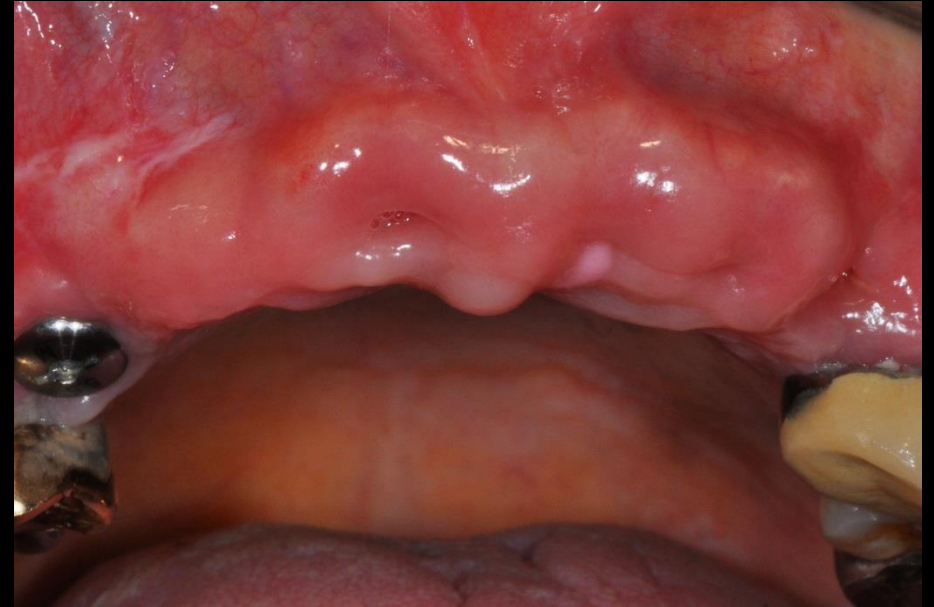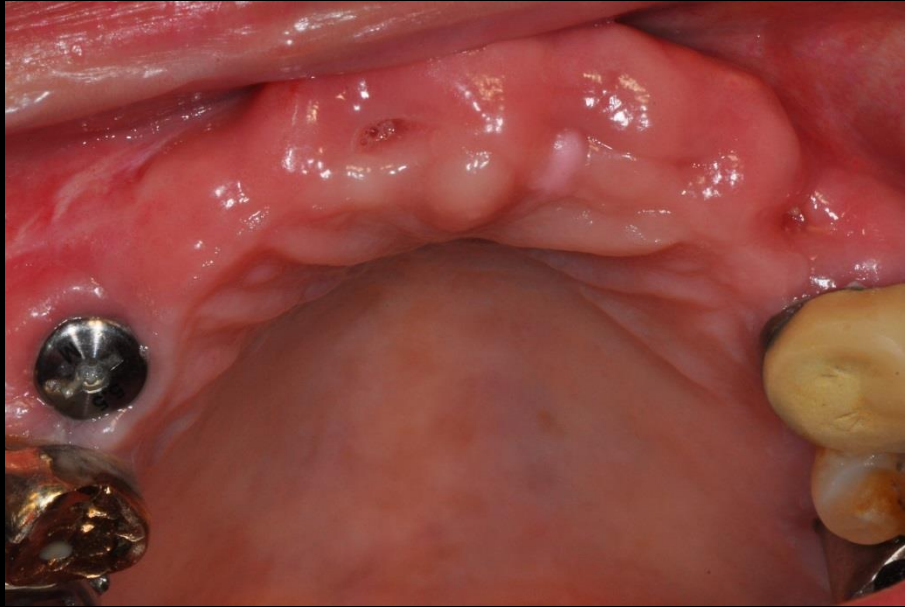


Pt. COJ (72/Female)

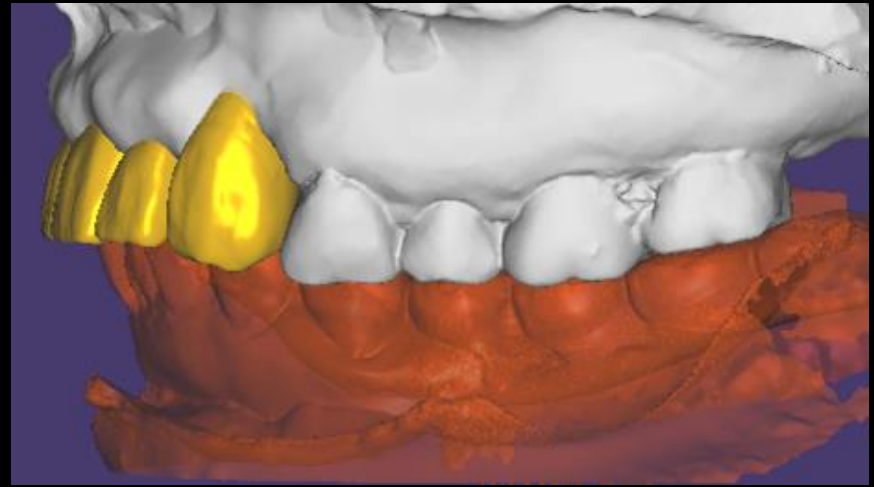
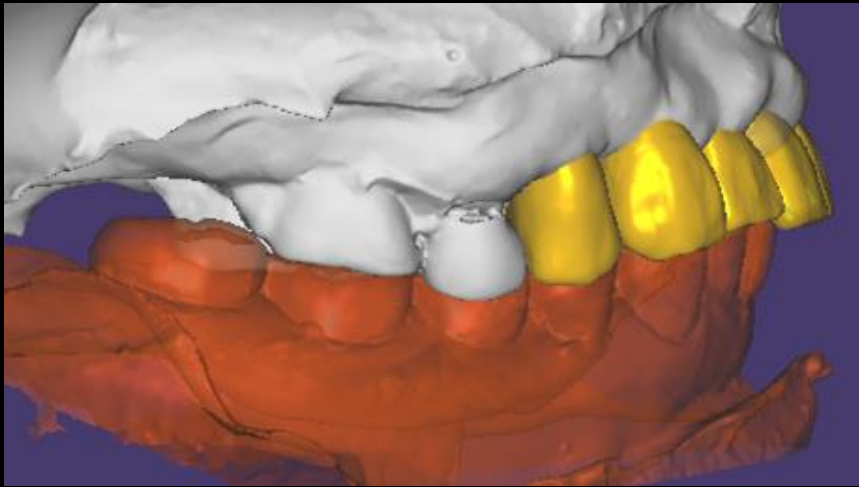
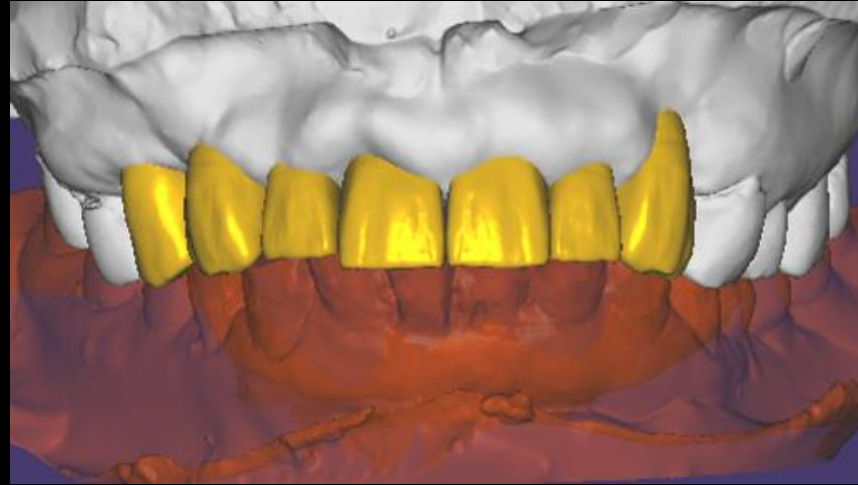
#23 Pre-op (2020-09-21)



Initial Photo

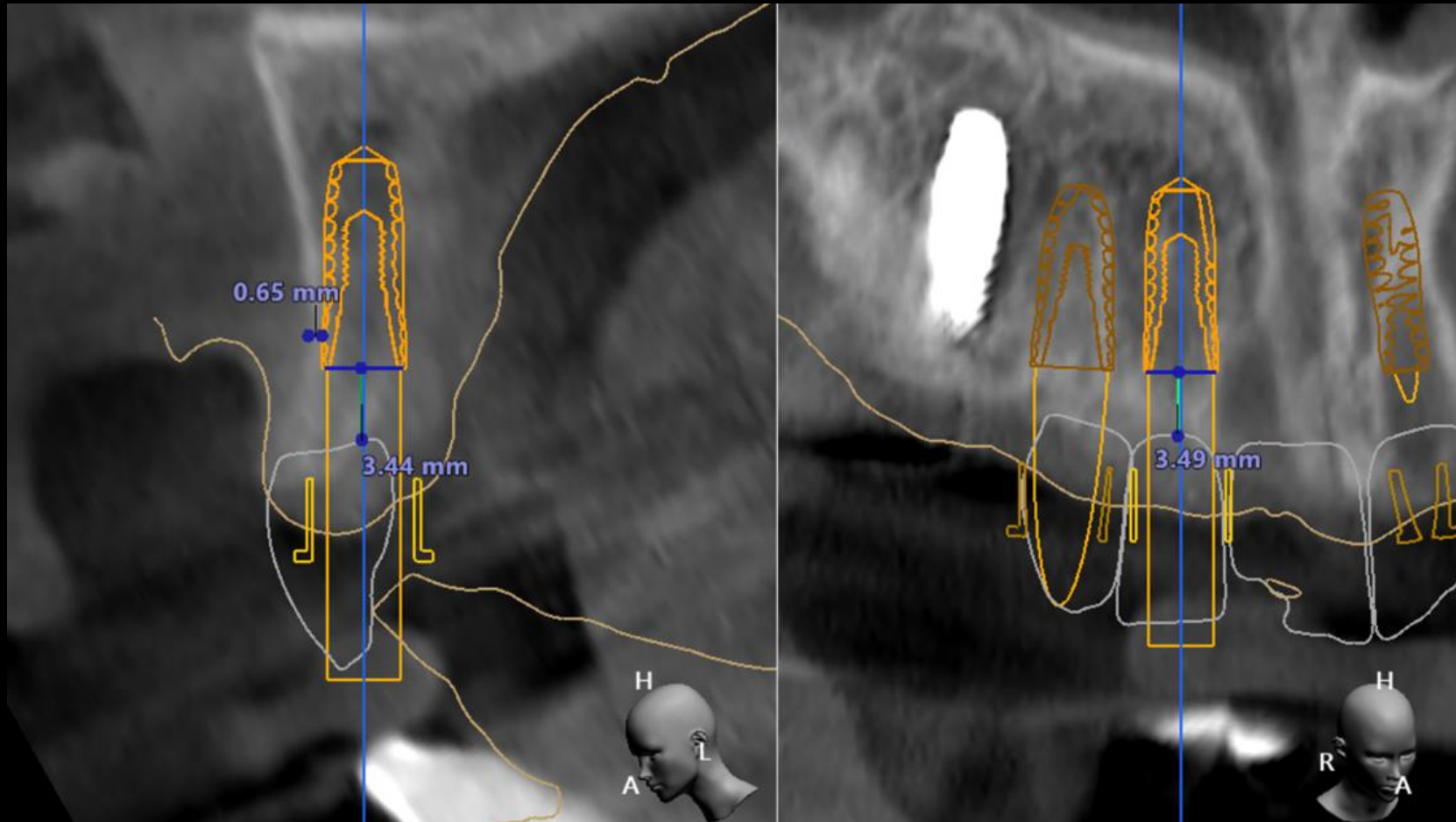


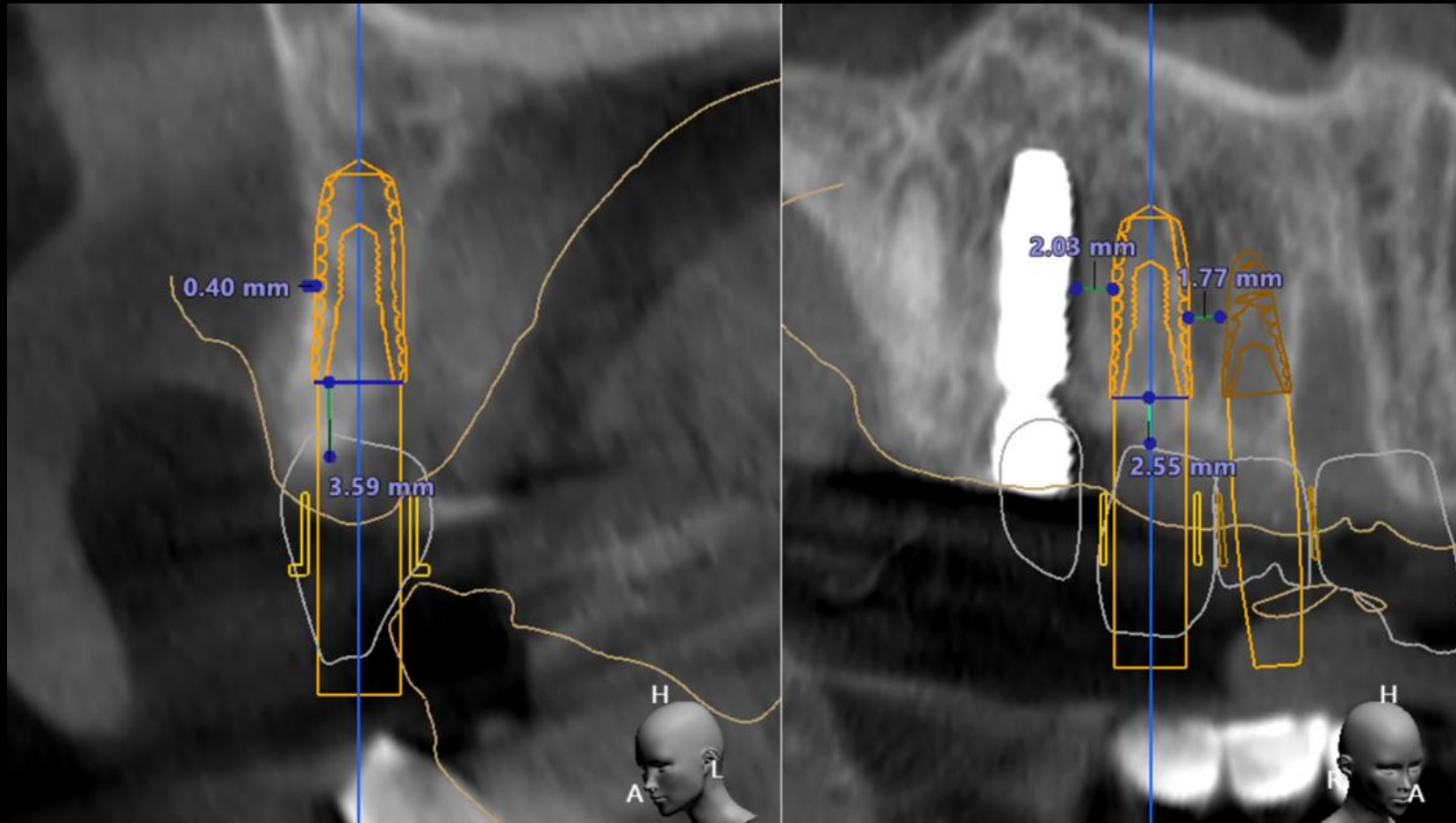
Virtual Set up



Implant Planning

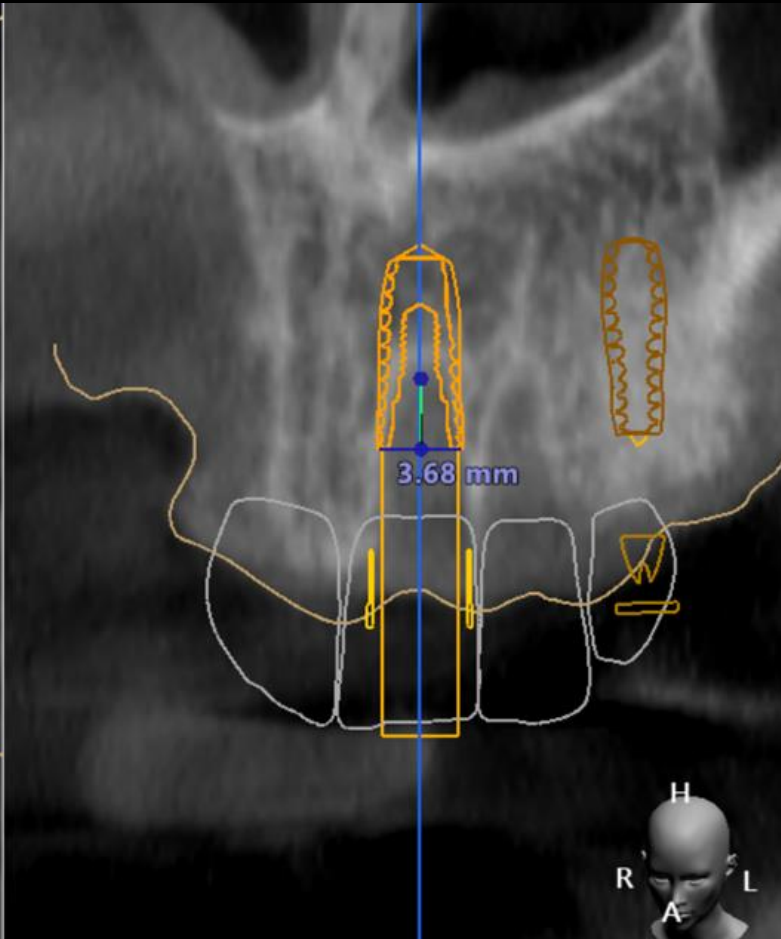
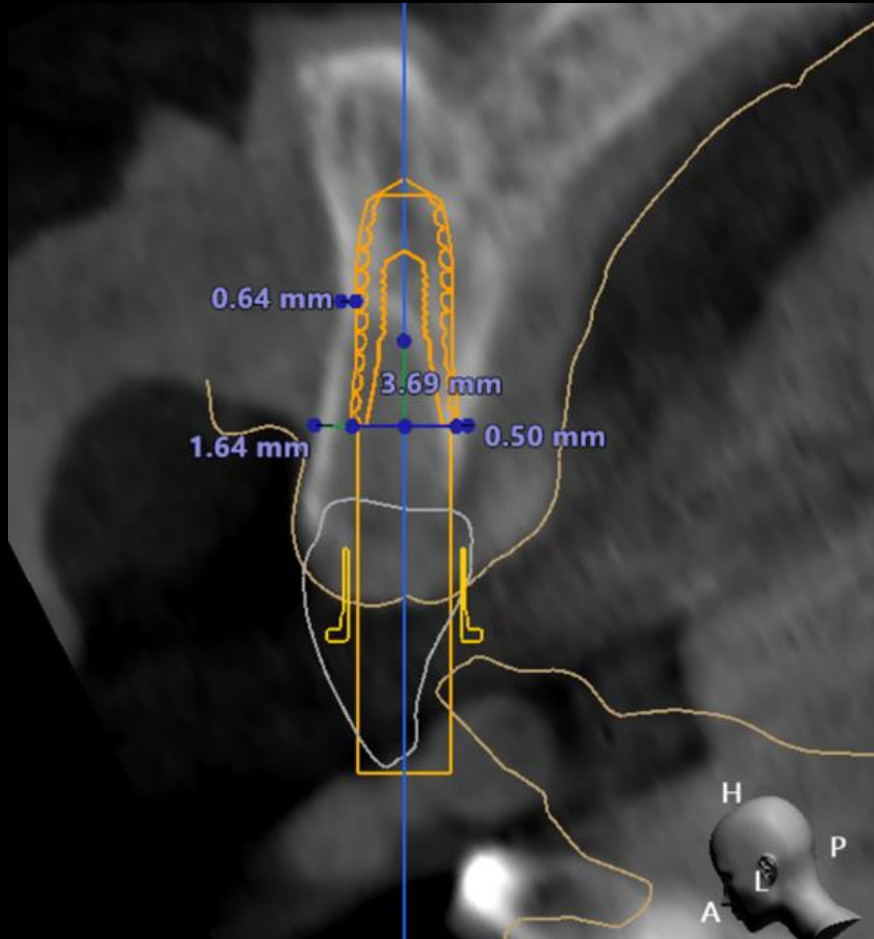
#12 (3610)





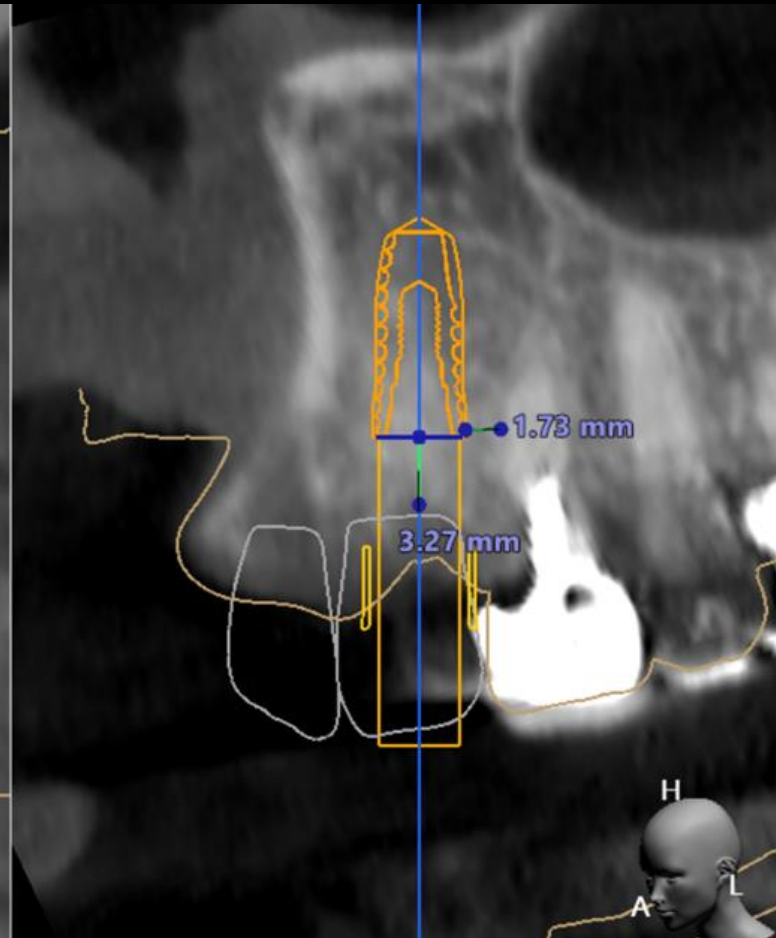
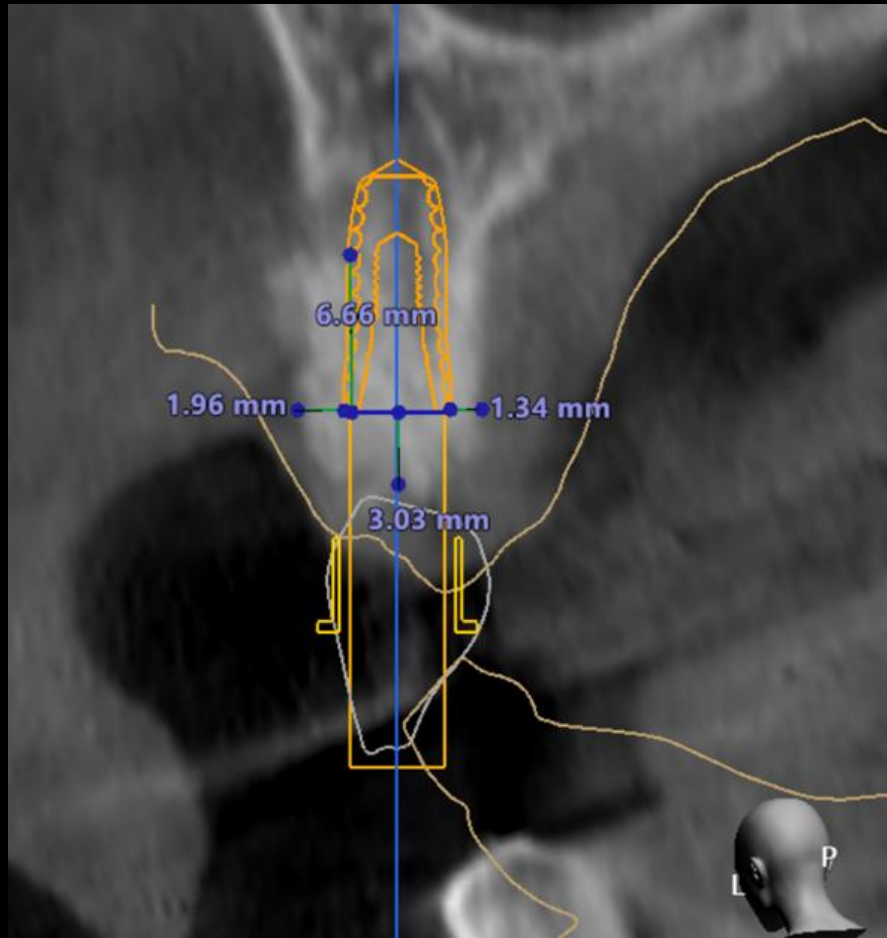
Implant Planning

#21 (4010)

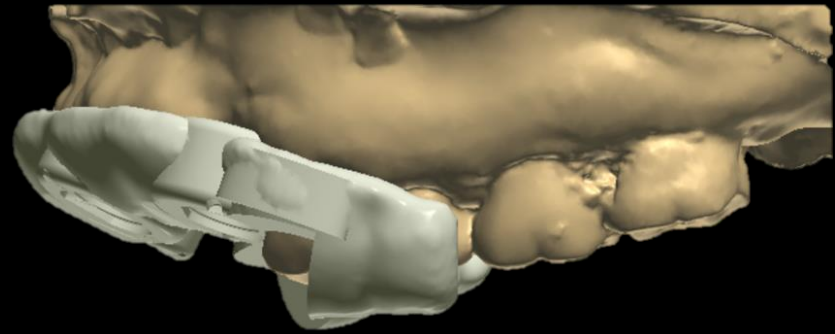
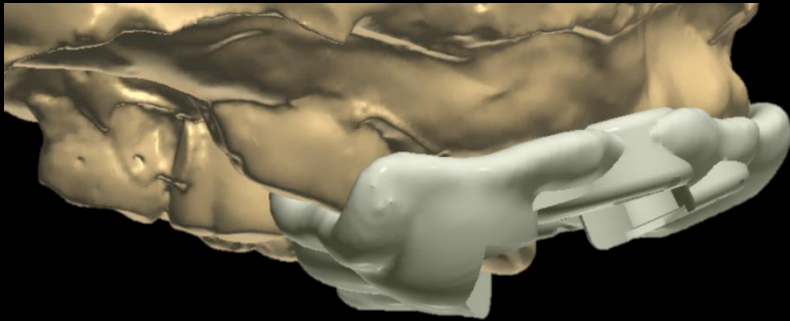
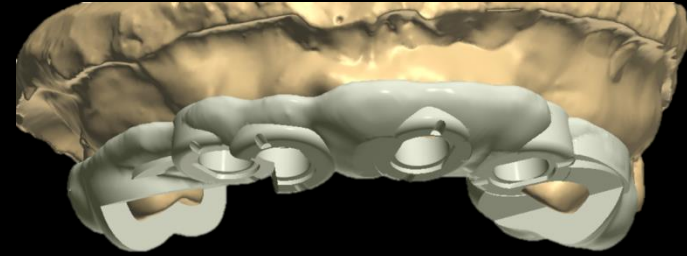
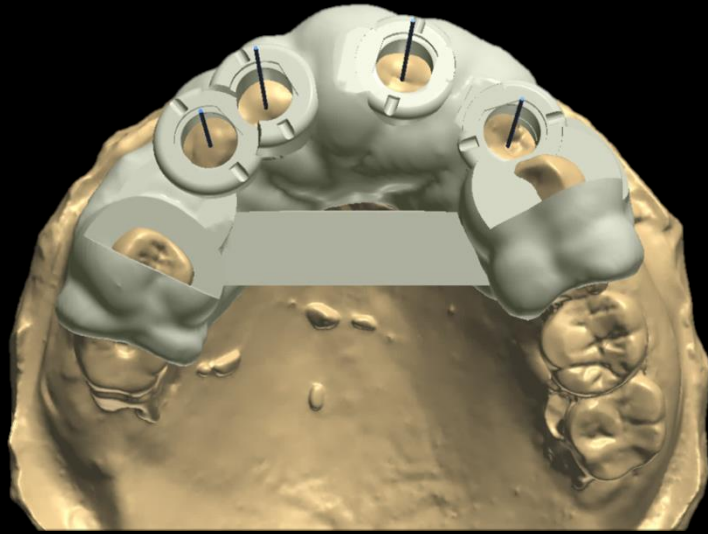


Implant Planning

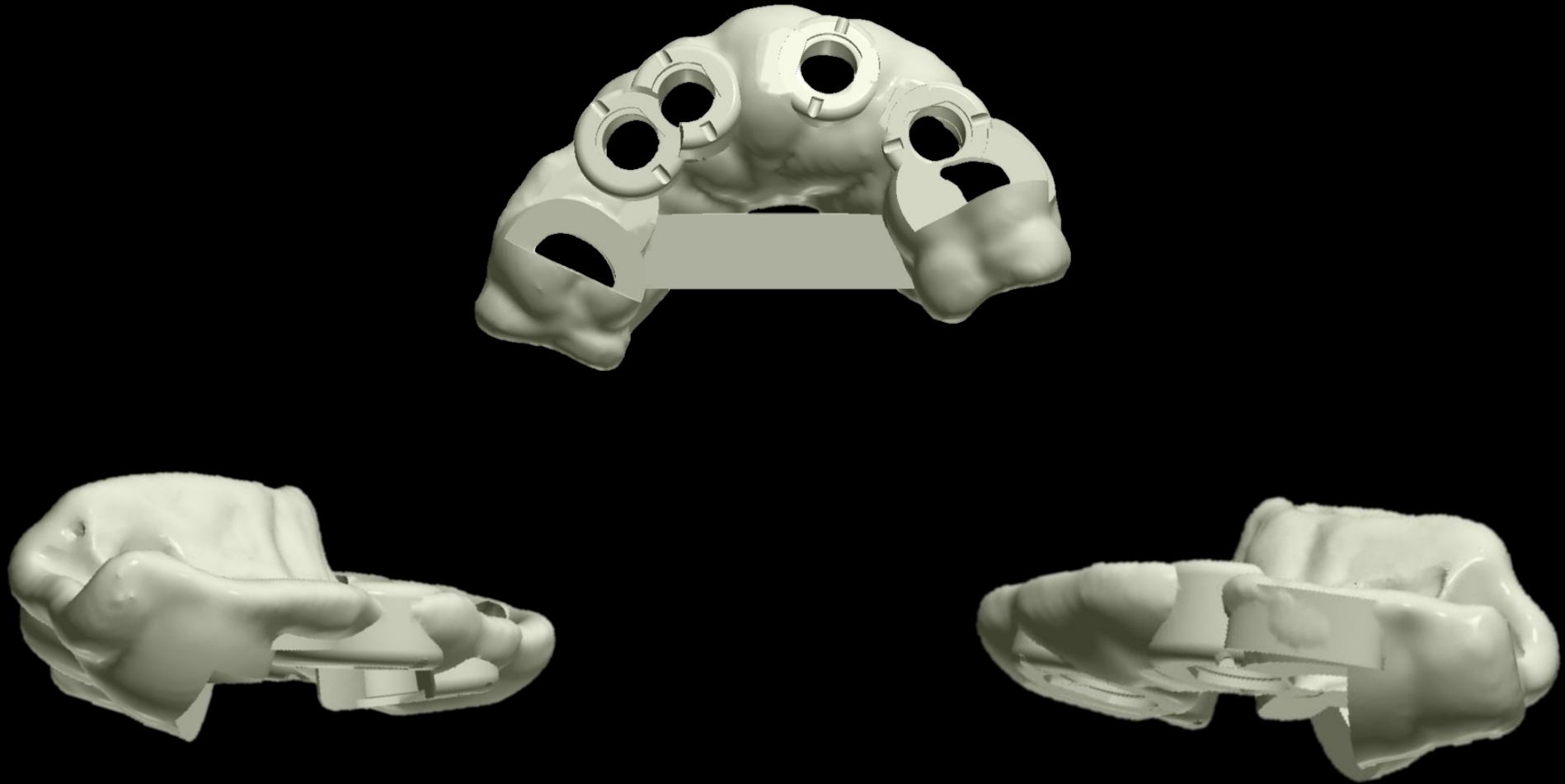
#23 (4010)



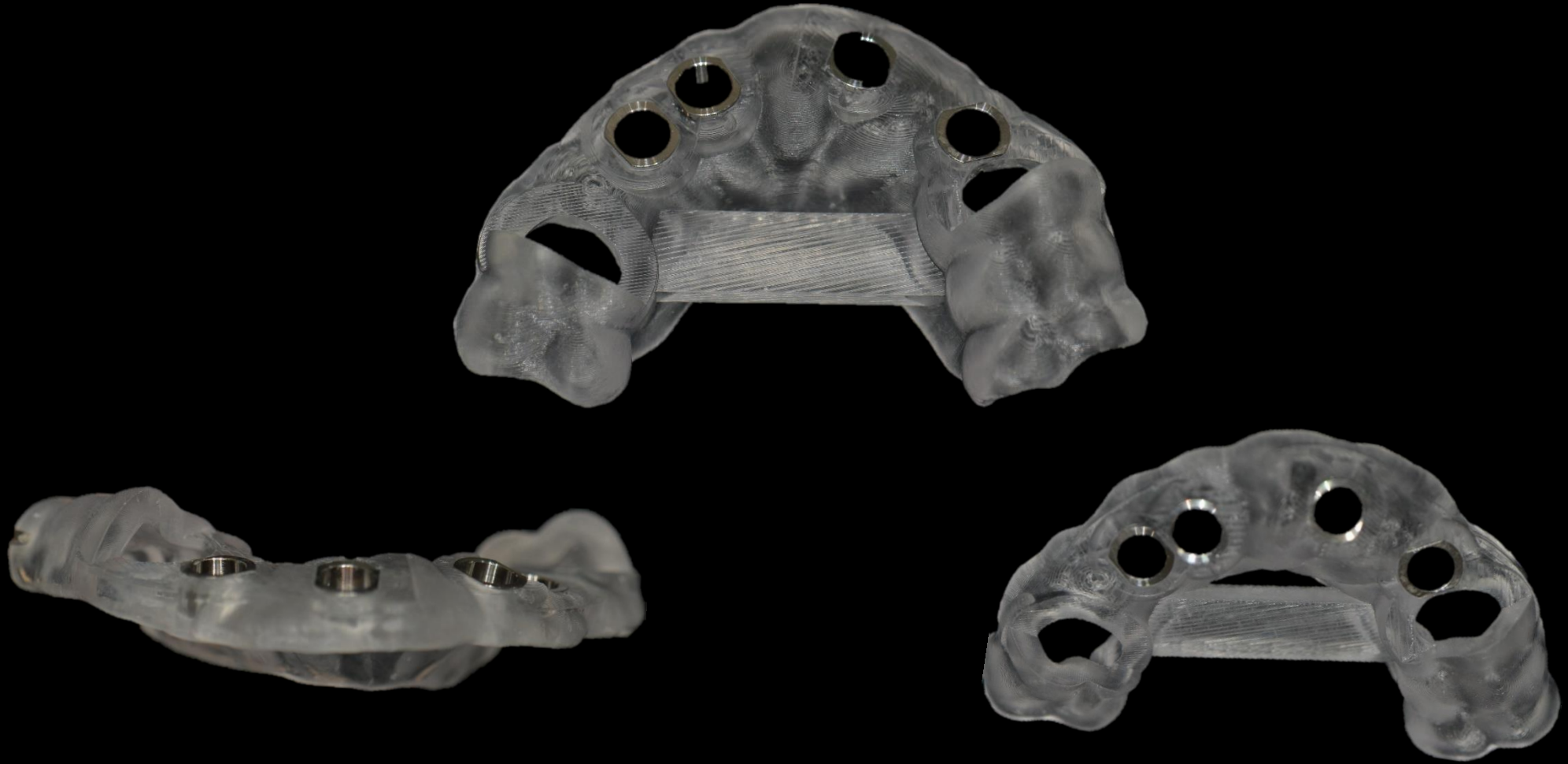
Stent design



Stent design

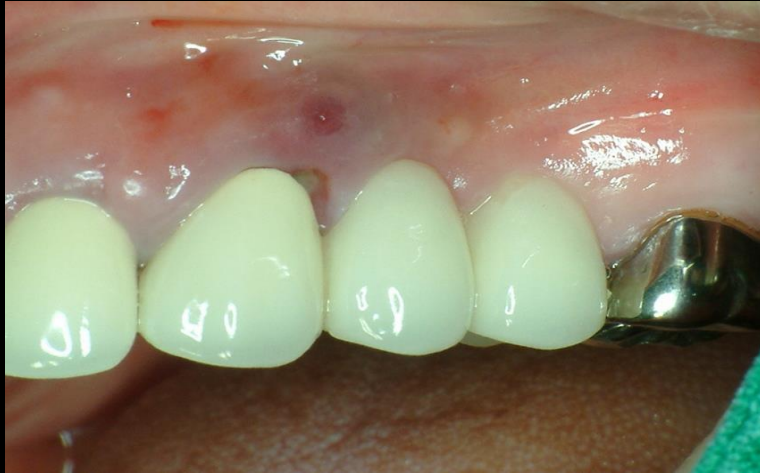

Stent

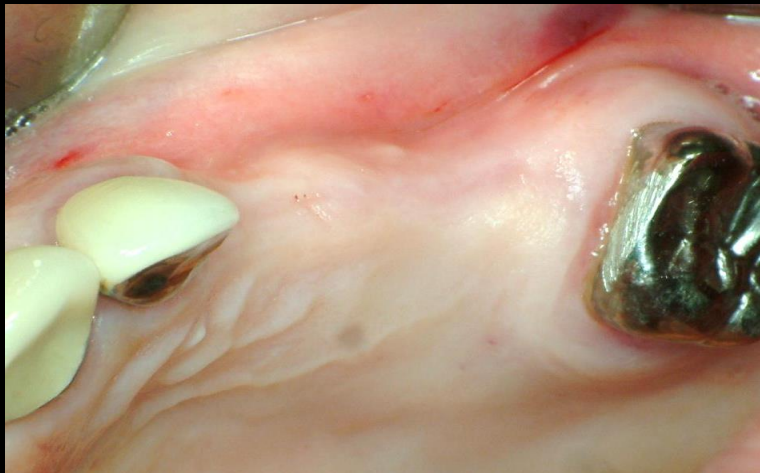
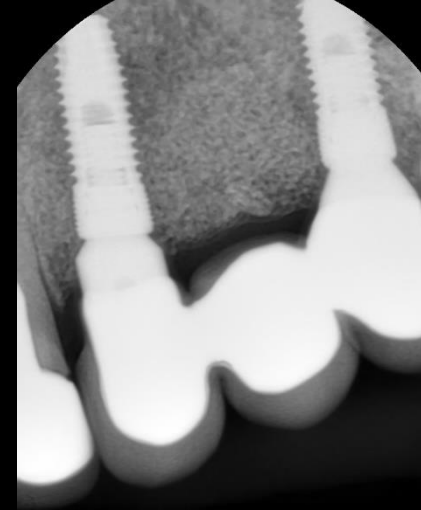


Similar case presentation (1)

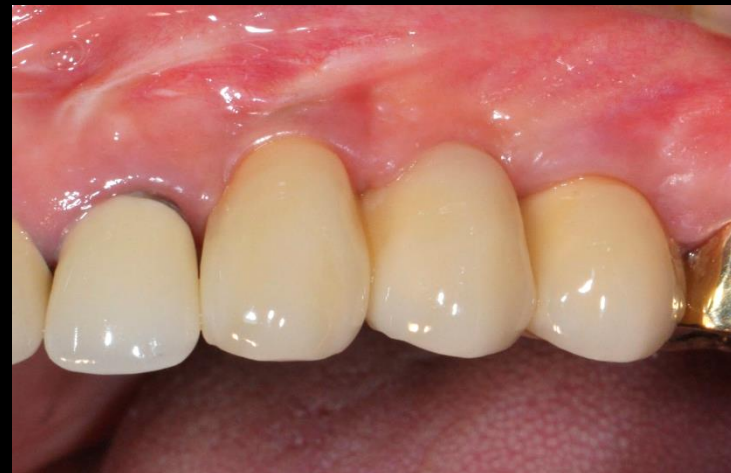- Ridge Splitting & GBR



Oral exam

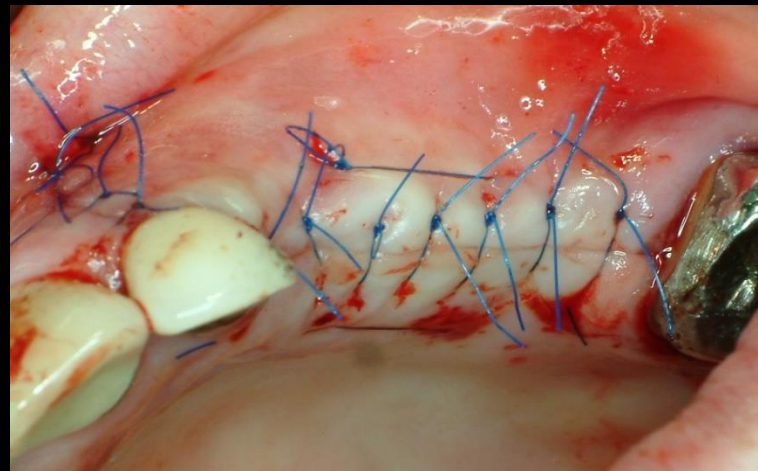
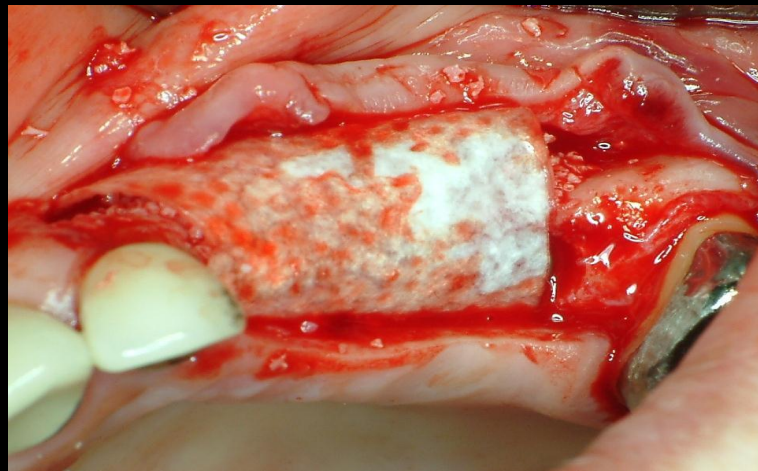
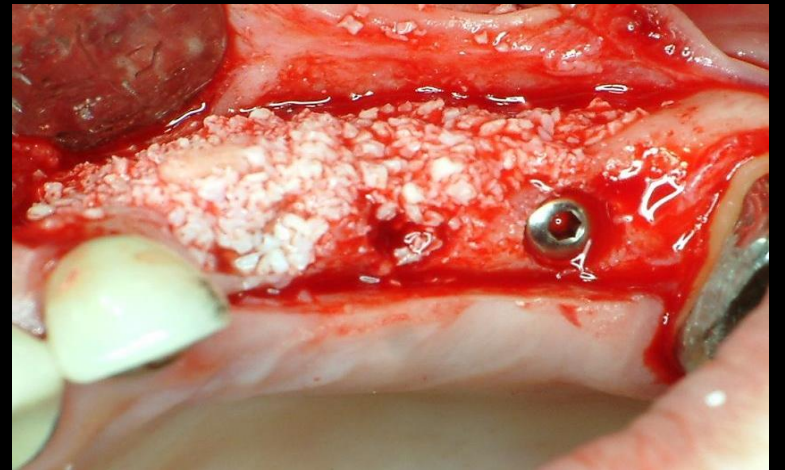
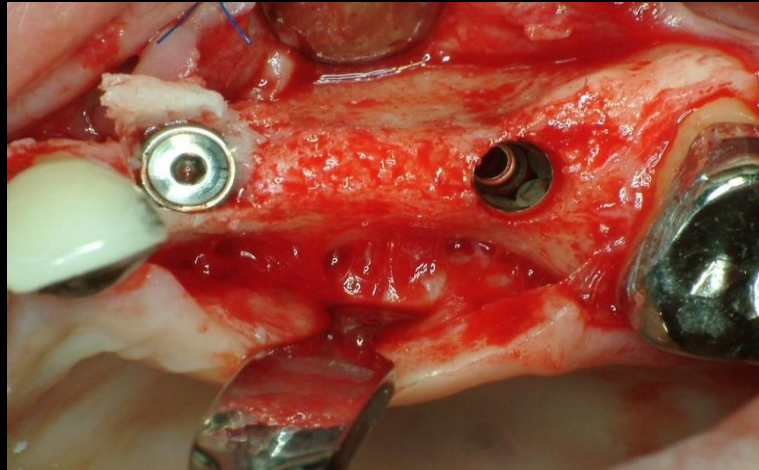
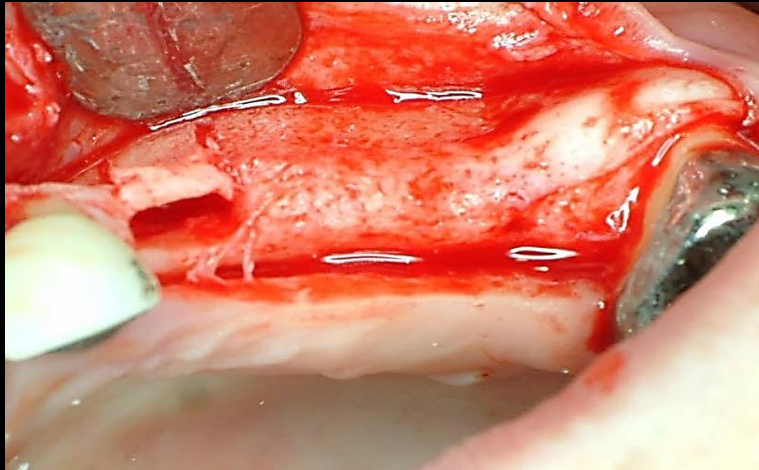


Pre-op



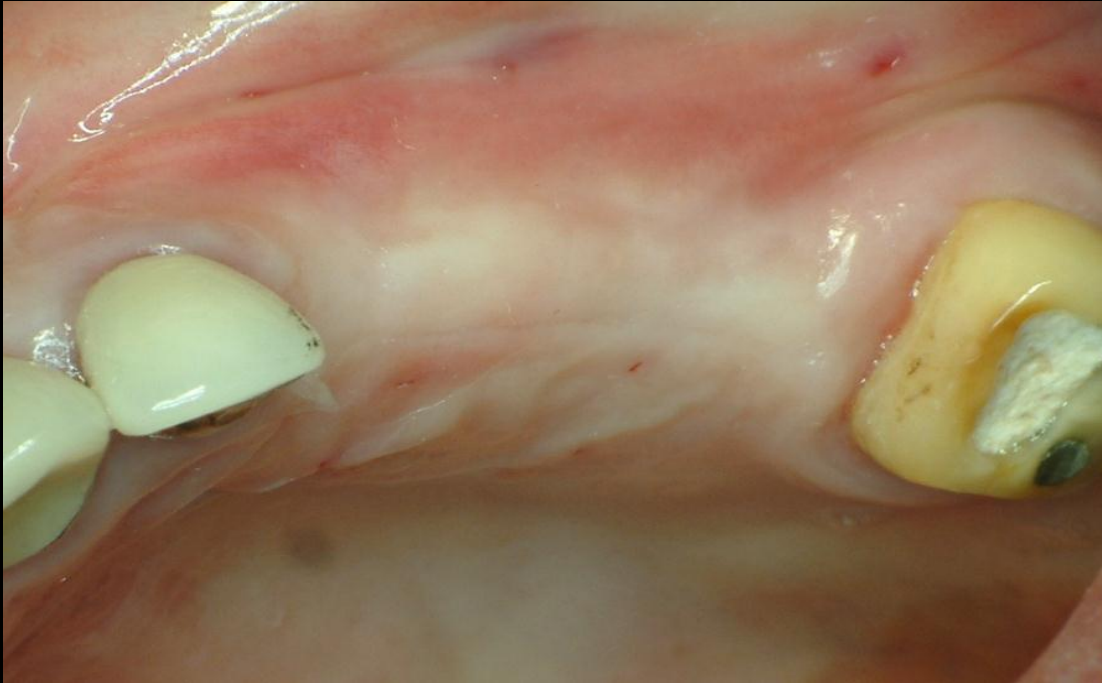
Final prosthesis

Similar case presentation (1) - Ridge Splitting & GBR

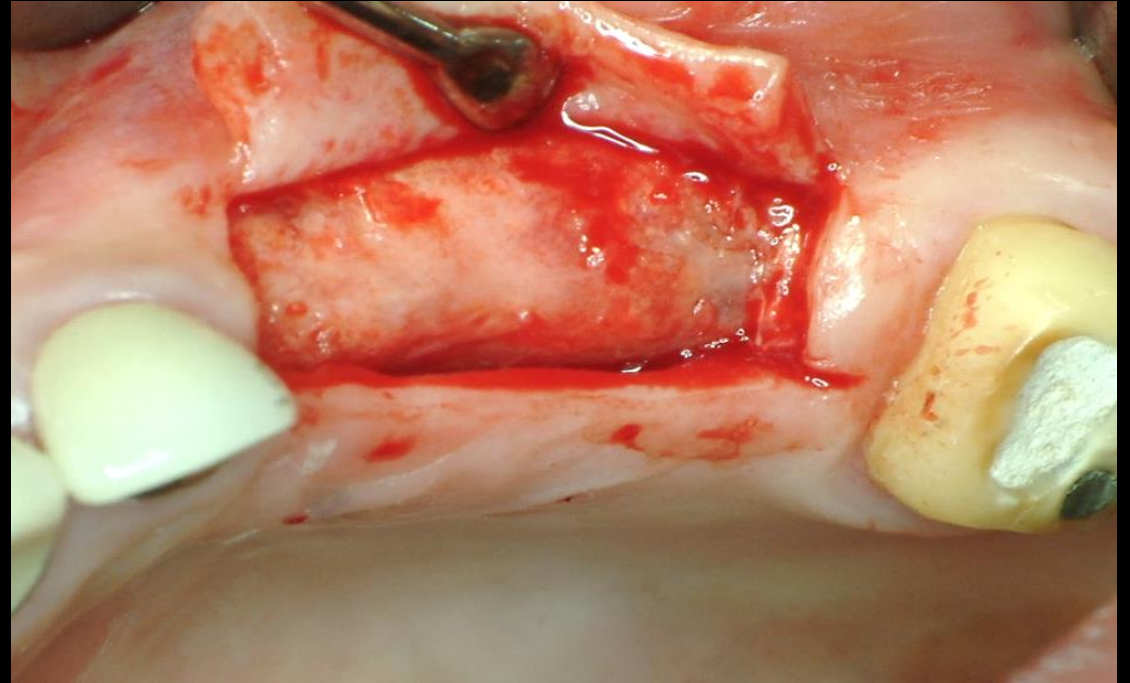


Similar case presentation (1)

- Ridge Splitting & GBR



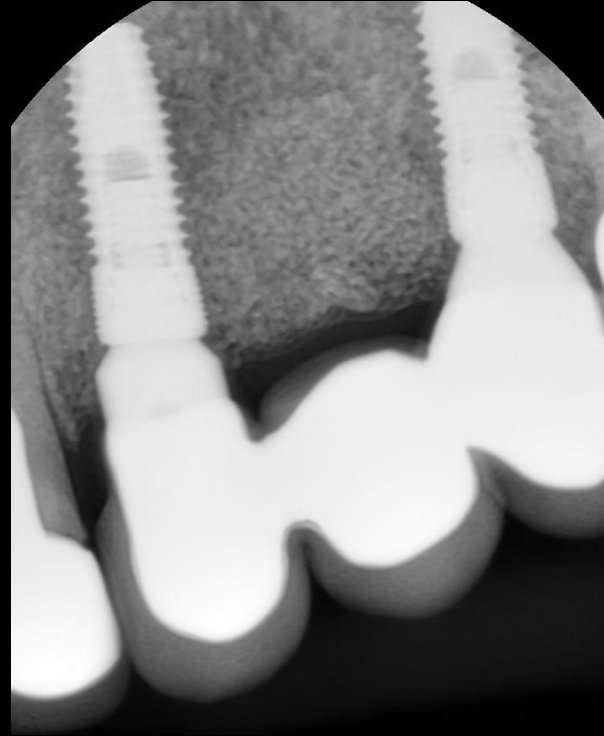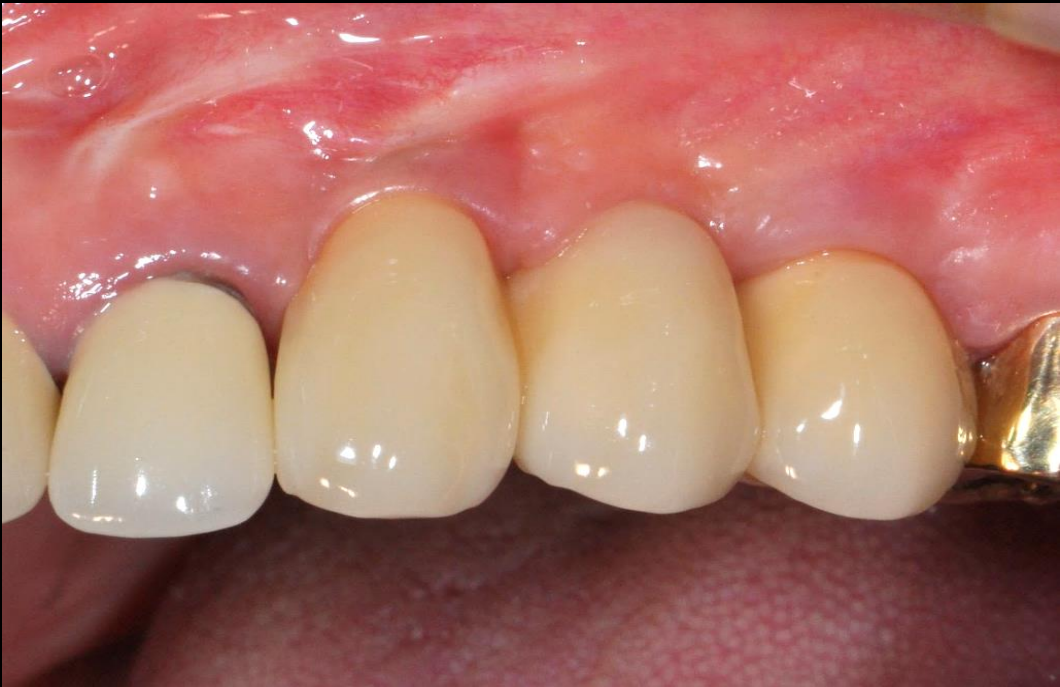Healing



Second Stage Surgery

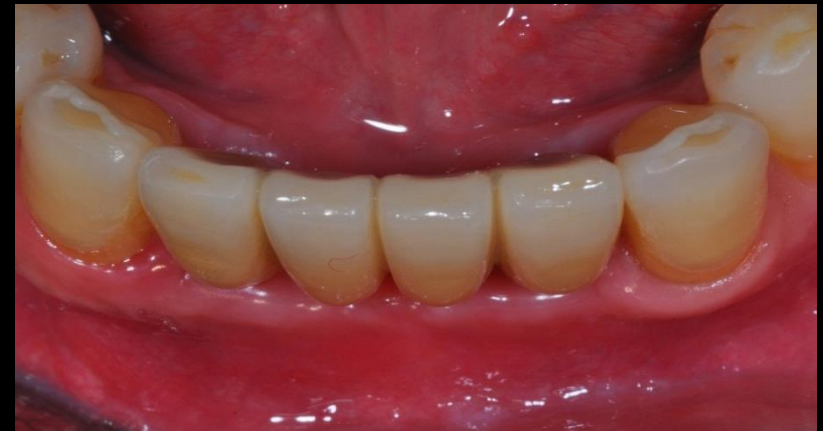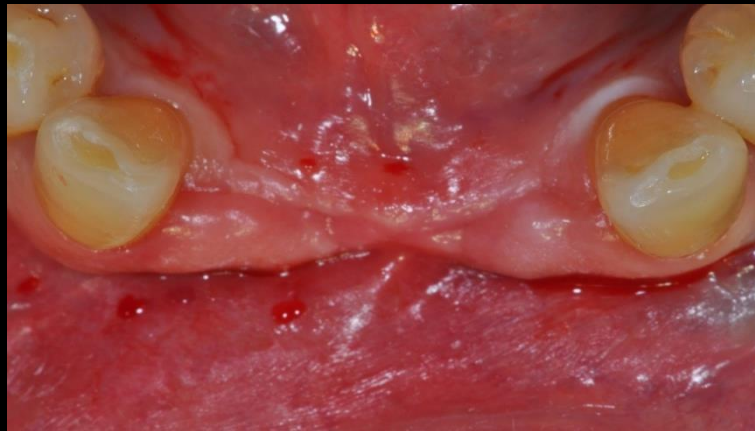
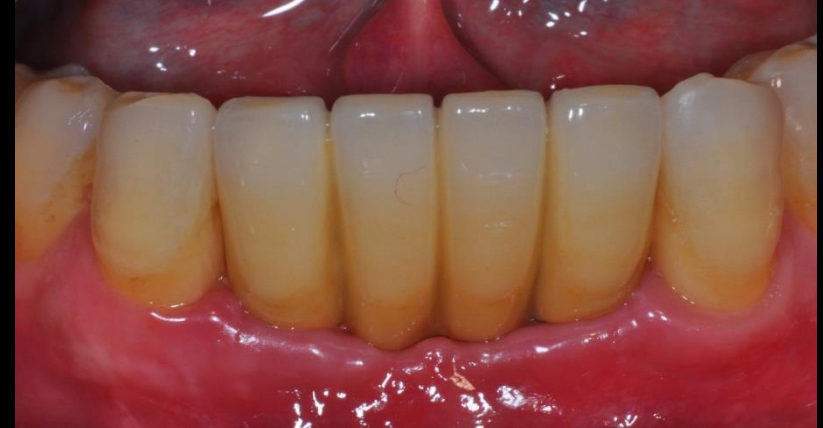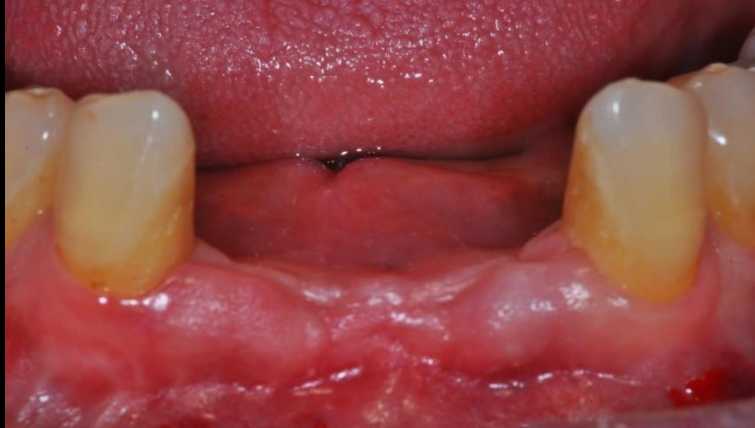Similar case presentation (1)

- Ridge Splitting & GBR



Final Prosthesis

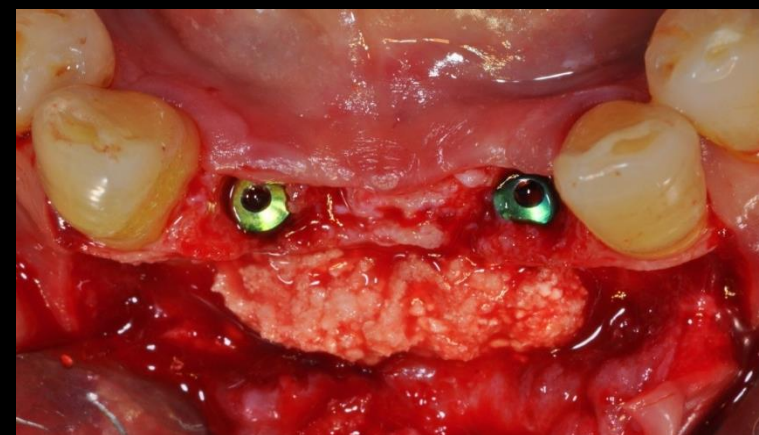
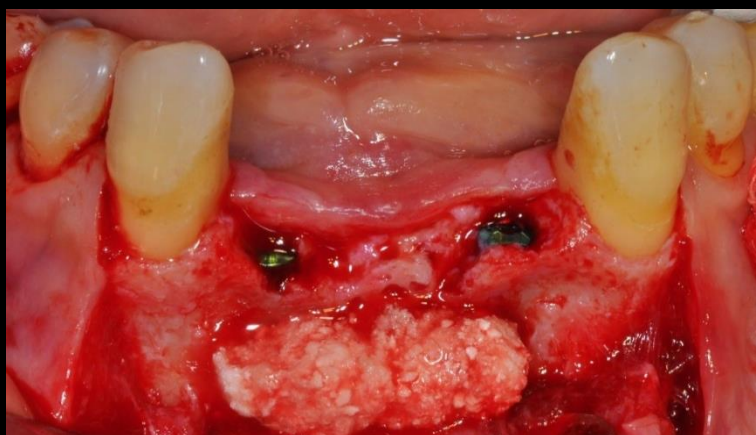
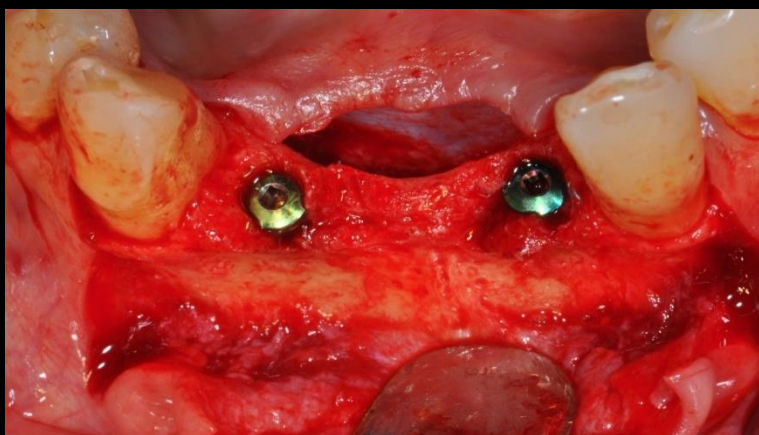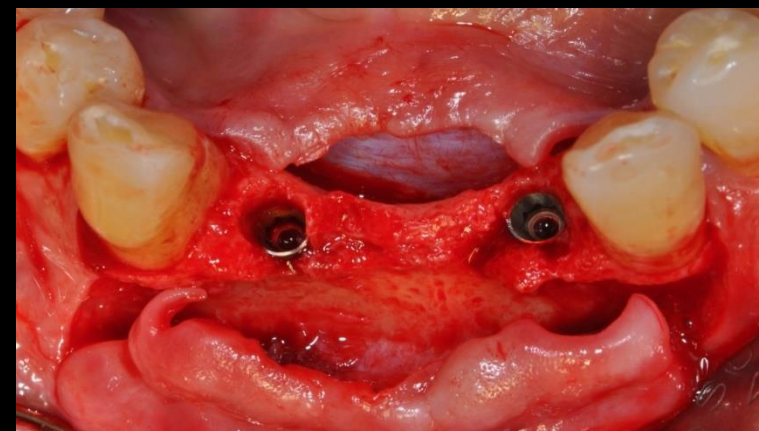
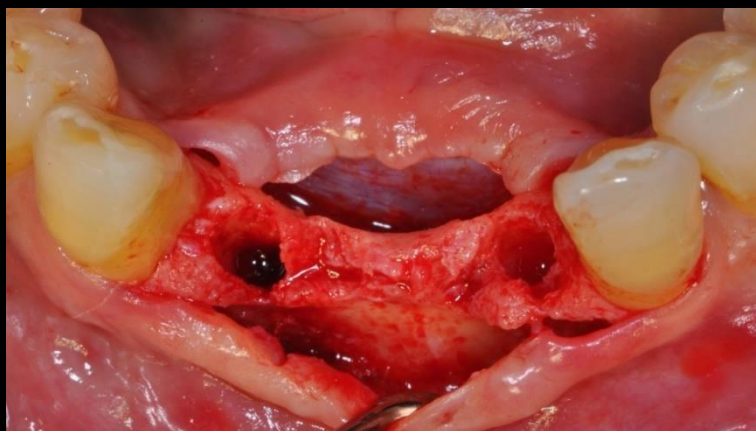
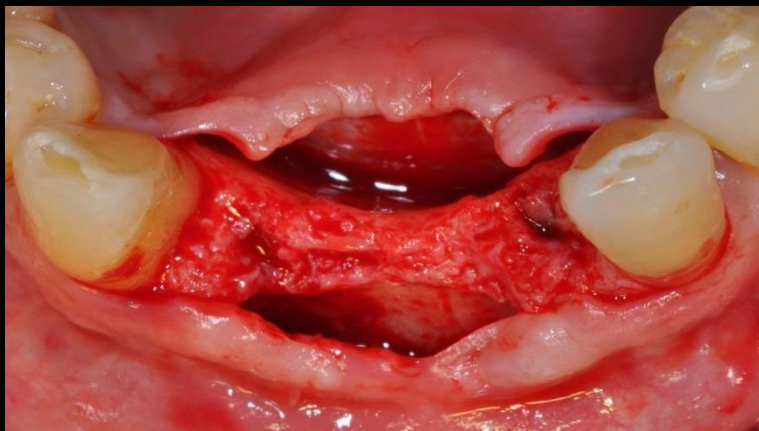
Similar case presentation (2) - DUK Technique



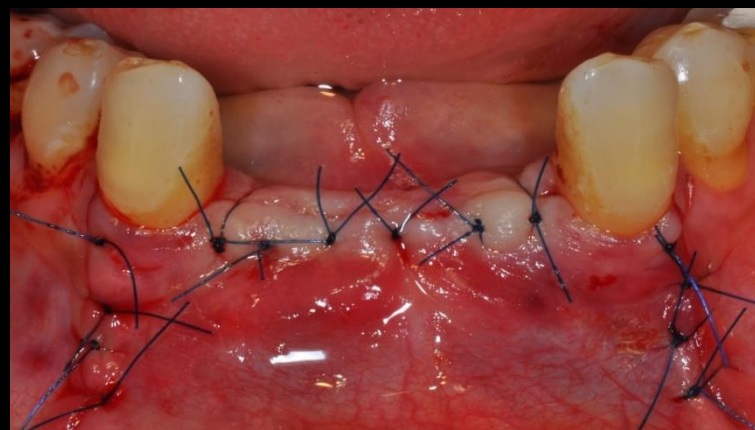
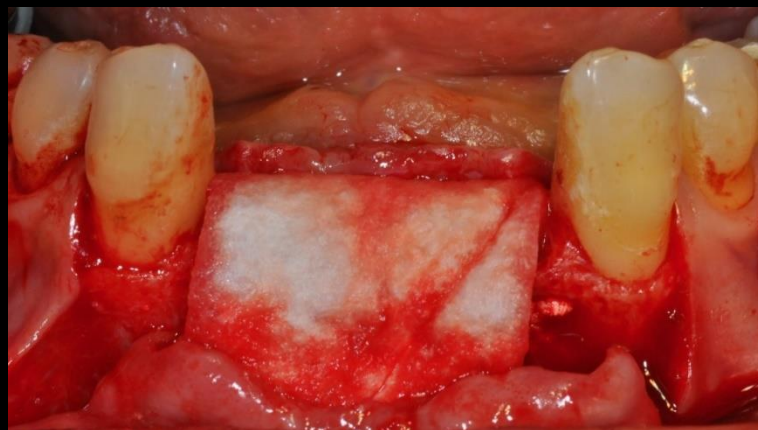
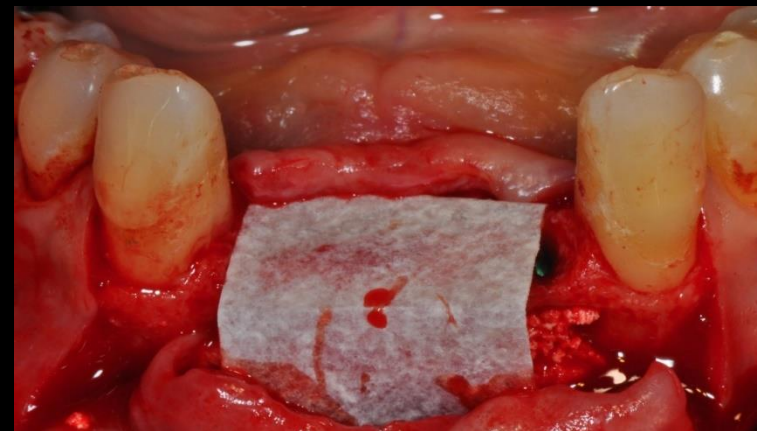
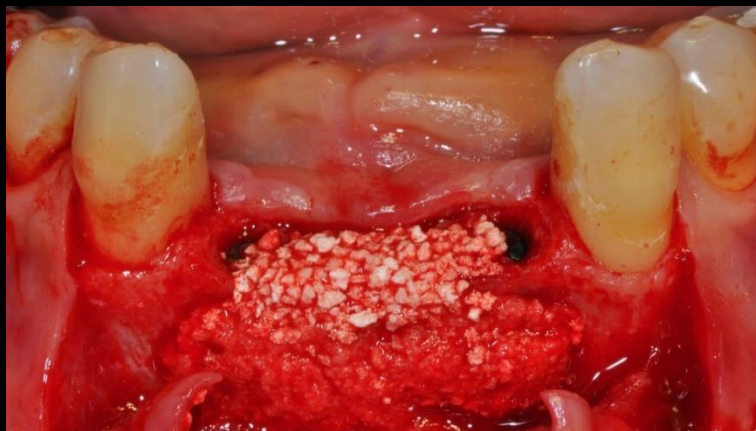
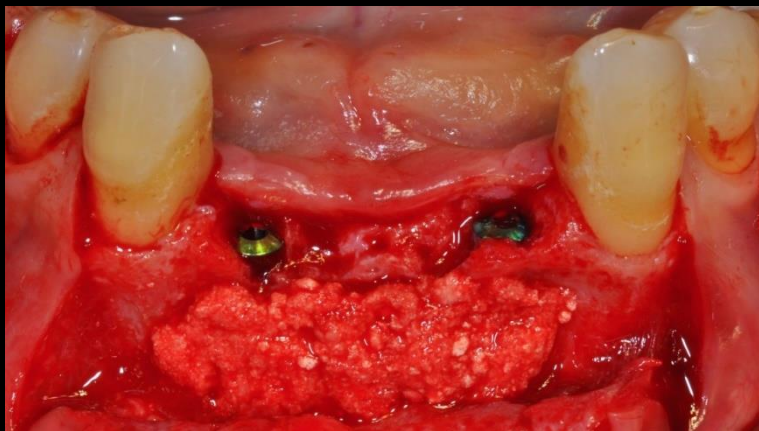
Pre-op

Final prosthesis

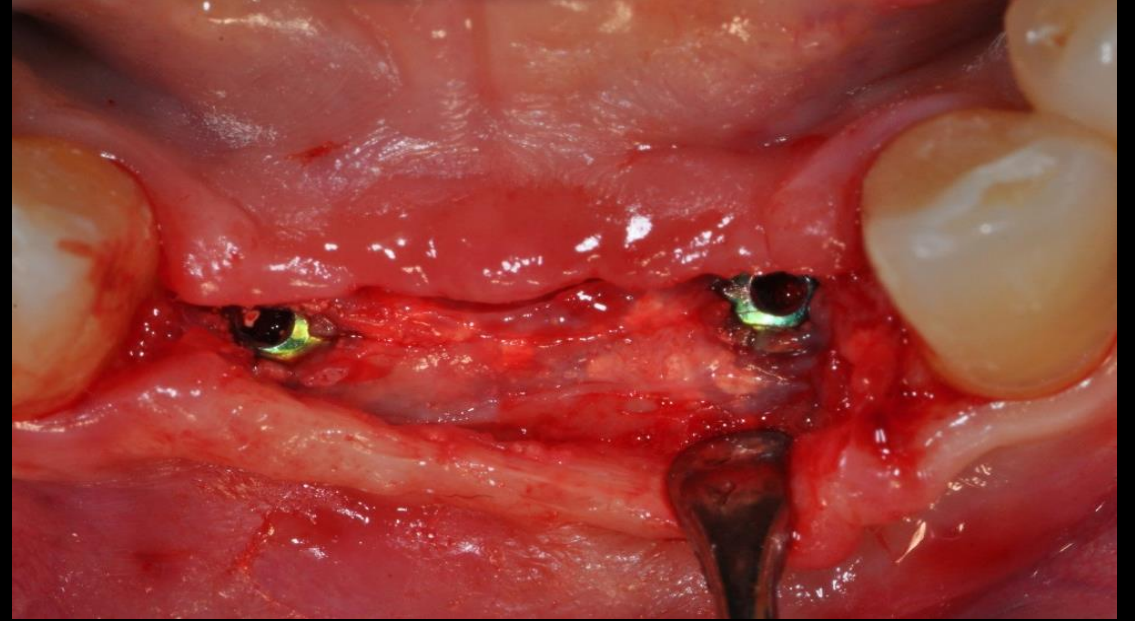
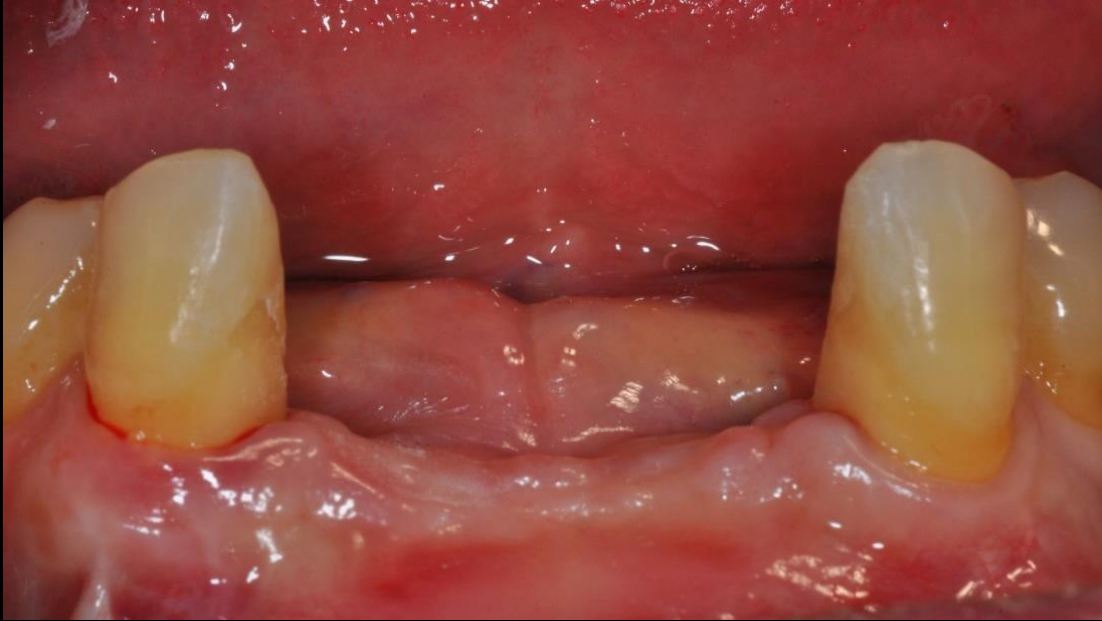Similar case presentation (2) - DUK Technique



Similar case presentation (2) - DUK Technique

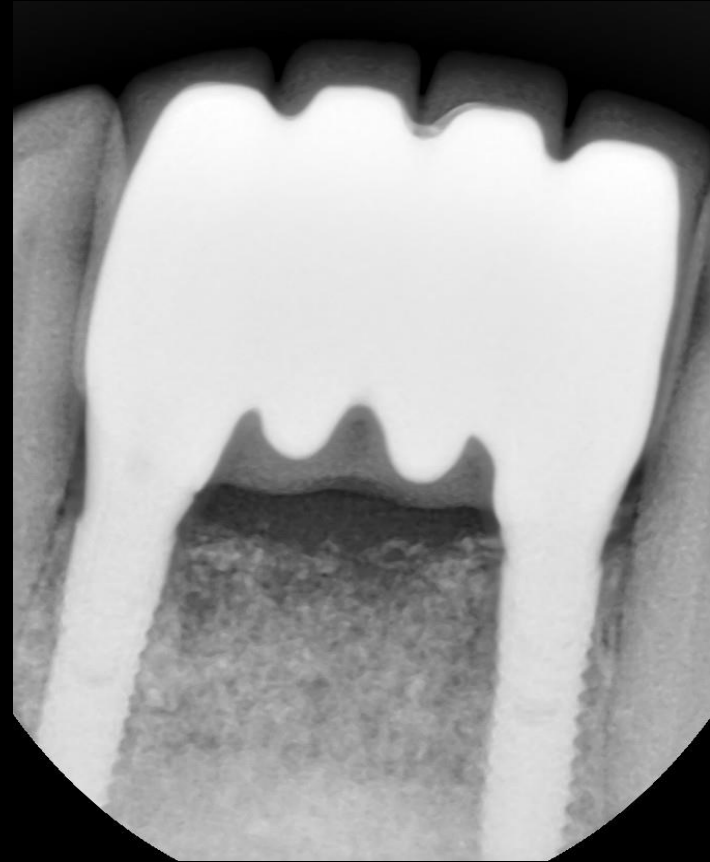
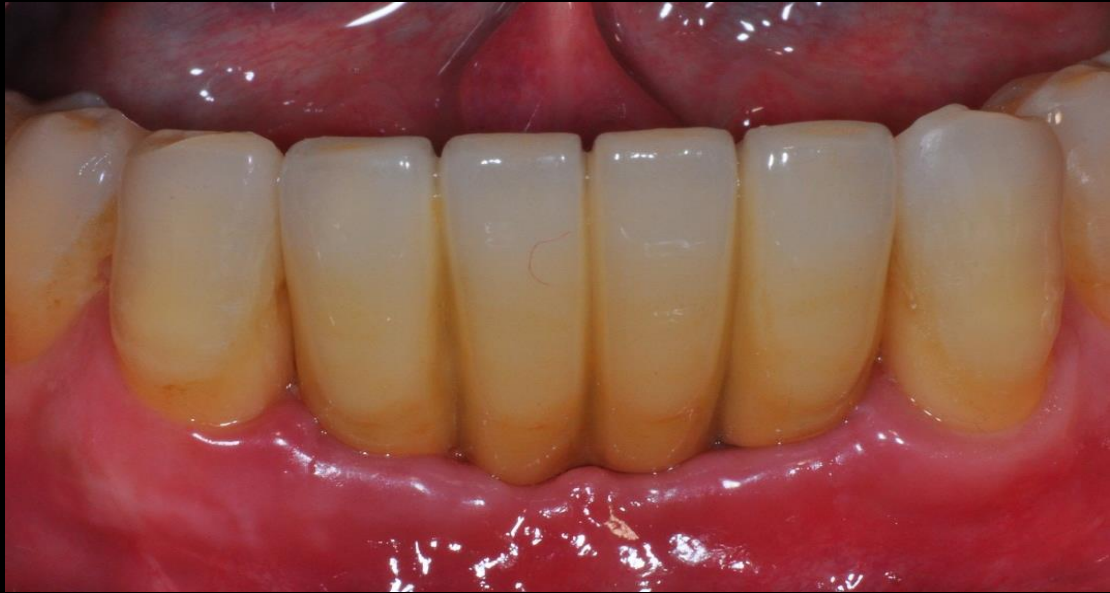
Similar case presentation (2) - DUK Technique



Second Stage Surgery

Similar case presentation (2) - DUK Technique



Final Prosthesis