



**LIVE**

# Surgey

Dr. Jung-Hyun Park

2021.10.15 (FRI.)



# [Case Preview]

Posterior restoration with bright Implant  
using Dentium Digital Guide

# Patient Information

**Age** : 50

**Sex** : Female

## Chief Complaint

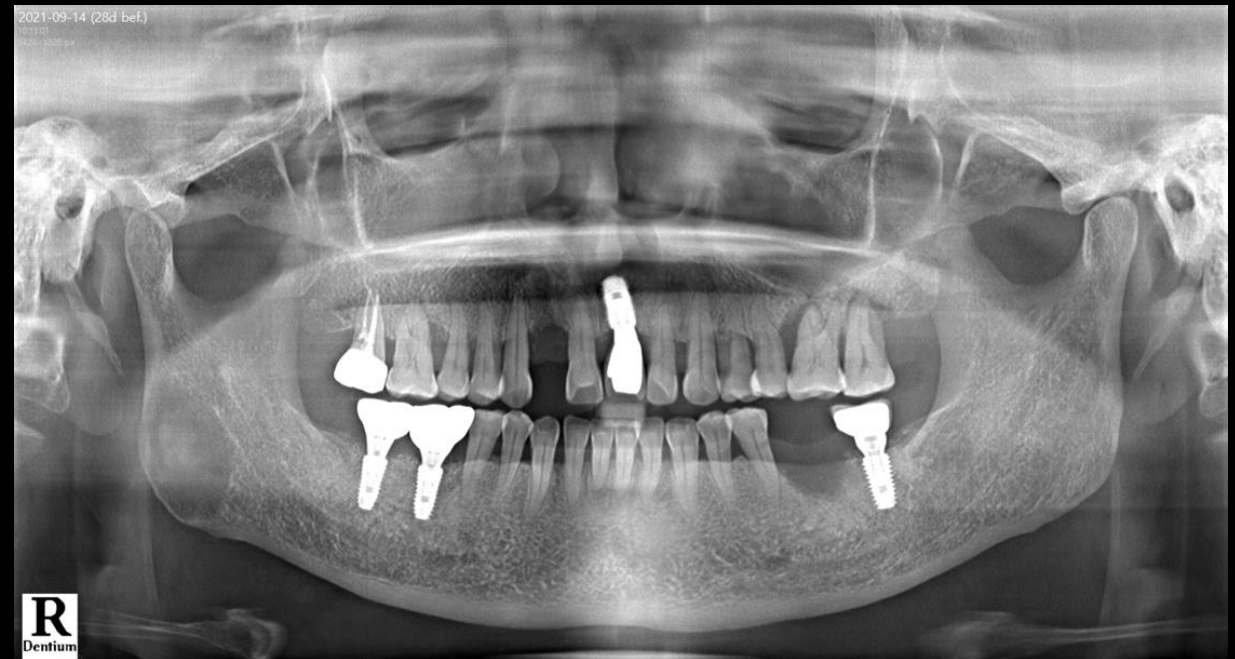
: My upper left molar shakes and  
uncomfortable to chew

## Past Dental History

: #21, 37, 46, 47 implant placement

## Past Medical History

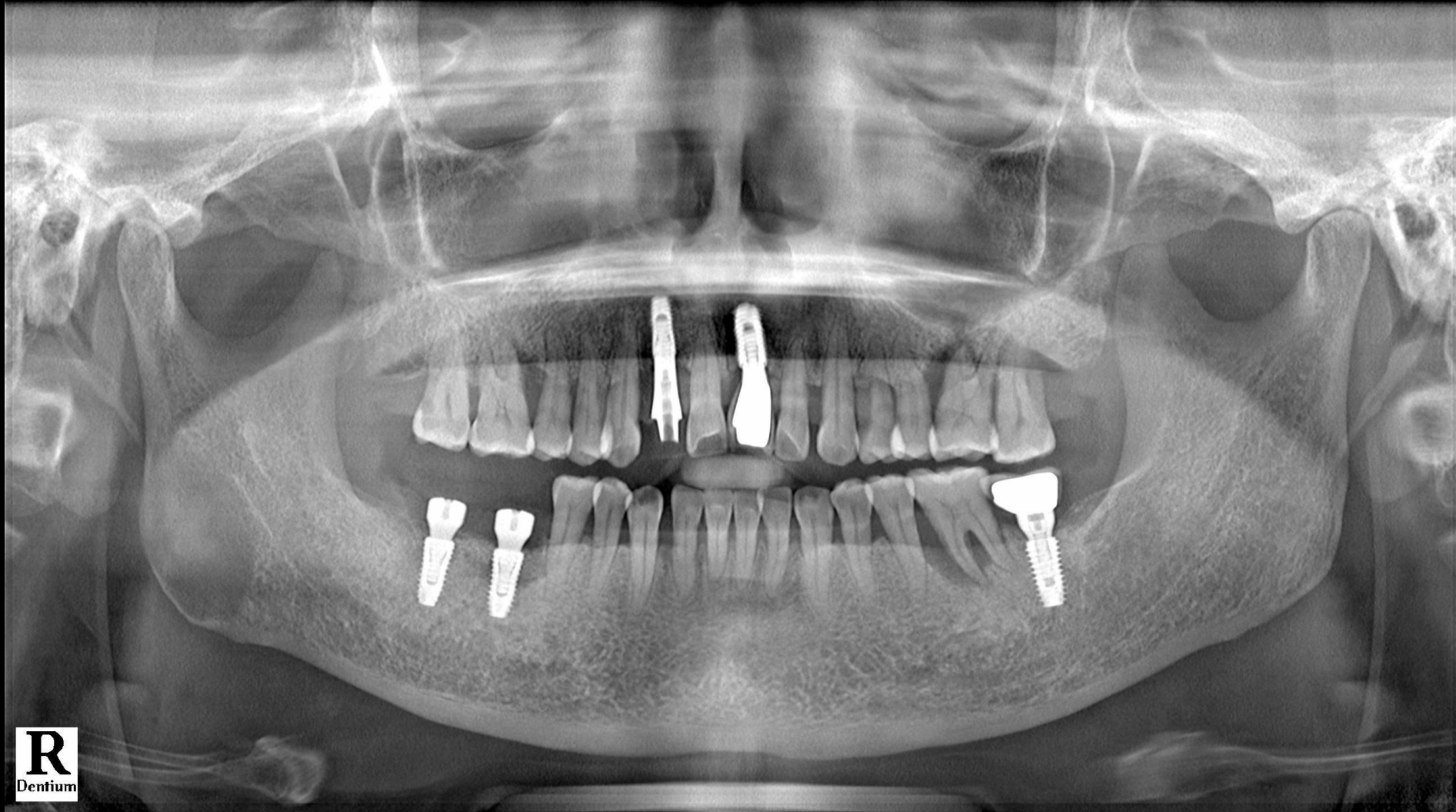
: N/S





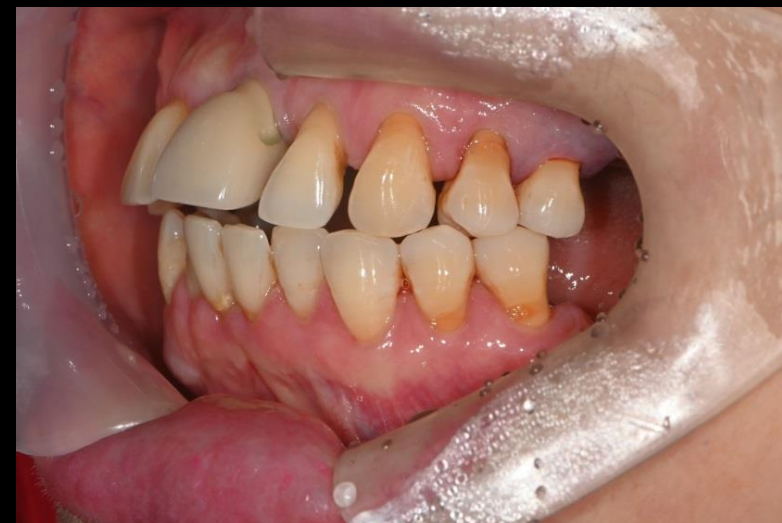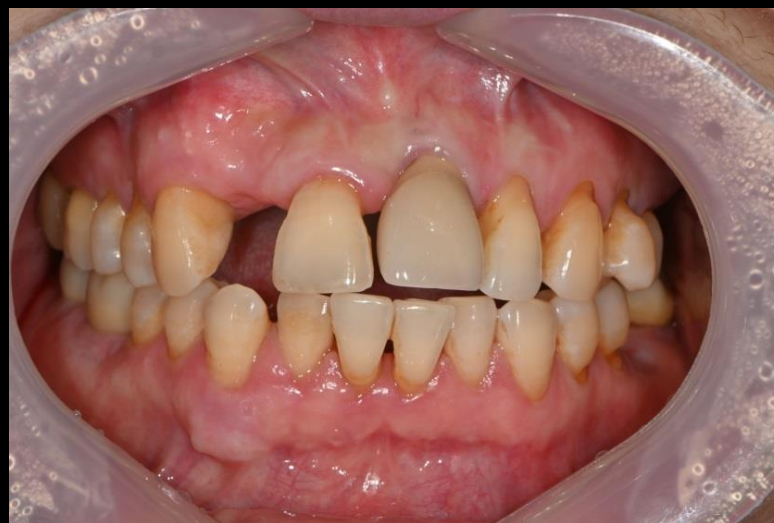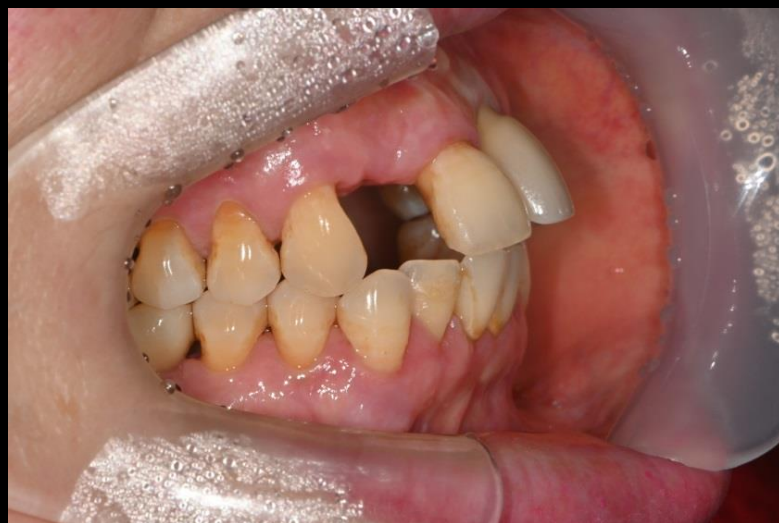# Past dental history

Oral exam (2021-03-26)



# Past dental history

Oral exam (2021-09-14)

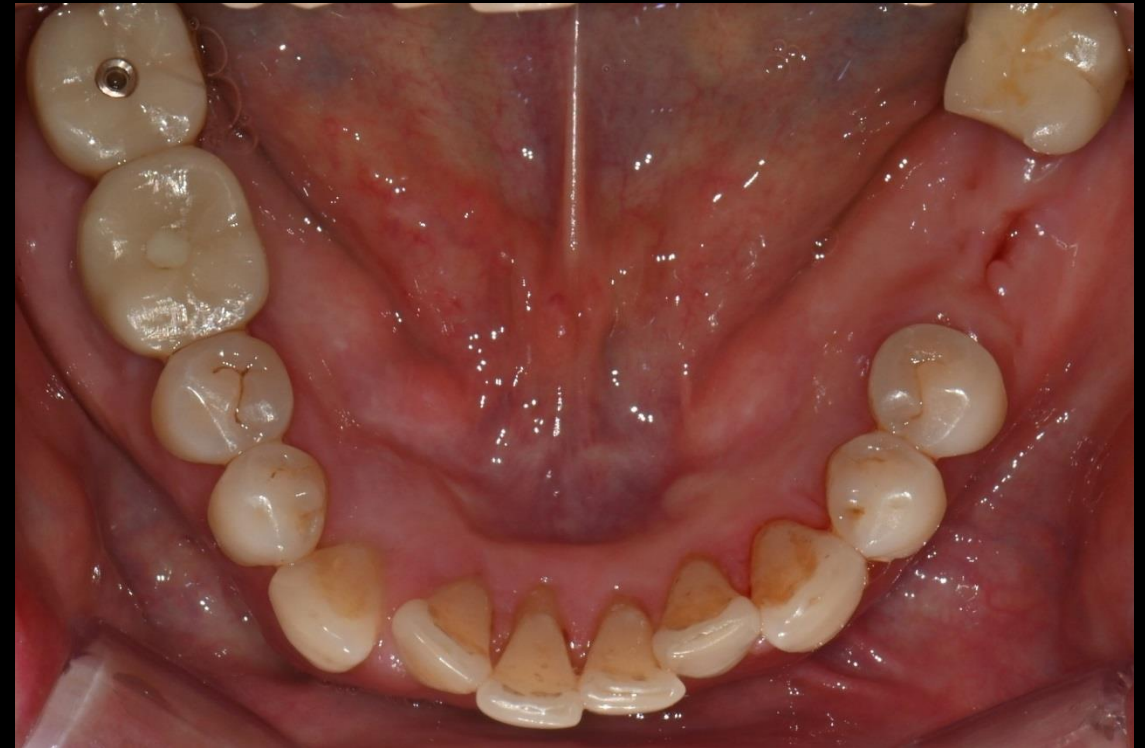
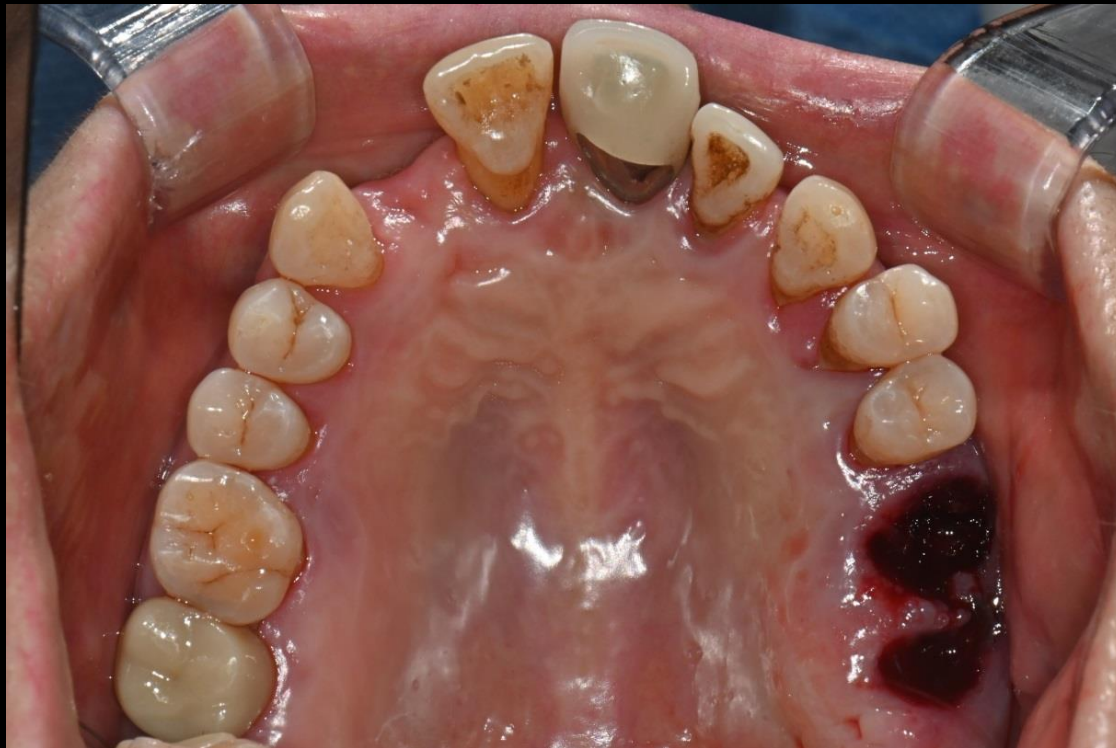


# Past dental history

Oral exam (2021-09-14)

- #26, 27 Extraction



# Today's Surgery Plan

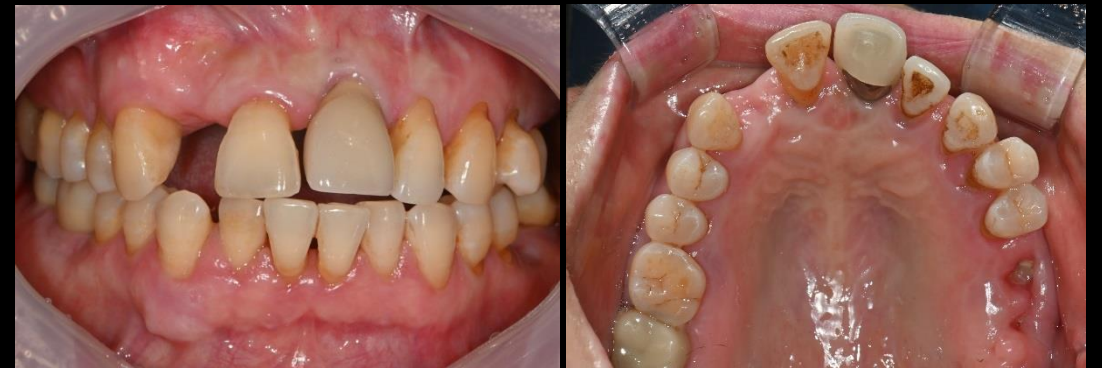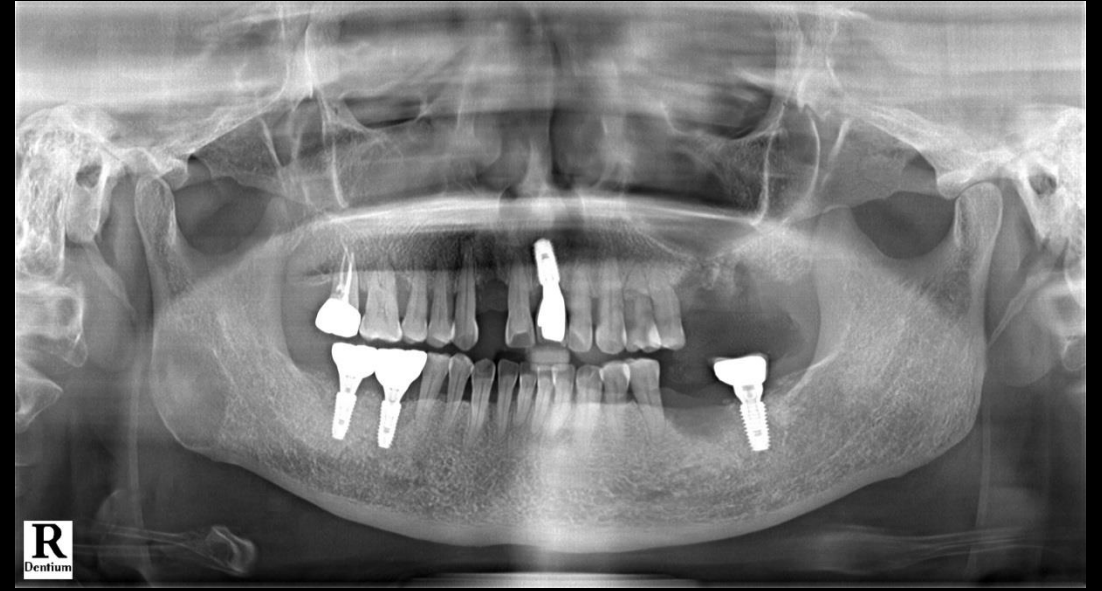# 24, 25

- Extraction

# 12, 24, 25, 27

- Implant placement with Digital Guide Stent

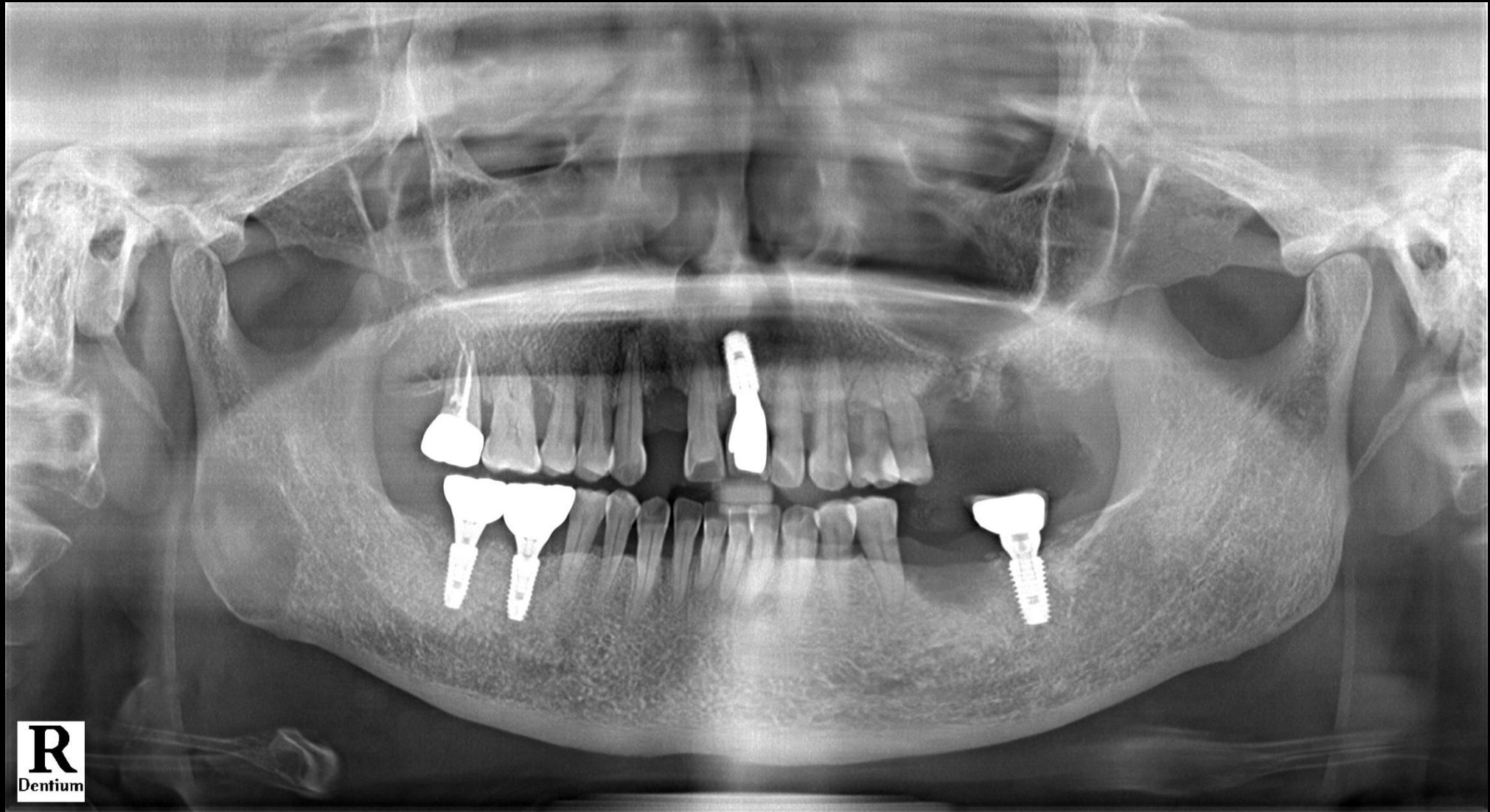- Bone graft





Pt. Mo (58/Female)

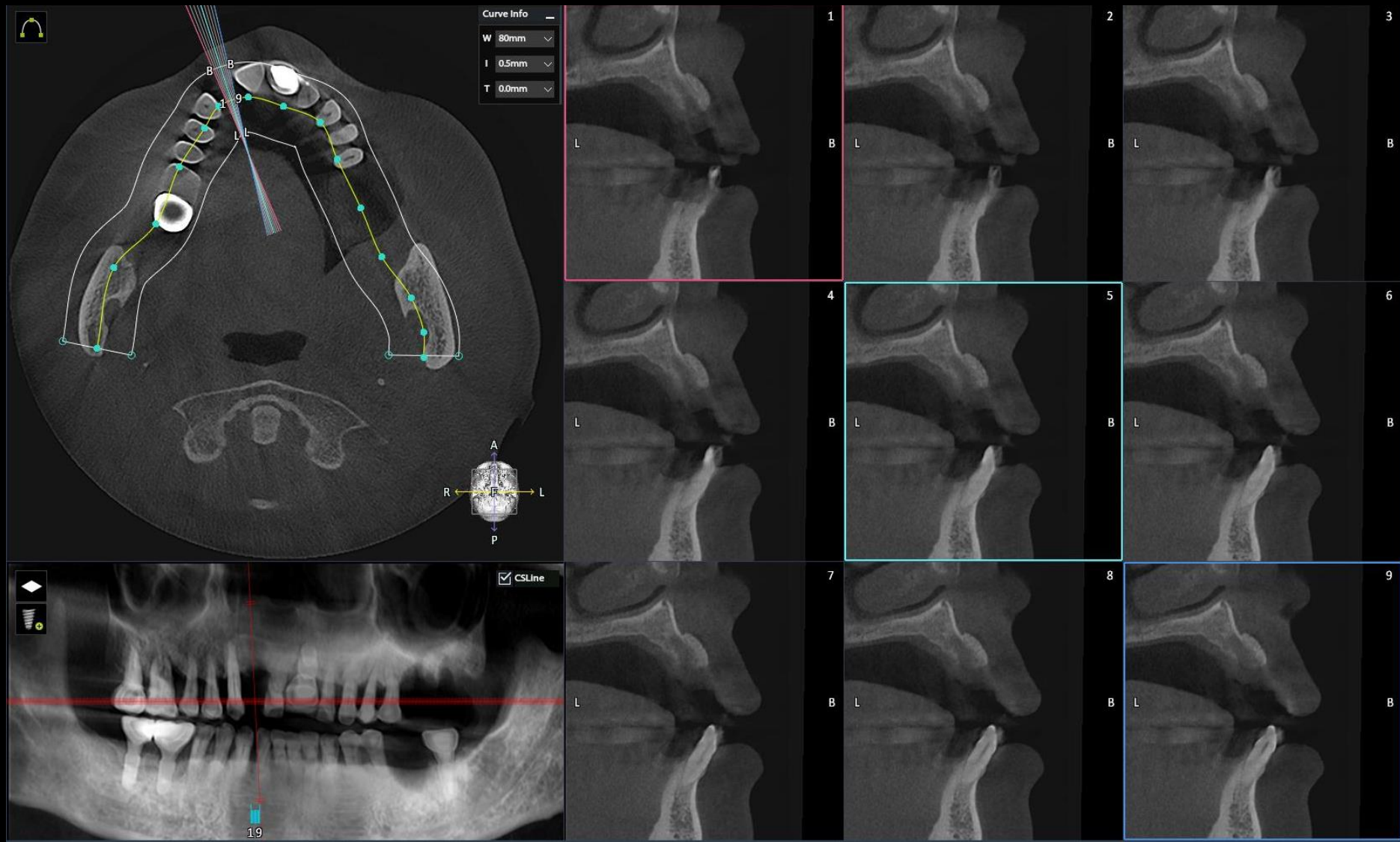
Pre-op (2021-09-14)





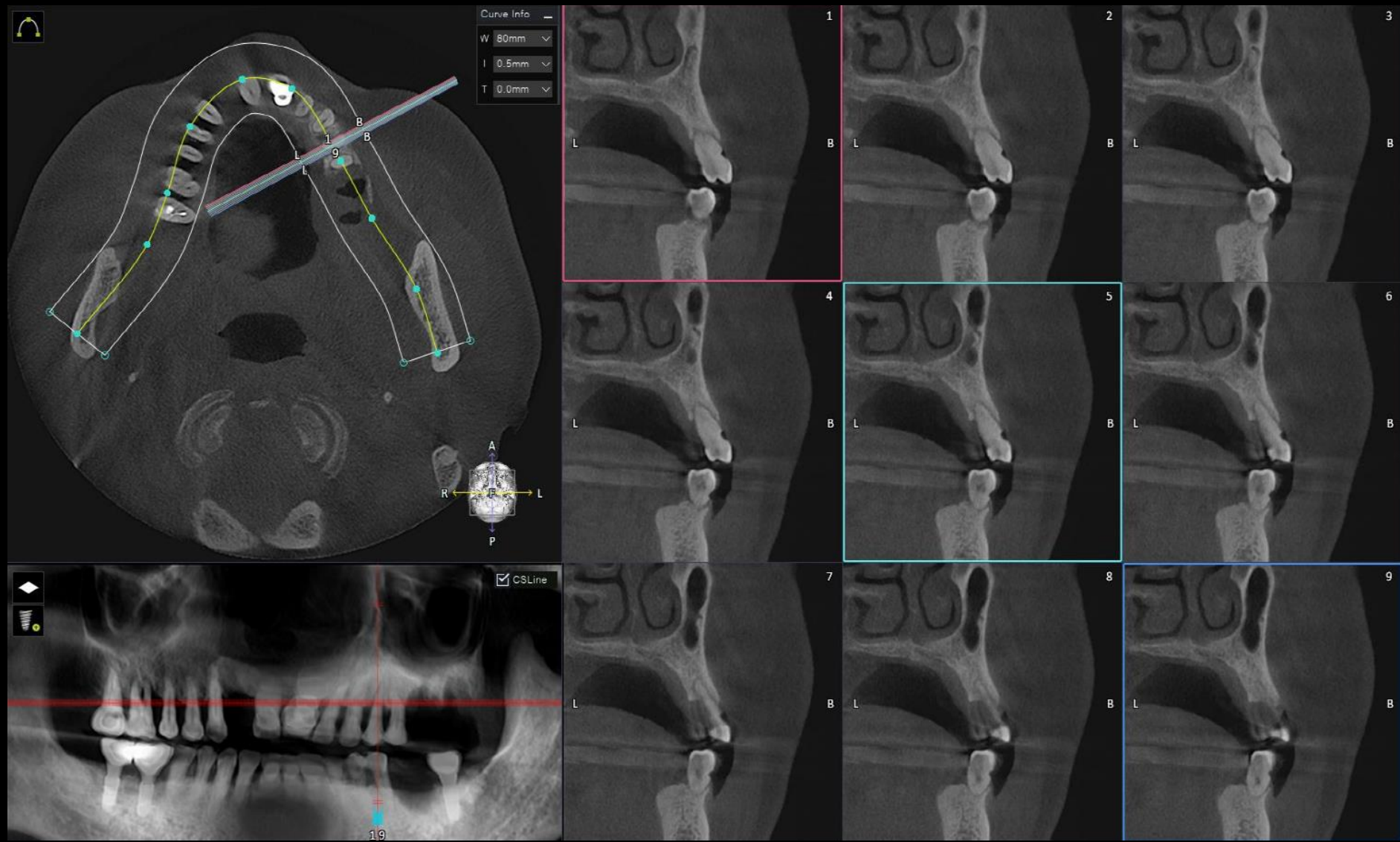
Pt. Mo (58/Female)

#12 Pre-op (2021-09-14)



Pt. Mo (58/Female)

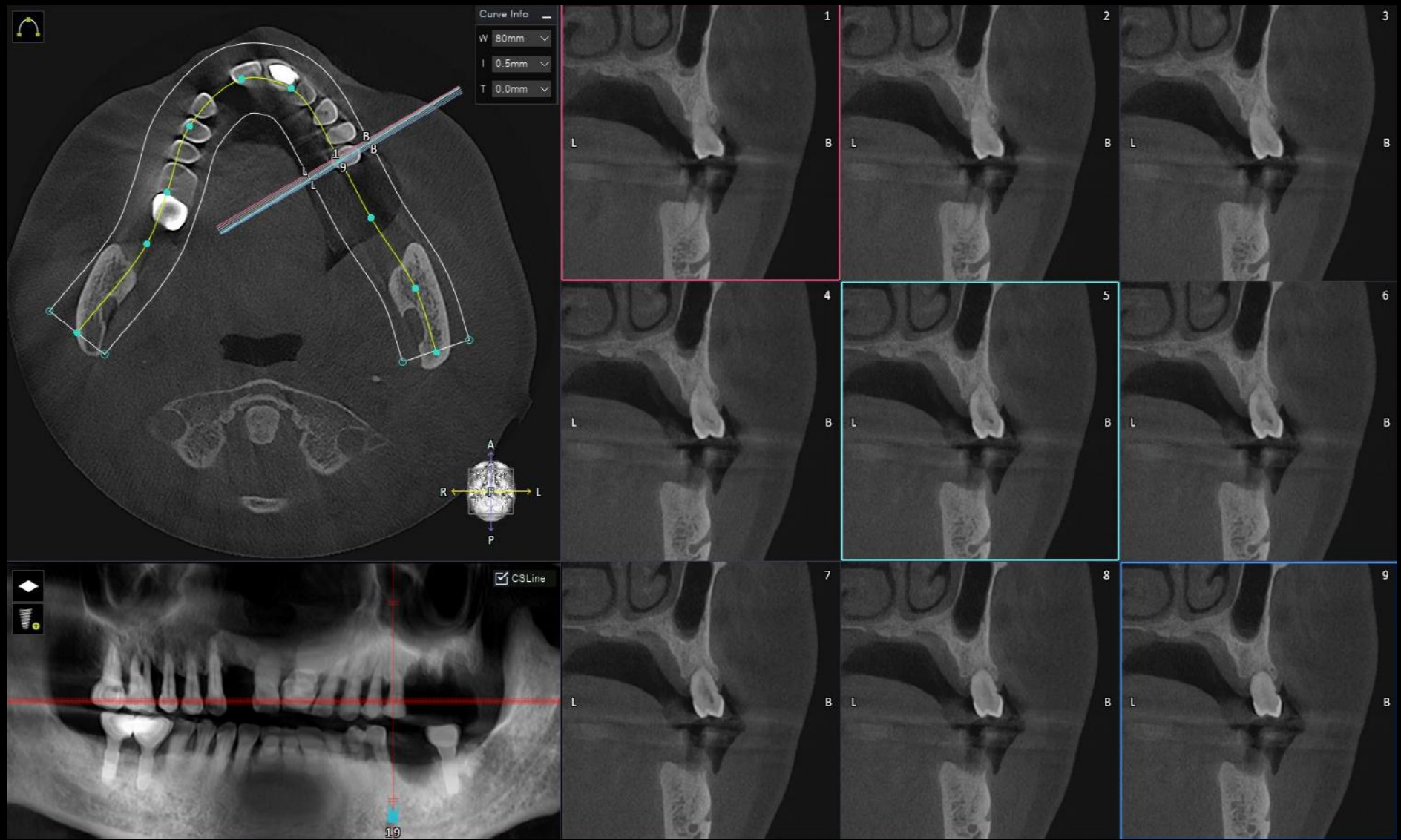
#24 Pre-op (2021-09-14)





Pt. Mo (58/Female)

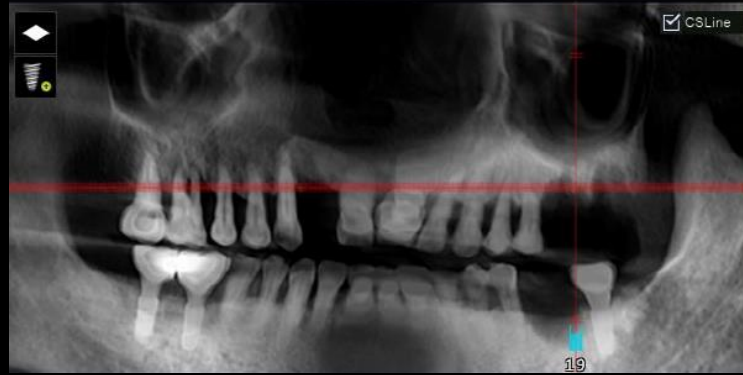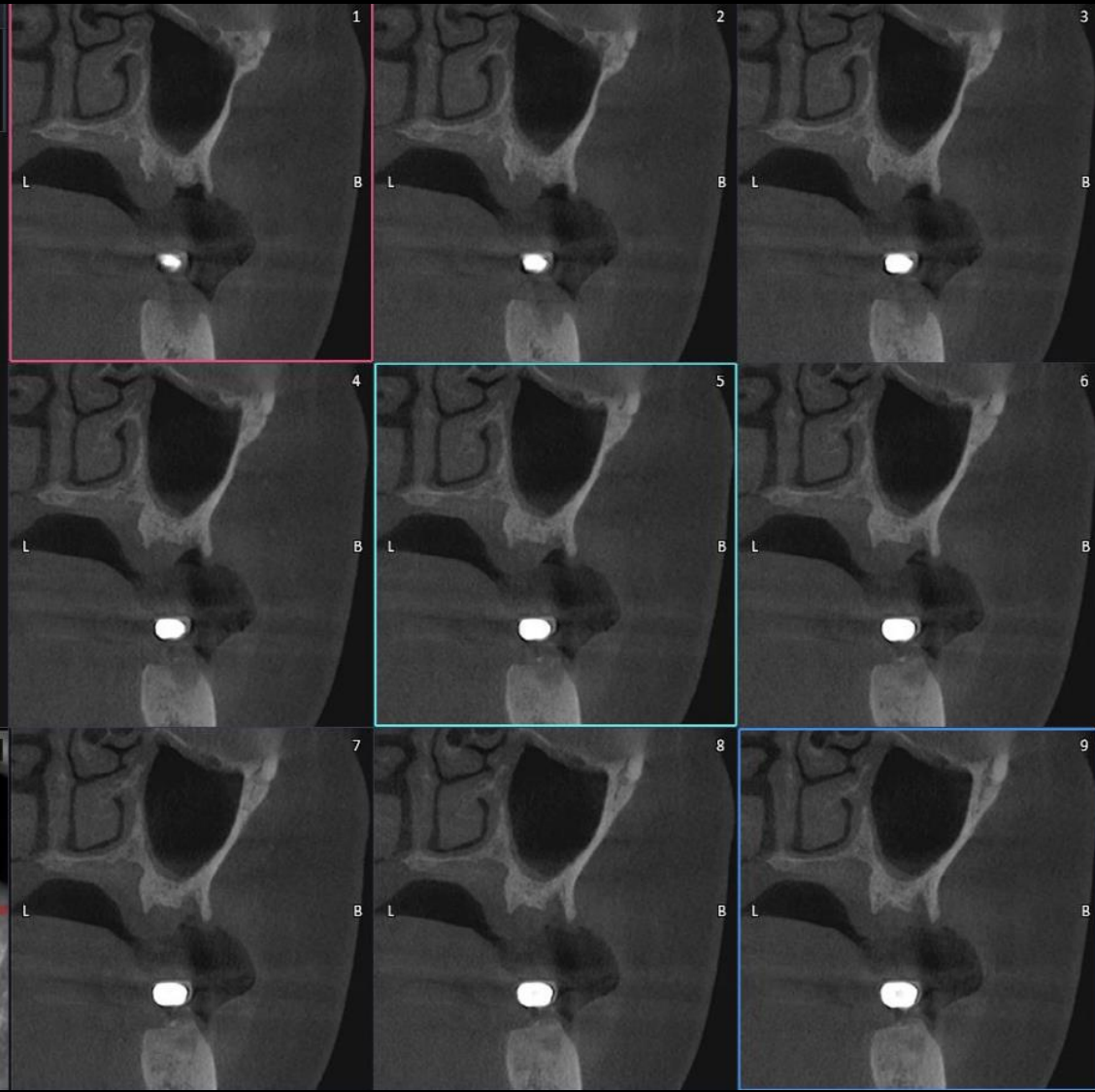
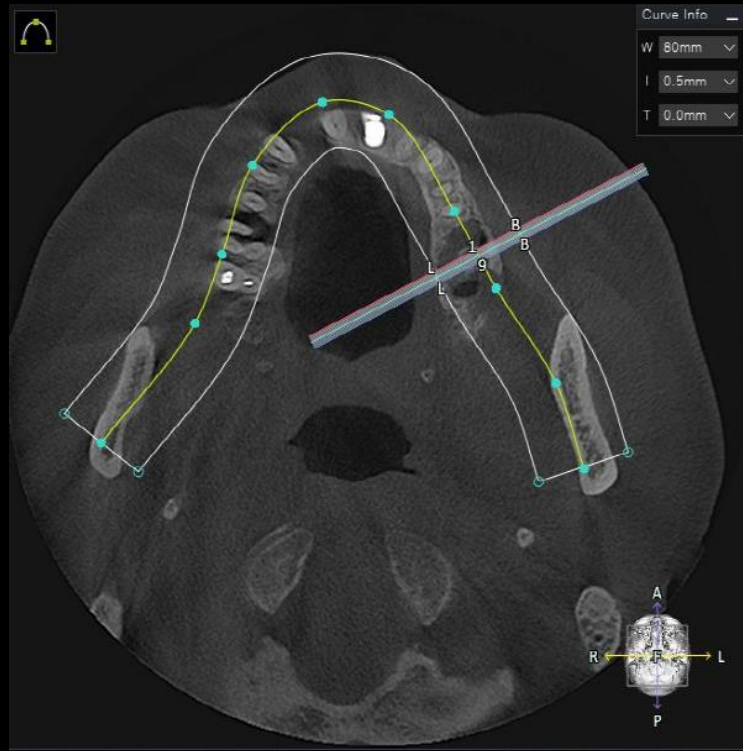
#25 Pre-op (2021-09-14)



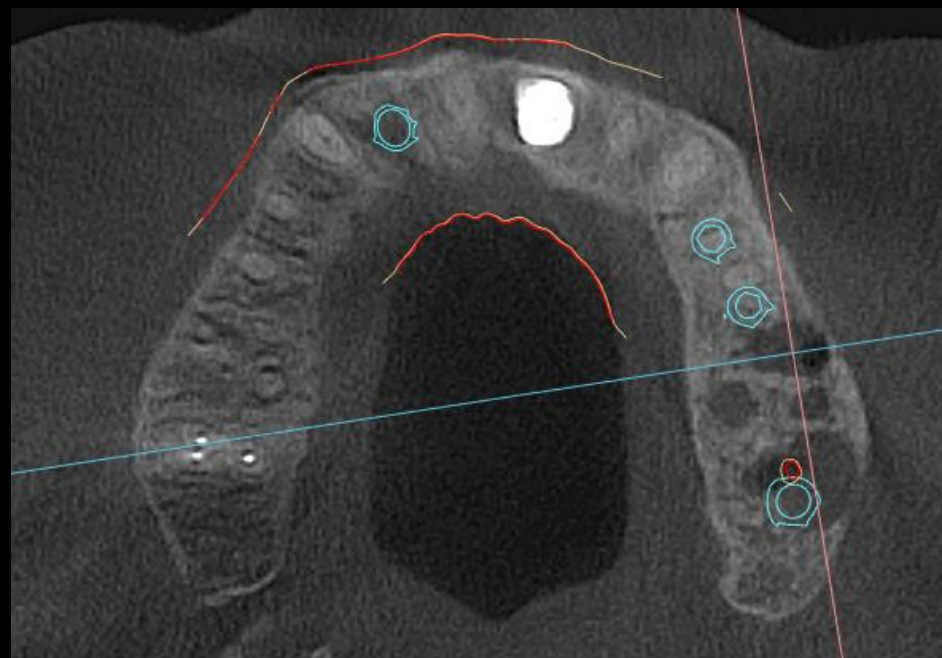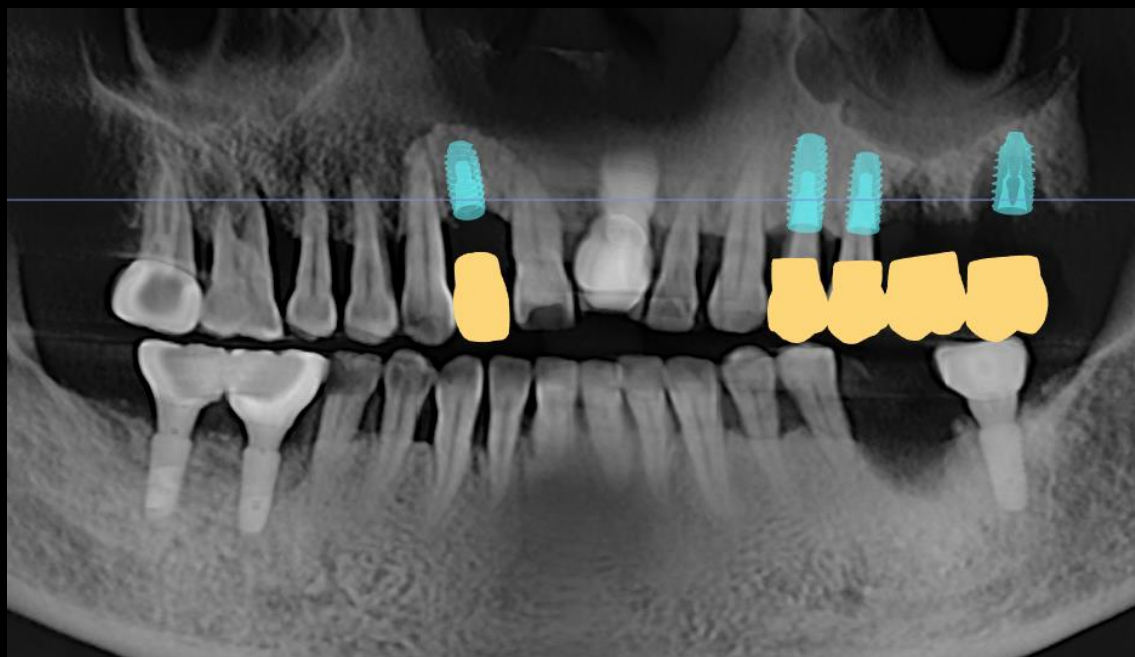


Pt. Mo (58/Female)

#27 Pre-op (2021-09-14)

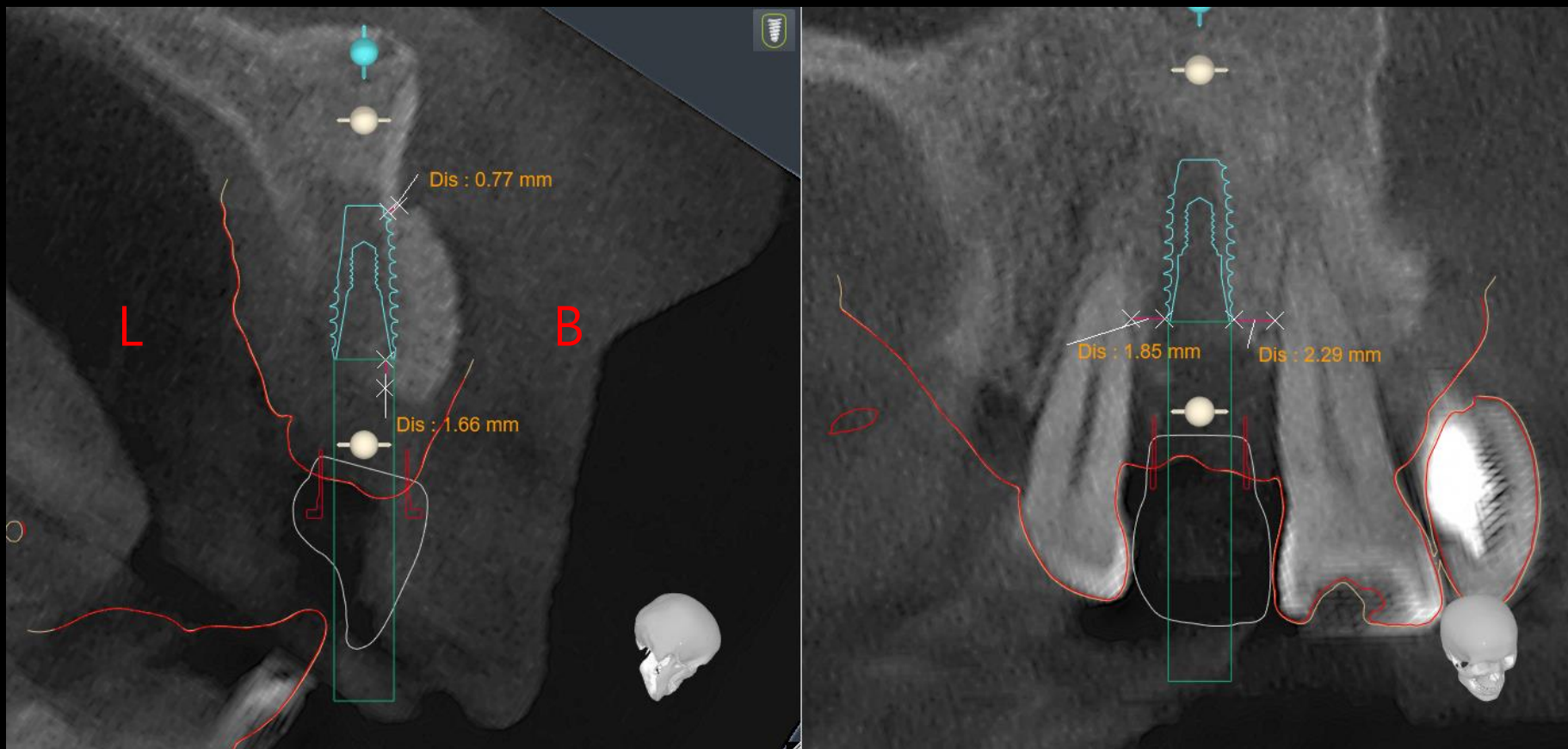


## Digital Guide S/W (Implant Planning)



# Digital Guide S/W (Implant Planning)

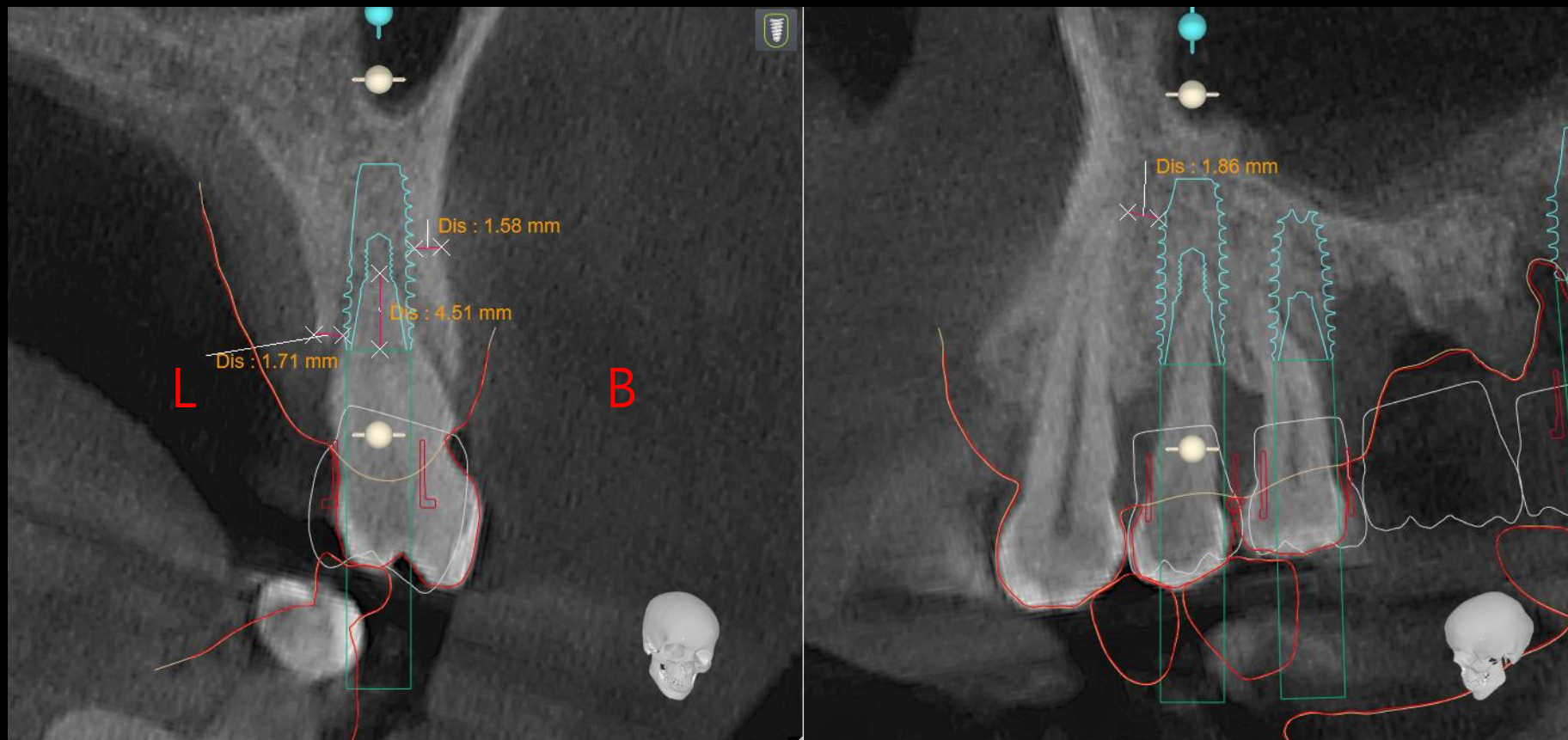
#12 (BFX3509)





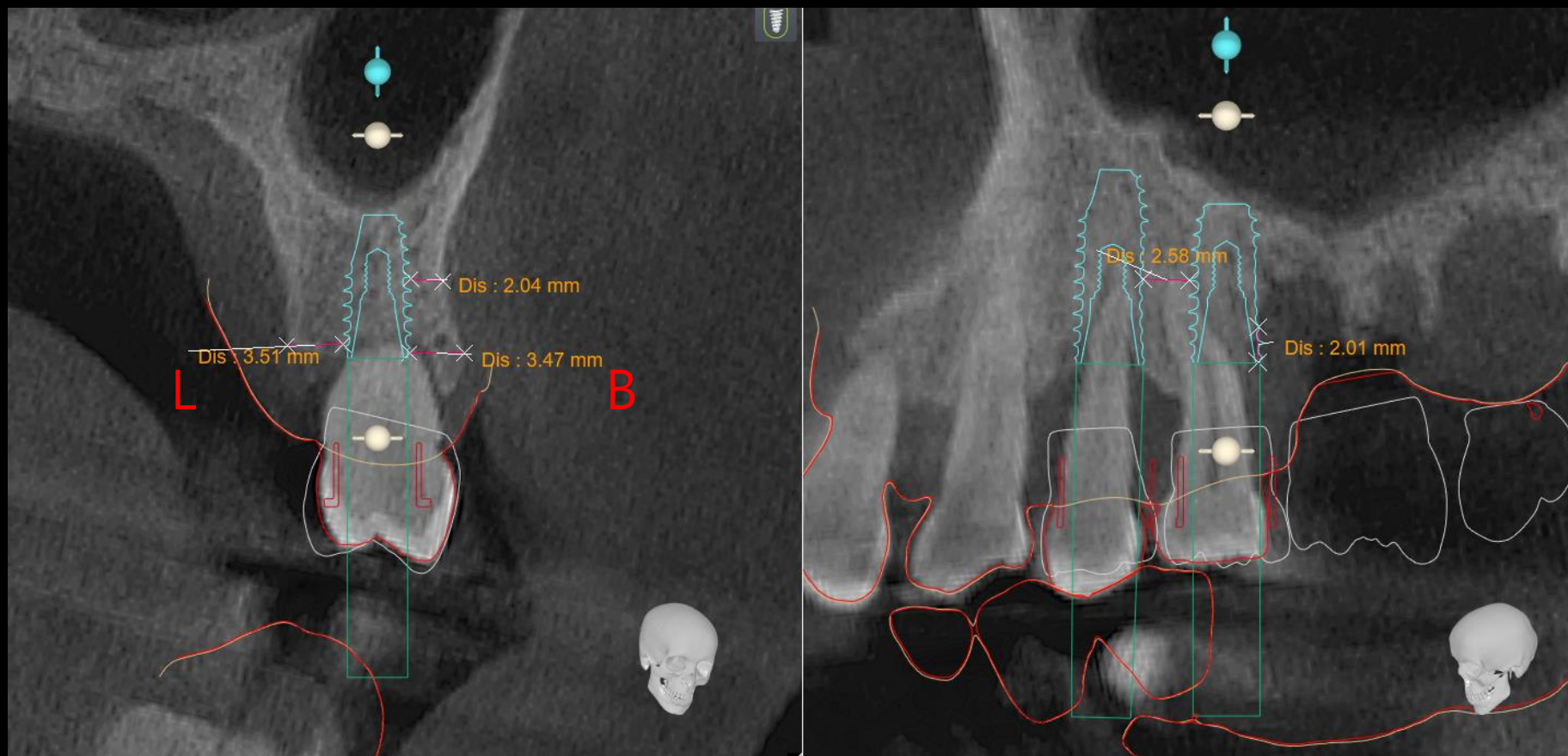
# Digital Guide S/W (Implant Planning)

#24 (BFX4011)



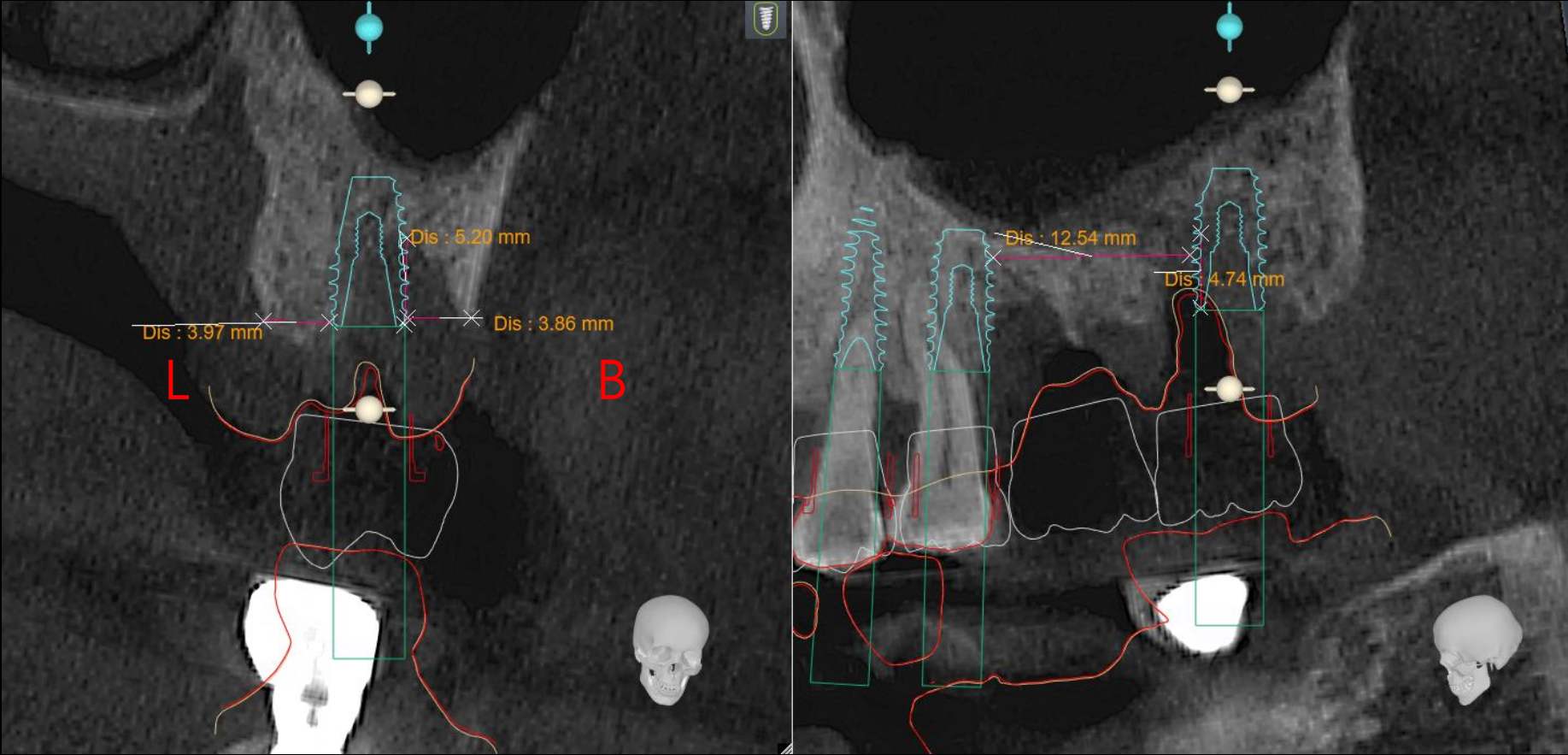
# Digital Guide S/W (Implant Planning)

#25 (BFX4009)



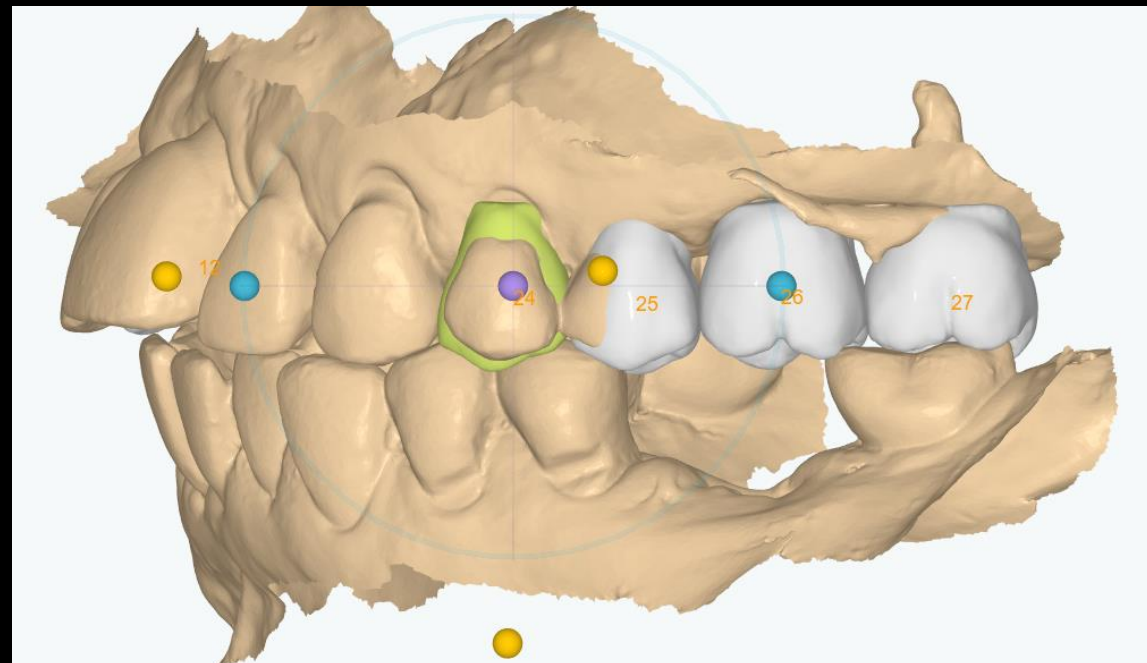
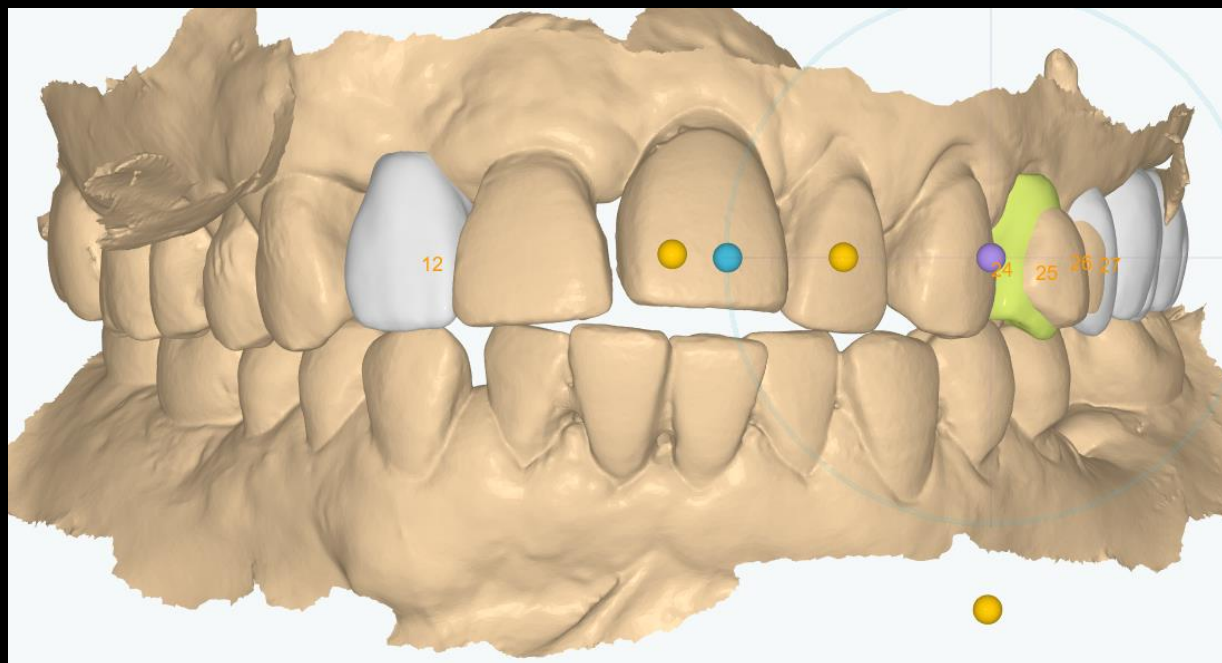
# Digital Guide S/W (Implant Planning)

#27 (BFX4509)

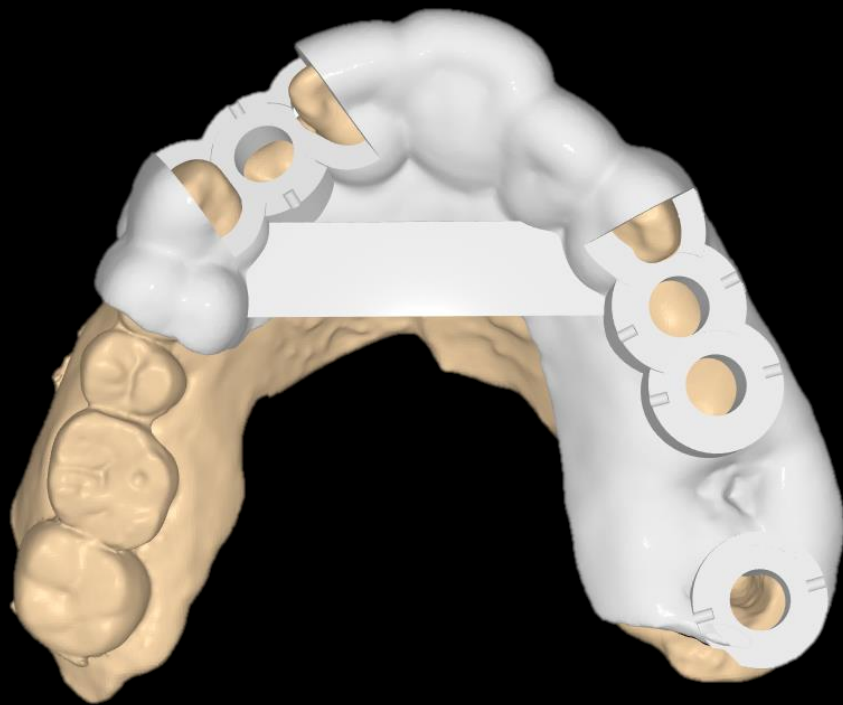




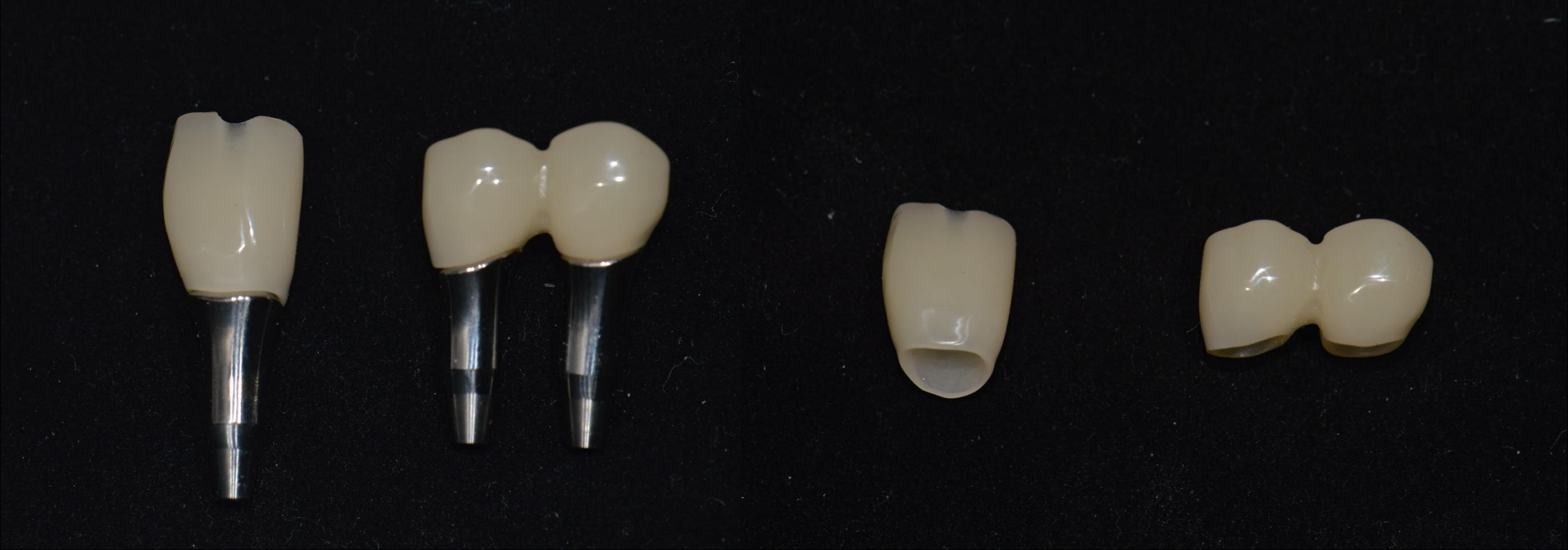# Digital Guide S/W (Virtual Set-up)



# Digital Guide S/W (Surgical Guide design)



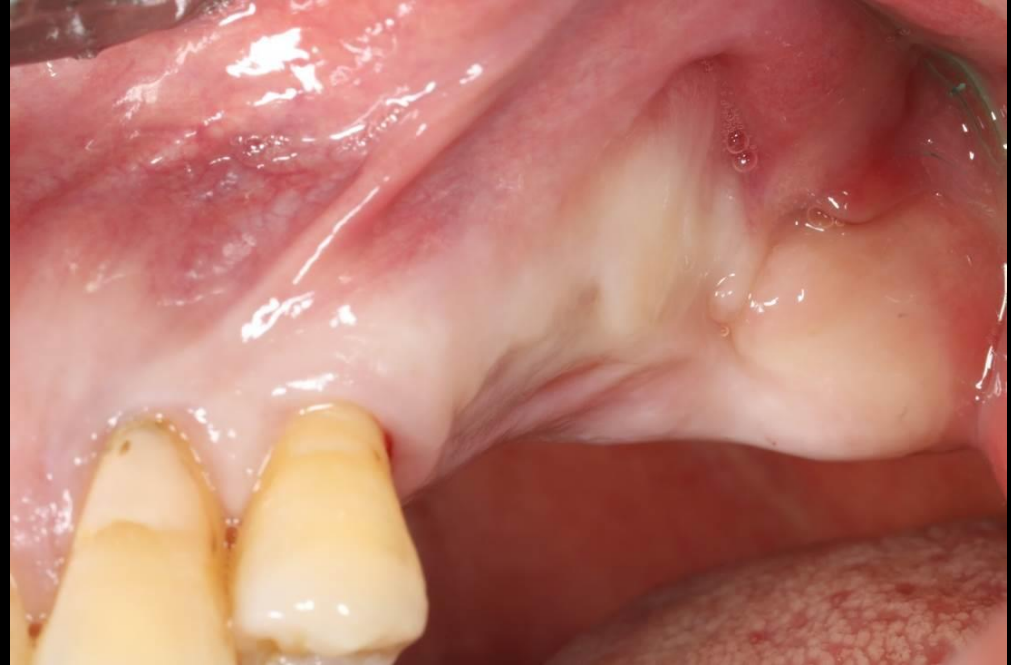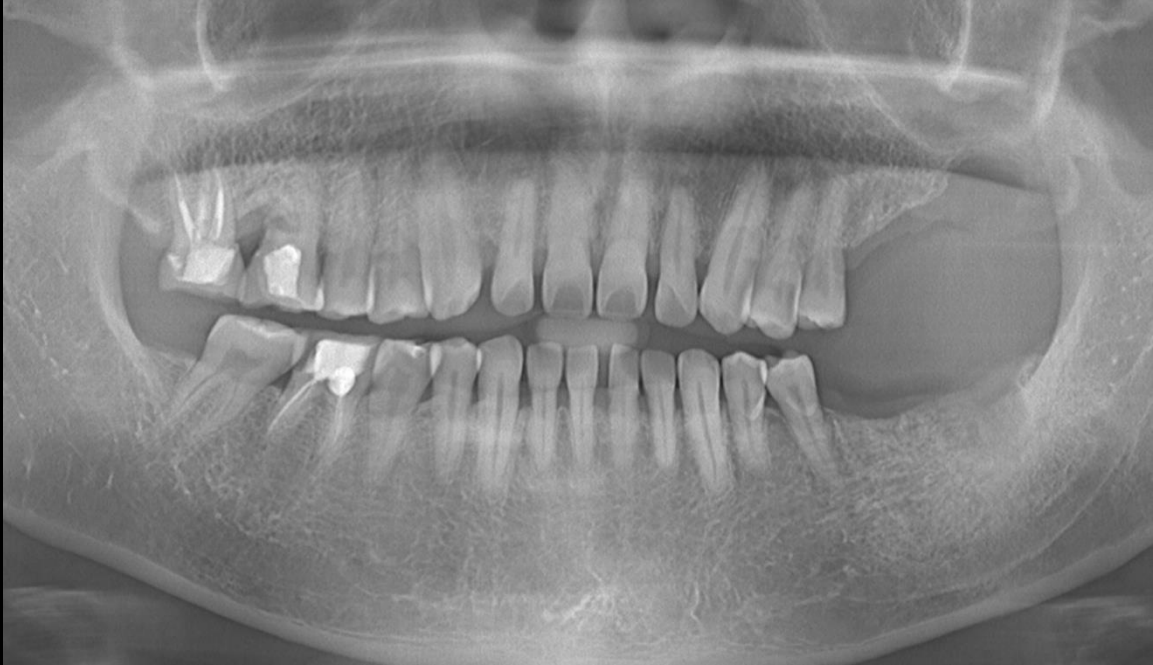Customized abutment & Provisional restoration





**Similar case**

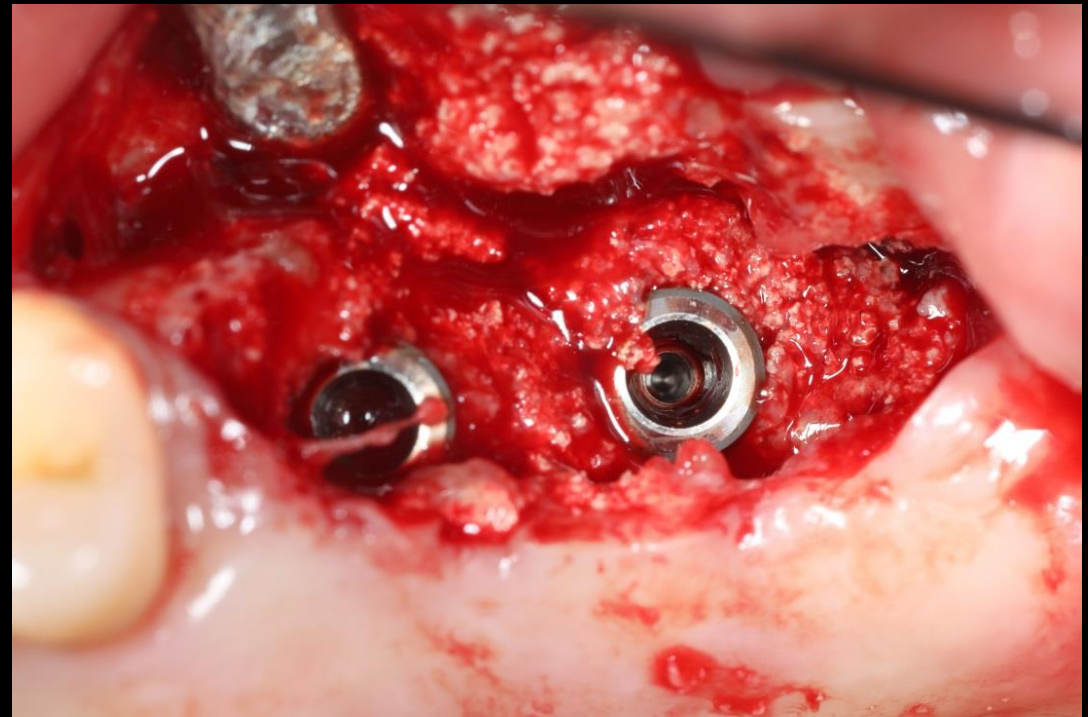
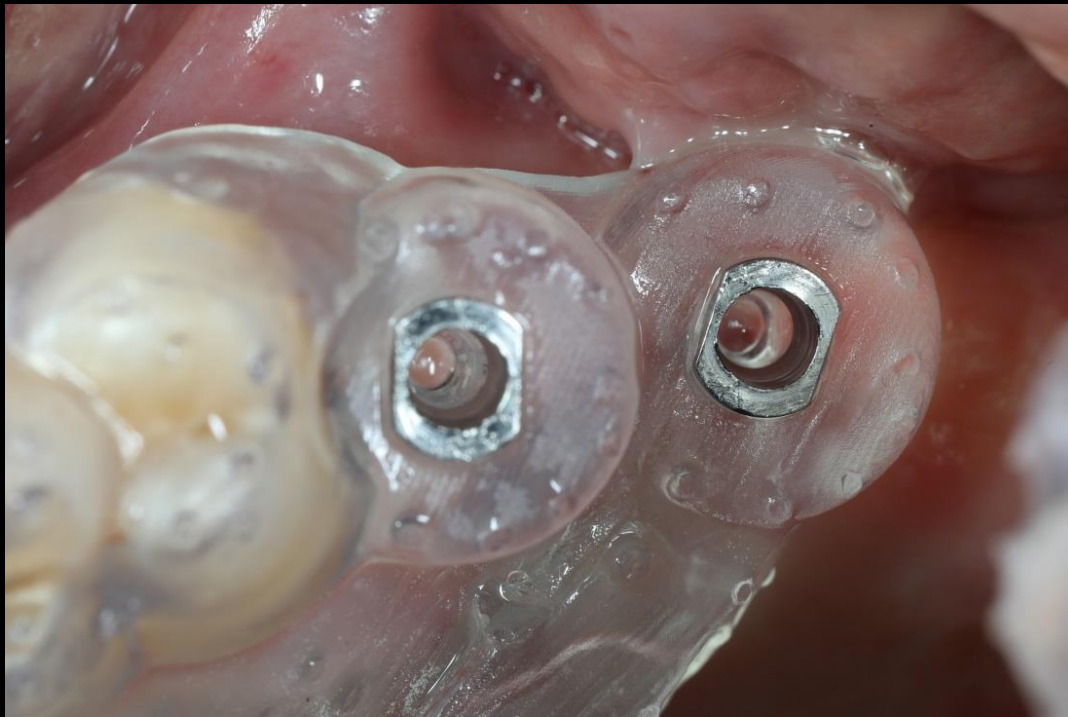**Implant placement with GBR**



Pre-op (2017-06-07)

**Similar case**

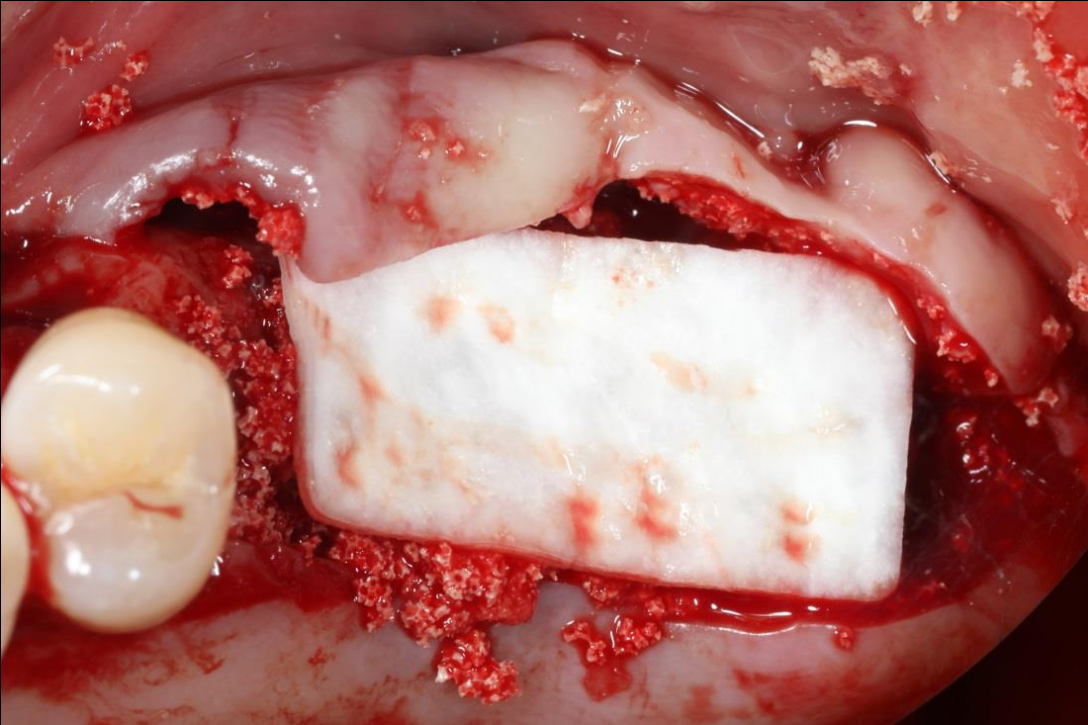
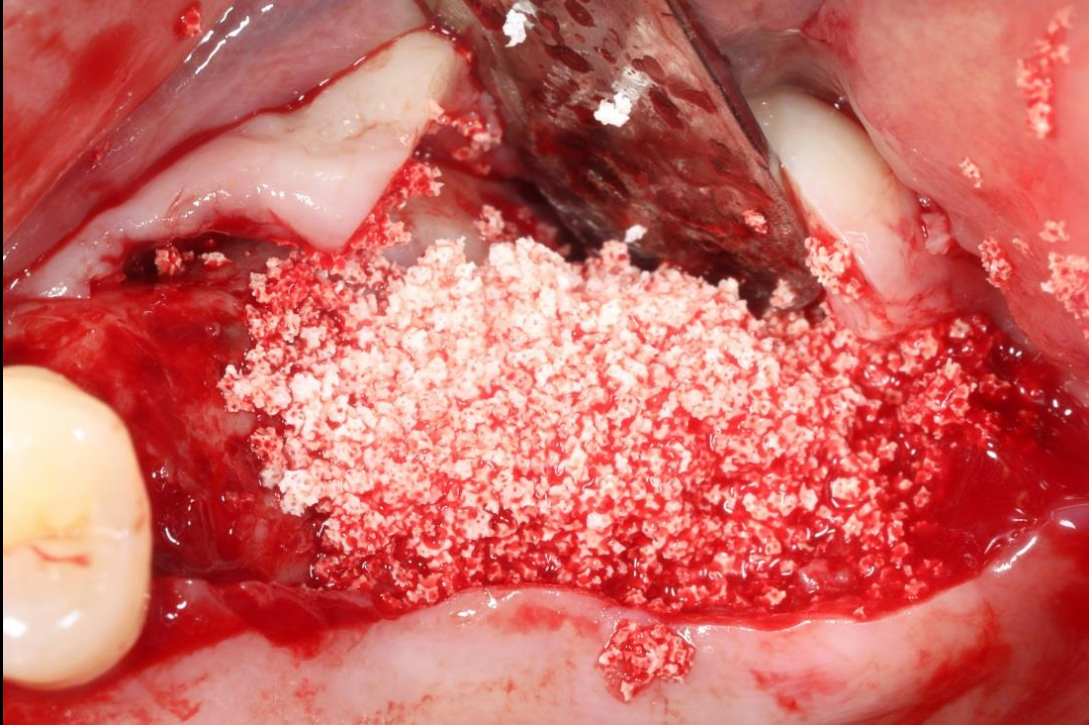
**Implant placement with GBR**





**Similar case**

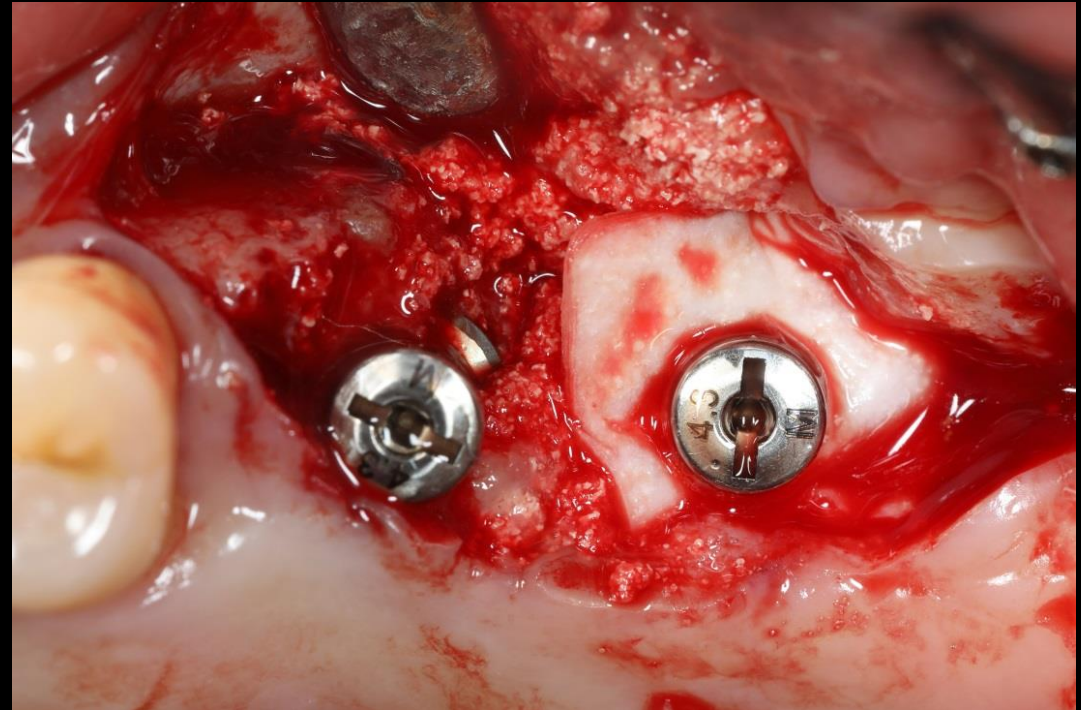
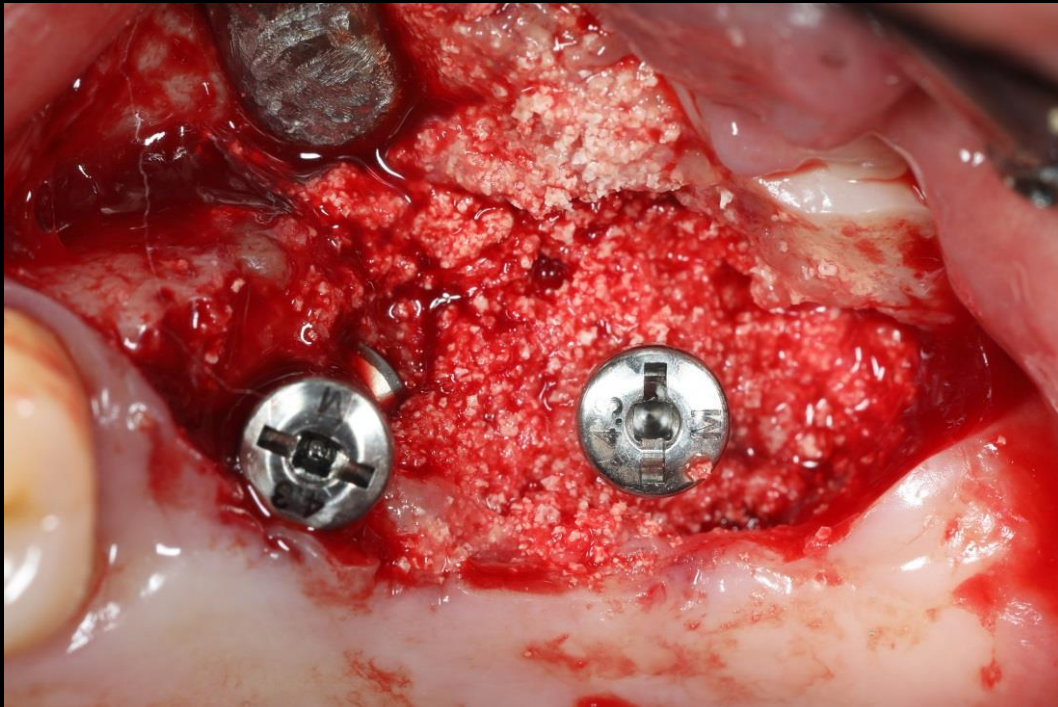
**Implant placement with GBR**





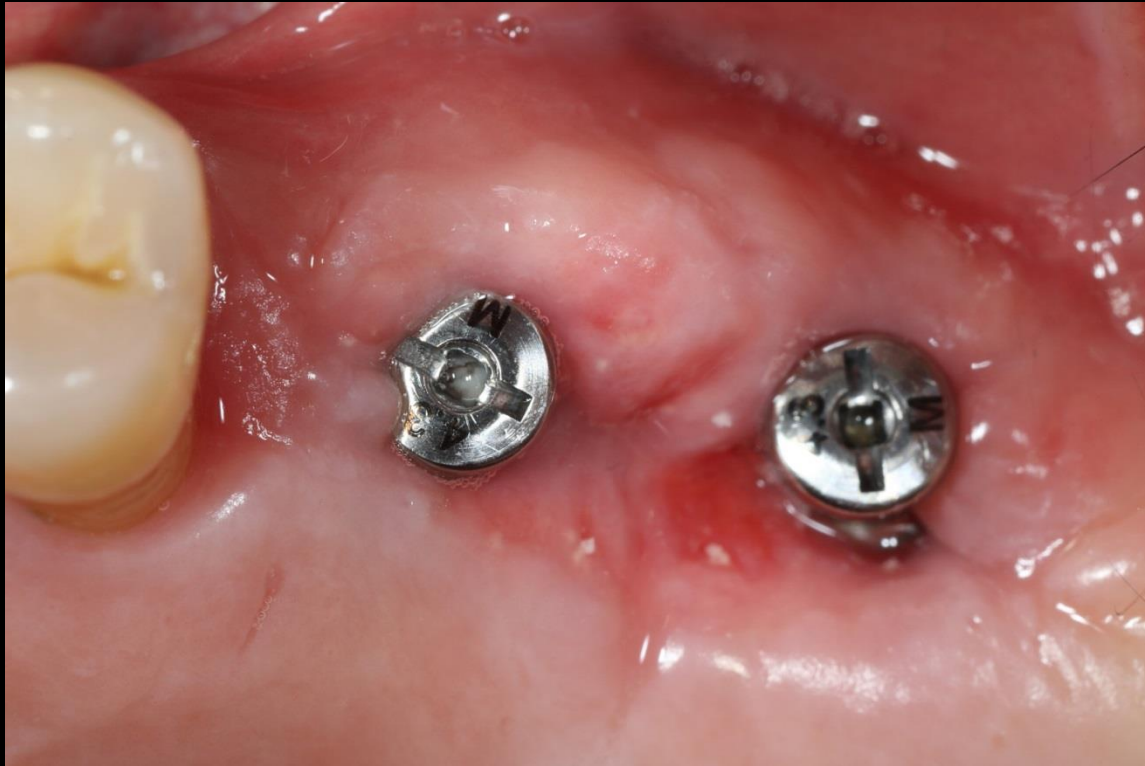**Similar case**

**Implant placement with GBR**

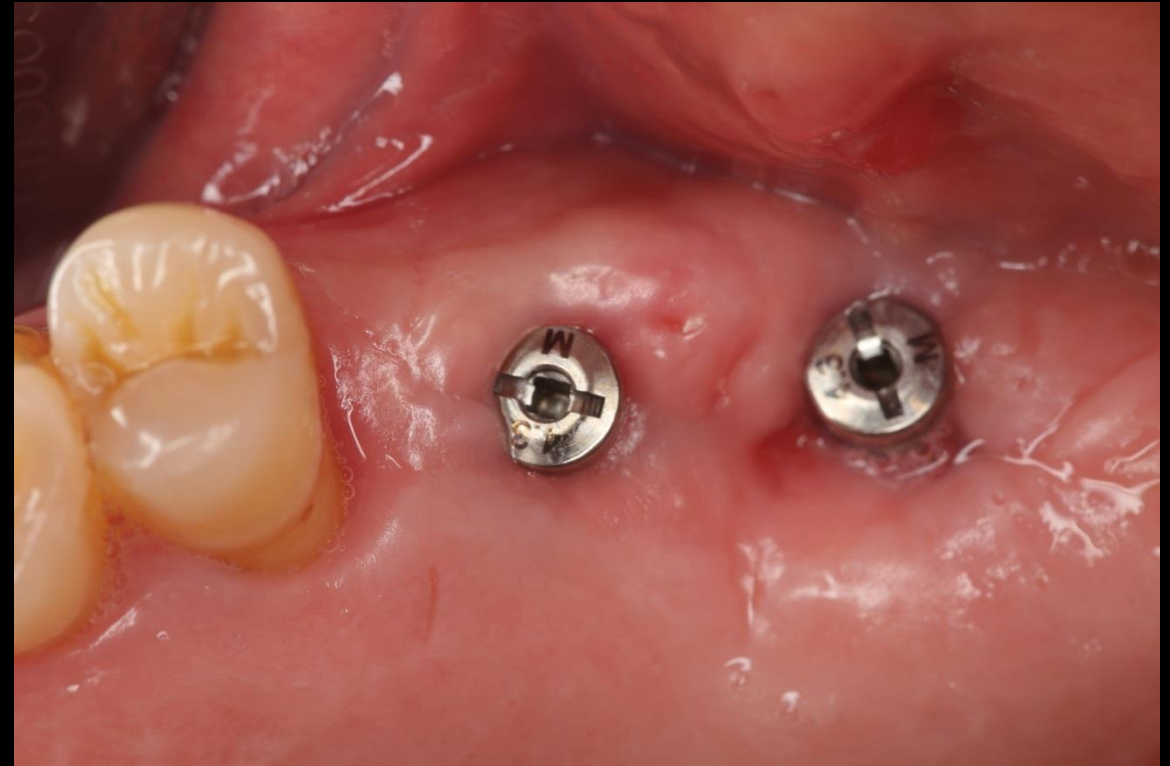

**Similar case**

**Implant placement with GBR**



Healing : 1 month 1 weeks  
(2018-01-24)

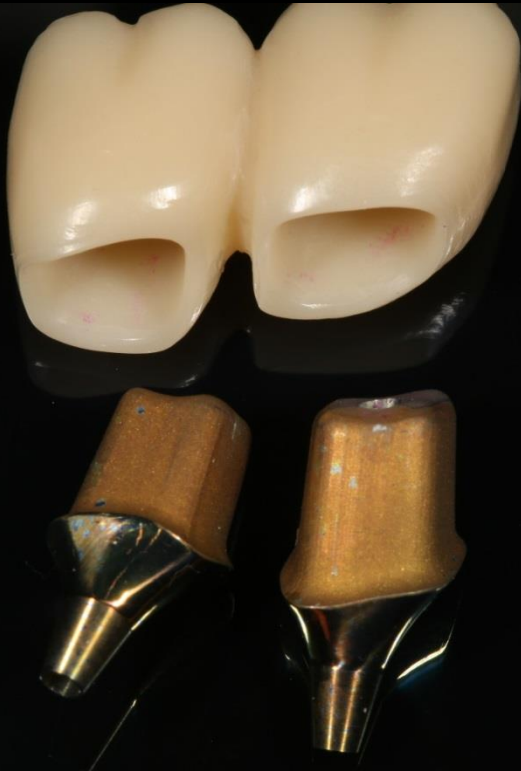

Healing : 2 month 2 weeks  
(2018-02-26)

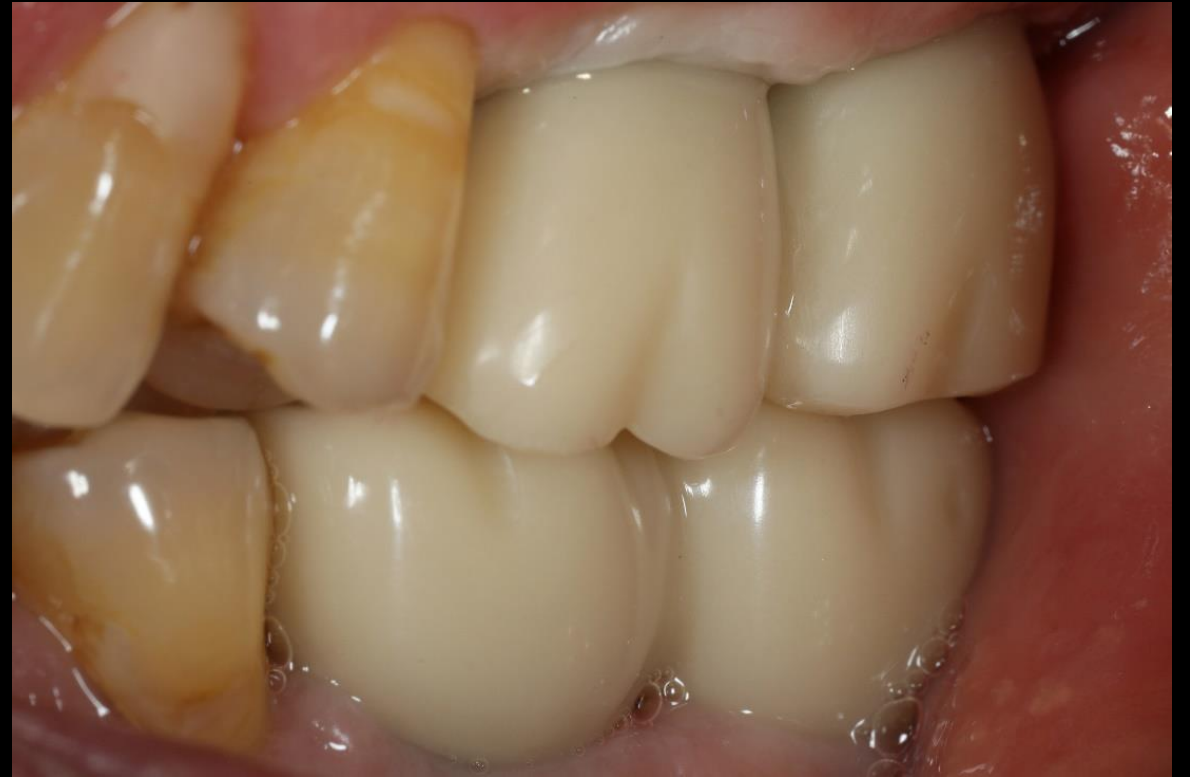

**Similar case**

**Implant placement with GBR**



Temporary

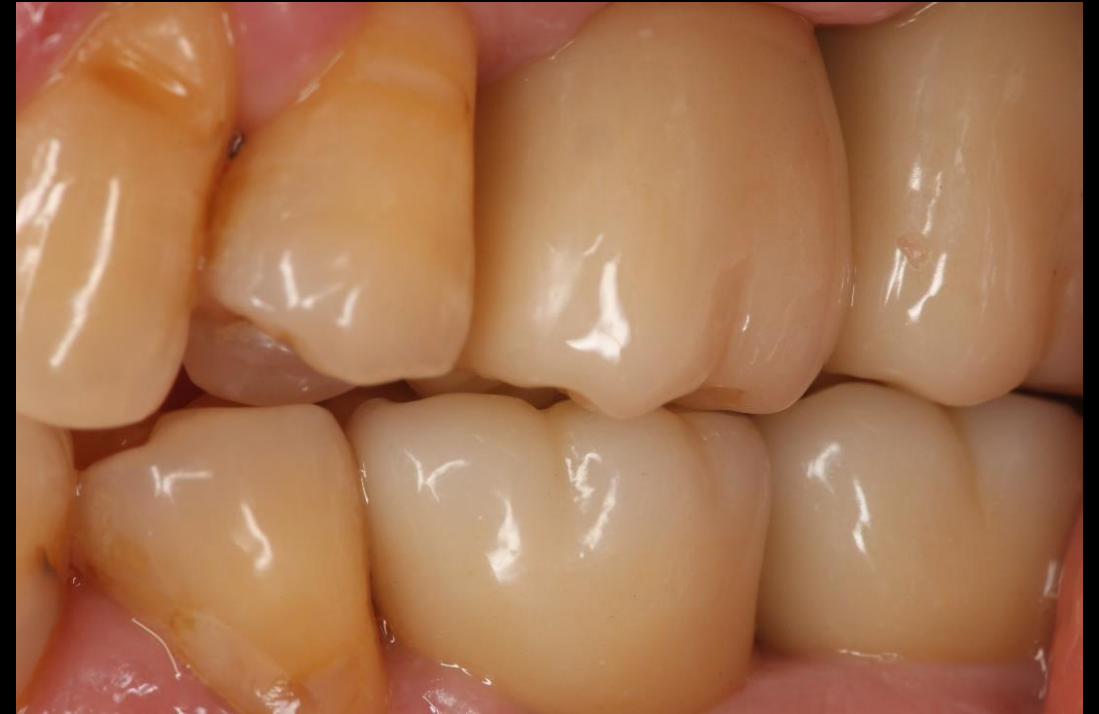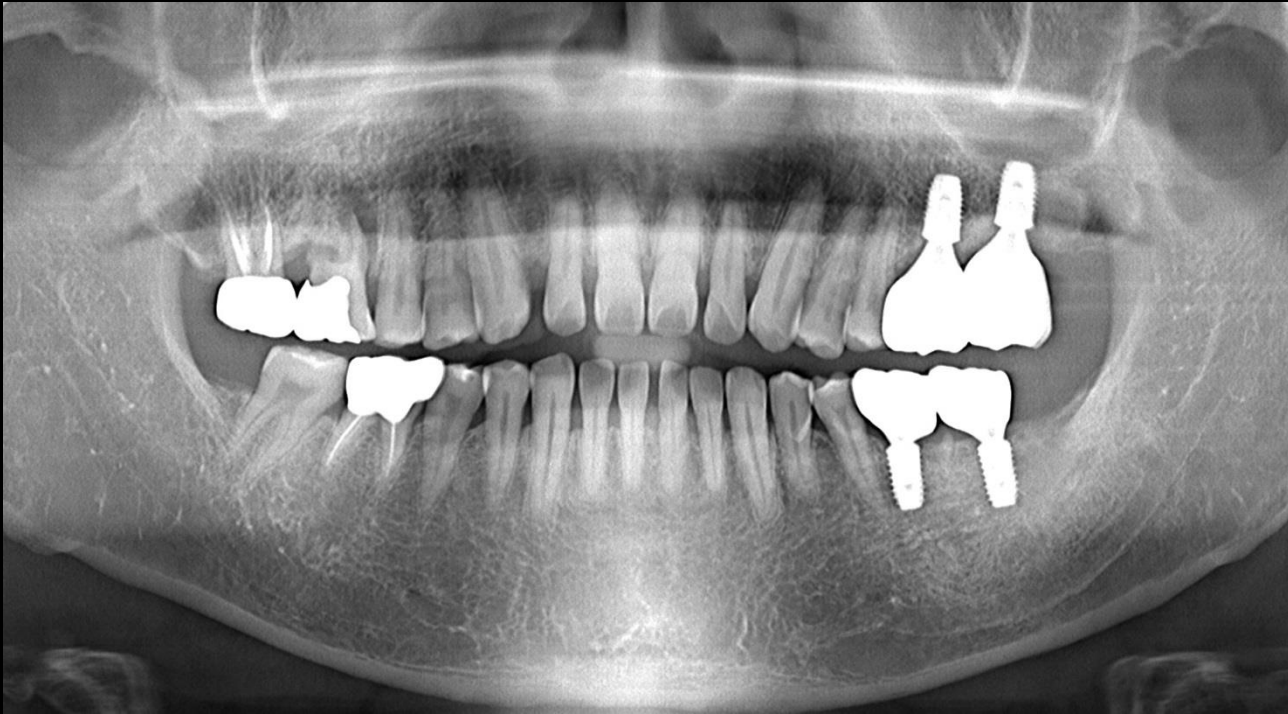


Provisional restoration  
(2018-03-15)



**Similar case**

**Implant placement with GBR**



Final prosthesis (2018-05-21)

