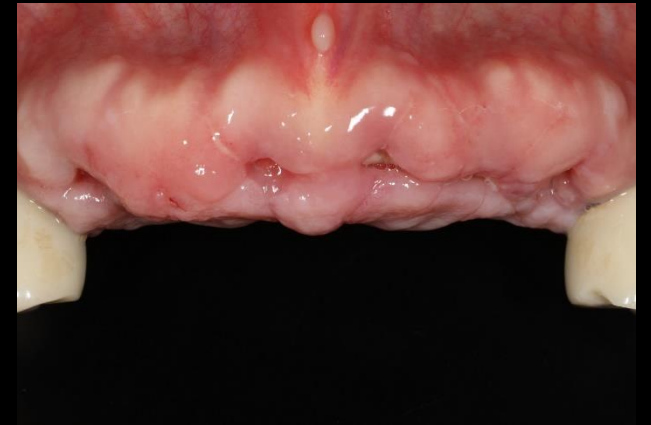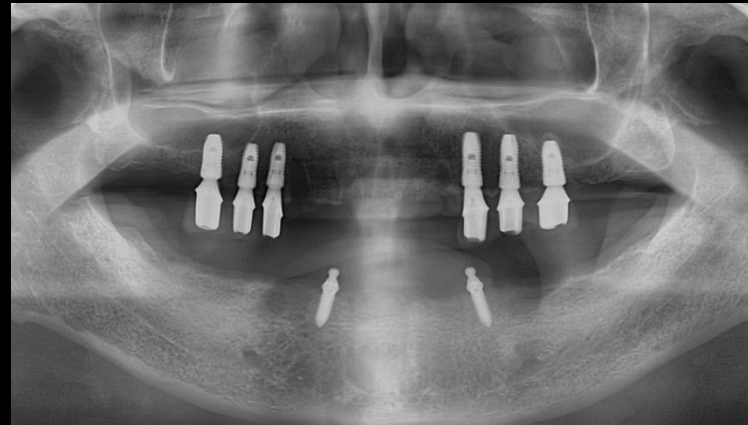




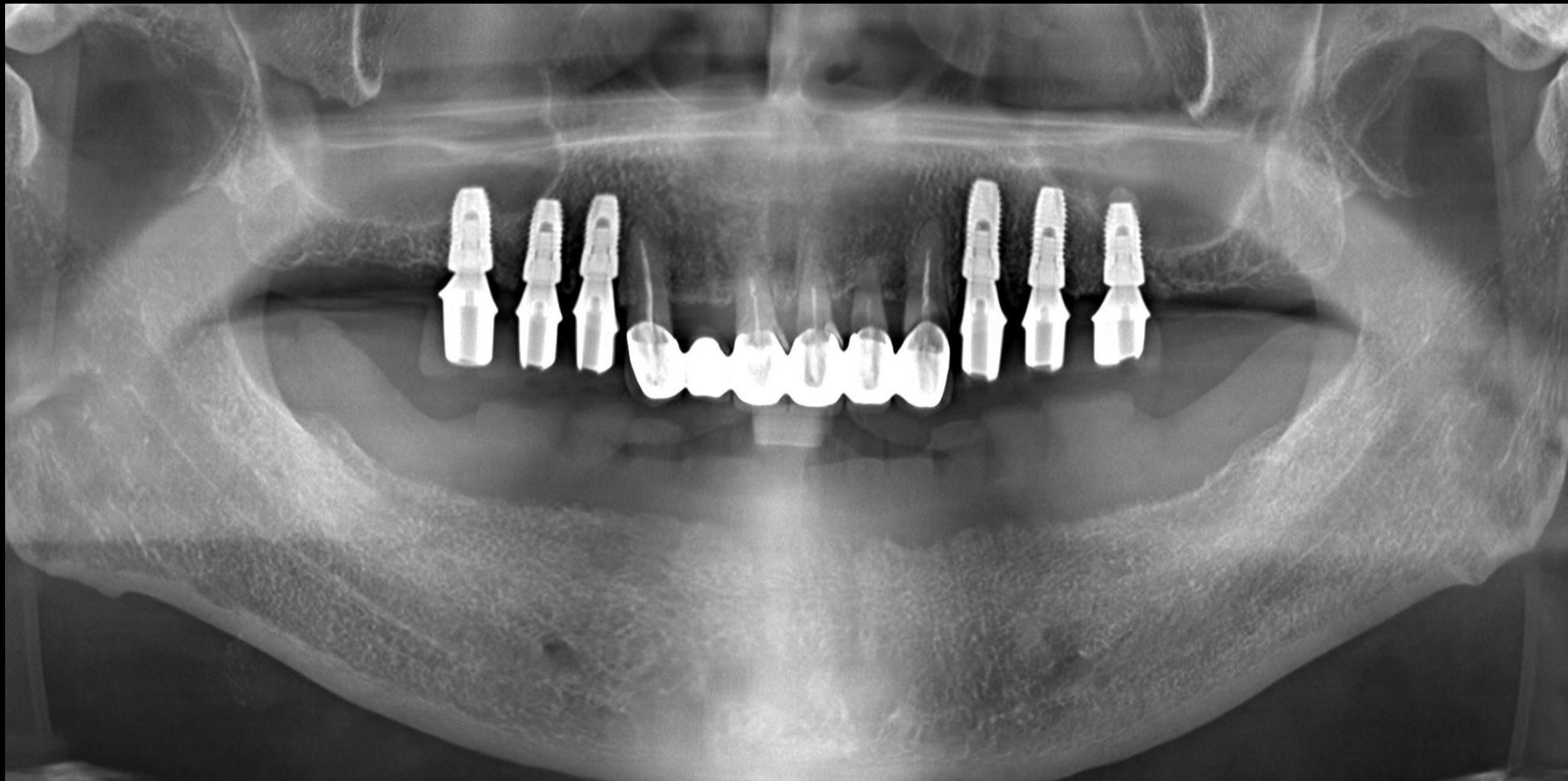
# Upper Anterior implant placement With Minimalism

Dr. SM Chung  
2021.10.8 (Fri)

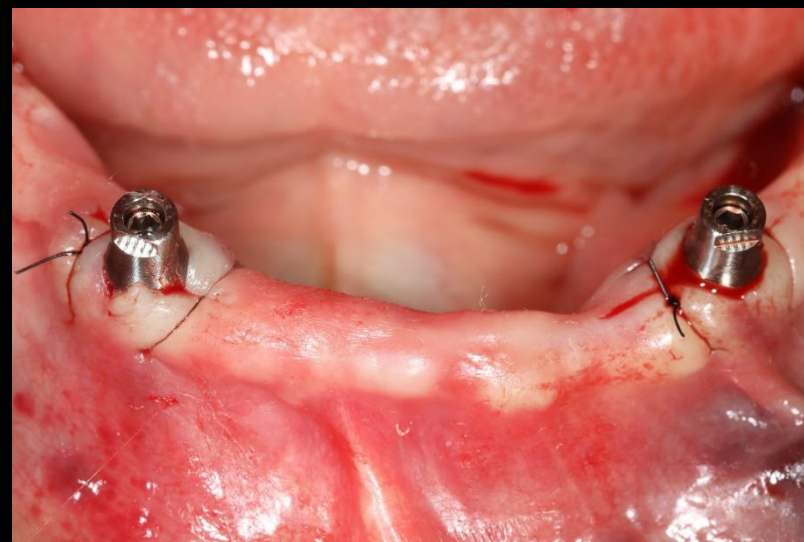
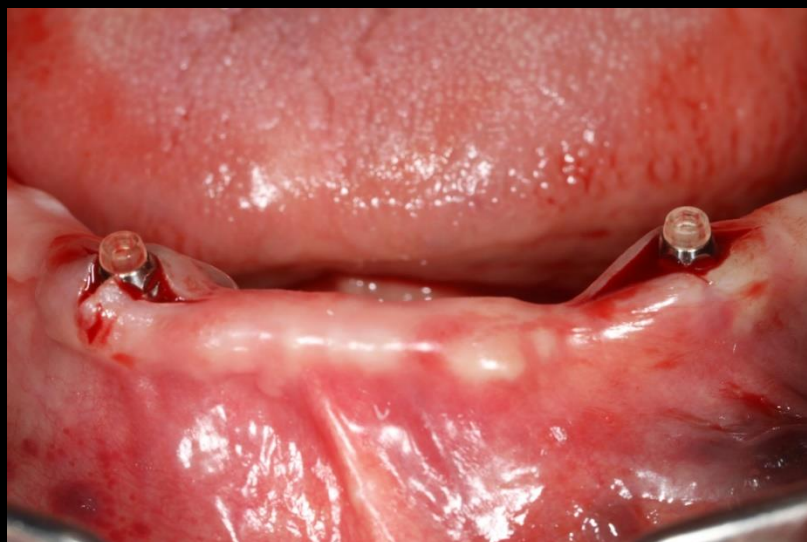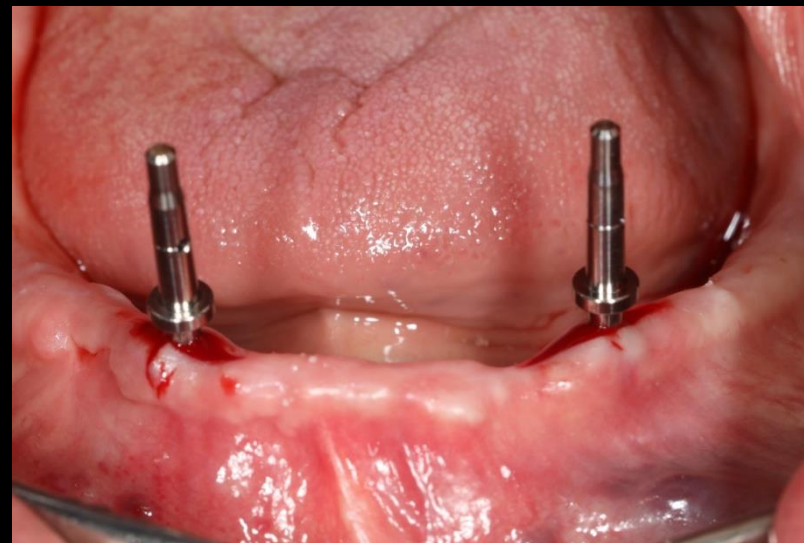

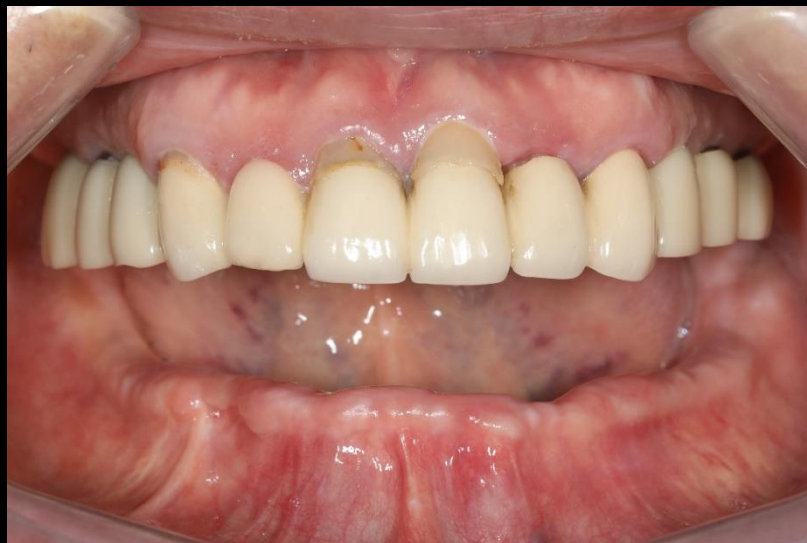
77yrs / Male

Oral exam (2019-11-12)

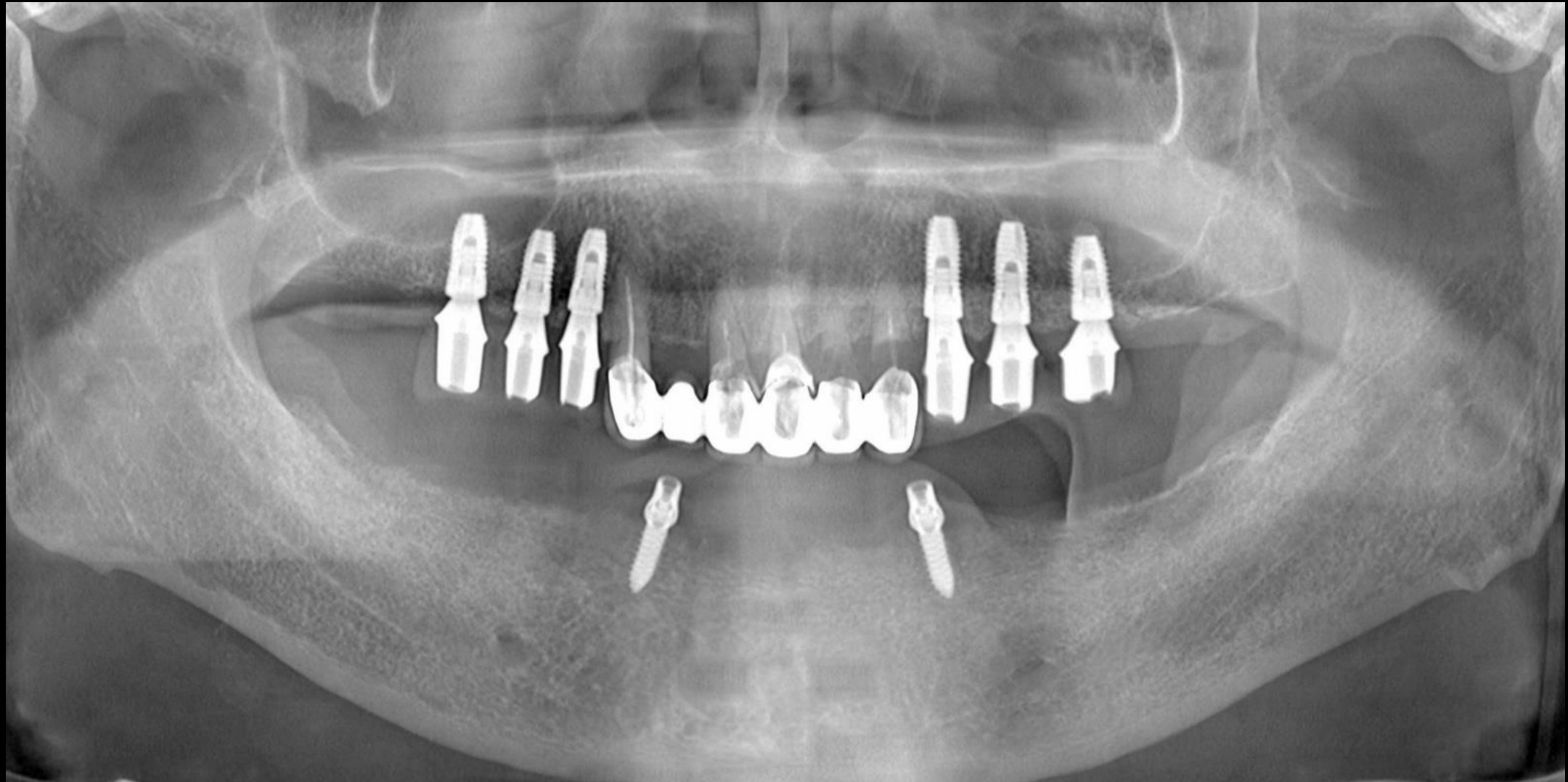


#34,43 Surgery (2021-05-06)

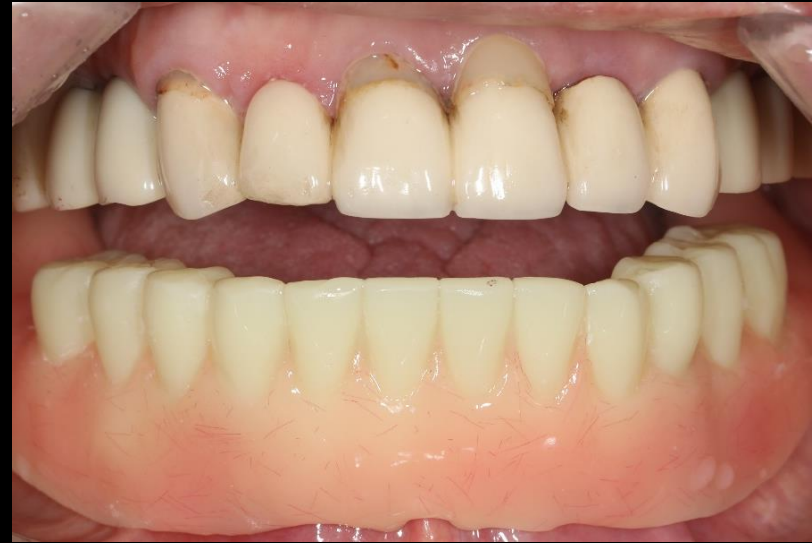
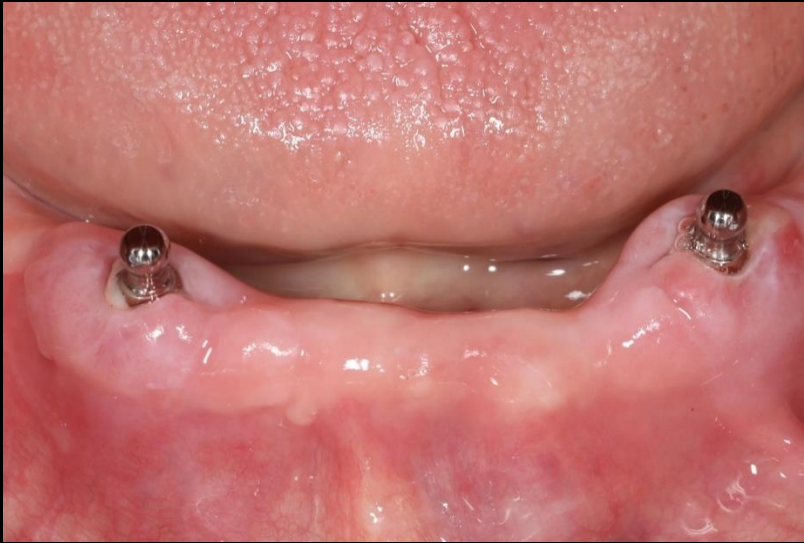
77yrs / Male

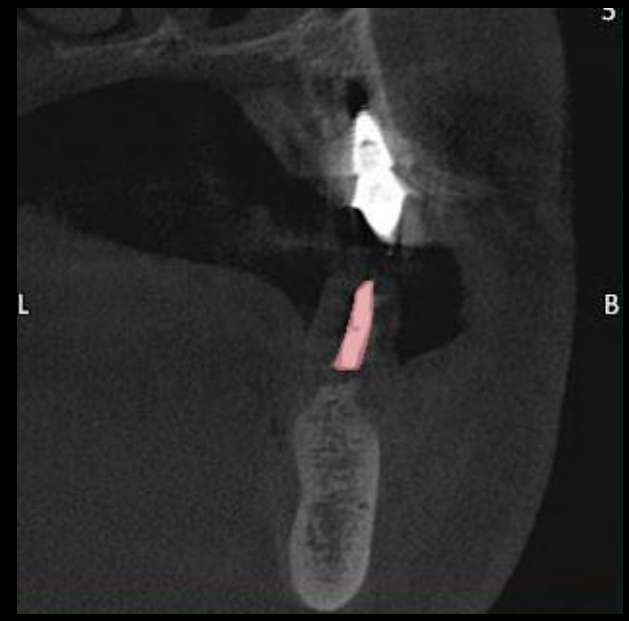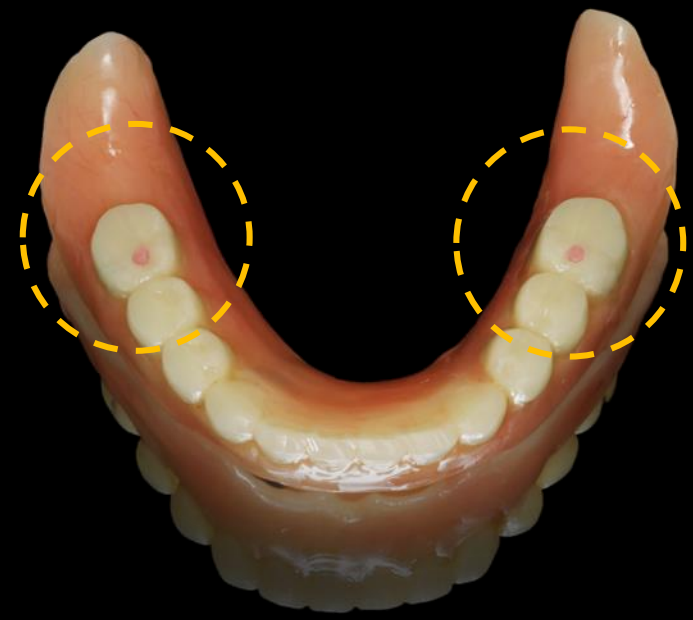
#34,43 Post-op (2021-05-13)



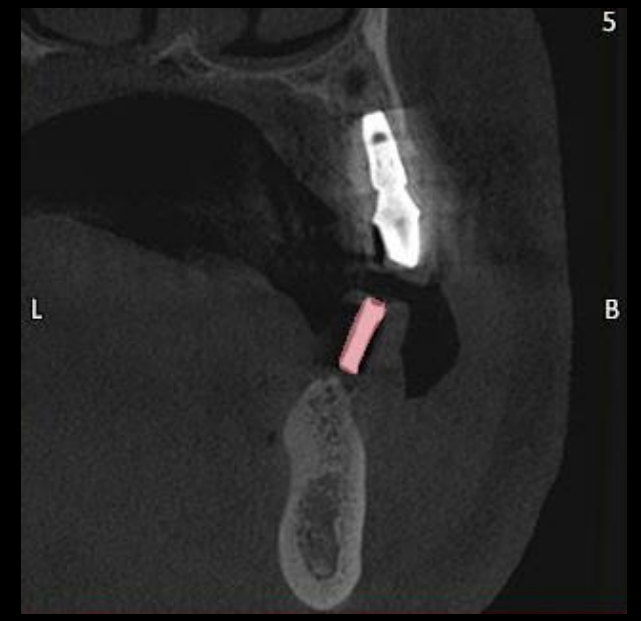**Ball attachment & 3D Printing Denture (2021-08-18)**



# GP cone marking & CT taking (2021-10-06)



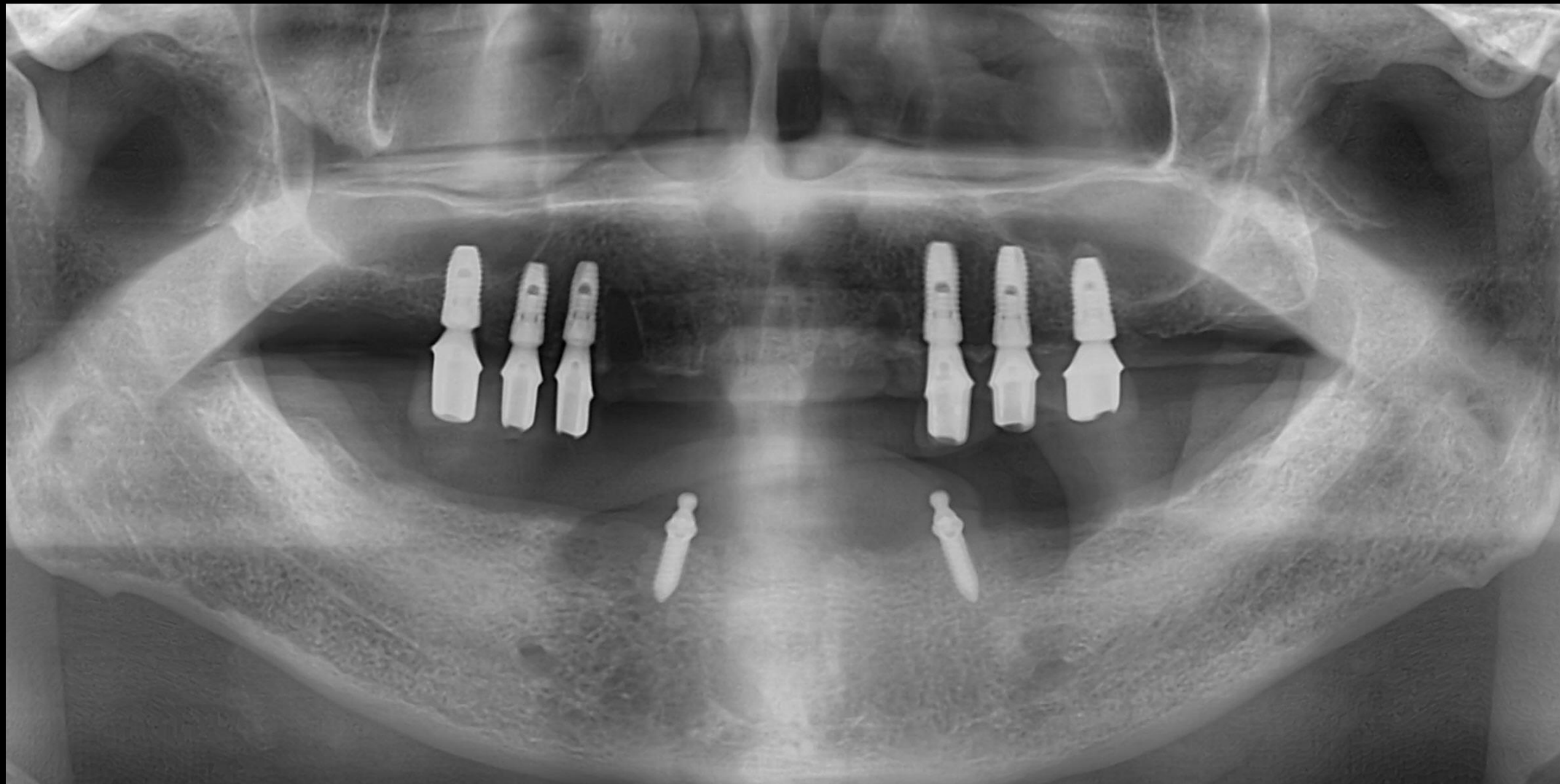
#36



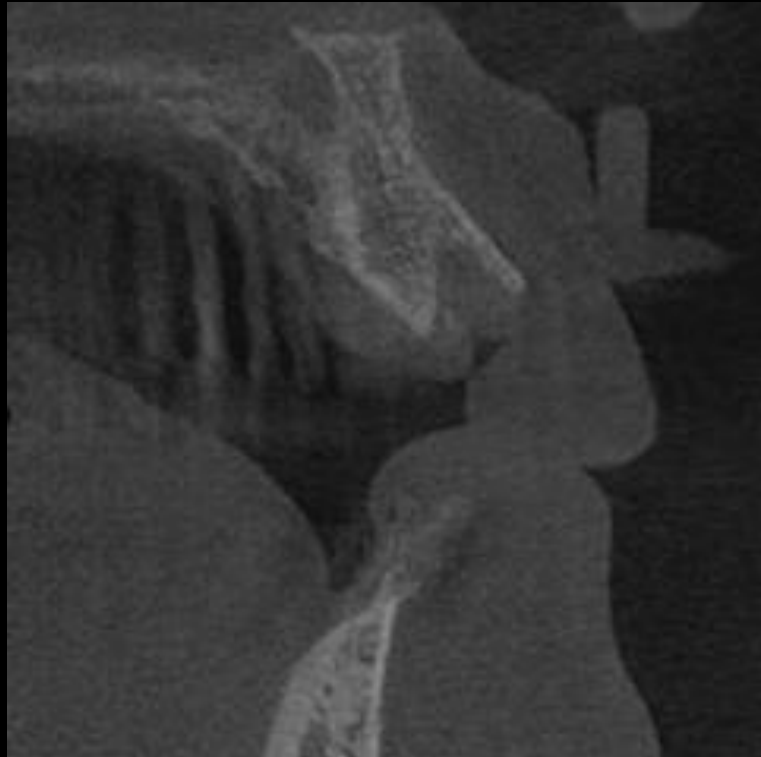
#46

77yrs / Male

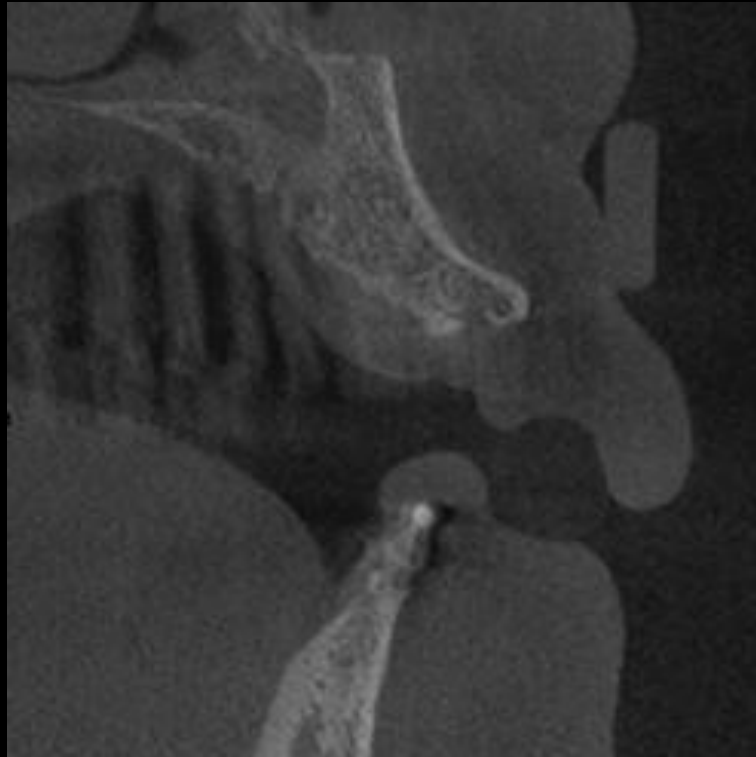Pre-op (2021-09-23)



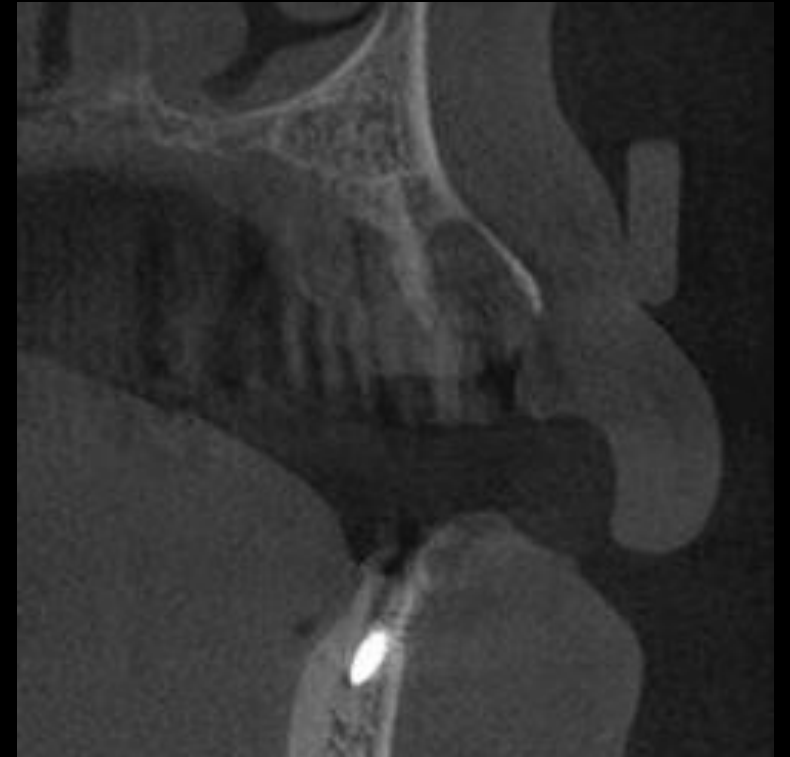
Pre-op (2021-09-23)



#11



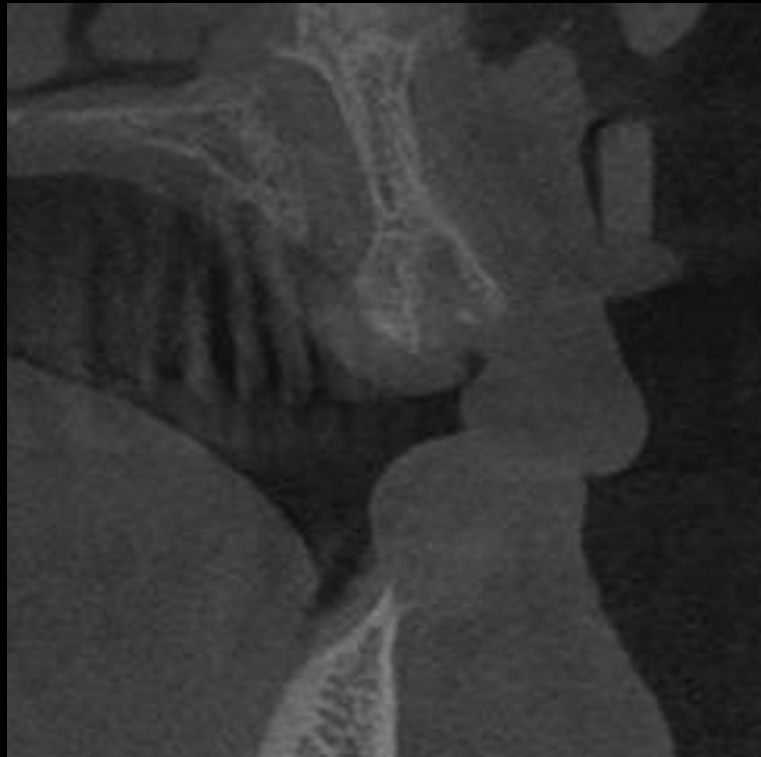#12



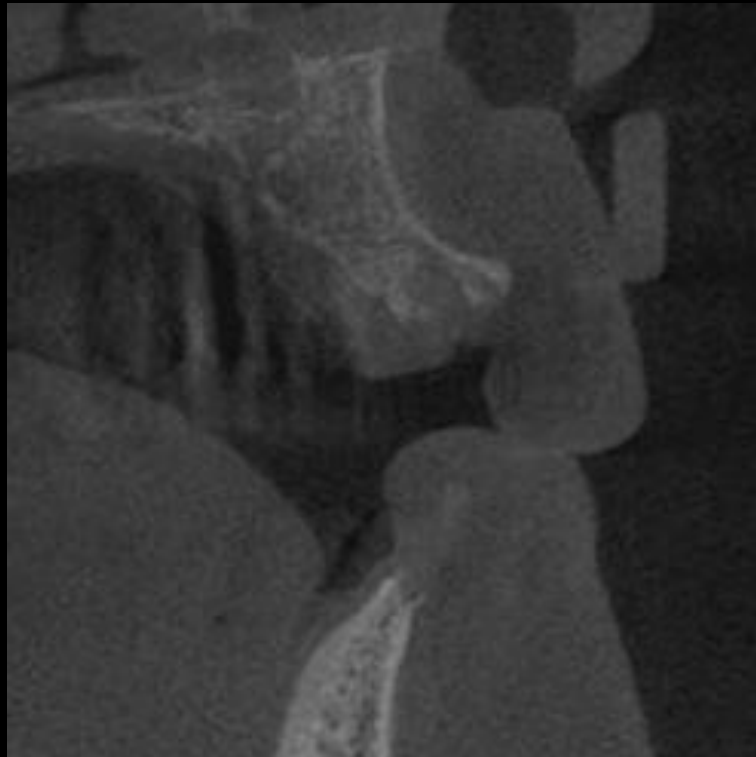
#13



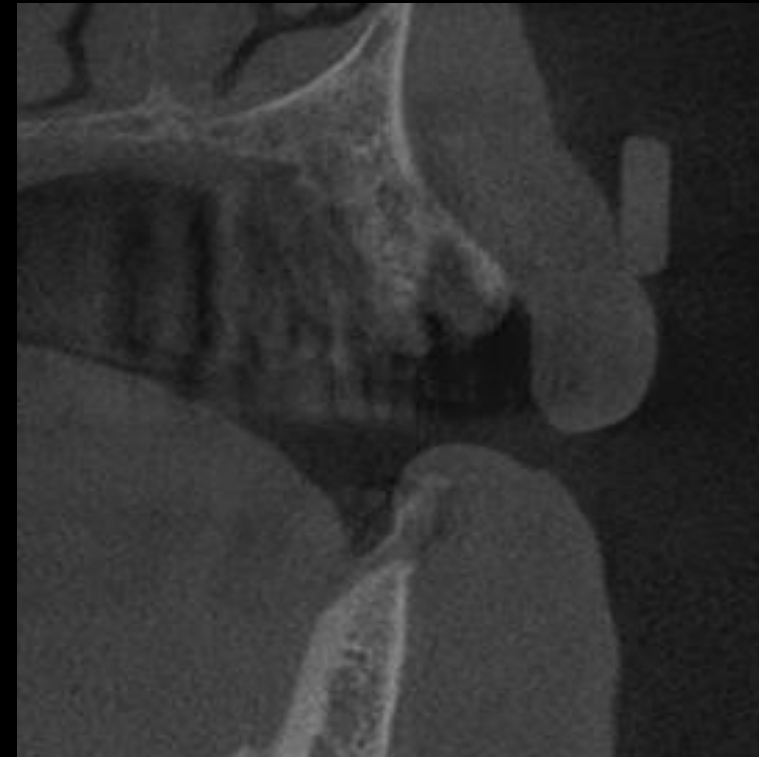Pre-op (2021-09-23)



#21

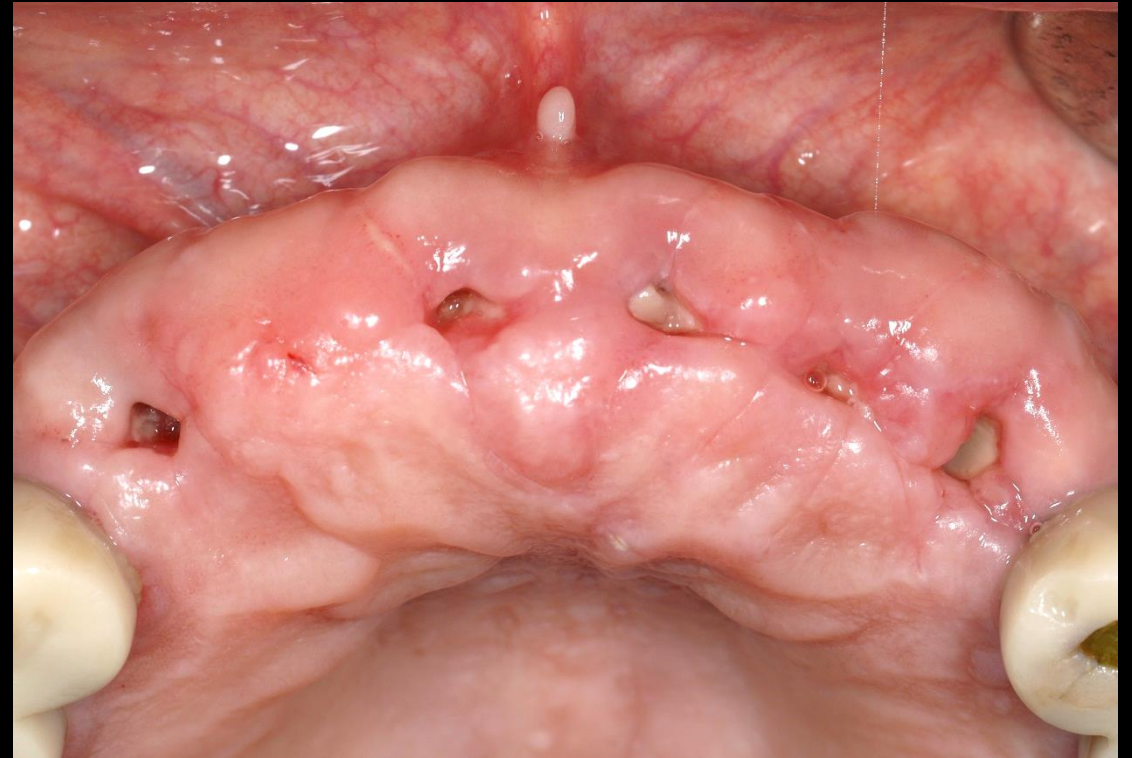
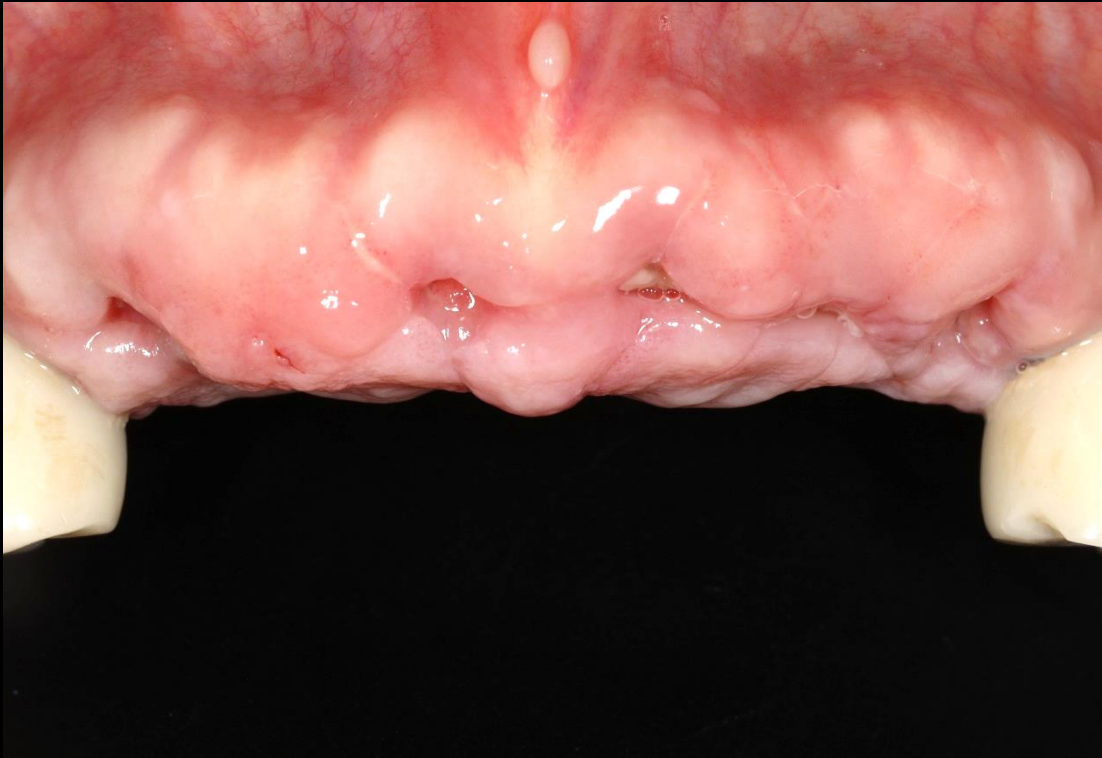
#22

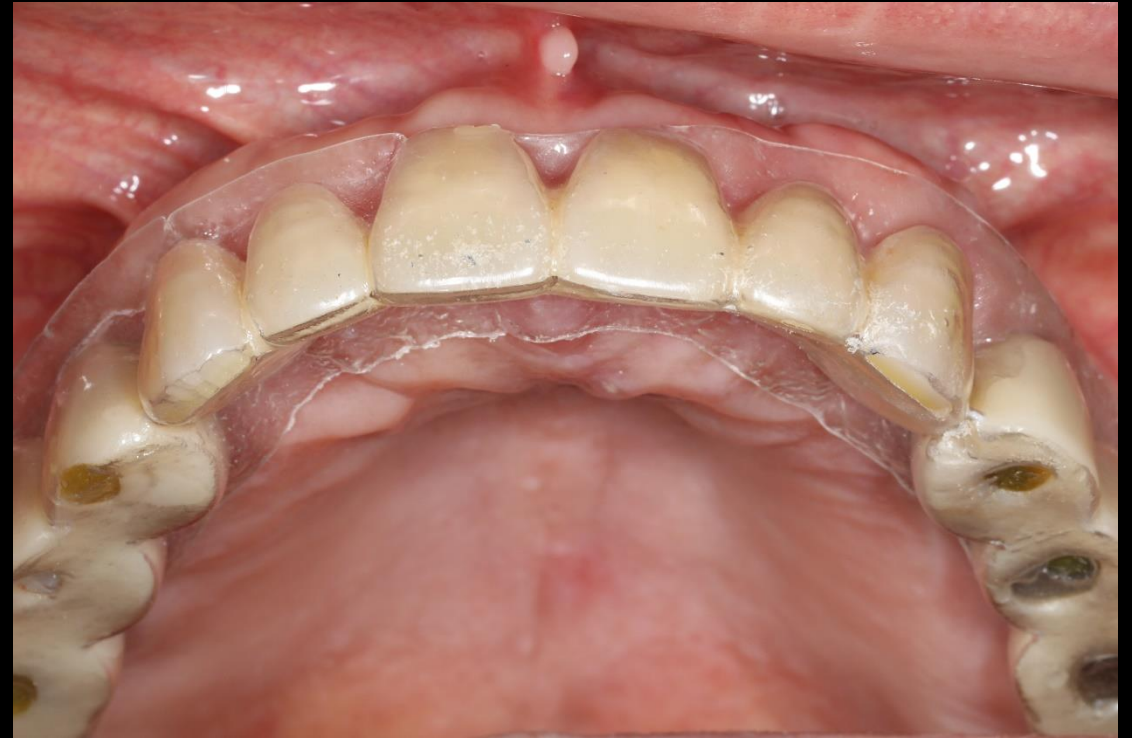
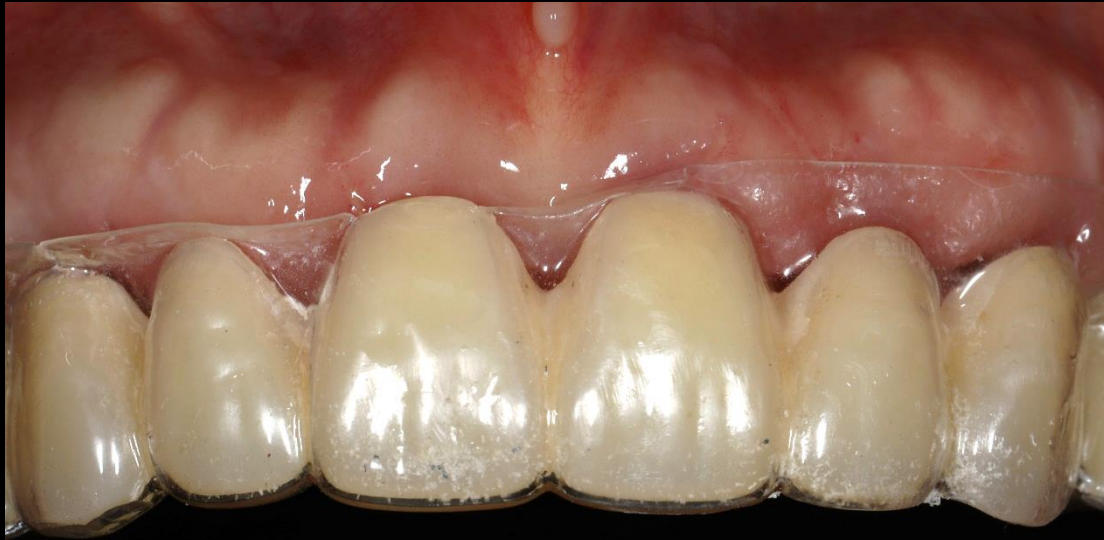
#23

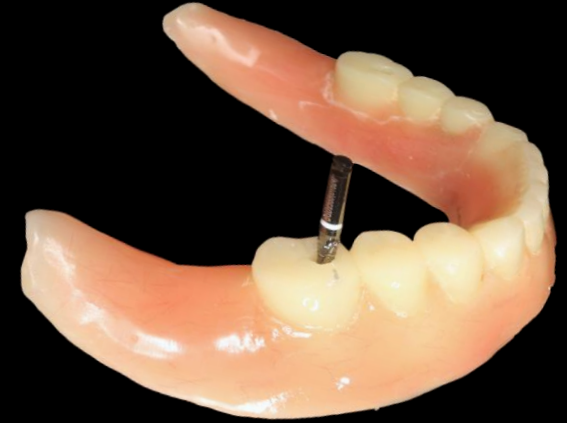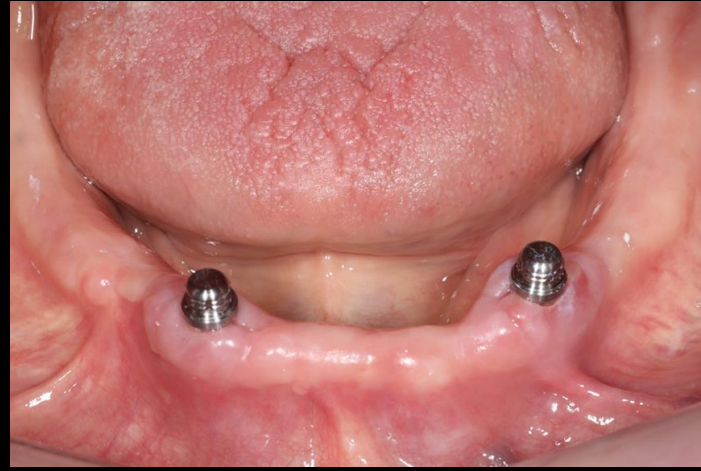
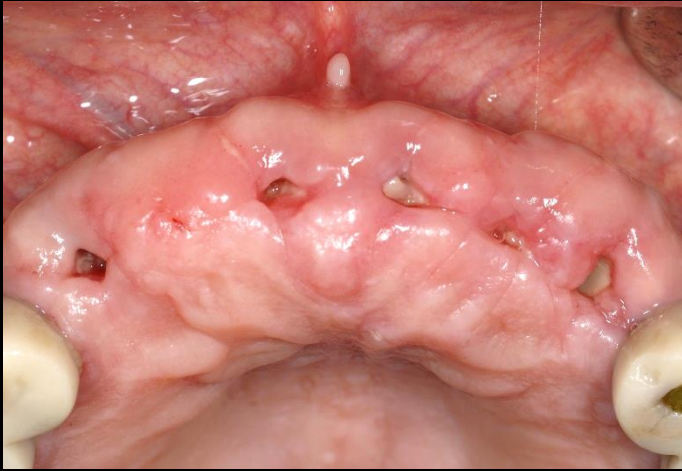
Healing : 1 week (After #11,13,21,23 Extraction) (2021-09-13)



Essix retainer (2021-09-23)



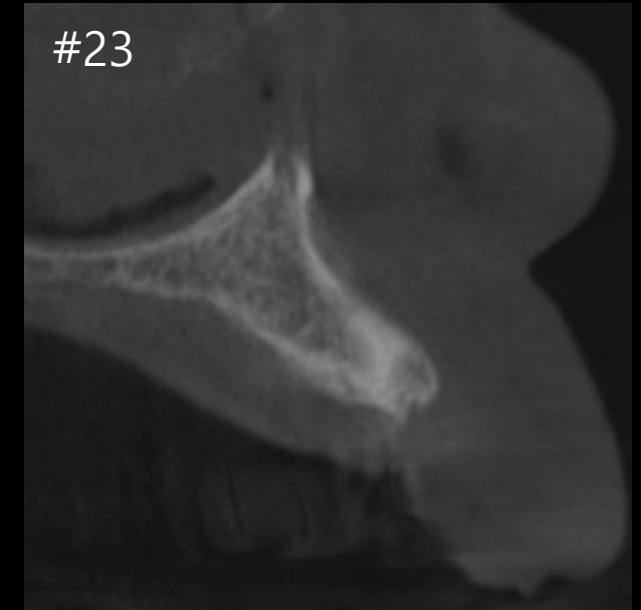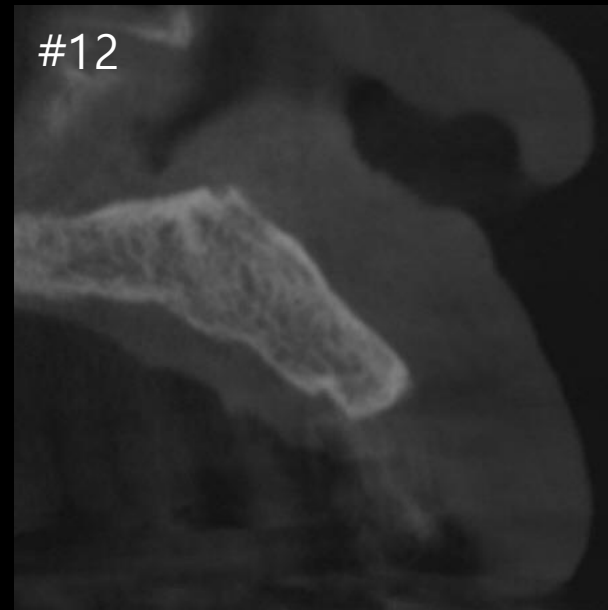
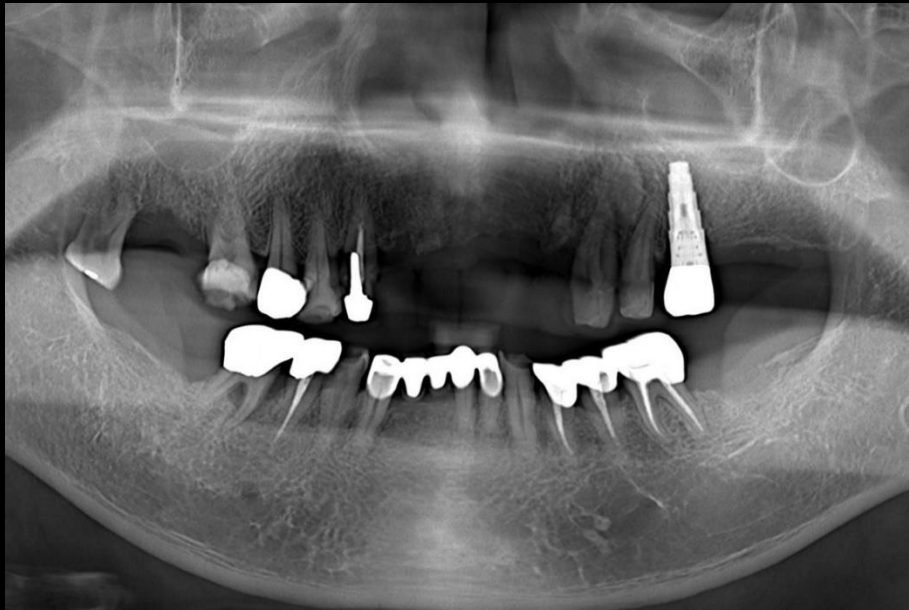## Surgery Plan (#12,22,36,46)



- #12,22 Implantation with bright Implant
- #36,46 Implantation using 3D Printing denture

## Similar case

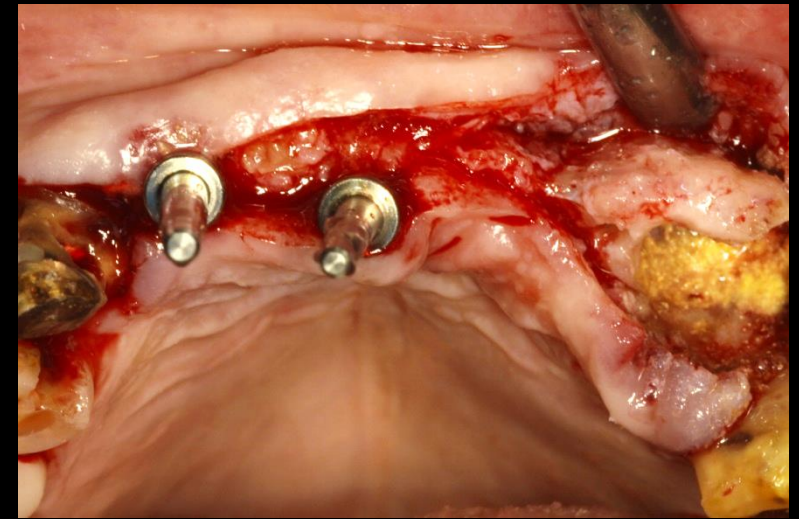
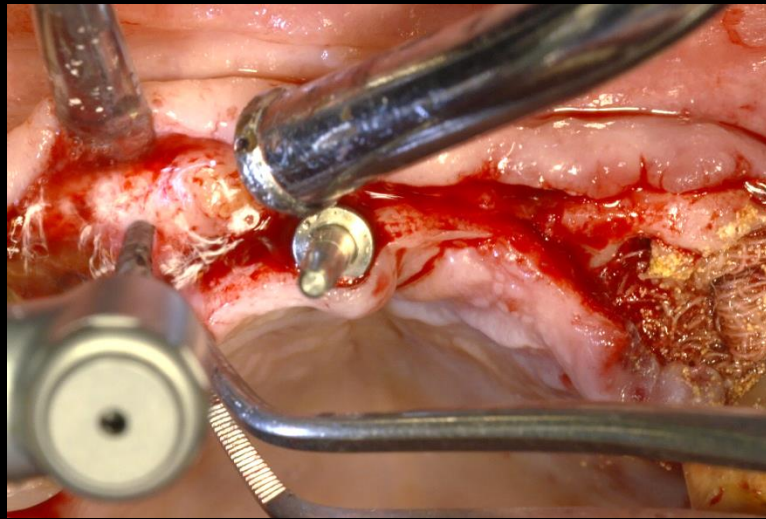
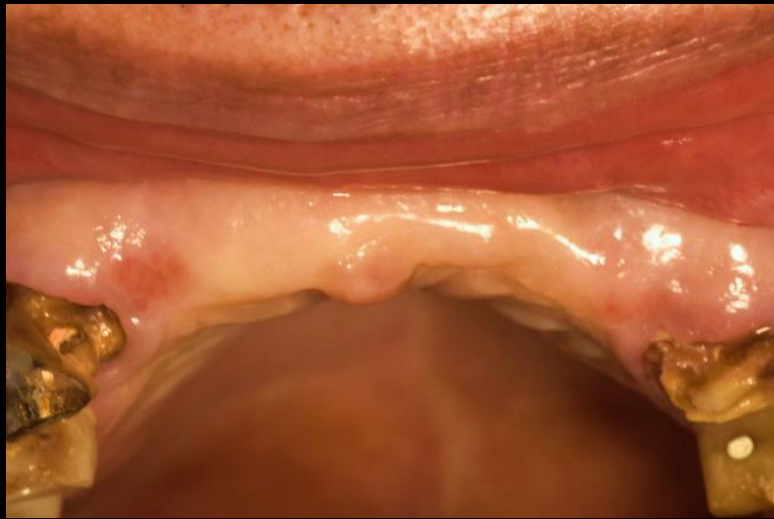## Implant placement & GBR on Maxillary anterior area



Pre-op

## Similar case

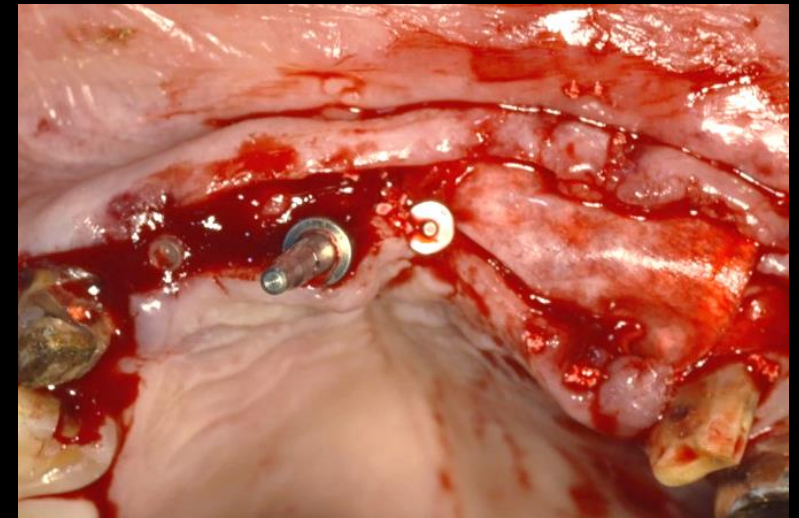
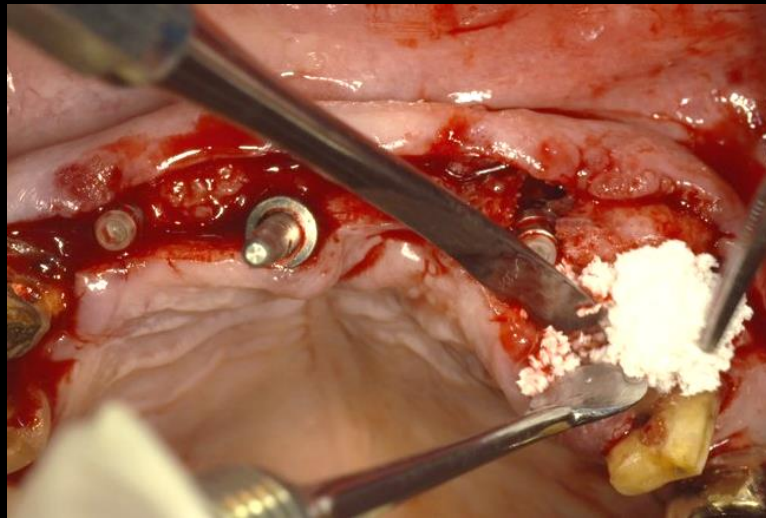
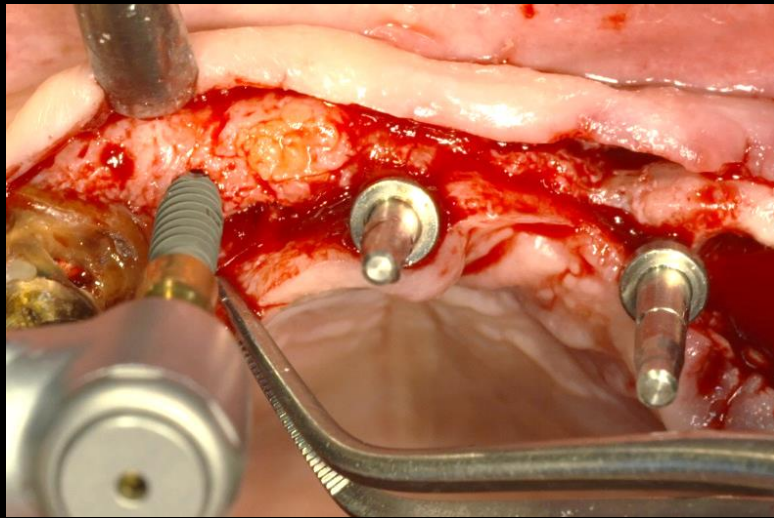
## Implant placement & GBR on Maxillary anterior area



Surgery

## Similar case

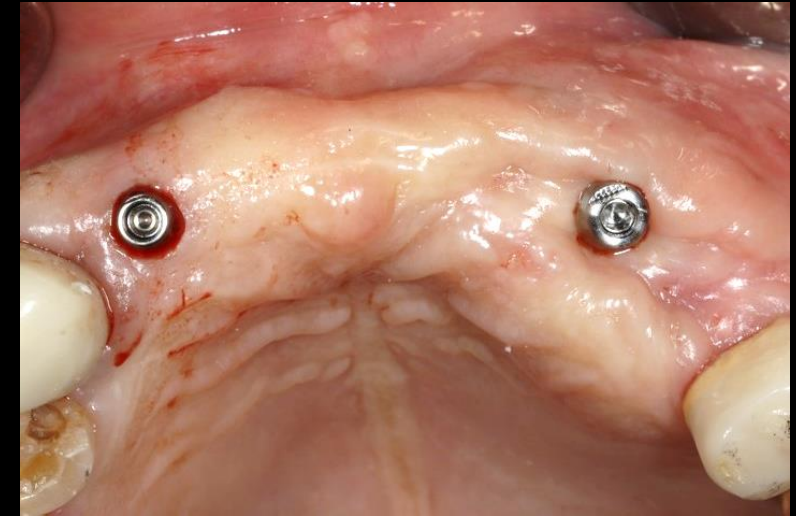
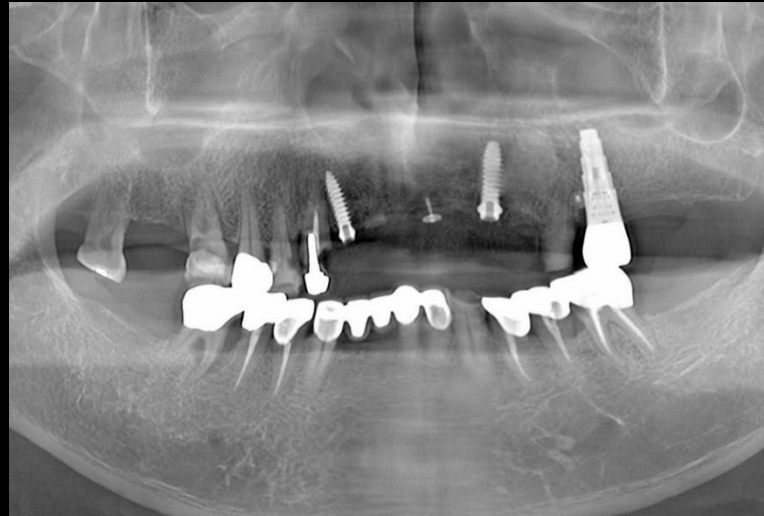
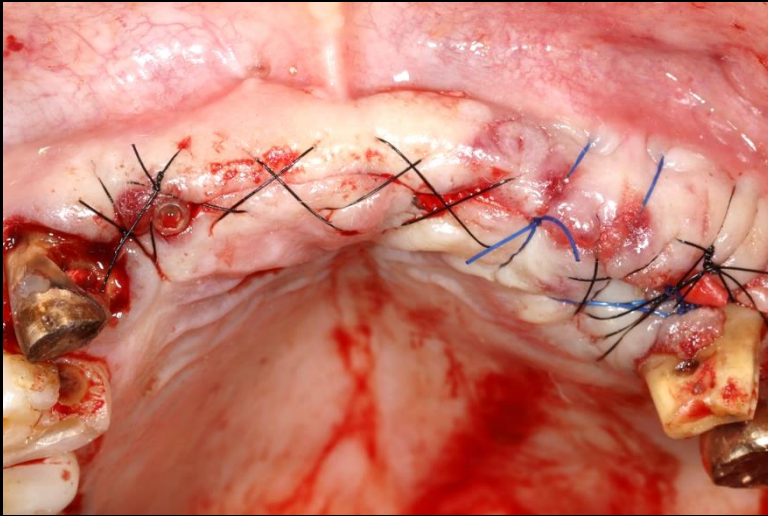
## Implant placement & GBR on Maxillary anterior area



Surgery

## Similar case

## Implant placement & GBR on Maxillary anterior area

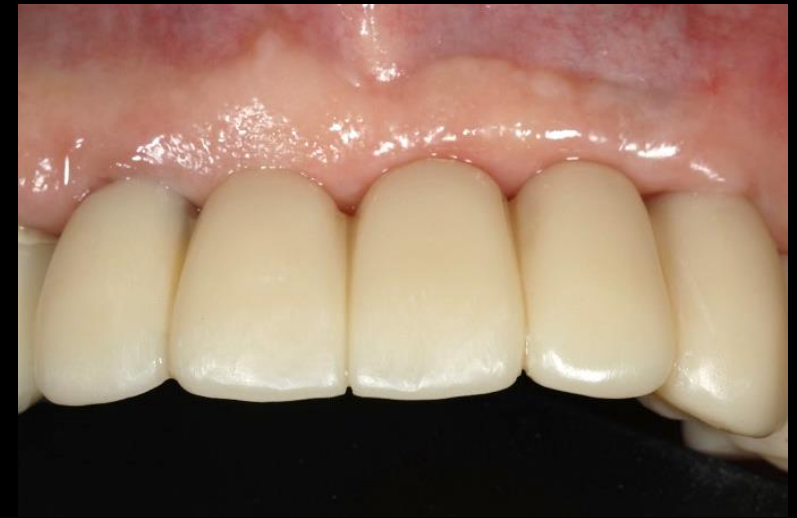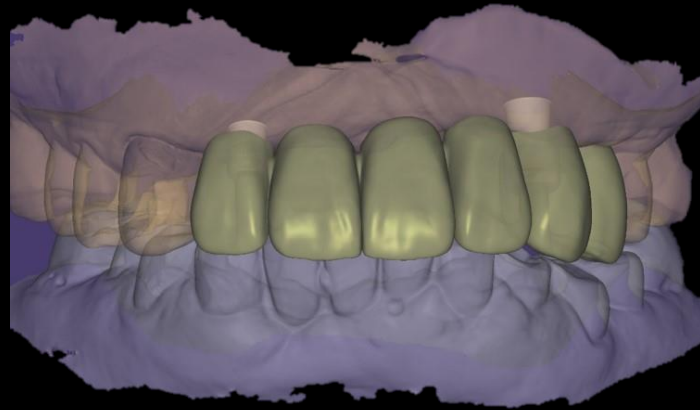

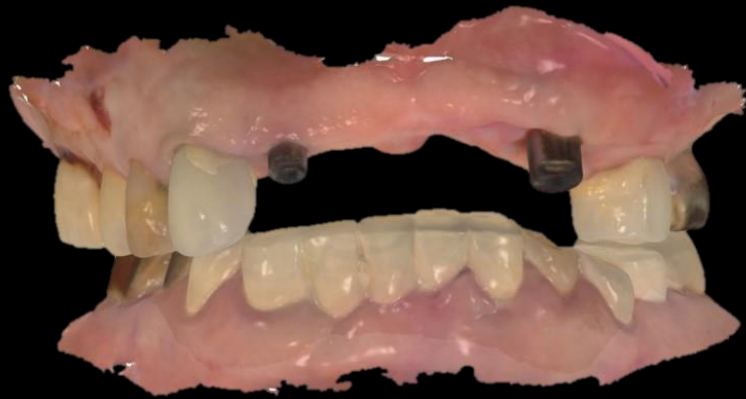
Post-op / 2<sup>nd</sup> Surgery



## Similar case

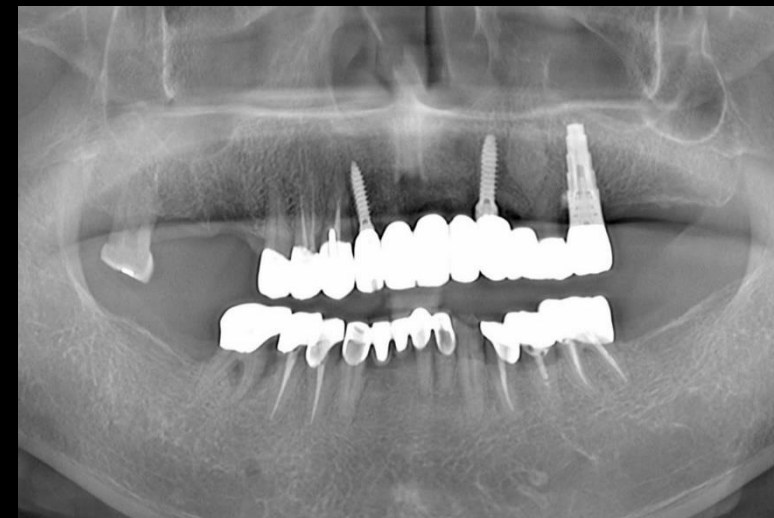
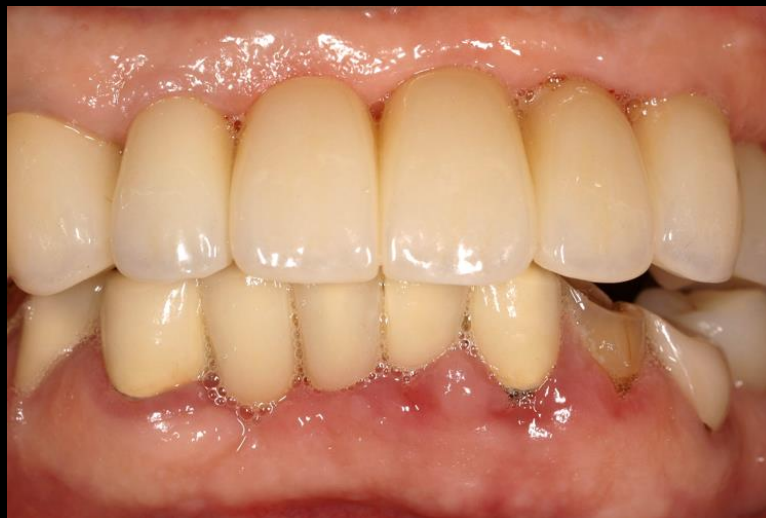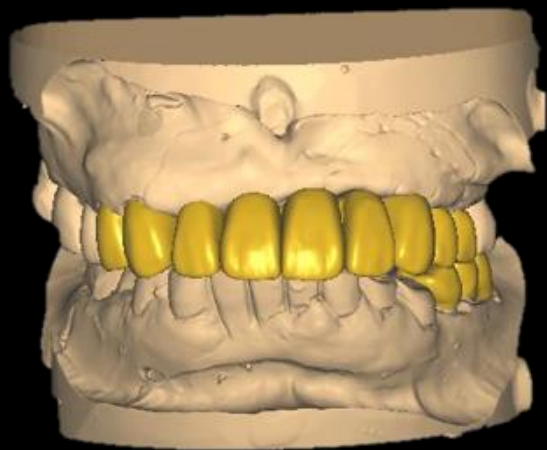Implant placement & GBR on Maxillary anterior area



Provisional restoration

**Similar case**

**Implant placement & GBR on Maxillary anterior area**



Final prosthesis

