



**LIVE**

# Surgey

Prof. Soo-Hwan Byun

2021.09.24 (FRI.)



[Case Preview]

Digital Guide Implant placement with GBR

# Patient Information

**Age** : 29

**Sex** : Female

## Chief Complaint

: My left facial is swelling(ER)

## Past Dental History

: Traffic accident 7 years ago

Numerous retained root and caries

Edentulous state at anterior mandible

## Past Medical History

N/S

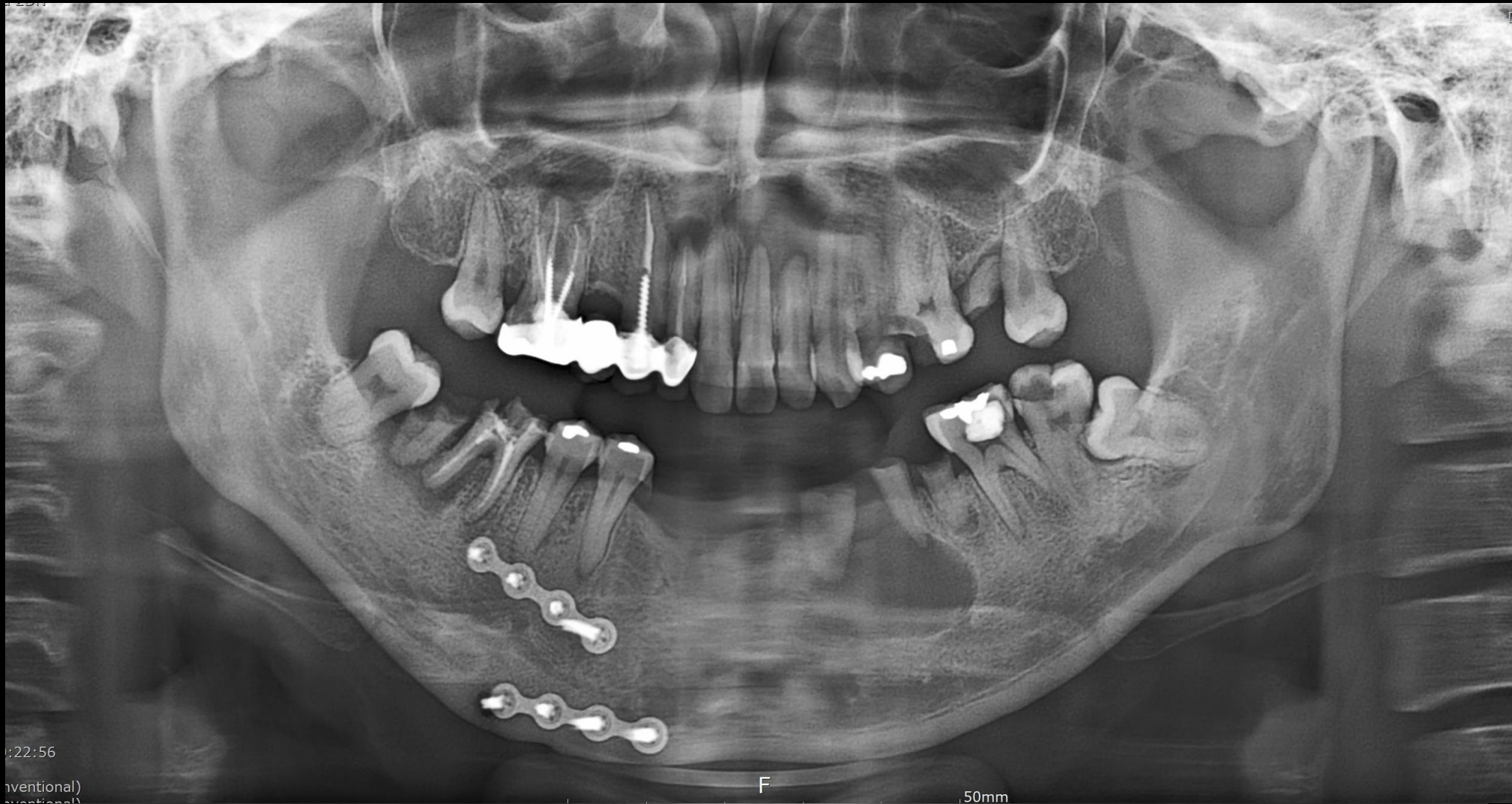## Systemic diseases

N/S



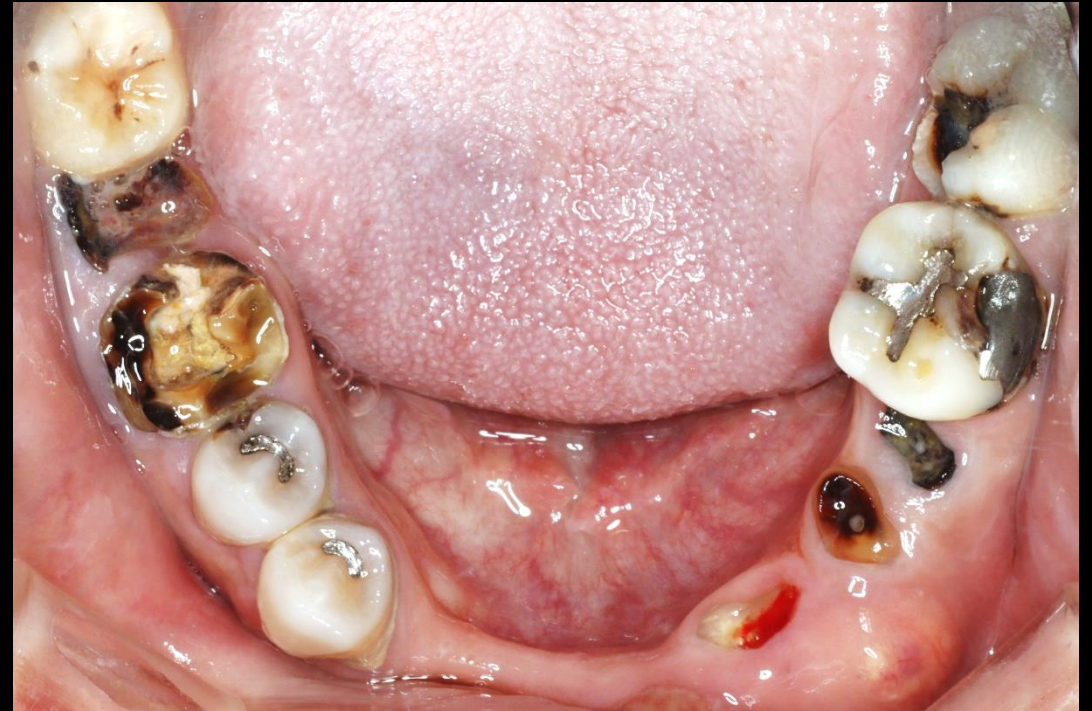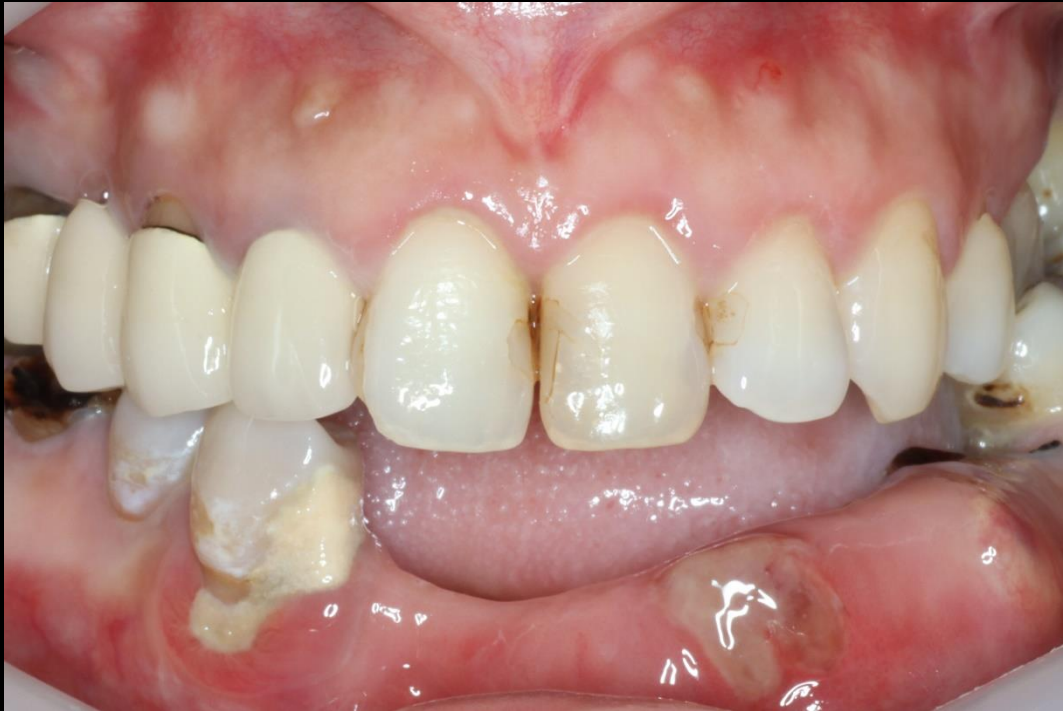# Past dental history

Oral exam (2021-03-02)



# Past dental history

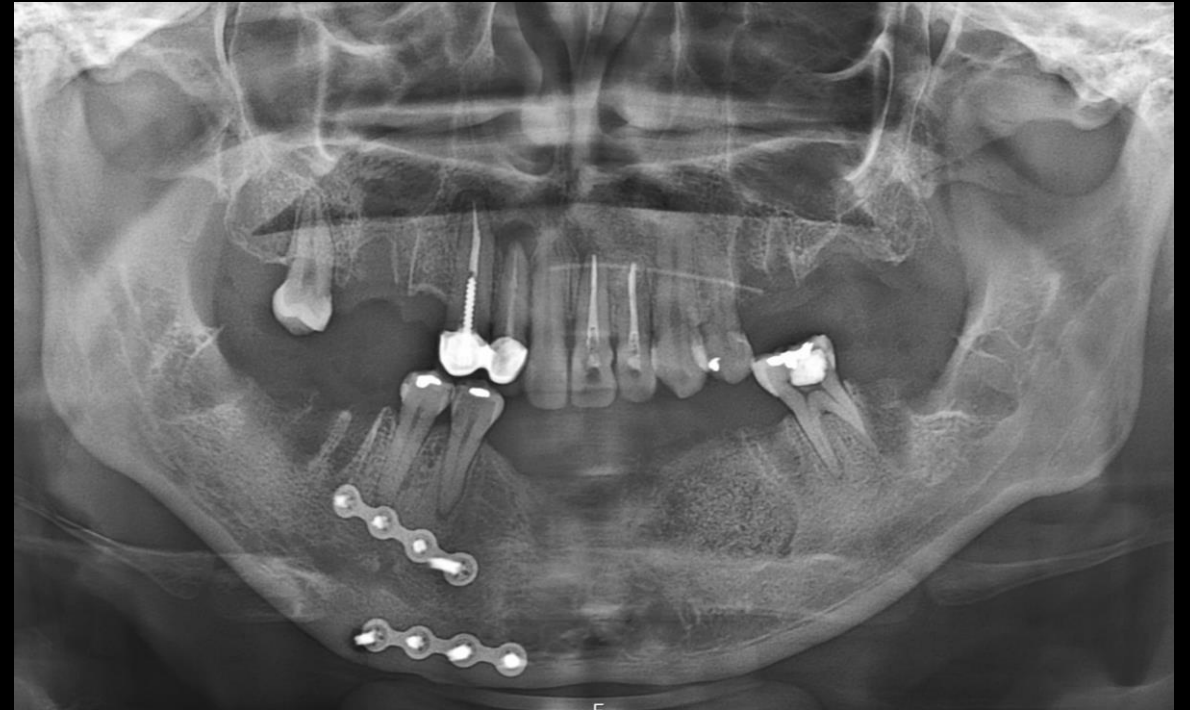
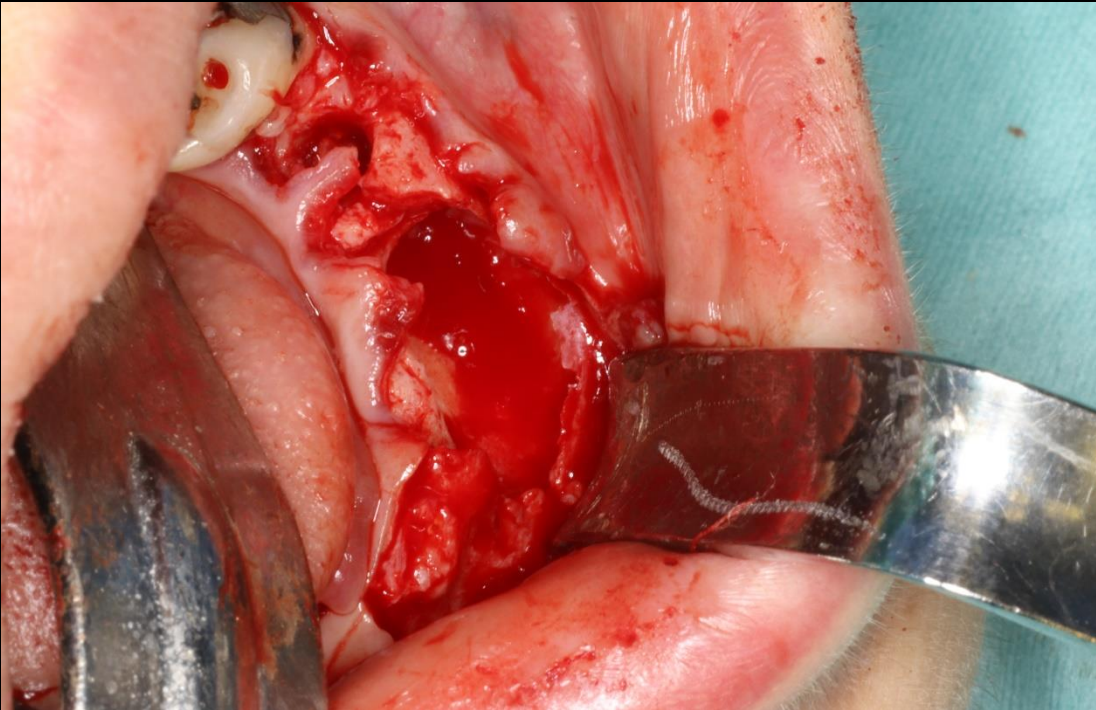
Oral exam (2021-03-02)





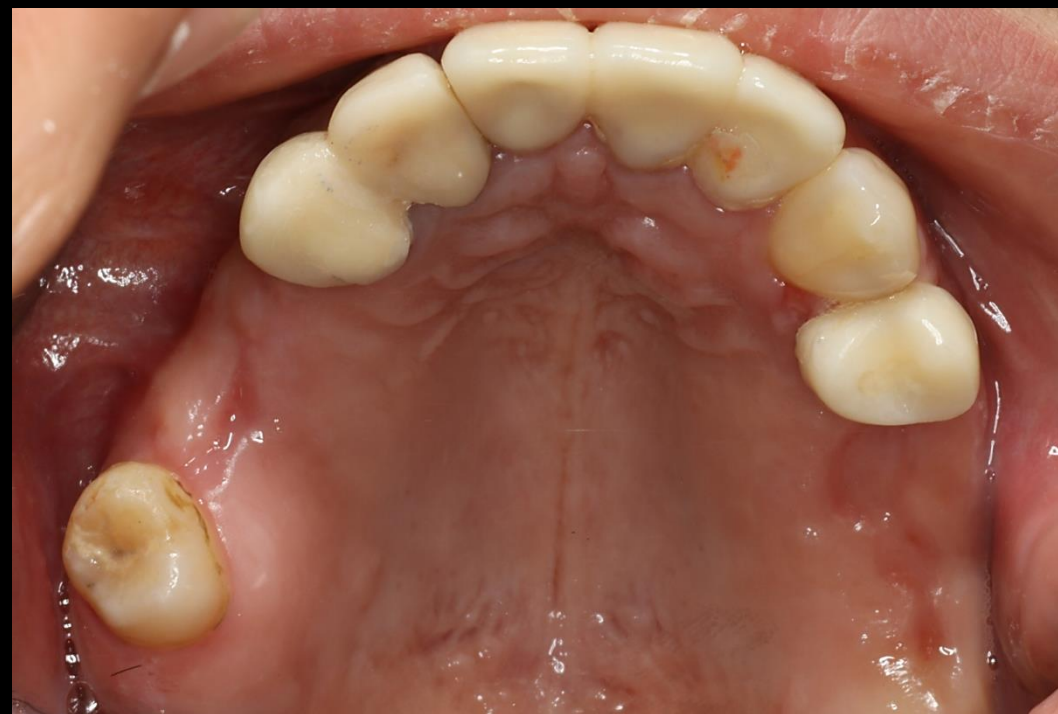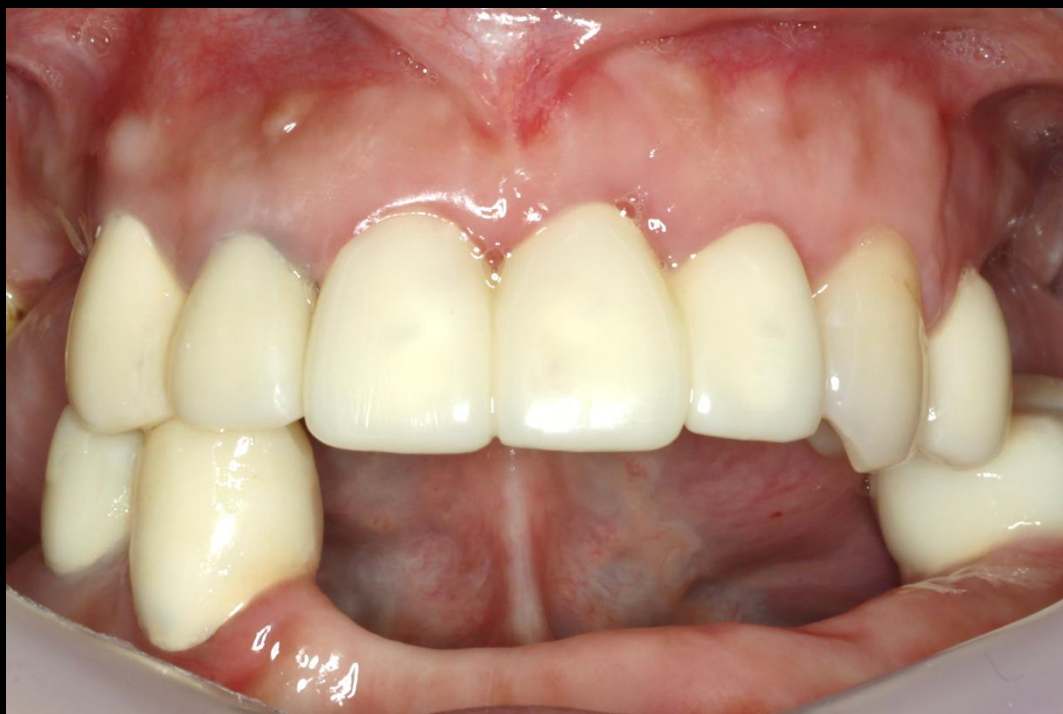## Past dental history

- Cyst enucleation of #21-22, #33-35 (2021-04-09)
- Radicular cyst
- #16, #26-28, #33-38, #46-48 Extraction
- #33-35 Bone graft with OSTEON3 and COLLAGEN MEMBRANE



# Past dental history

(2021-06-03)

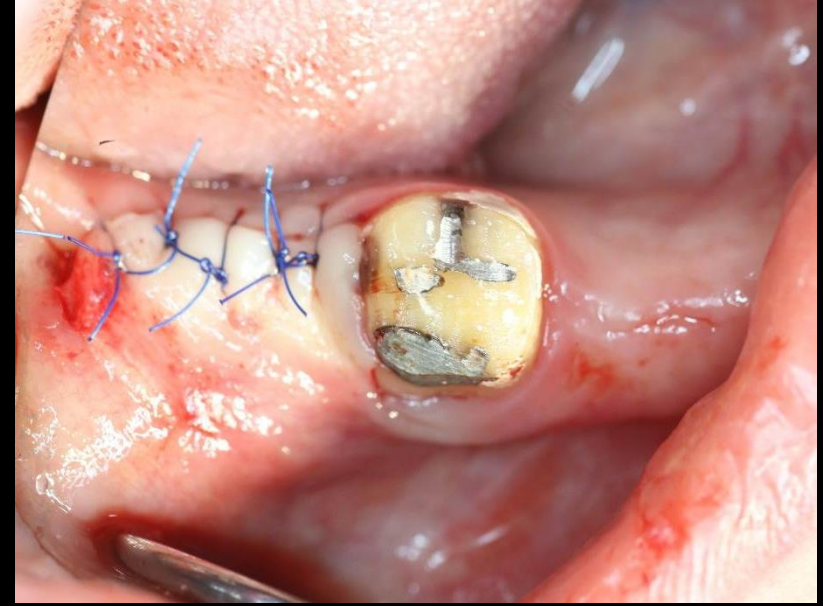
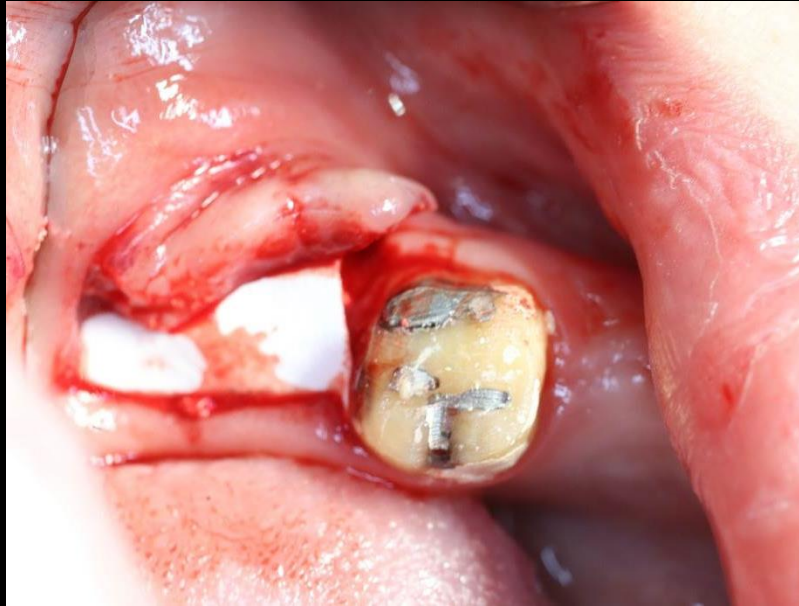
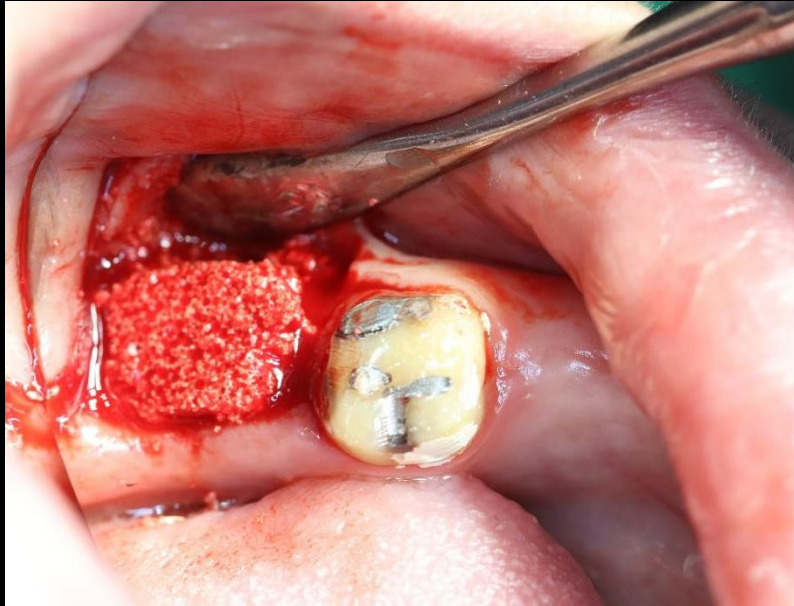


## Past dental history

- #37 vertical augmentation with OSTEON3 Block and COLLAGEN MEMBRANE

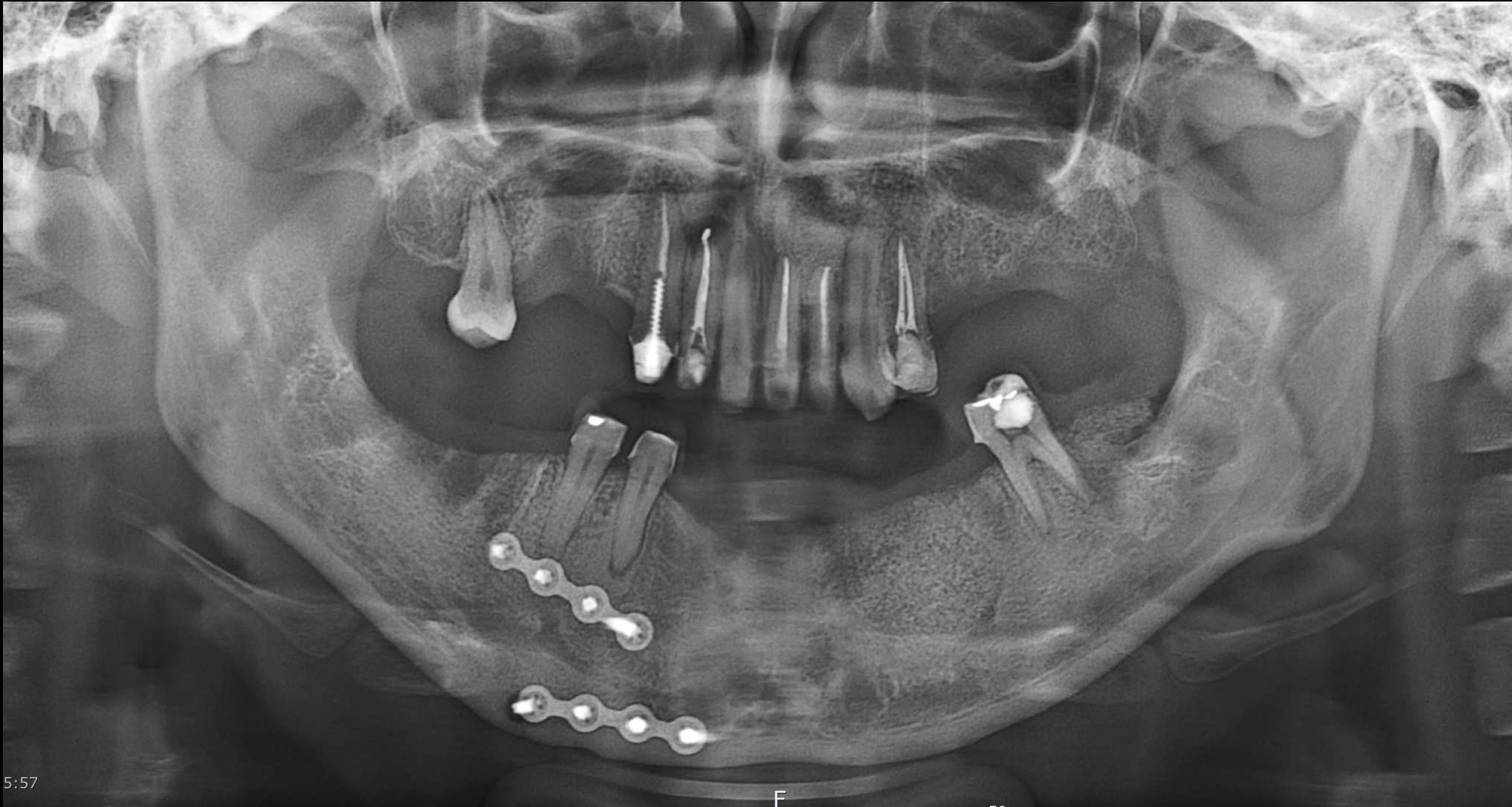
#37 (2021-06-22)





## Past dental history

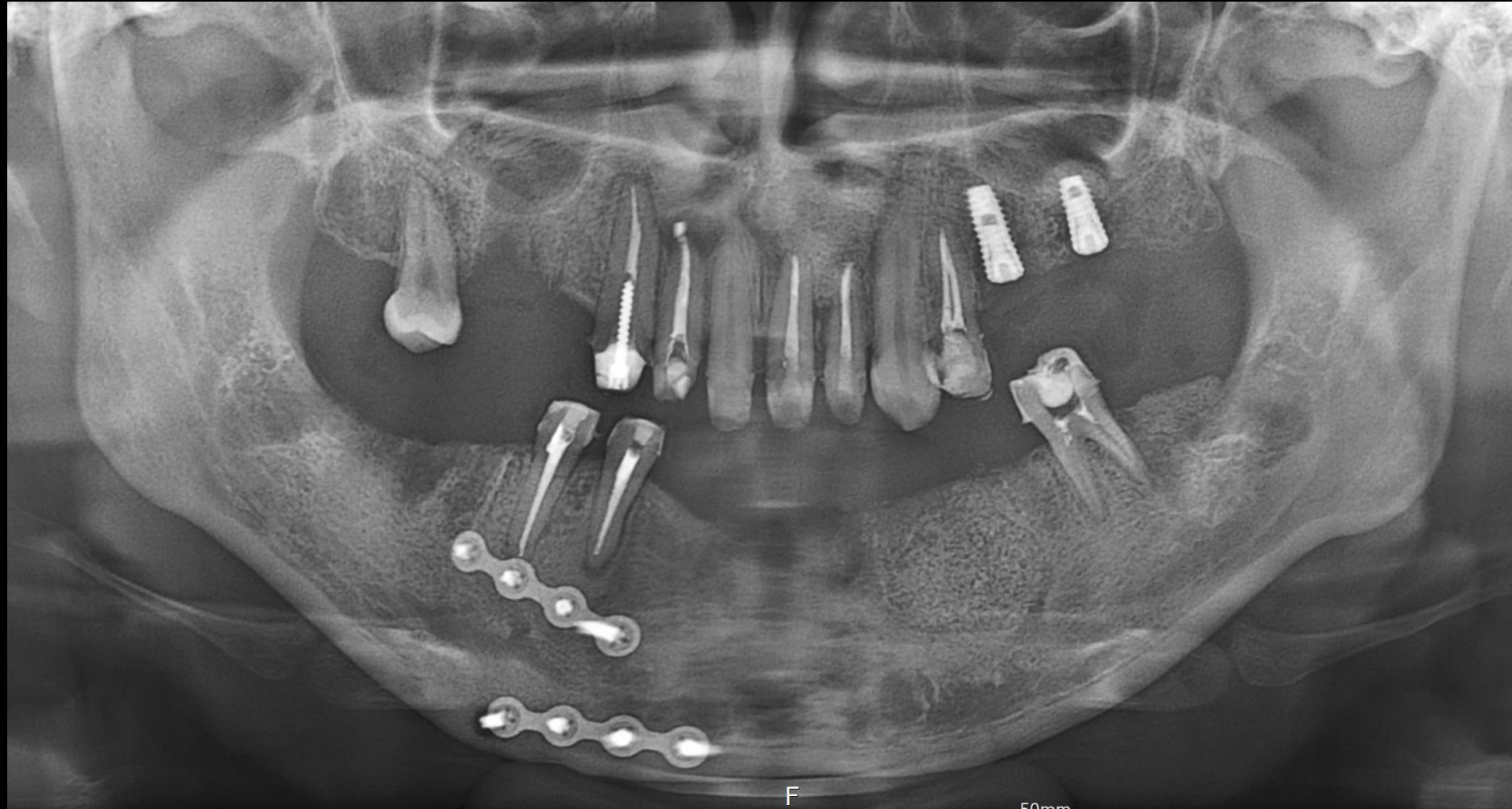
- #37 vertical augmentation with OSTEON3 Block and COLLAGEN MEMBRANE



## Past dental history

- #26, 27 Implant placement with  
sinus augmentation

(2021-07-20)

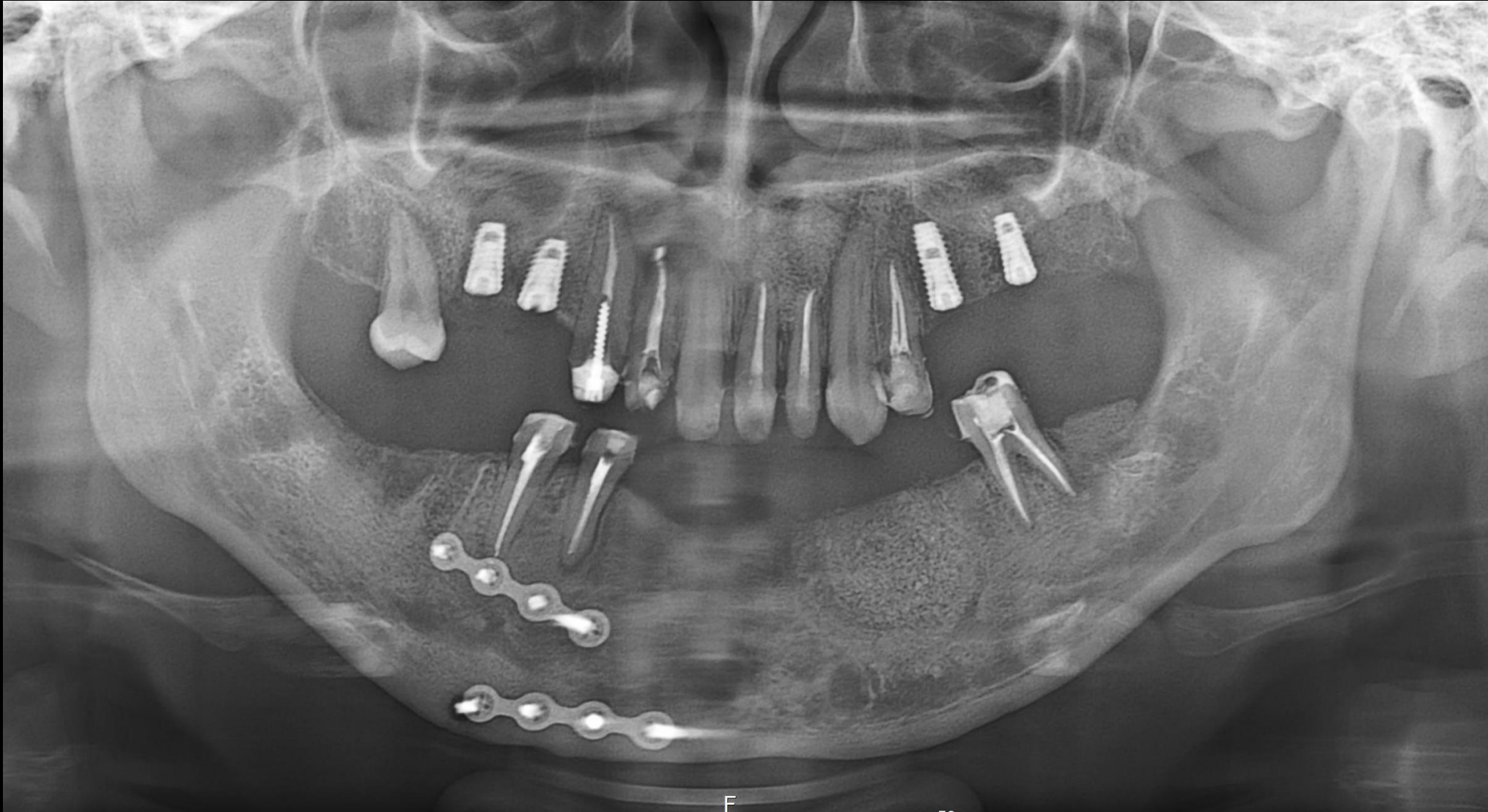




## Past dental history

- #15, 16 Implant placement with  
sinus augmentation

(2021-08-31)

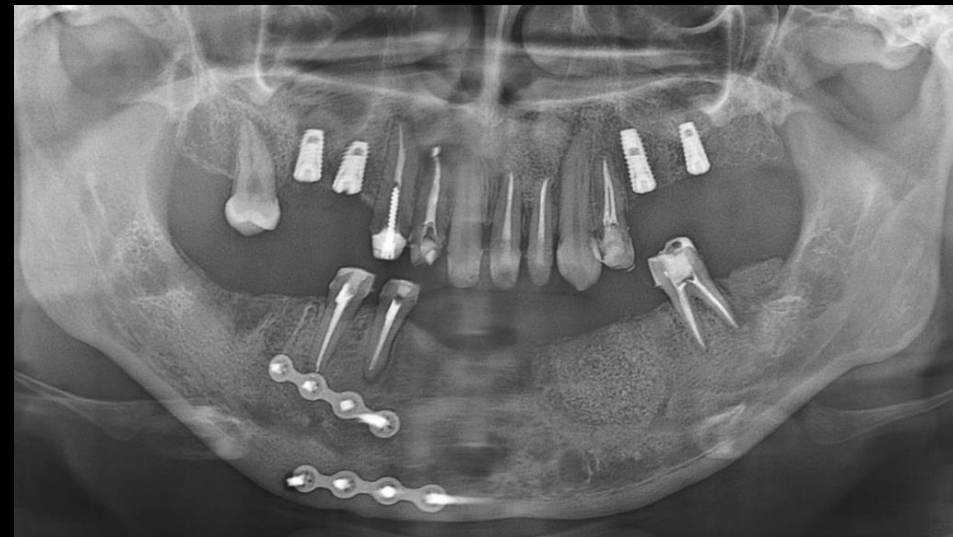
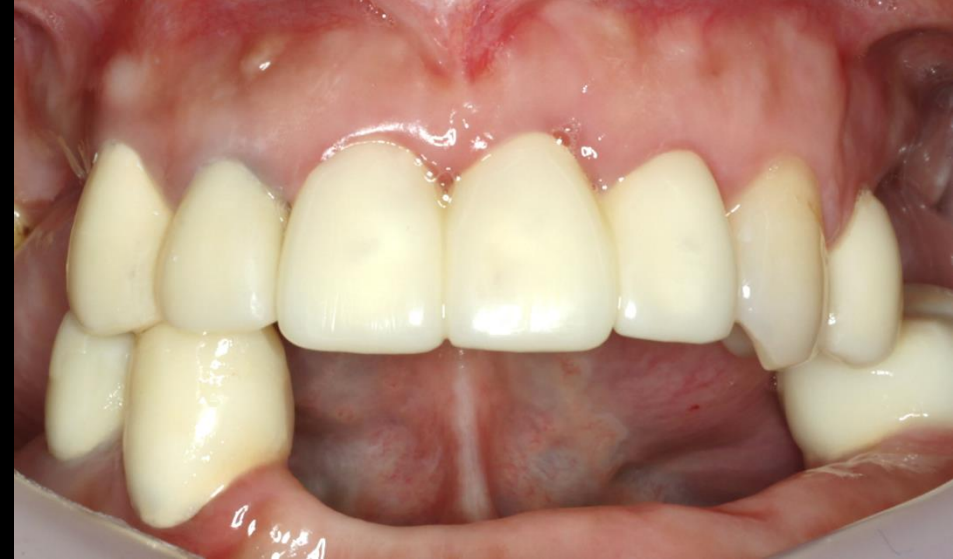



# Today's Surgery Plan

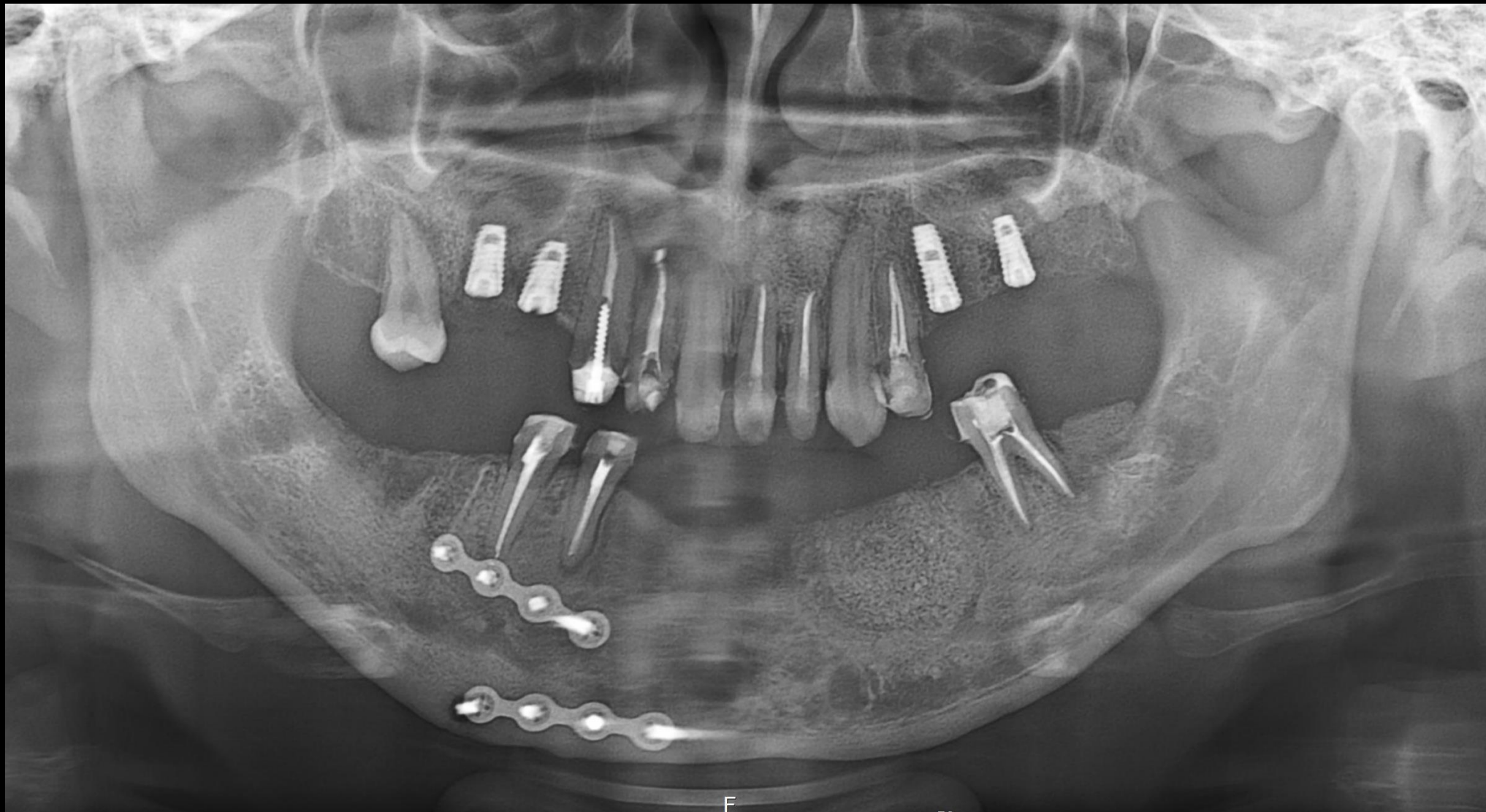#47, 46, 43, 33, 35

- Implant placement by using Dentium digital guide system
- Simultaneous GBR



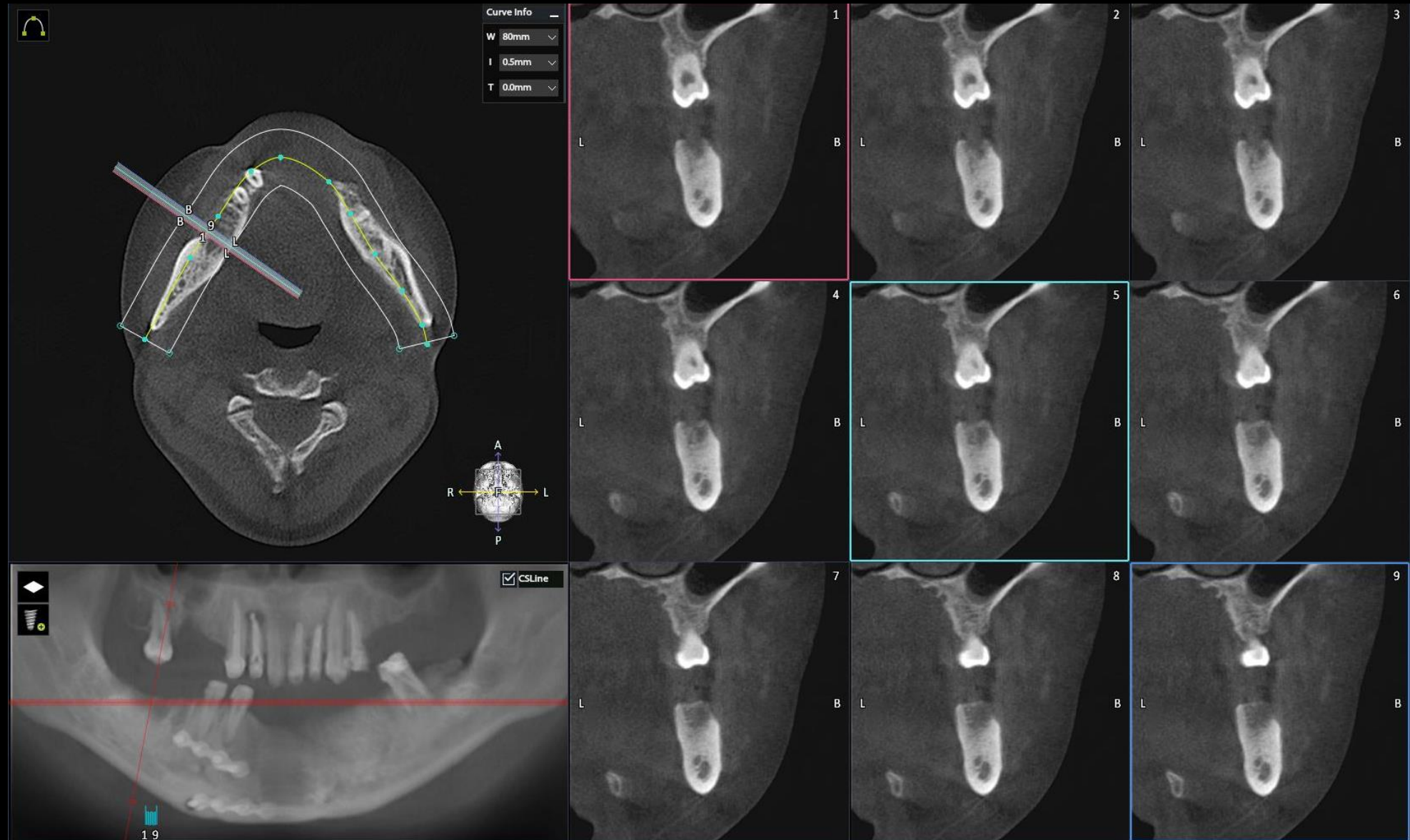
Pt. Yu (29/Female)

Pre-op (2021-08-31)



Pt. Yu (29/Female)

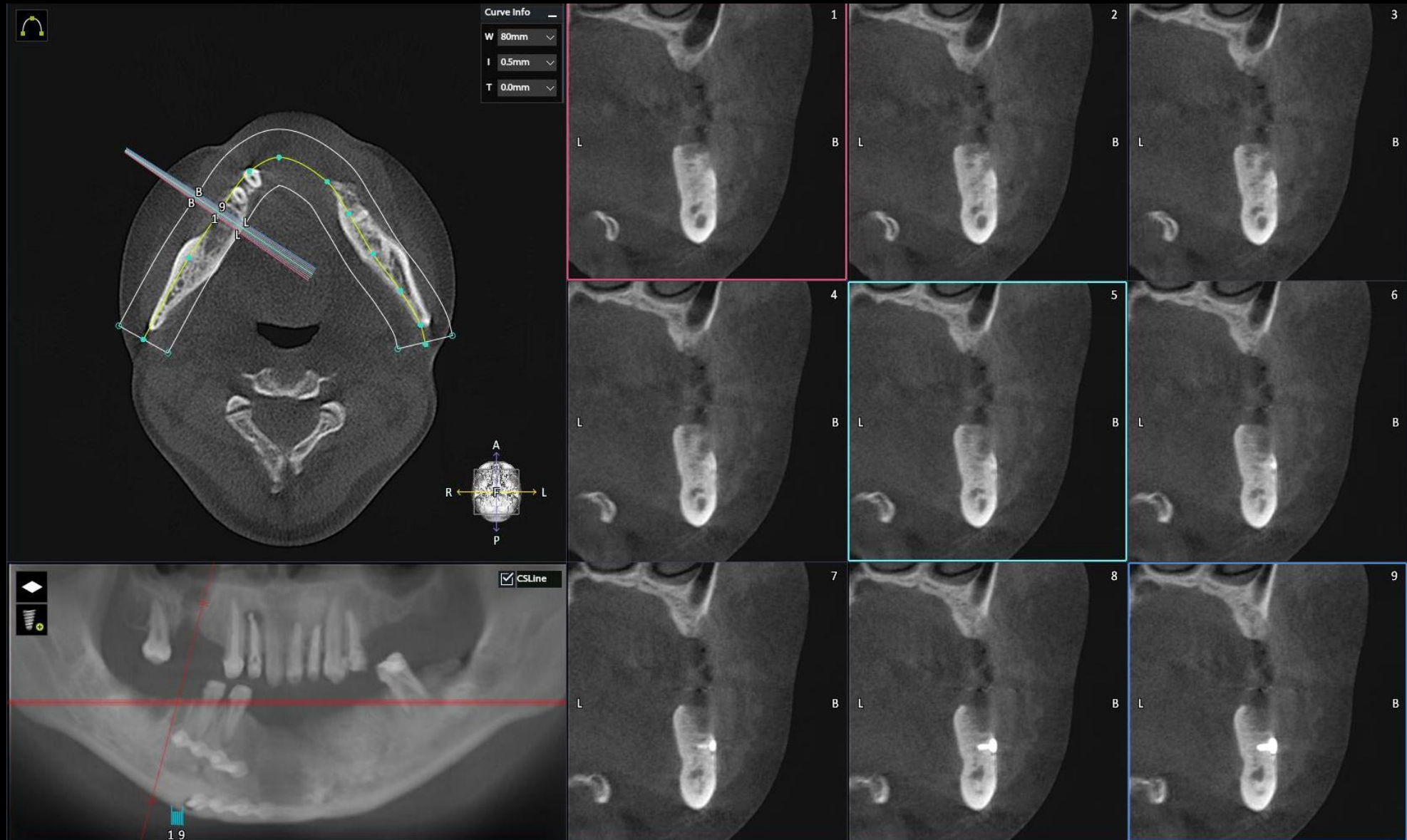
#47 Pre-op (2021-06-22)





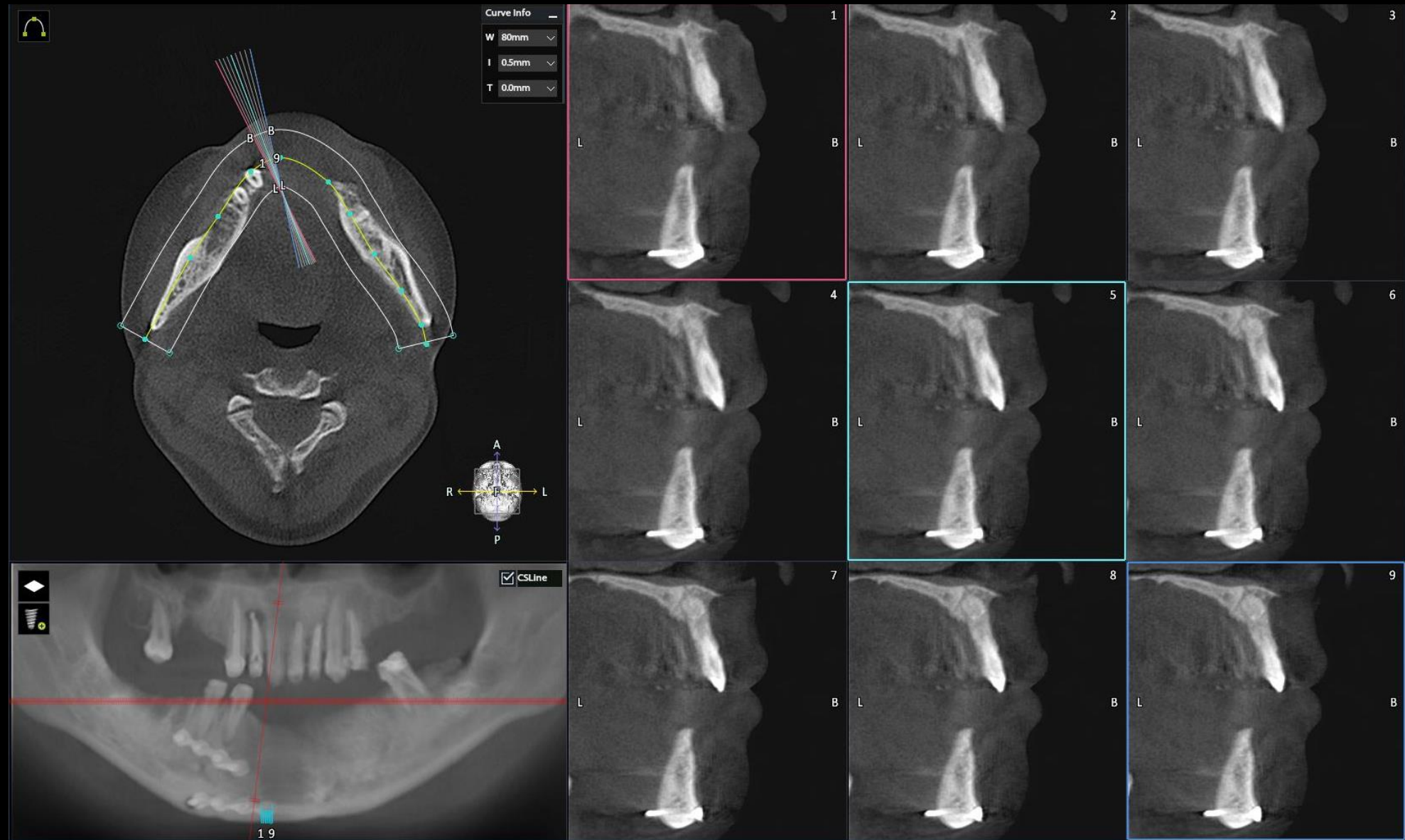
Pt. Yu (29/Female)

#46 Pre-op (2021-06-22)



Pt. Yu (29/Female)

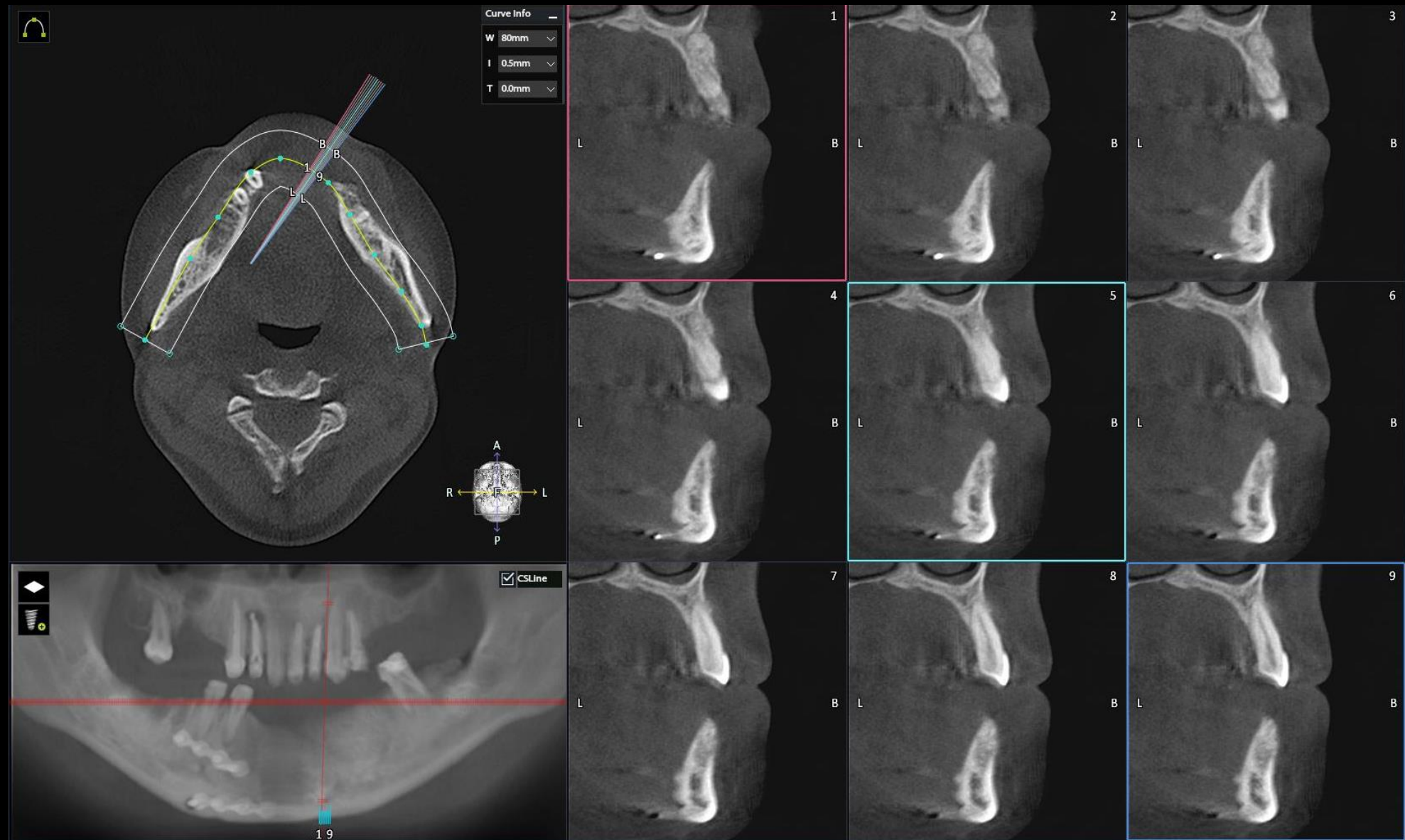
#43 Pre-op (2021-06-22)





Pt. Yu (29/Female)

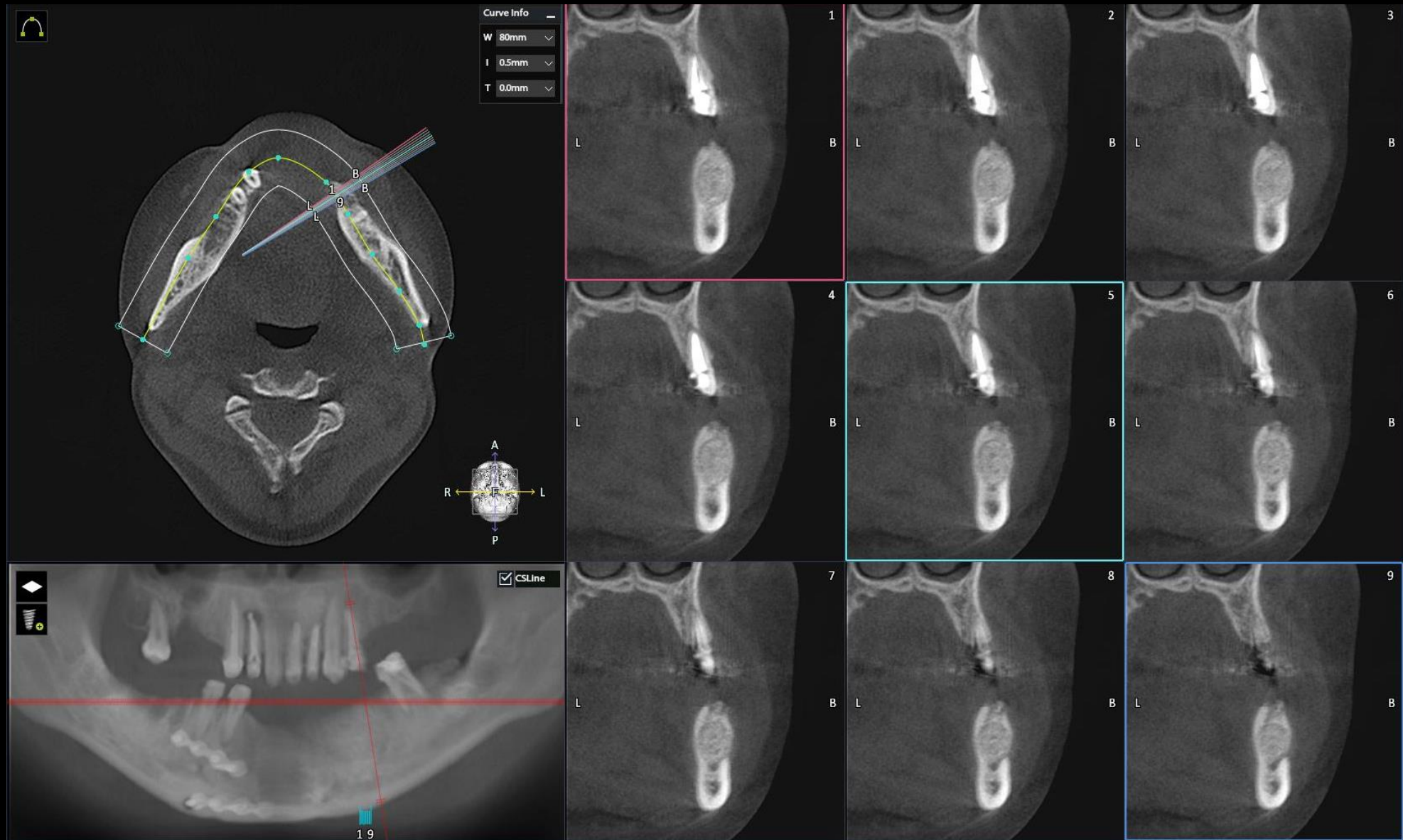
#33 Pre-op (2021-06-22)



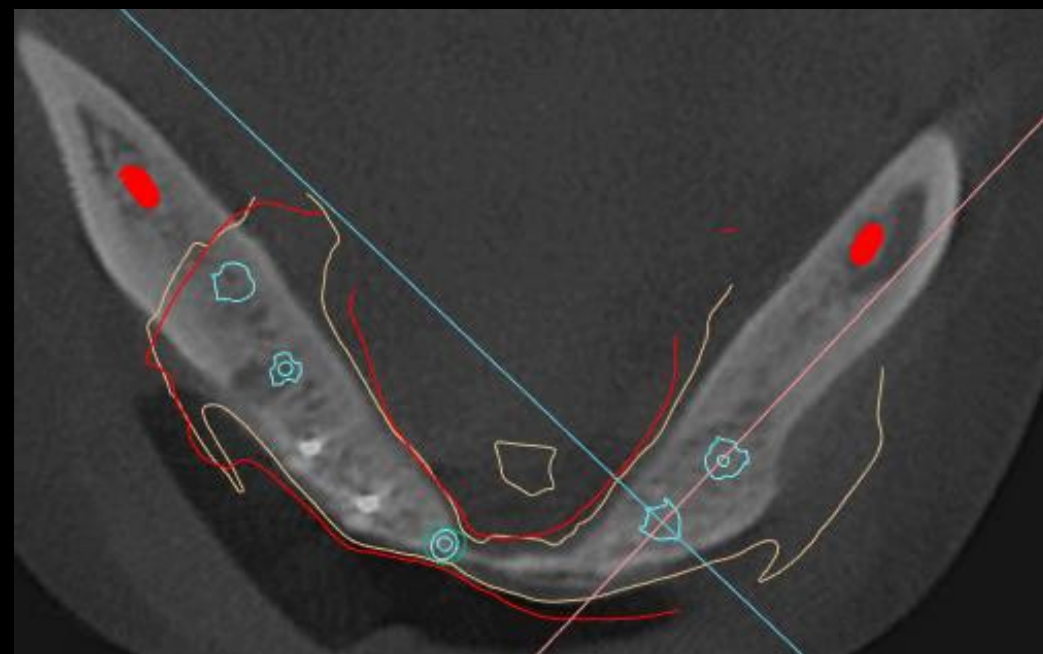
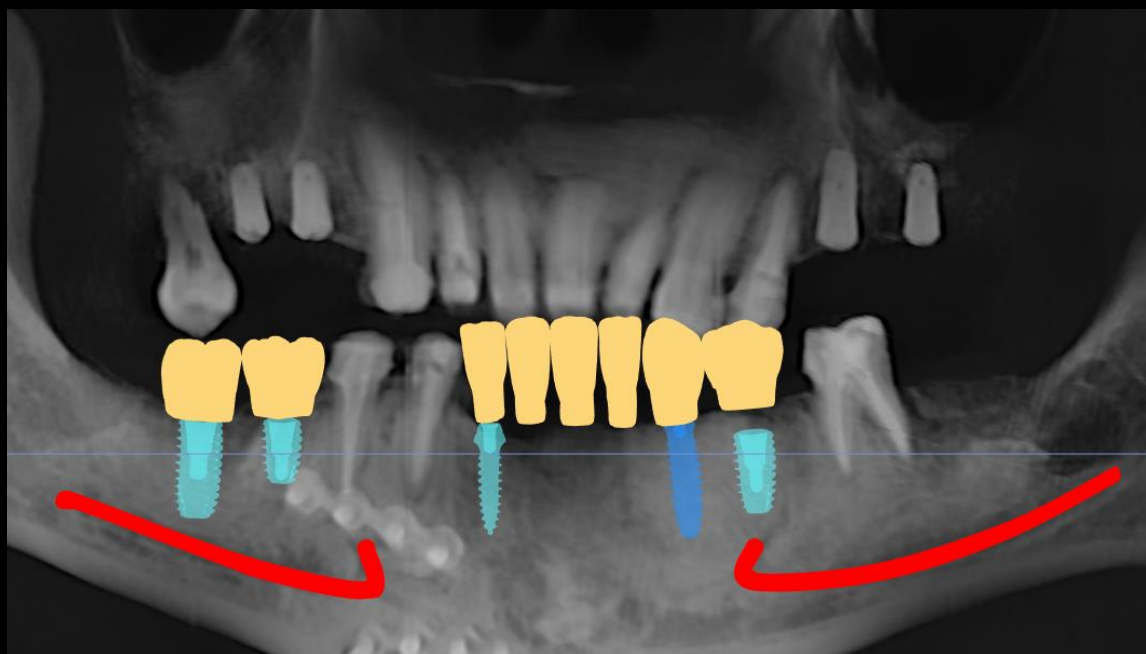


Pt. Yu (29/Female)

#35 Pre-op (2021-06-22)

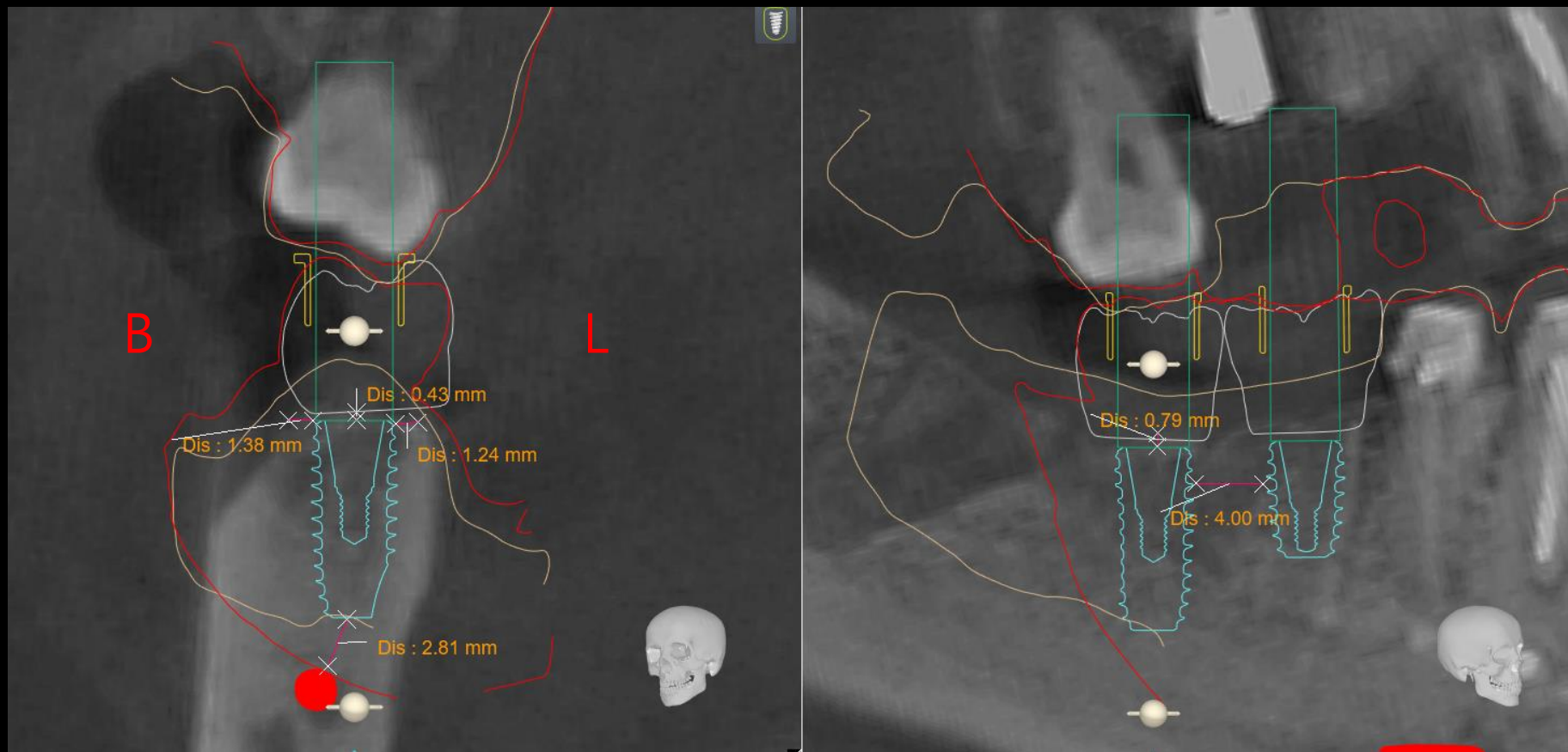


## Digital Guide S/W (Implant Planning)



# Digital Guide S/W (Implant Planning)

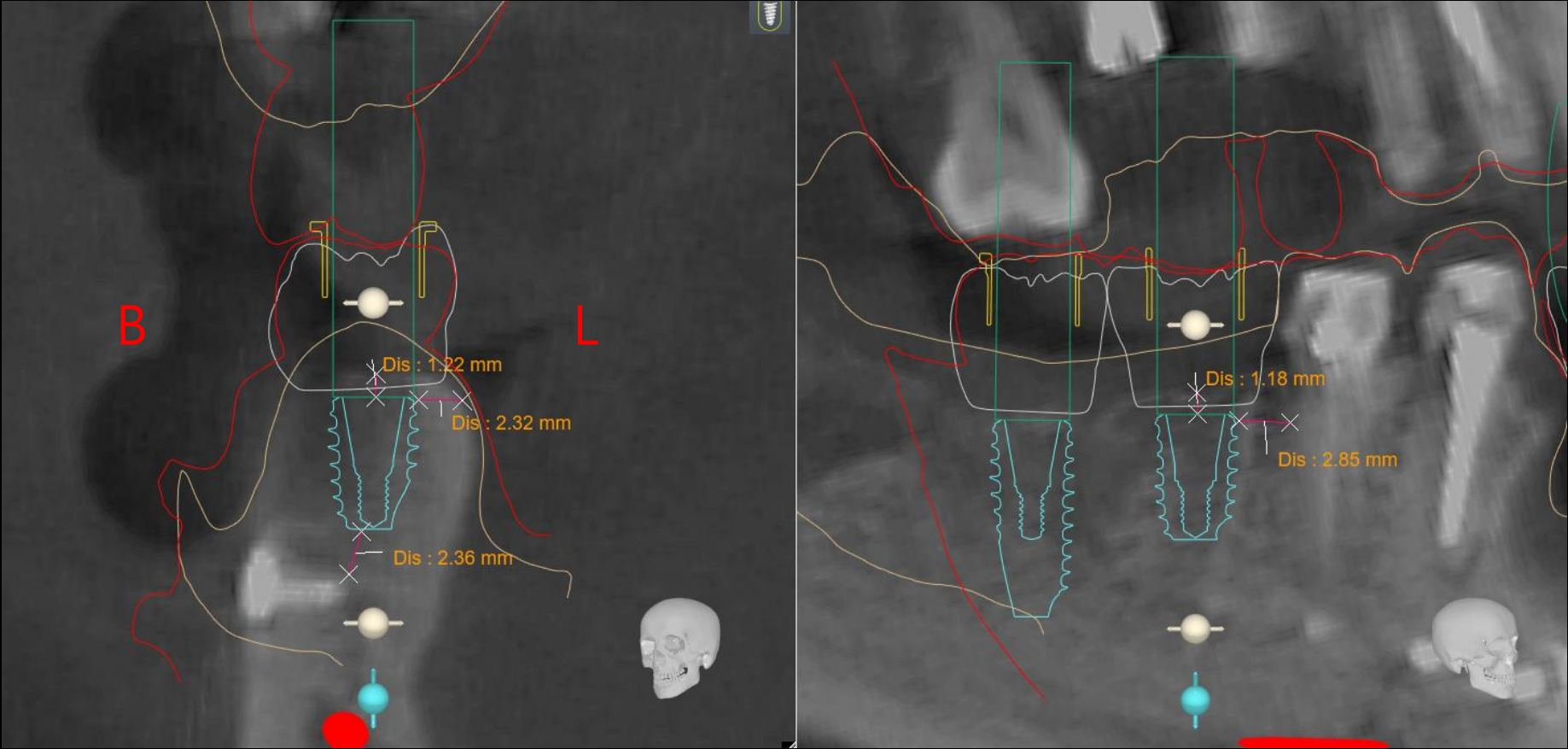
#47 (BFX4511)





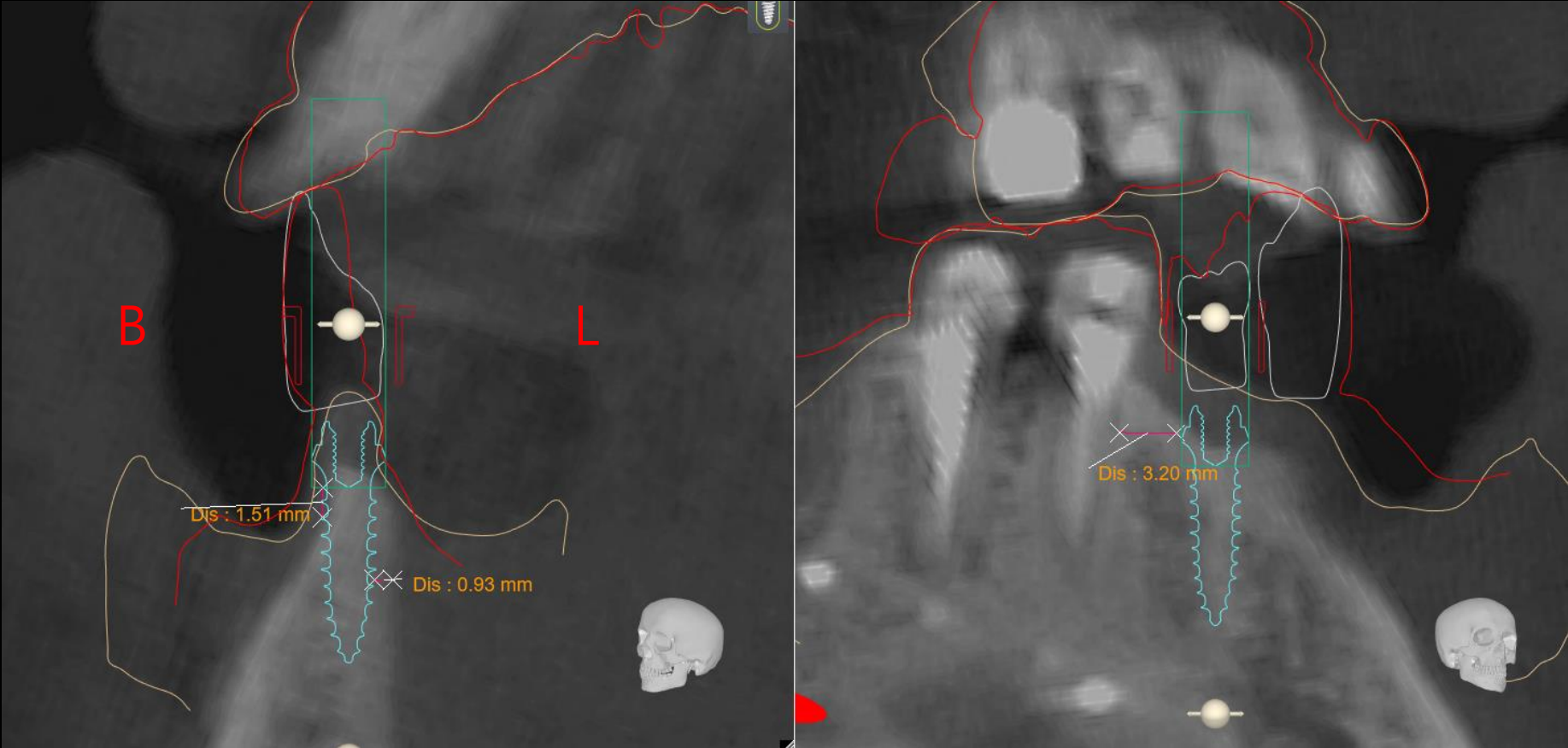# Digital Guide S/W (Implant Planning)

#46 (BFX4507)



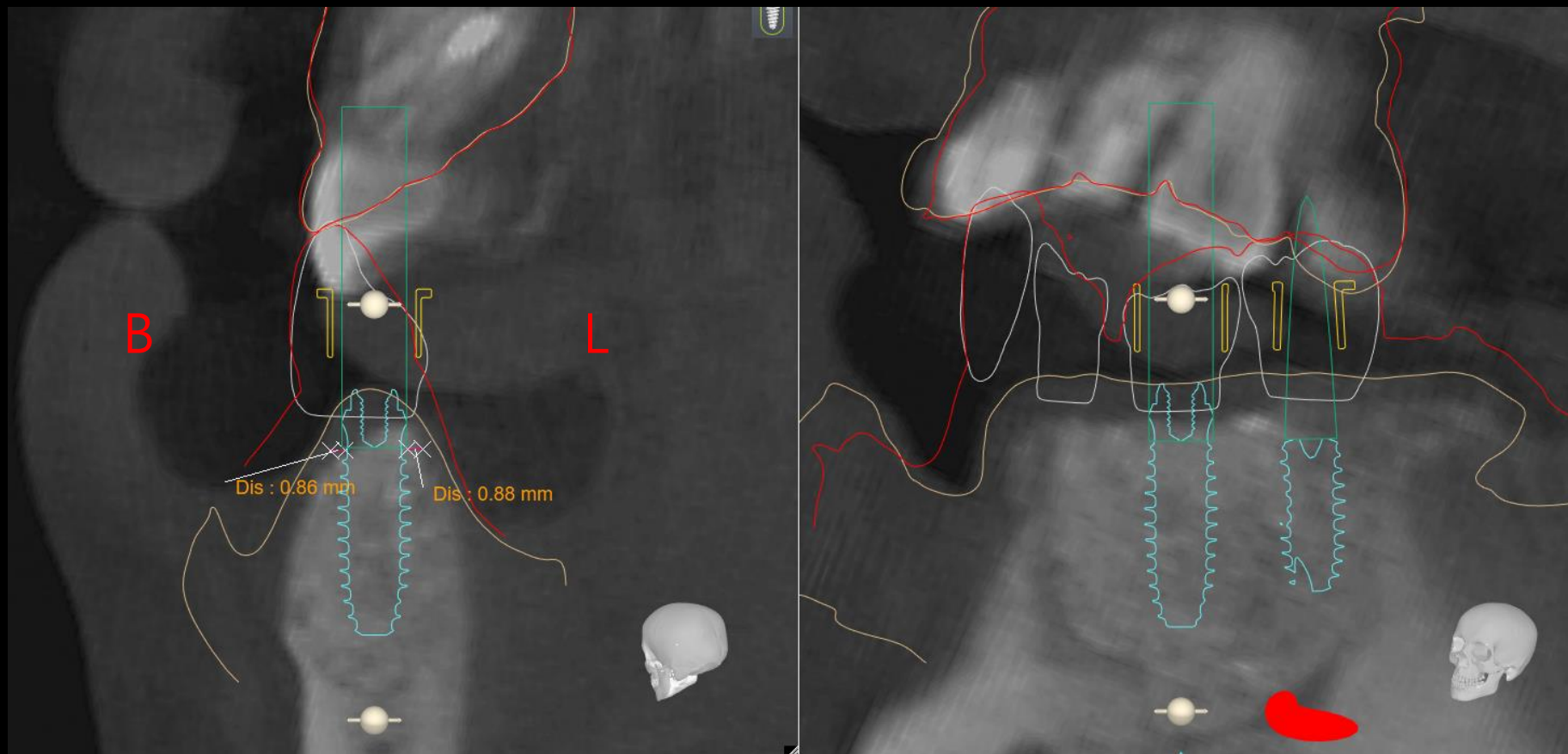
# Digital Guide S/W (Implant Planning)

#43 (NTI382509)



# Digital Guide S/W (Implant Planning)

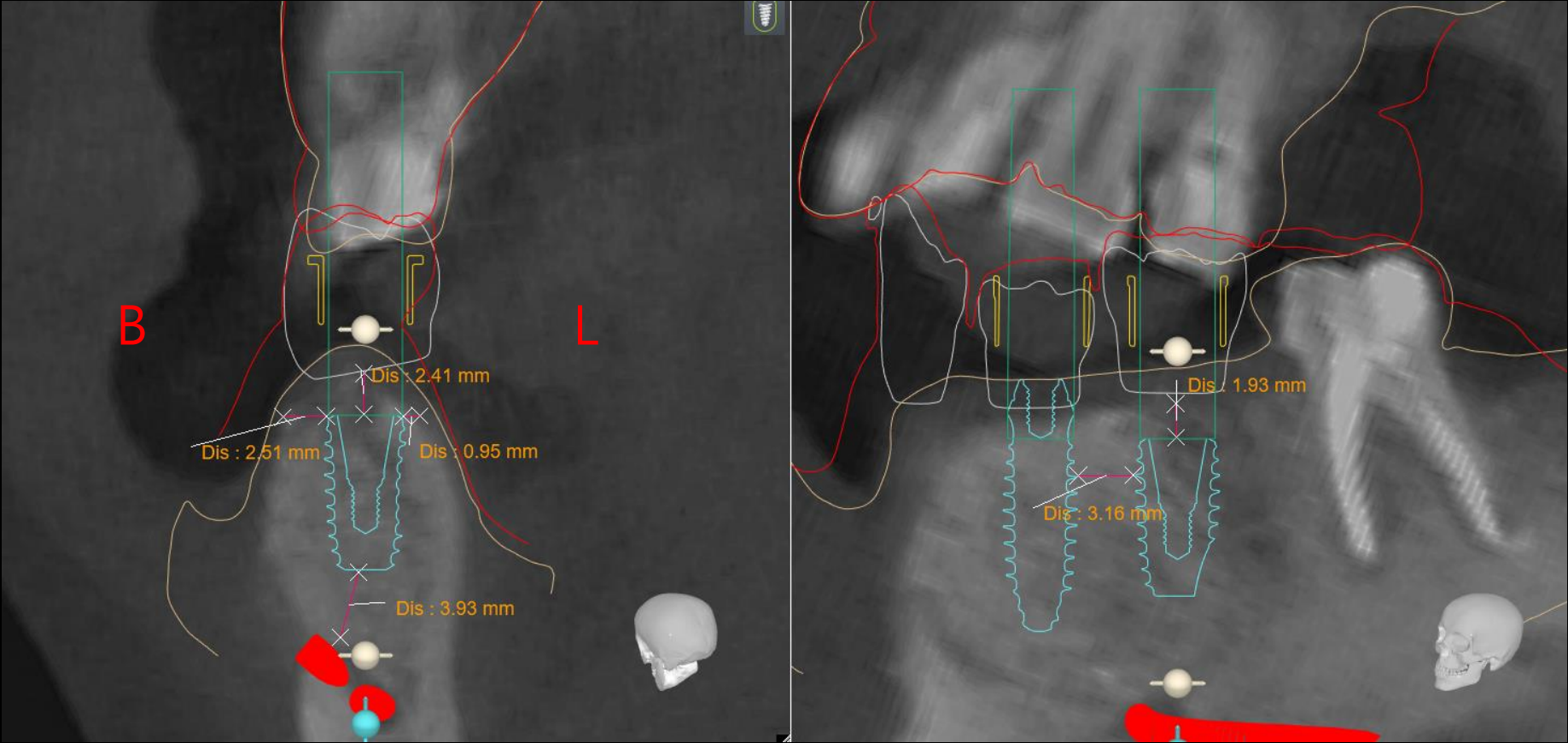
#33 (NTI384011)



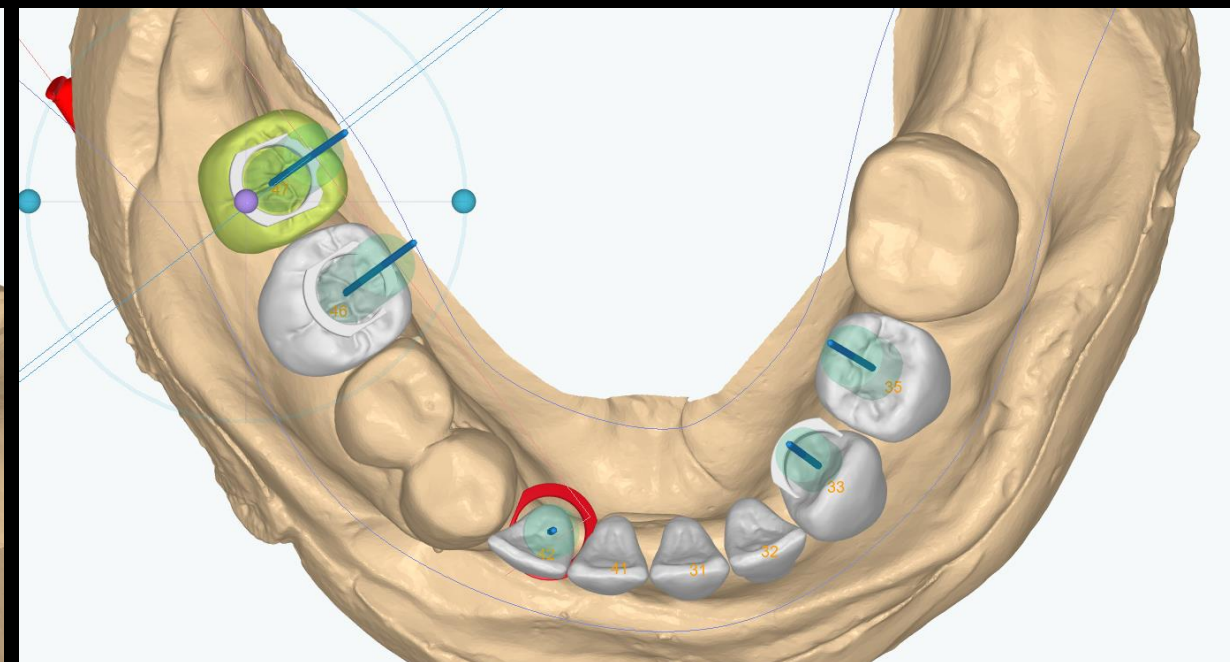
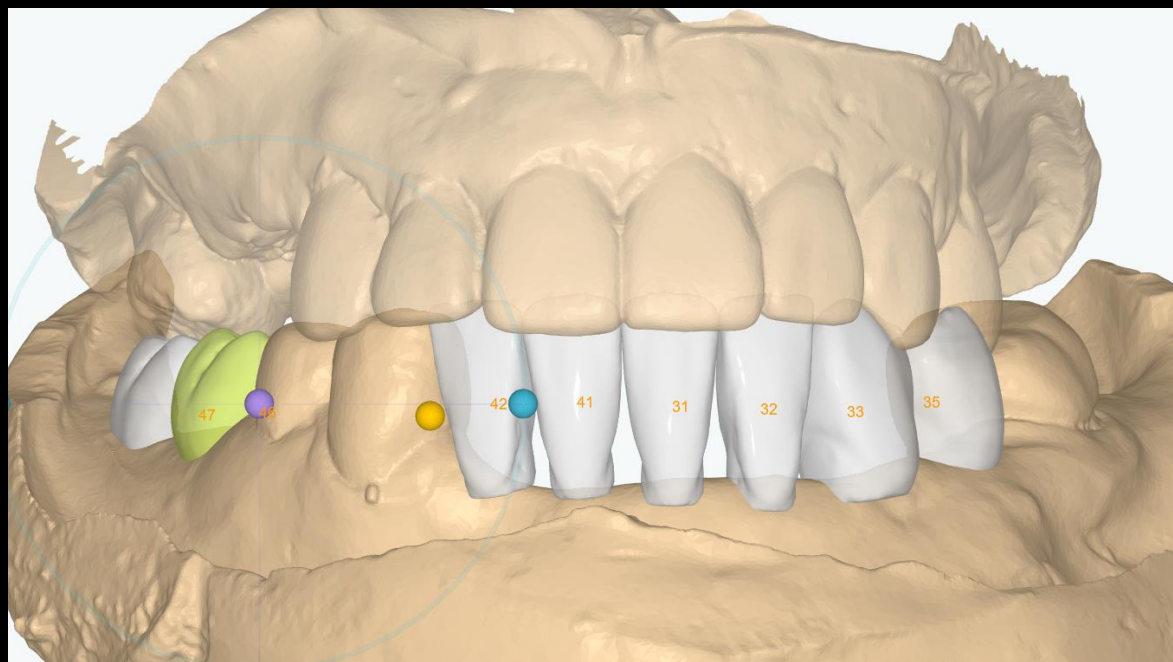


# Digital Guide S/W (Implant Planning)

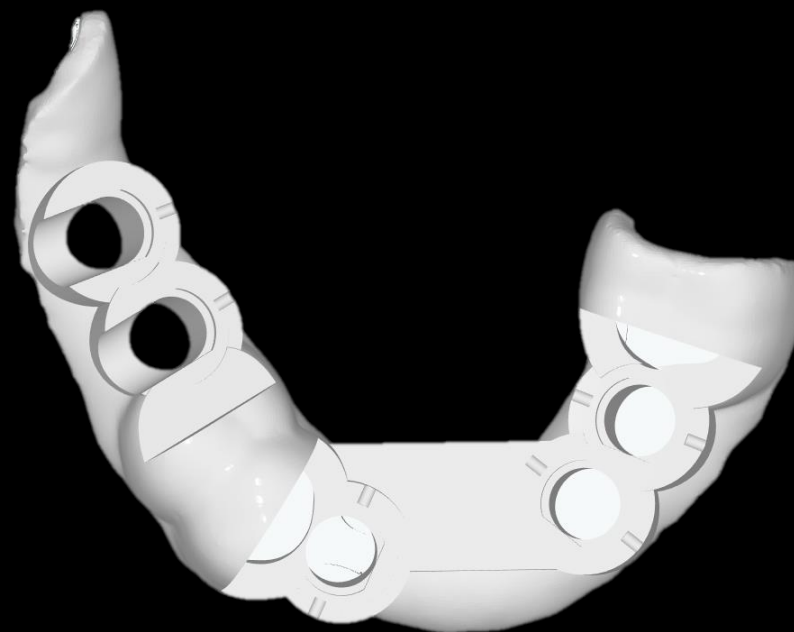
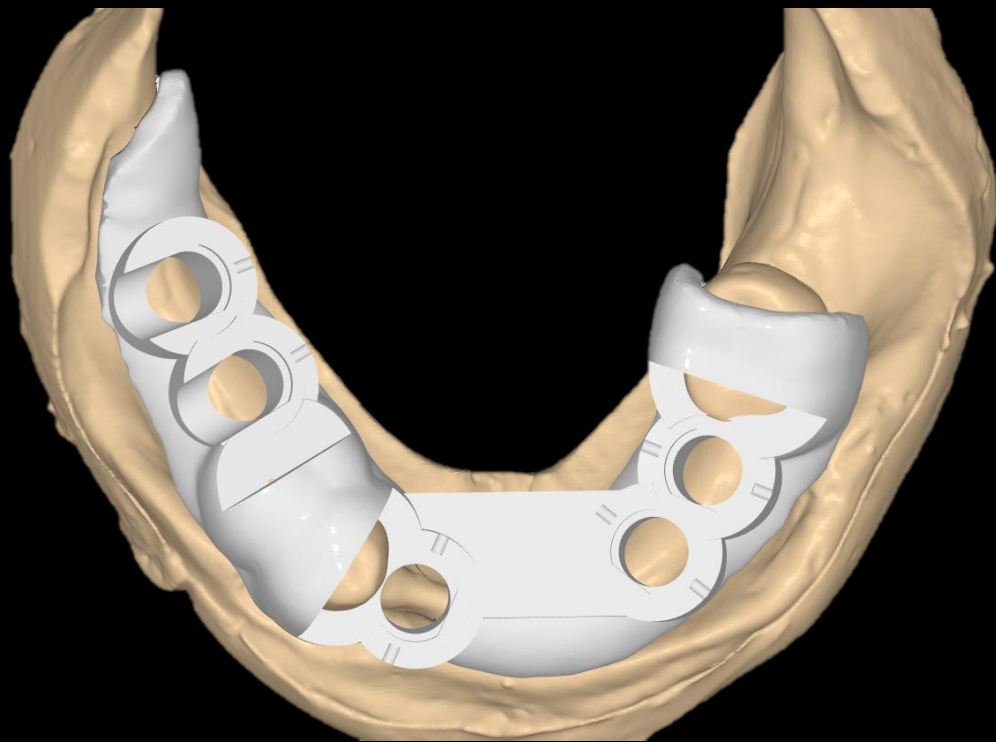
#35 (BFX4509)



# Digital Guide S/W (Virtual Set-up)

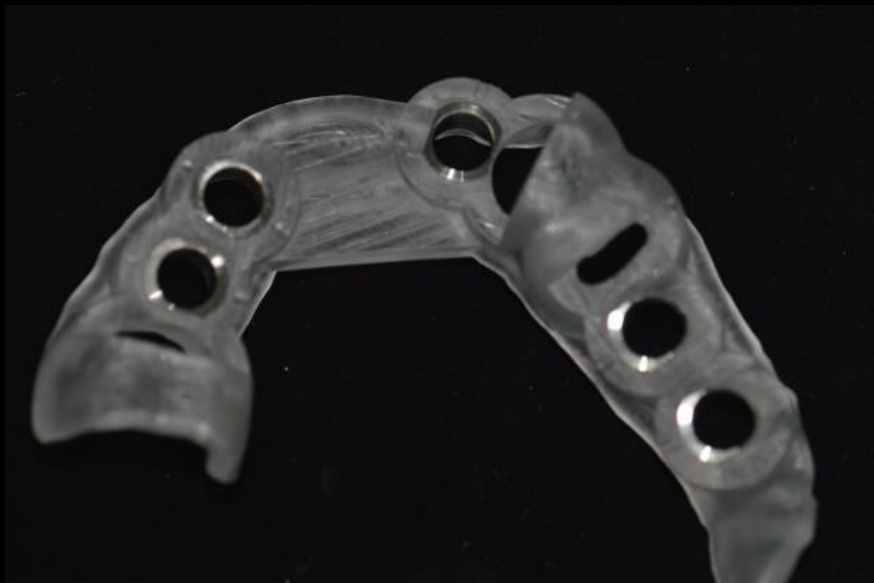

# Digital Guide S/W (Surgical Guide design)

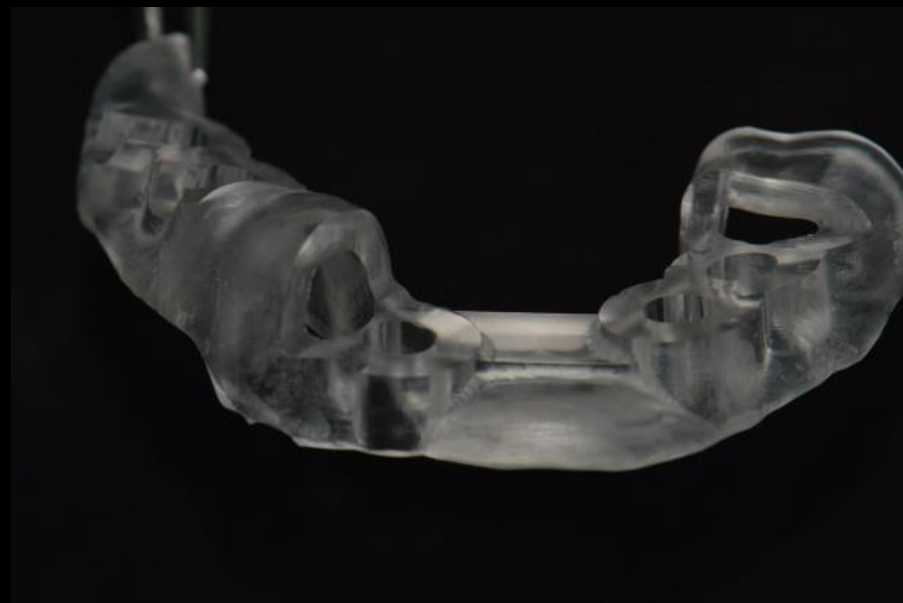
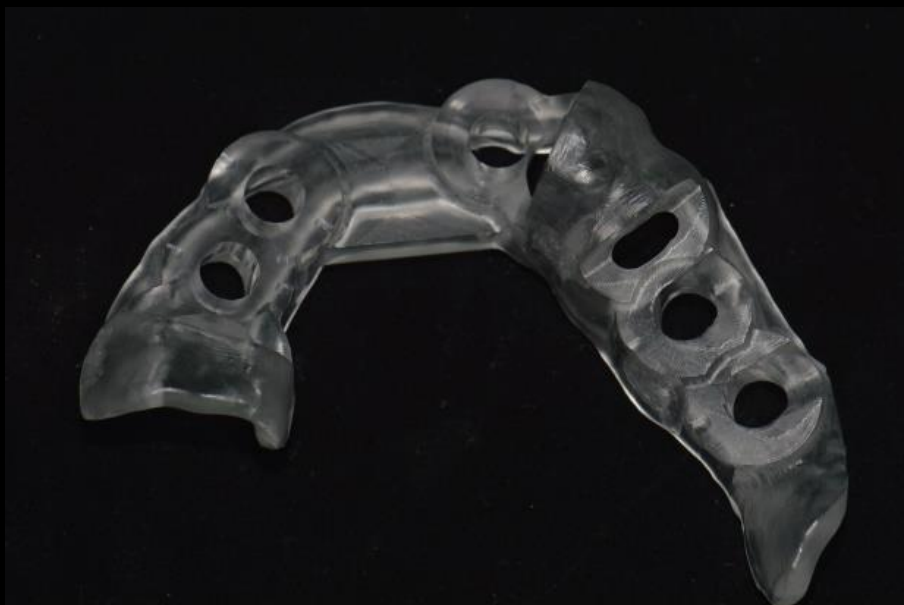


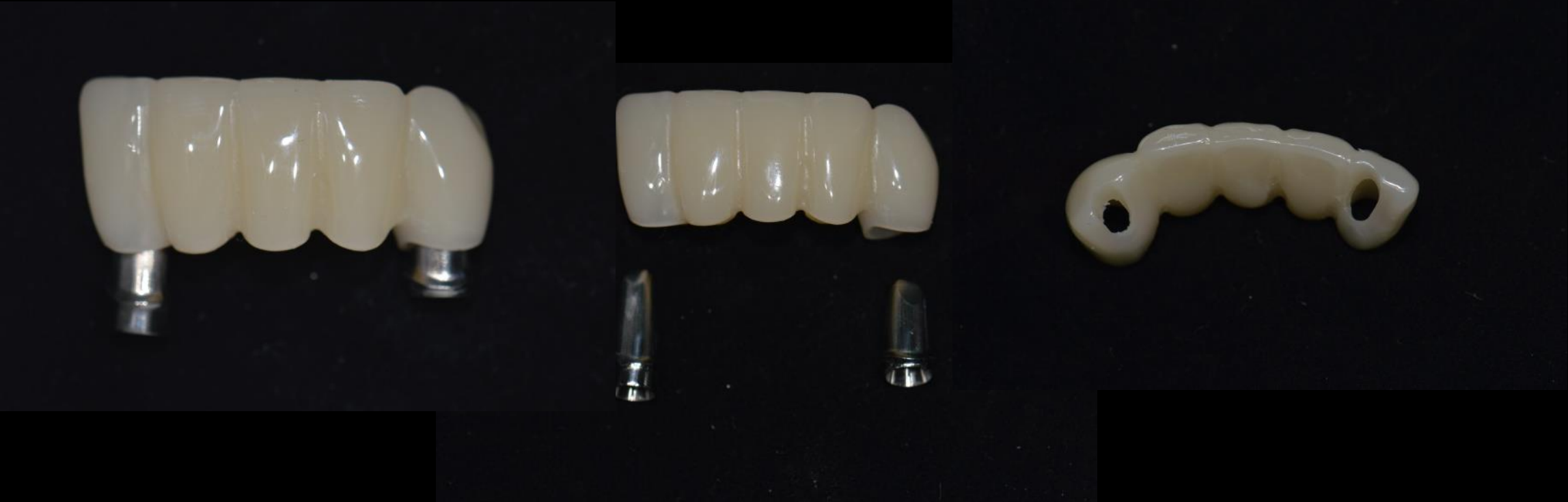## Printing Guide (Metal Sleeve)



## Milling Guide (Non Sleeve)



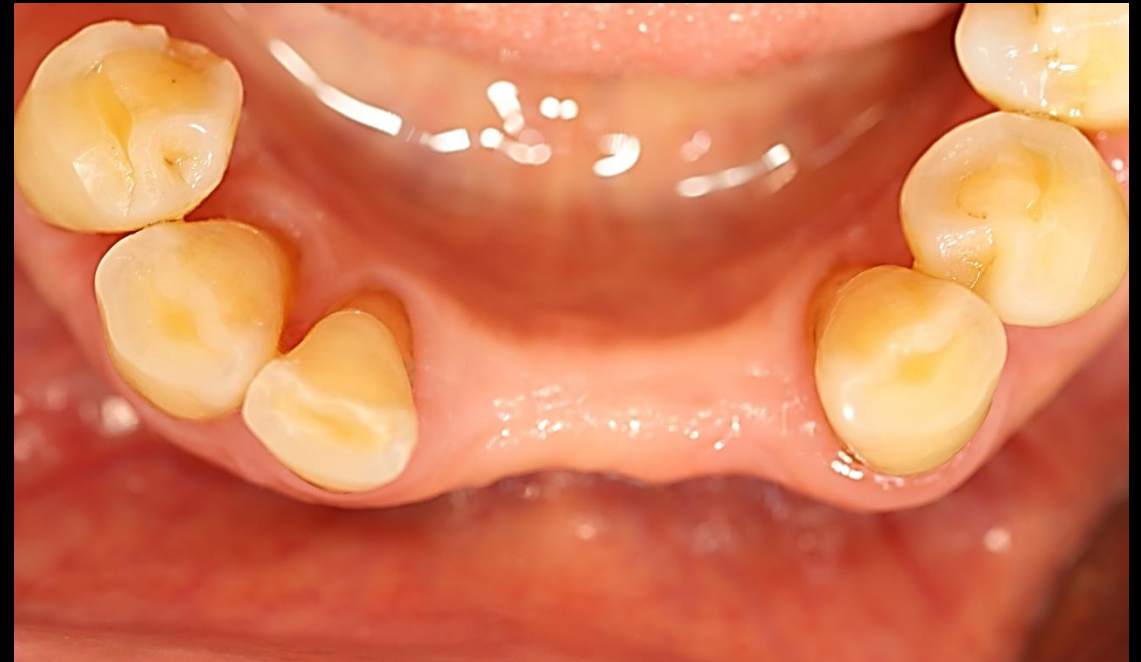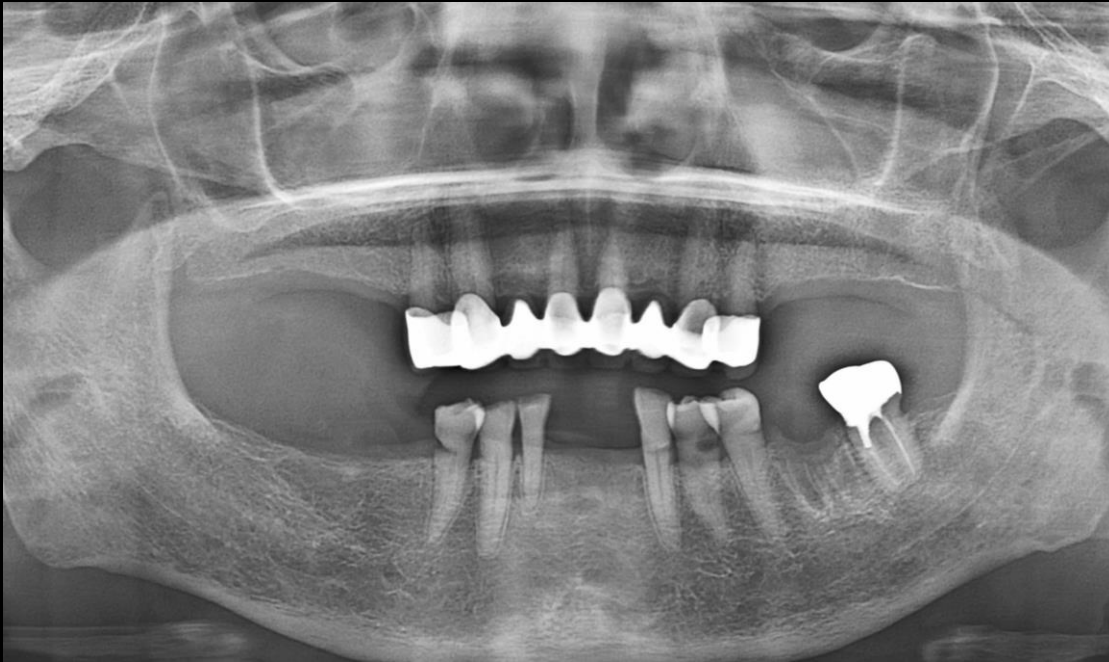# Customized abutment & Provisional restoration





## Similar case

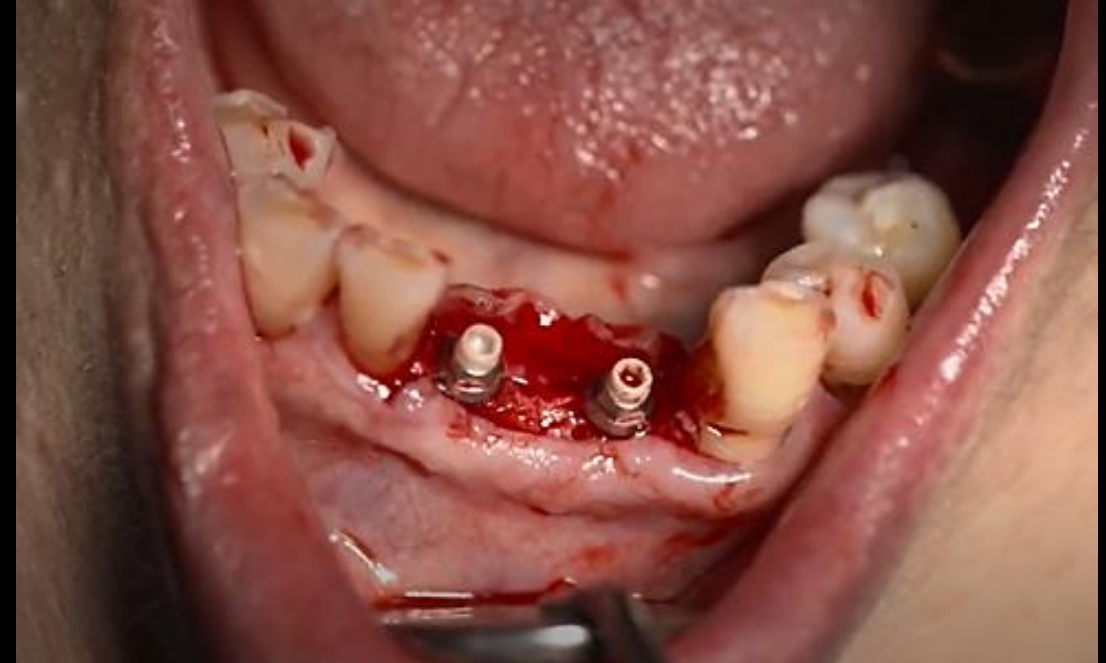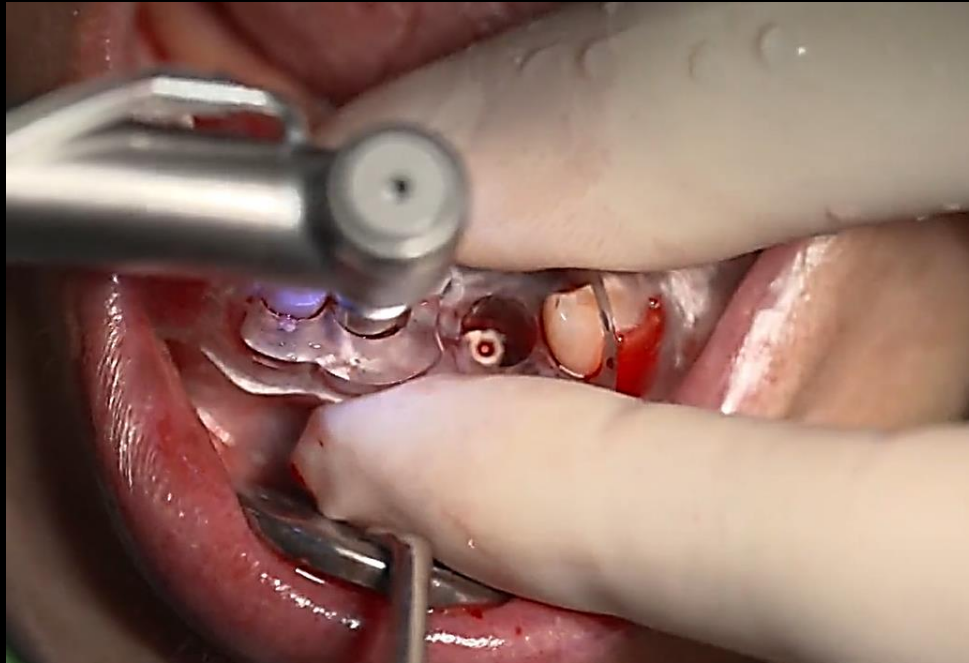
## Narrow ridge implant placement with digital guide system



Pre-op (2021-06-11)

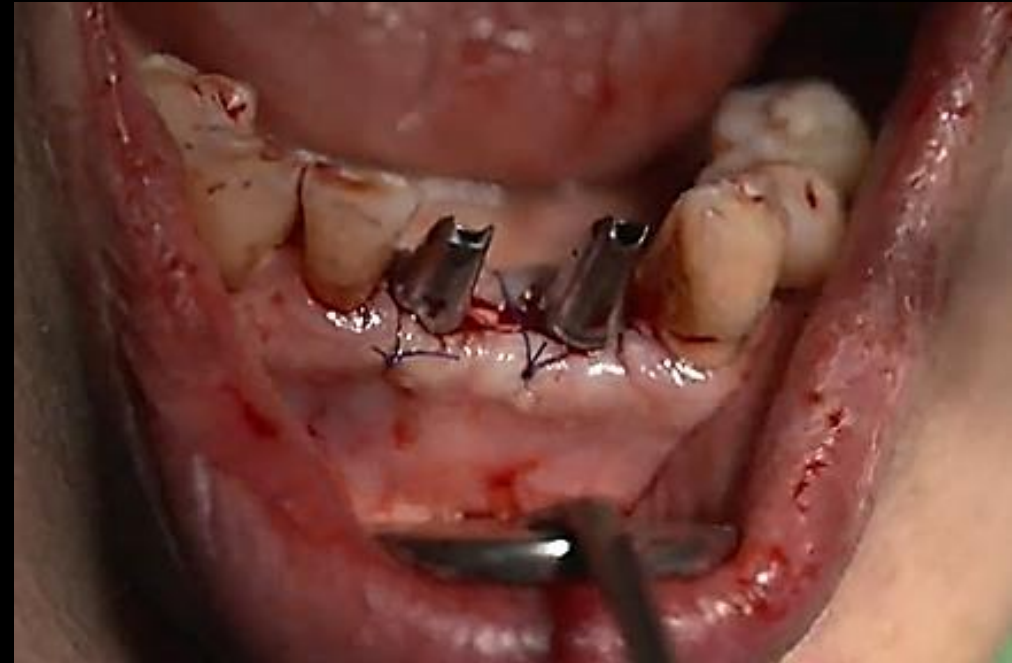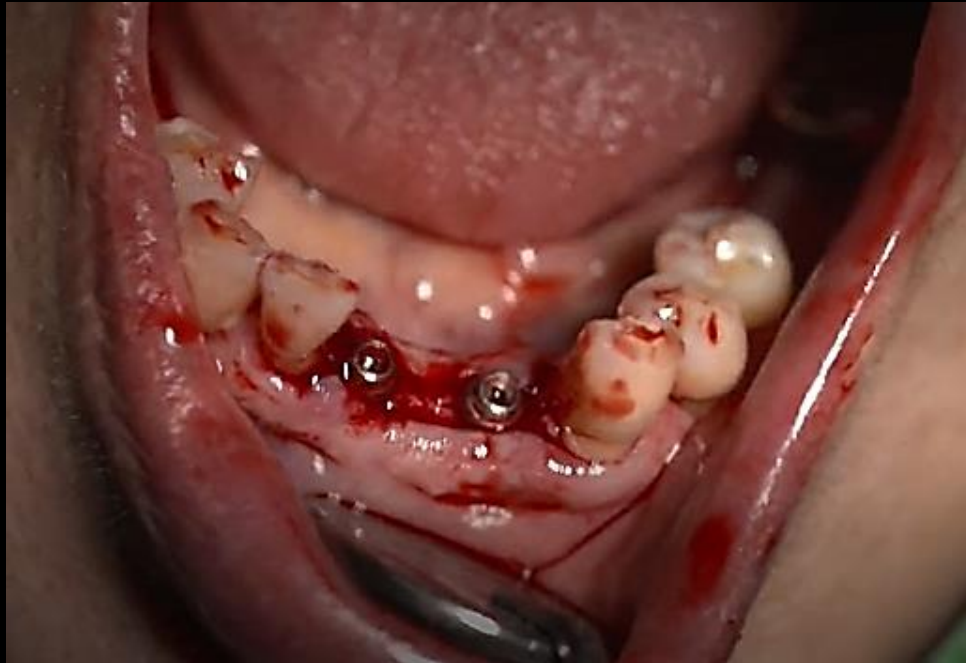## Similar case

Narrow ridge implant placement with digital guide system



## Similar case

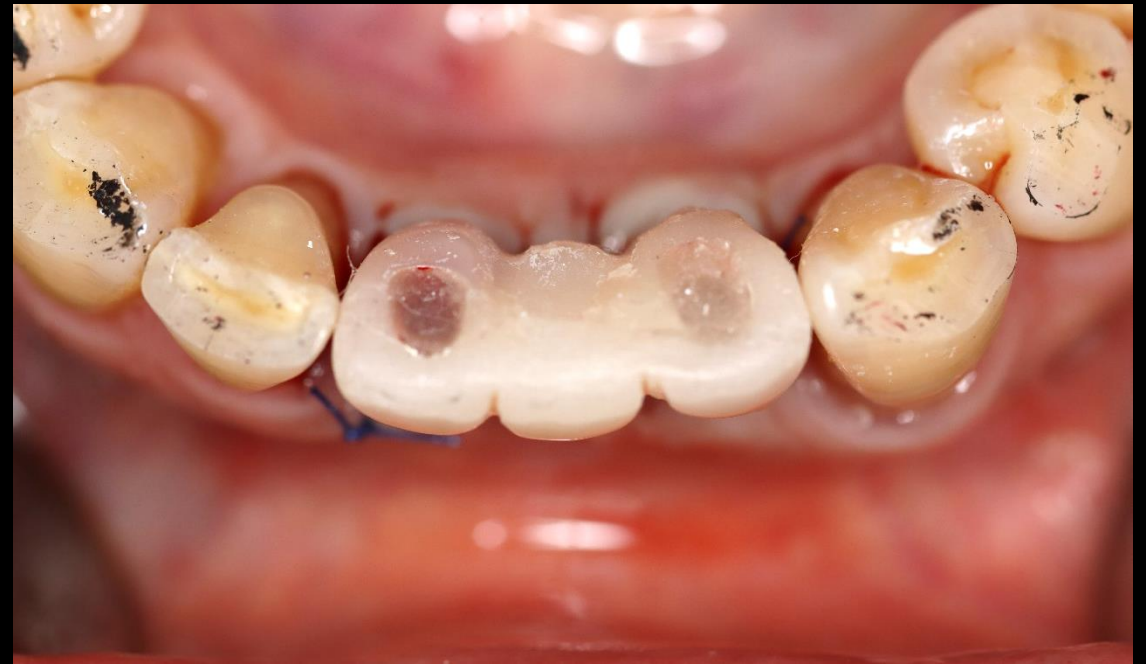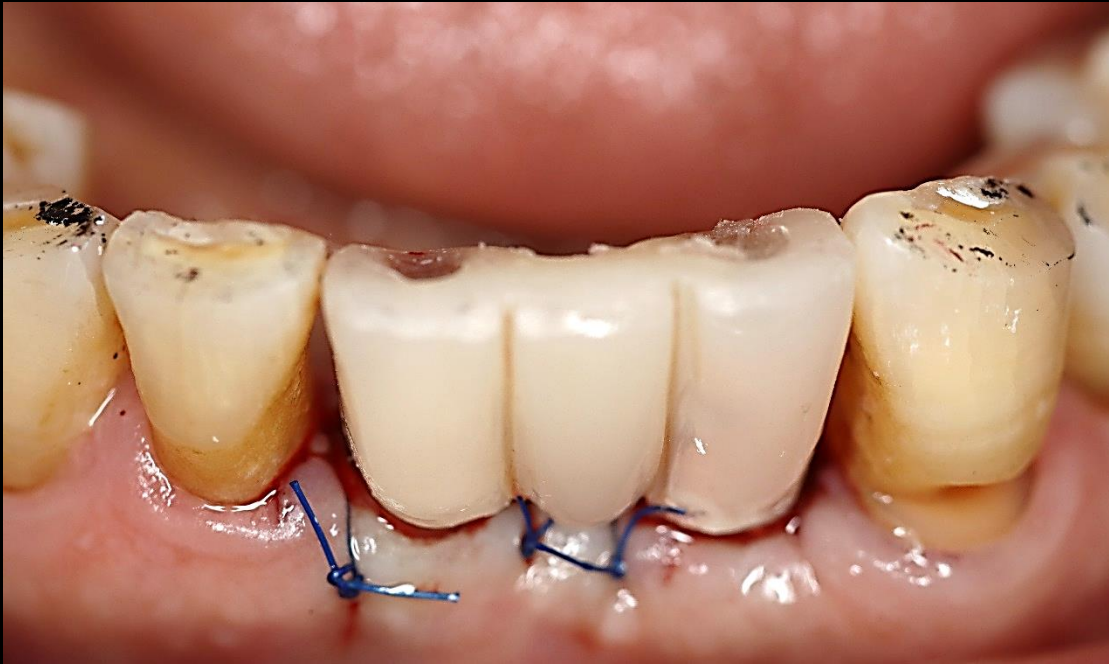Narrow ridge implant placement with digital guide system





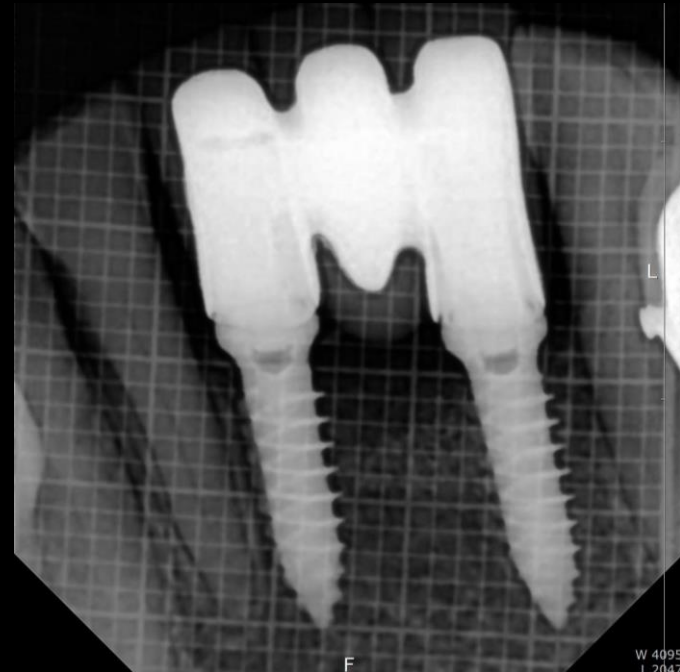
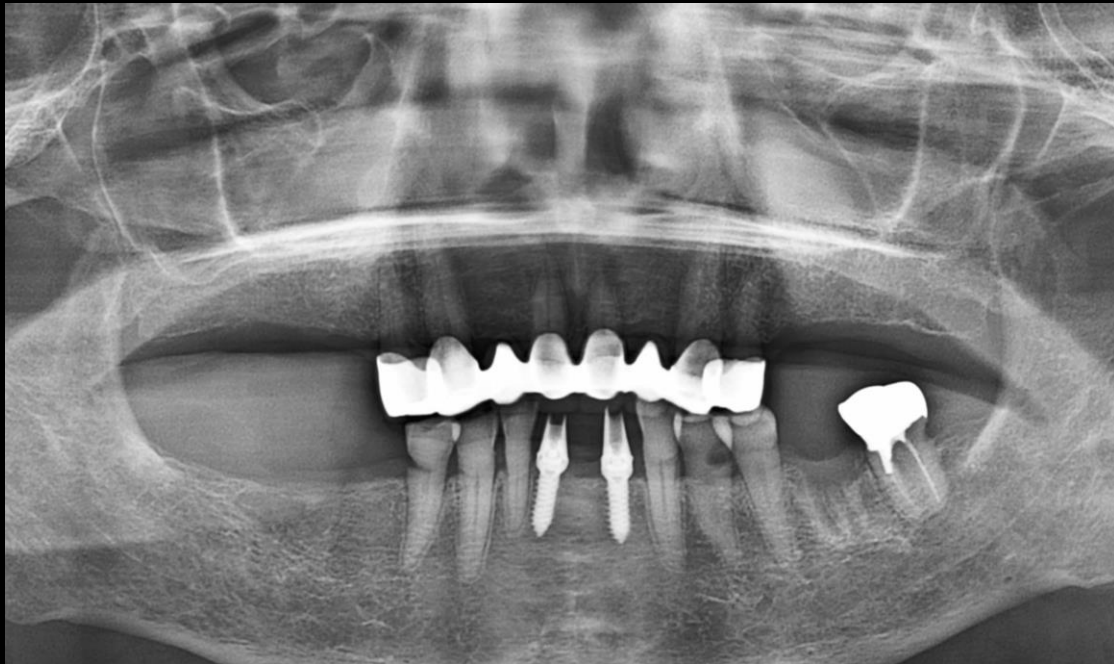## Similar case

Narrow ridge implant placement with digital guide system



## Similar case

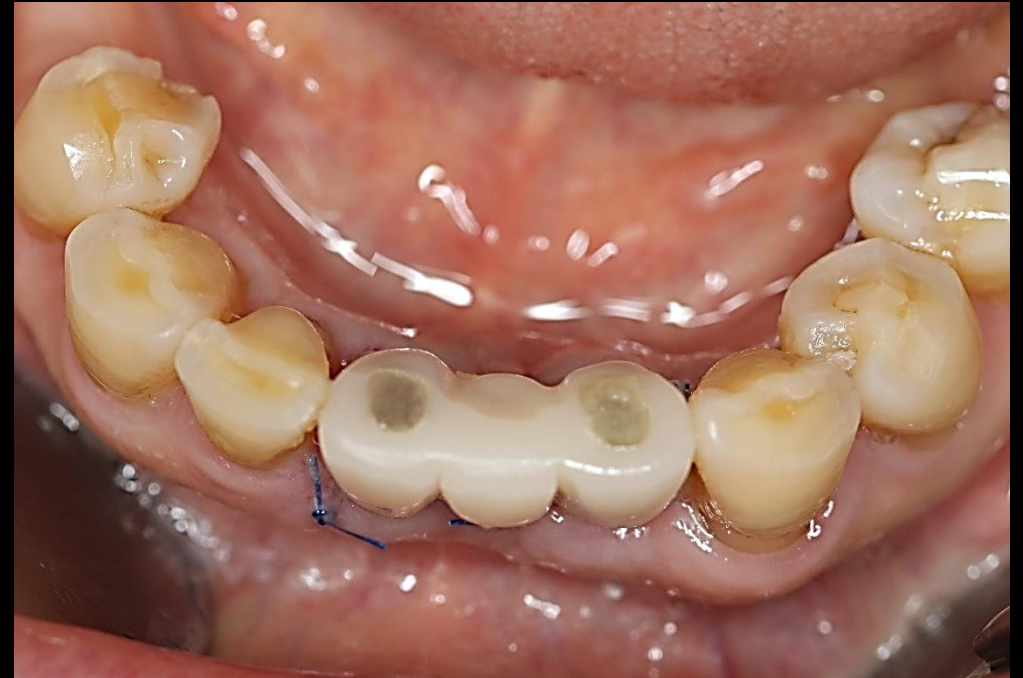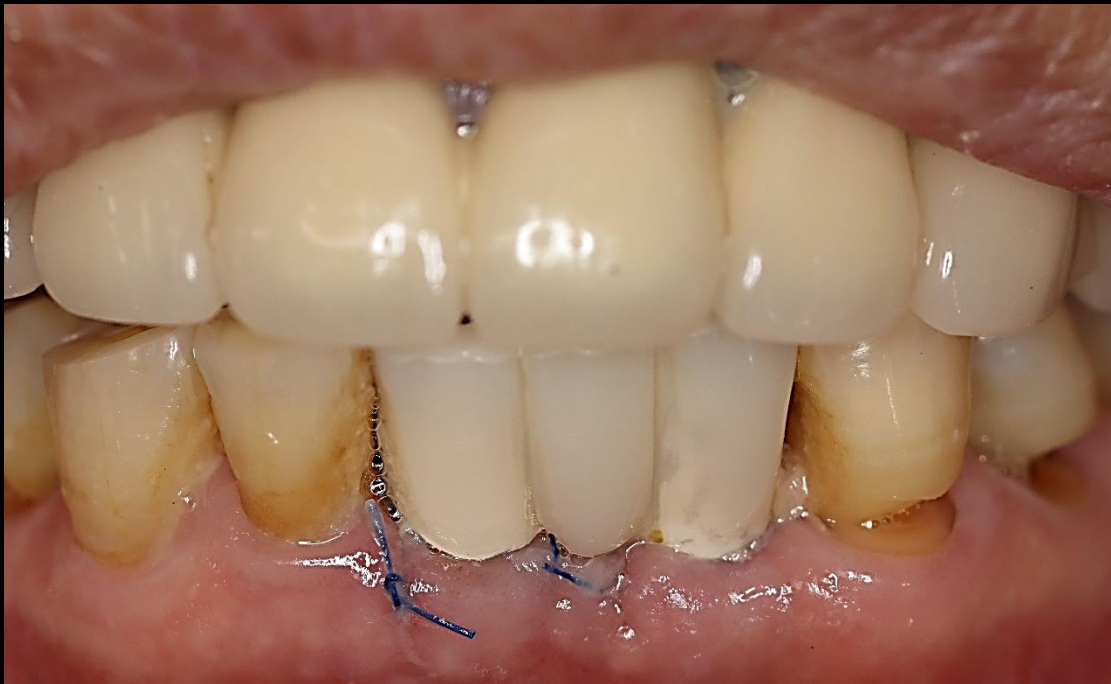## Narrow ridge implant placement with digital guide system



Post-op (2021-06-11)

## Similar case

Narrow ridge implant placement with digital guide system

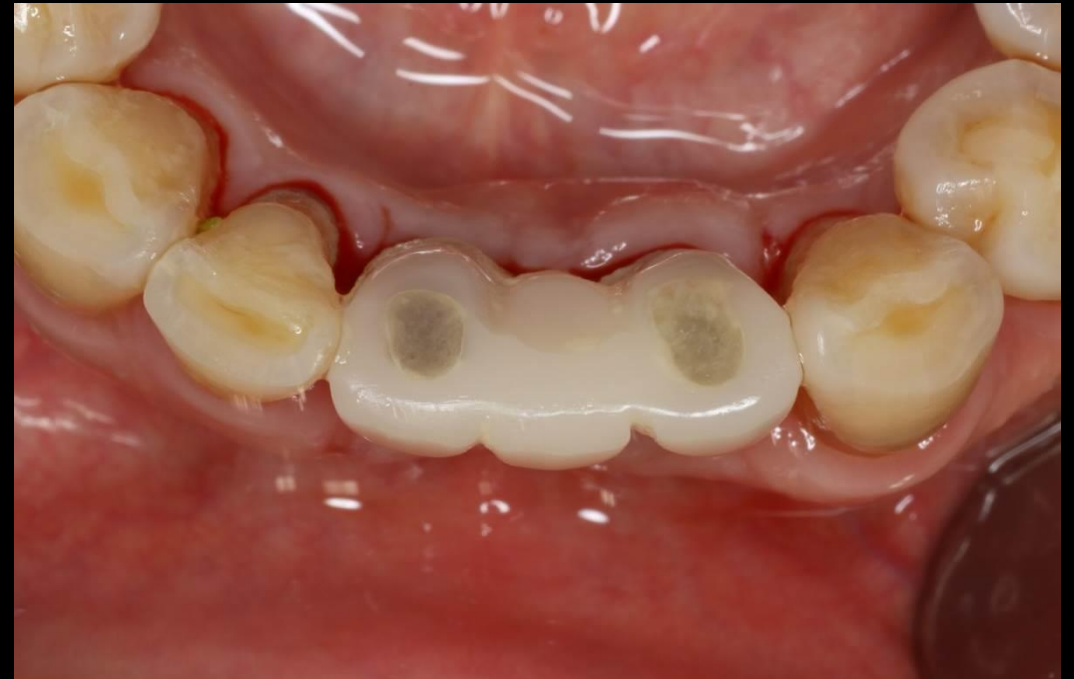
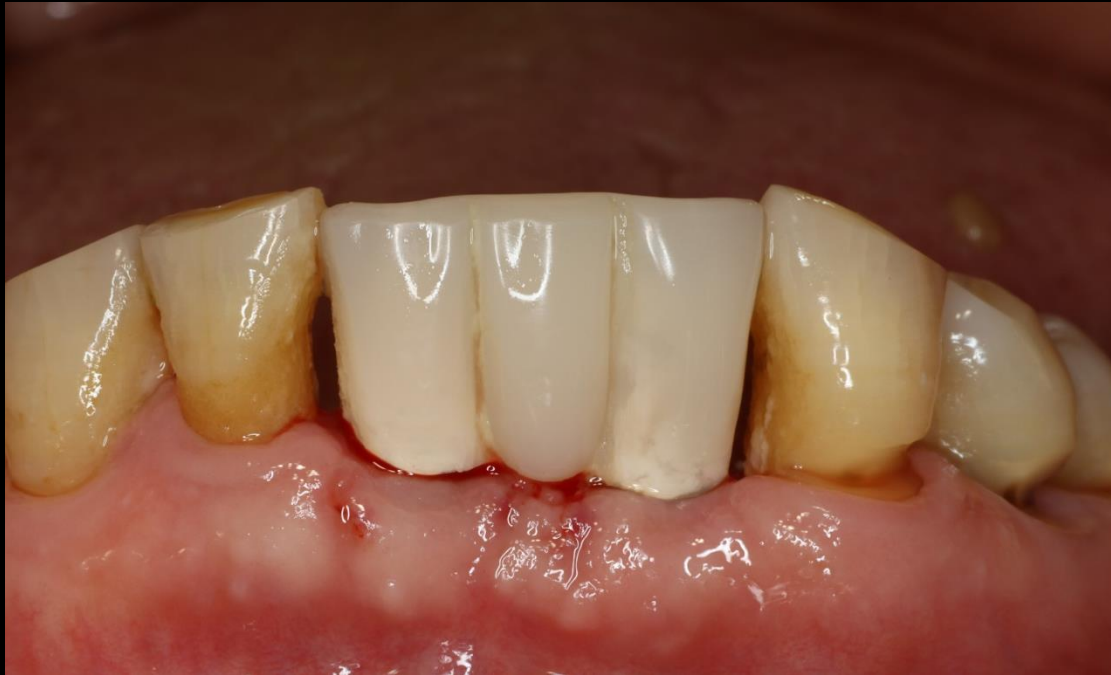
Healing : 1 weeks  
(2021-06-17)



## Similar case

Narrow ridge implant placement with digital guide system



Healing : 2 weeks  
(2021-06-24)

