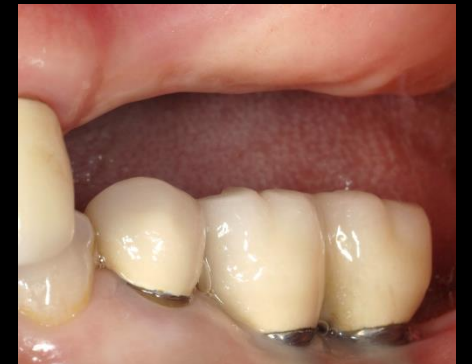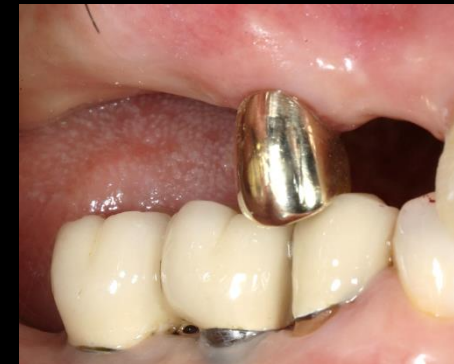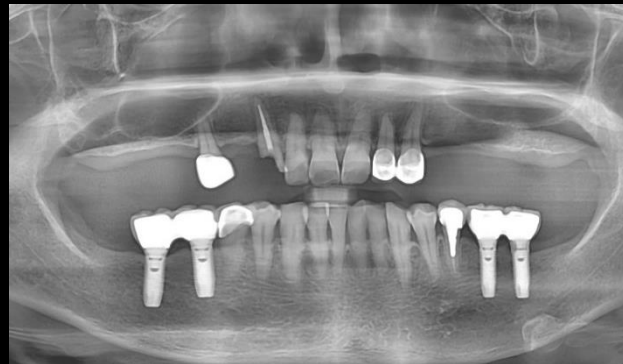




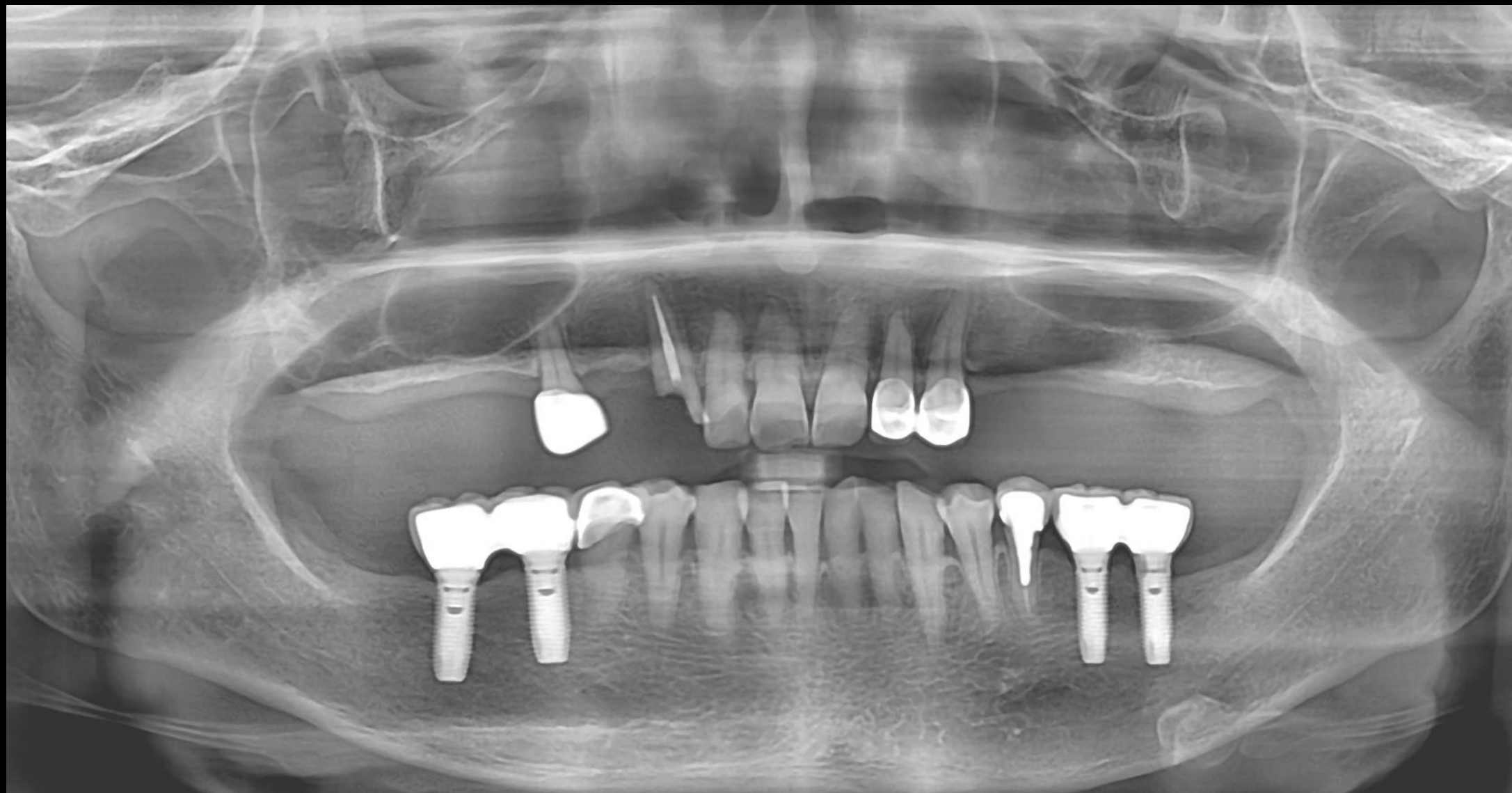
Bilateral maxillary sinus elevation and Simultaneous implantation

Dr. SM Chung
2021.9.3 (Fri)

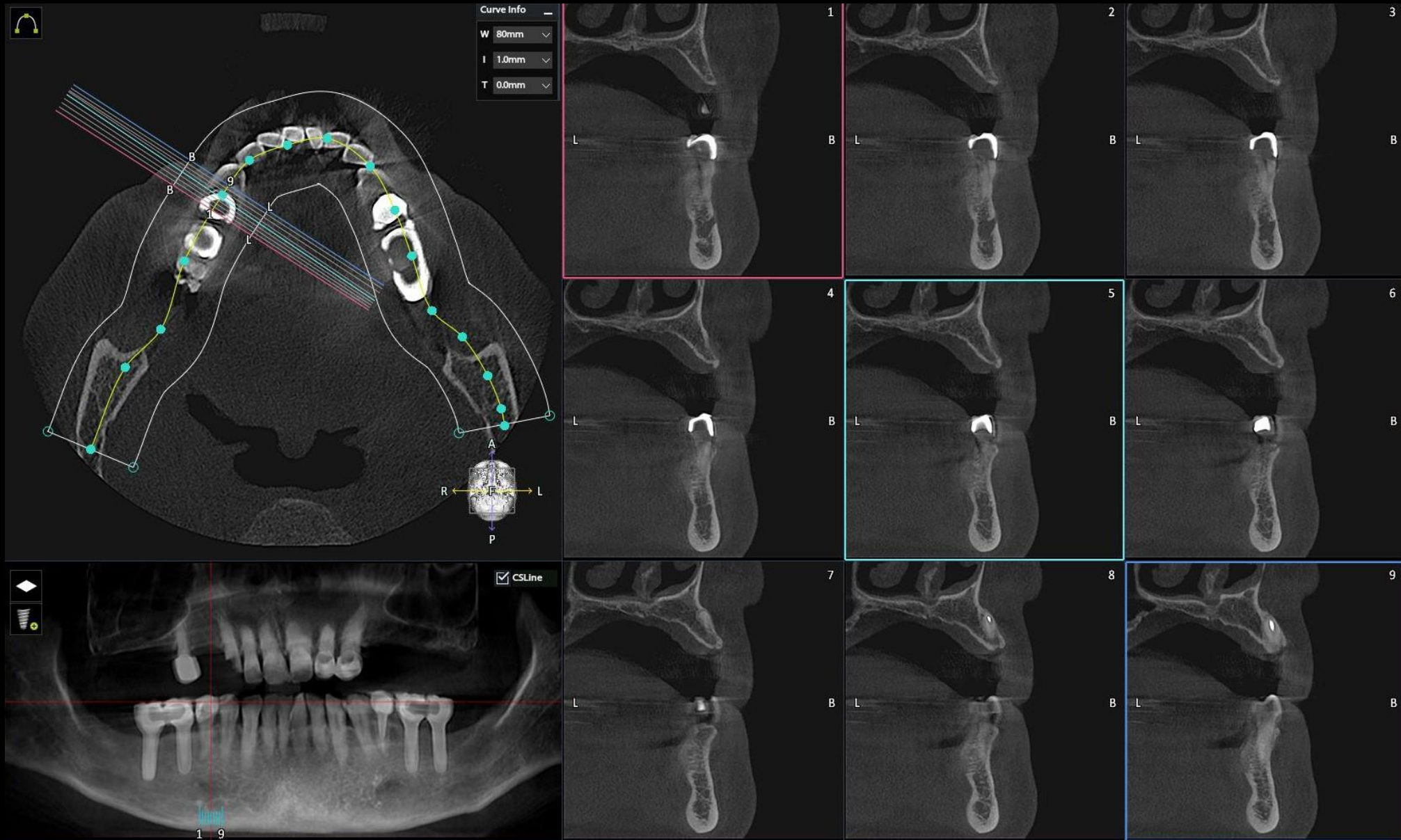


64yrs / Female

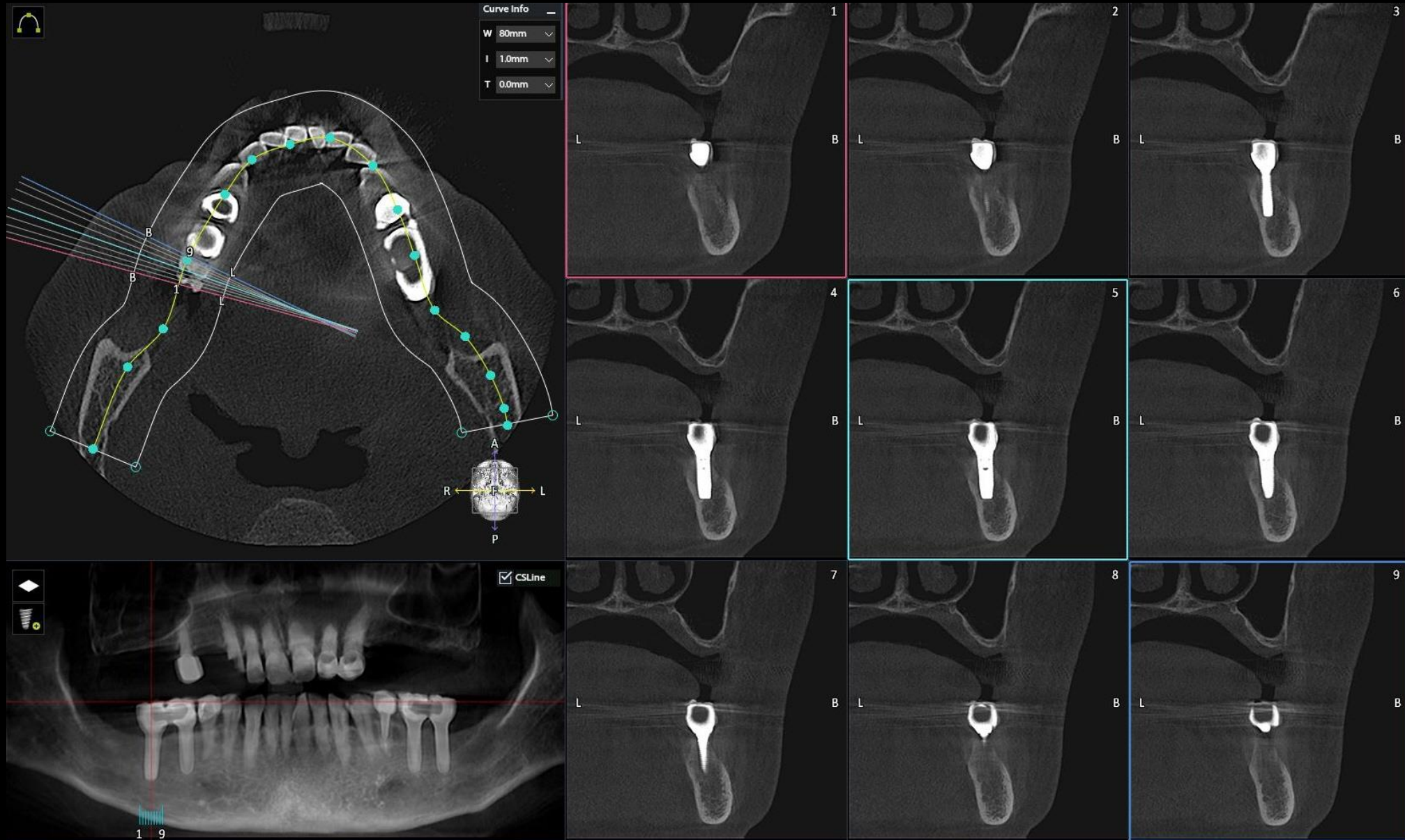
Pre-op (2021-07-26)



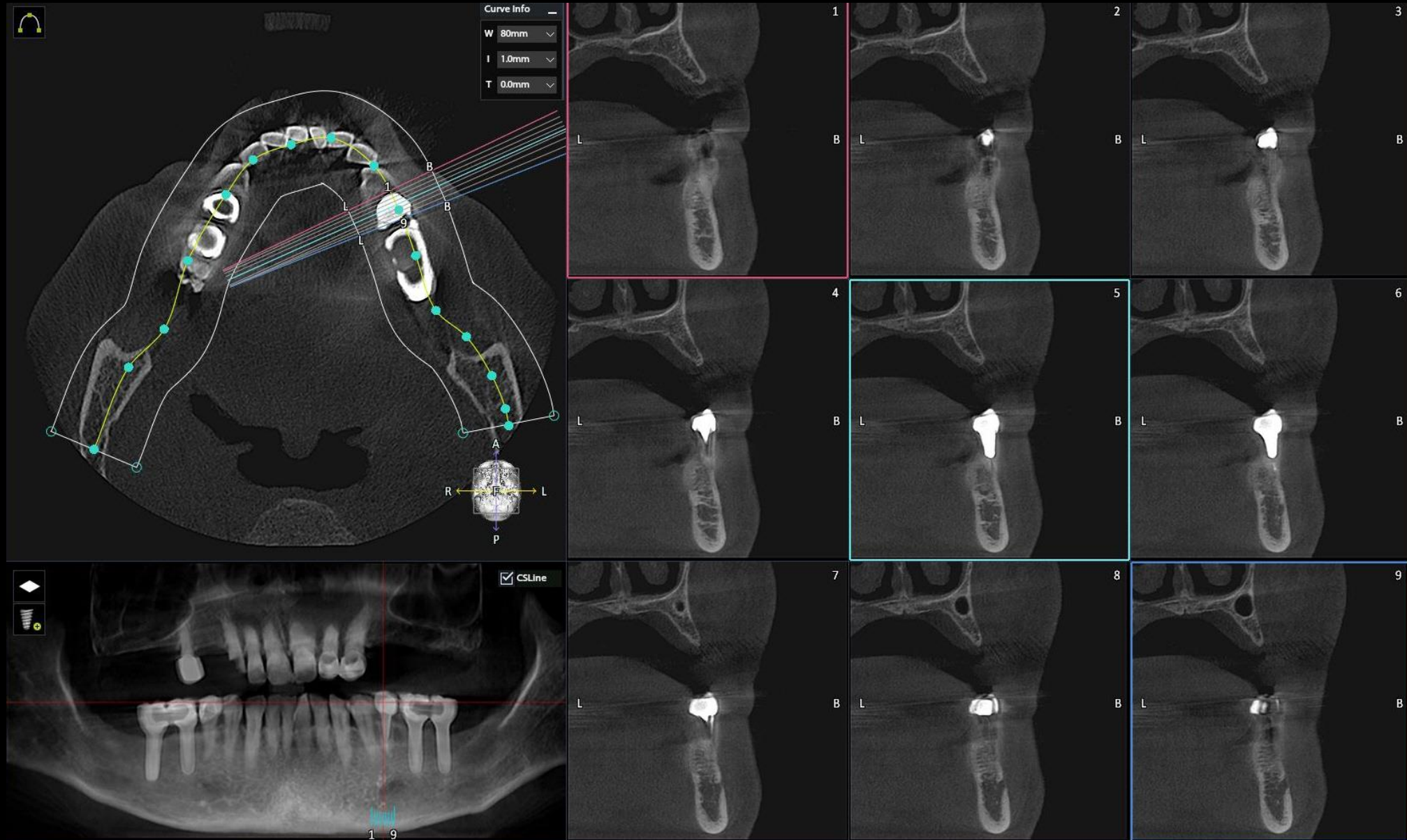
#14 Pre-op (2021-07-26)

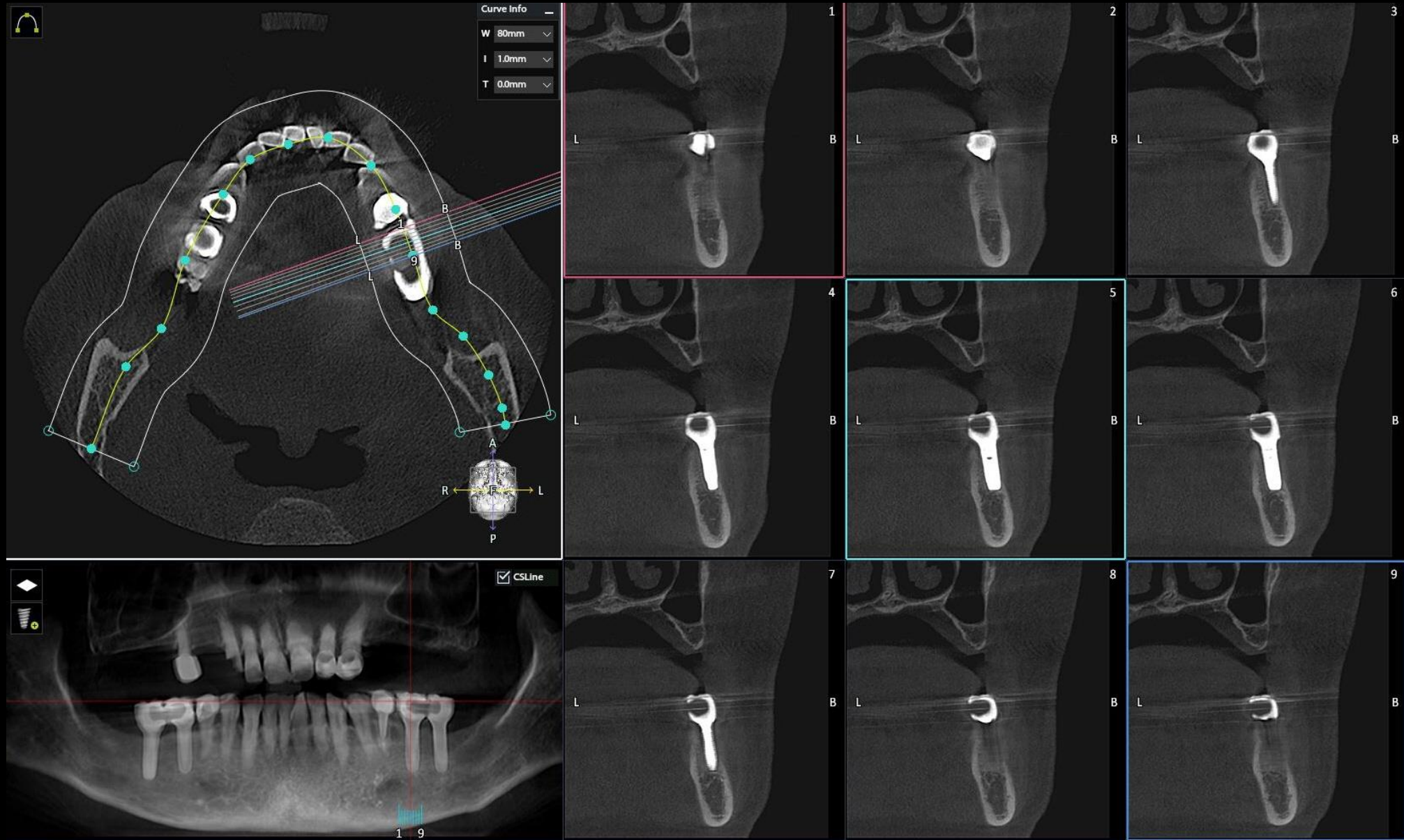


#16 Pre-op (2021-07-26)

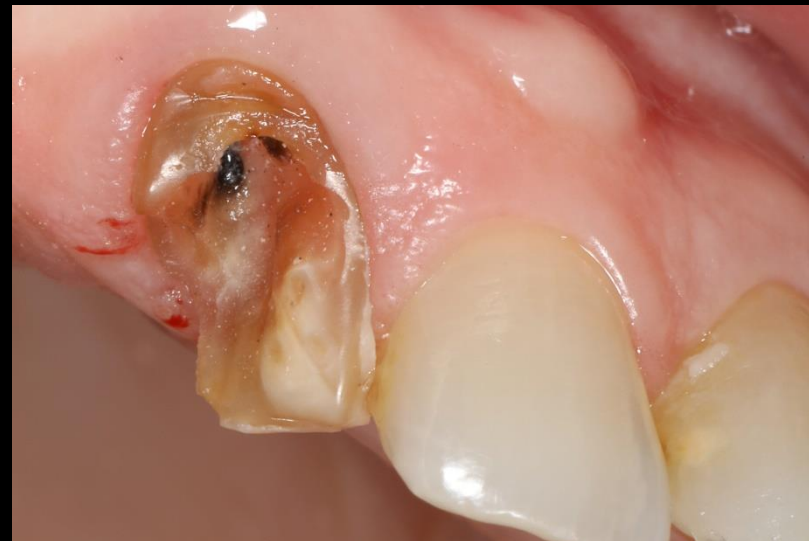
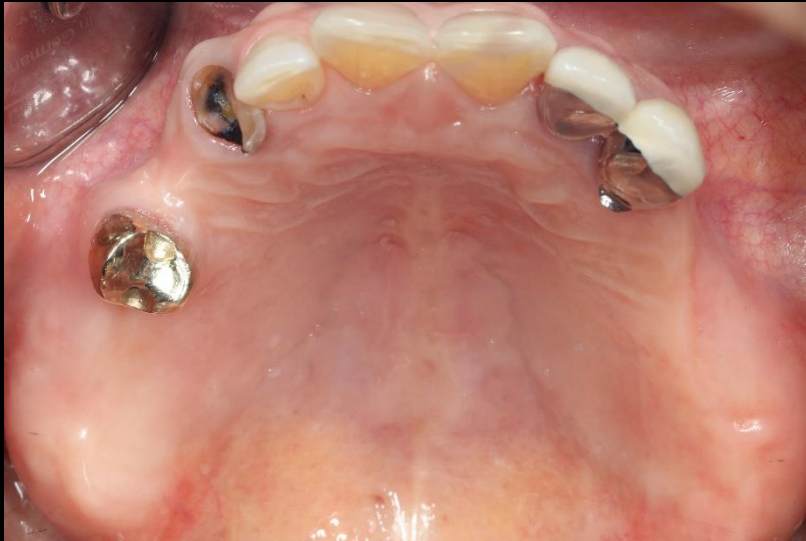
#24 Pre-op (2021-07-26)

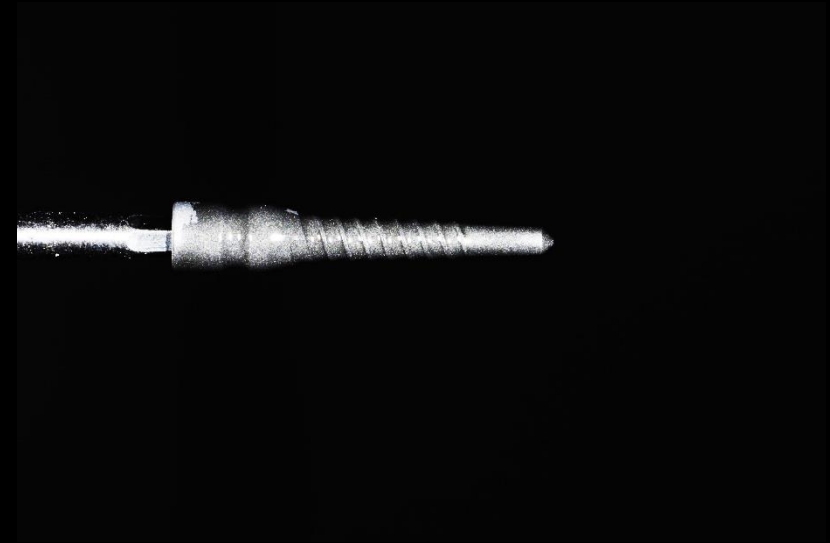
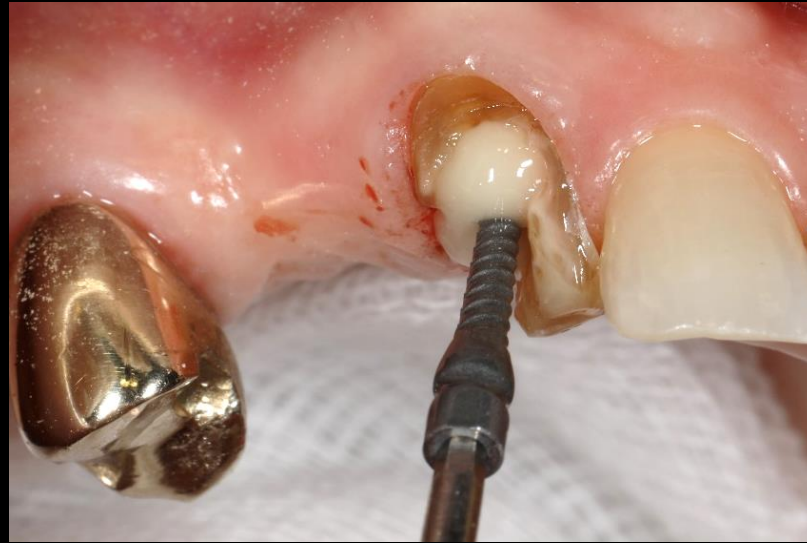
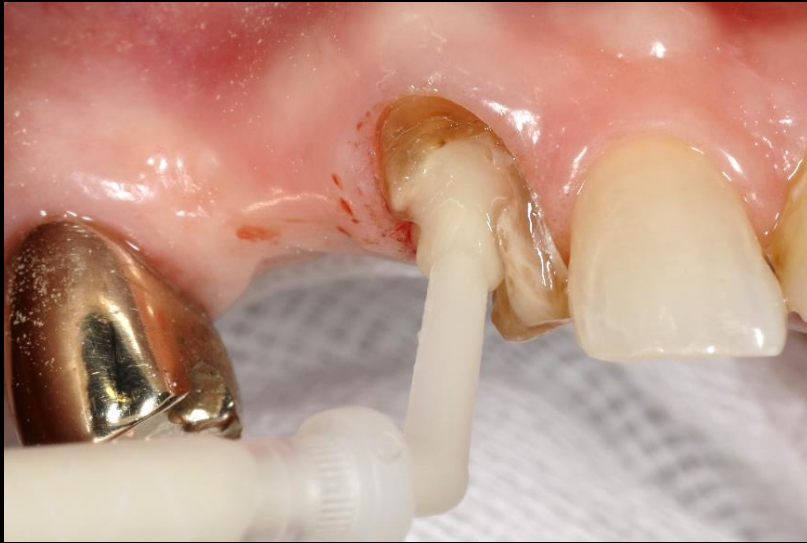


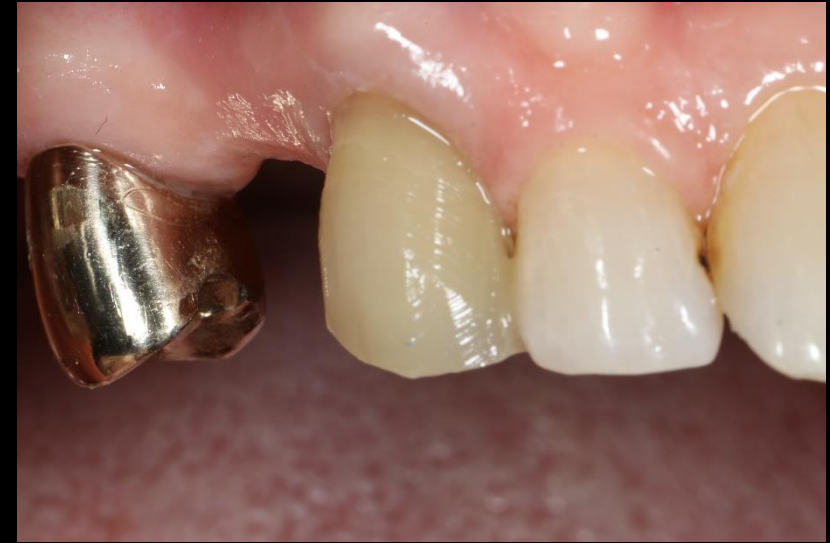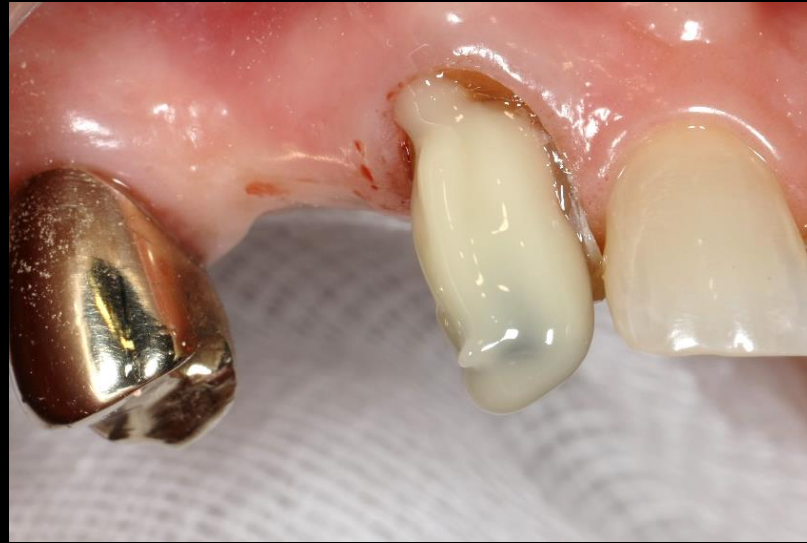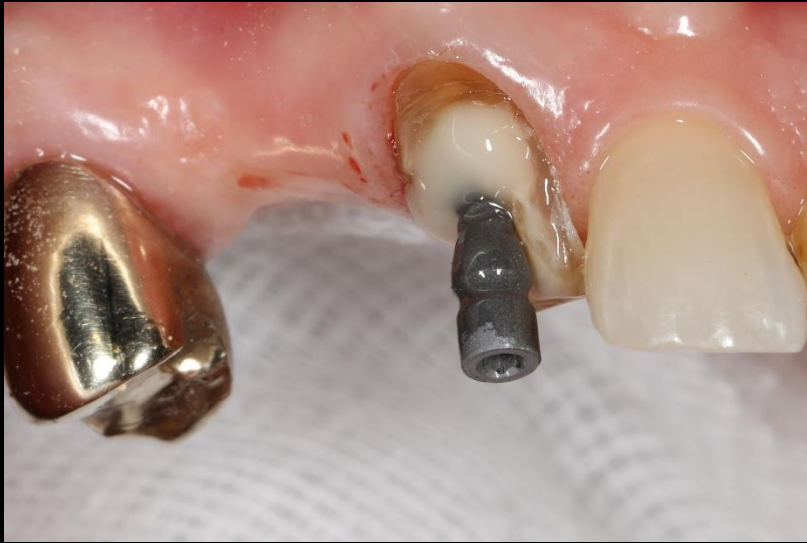Oral exam (2021-08-18)



#13 Post & Core (2021-08-18)



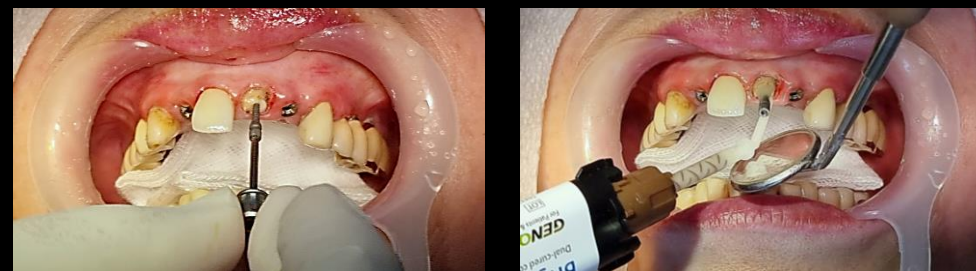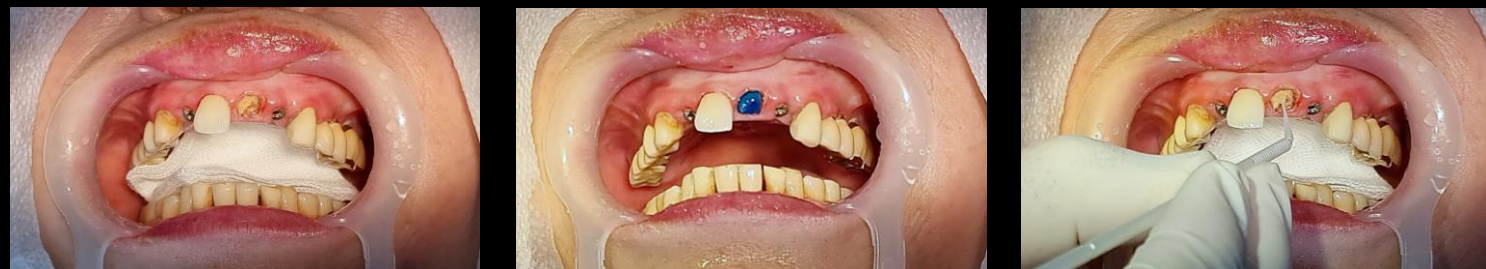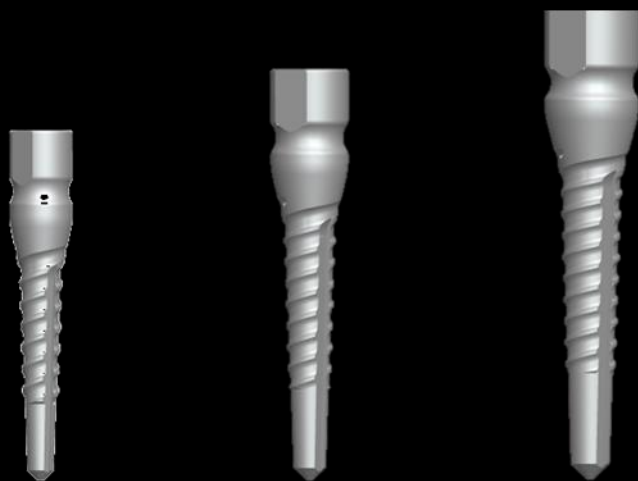
#13 Post & Core (2021-08-18)



Metal(Titanium) Post

Bright

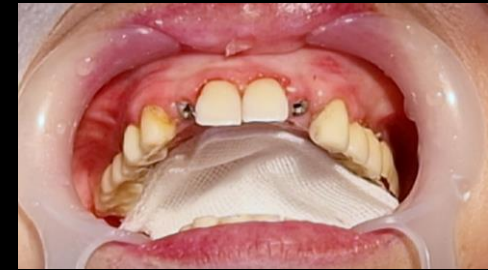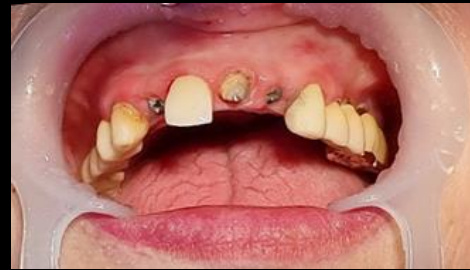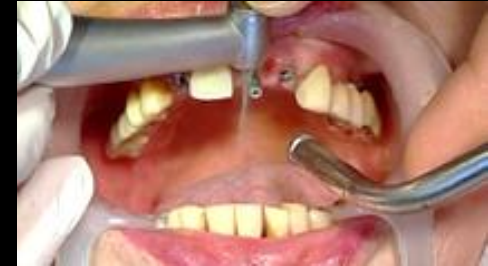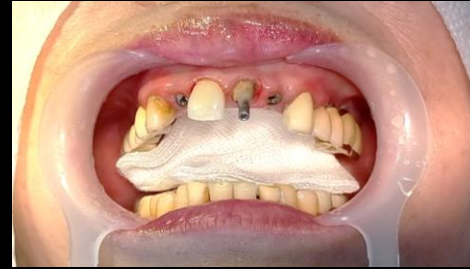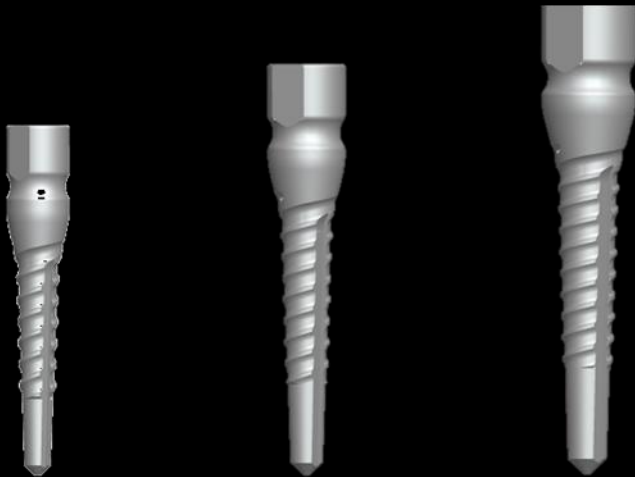
ROOT CANAL IMPLANT



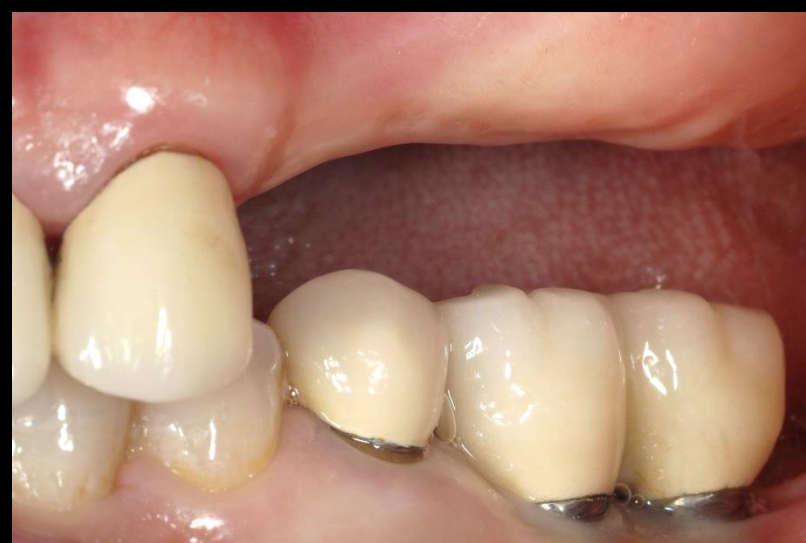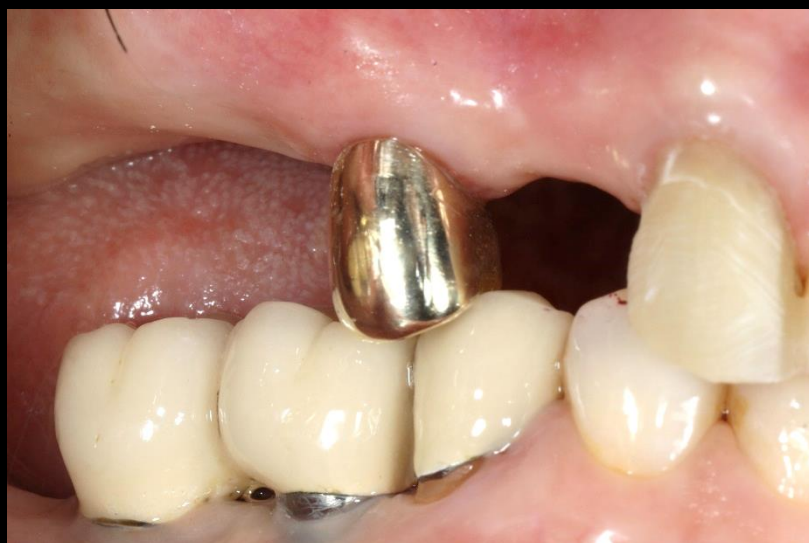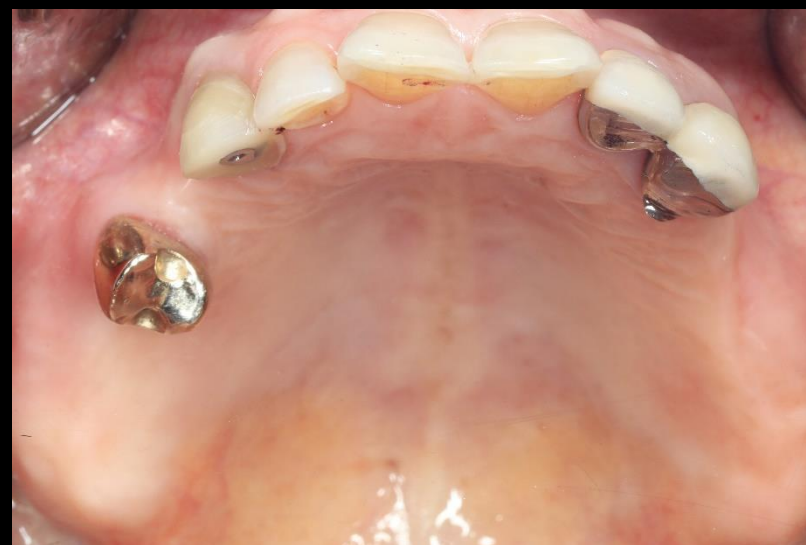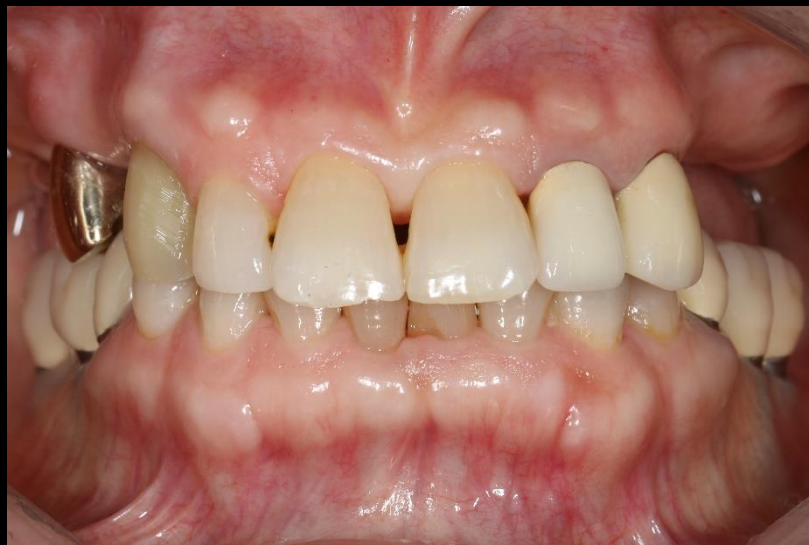Metal(Titanium) Post

Bright

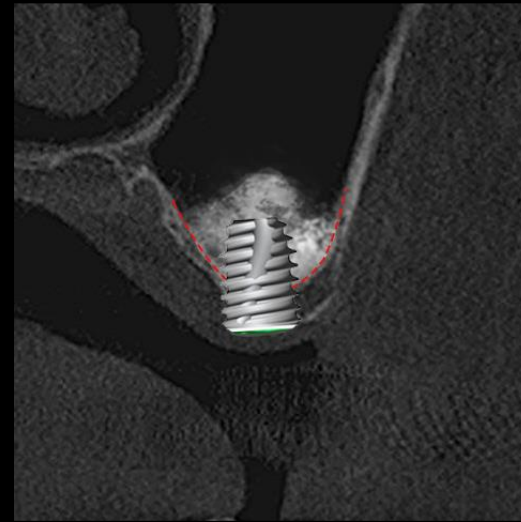
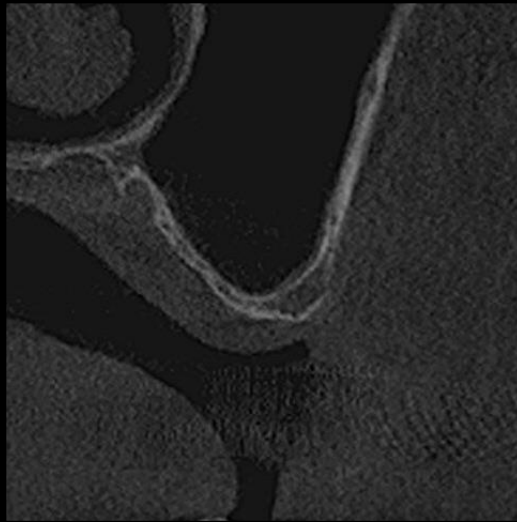
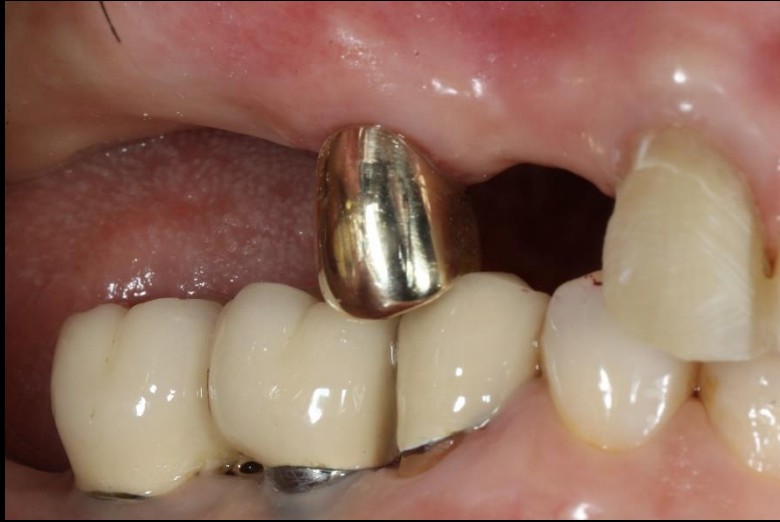ROOT CANAL IMPLANT



Pre-op (2021-08-18)

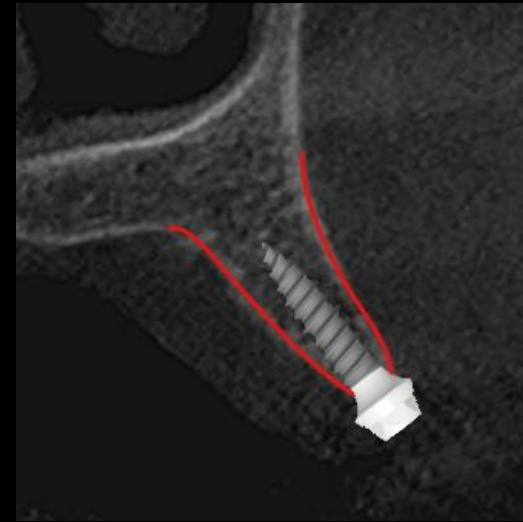
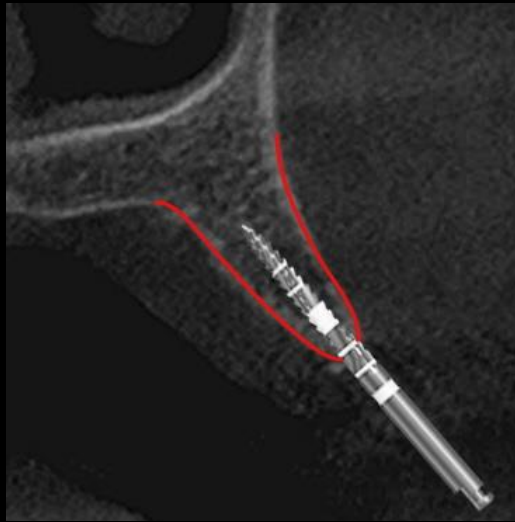
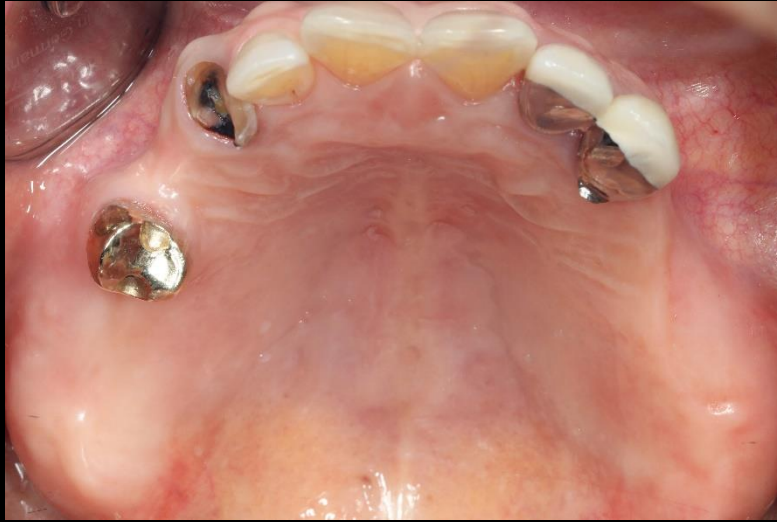

Surgery Plan (#16)



- 2 Stage surgery with bright Bone Level $\varnothing 5.0 * 7\text{mm}$
- Sinus elevation with Lateral approach

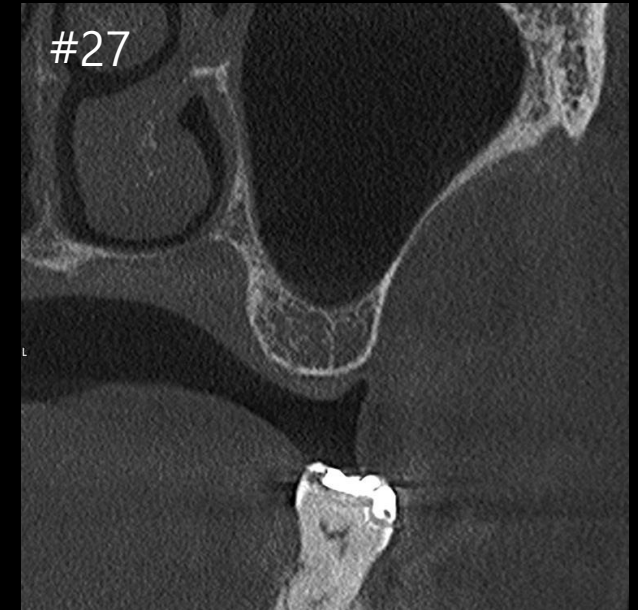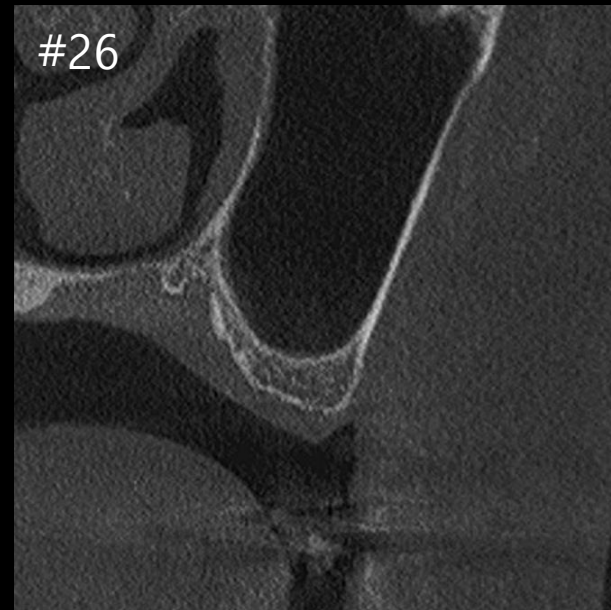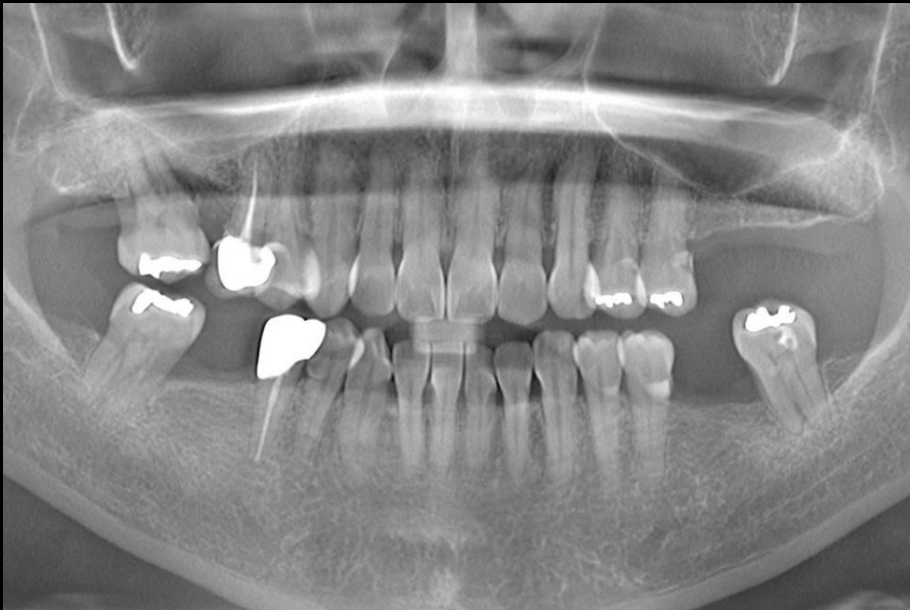
Surgery Plan (#14,24,26)



- Narrow ridge implantation with **“Minimalism”**
- #14 bright Tissue Level $\varnothing 3.0 * 9\text{mm}$ / #24 $\varnothing 2.5 * 7\text{mm}$
- #26 bright Tissue Level $\varnothing 3.5 * 7\text{mm}$

Similar case 1

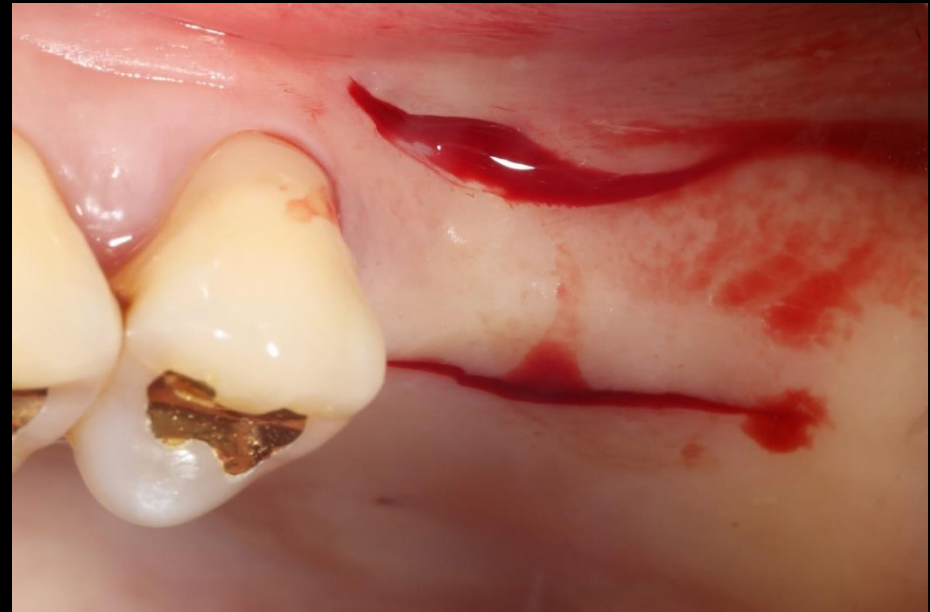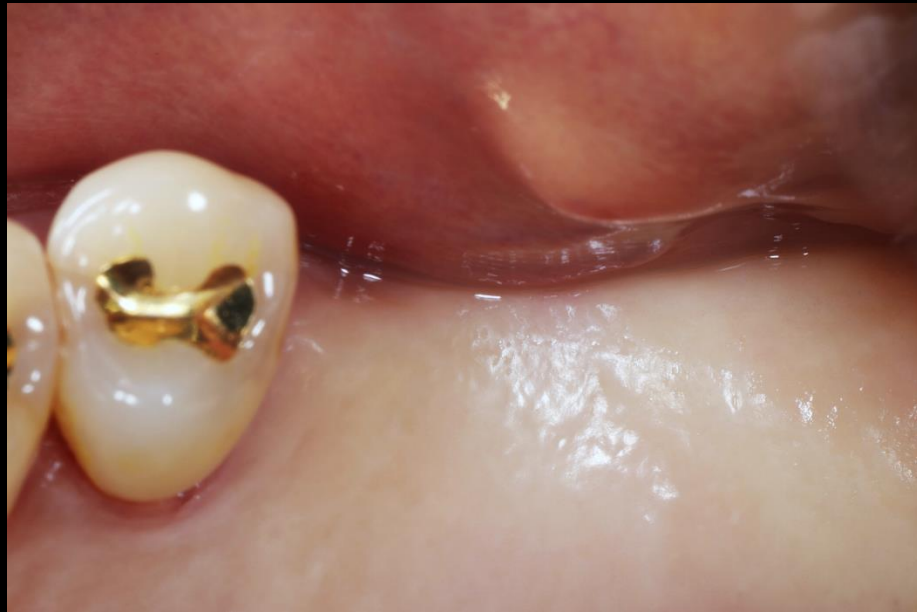Posterior implant restoration using Digital impression process



Pre-op

Similar case 1

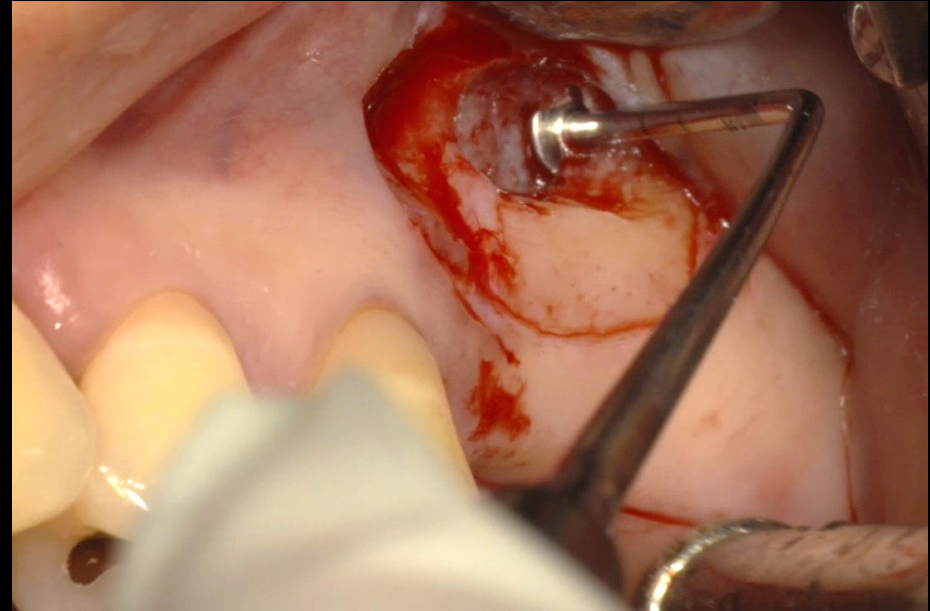
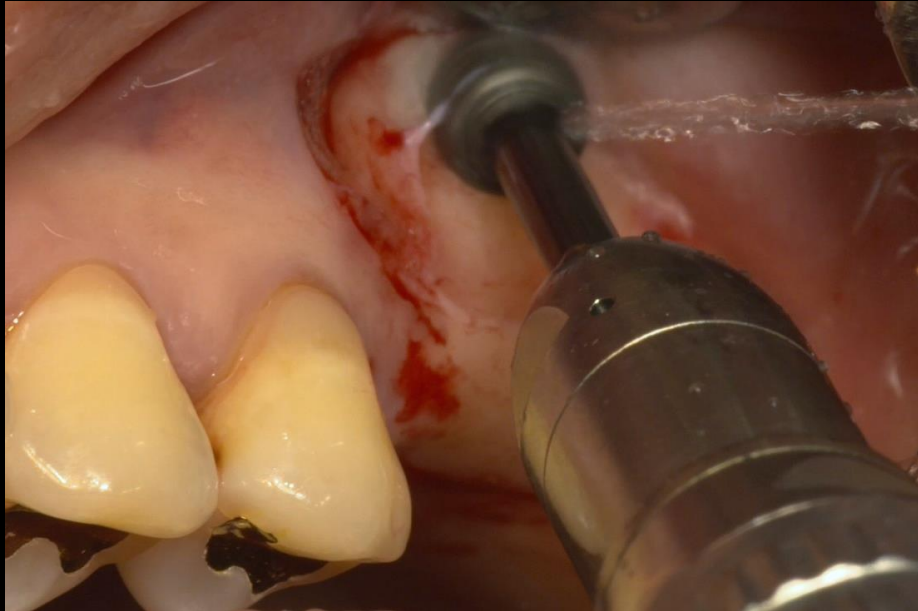
Posterior implant restoration using Digital impression process



Surgery

Similar case 1

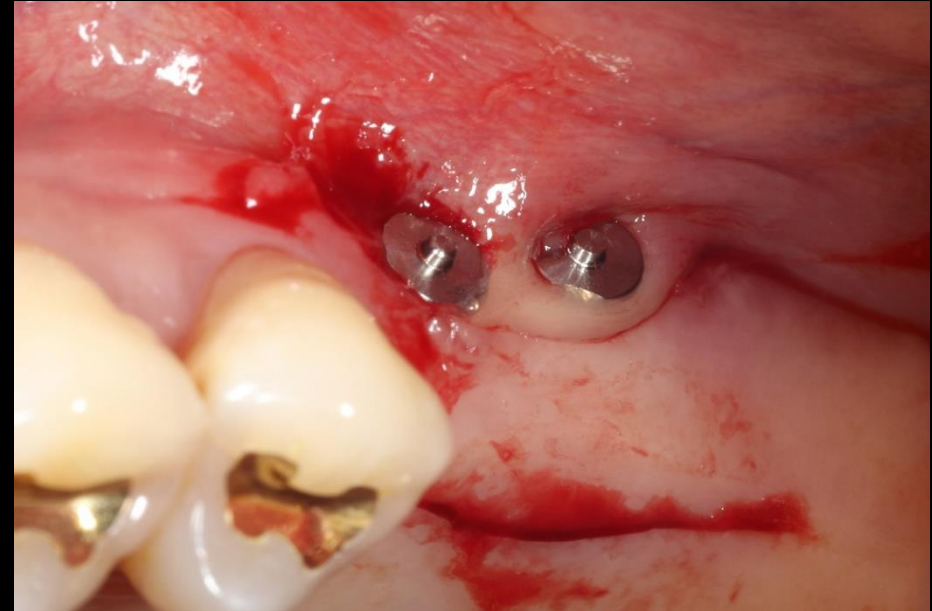
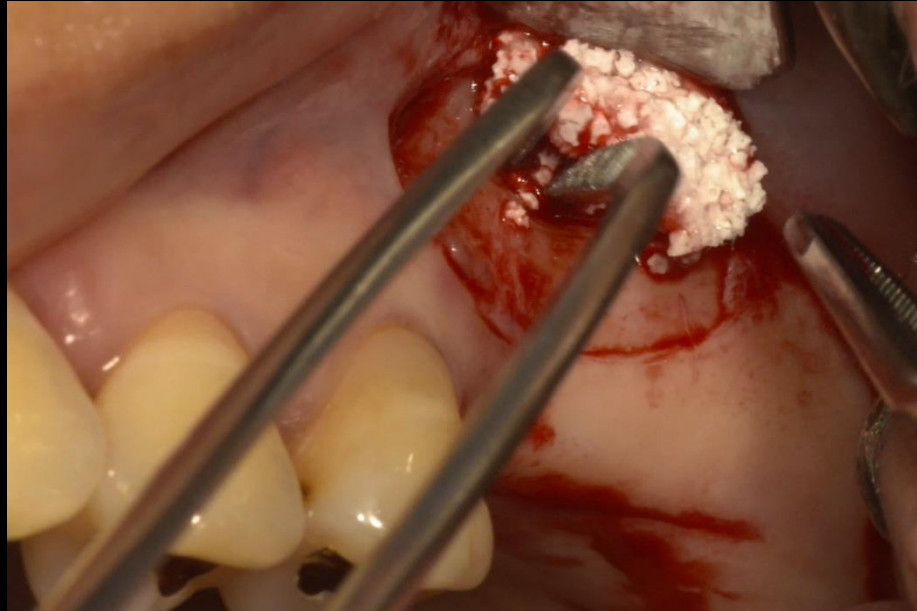
Posterior implant restoration using Digital impression process



Surgery

Similar case 1

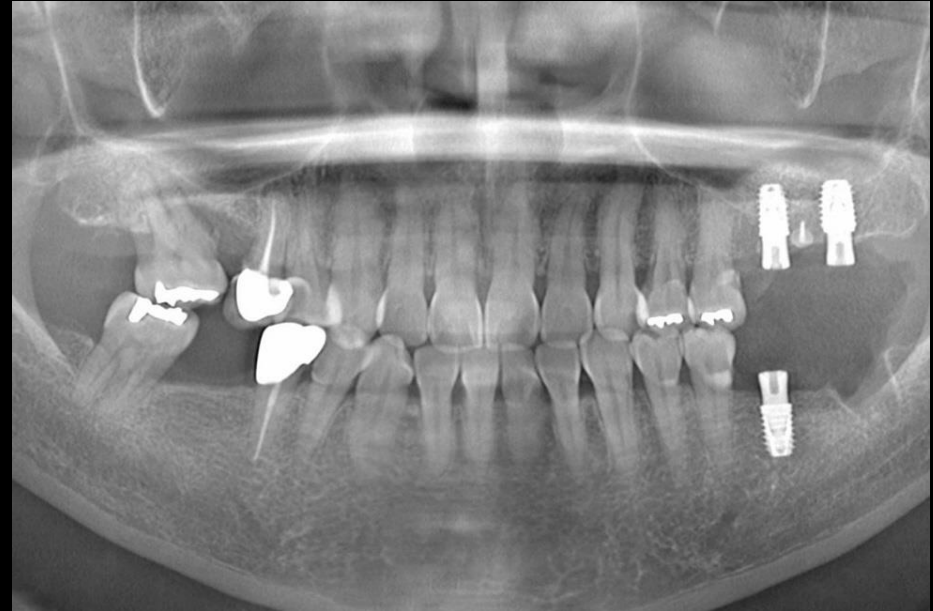
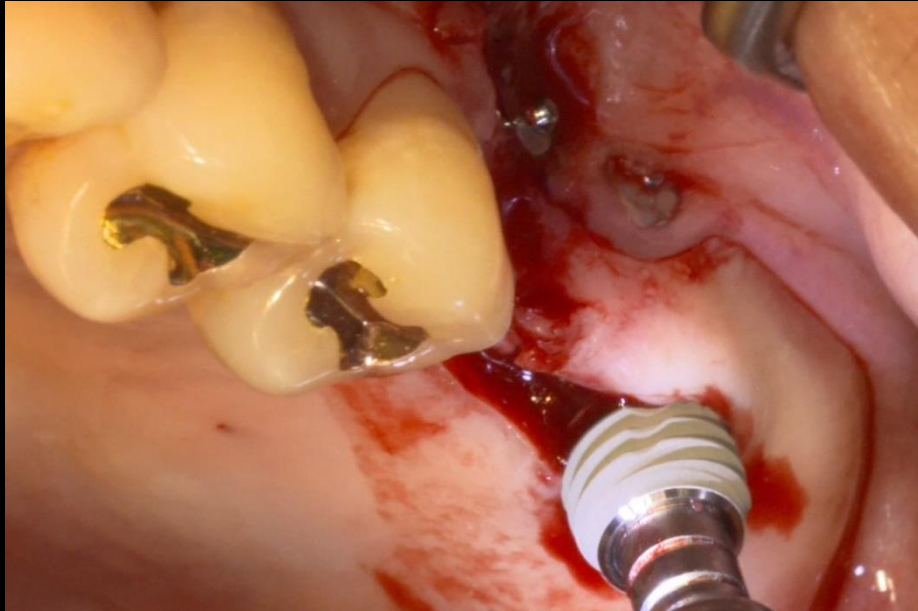
Posterior implant restoration using Digital impression process



Surgery

Similar case 1

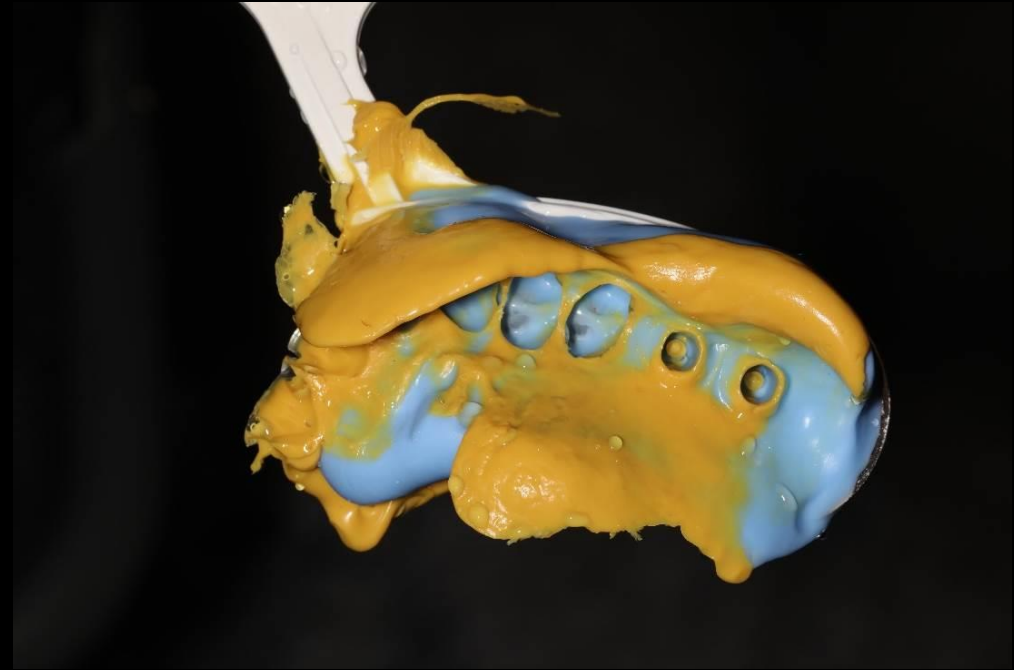
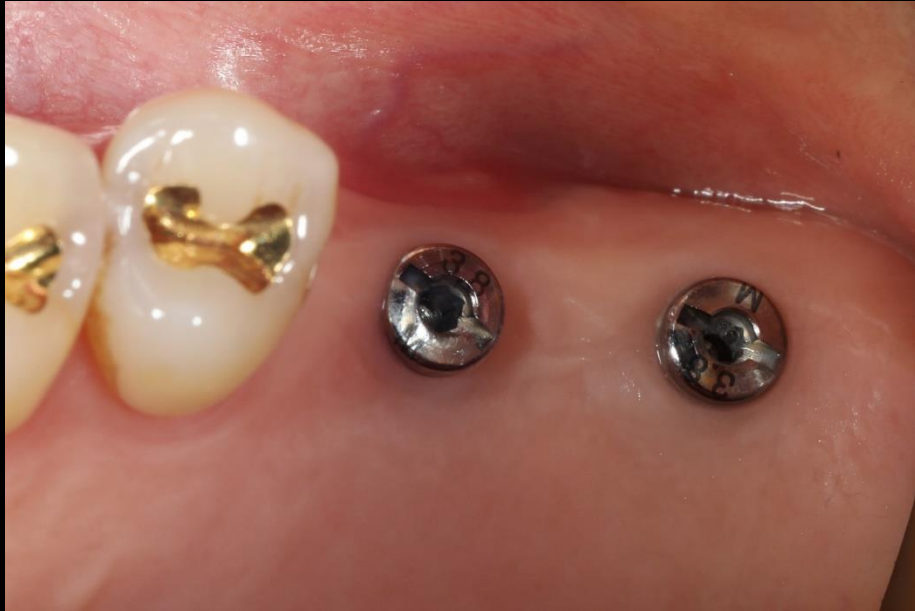Posterior implant restoration using Digital impression process



Post-op

Similar case 1

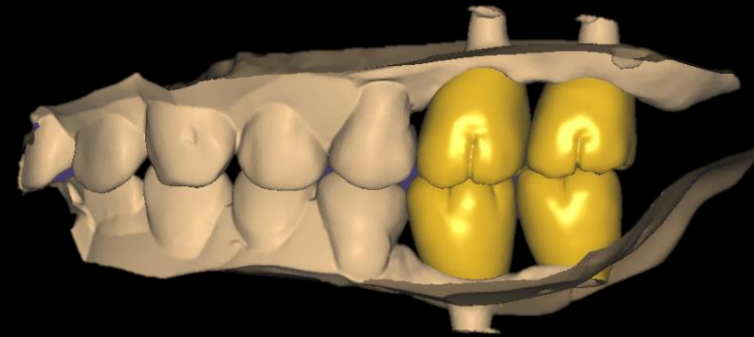
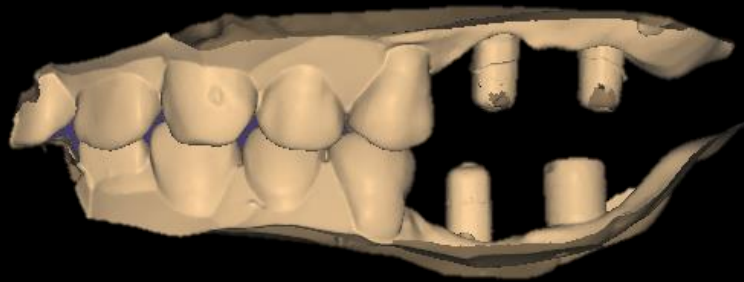
Posterior implant restoration using Digital impression process



Impression

Similar case 1

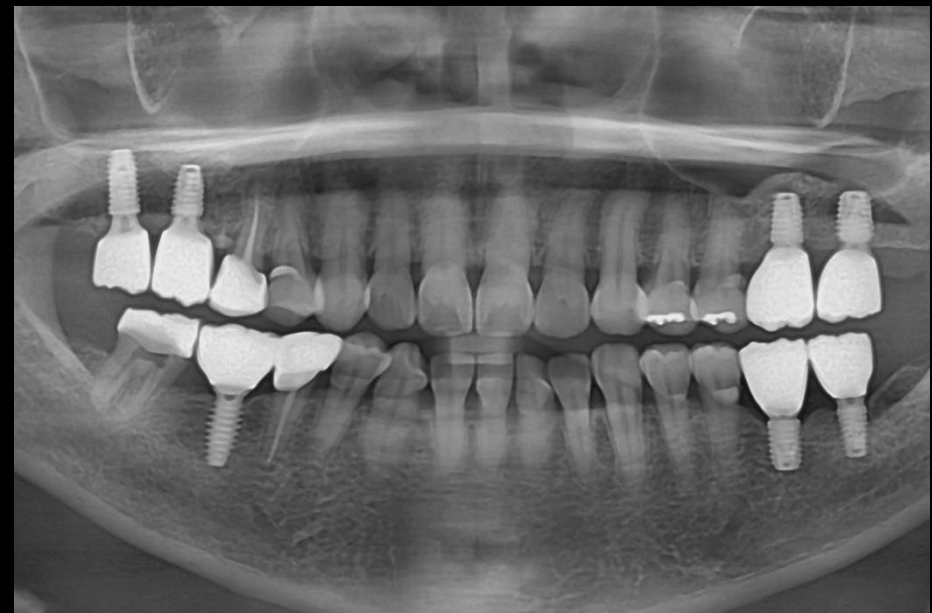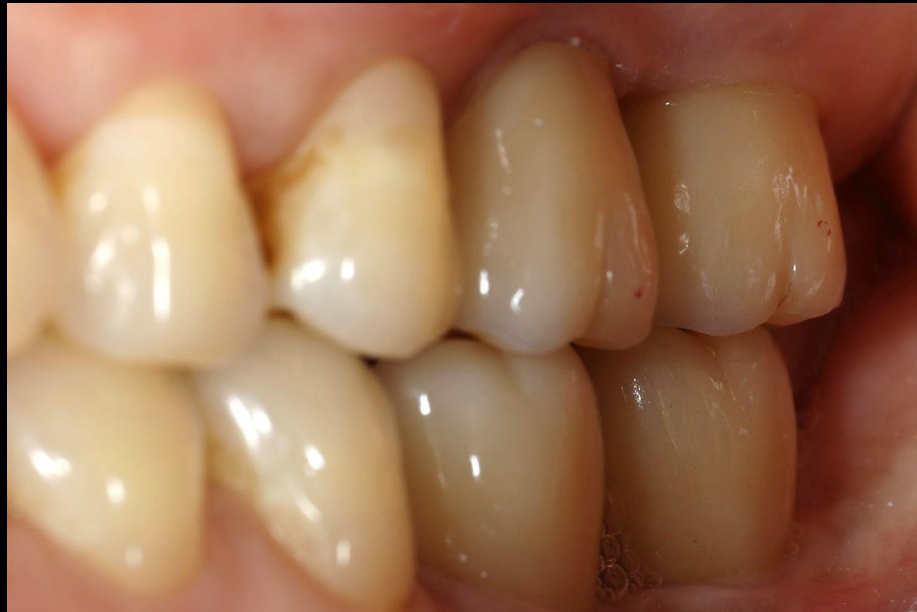Posterior implant restoration using Digital impression process



Impression Scan & CAD Design

Similar case 1

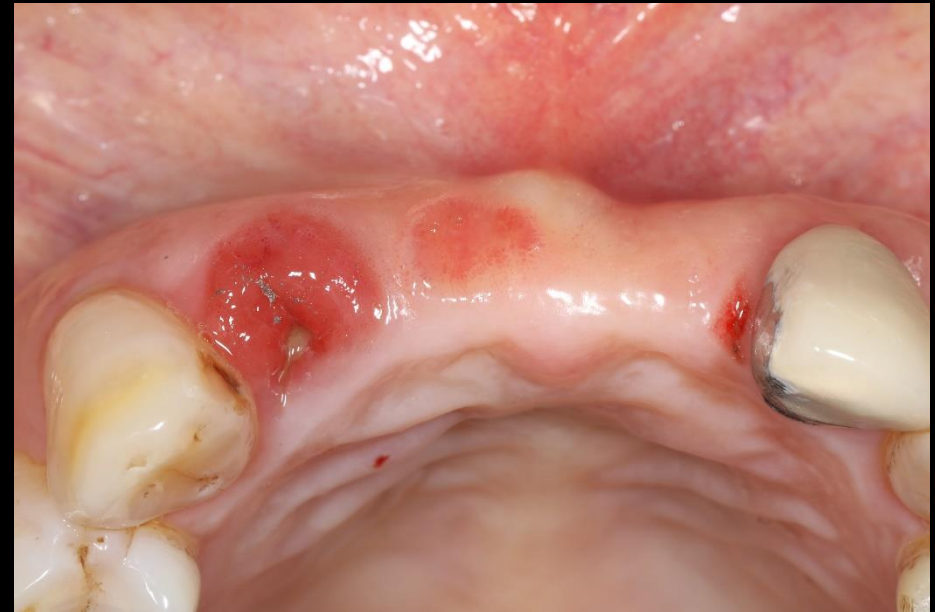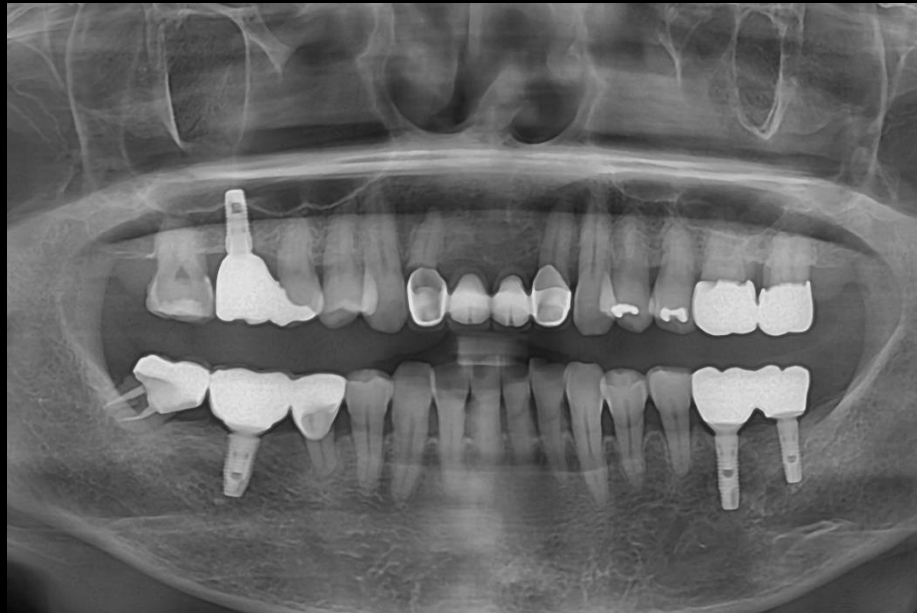Posterior implant restoration using Digital impression process



Final prosthesis

Similar case 2

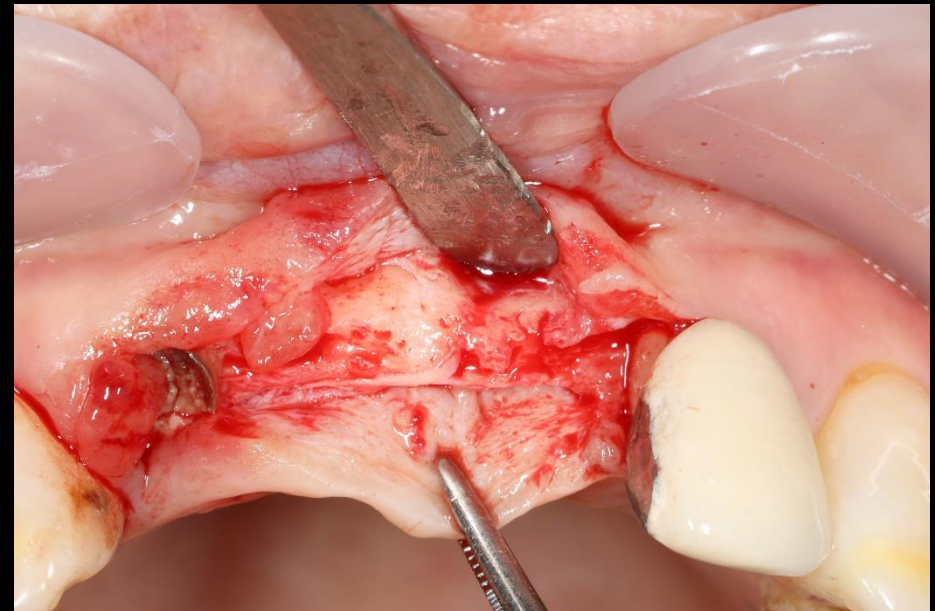
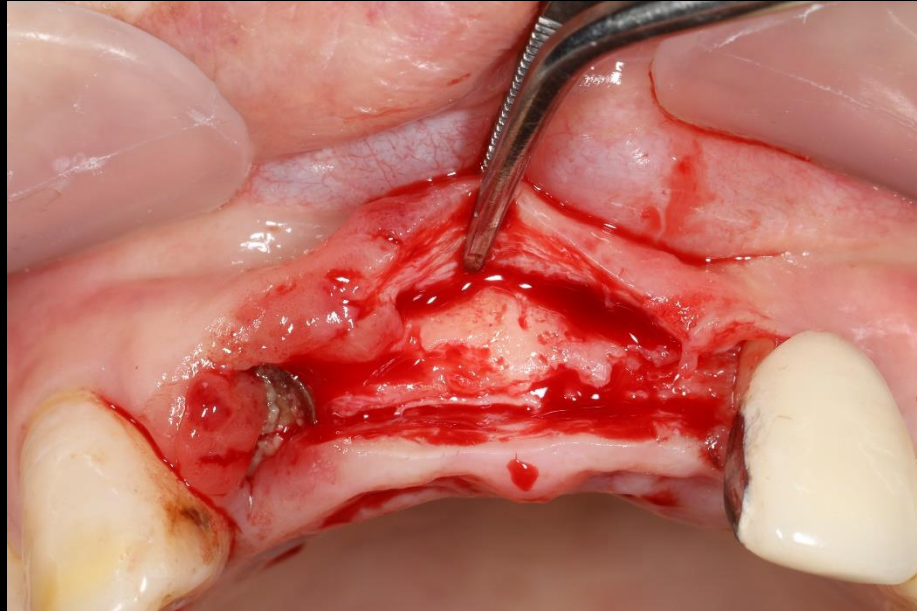
Narrow ridge implantation with Minimalism



Pre-op

Similar case 2

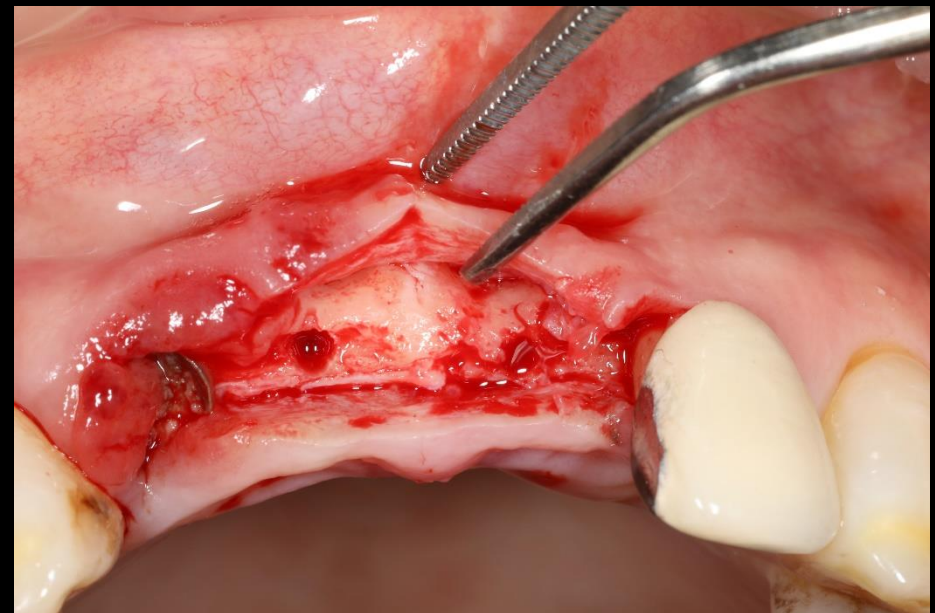
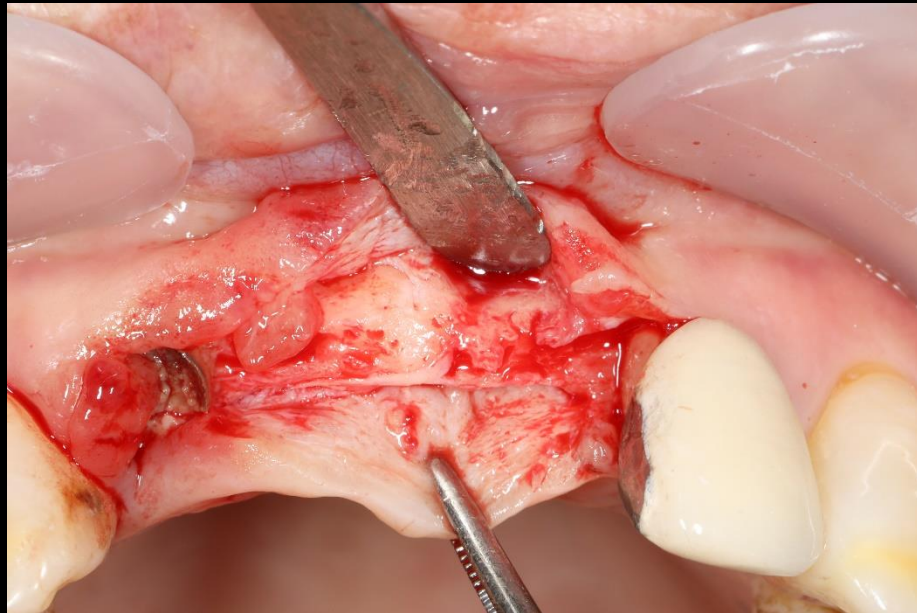
Narrow ridge implantation with Minimalism



Surgery

Similar case 2

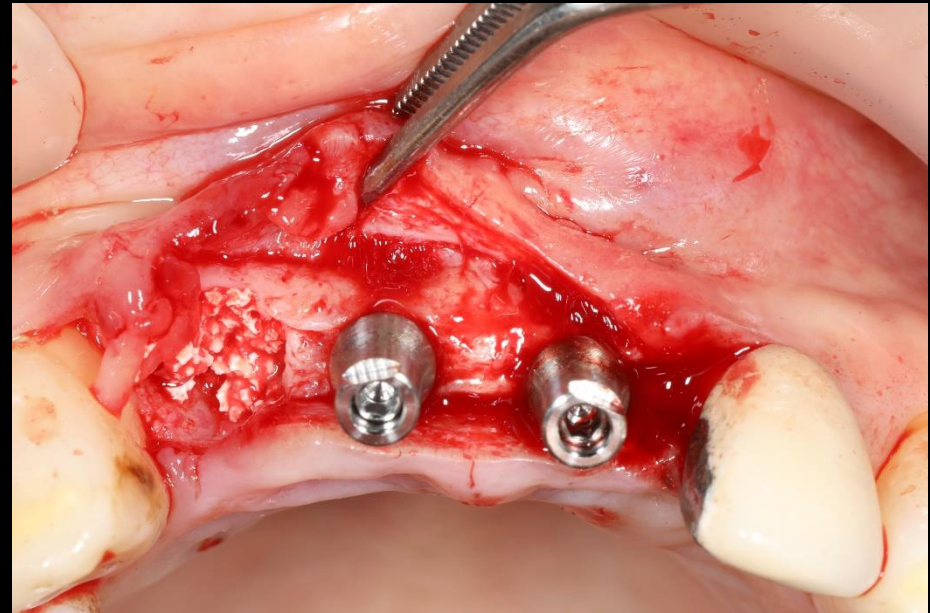
Narrow ridge implantation with Minimalism



Surgery

Similar case 2

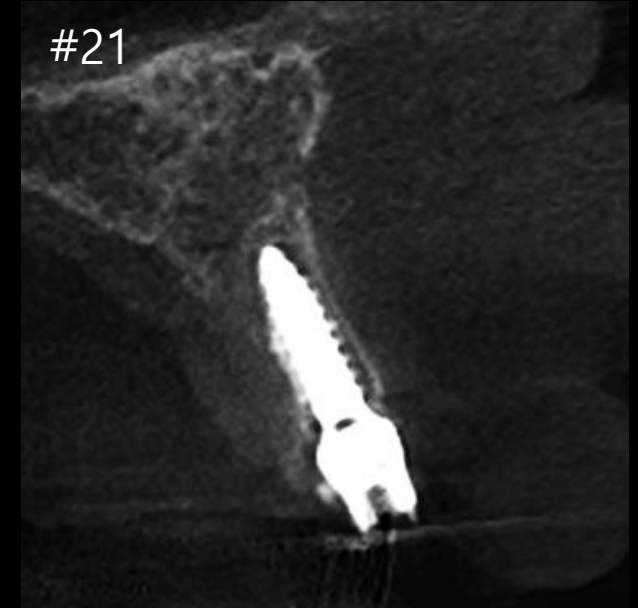
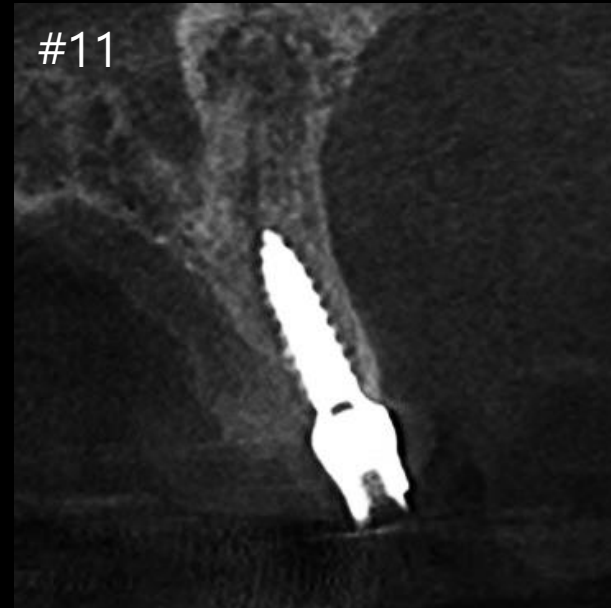
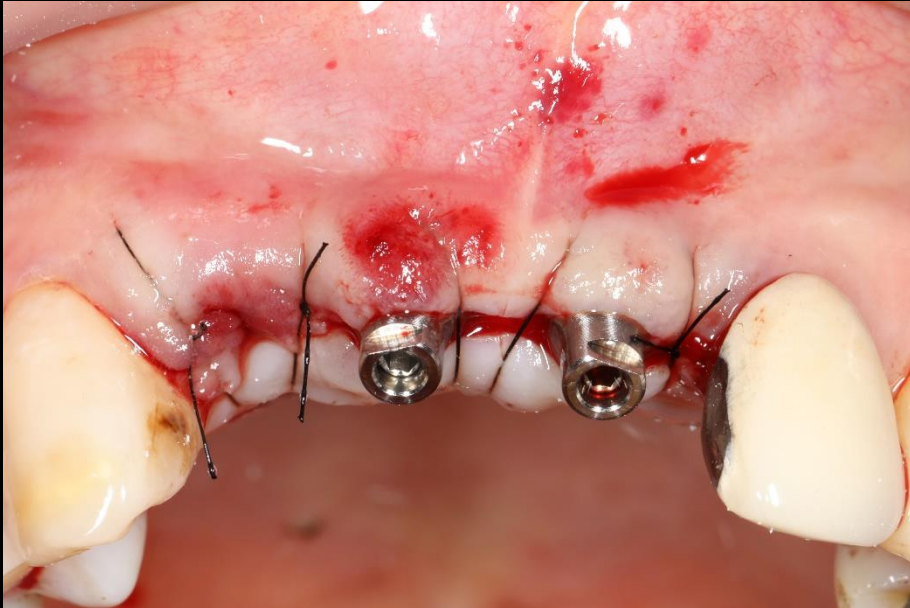Narrow ridge implantation with Minimalism



Surgery

Similar case 2

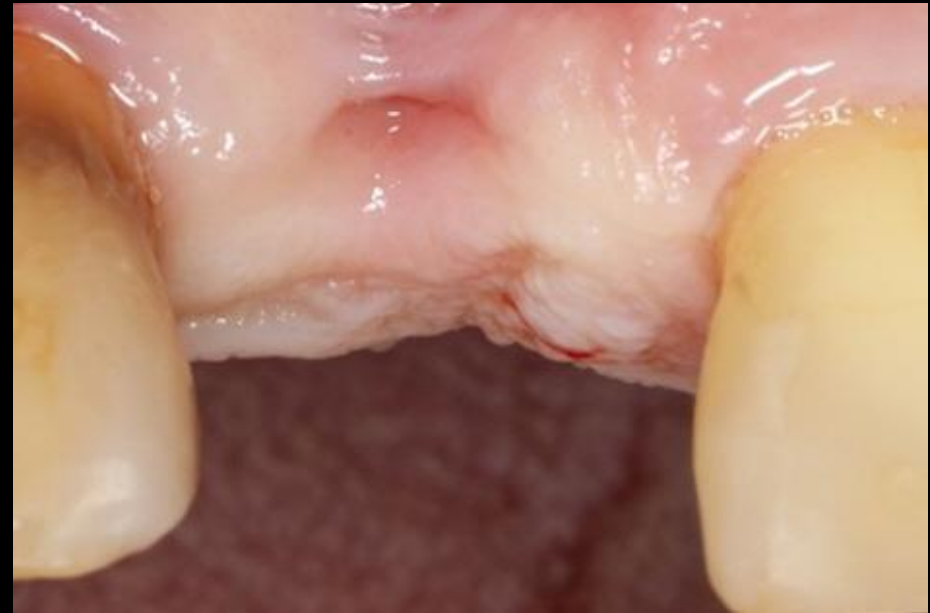
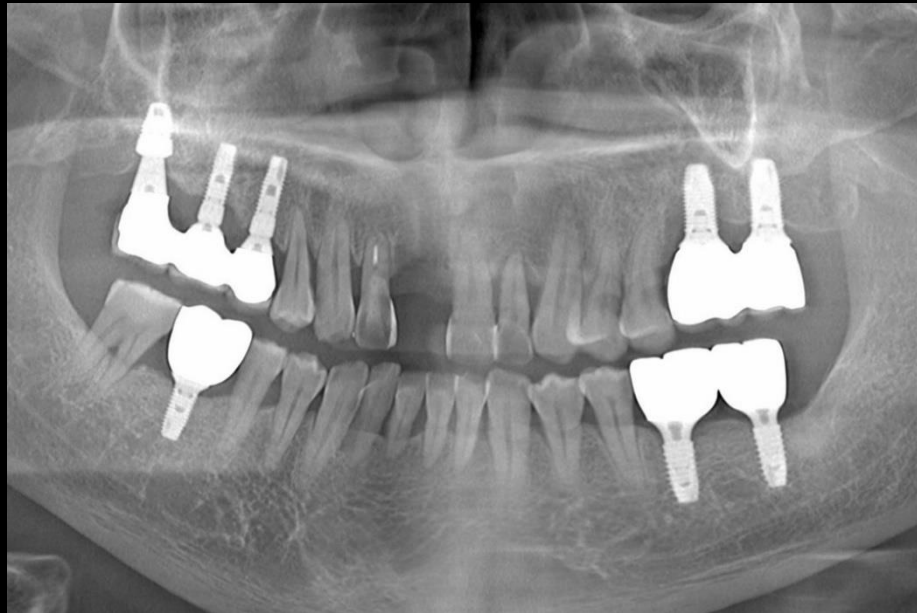
Narrow ridge implantation with Minimalism



Post-op

Similar case 3

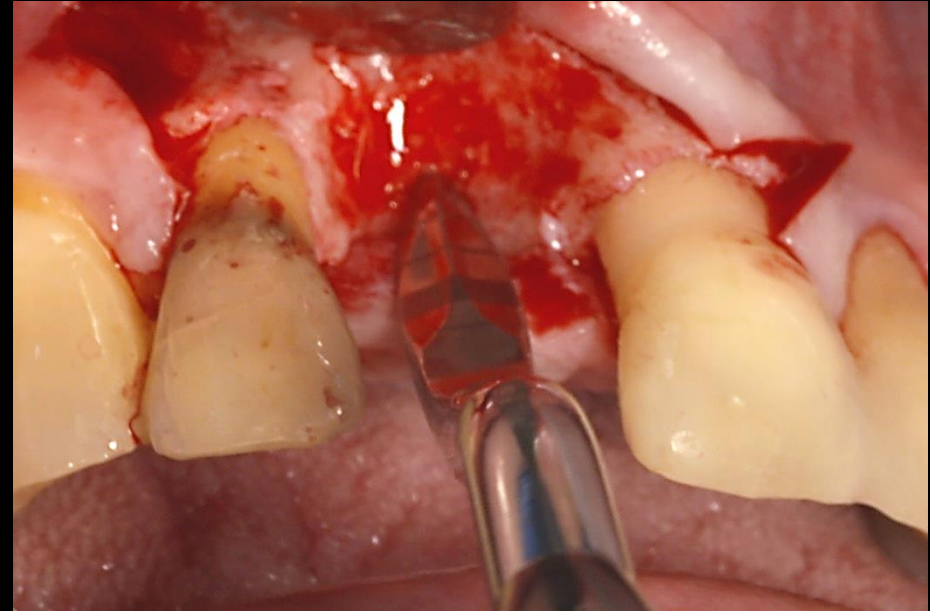
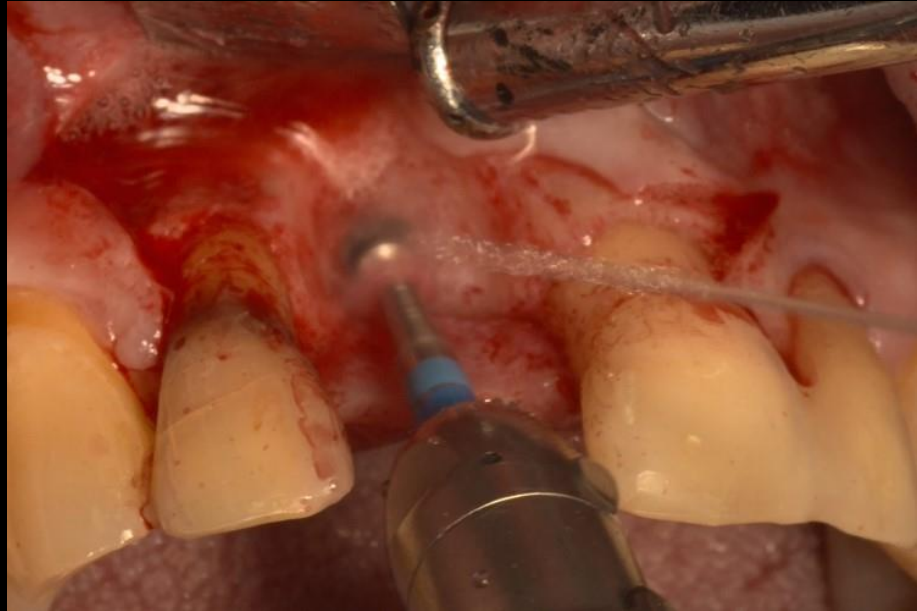
Narrow ridge implantation with Ridge expansion



Pre-op

Similar case 3

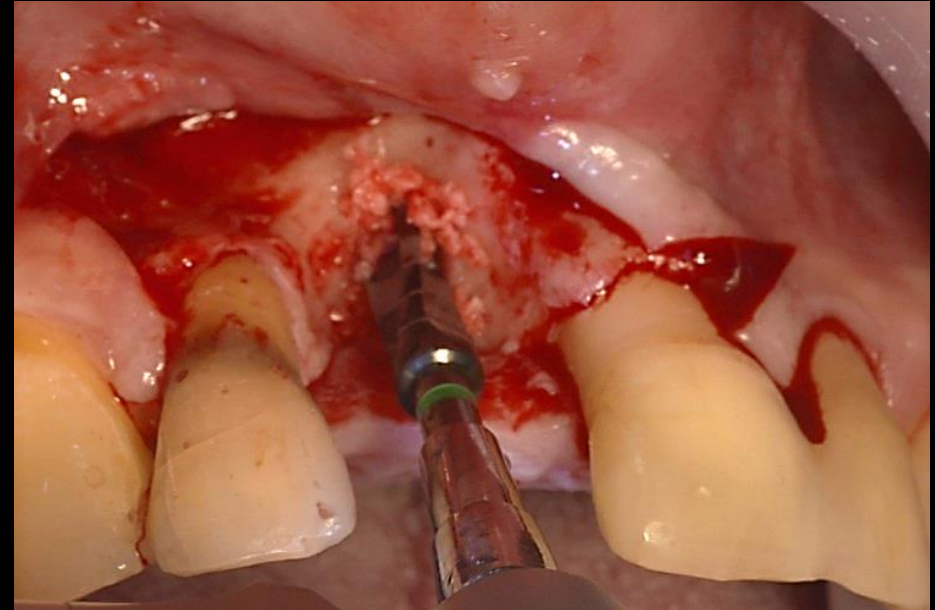
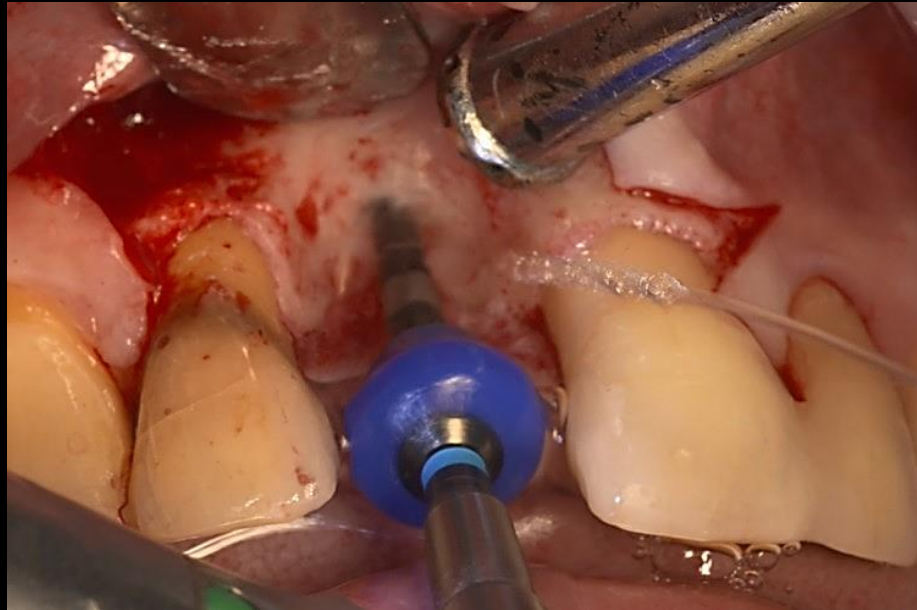
Narrow ridge implantation with Ridge expansion



Surgery

Similar case 3

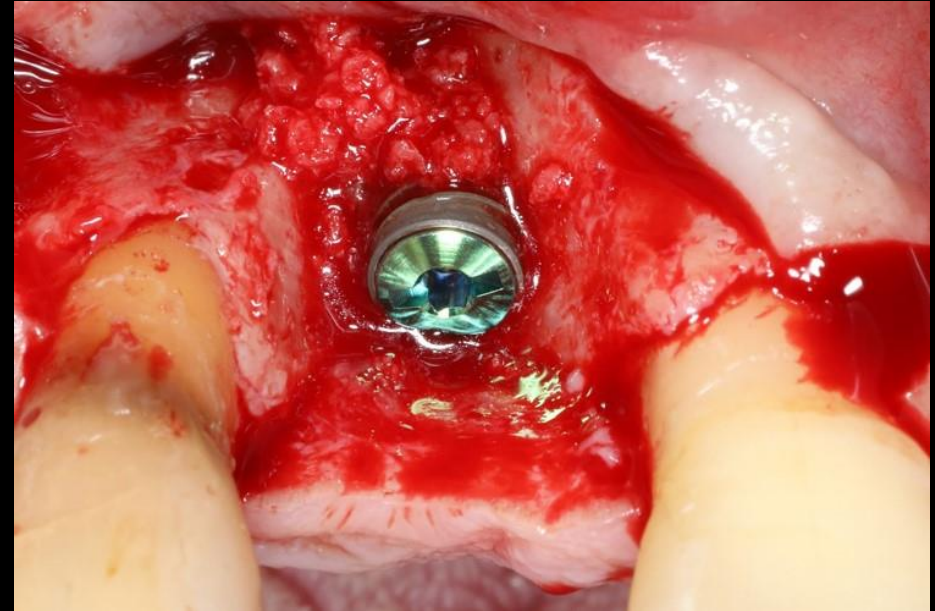
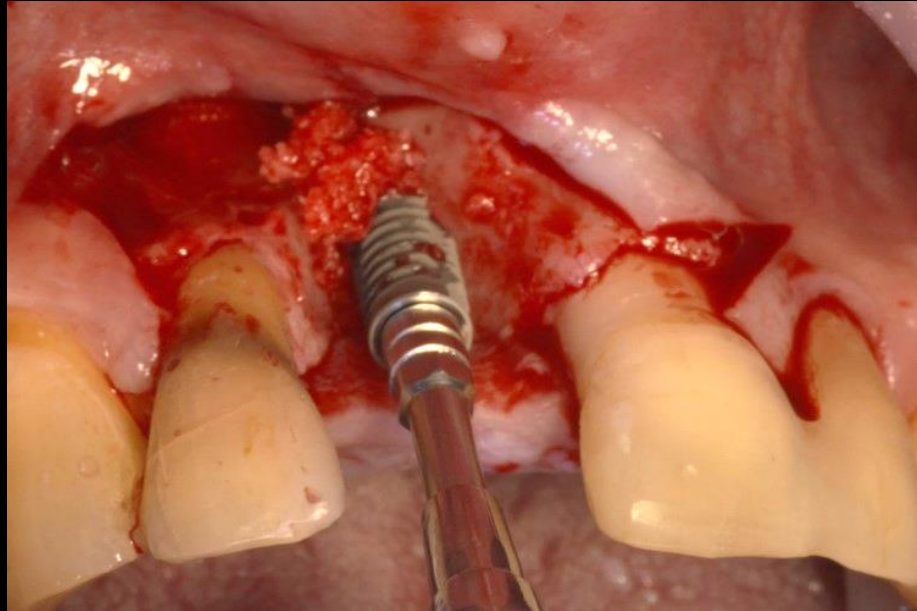
Narrow ridge implantation with Ridge expansion



Surgery

Similar case 3

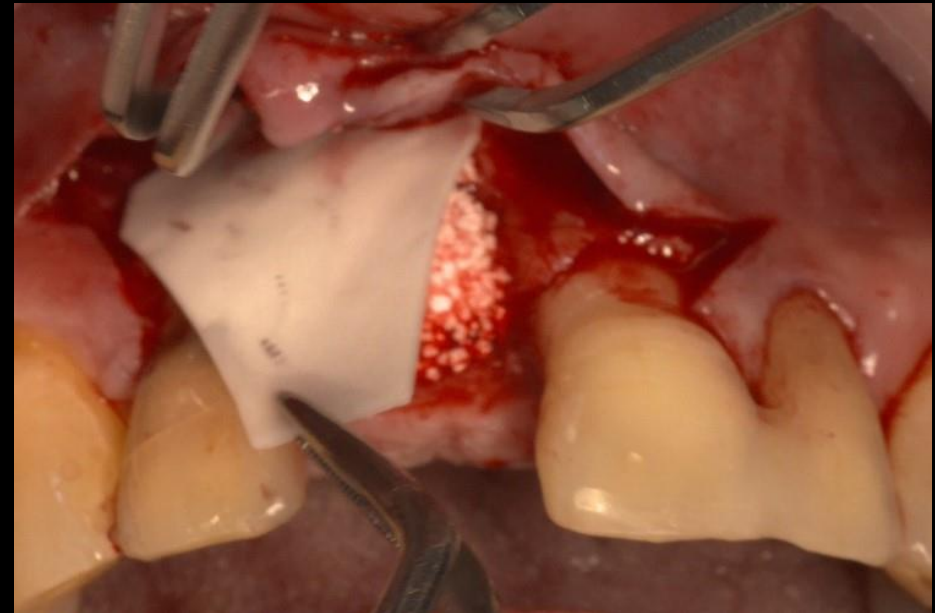
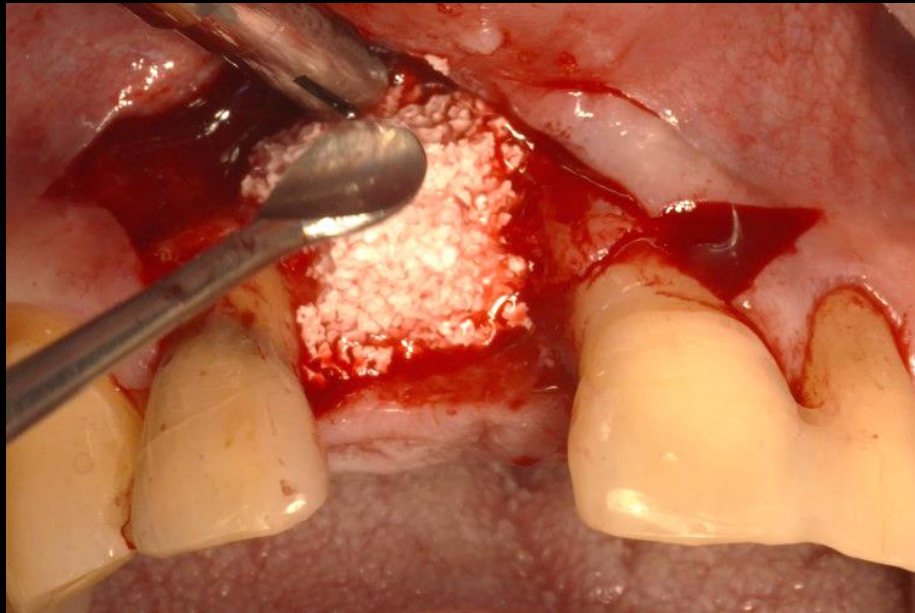
Narrow ridge implantation with Ridge expansion



Surgery

Similar case 3

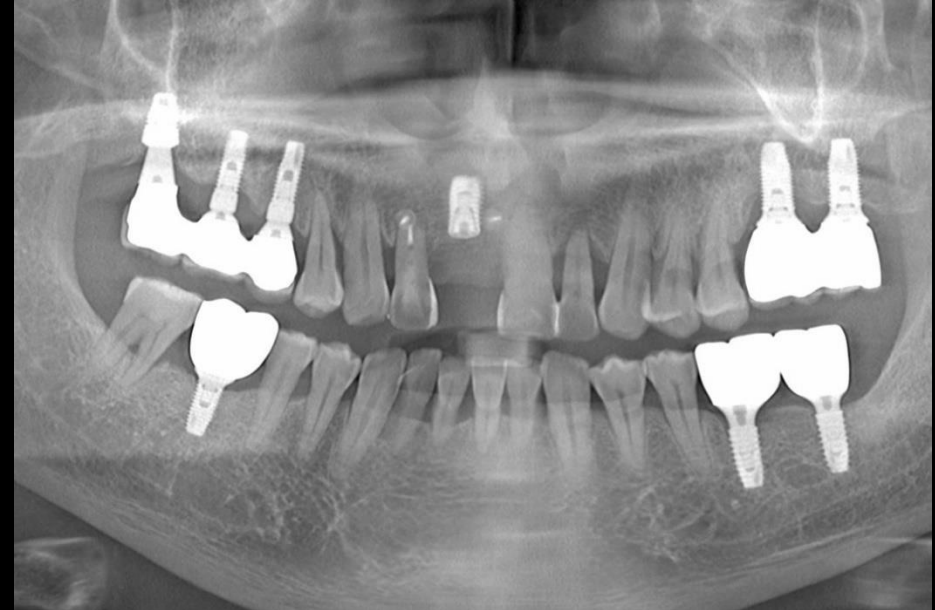
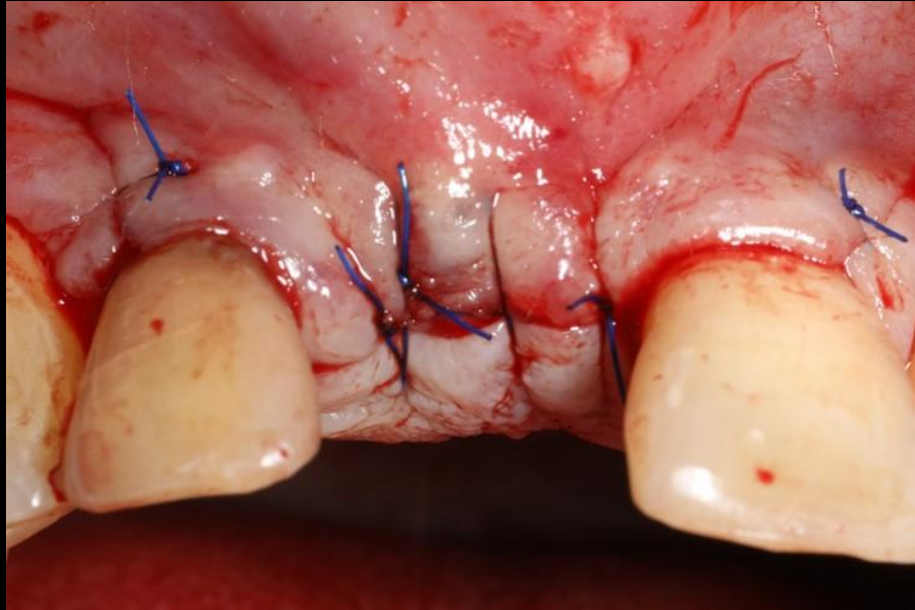
Narrow ridge implantation with Ridge expansion



Surgery

Similar case 3

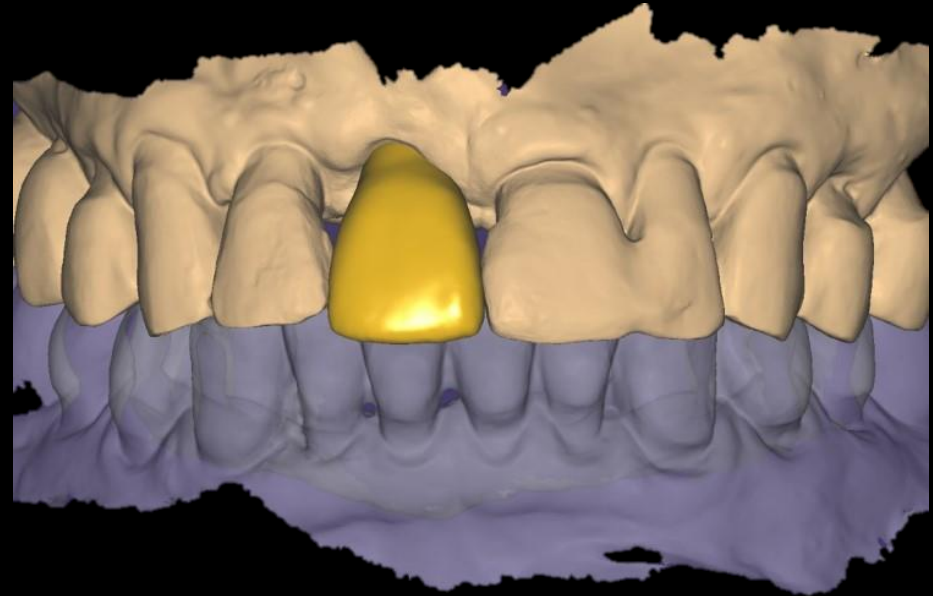
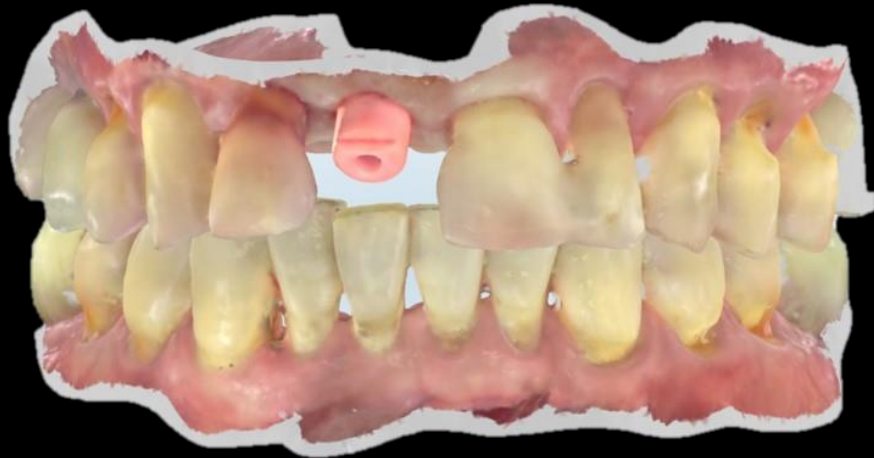Narrow ridge implantation with Ridge expansion



Post-op

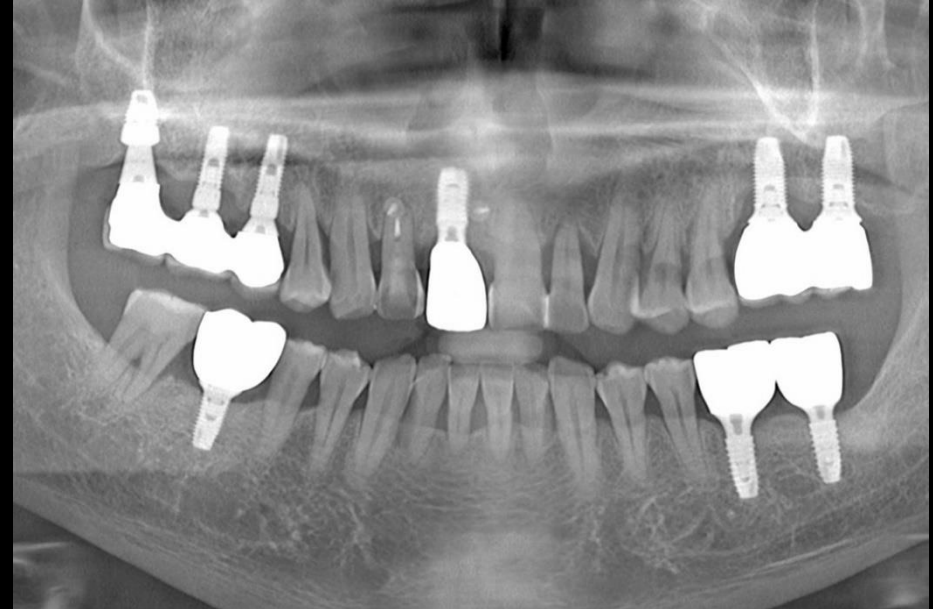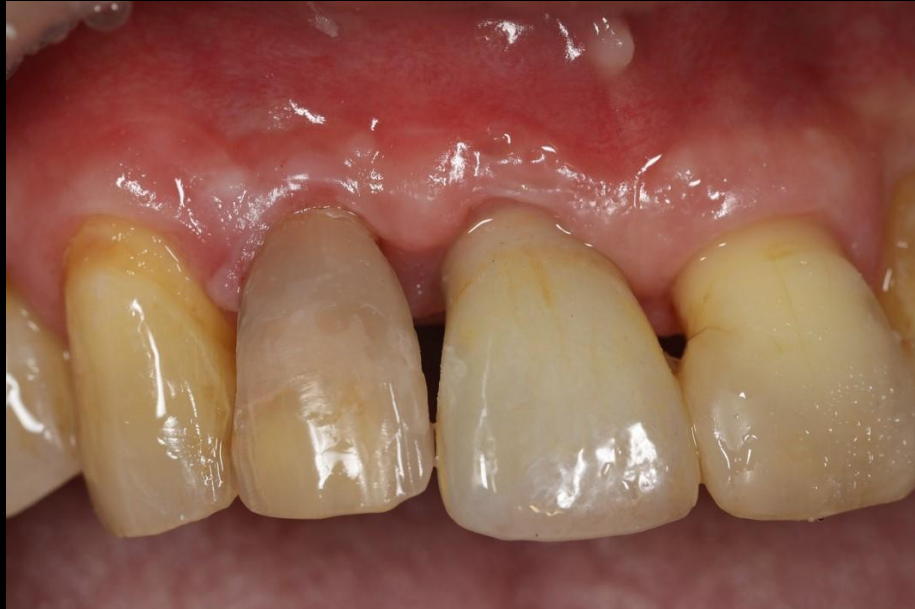Similar case 3

Narrow ridge implantation with Ridge expansion



Similar case 3

Narrow ridge implantation with Ridge expansion



Final prosthesis