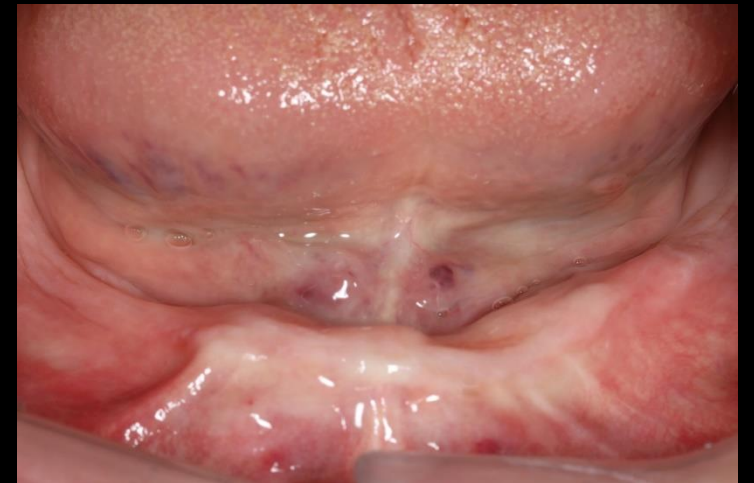
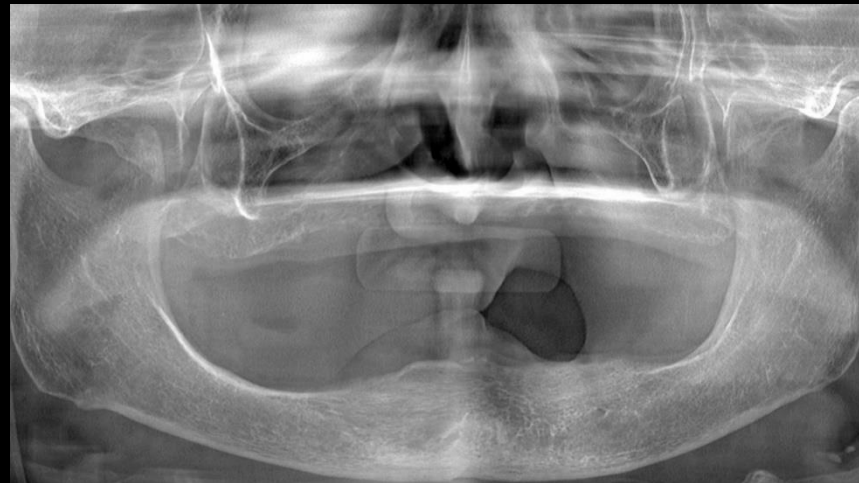
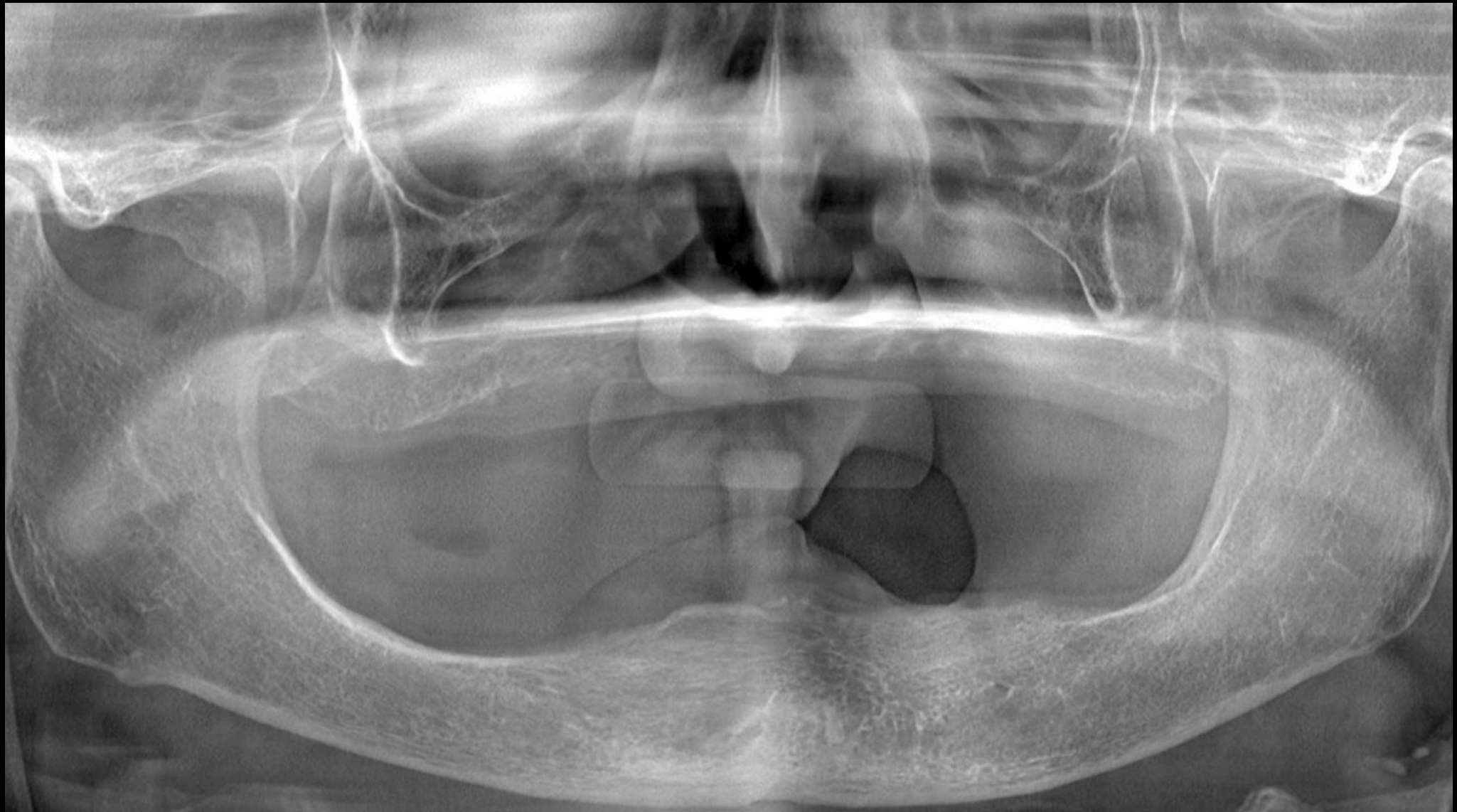


Implant supported prosthesis in extremely destructed edentulous situation

Dr. SM Chung
2021.7.2 (Fri)



Pre-op (2021-06-16)



Treatment Styles

- 1 Complete Denture
- 2 Implant Overdenture
- 3 Fixed hybrid Prosthesis
- 4 Fixed prosthesis with Zirconia

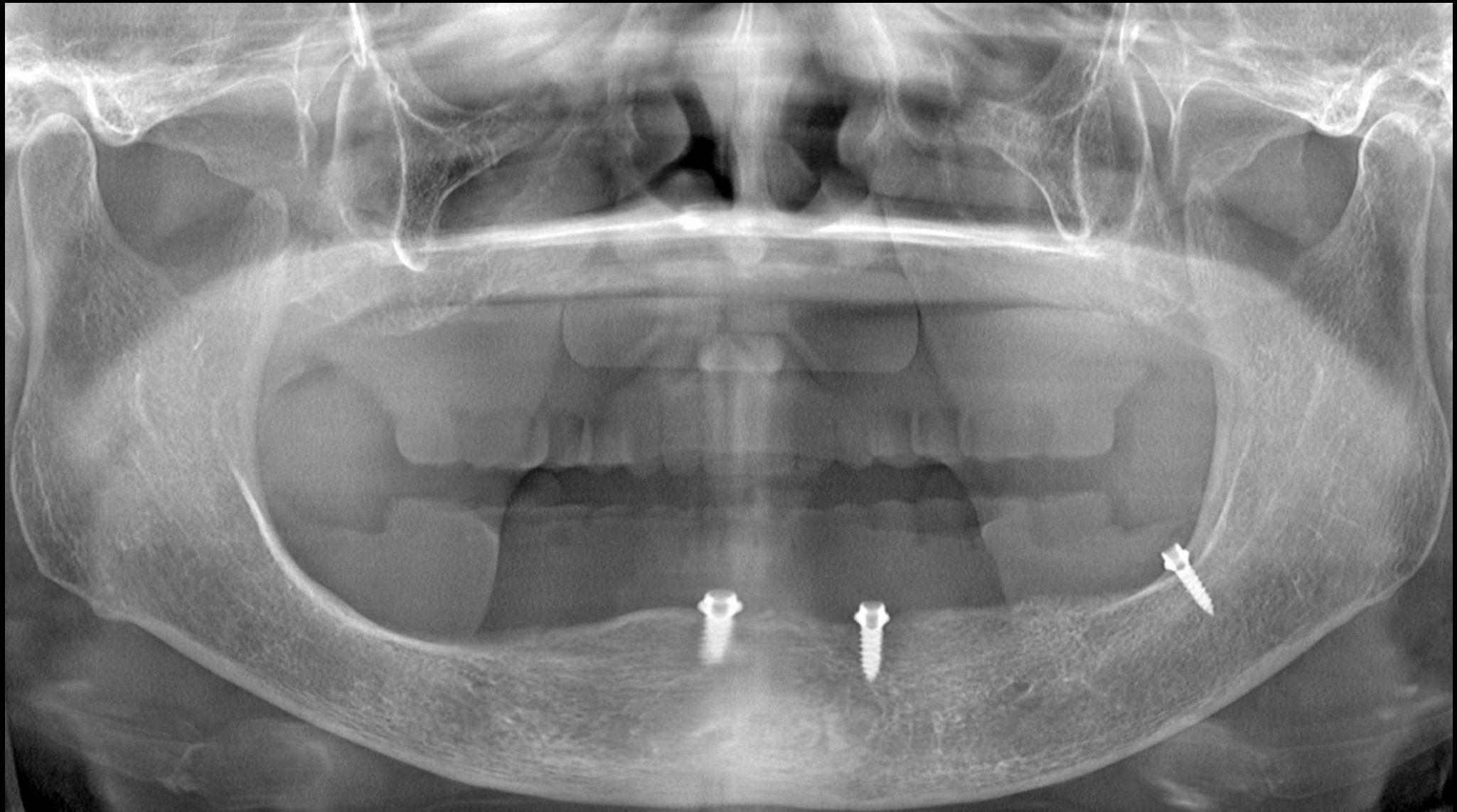
In a 2,3

There is extremely highly resorbed situation

2,3 are good for function

But 3,4 are better in psychology.

Surgery (2021-06-16)



Implant position

- 1 Posterior tilted Implant

- 2 Anterior implant between lateral incisor and canine area

In this situation,

We will place in these areas.

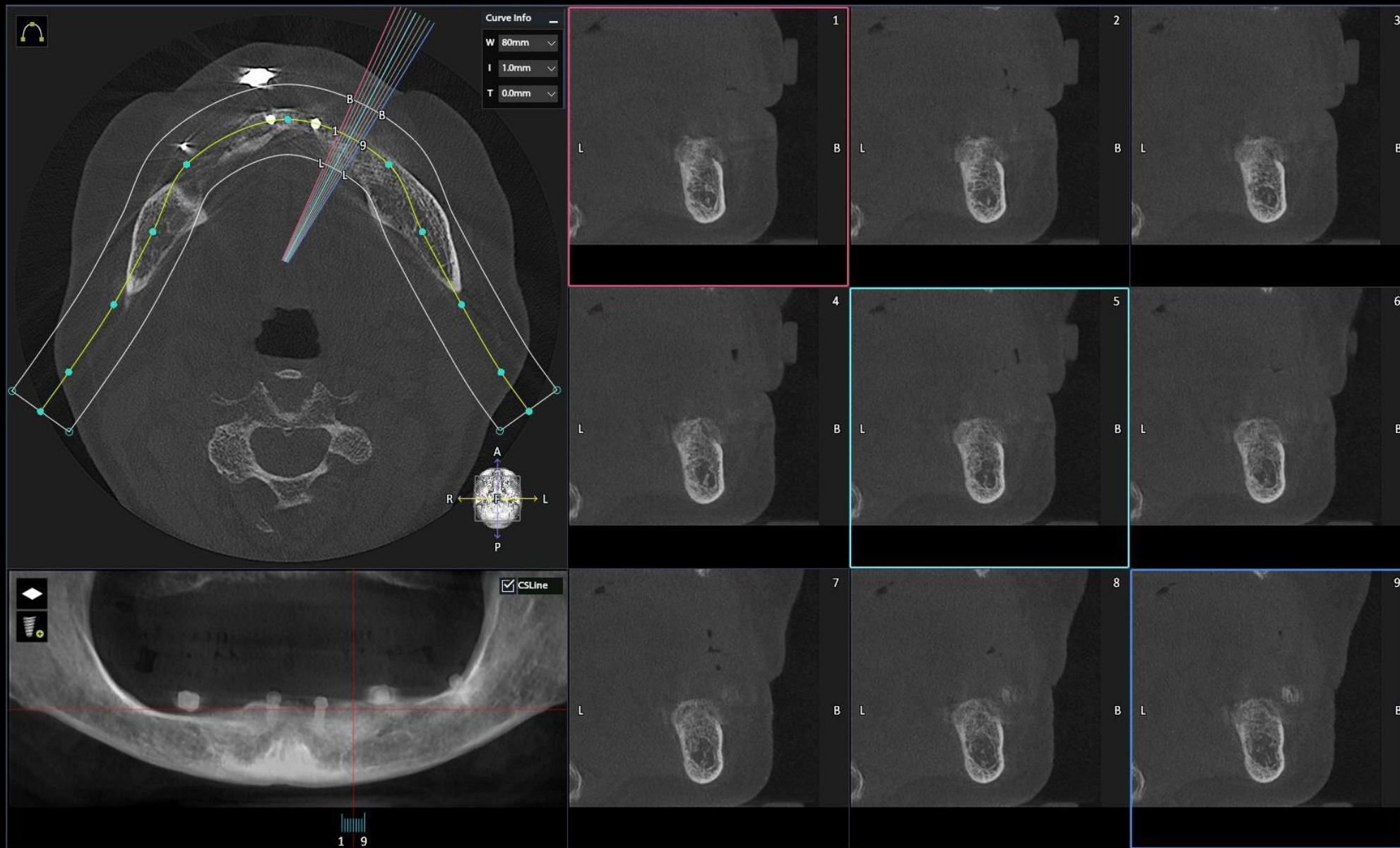
#44i

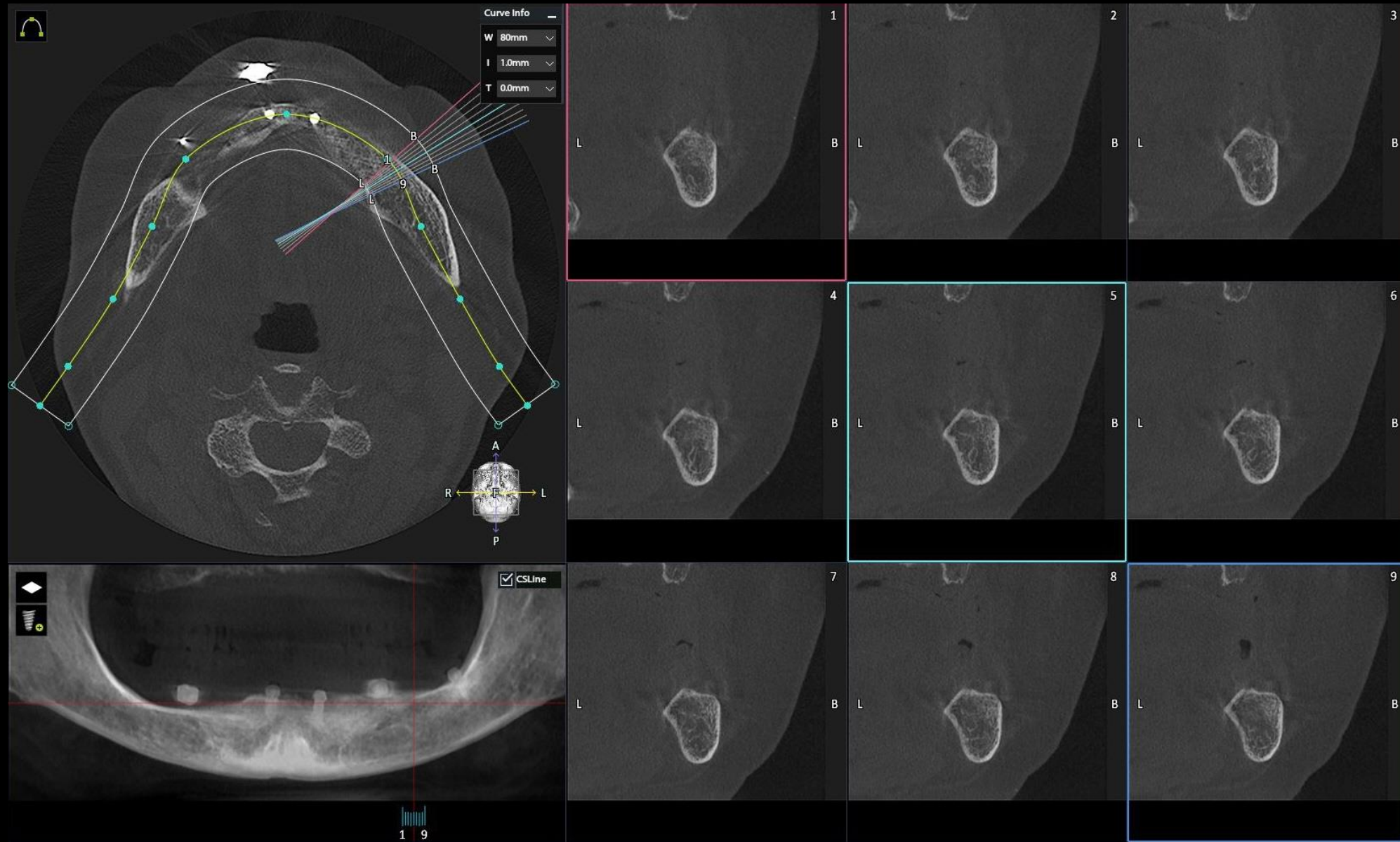
#43i

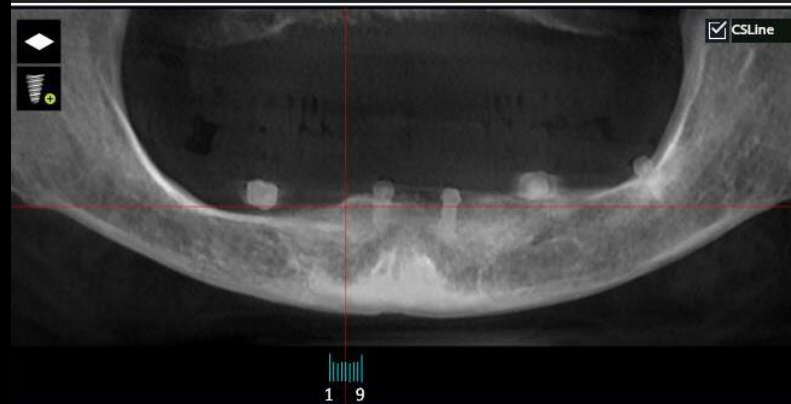
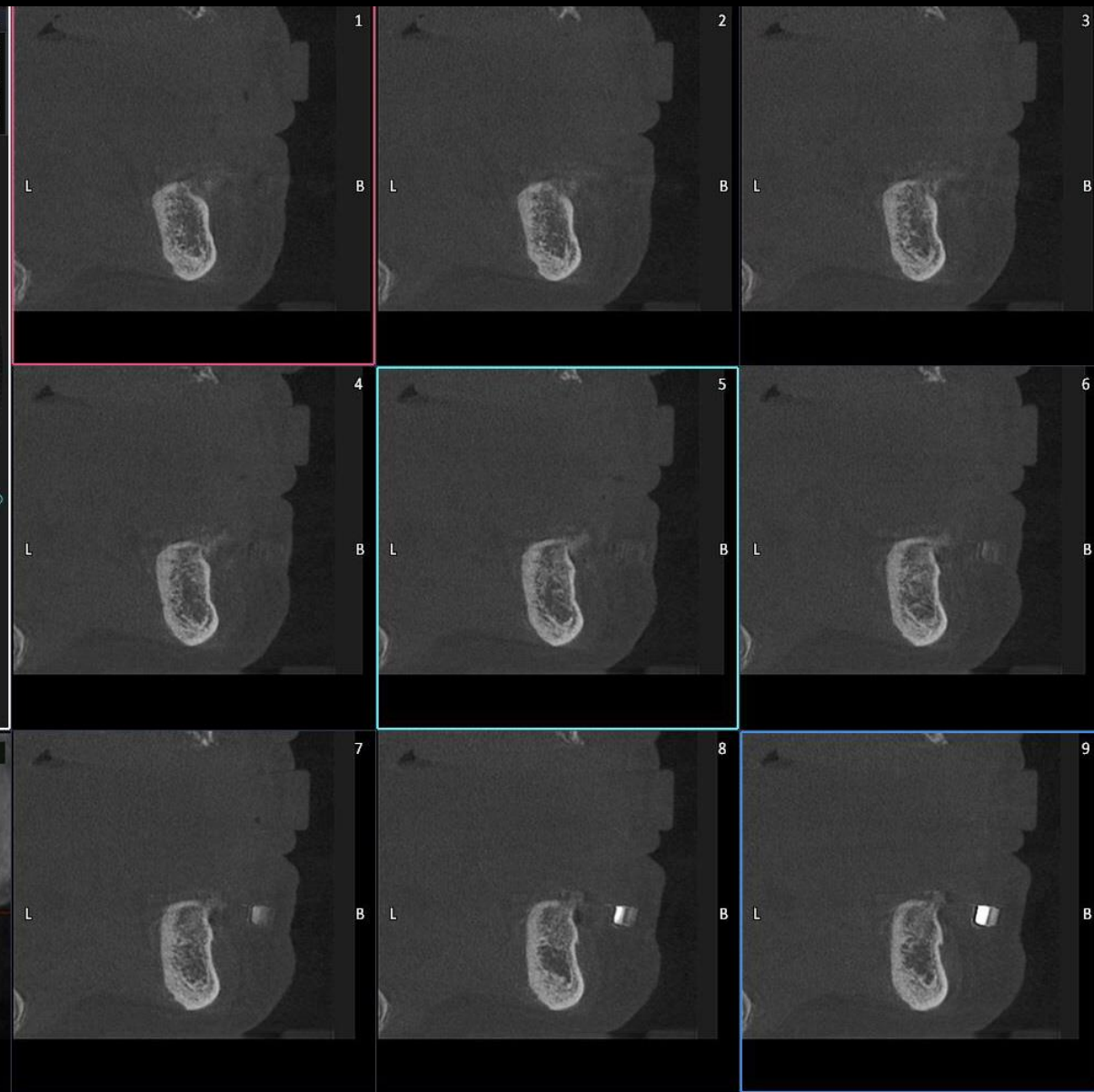
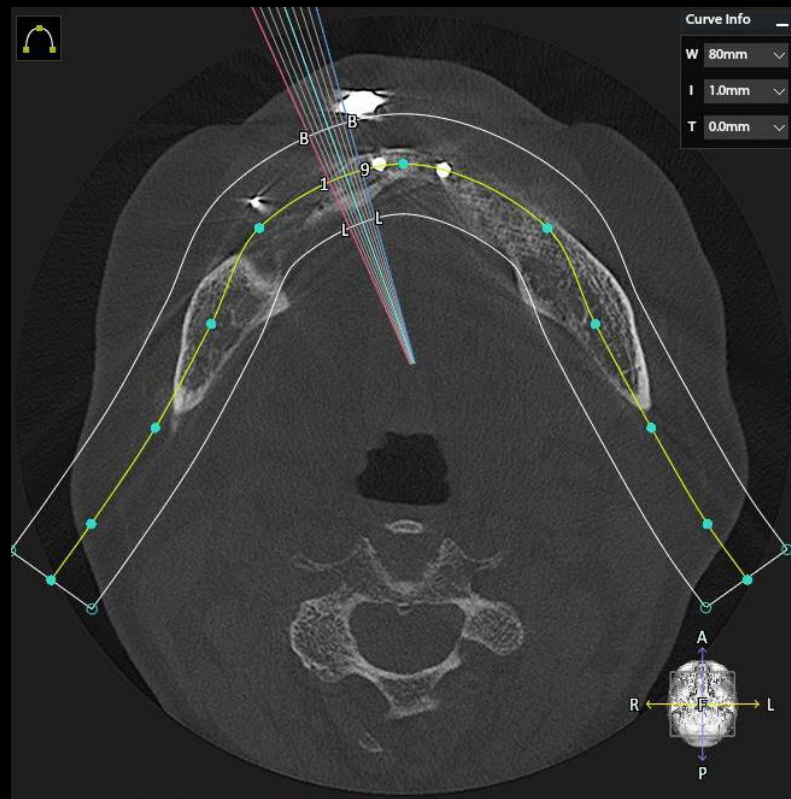
#34i

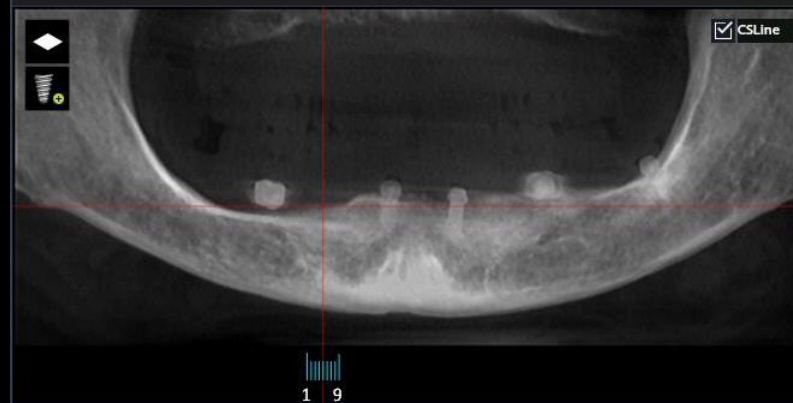
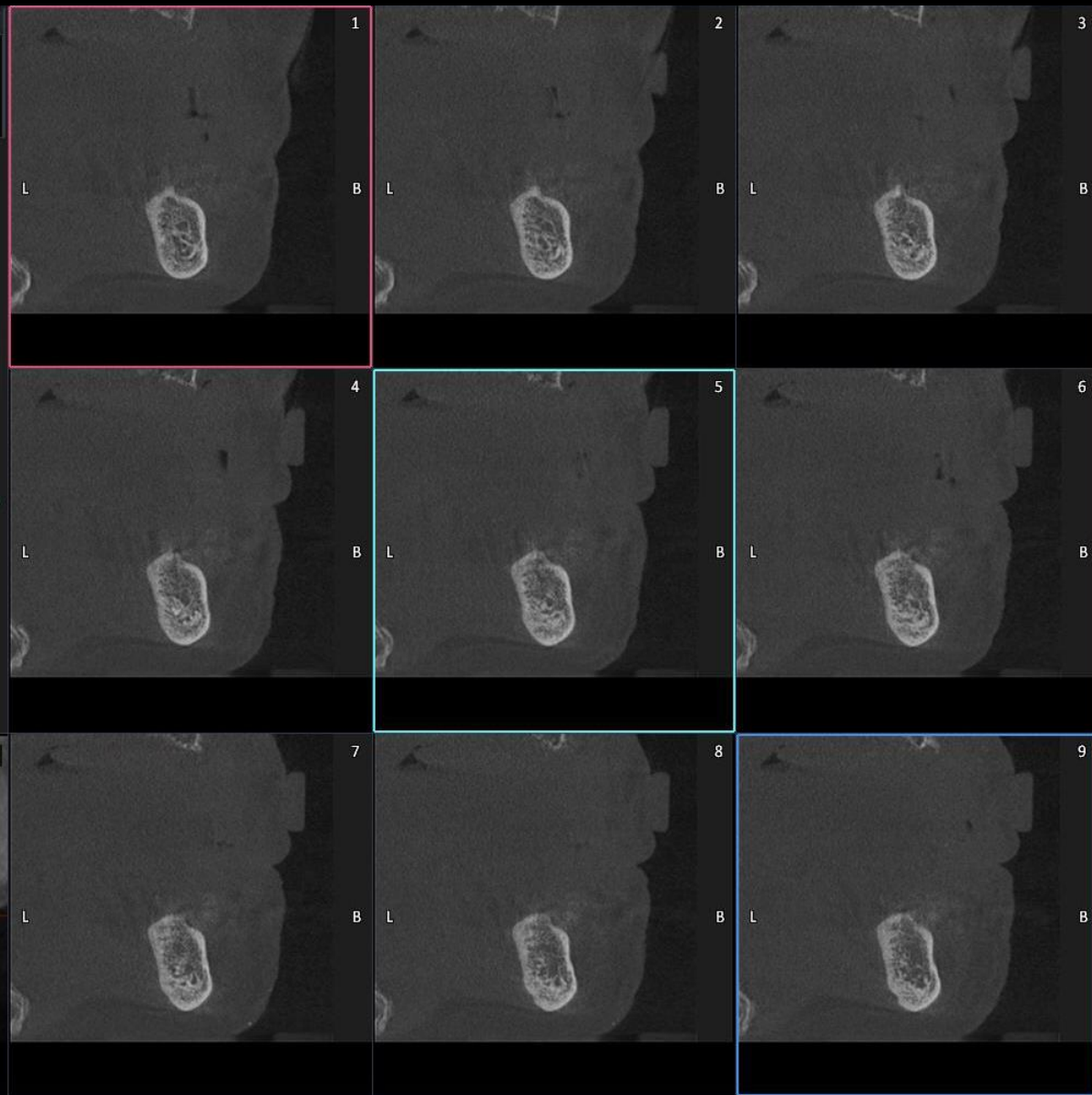
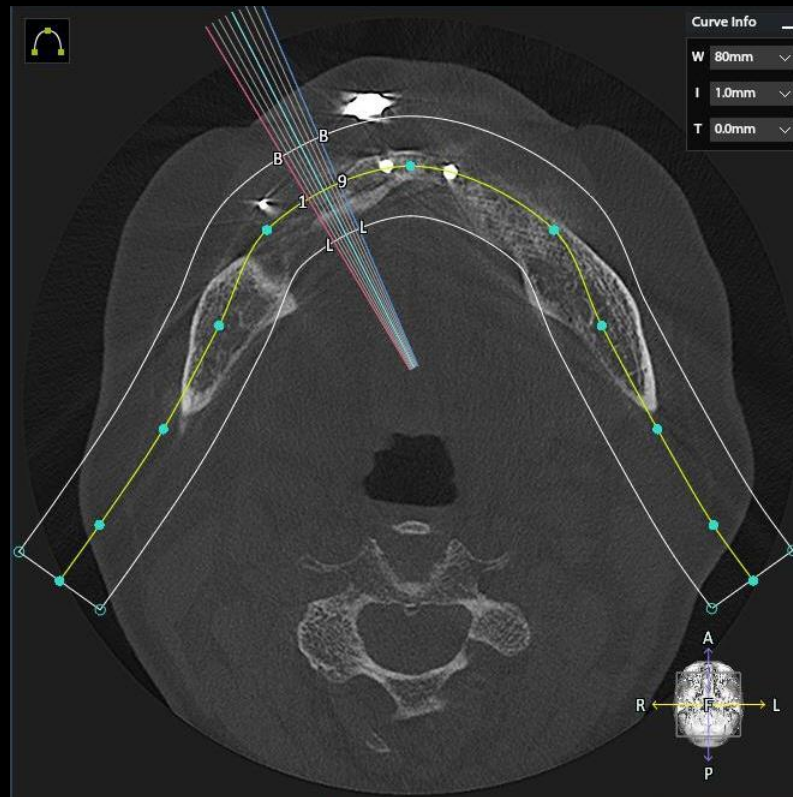
#36i

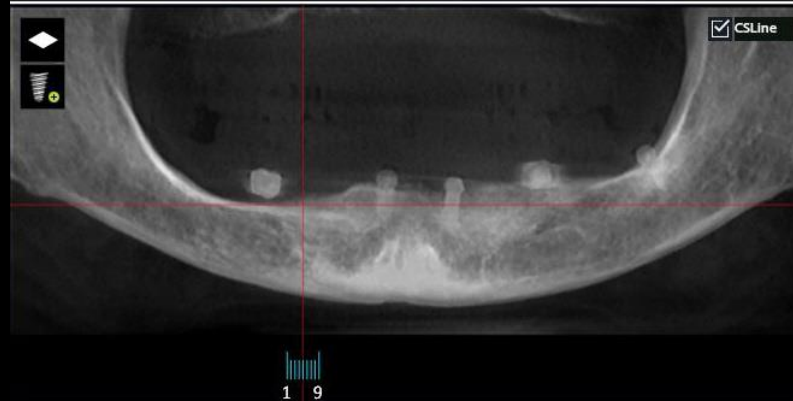
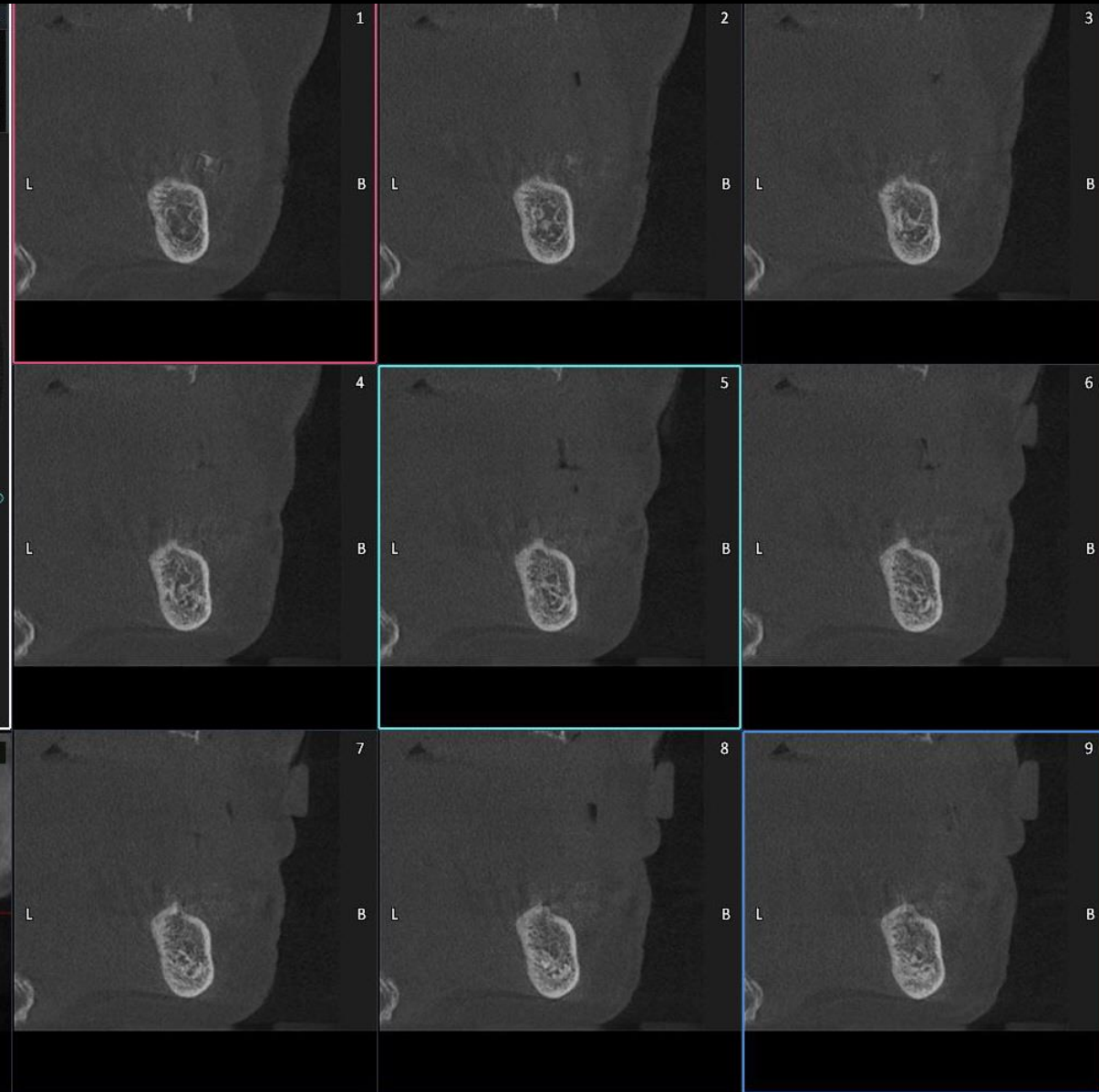
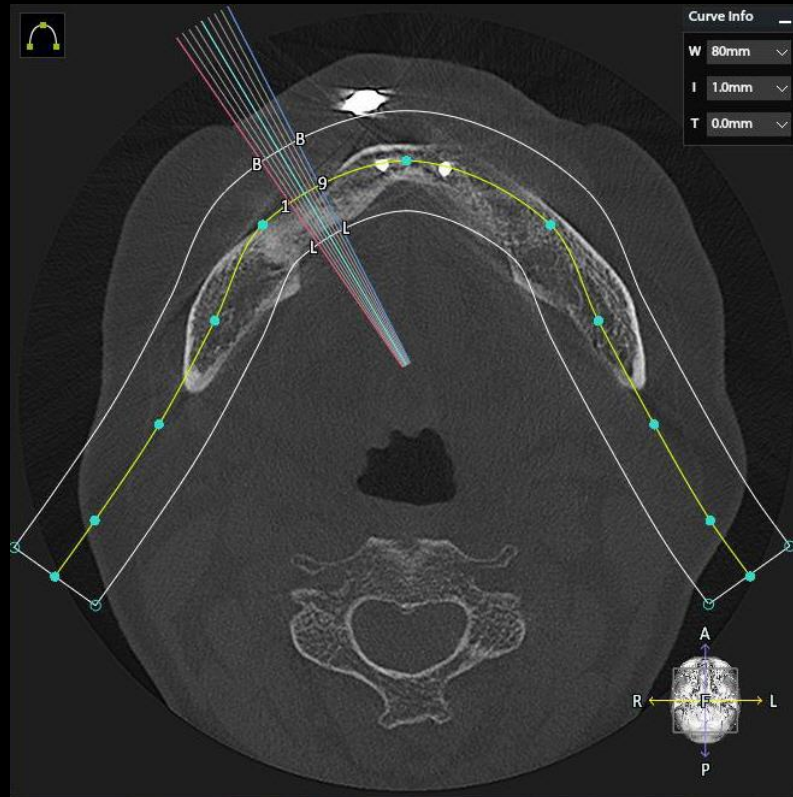
Tilted implant



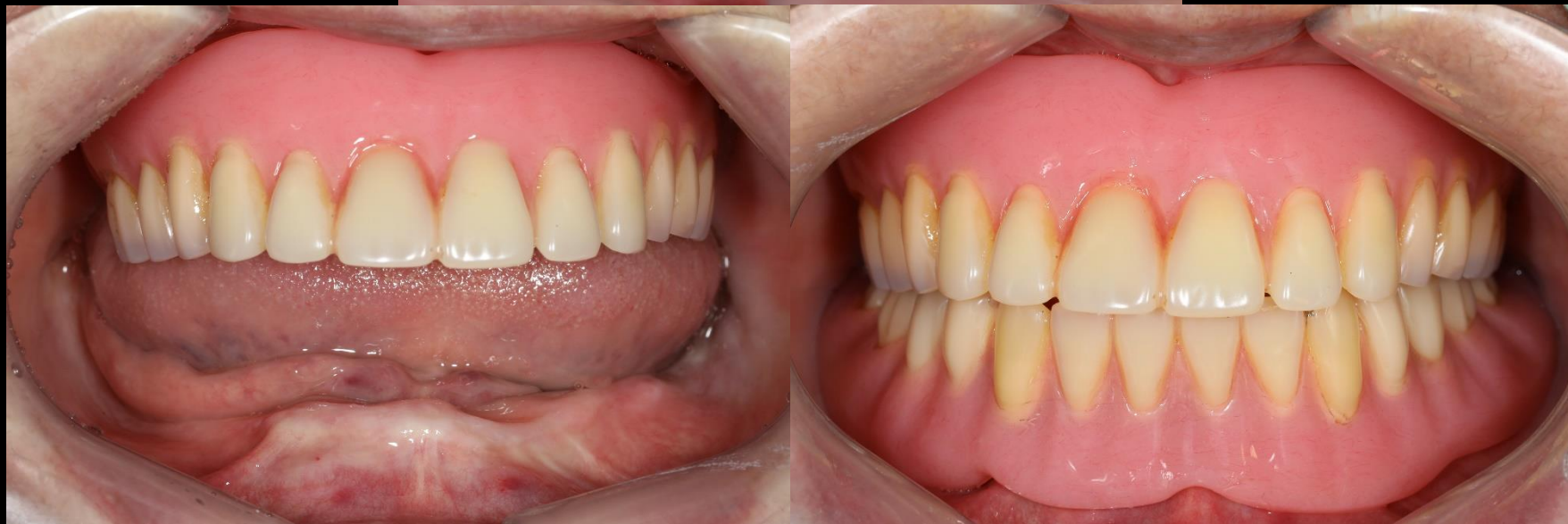
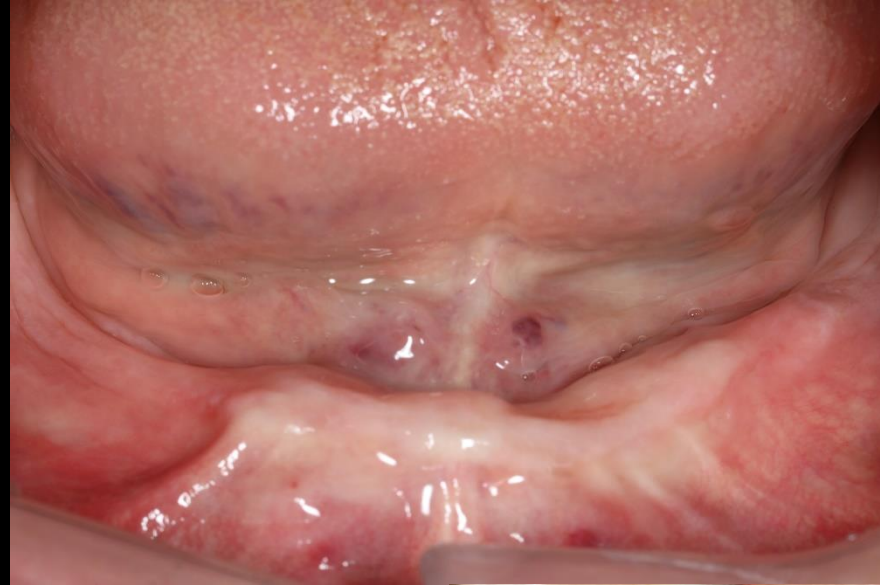


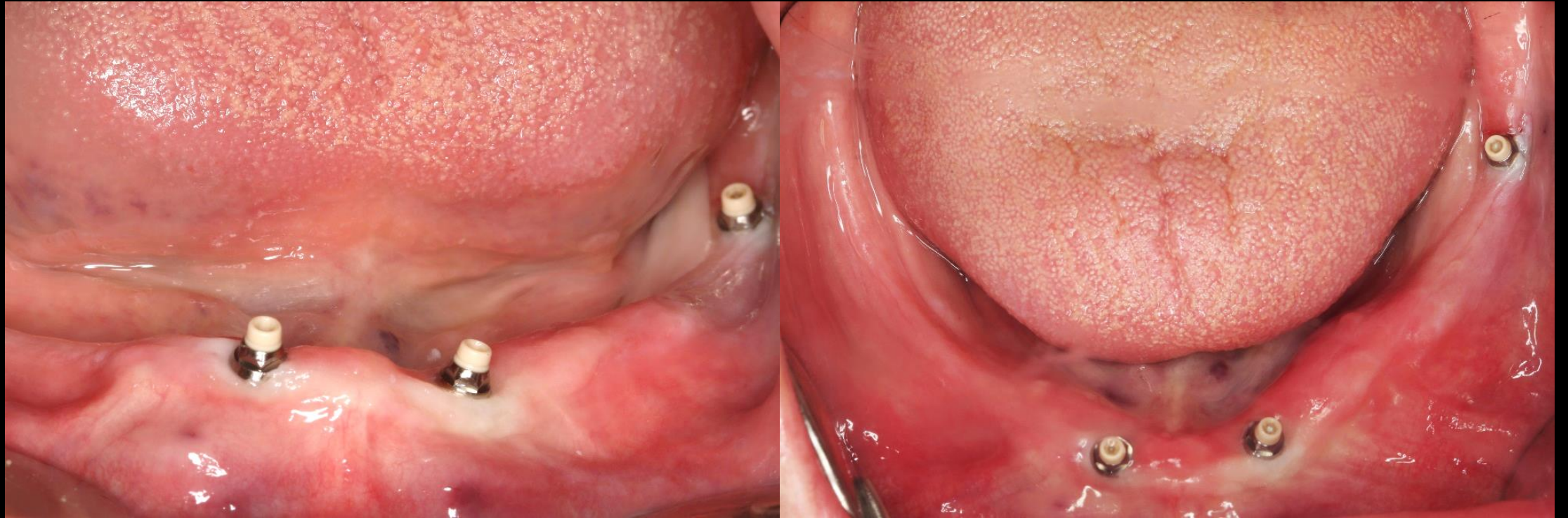




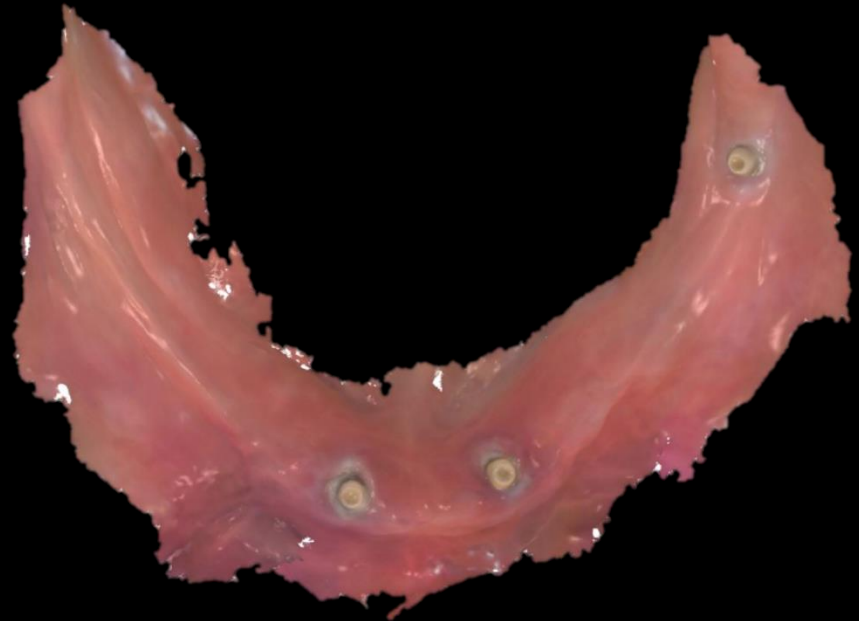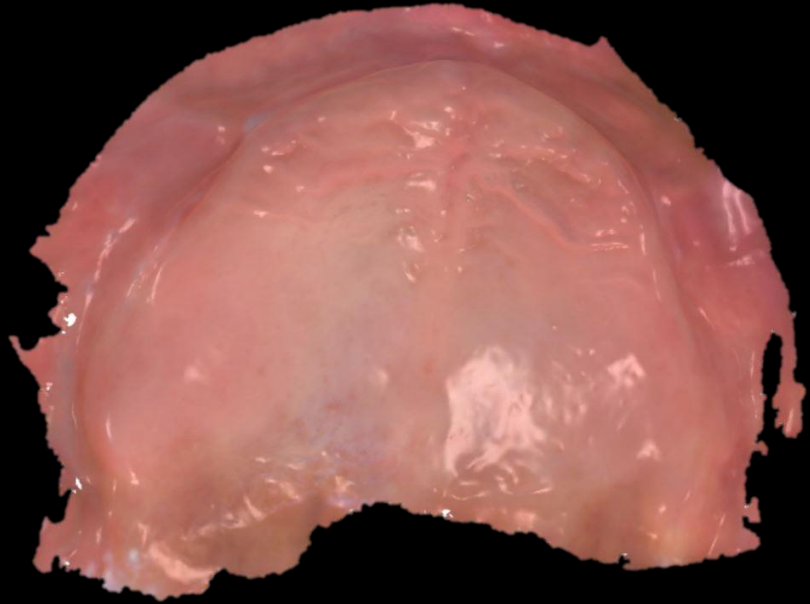
Pre-op (2021-06-16)



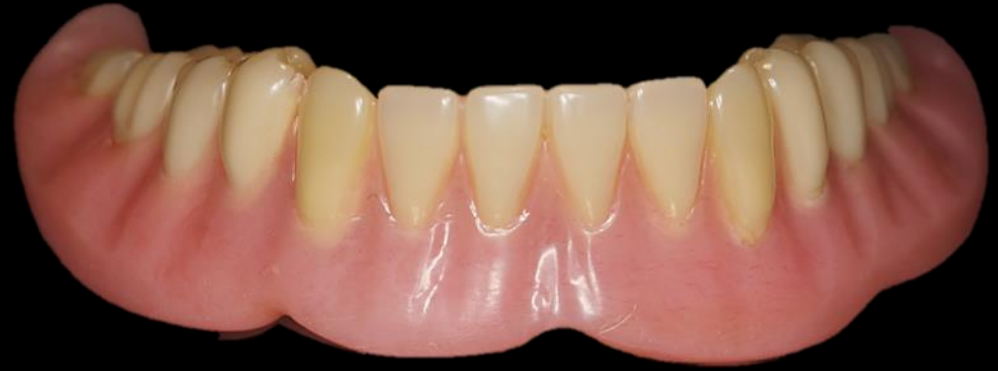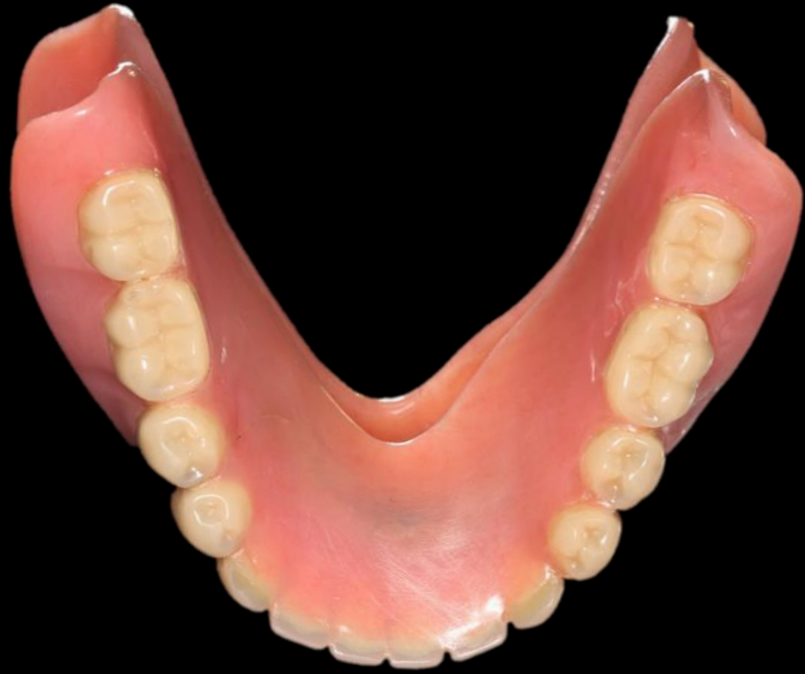Surgery (2021-06-16)



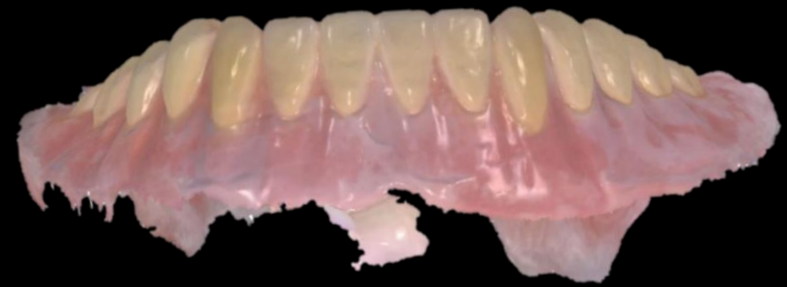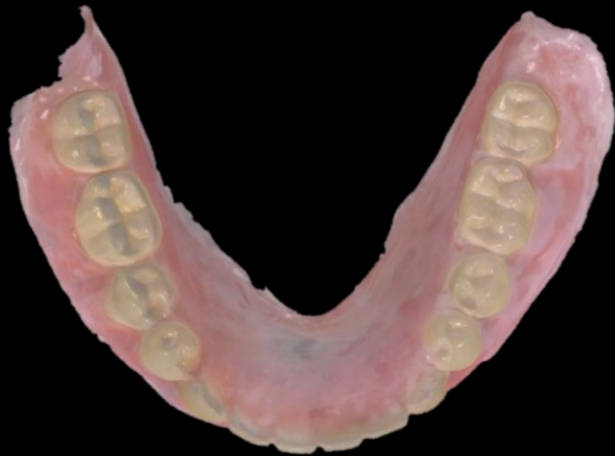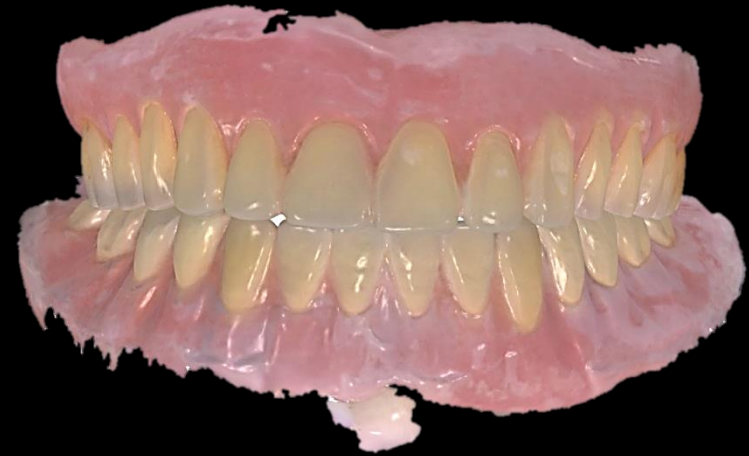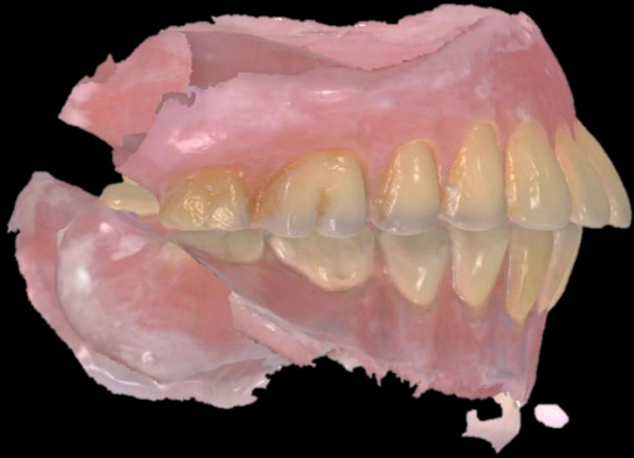Intraoral Scanning



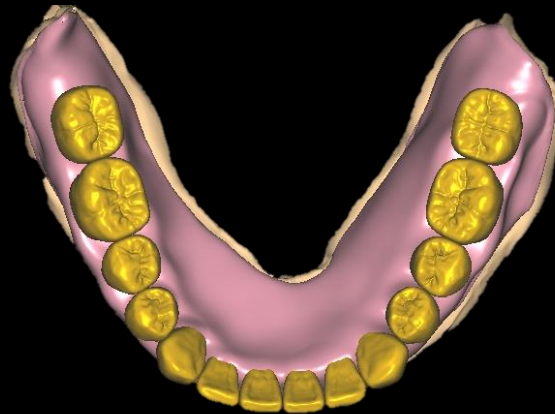
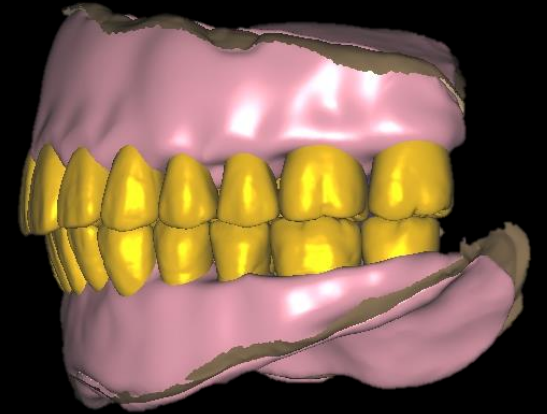
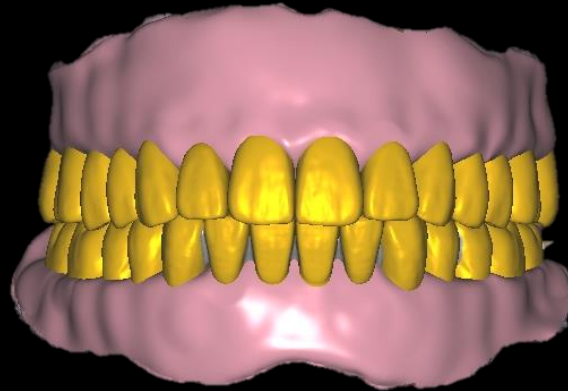
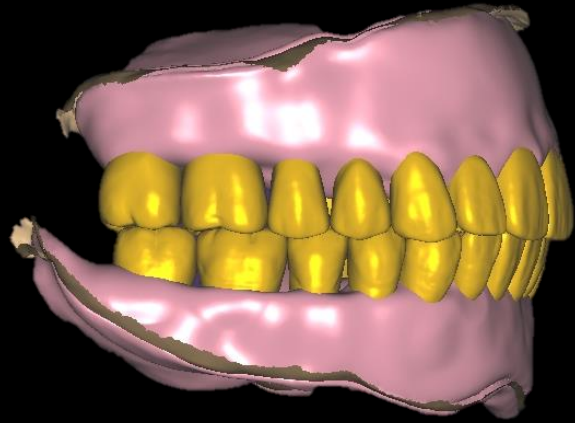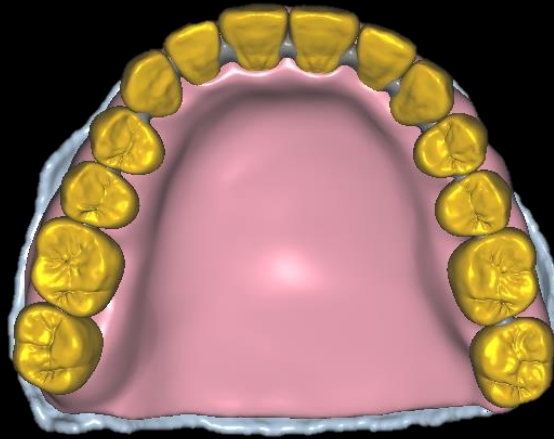
Existing Complete Denture



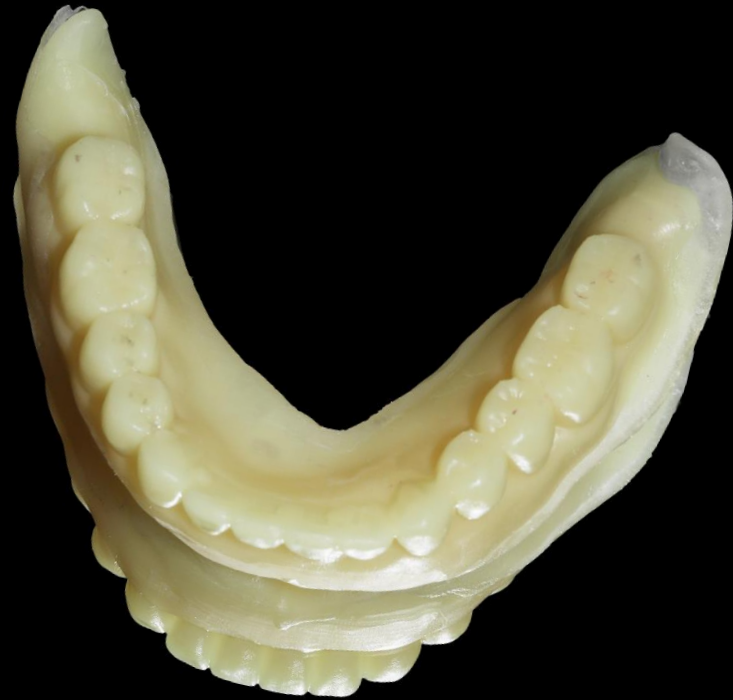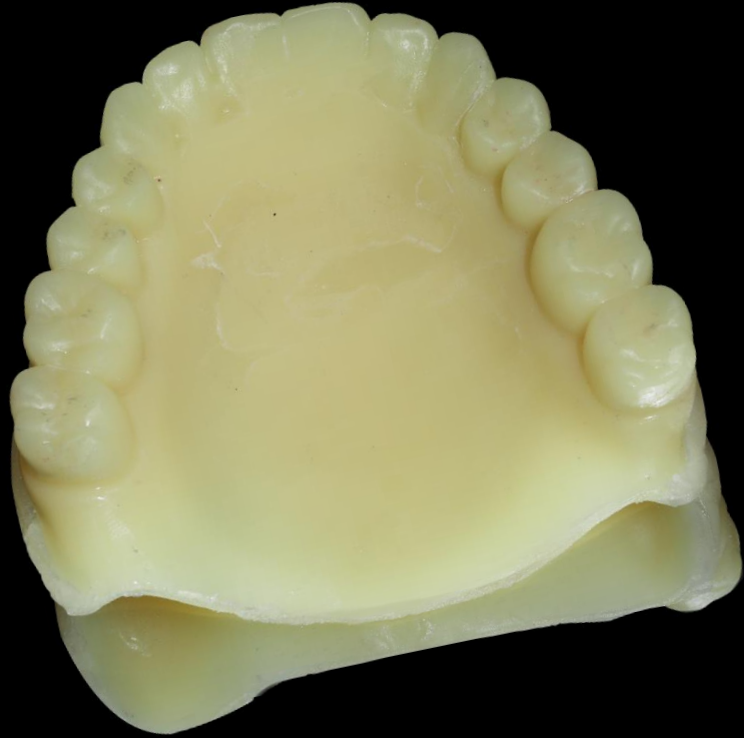Intraoral Scanning with denture



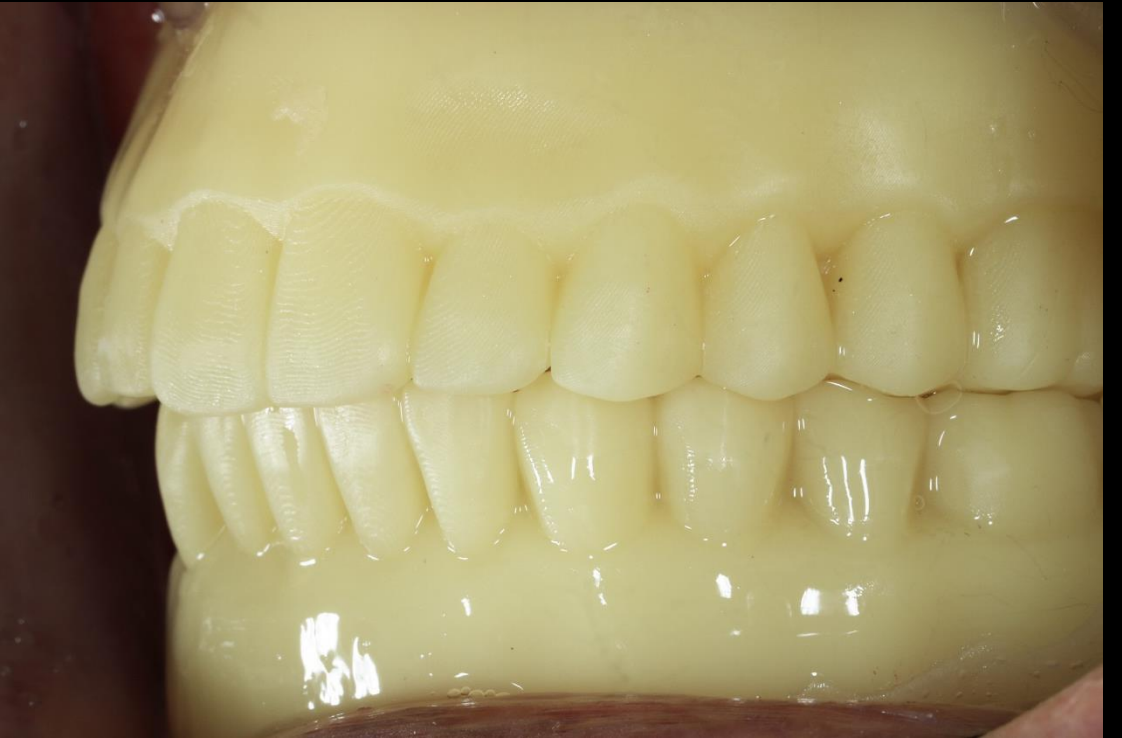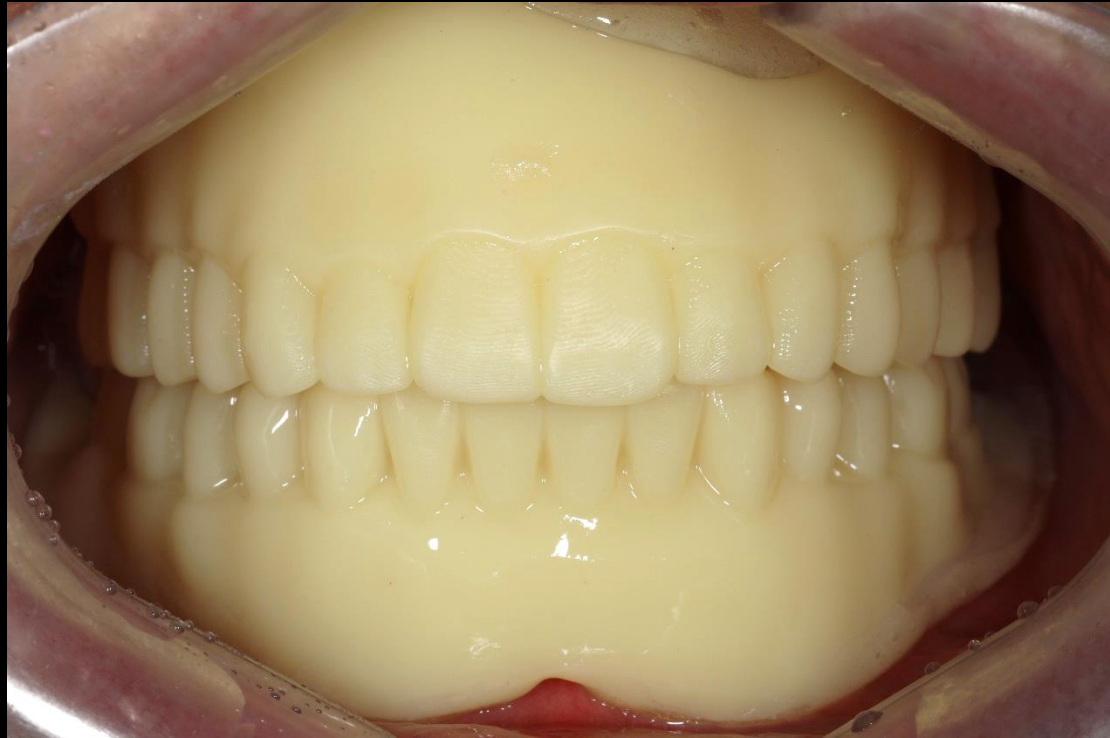
Temporary Denture design



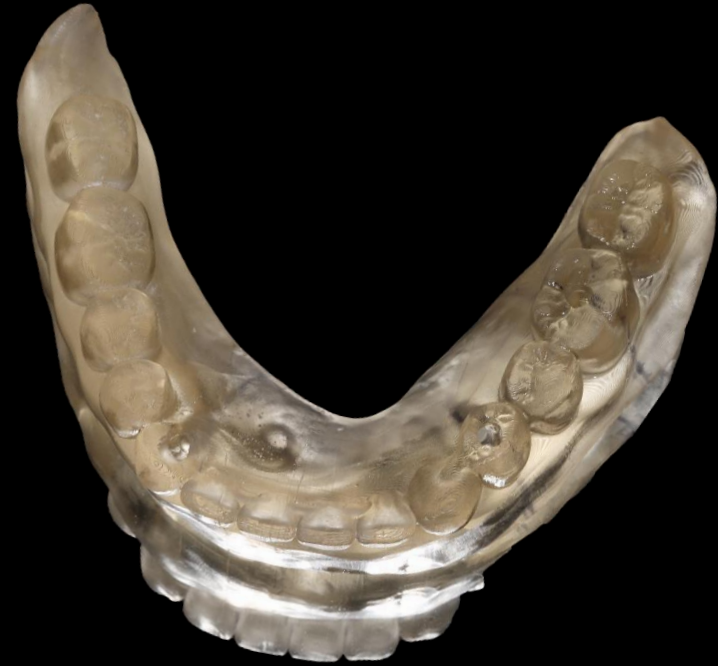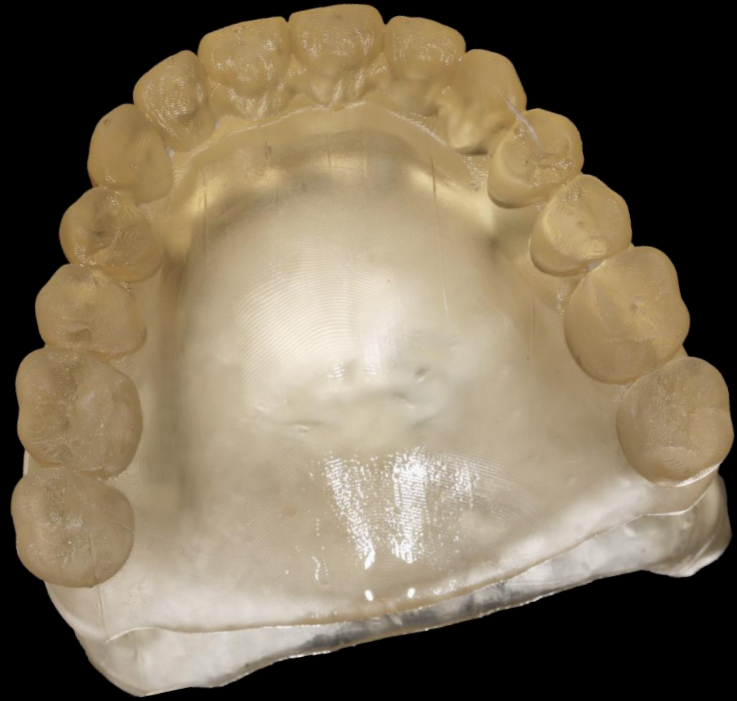Temporary Denture (Printing)



Temporary Denture delivery (2021-06-30)

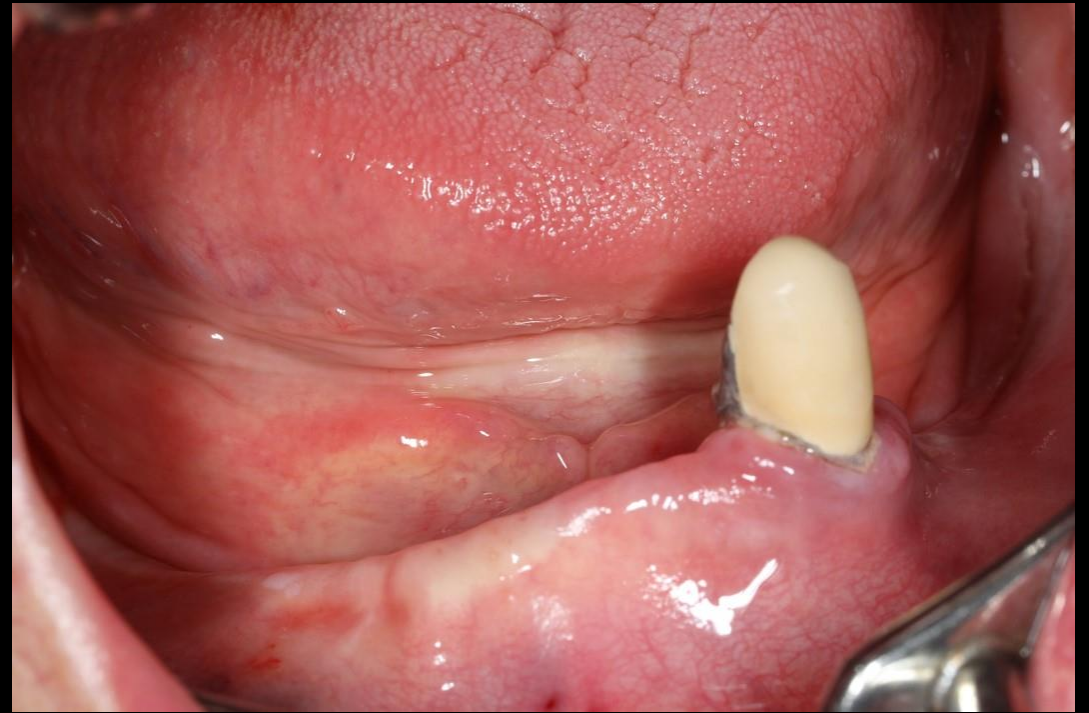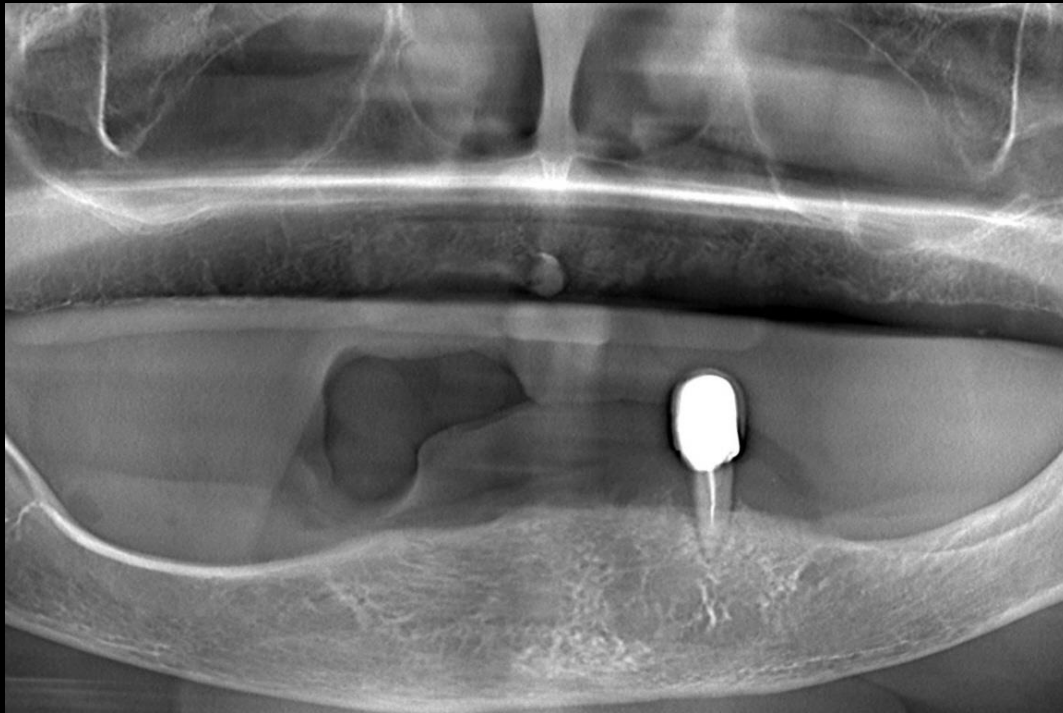


Clear acrylic resin Guide



Similar case

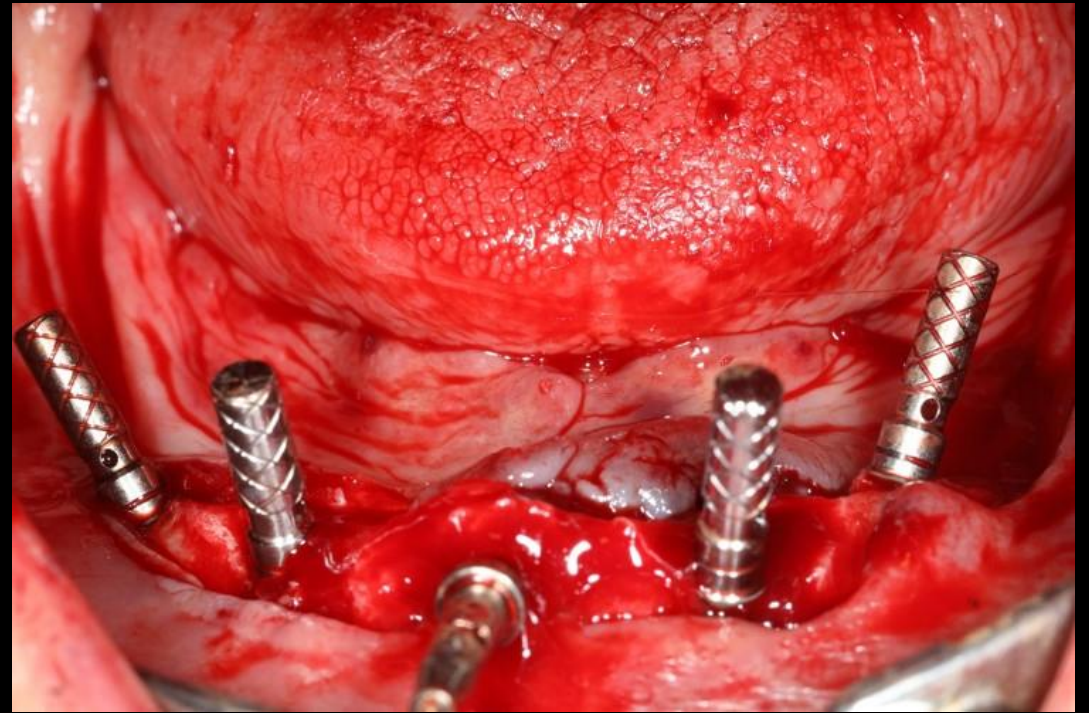
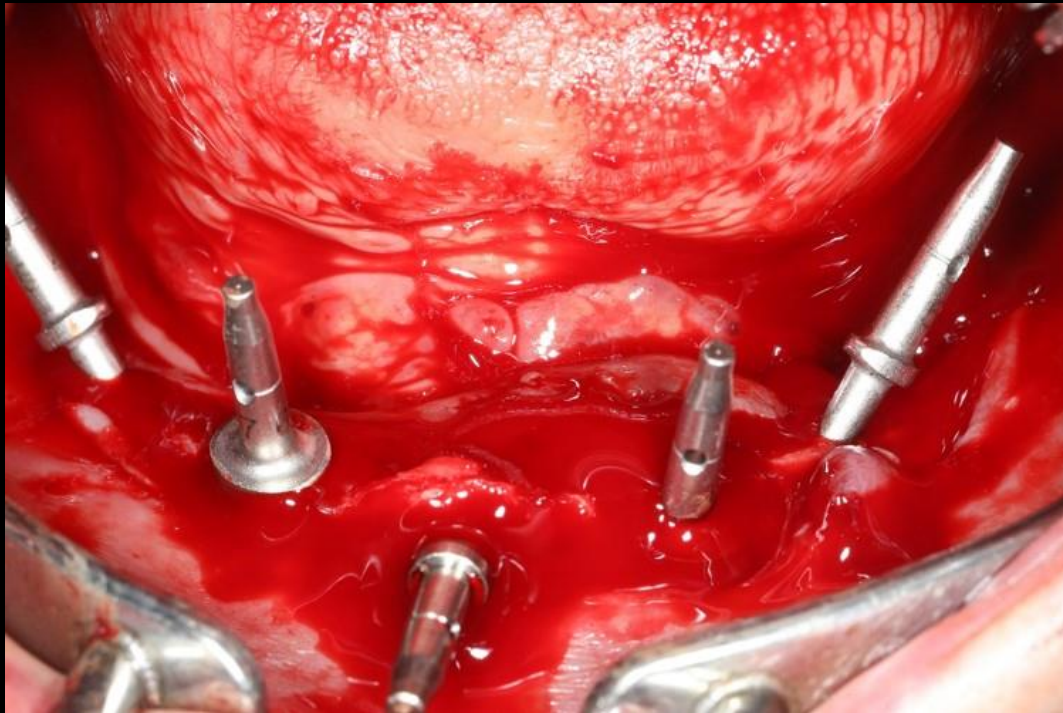
Full mouth rehabilitation with Implant angulation



Pre-op

Similar case

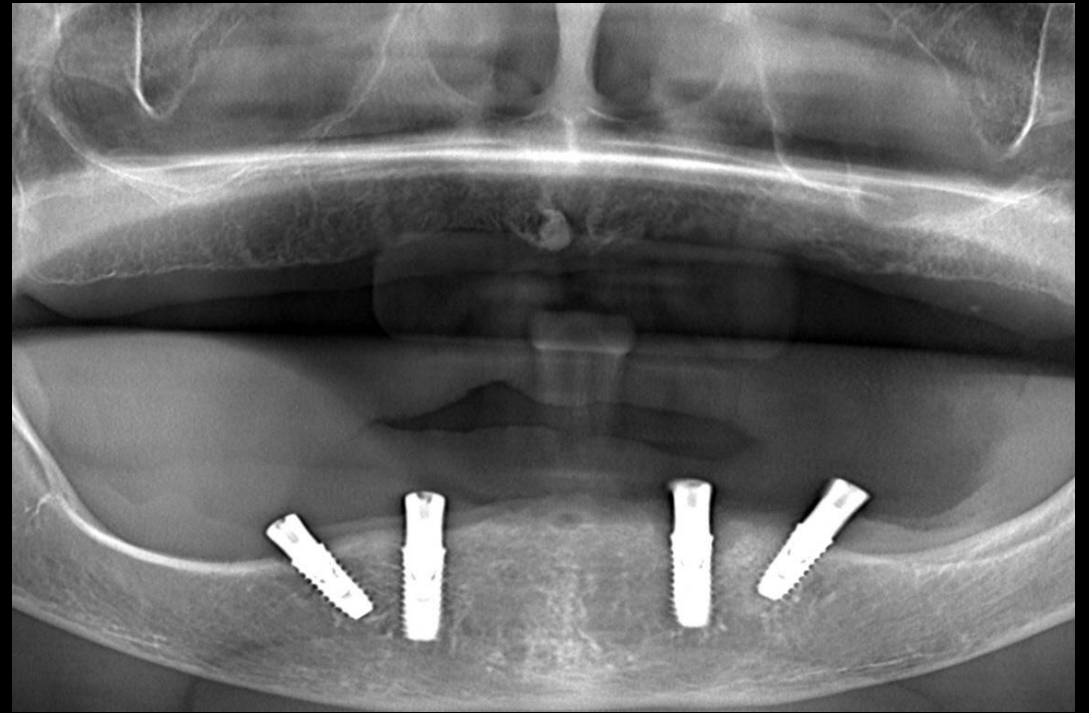
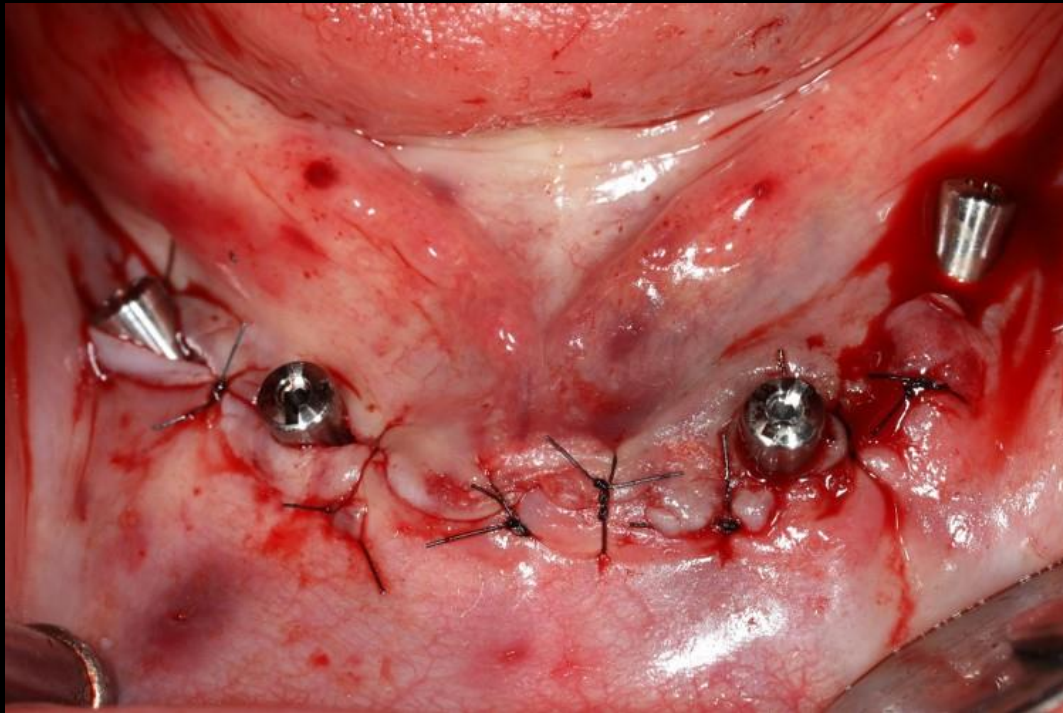
Full mouth rehabilitation with Implant angulation



Surgery

Similar case

Full mouth rehabilitation with Implant angulation



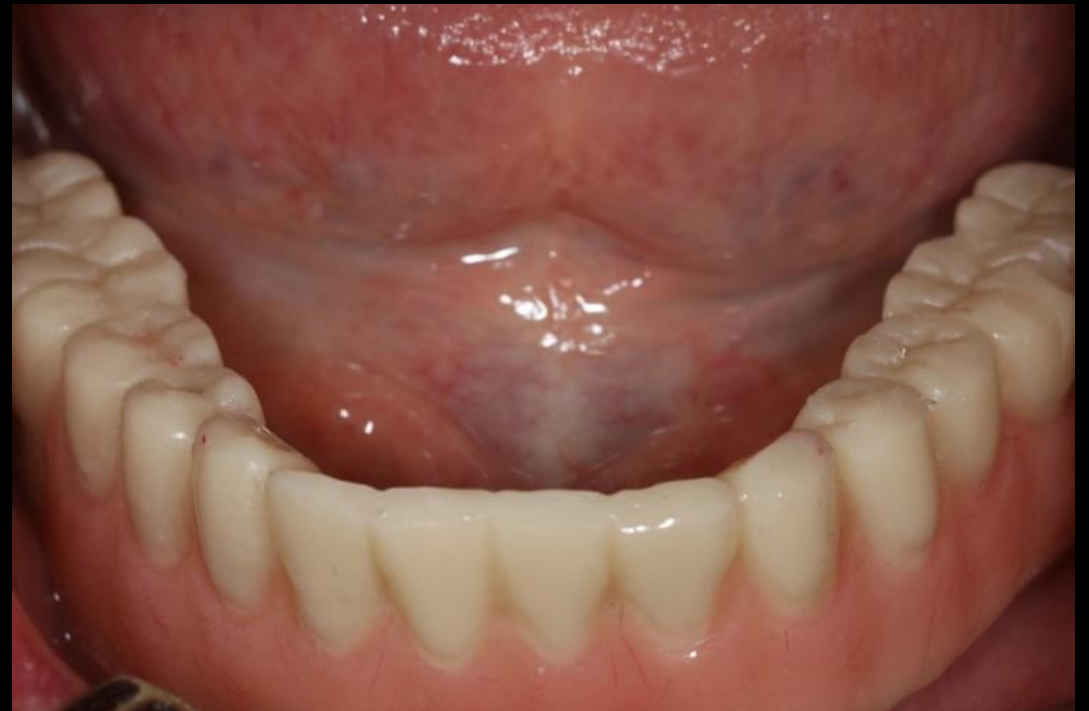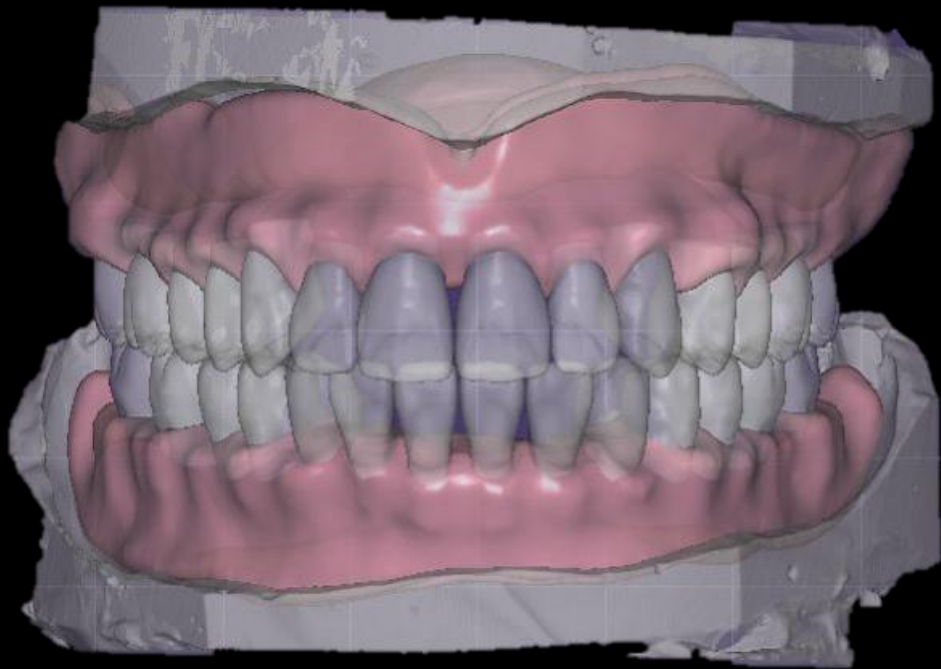Post-op

Prosthesis

- 1 Screw retained prosthesis
- 2 Telescope prosthesis with attachment for cleansing

Similar case

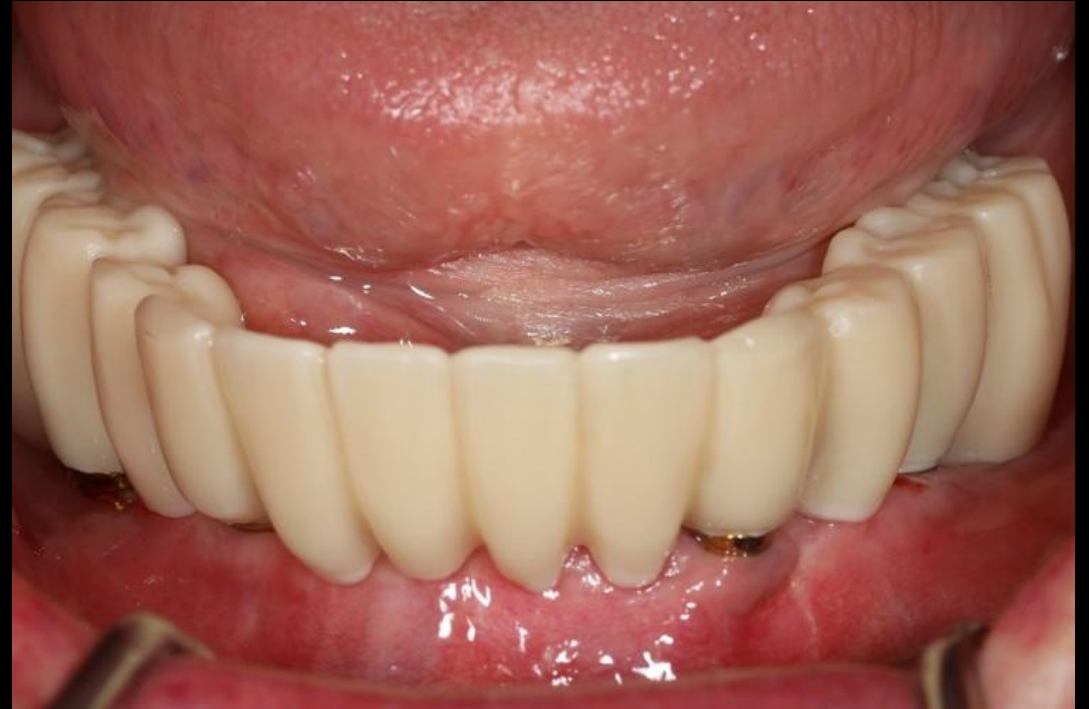Full mouth rehabilitation with Implant angulation



Temporary Denture (Milling)

Similar case

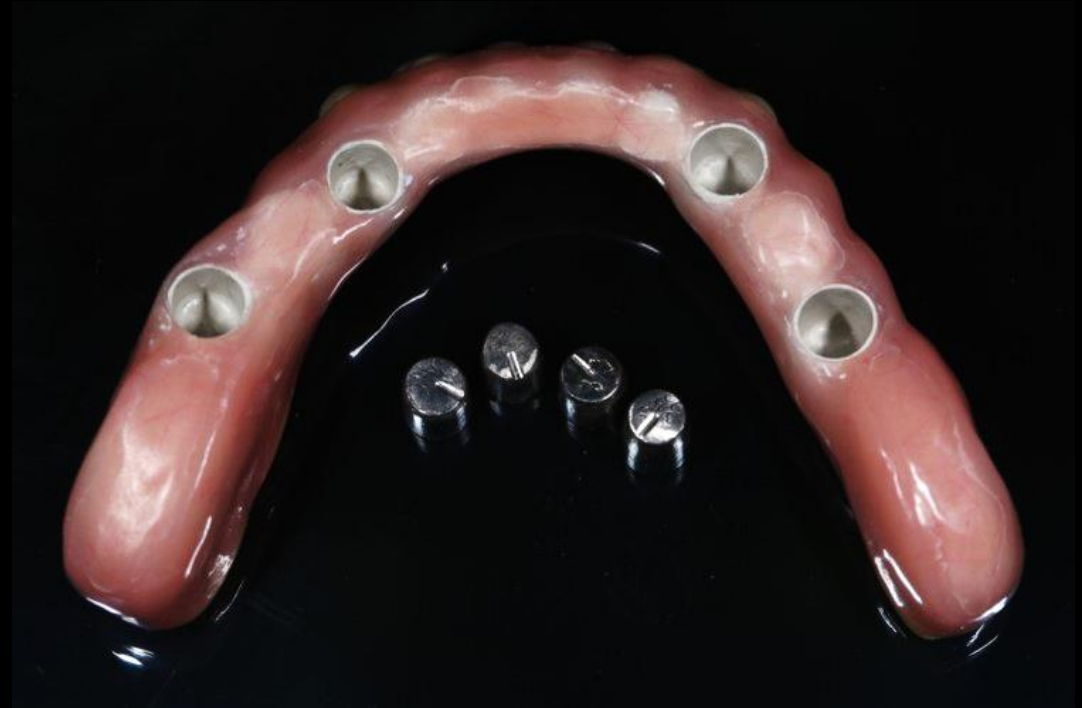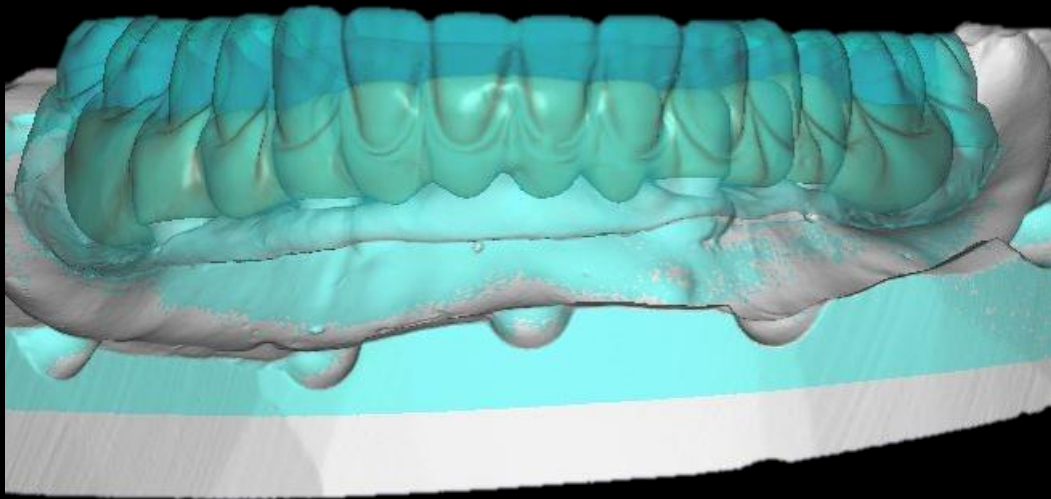
Full mouth rehabilitation with Implant angulation



Provisional restoration

Similar case

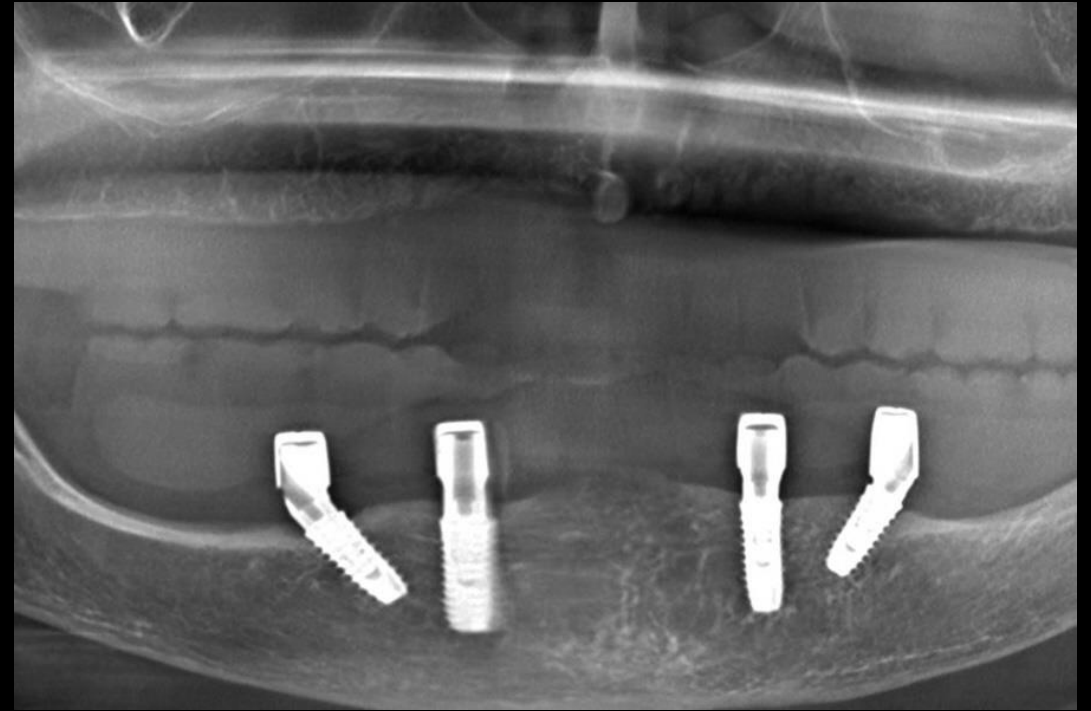
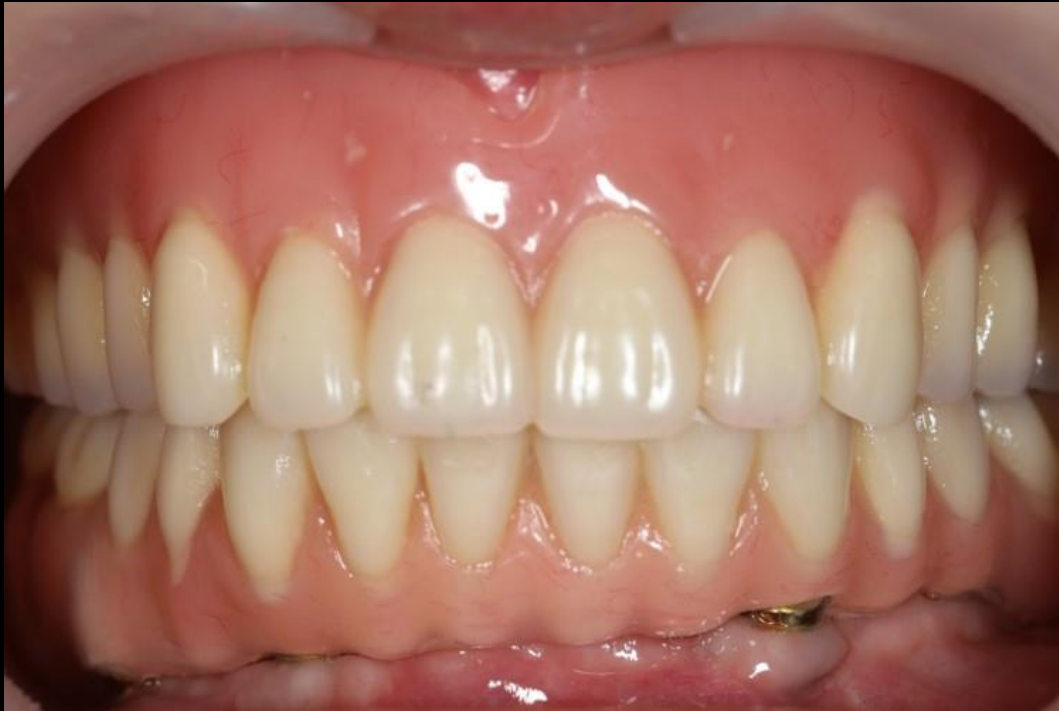Full mouth rehabilitation with Implant angulation



Hybrid Denture

Similar case

Full mouth rehabilitation with Implant angulation



Final prosthesis

