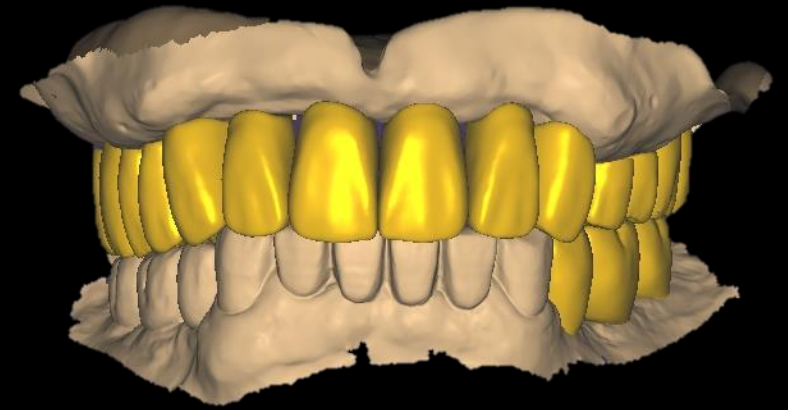
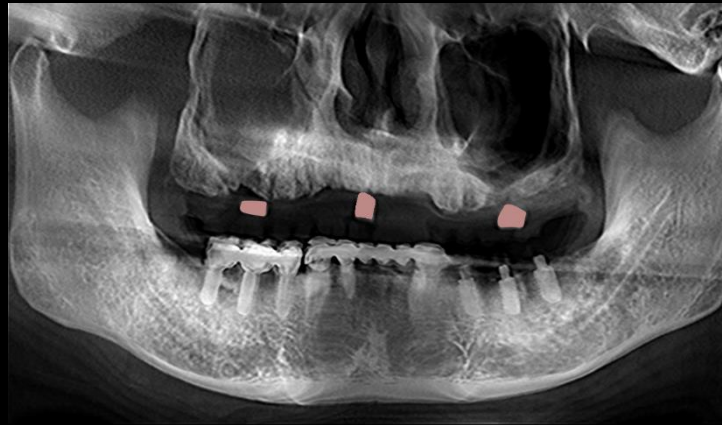


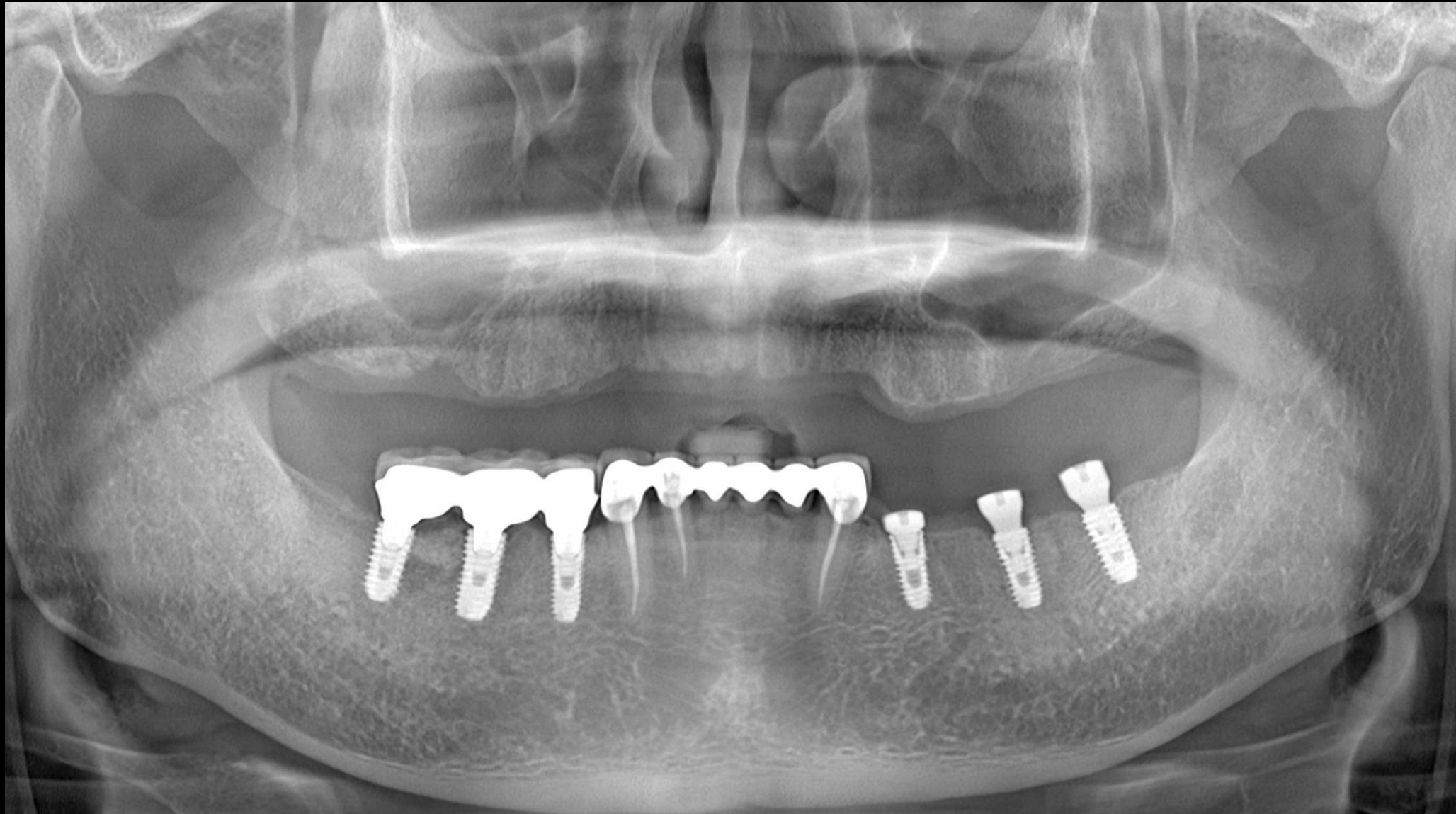

Digital workflow With Dentium Digital Guide

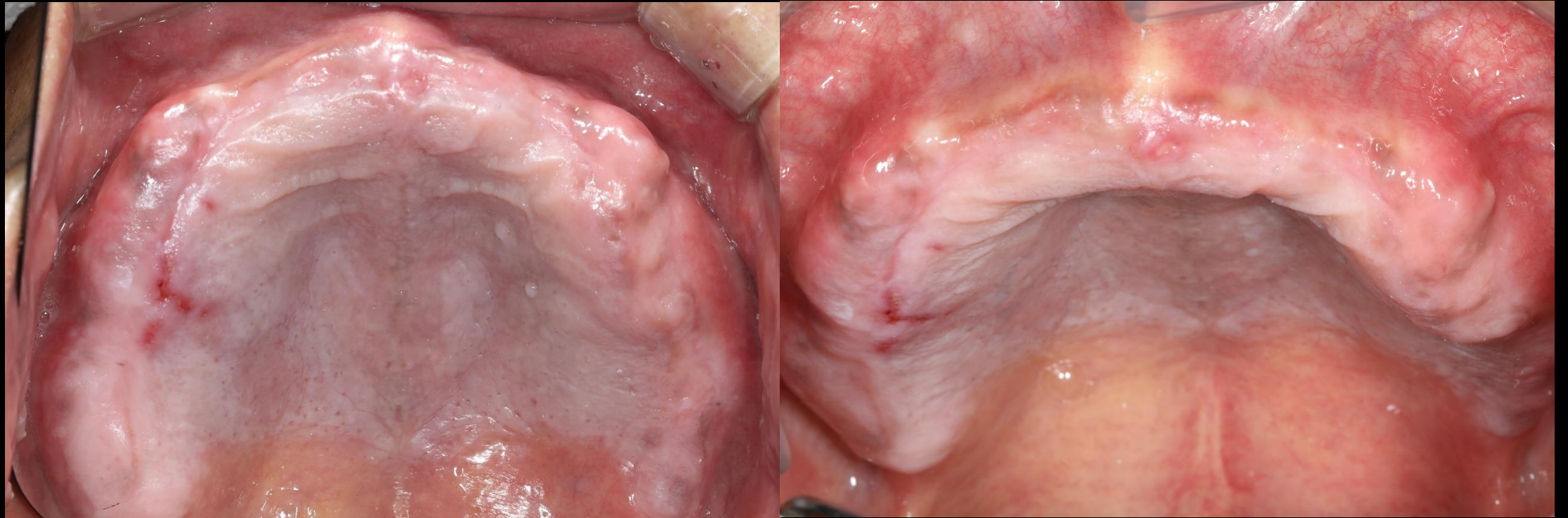
Dr. SM Chung
2021.6.22 (Tue)



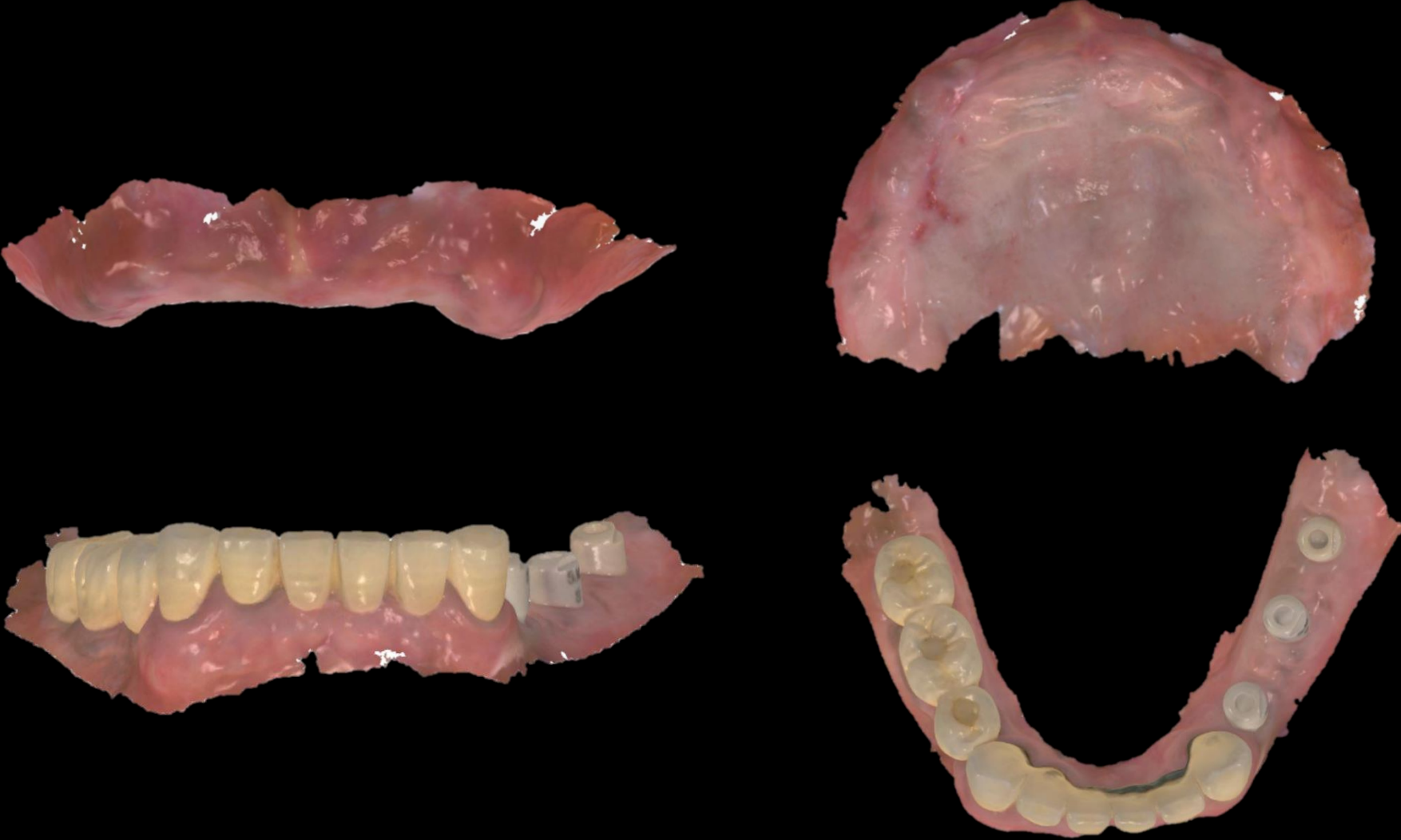Pre-op (2021-06-09)



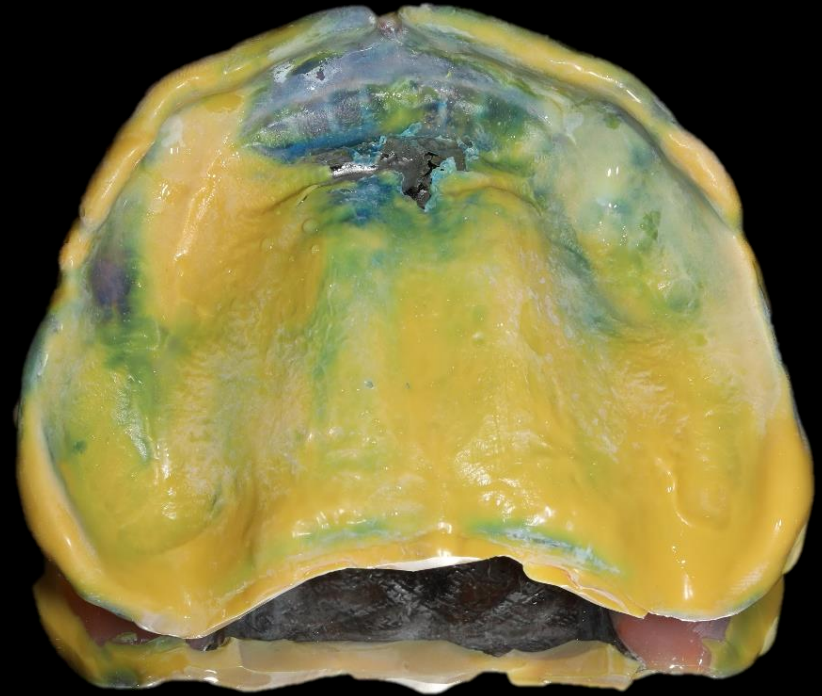
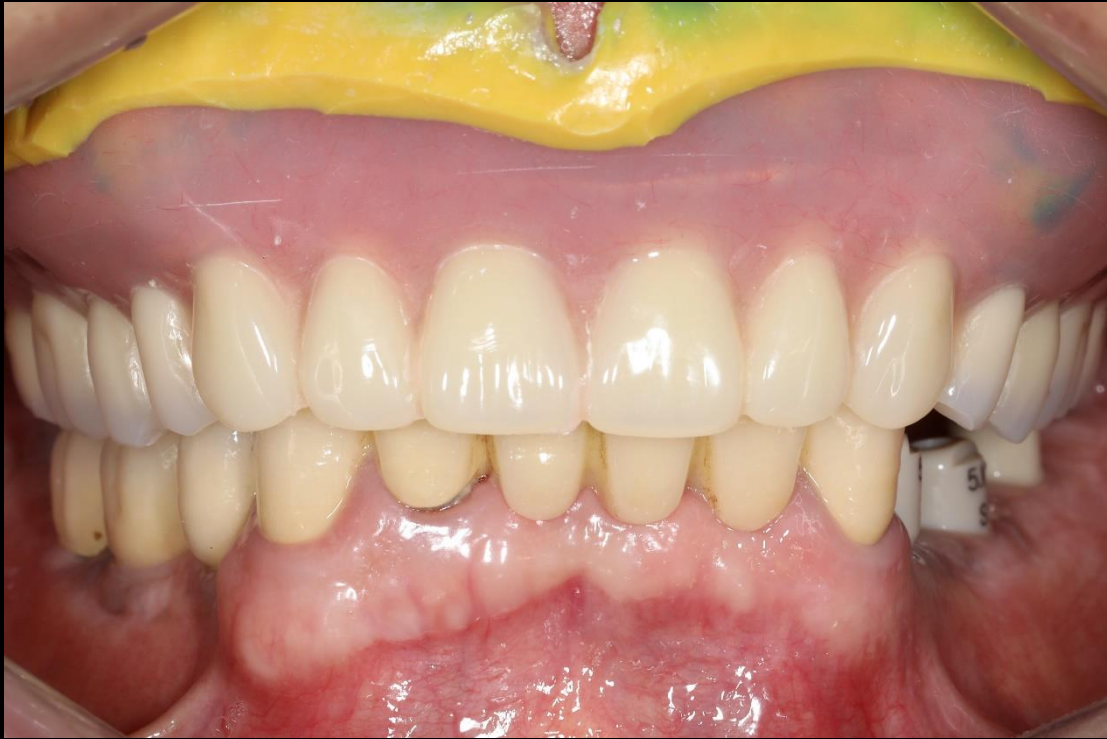Pre-op (2021-06-09)



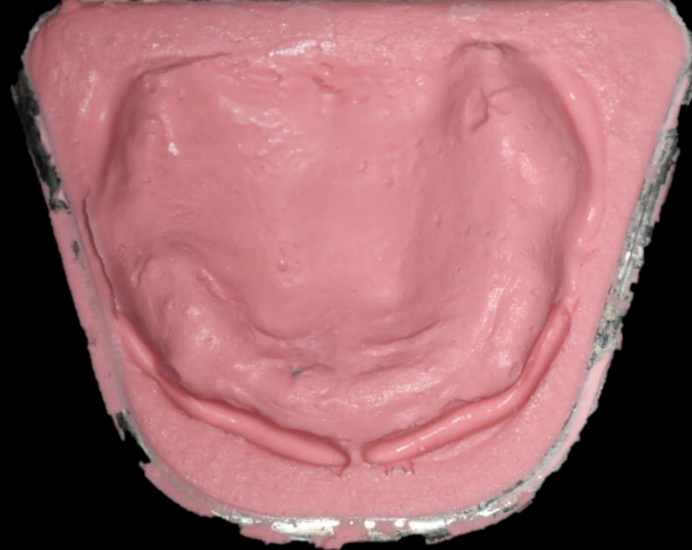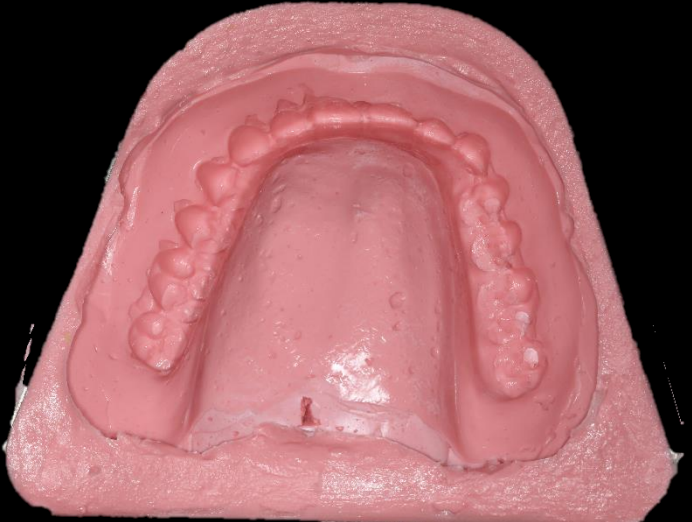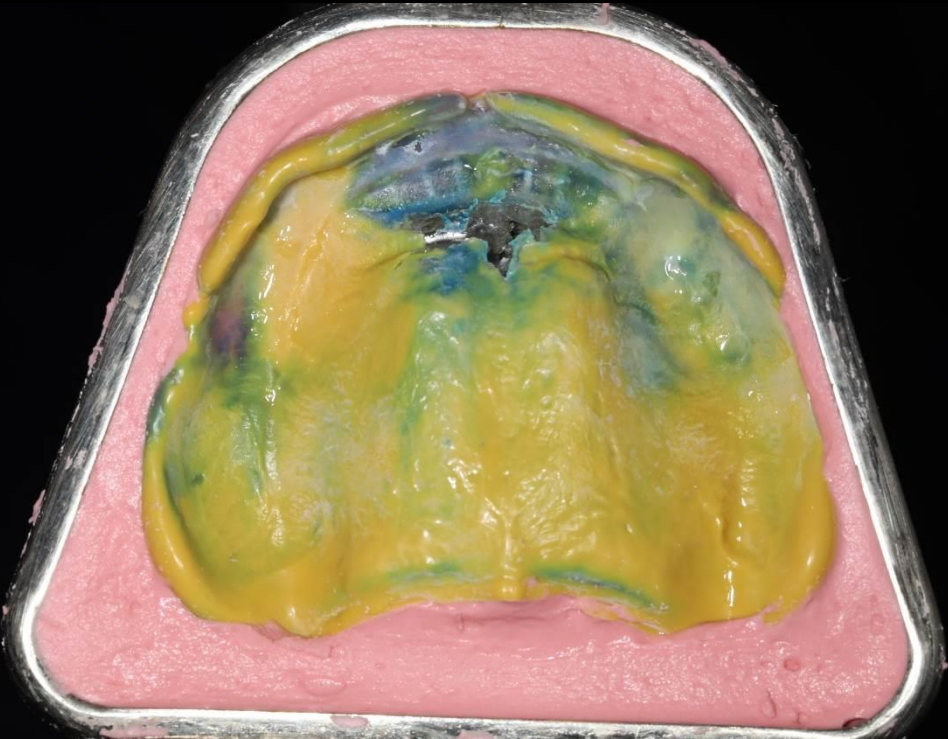
Intraoral Scanning



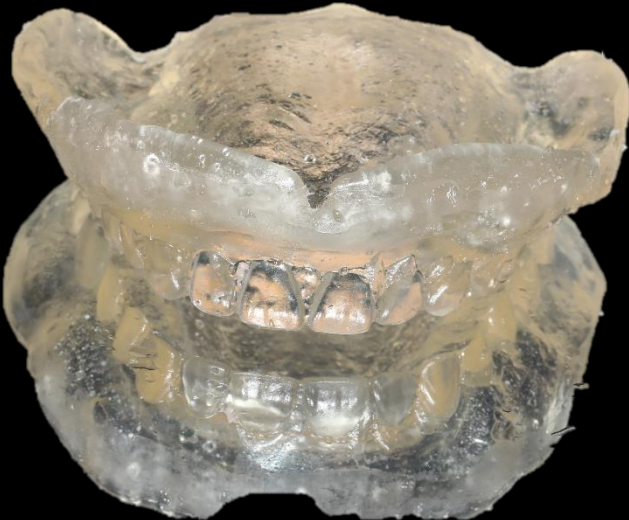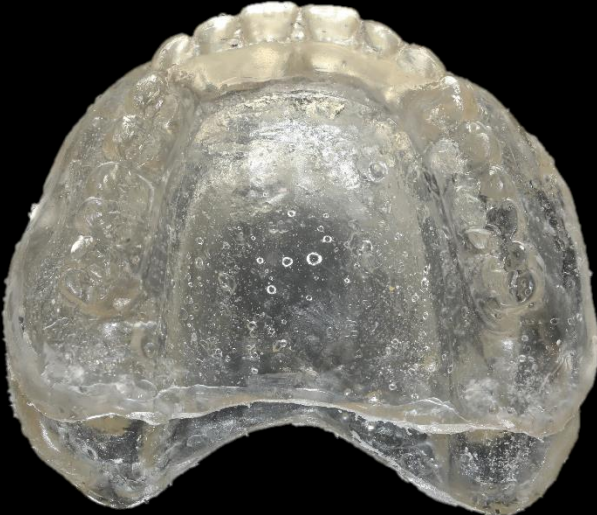
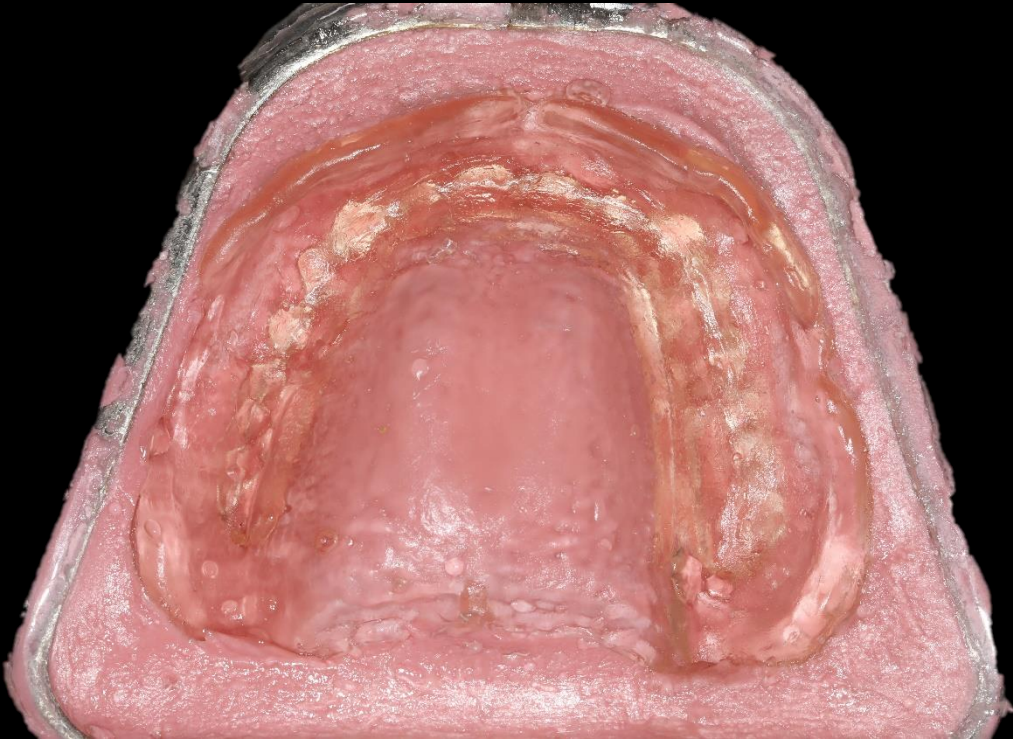
Impression using existing Denture
(Bright Impress Light body)



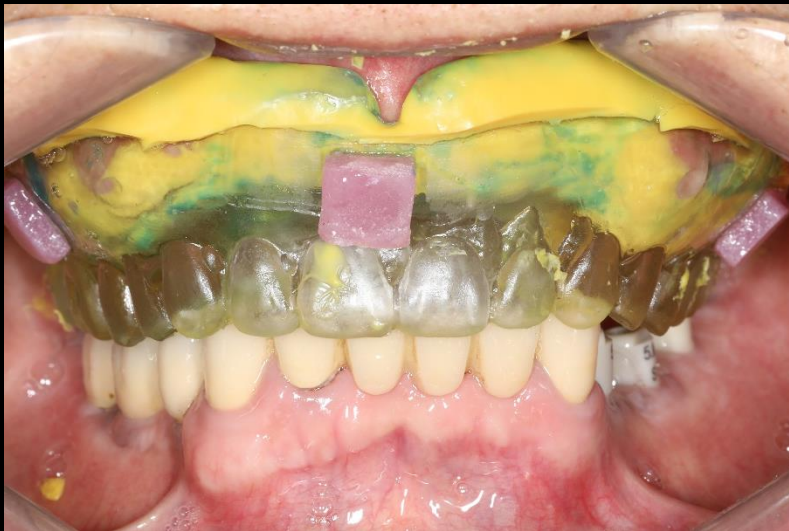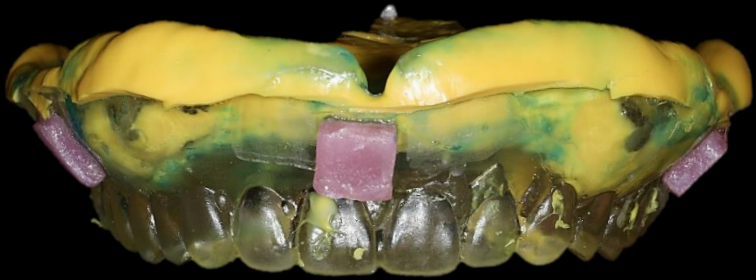Denture duplication



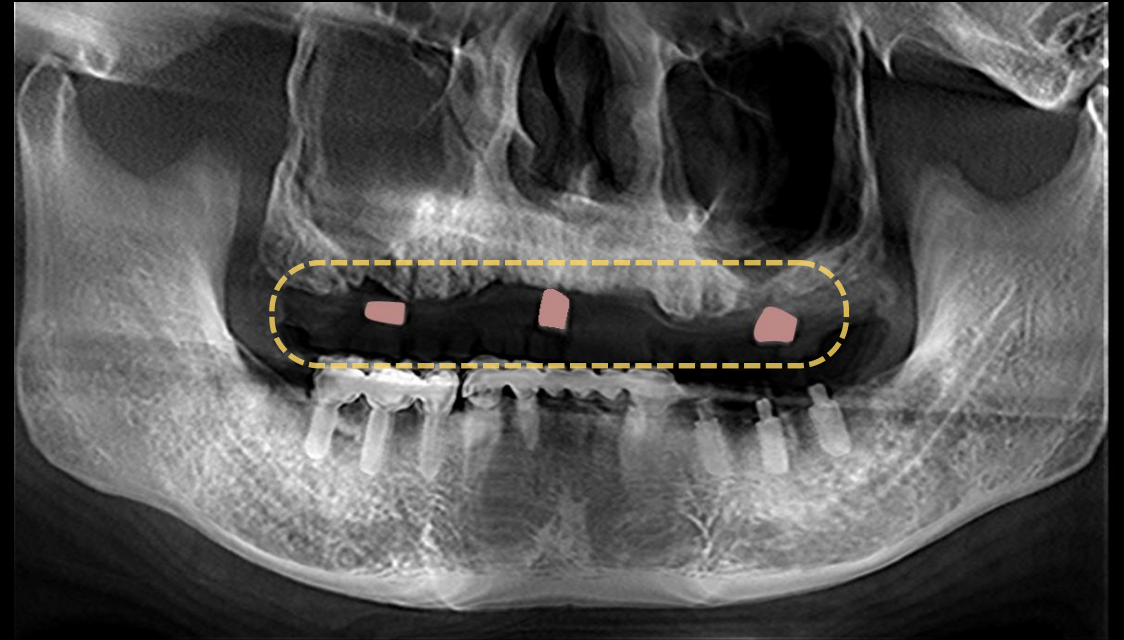
Clear acrylic resin template



Resin marking & CT taking

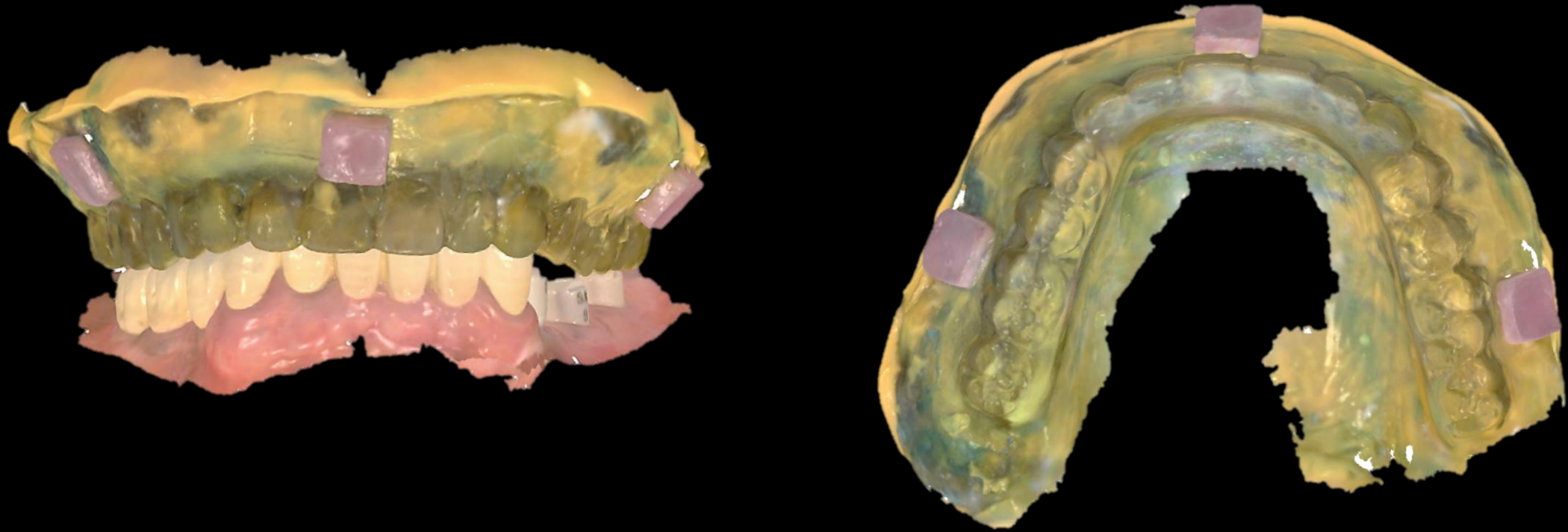


Resin marking

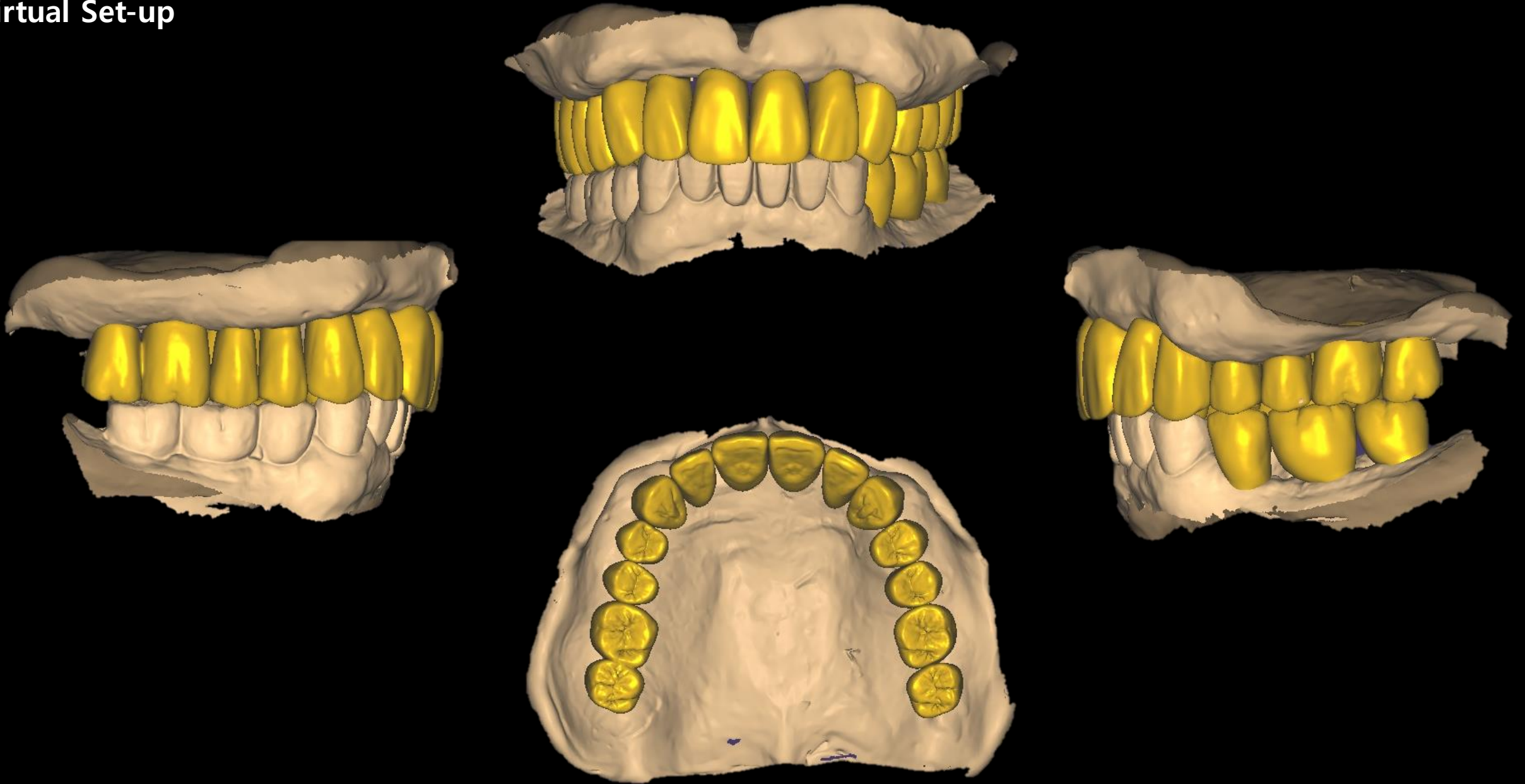


CT image with Clear acrylic resin template

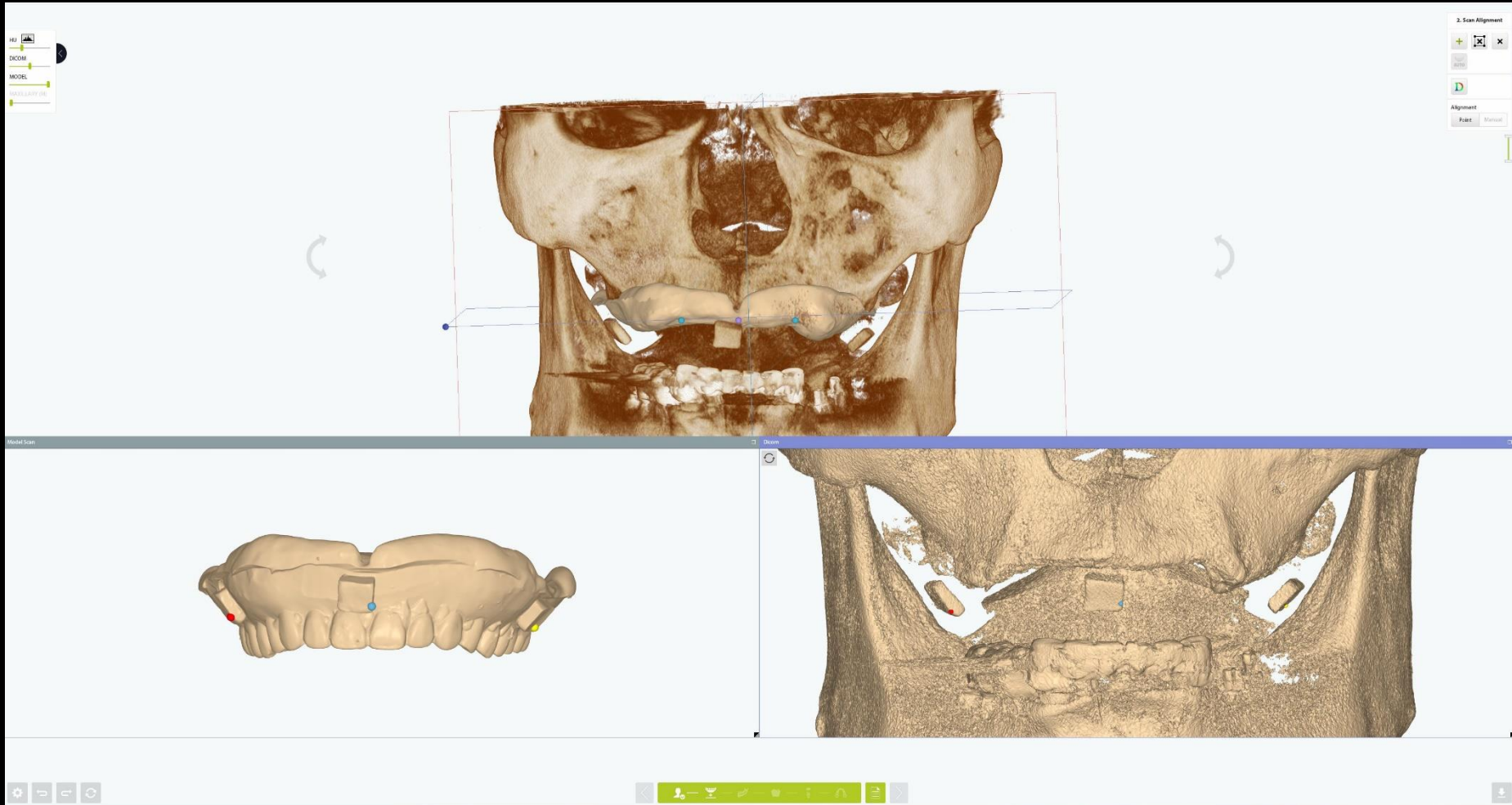
Intraoral Scanning with Clear acrylic resin template



Virtual Set-up

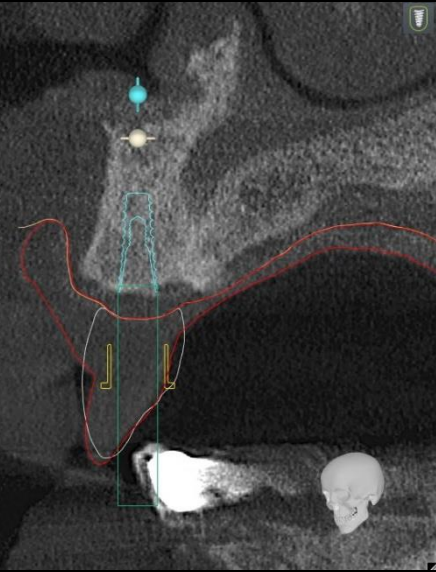


Digital Guide S/W (Model Scan & CT data merging)



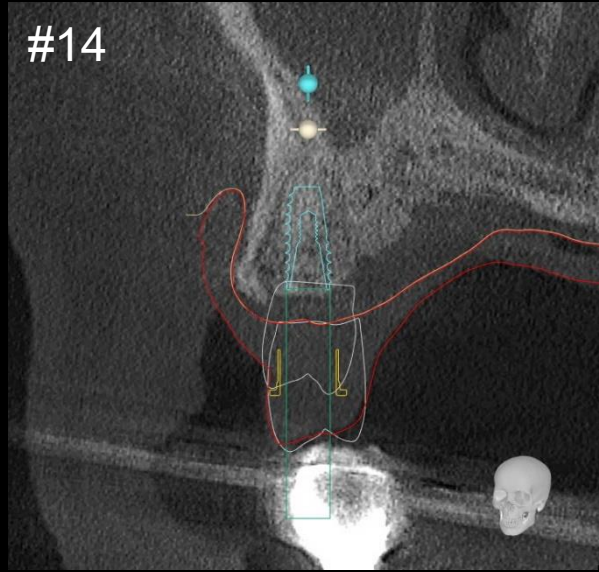
Digital Guide S/W (Implant Planning / bright Bone Level)

#11



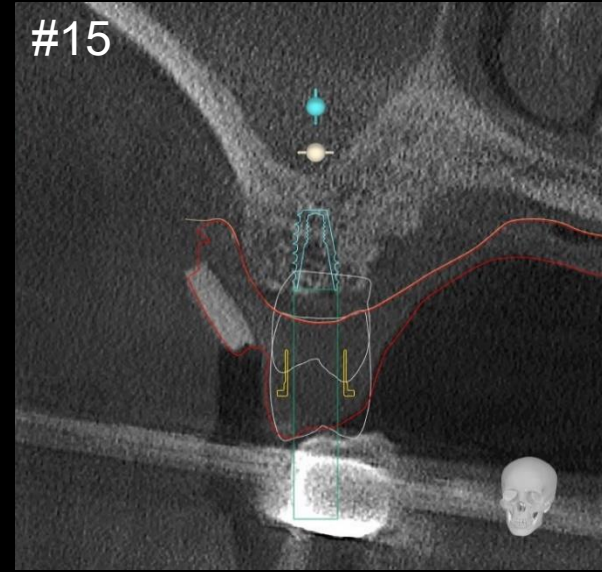
ø4.0 * 11mm

#14



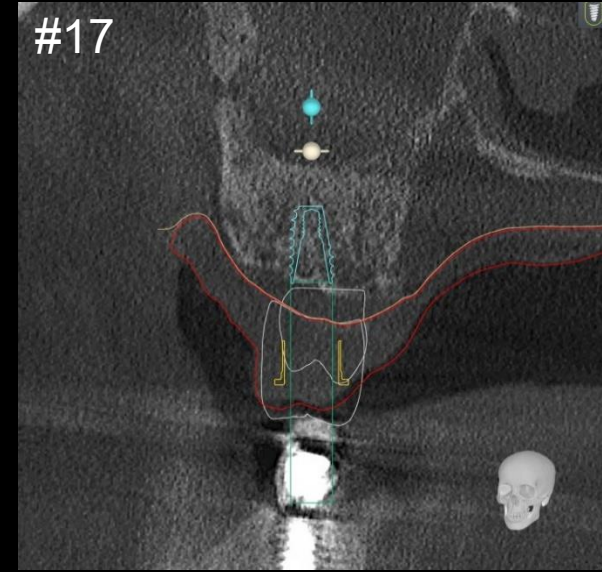
Ø4.0 * 11mm

#15



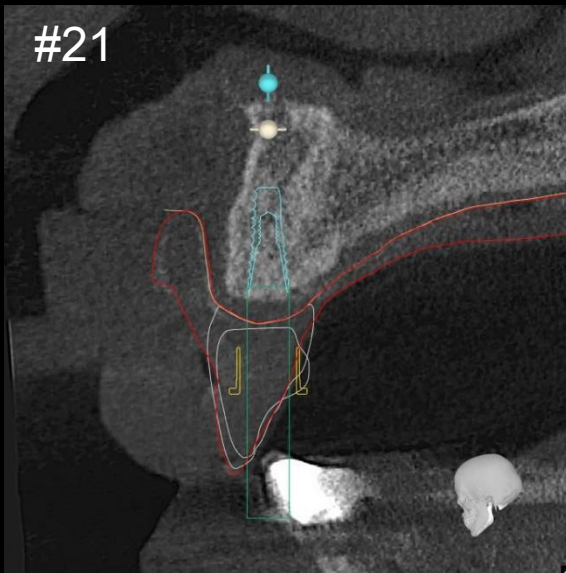
Ø4.0 * 11mm

#17

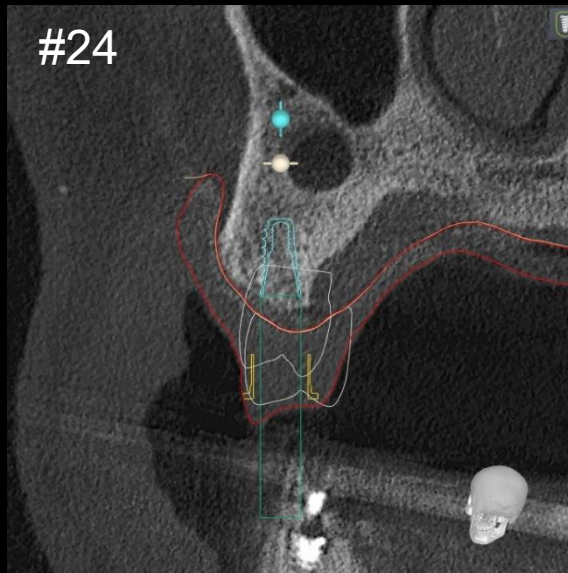


ø5.0 * 7mm

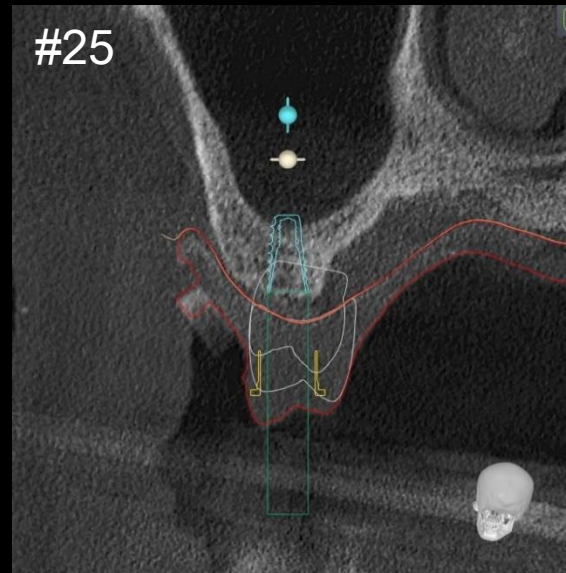
Digital Guide S/W (Implant Planning / bright Bone Level)



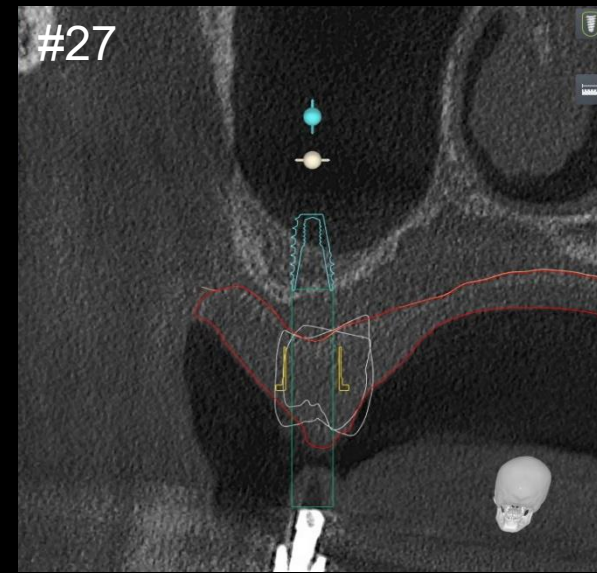
ø3.5 * 11mm



Ø4.5 * 11mm

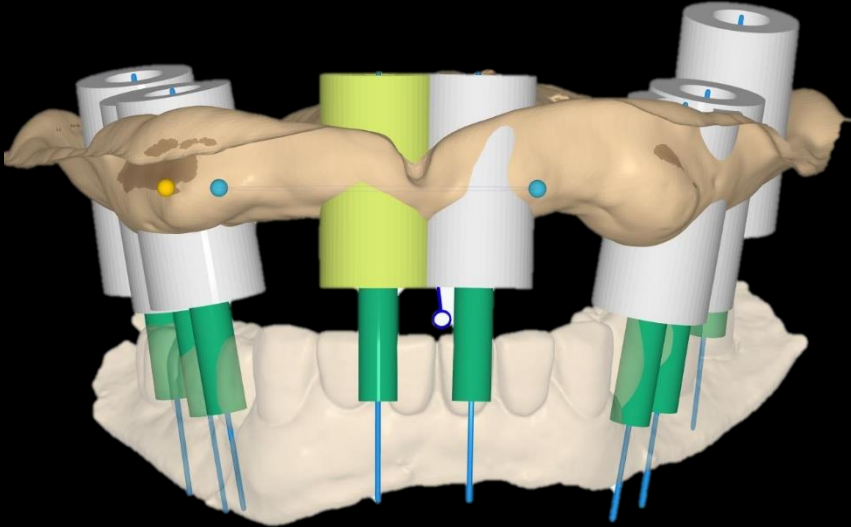
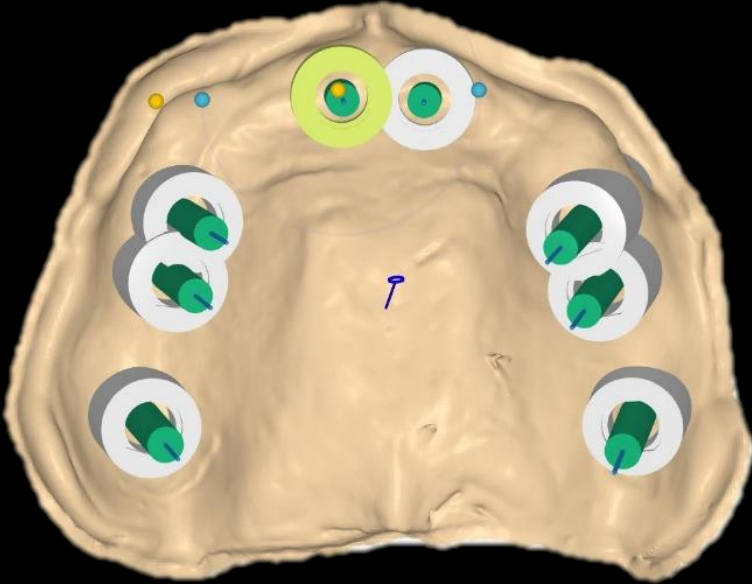


ø4.5 * 9mm

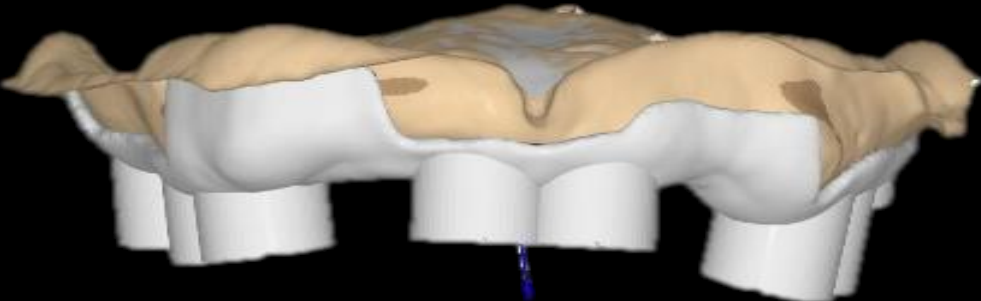
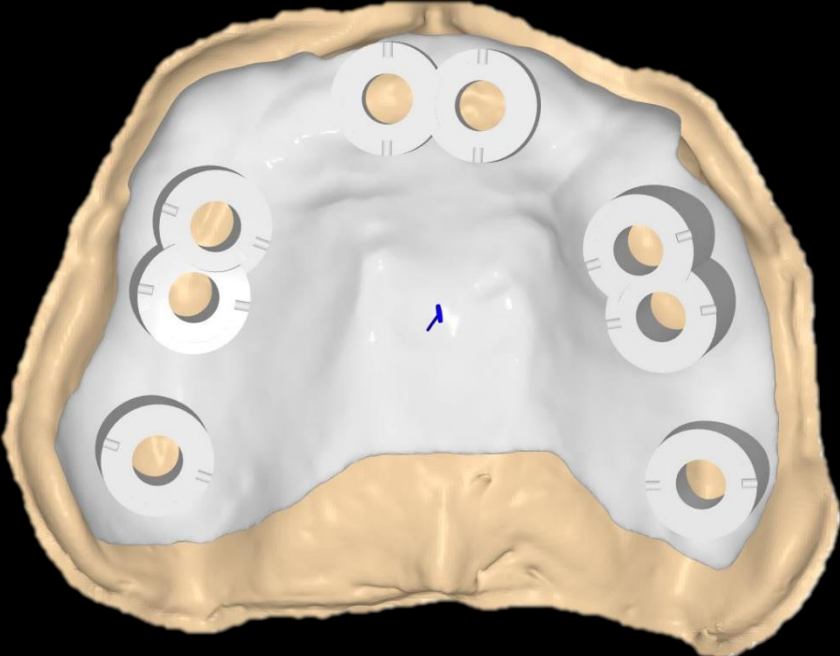


ø5.0 * 7mm

Digital Guide S/W (Surgical Guide design)



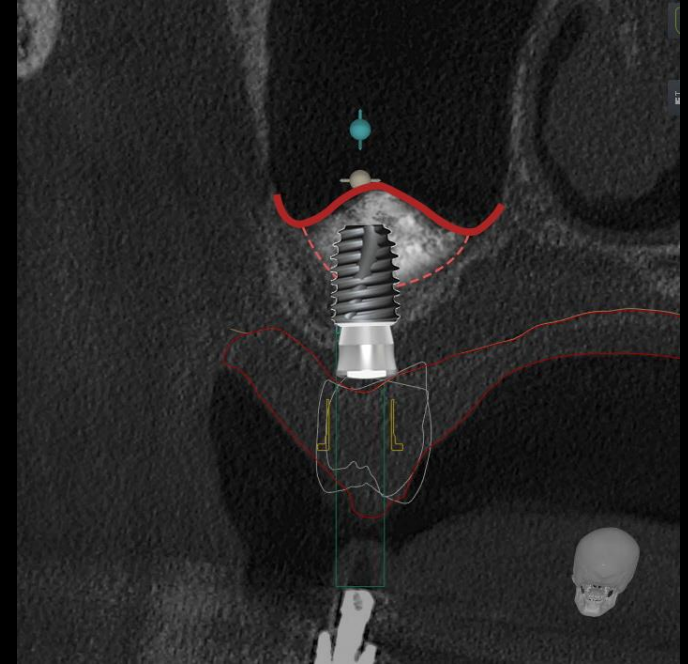
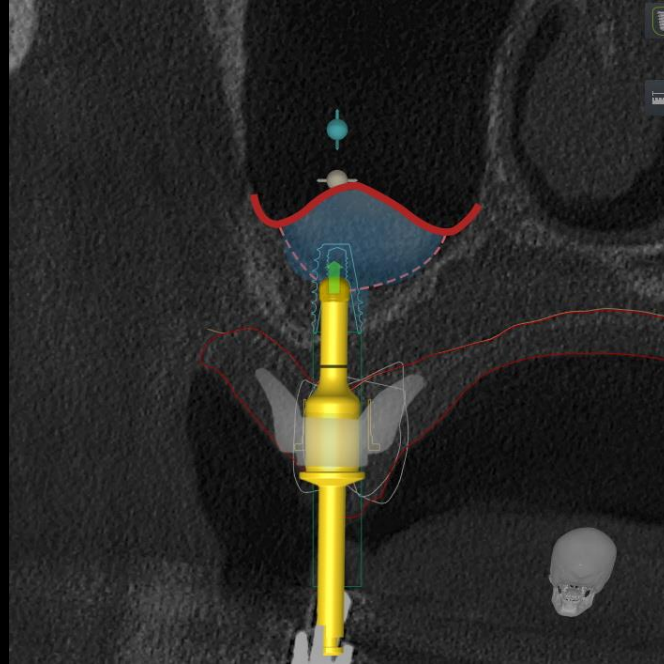
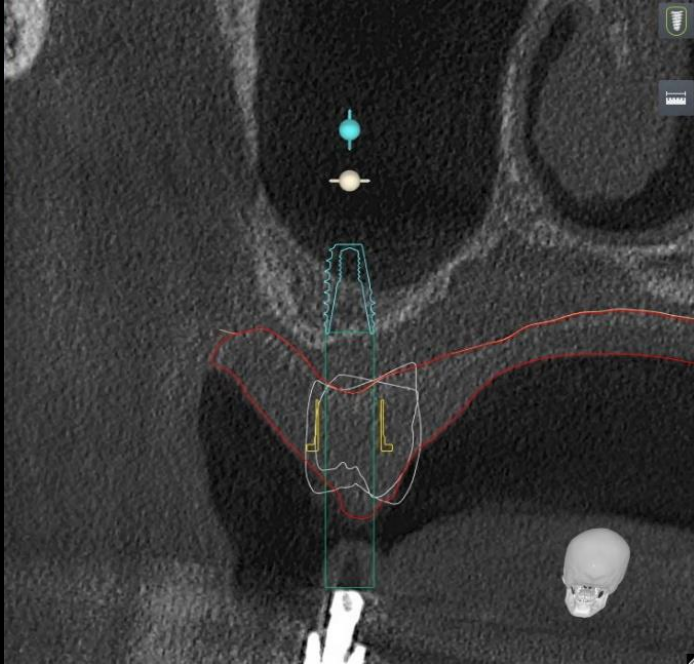
Digital Guide S/W (Surgical Guide design)



Surgical Guide (Milling)



Surgery Plan

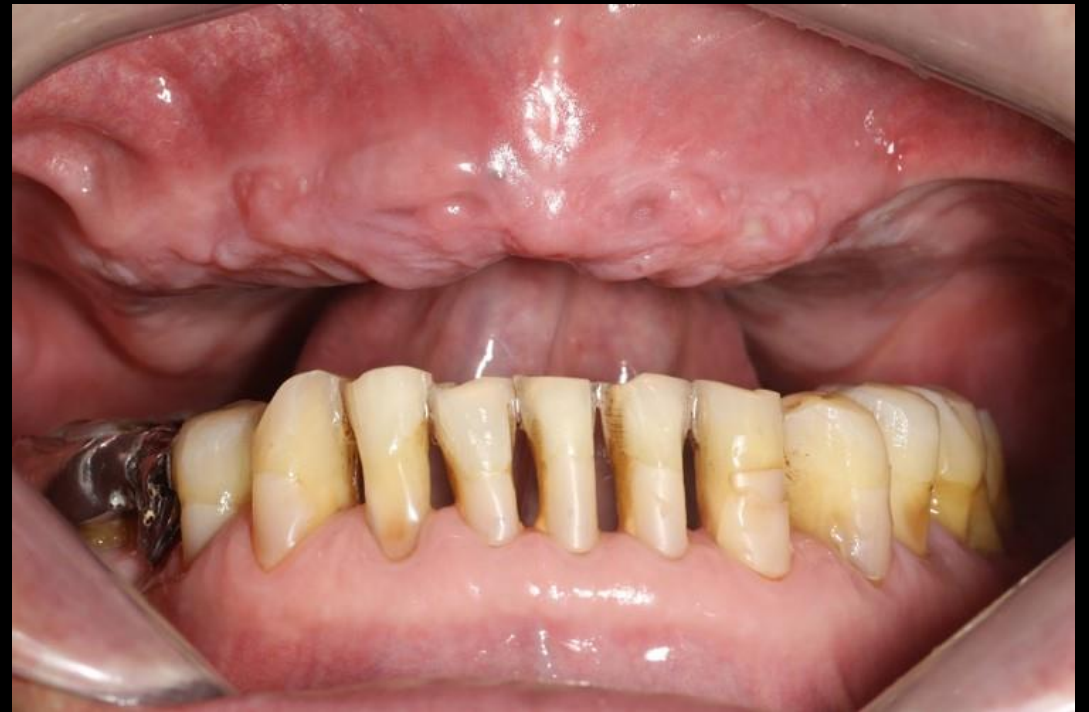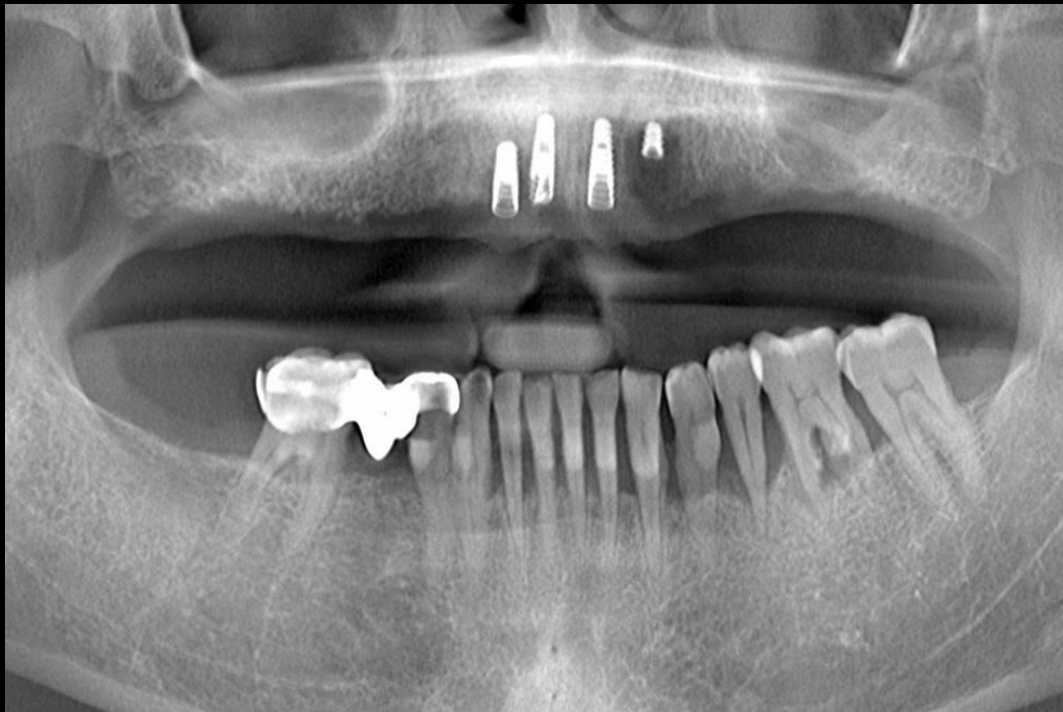


- #10,20 bright Bone Level Fixture installation using **Digital Guide**
- #20 Sinus Elevation (Crestal approach) with **Crestal Drill**



Similar case

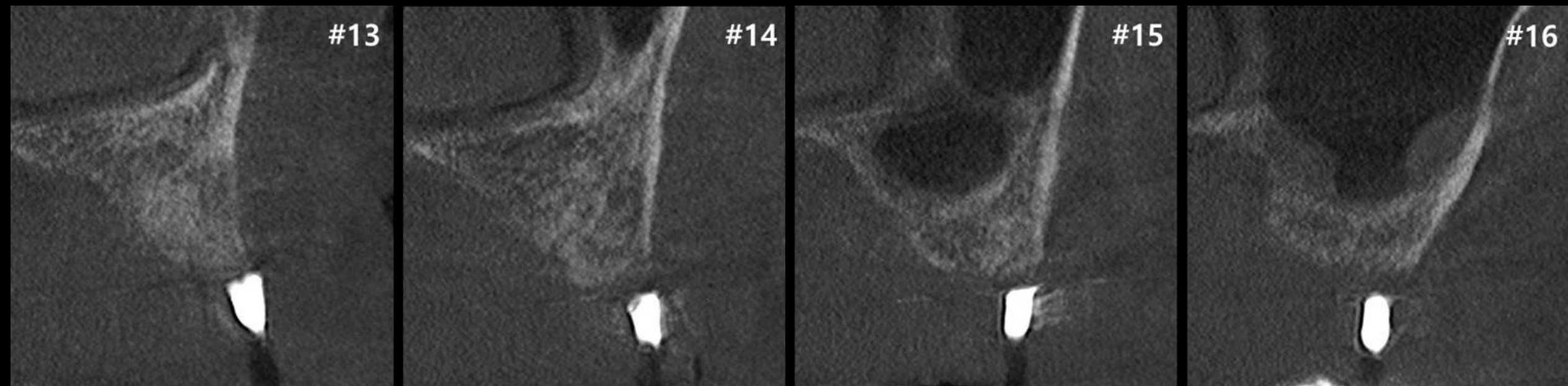
Full mouth rehabilitation with Denture duplication



Pre-op

Similar case

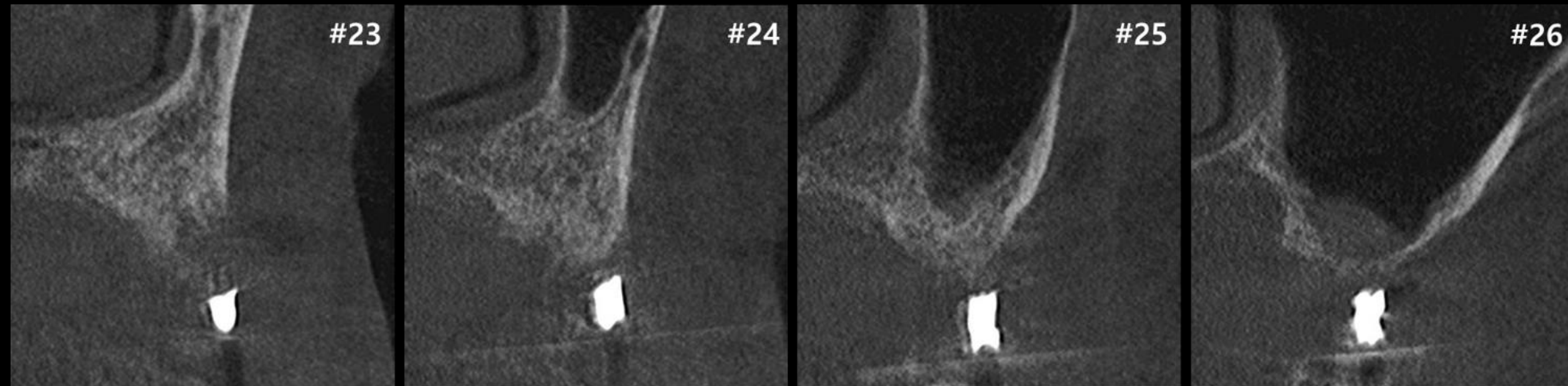
Full mouth rehabilitation with Denture duplication



#10 Pre-op

Similar case

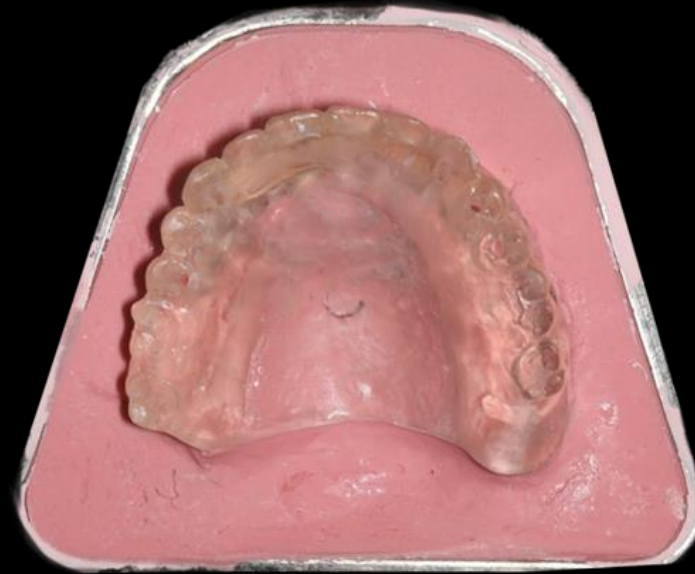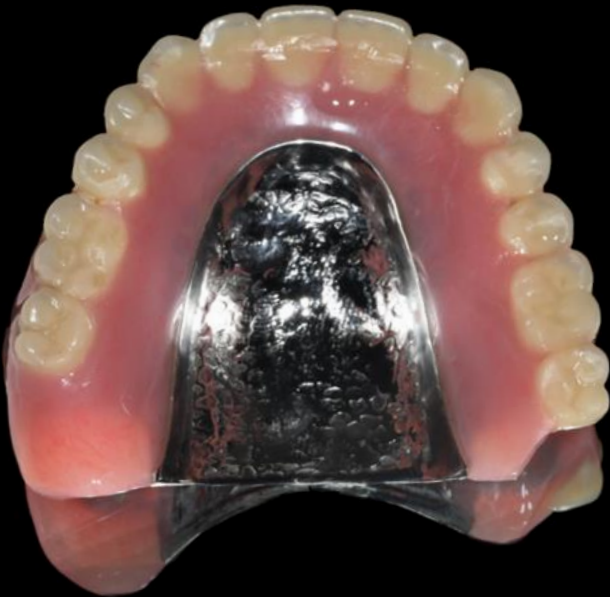Full mouth rehabilitation with Denture duplication



#20 Pre-op

Similar case

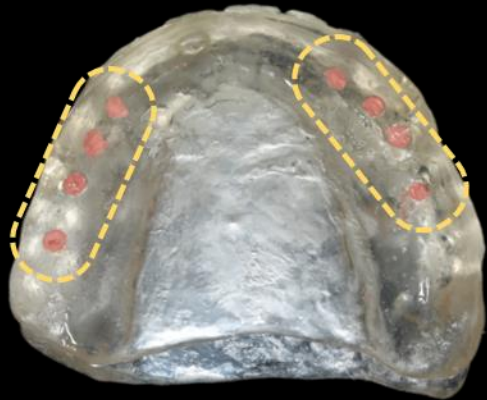
Full mouth rehabilitation with Denture duplication



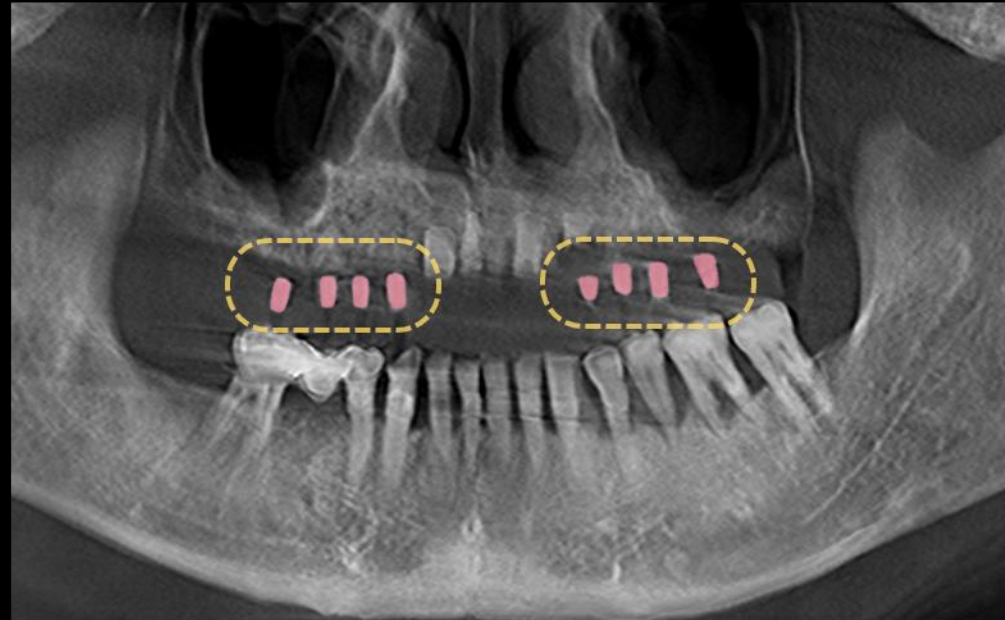
Denture duplication & Clear acrylic radiographic guide

Similar case

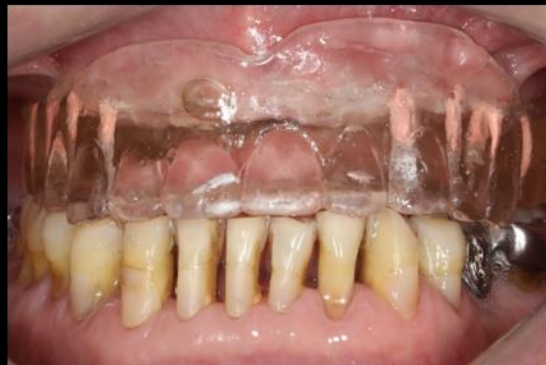Full mouth rehabilitation with Denture duplication



GP Cone marking

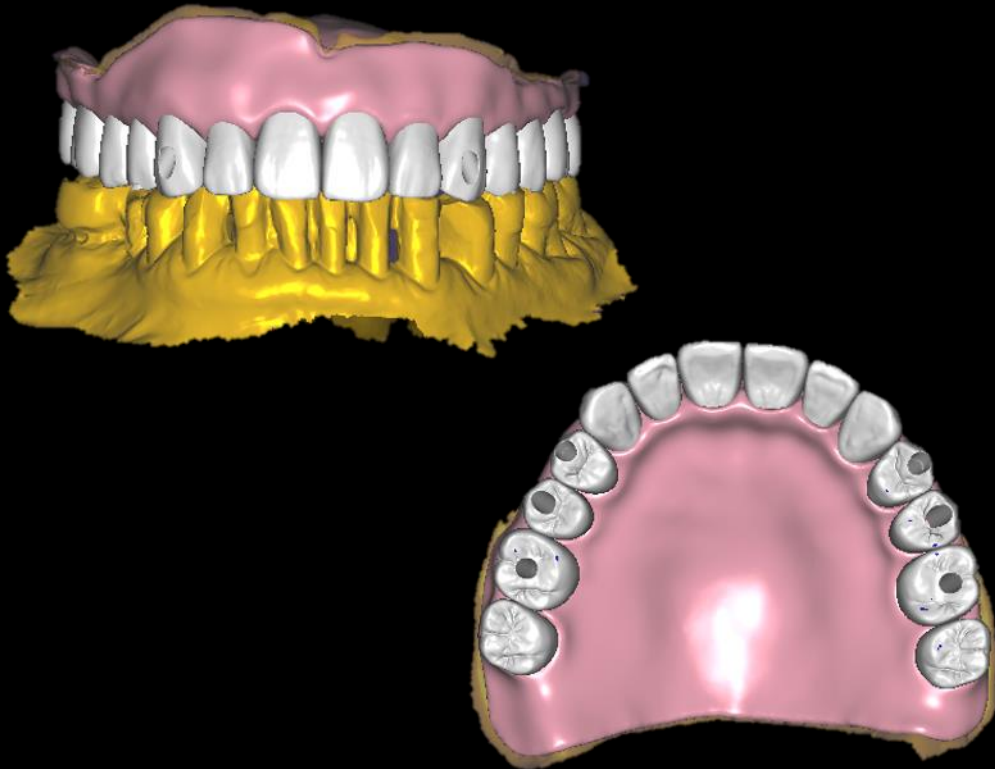


CT image with Radiographic Guide

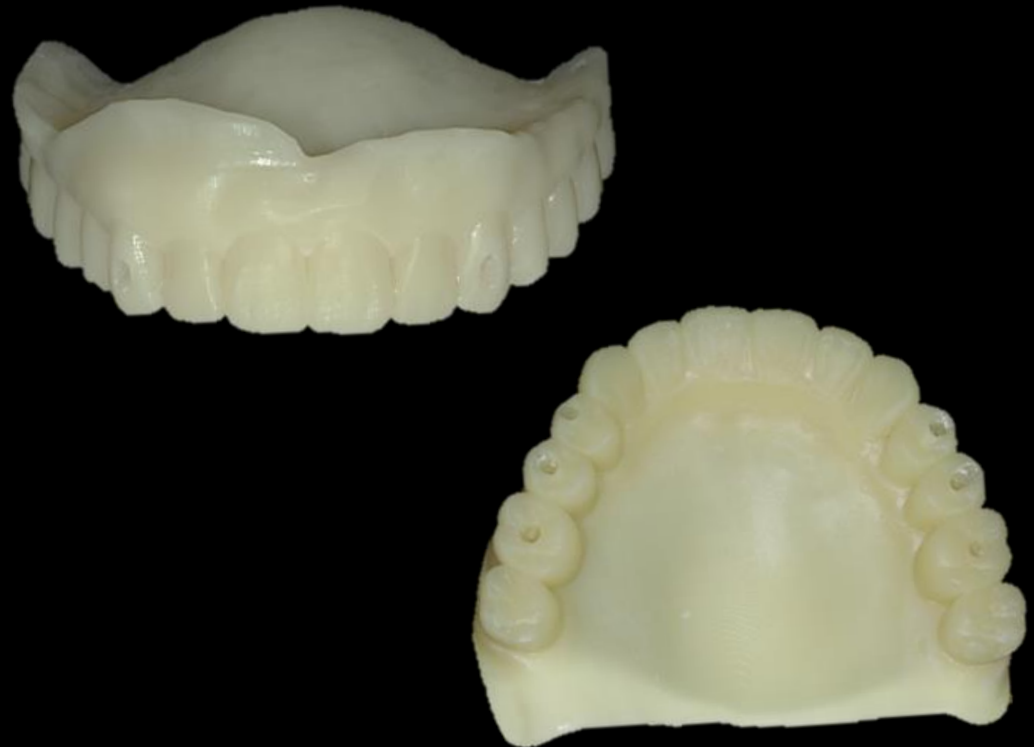

Similar case

Full mouth rehabilitation with Denture duplication



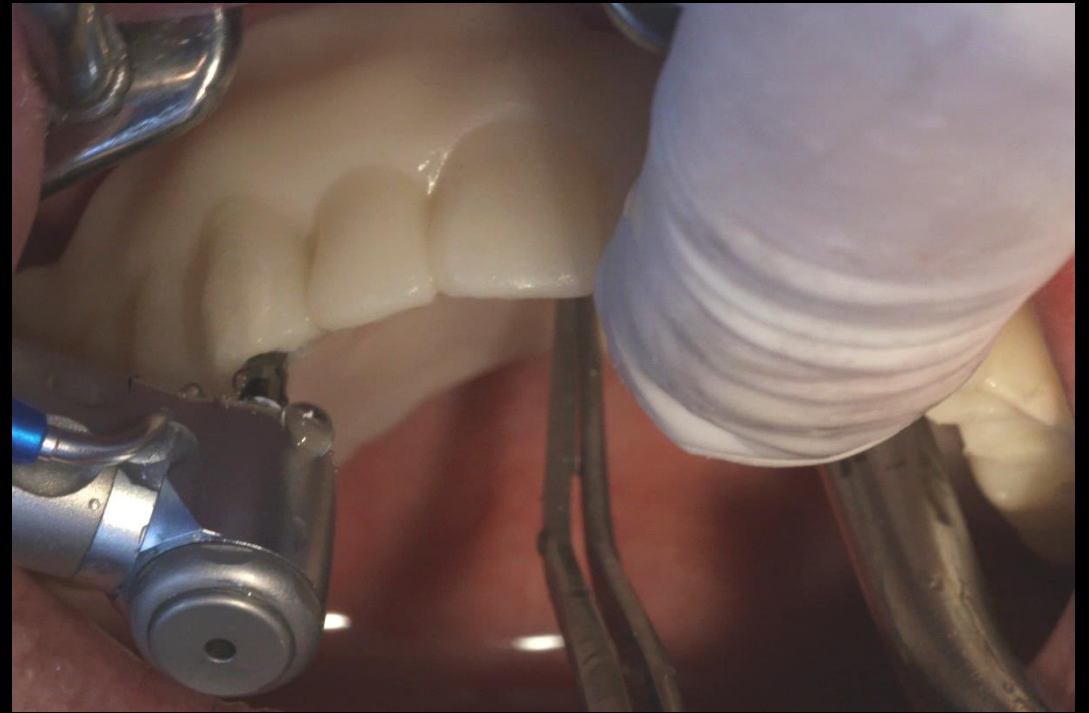
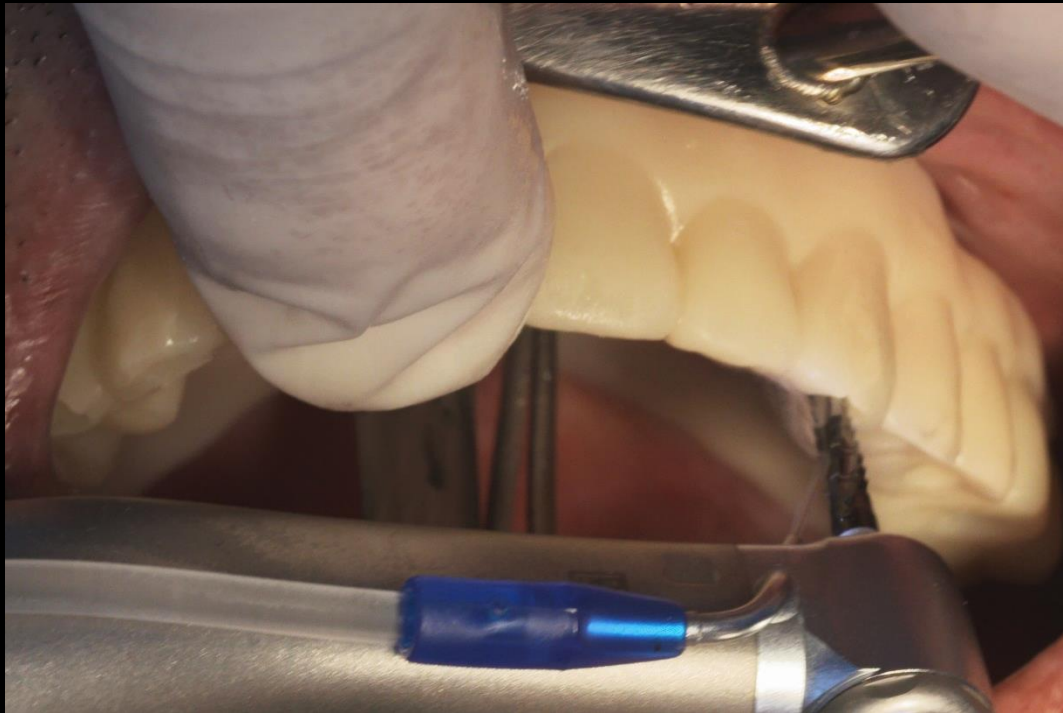Temporary Denture design



3D Printing denture

Similar case

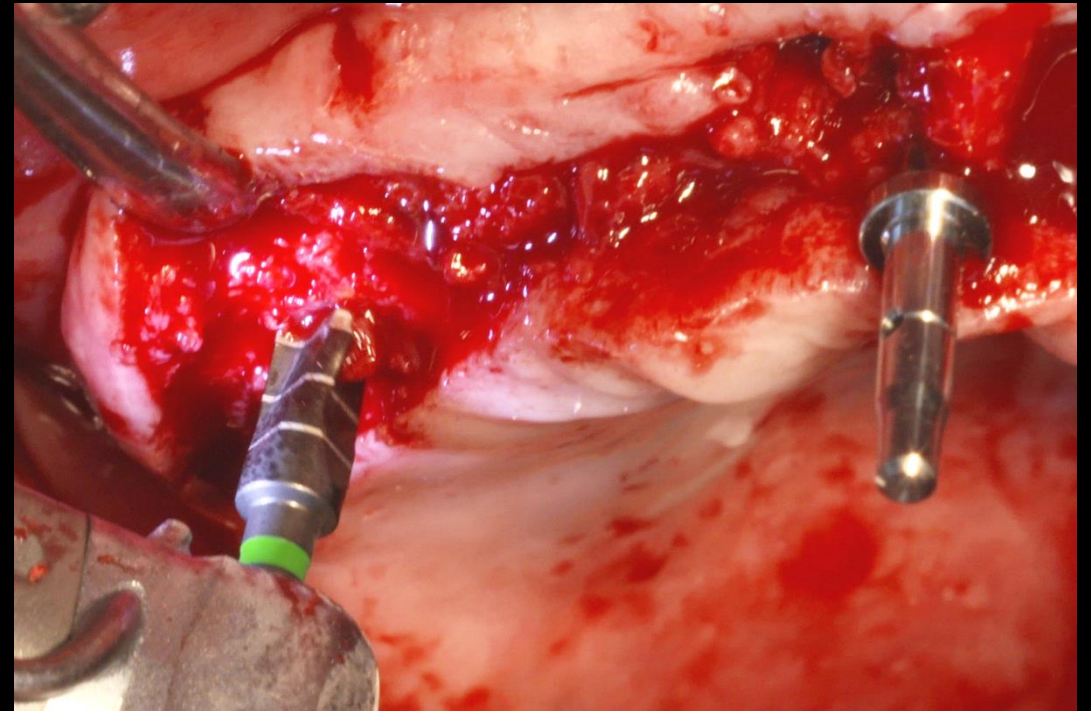
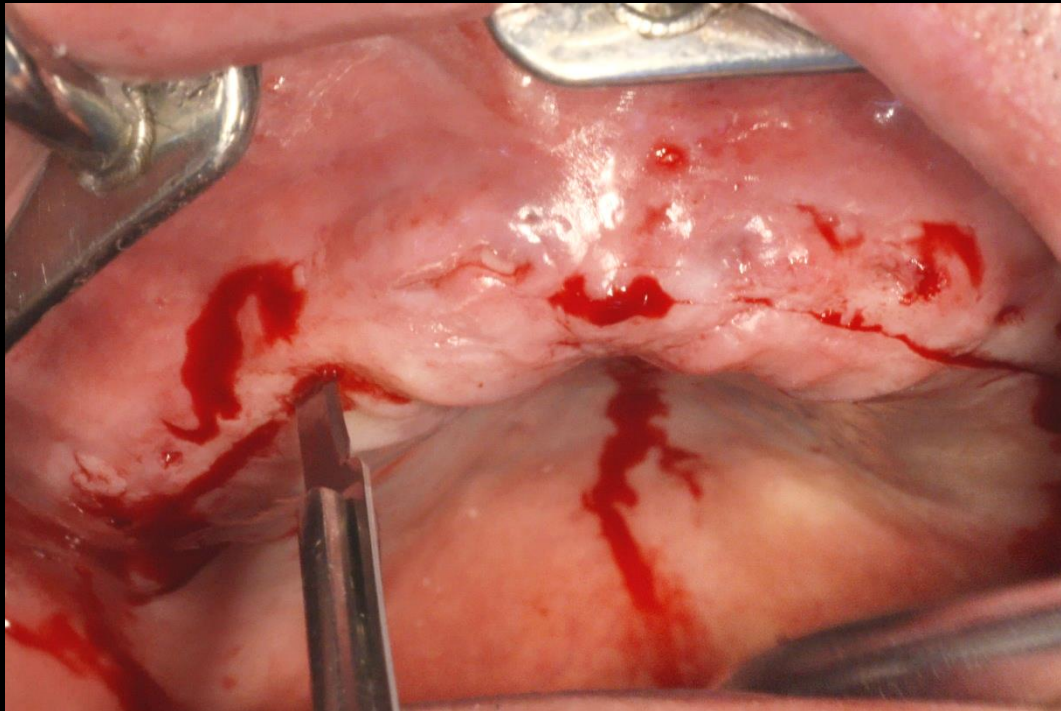
Full mouth rehabilitation with Denture duplication



Surgery

Similar case

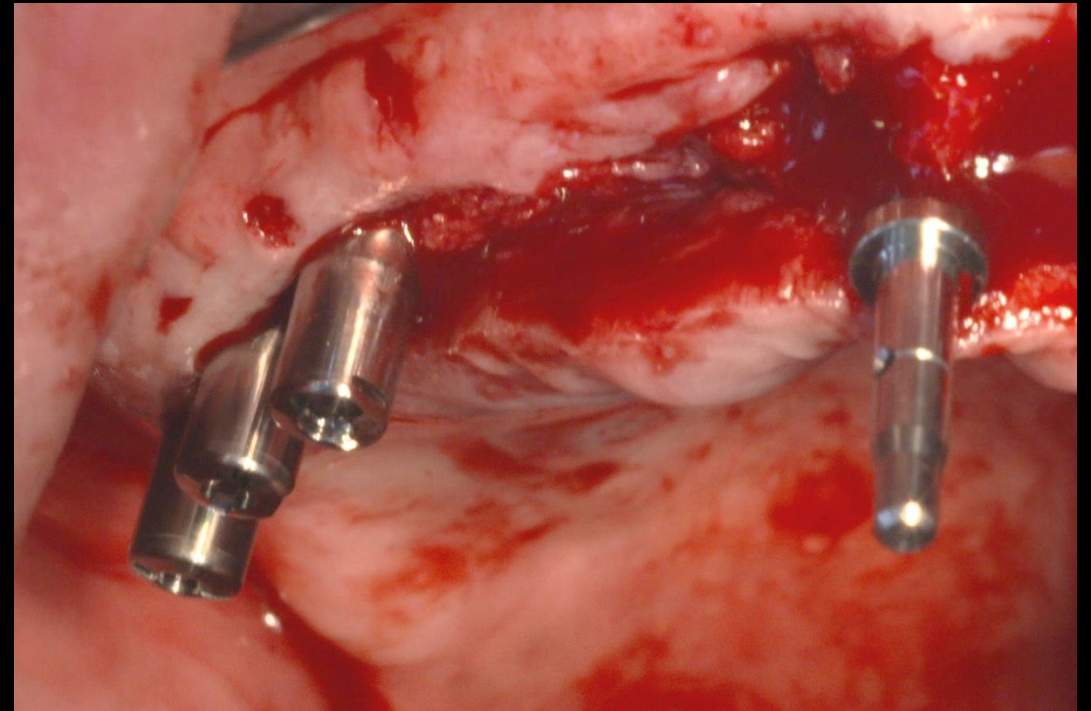
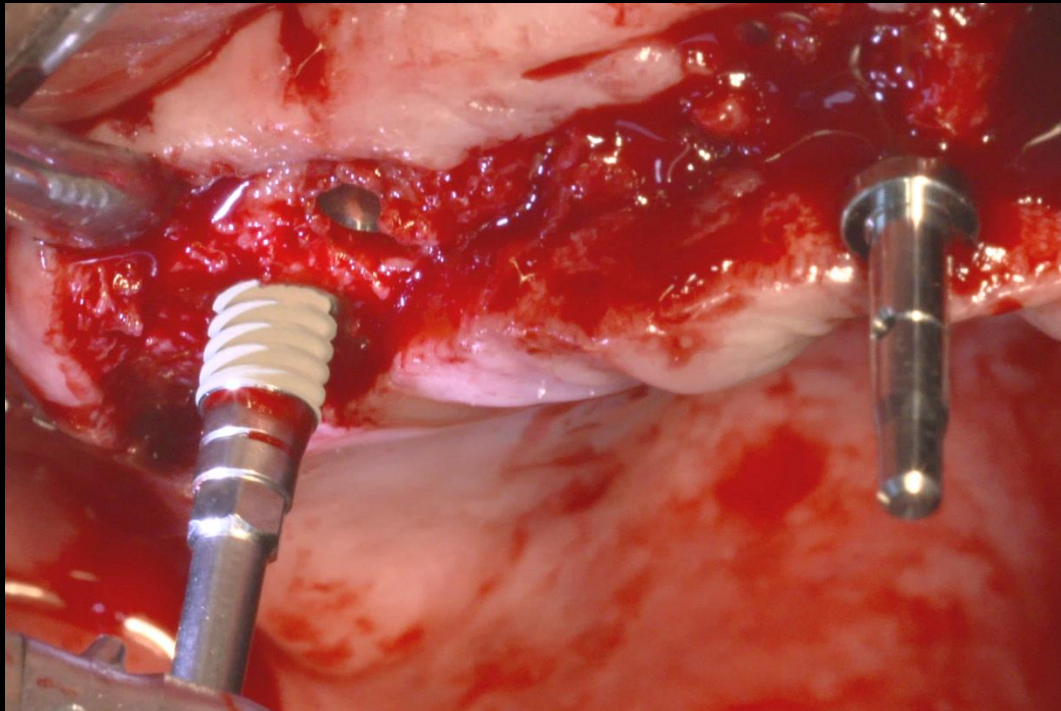
Full mouth rehabilitation with Denture duplication



Surgery

Similar case

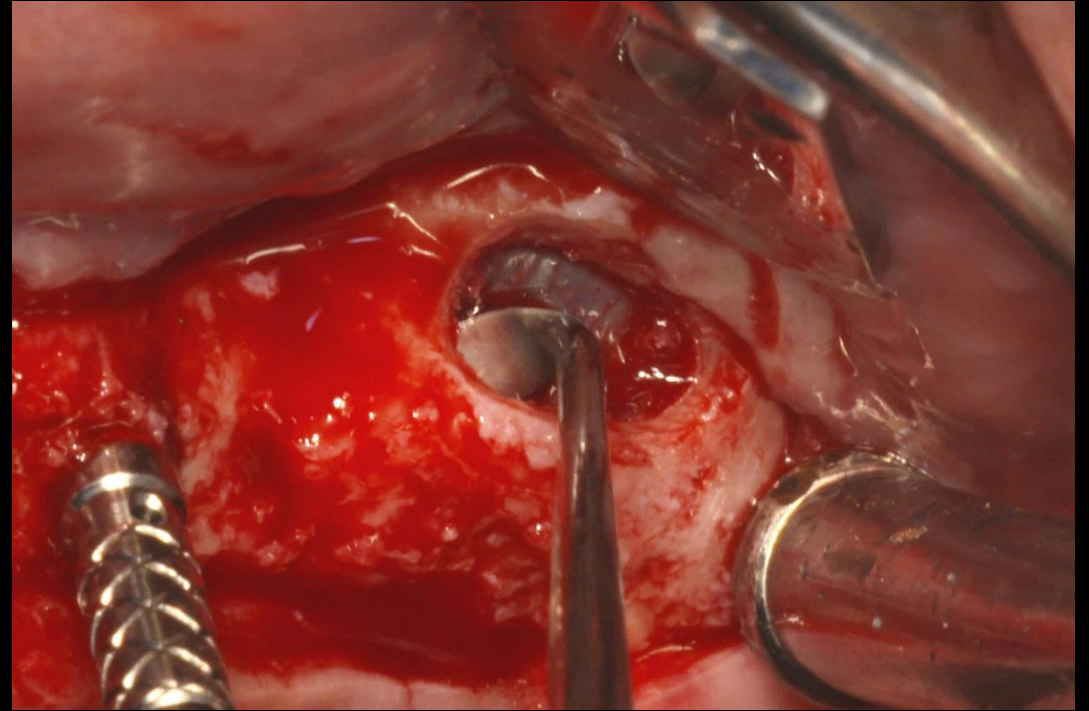
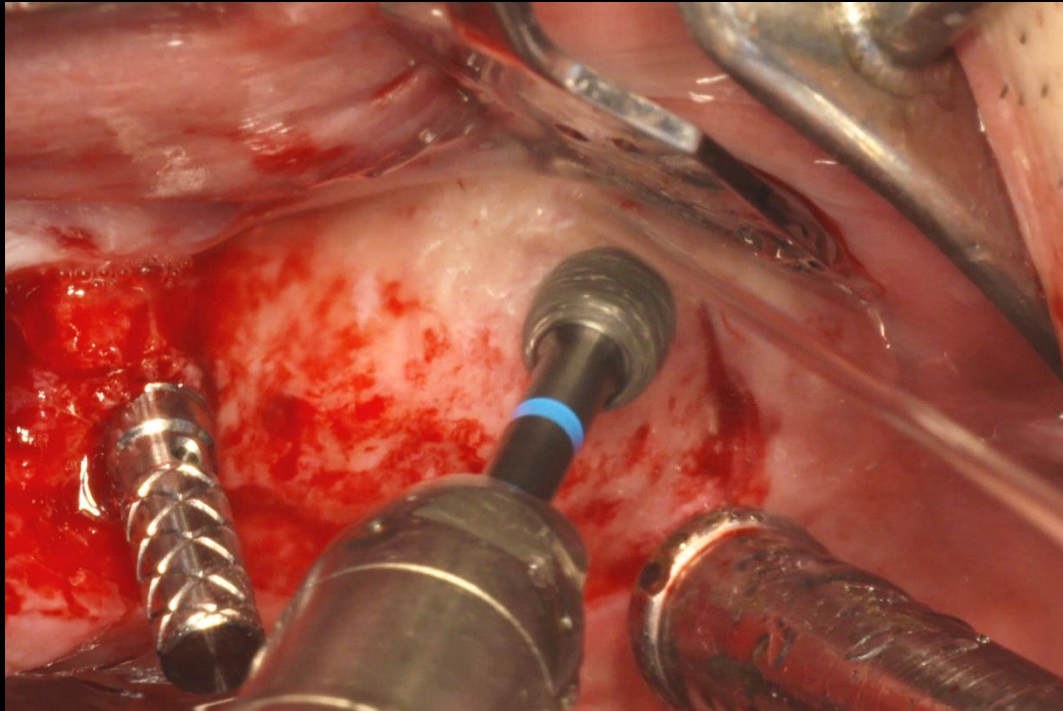
Full mouth rehabilitation with Denture duplication



Surgery

Similar case

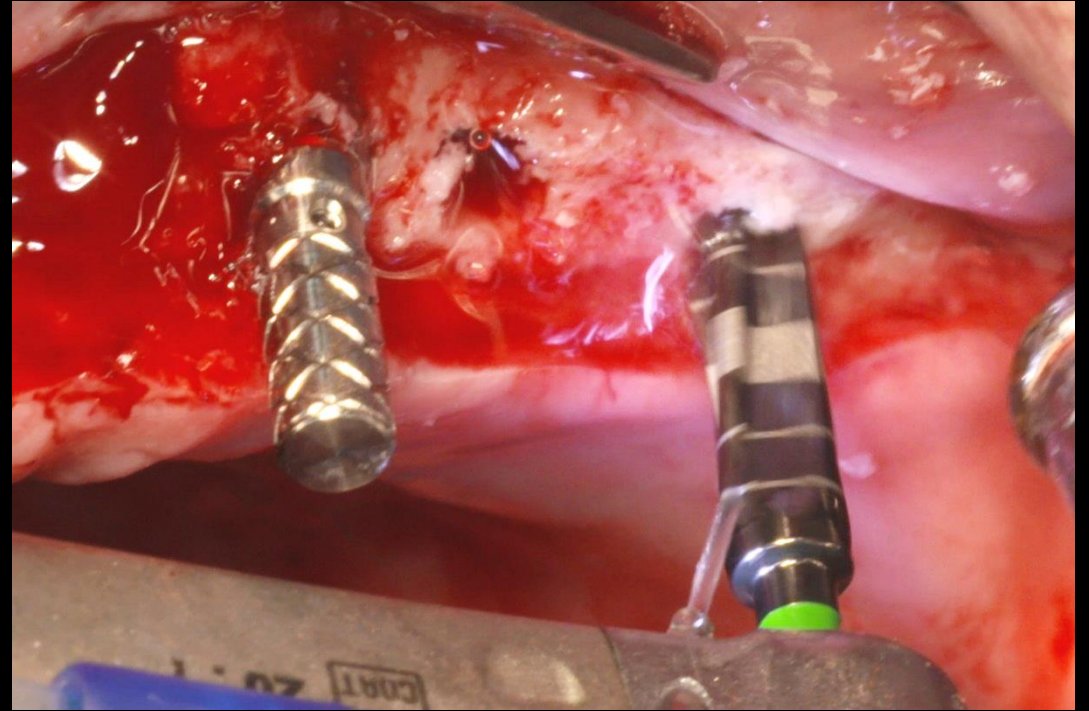
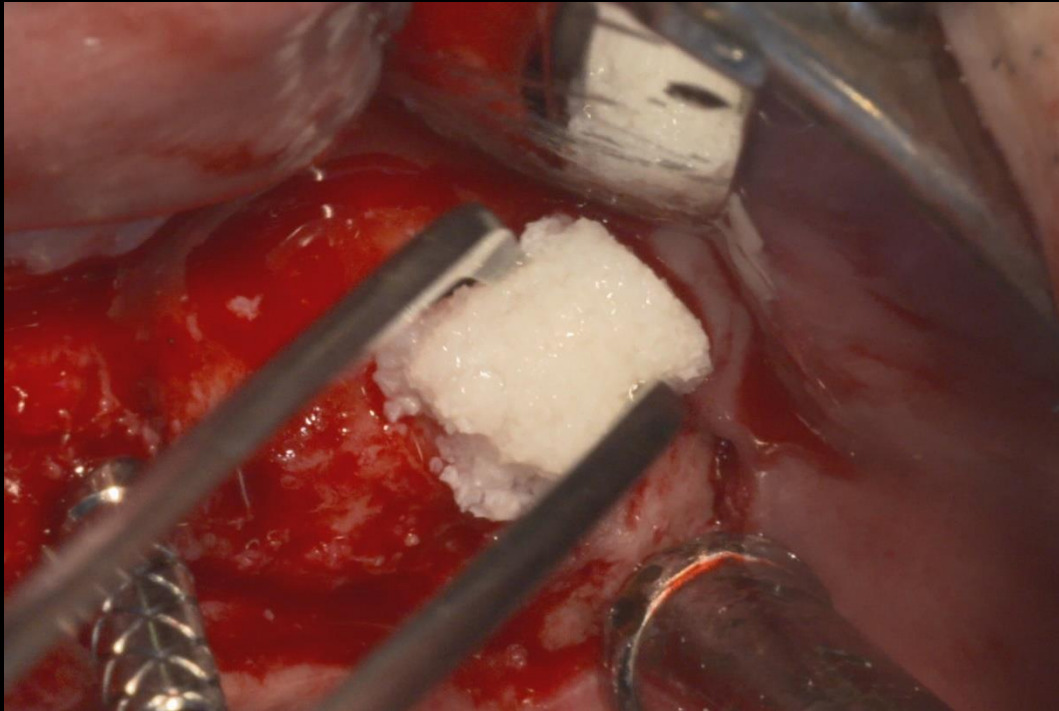
Full mouth rehabilitation with Denture duplication



Surgery

Similar case

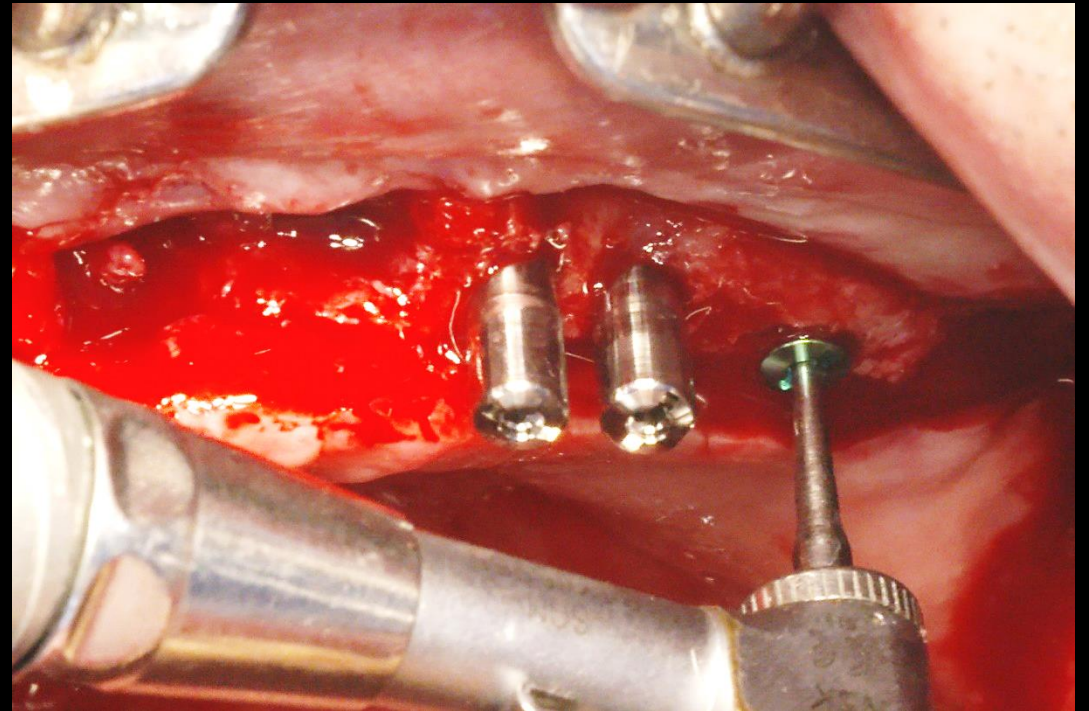
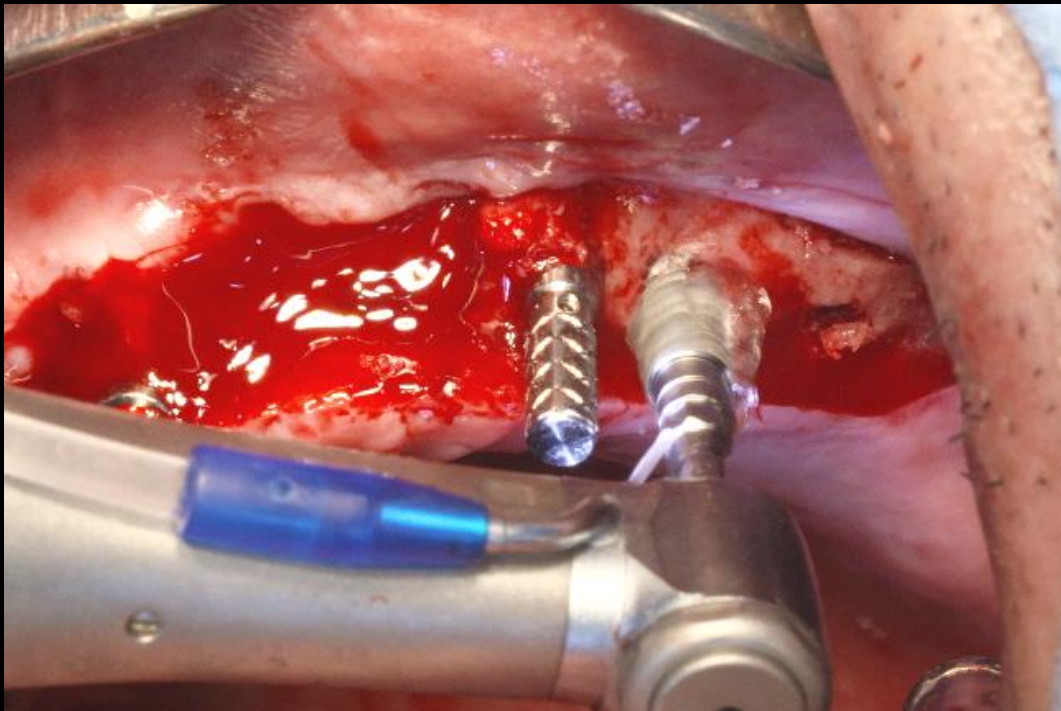
Full mouth rehabilitation with Denture duplication



Surgery

Similar case

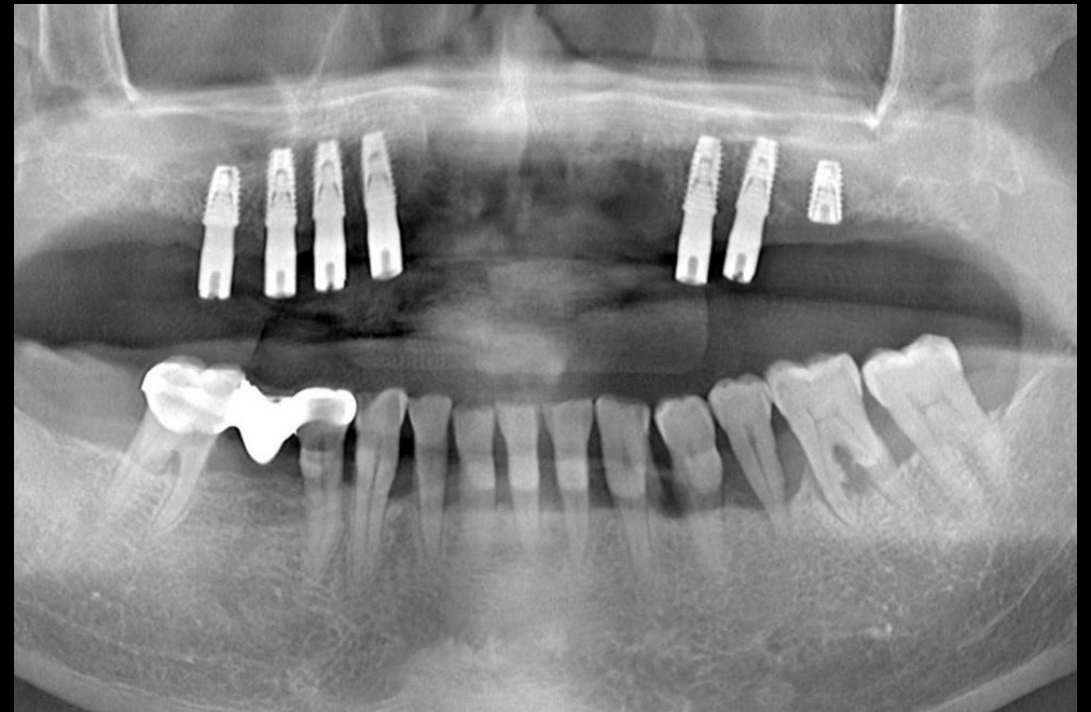
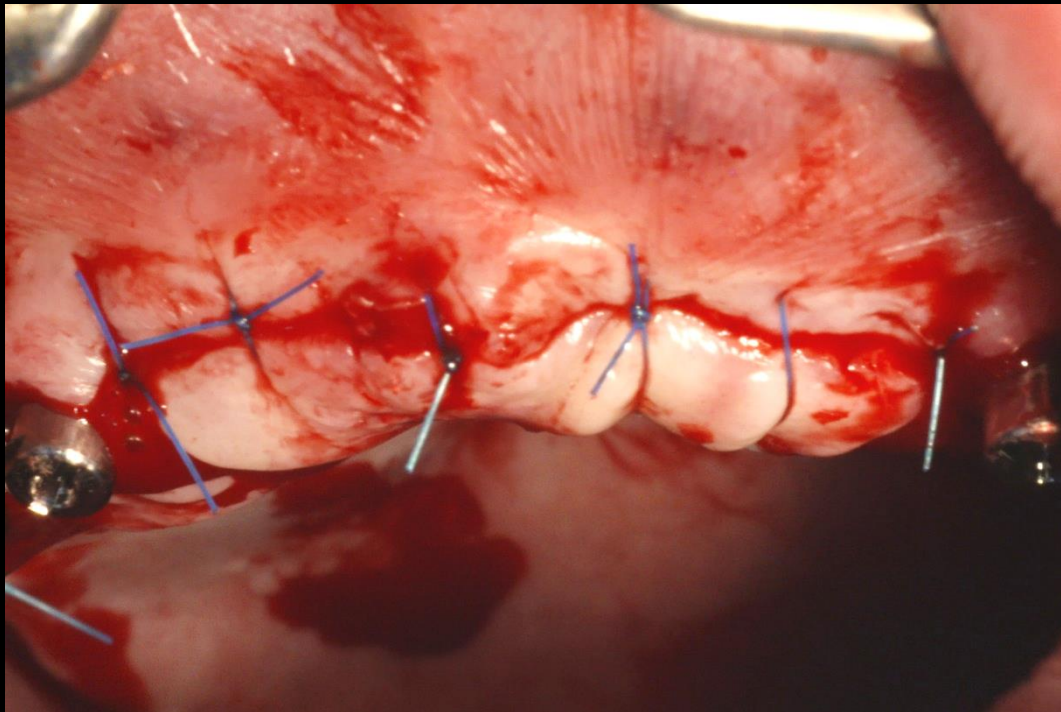
Full mouth rehabilitation with Denture duplication



Surgery

Similar case

Full mouth rehabilitation with Denture duplication



Post-op

Similar case

Full mouth rehabilitation with Denture duplication

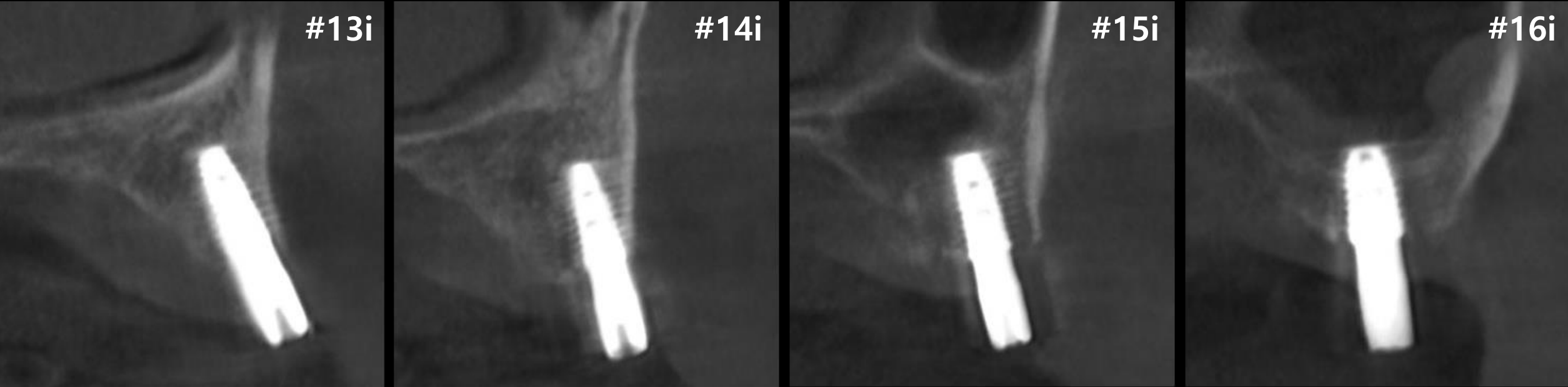
#13i

#14i

#15i

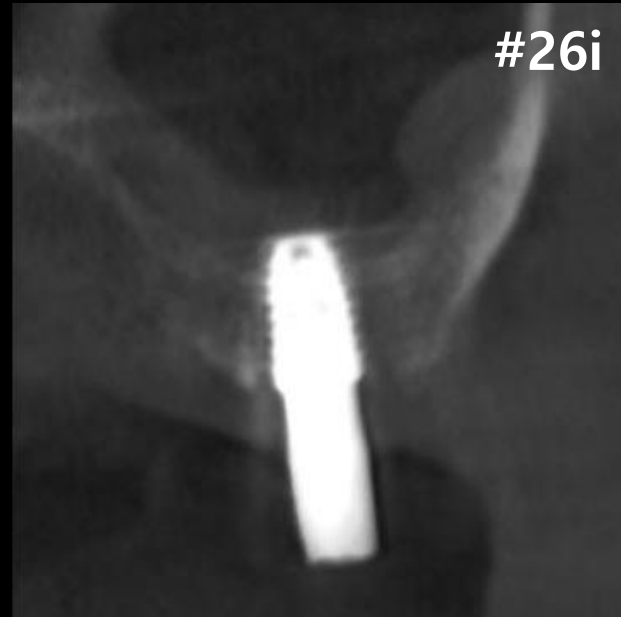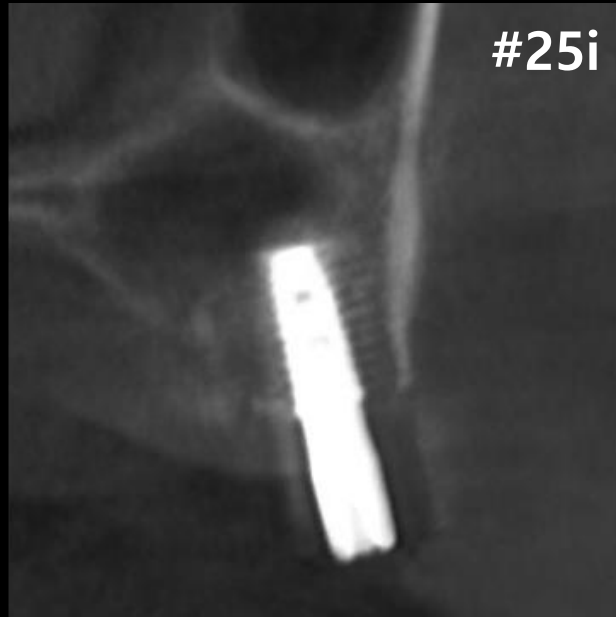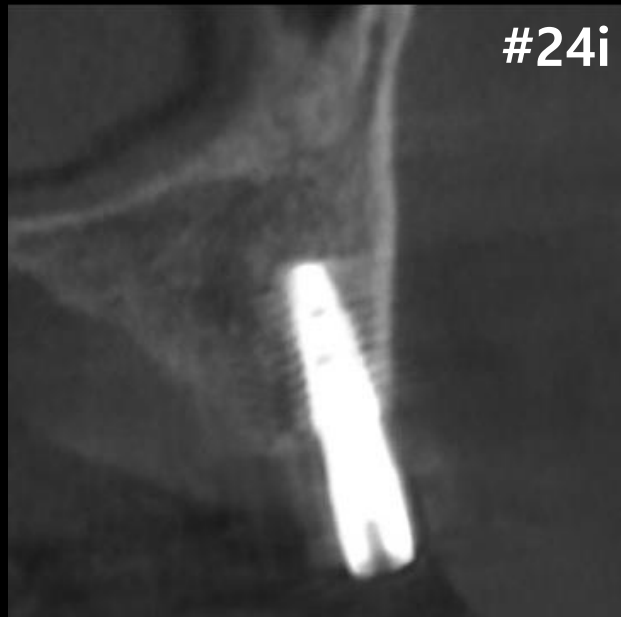#16i

#10 Post-op



Similar case

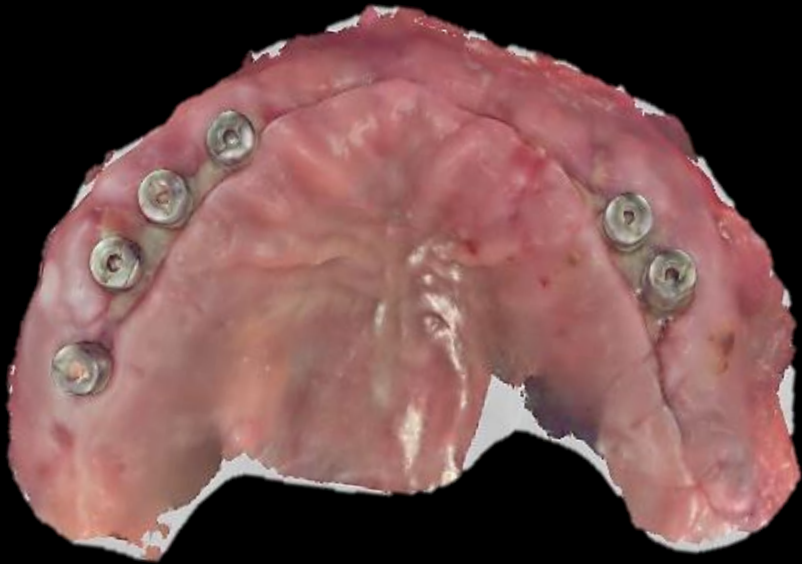Full mouth rehabilitation with Denture duplication



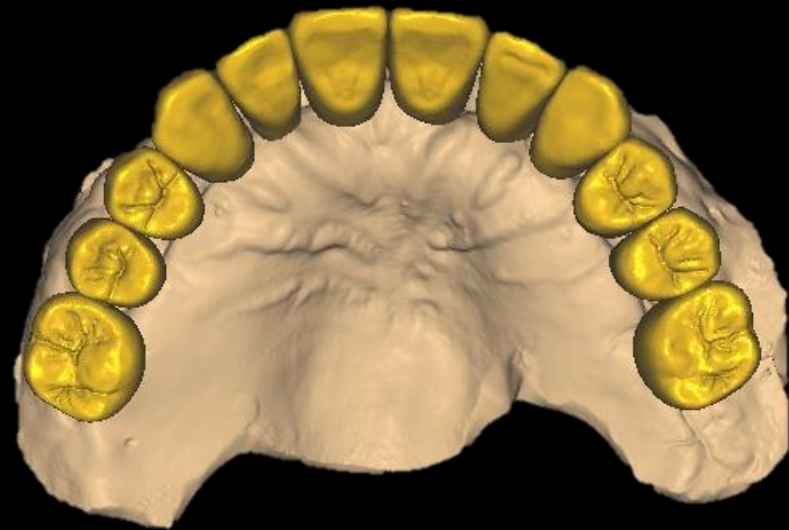
#20 Post-op

Similar case

Full mouth rehabilitation with Denture duplication



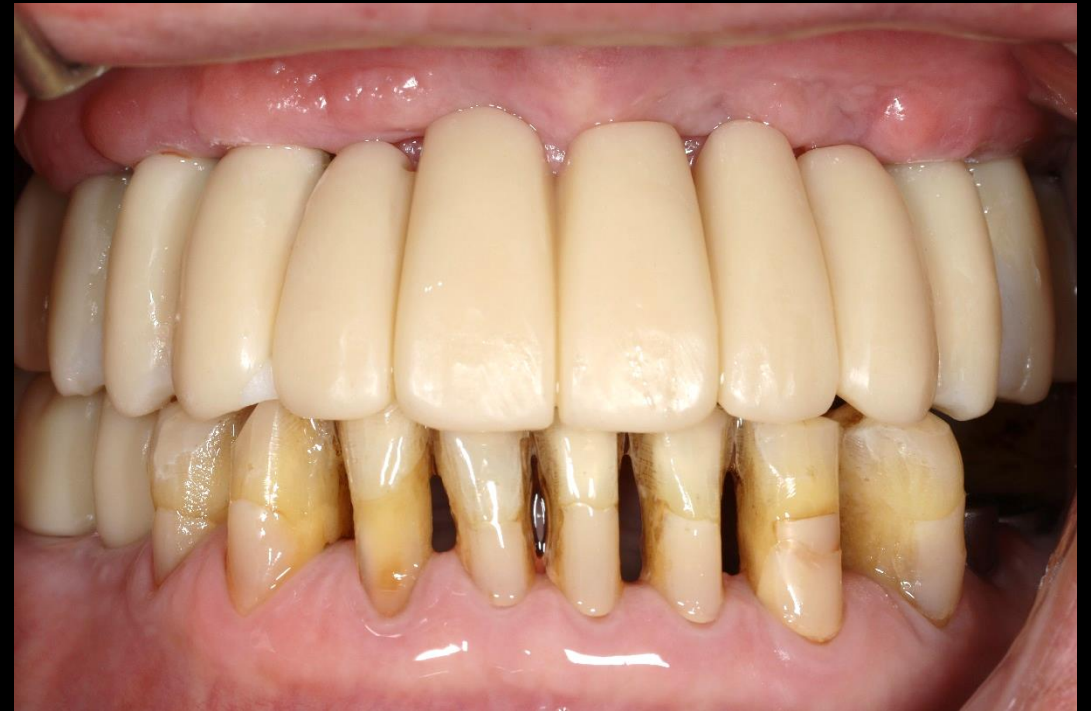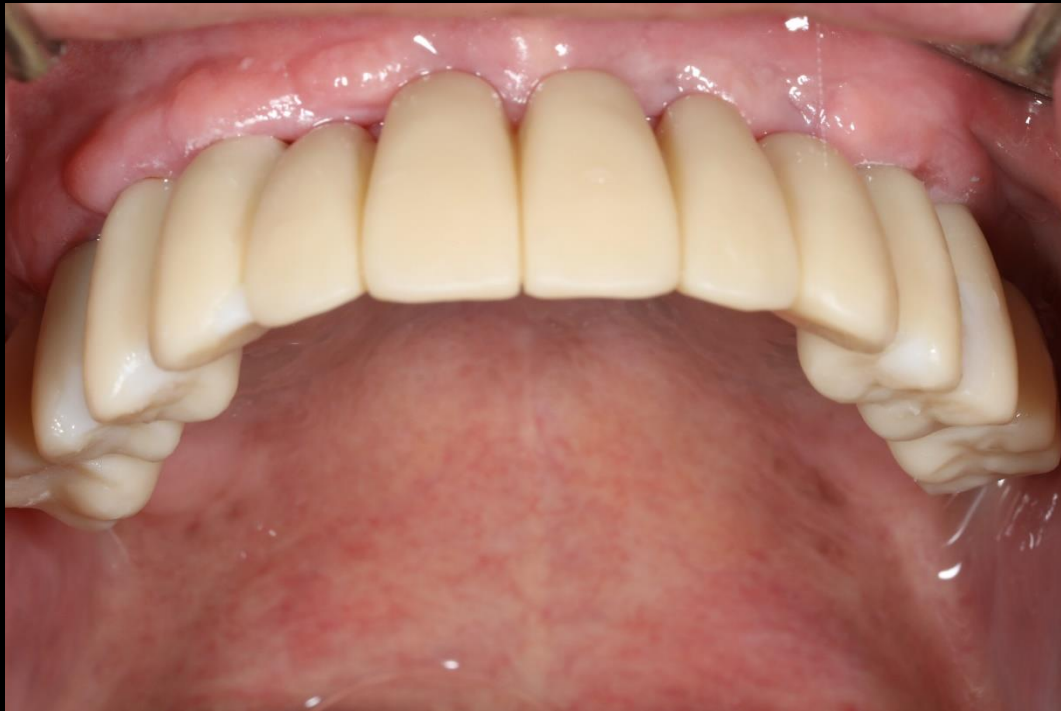Intraoral Scanning



CAD Design

Similar case

Full mouth rehabilitation with Denture duplication



Provisional restoration