



LIVE

Surgey

Prof. Soo-Hwan Byun

2021.06.11 (FRI.)



[Case Preview]

bright implant placement at anterior narrow ridge
by using Dentium digital guide system

Patient Information

Age : 76

Sex : Female

Chief Complaint

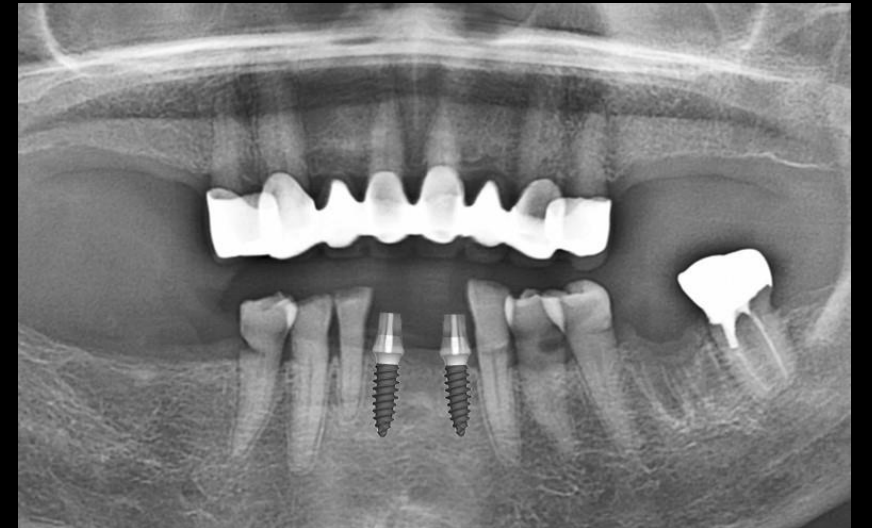
: I want to get implant treatment at anterior mandibular area

Past Dental History

: Maxillary Partial Denture → Surveyed crown

Past Medical History

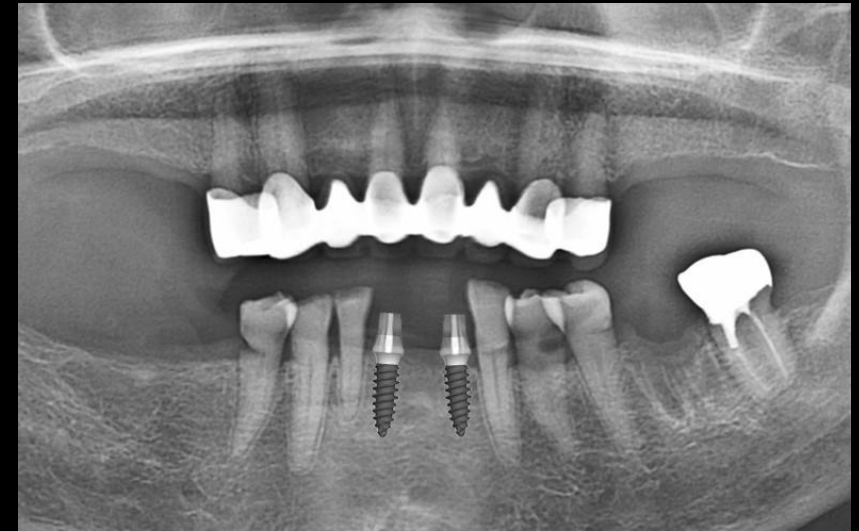
: Thyroid medication



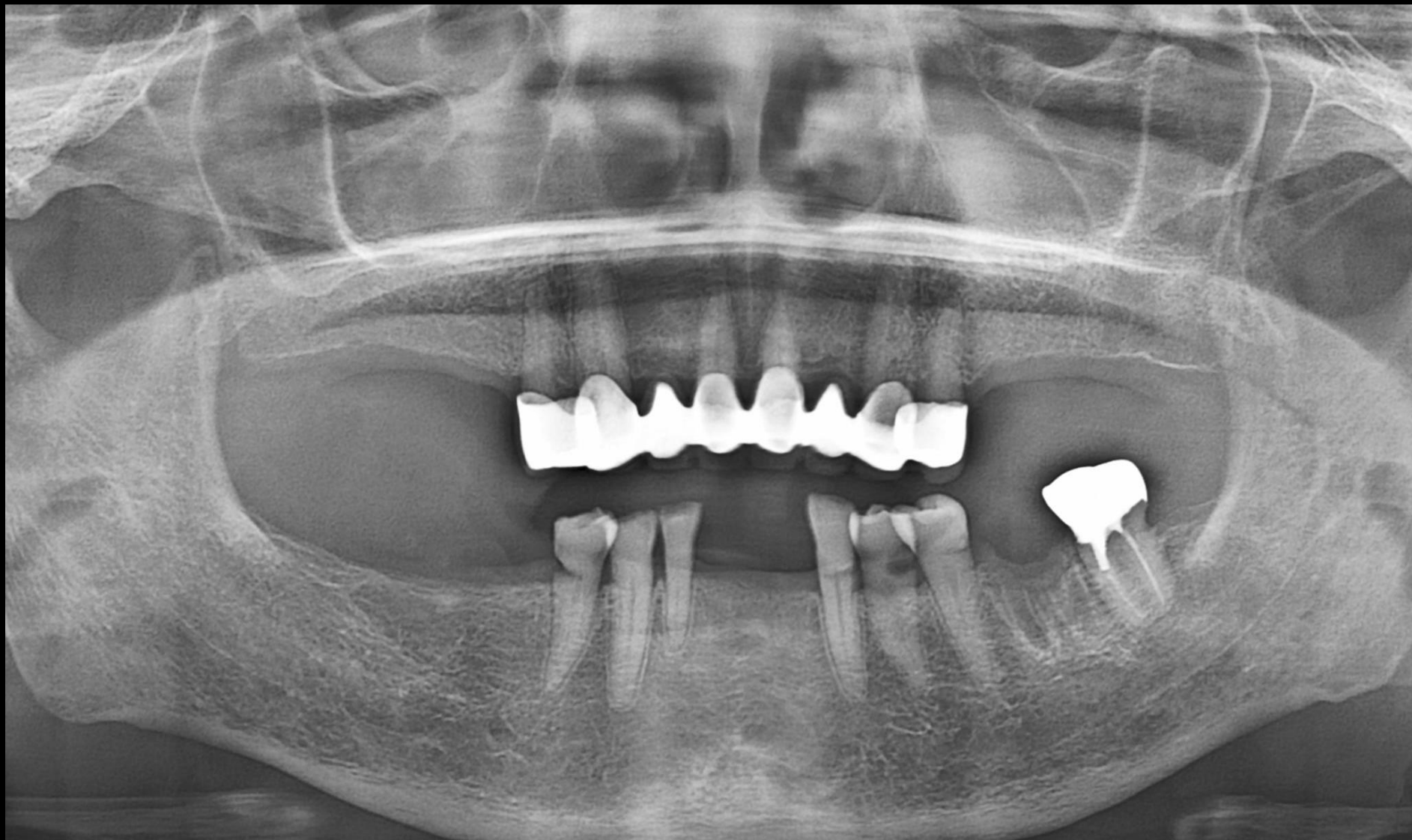
Today's Surgery Plan

#32, 41

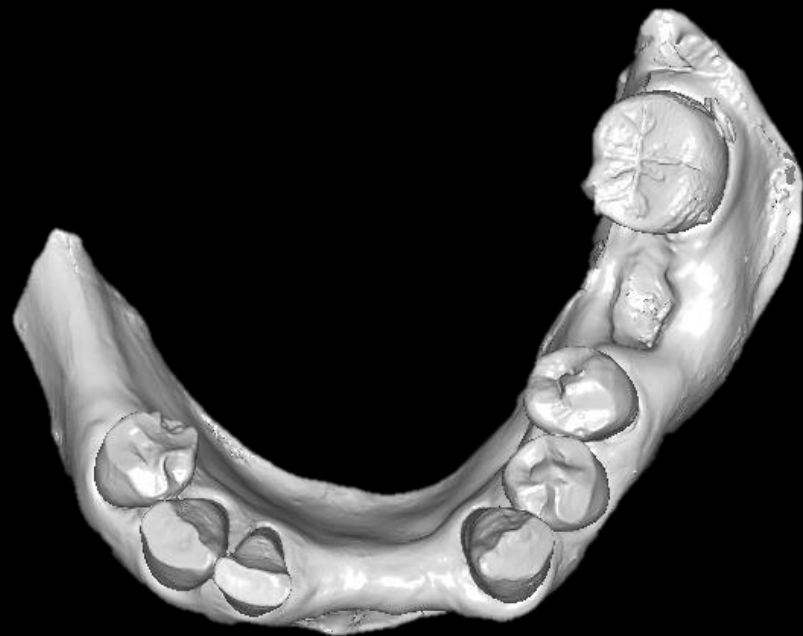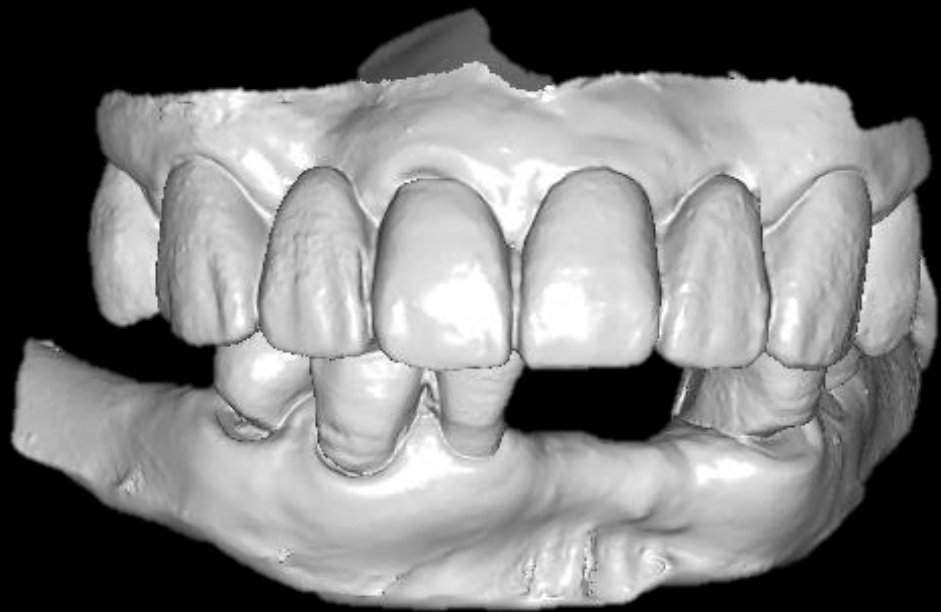- Implant placement by using Dentium digital guide system
(bright Tissue Level $\varnothing 3.0$ * 9mm)
- Simultaneous GBR



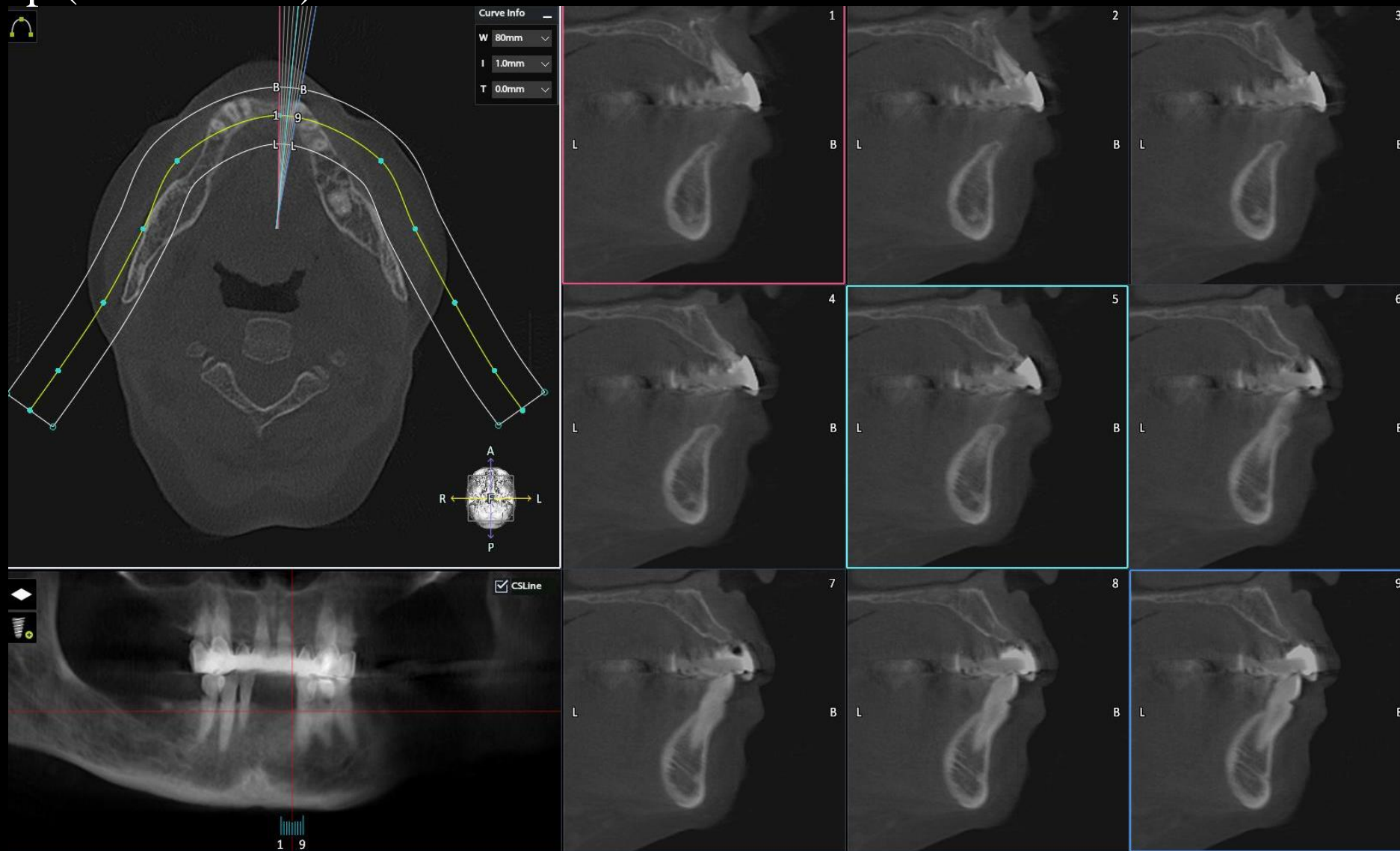
Oral exam (2021-05-11)



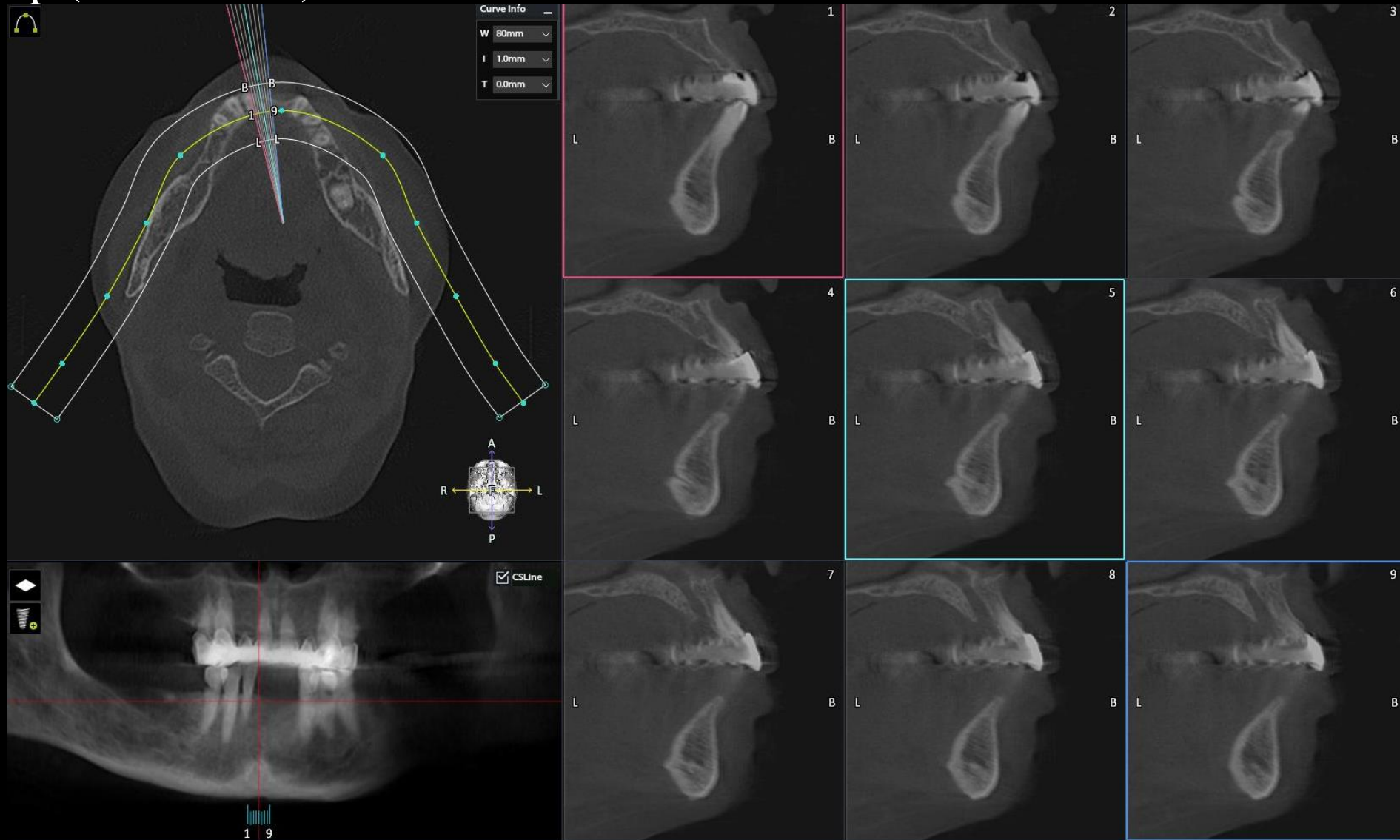
Intraoral Scanning



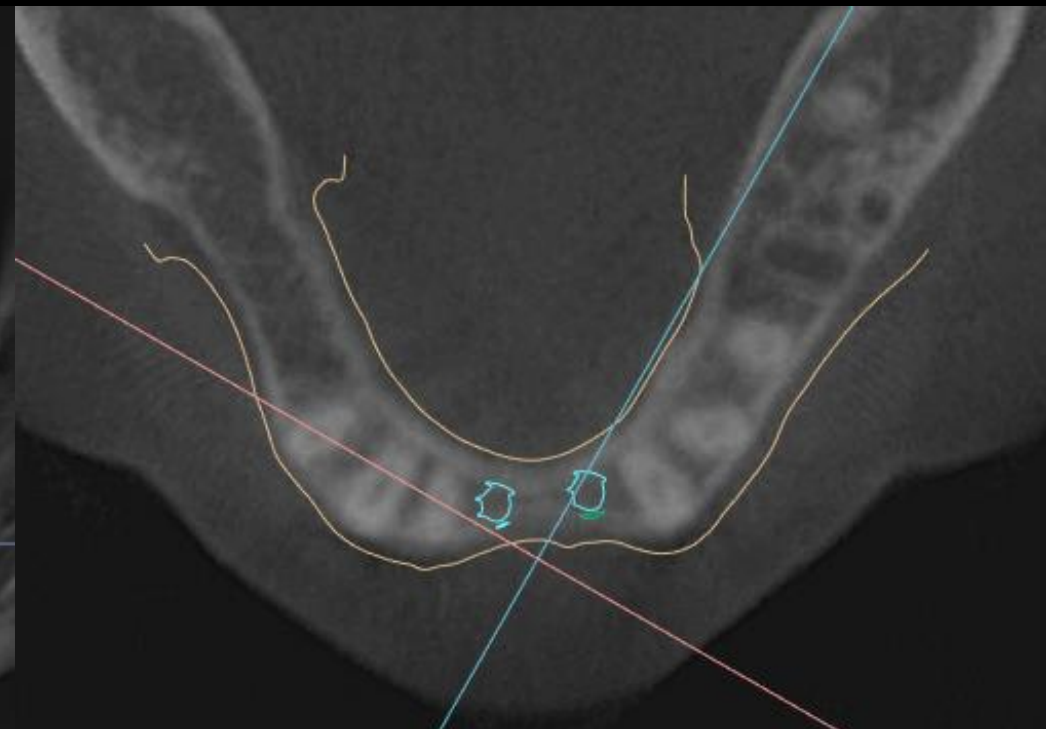
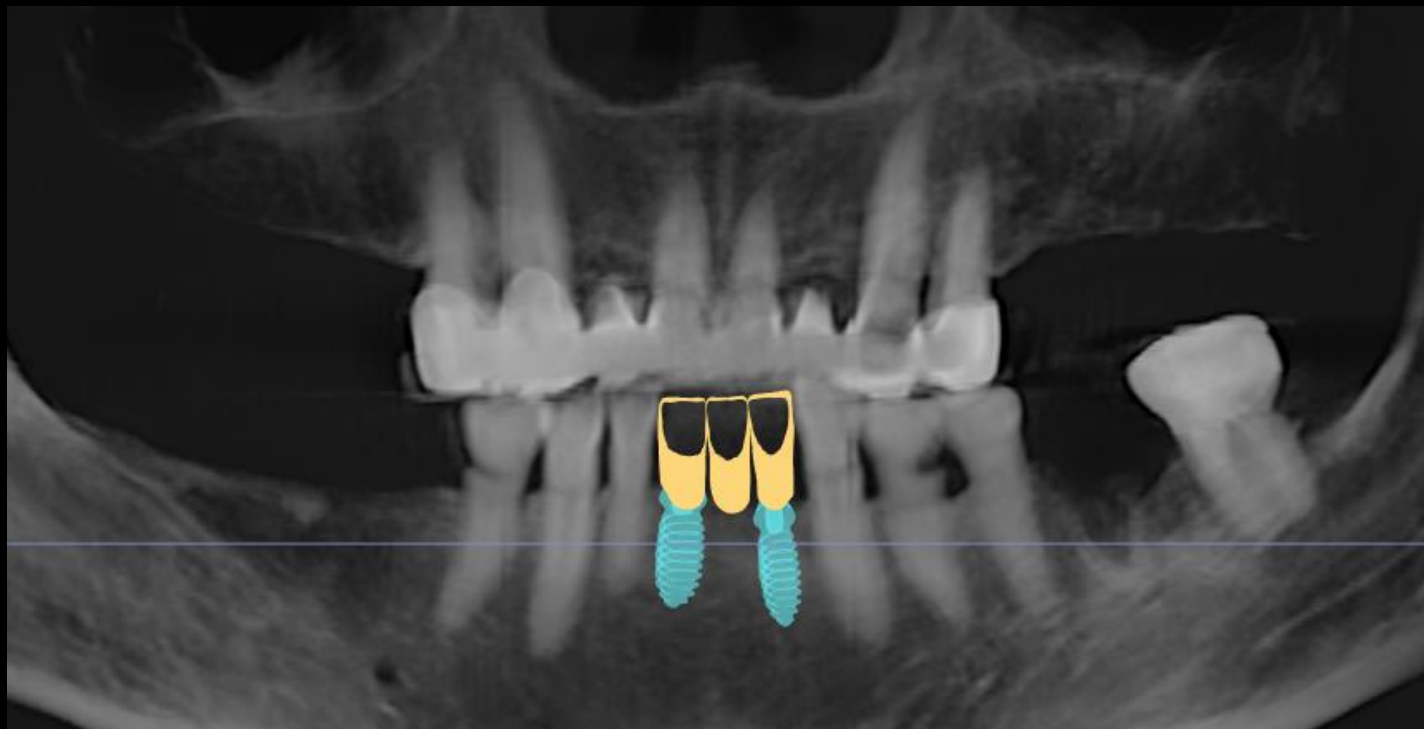#32 Pre-op (2021-05-11)



#41 Pre-op (2021-05-11)

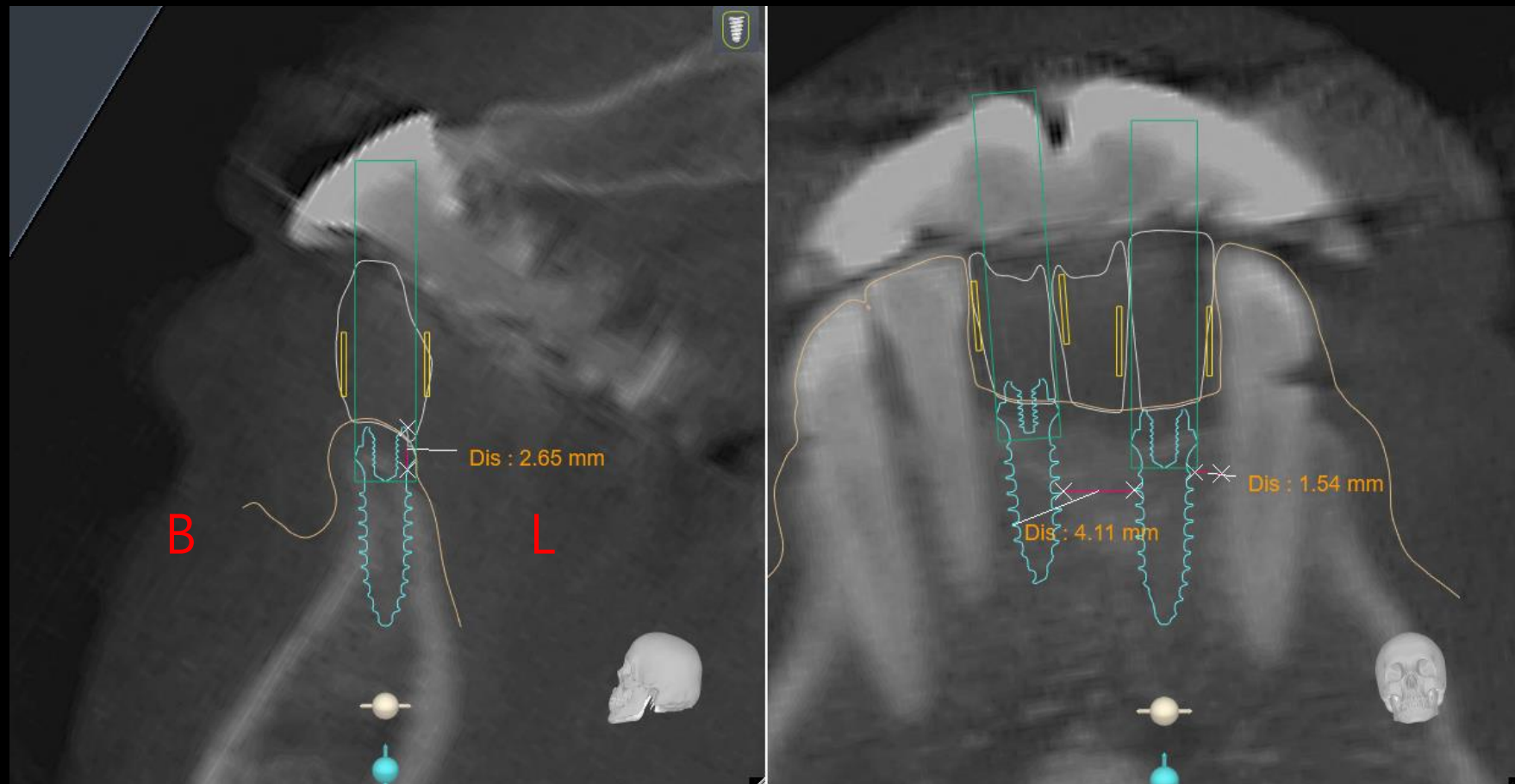


Digital Guide S/W (Implant Planning)



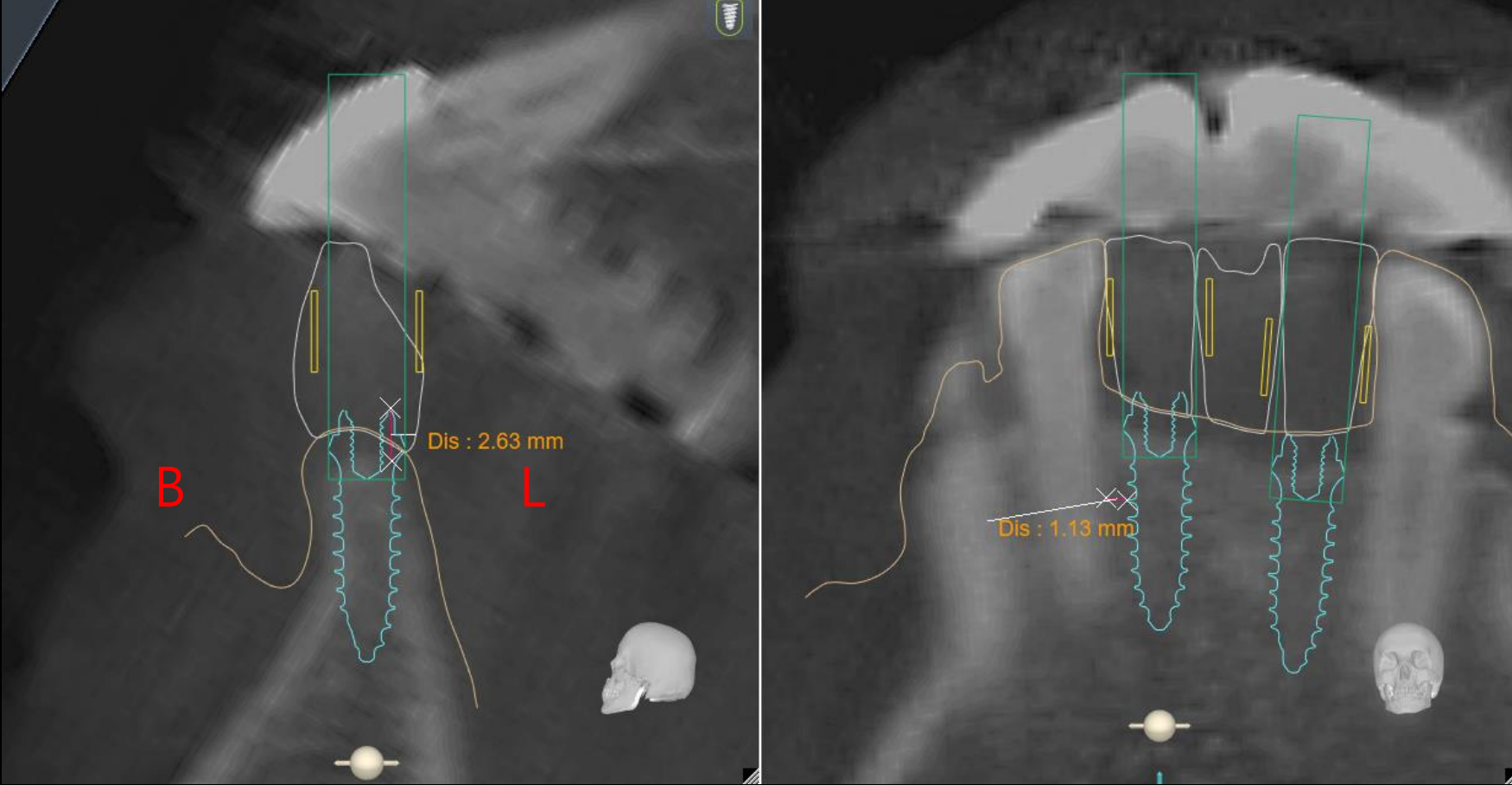
Digital Guide S/W (Implant Planning)

#32 (NTI383009)

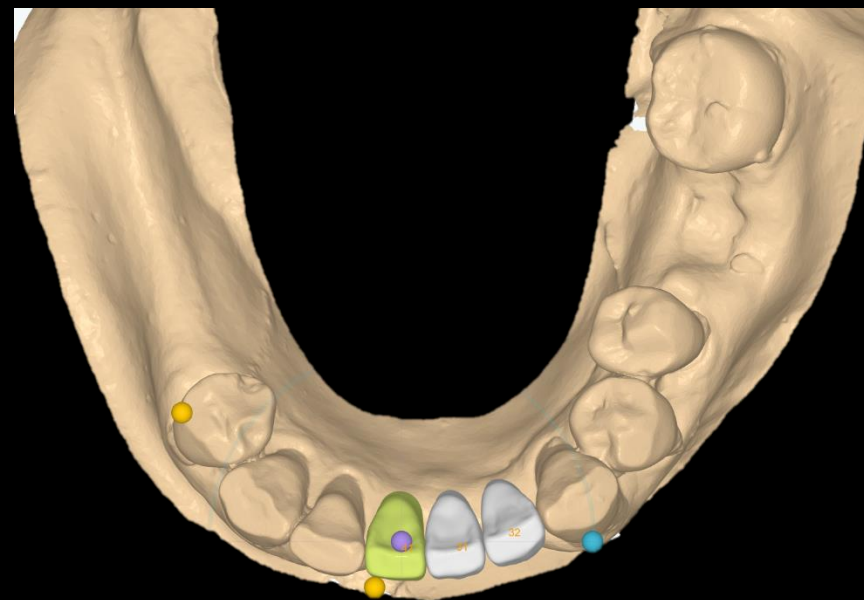
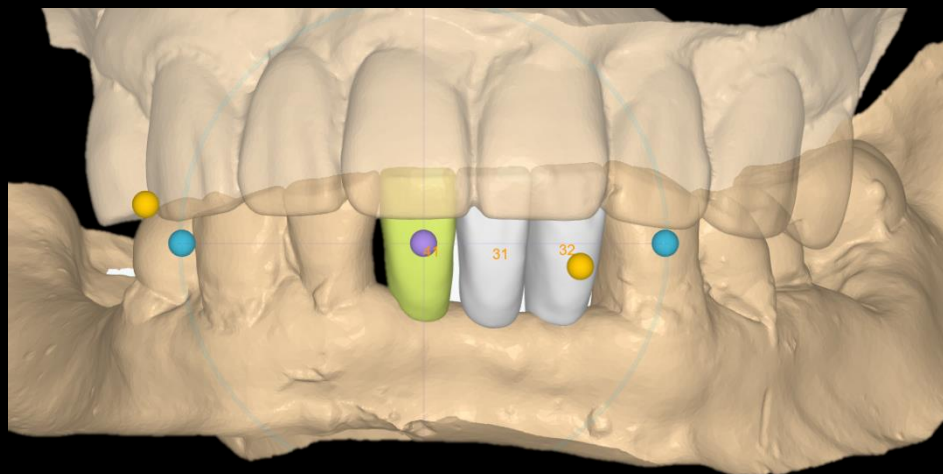


Digital Guide S/W (Implant Planning)

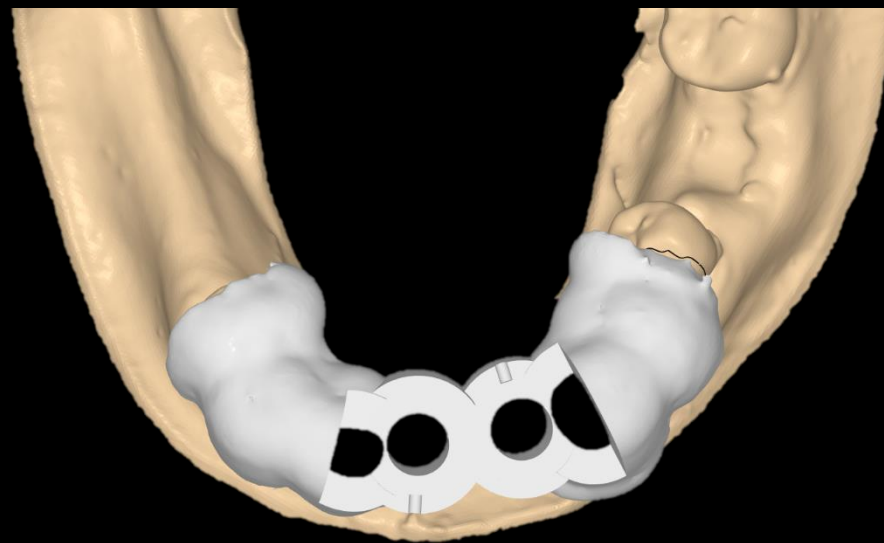
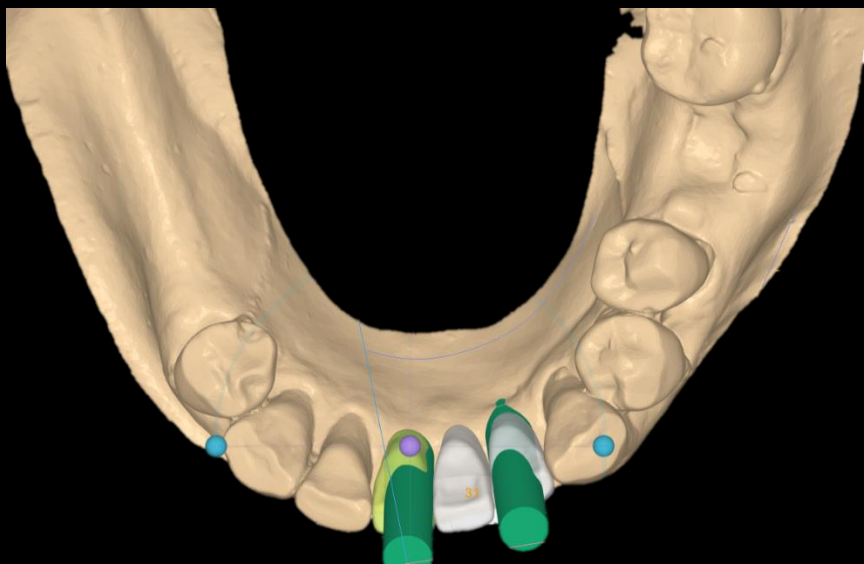
#41 (NTI383009)



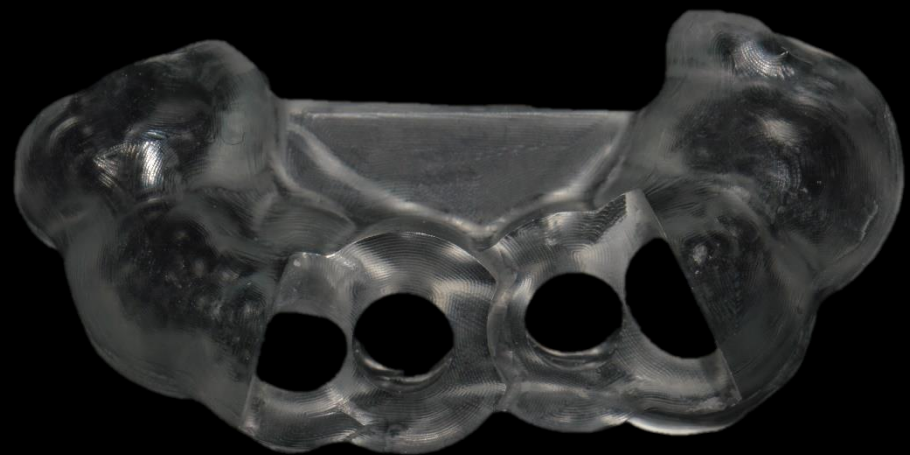
Digital Guide S/W (Virtual Set-up)



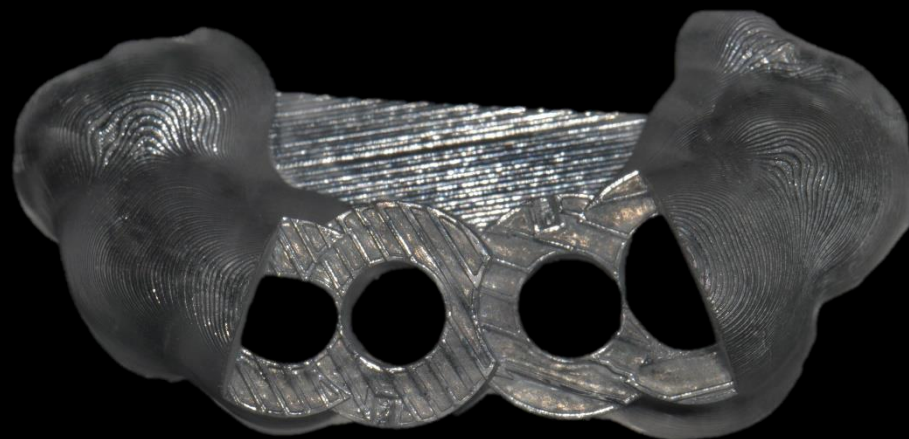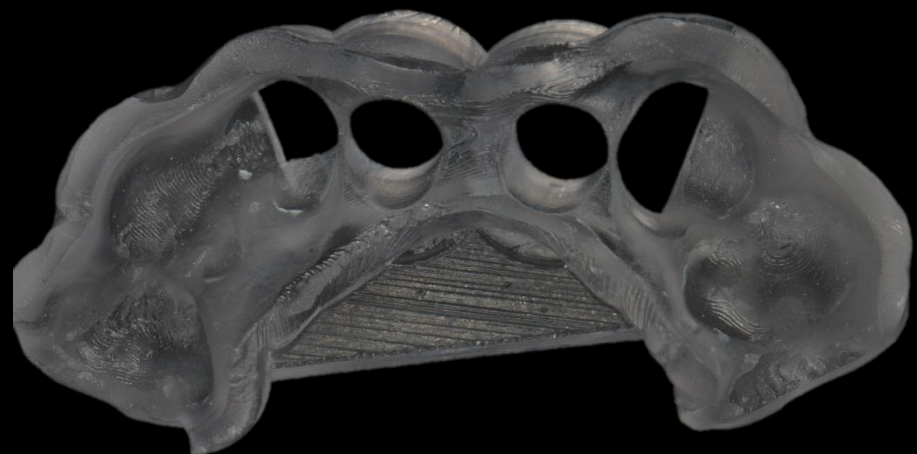Digital Guide S/W (Surgical Guide design)



Digital Guide (Milling)

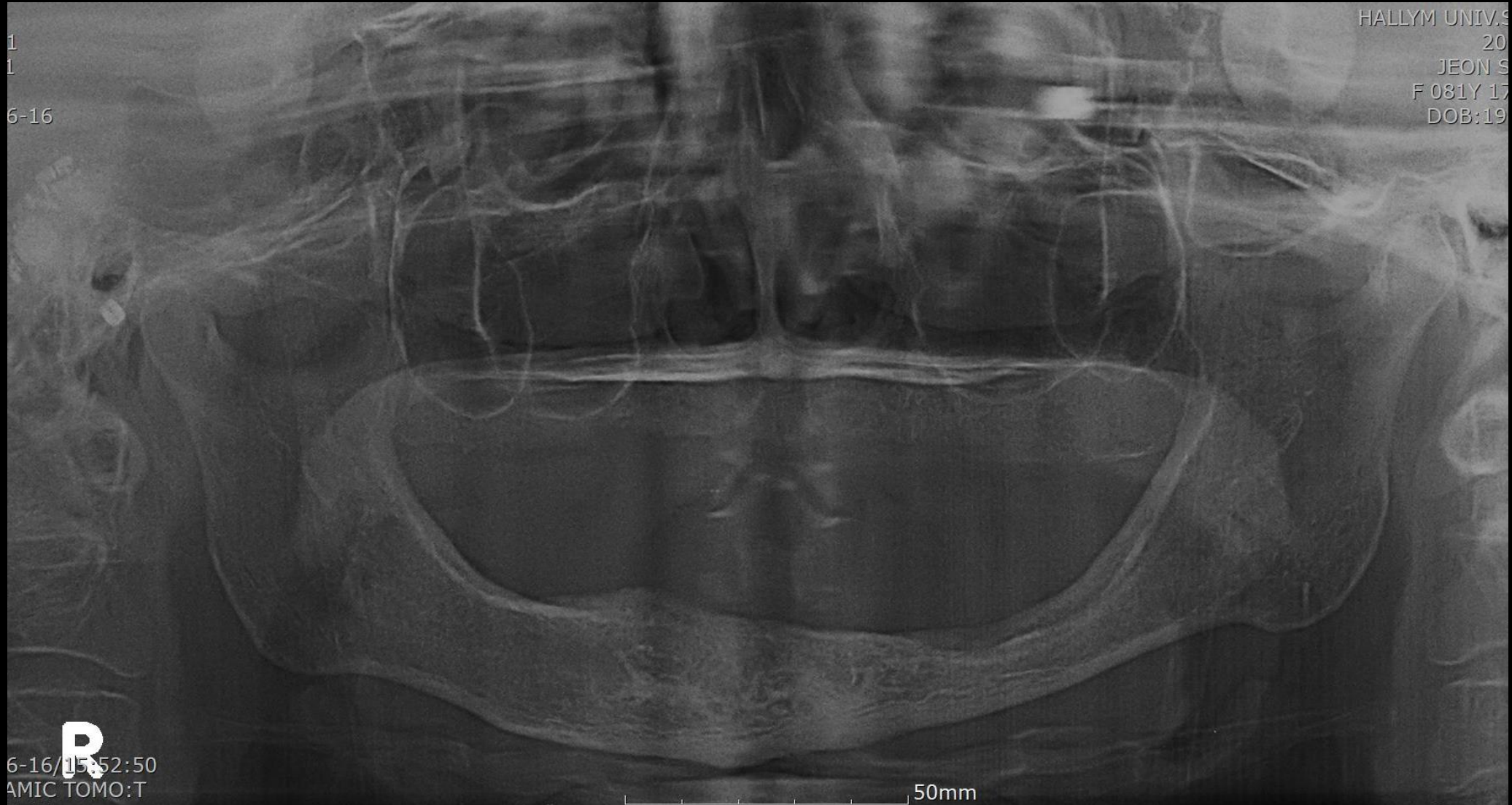


Digital Guide (Printing)



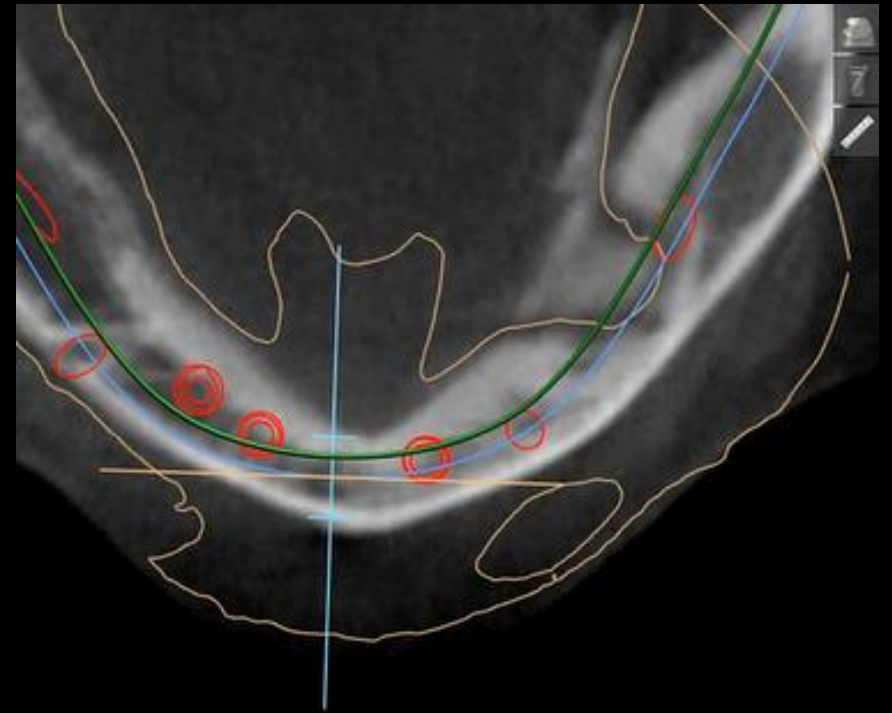
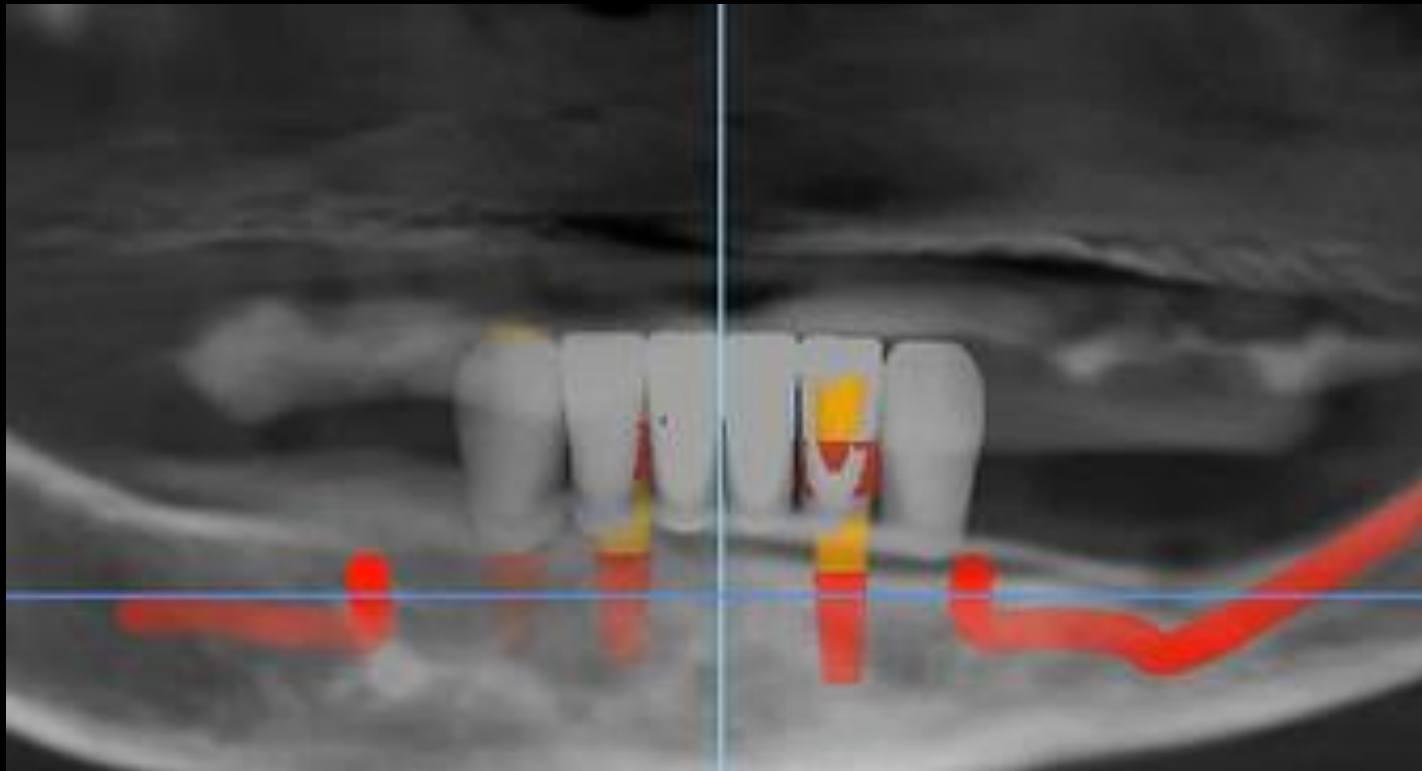
Similar case 1

Pre-op (2020-06-16)



Similar case 1

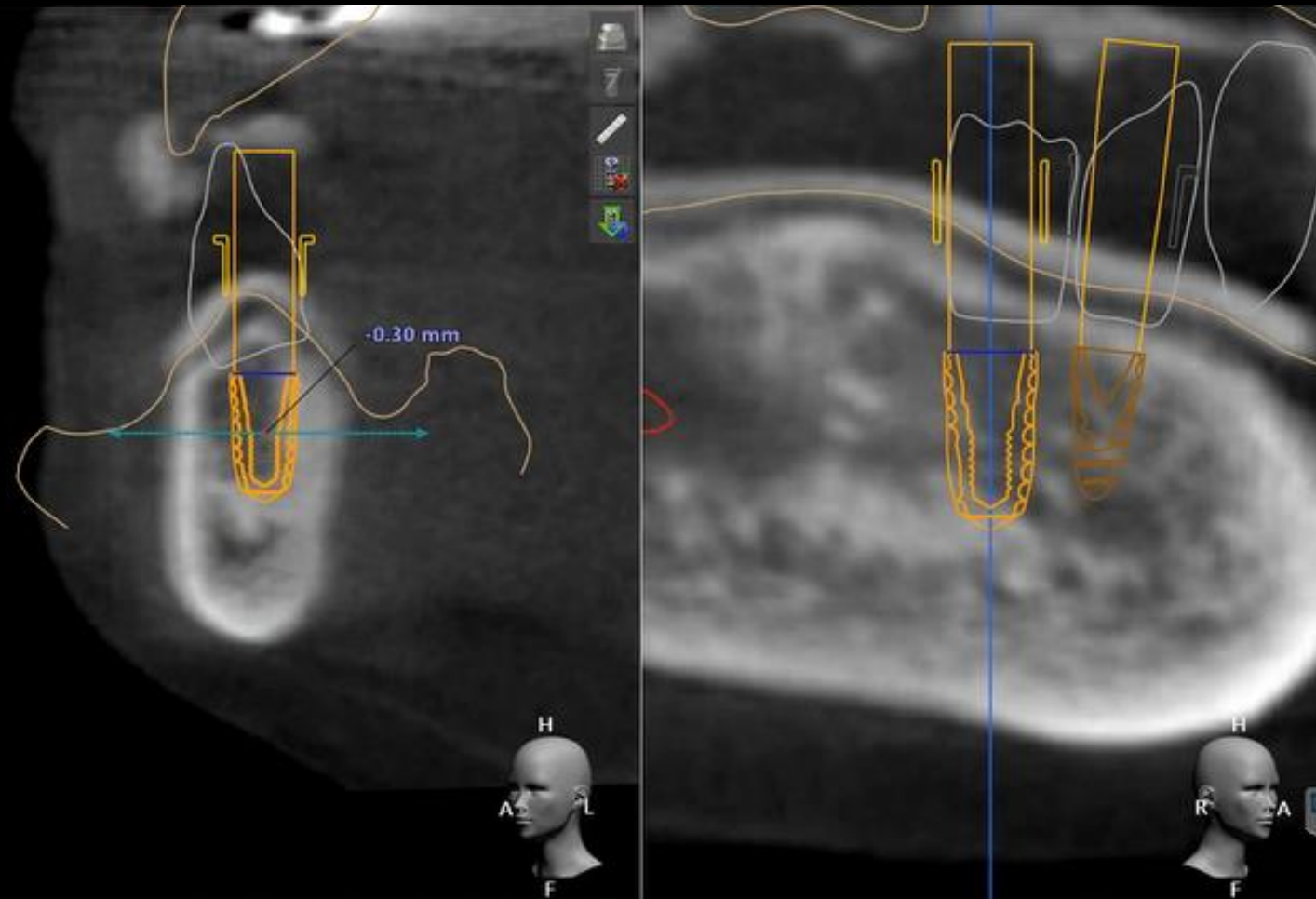
Digital Guide S/W (Implant Planning)



Similar case 1

Digital Guide S/W (Implant Planning)

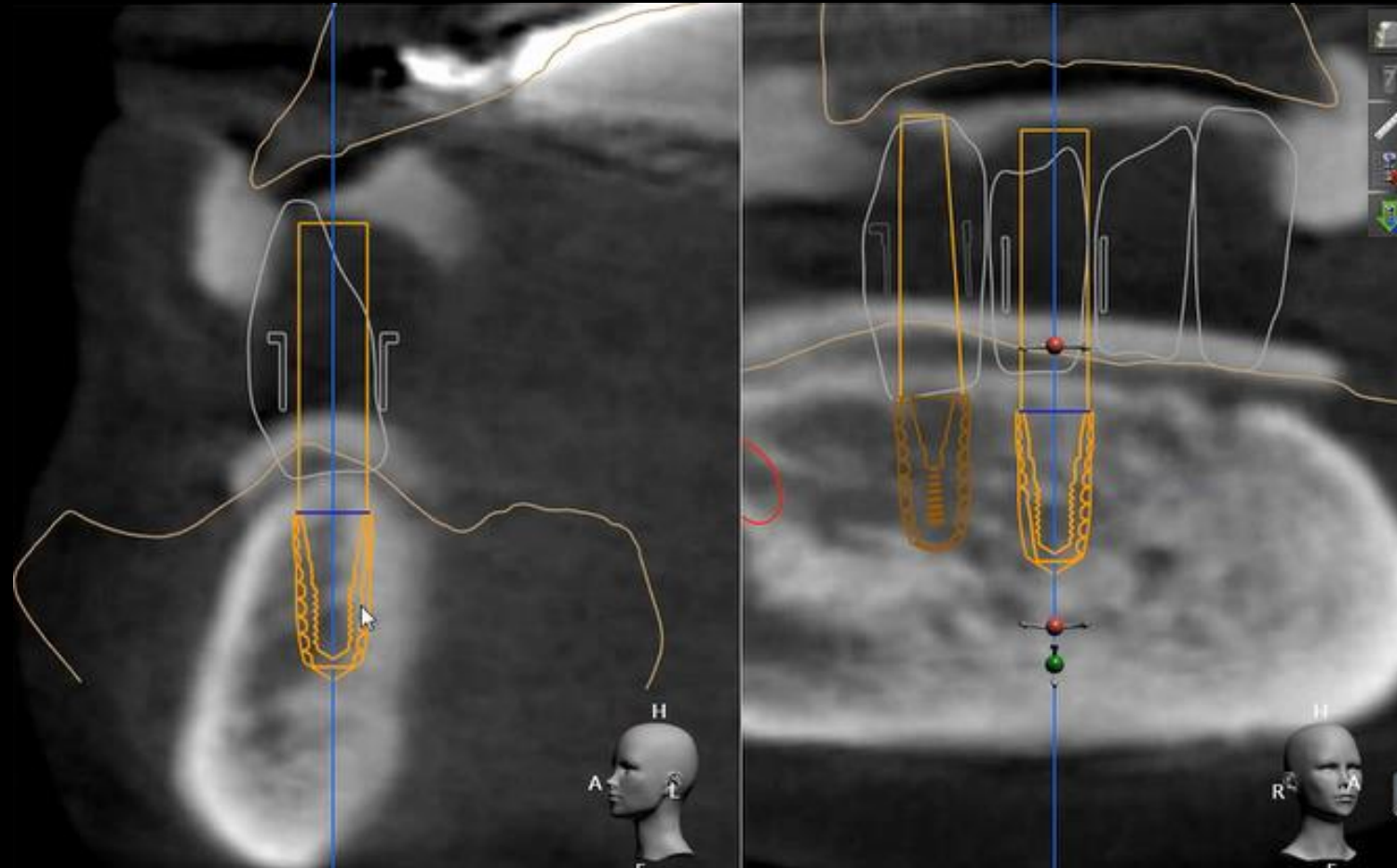
#43(FXS 4008)



Similar case 1

Digital Guide S/W (Implant Planning)

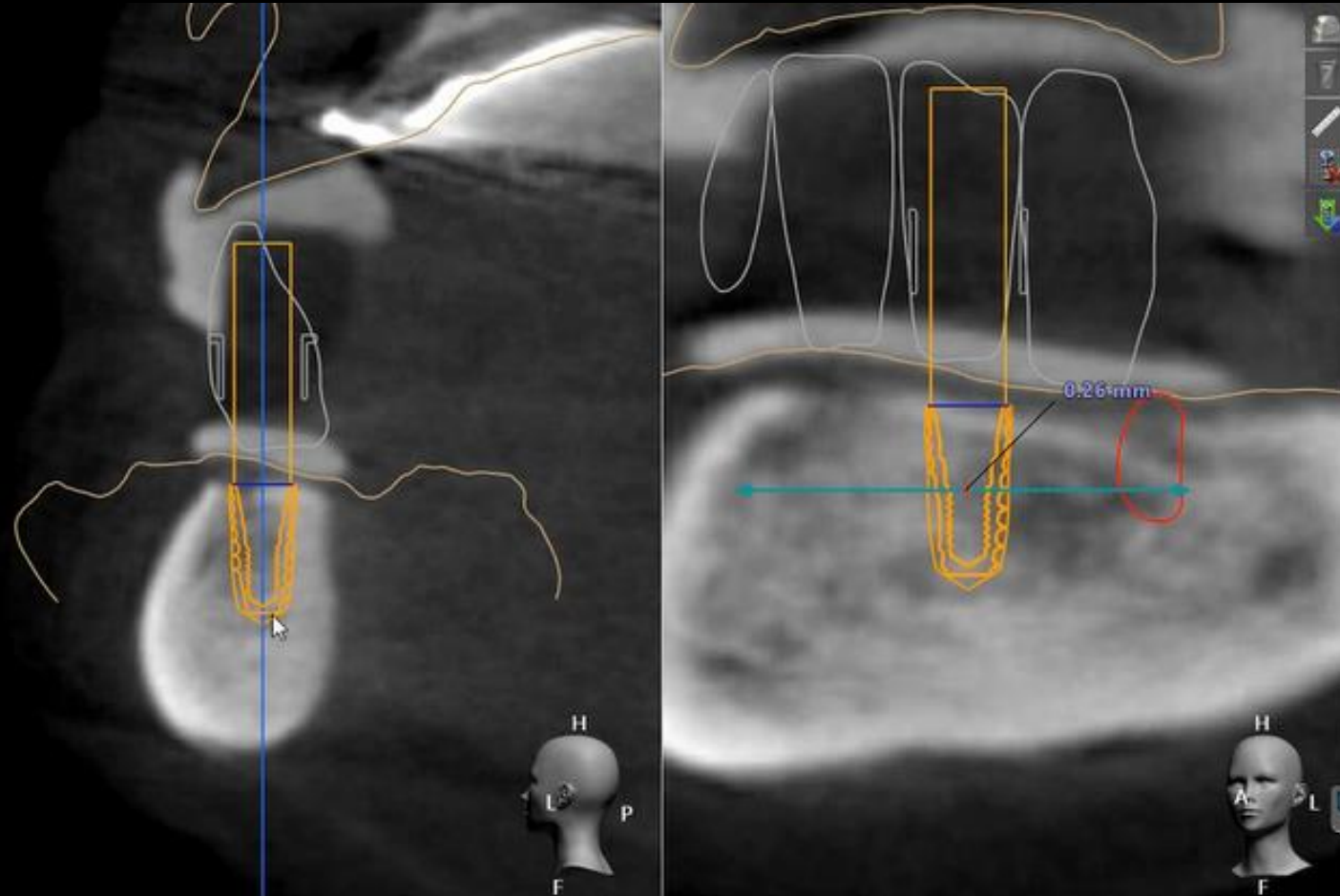
#42(FXS 4008)



Similar case 1

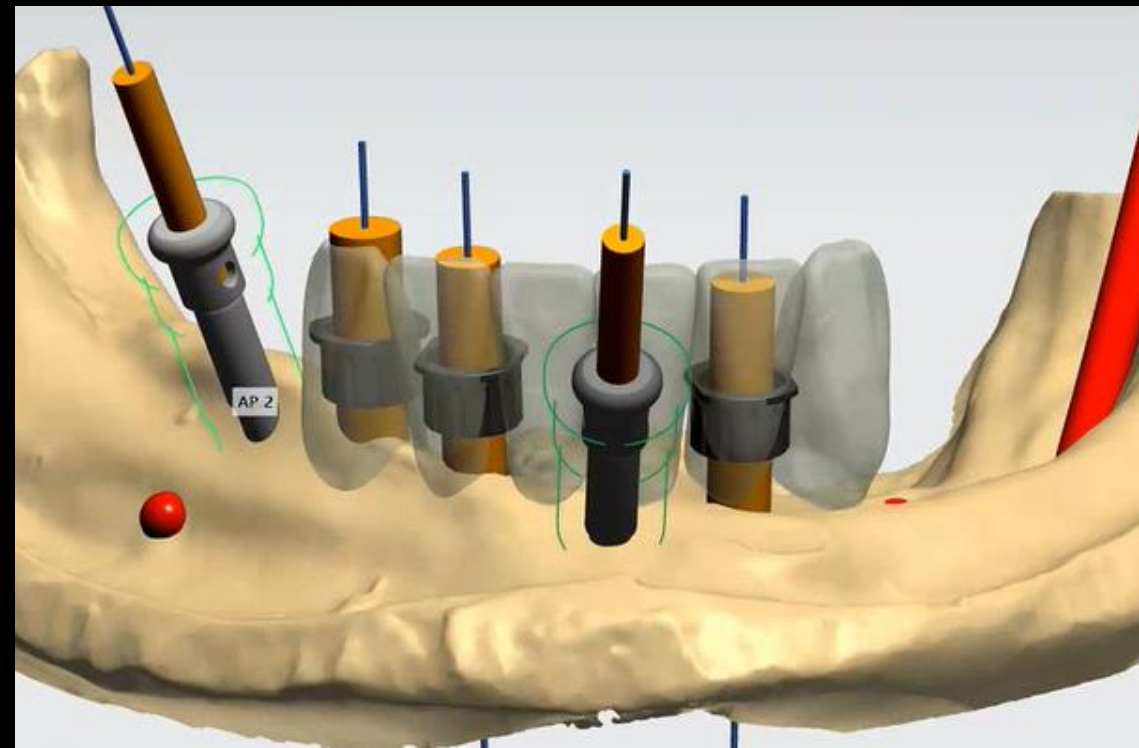
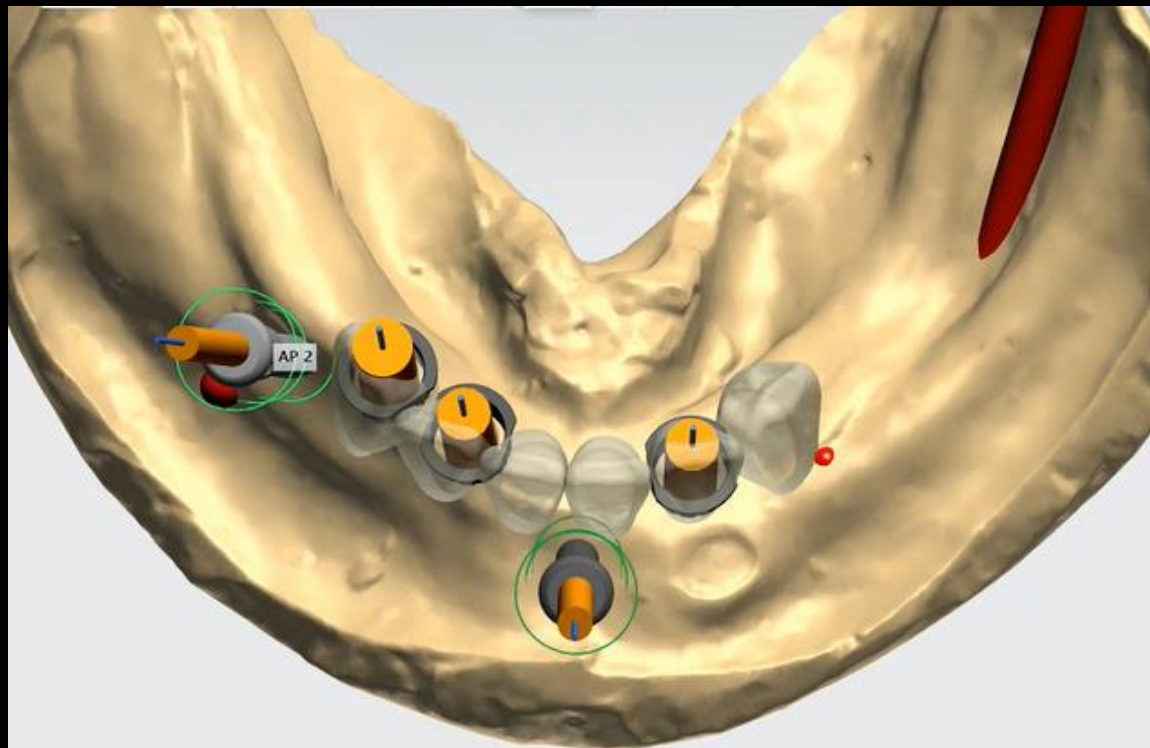
Digital Guide S/W (Implant Planning)

#33(FXS 4008)



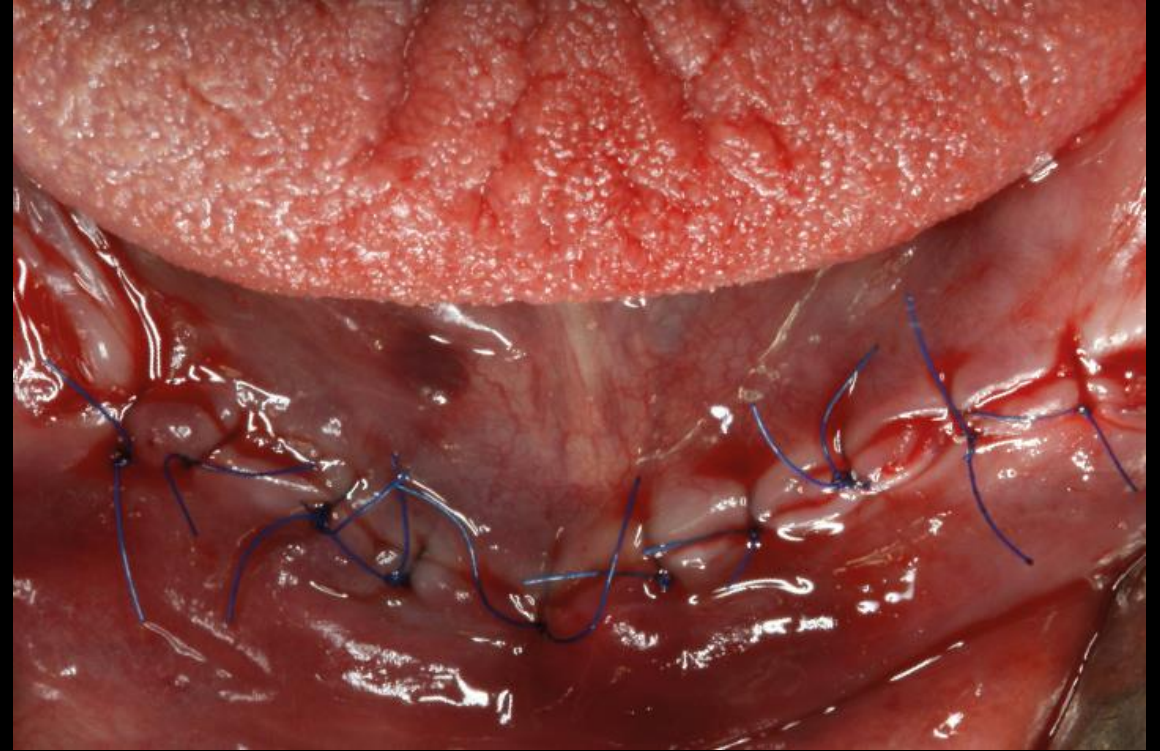
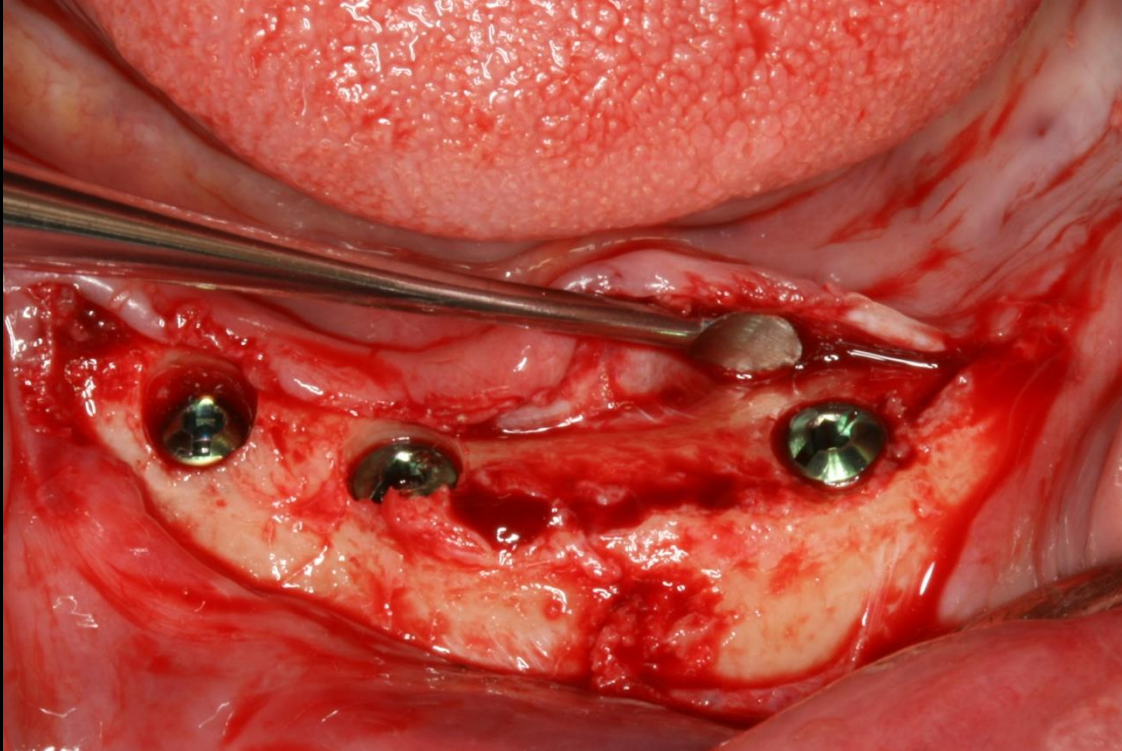
Similar case 1

Digital Guide S/W (Virtual Set-up & Surgical Guide design)



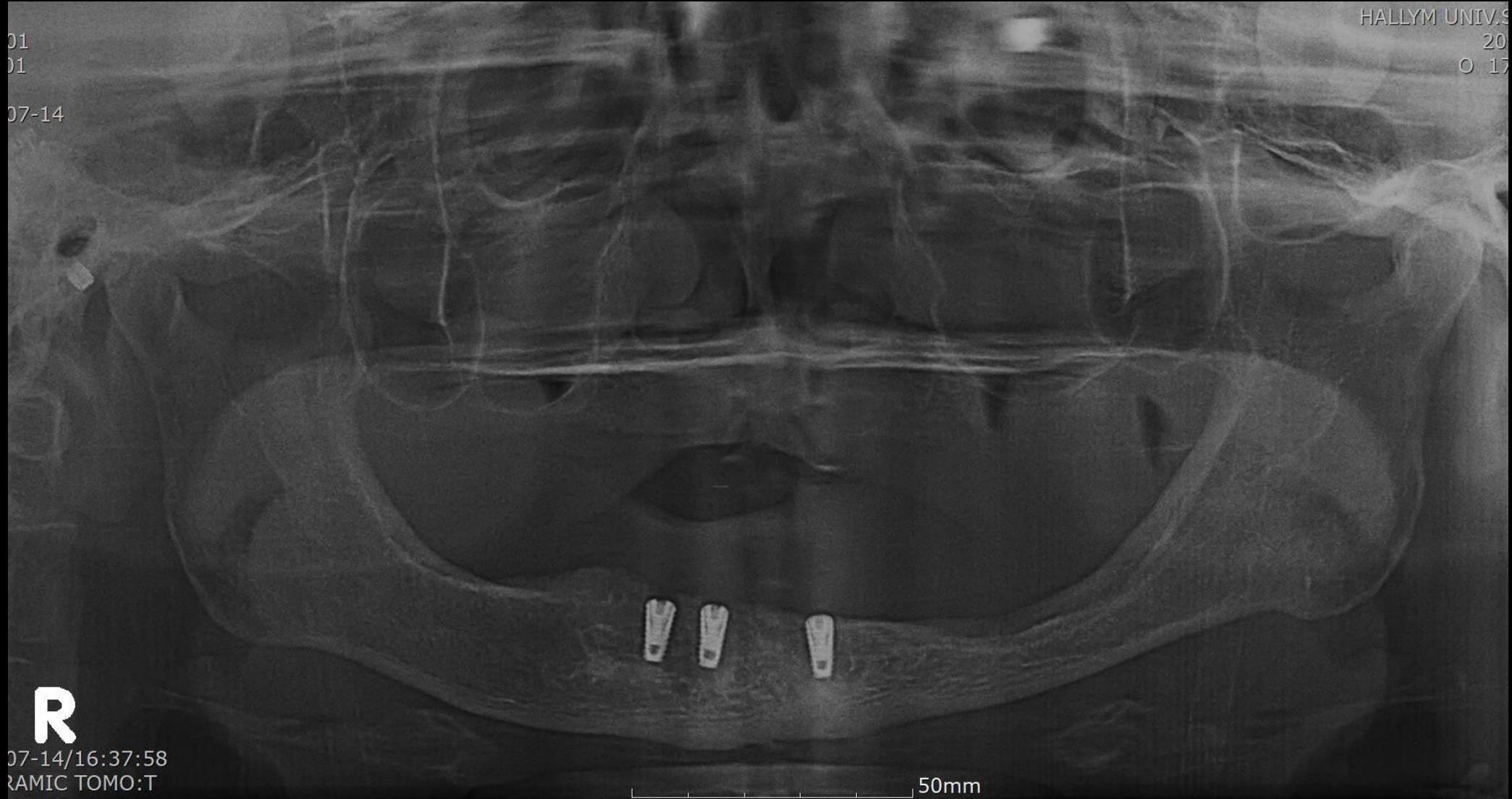
Similar case 1

1st Surgery : Cover Screw connection



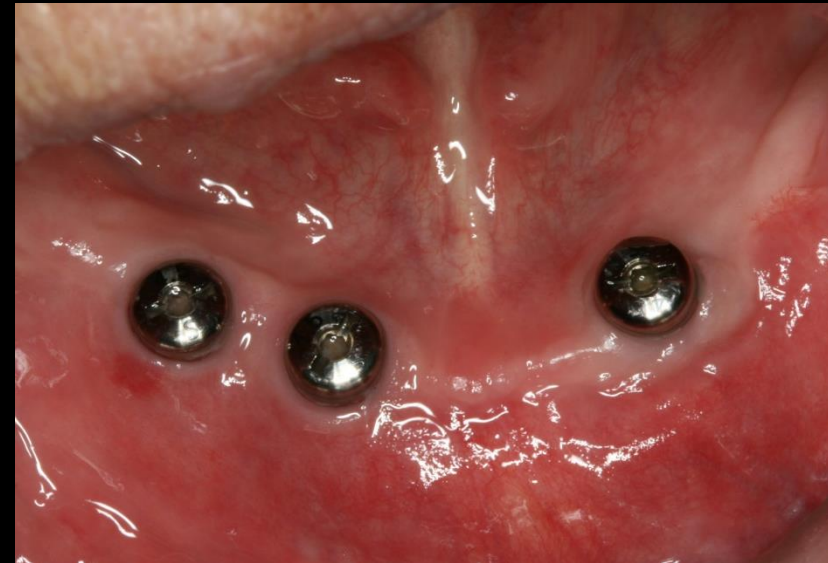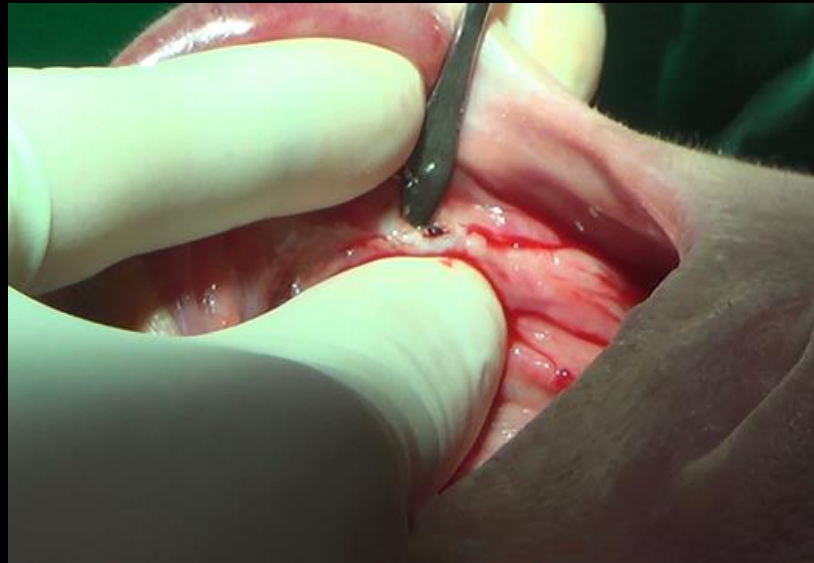
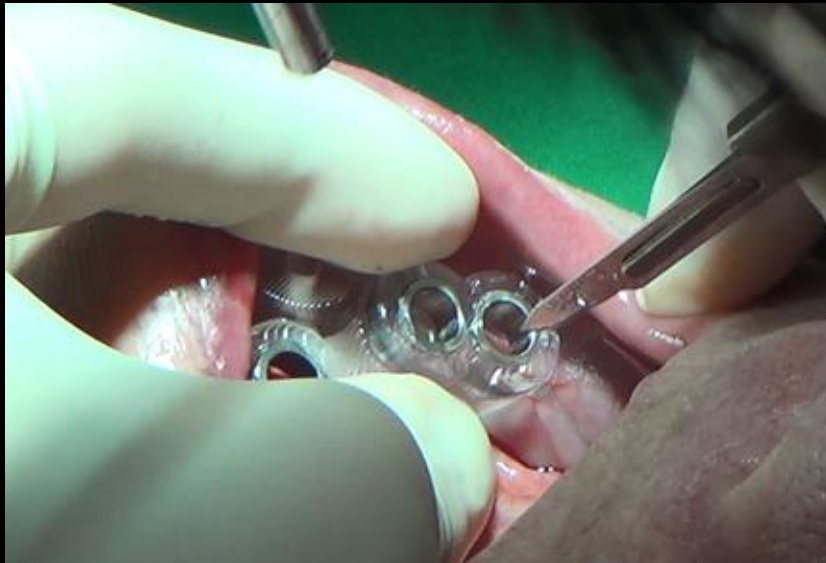Similar case 1

Post- 1st op (2020-07-14)



Similar case 1

2nd Surgery : Healing Abutment connection



Similar case 1

Post- 2nd op (2020-10-27)

