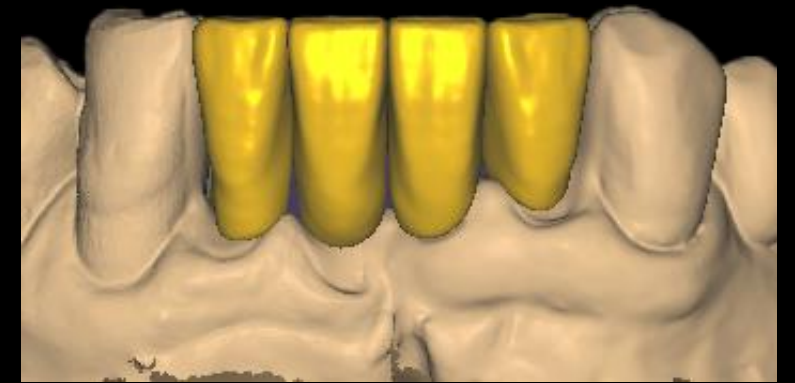
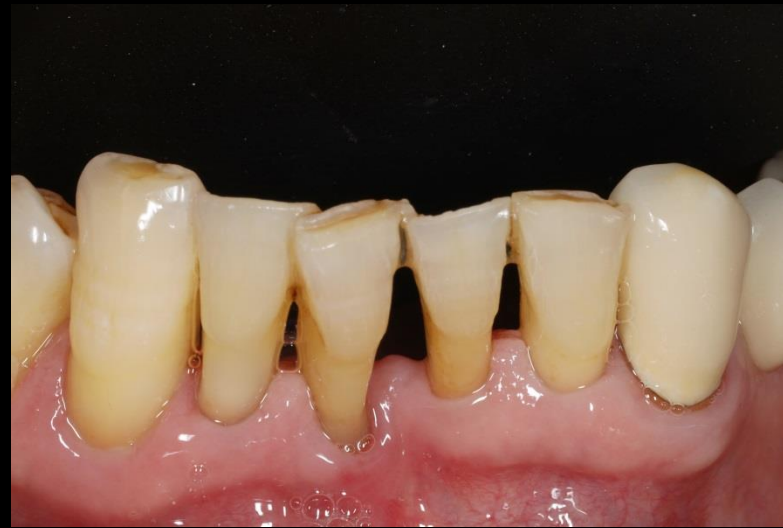
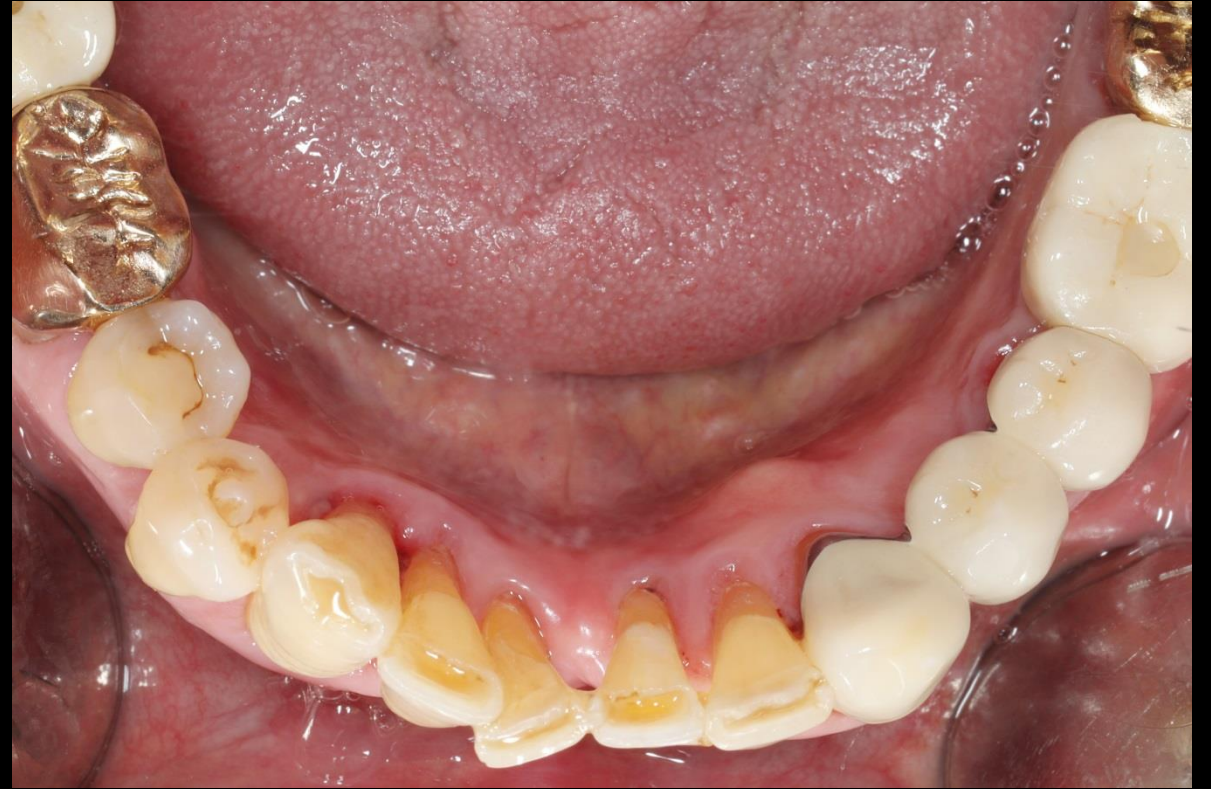
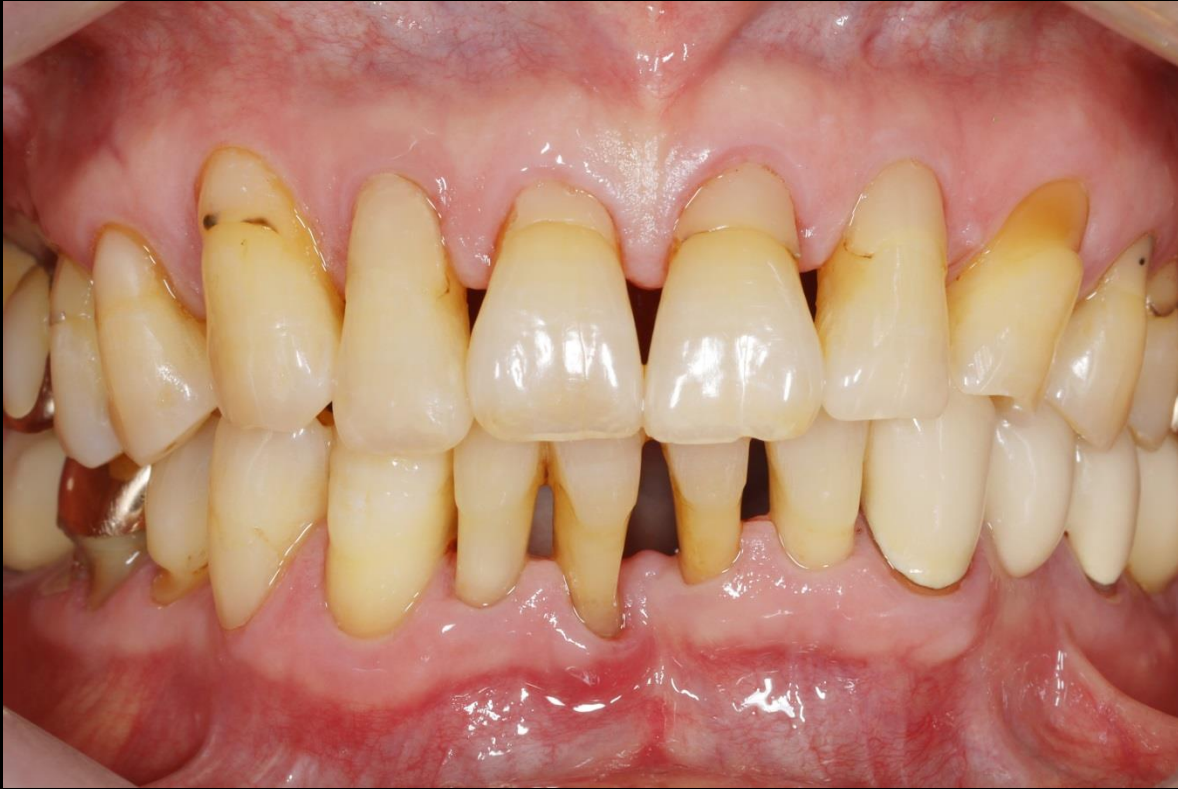Minimalistic strategy for Immediate implantation in narrow ridge & Socket preservation

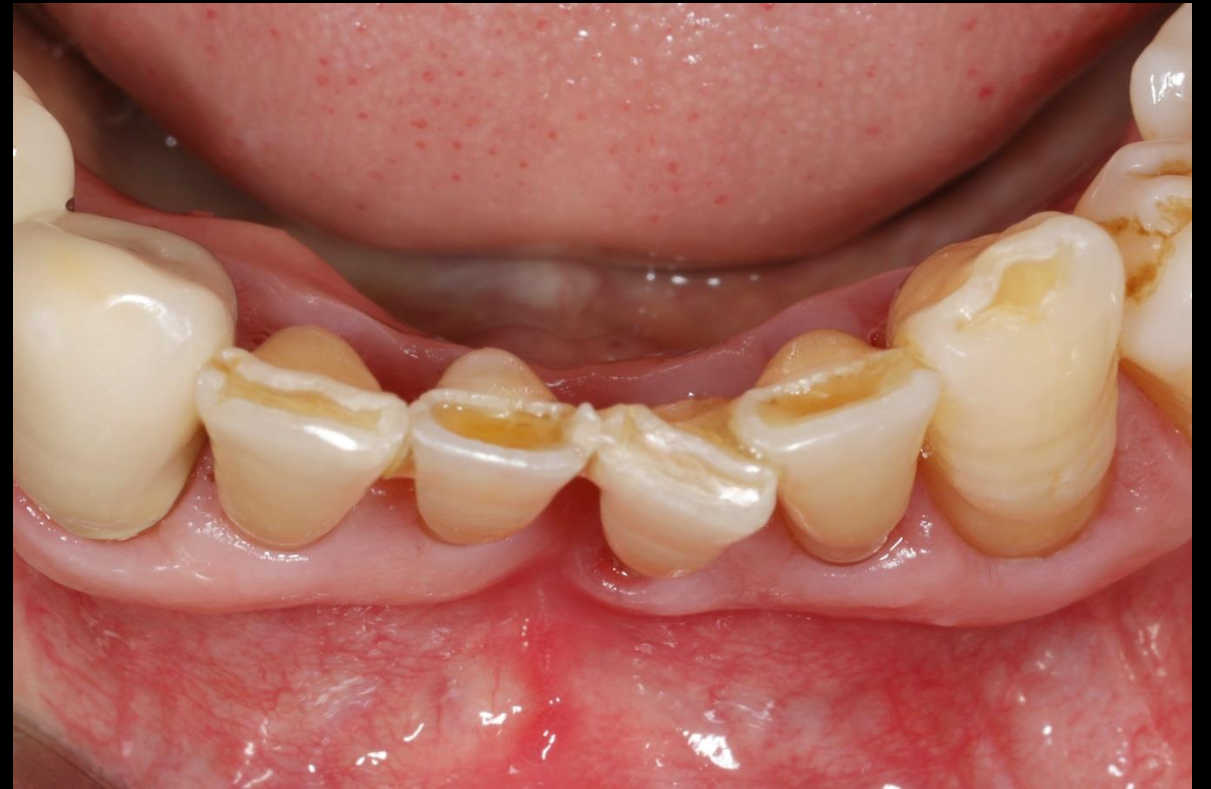
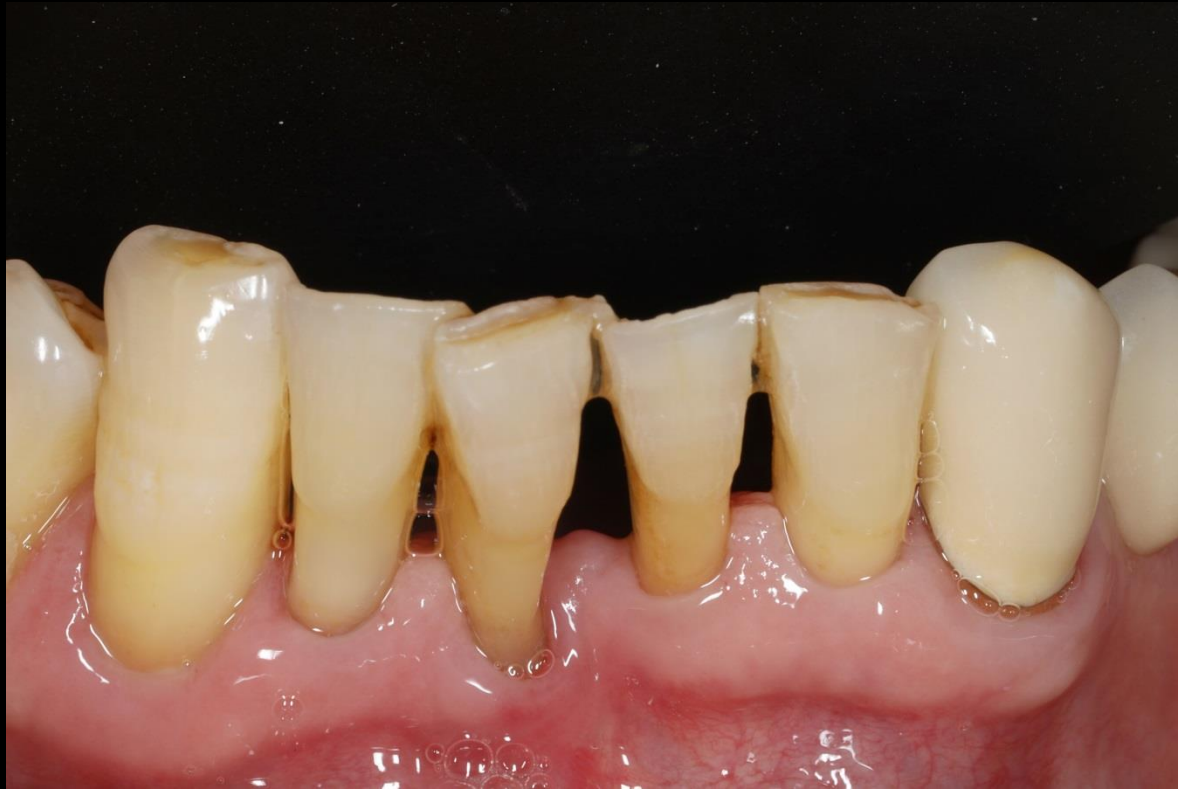
Dr. SM Chung
2021.4.2 (Fri)

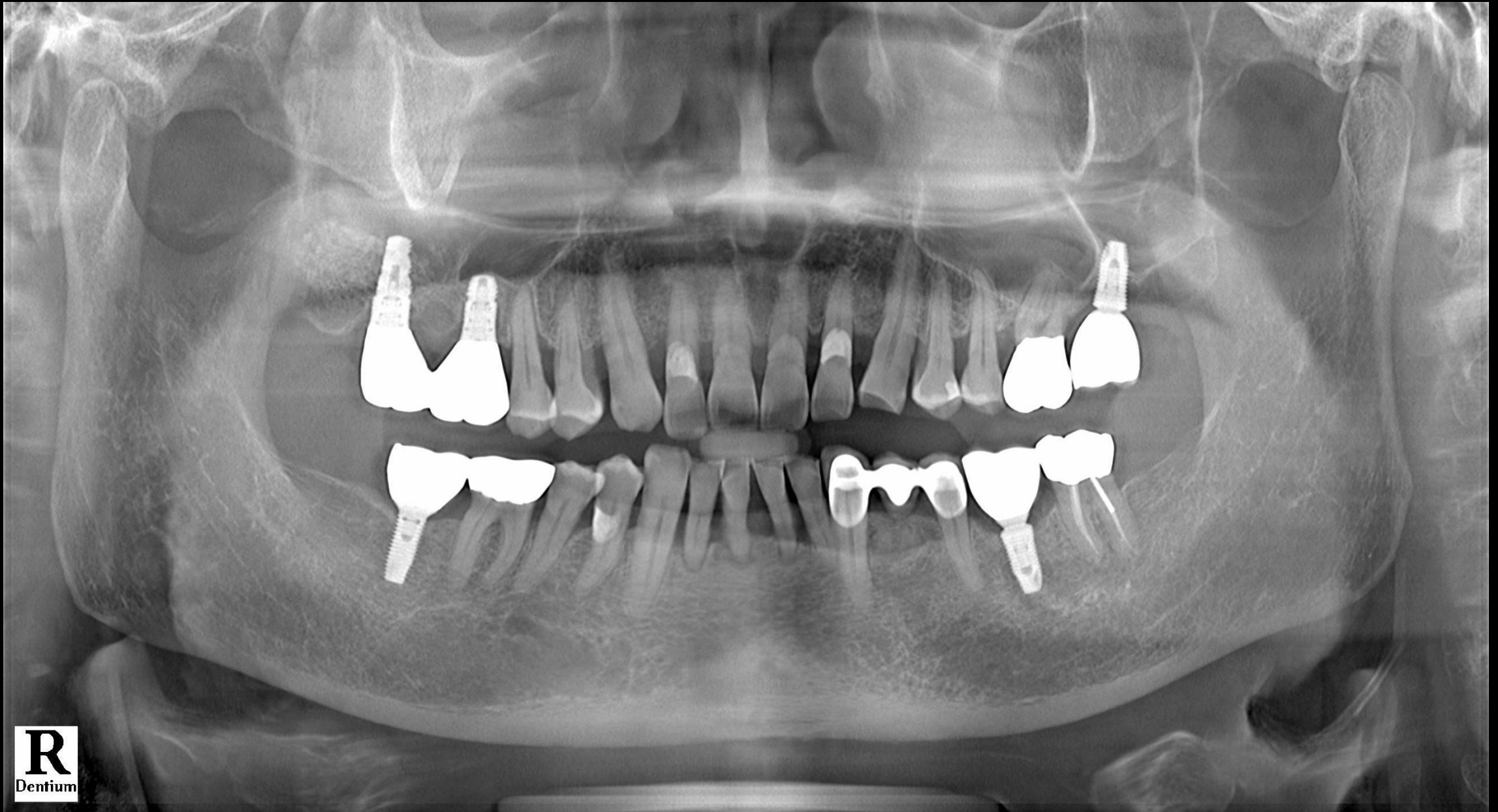Oral exam (2021-03-17)



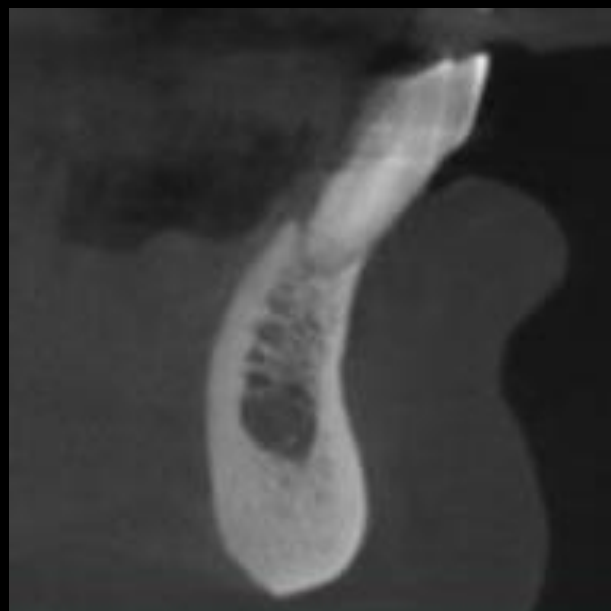
Oral exam (2021-03-17)



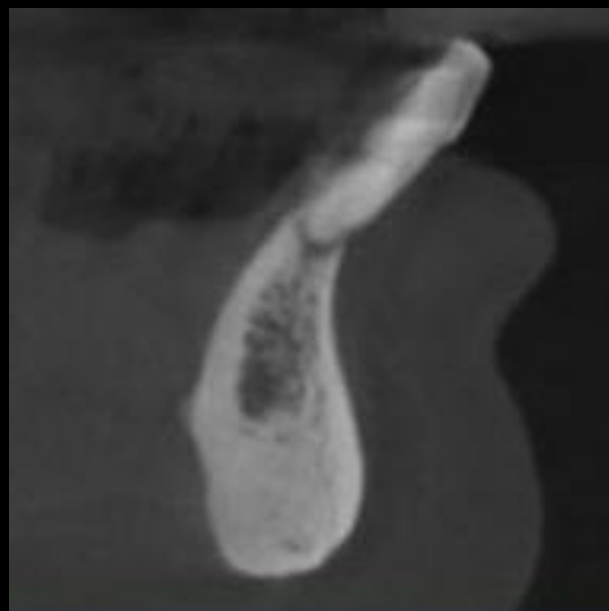
Pre-op (2021-03-17)



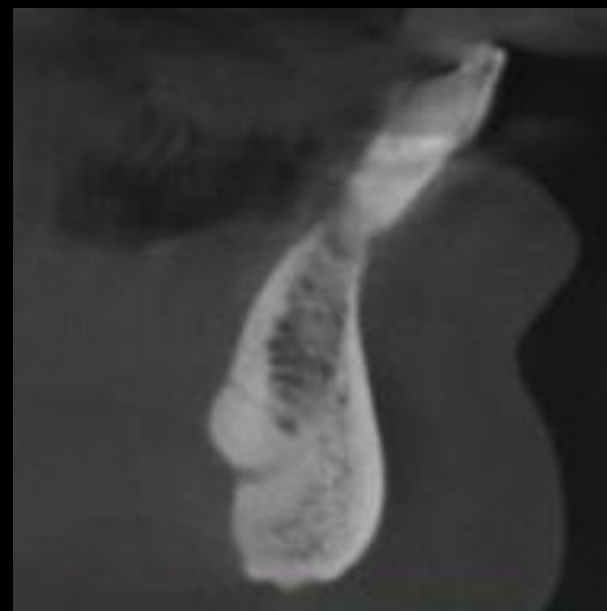
Pre-op (2021-03-17)



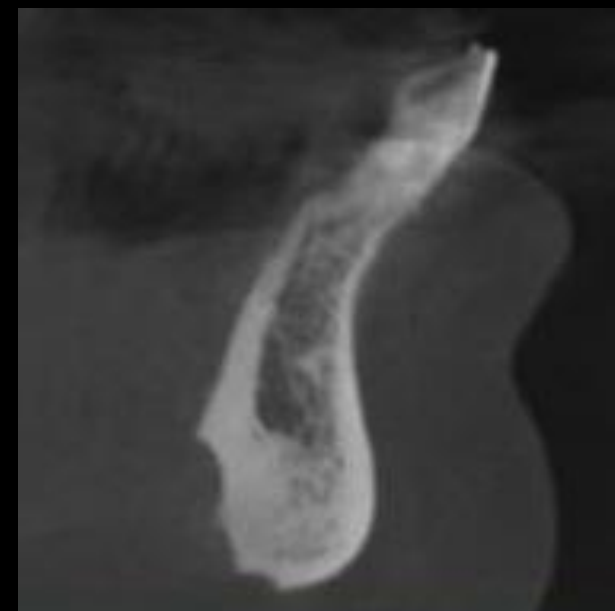
#42



#41



#31

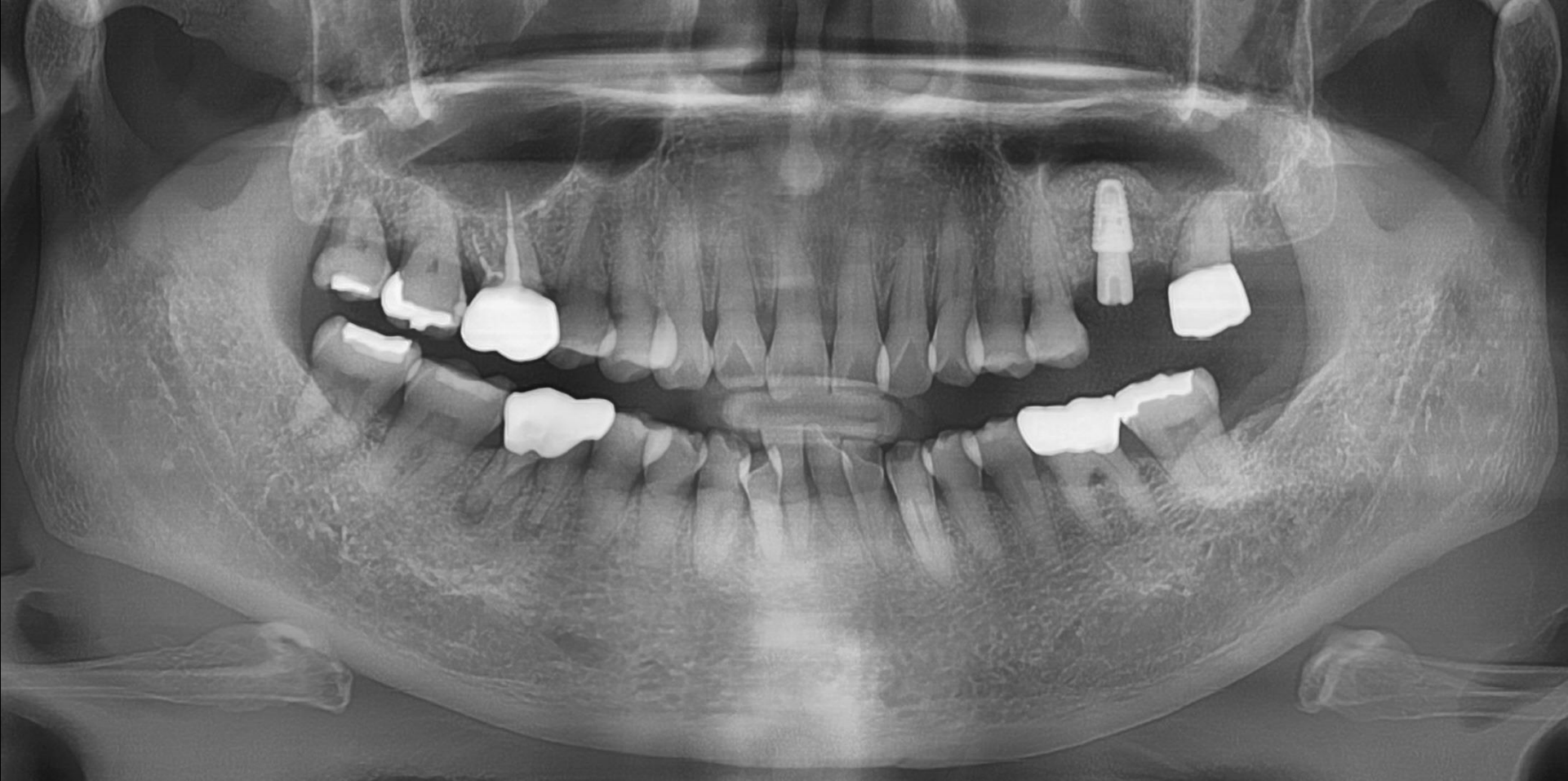


#32

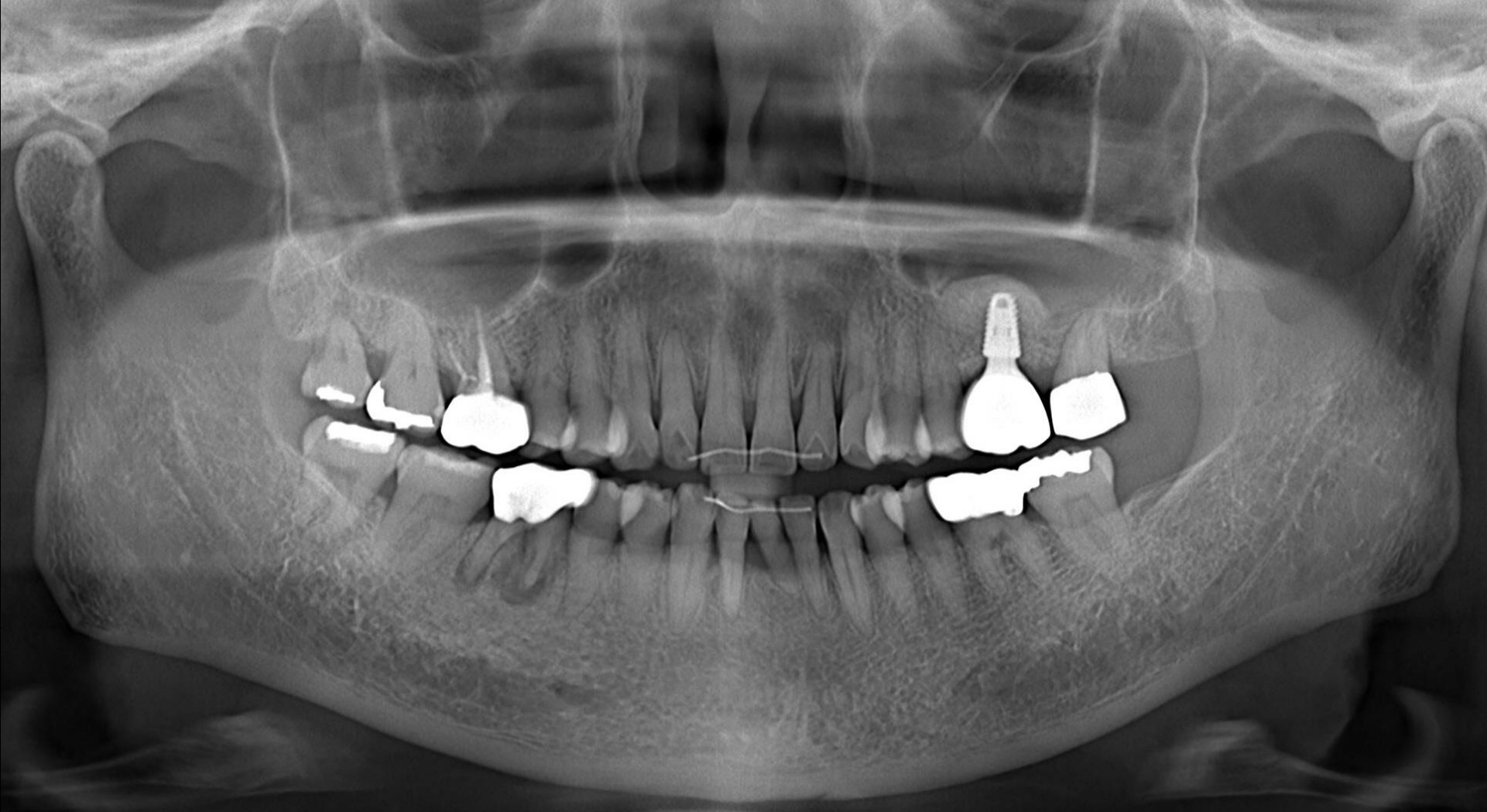The reality in Lower Anterior

- Orthodontic Treatment
- Bridge
- Implant

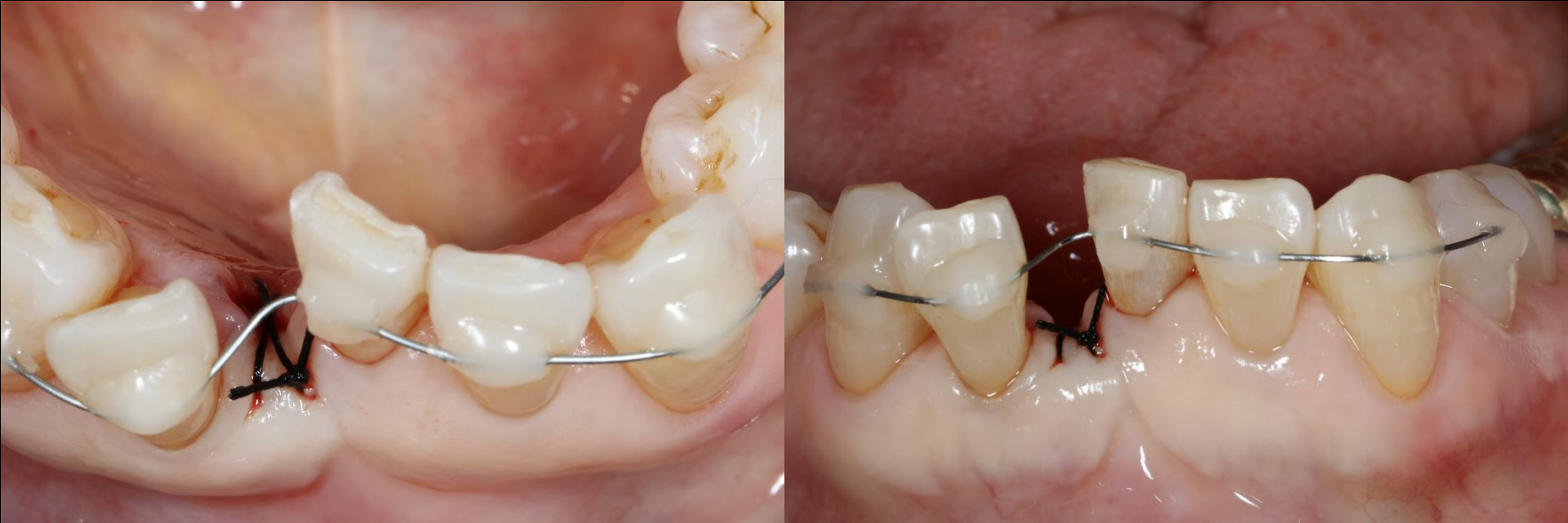Oral exam (2016-09-30)



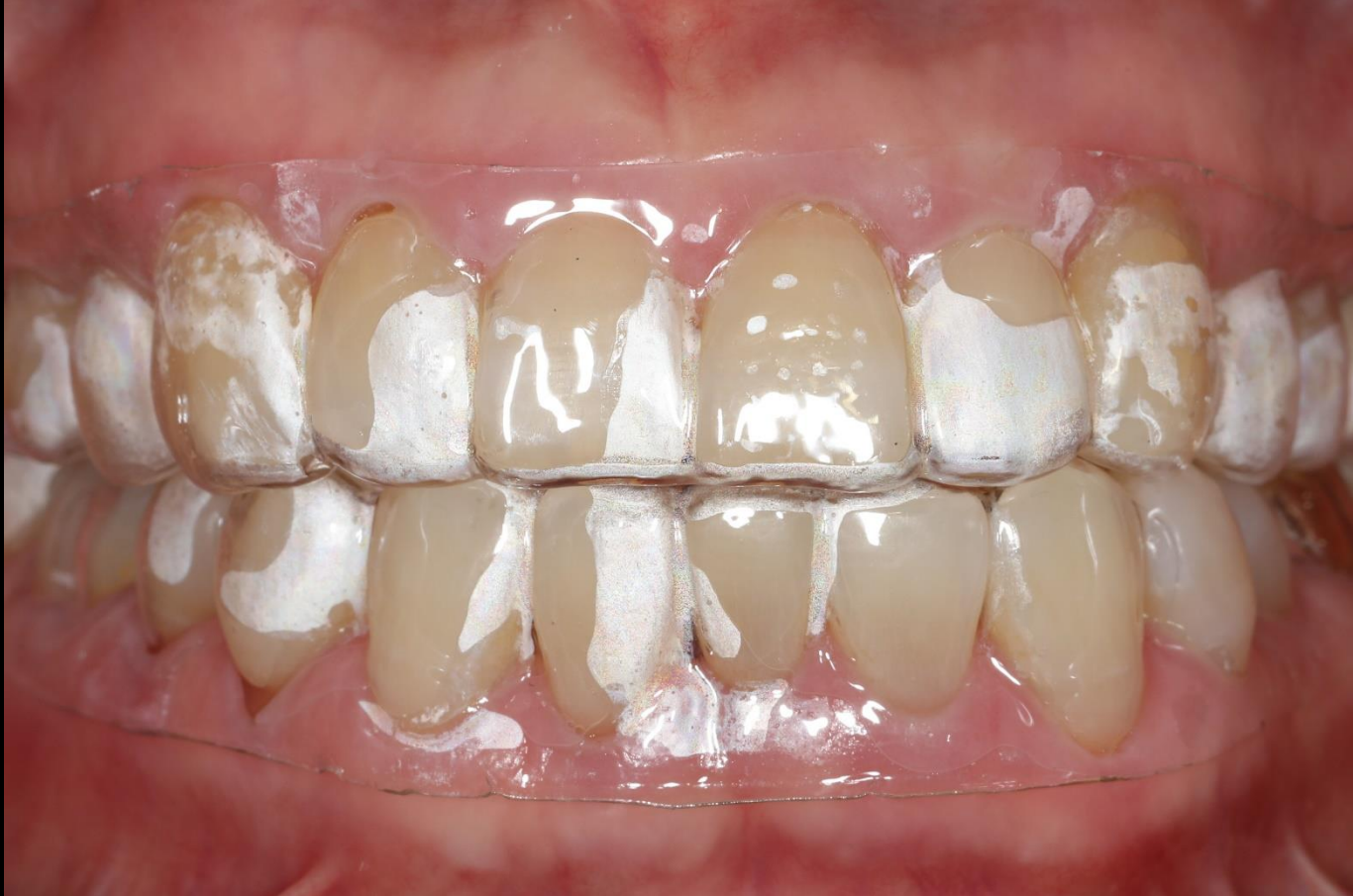Orthodontics Final Check (2019-06-20)



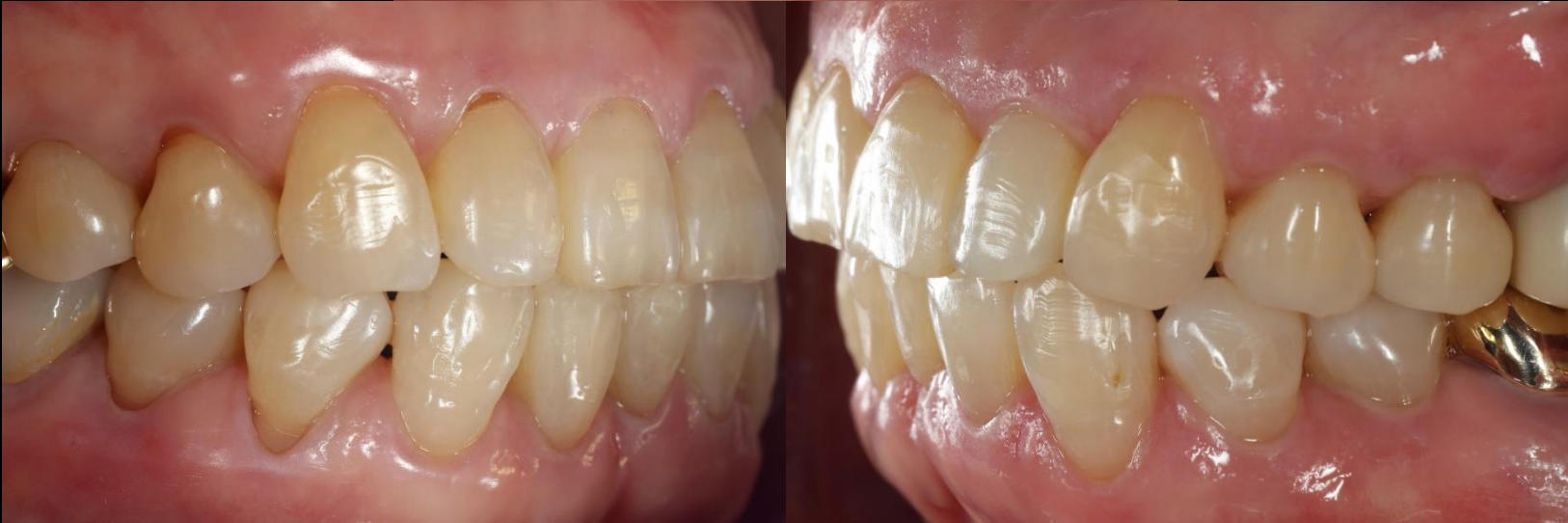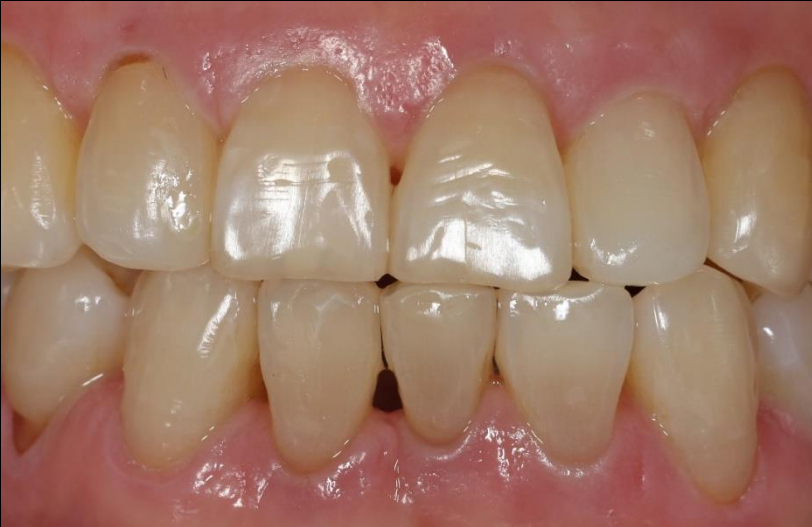Tooth extraction (2017-01-12)



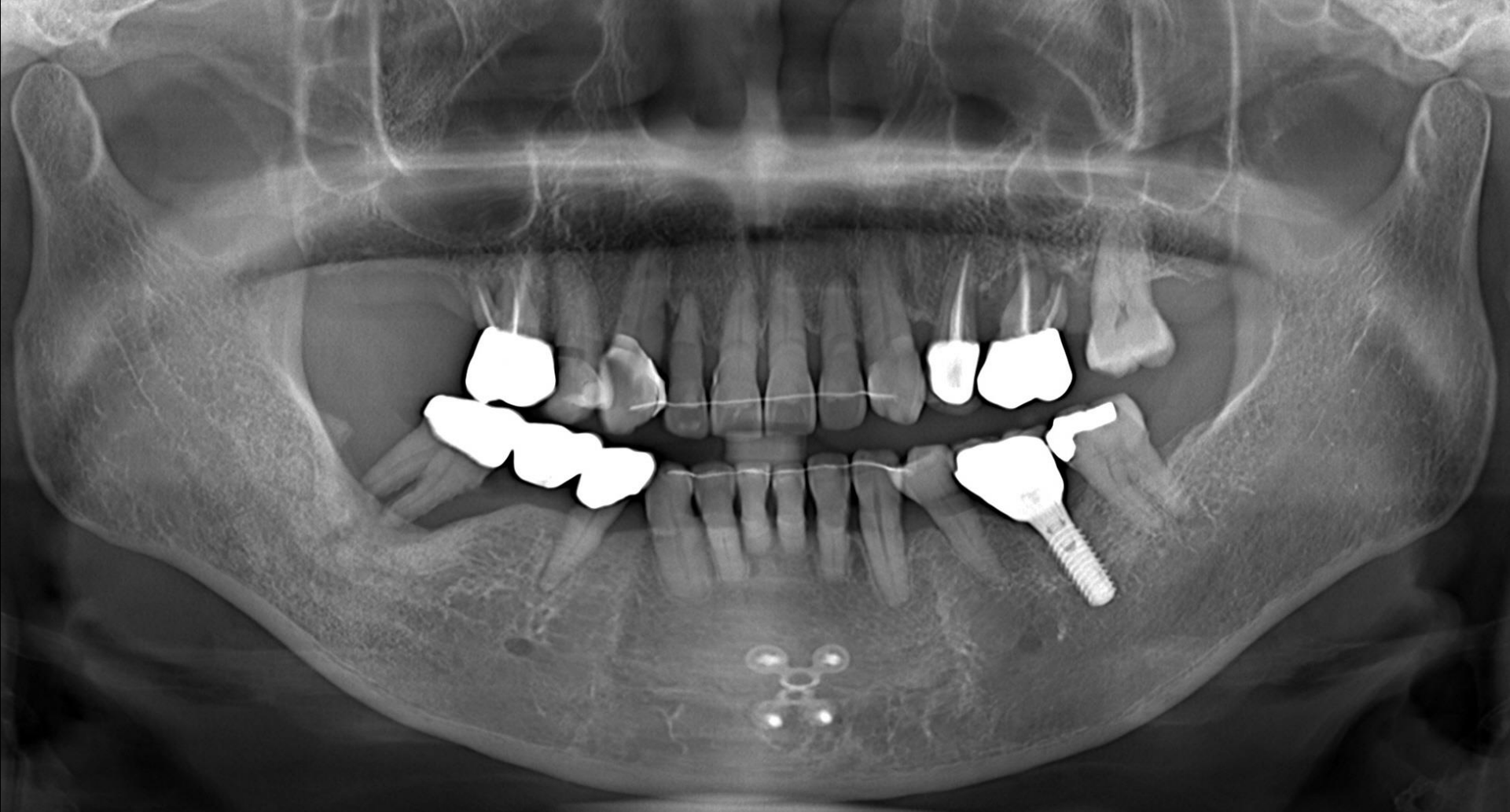Orthodontics Final Check (2017-07-27)



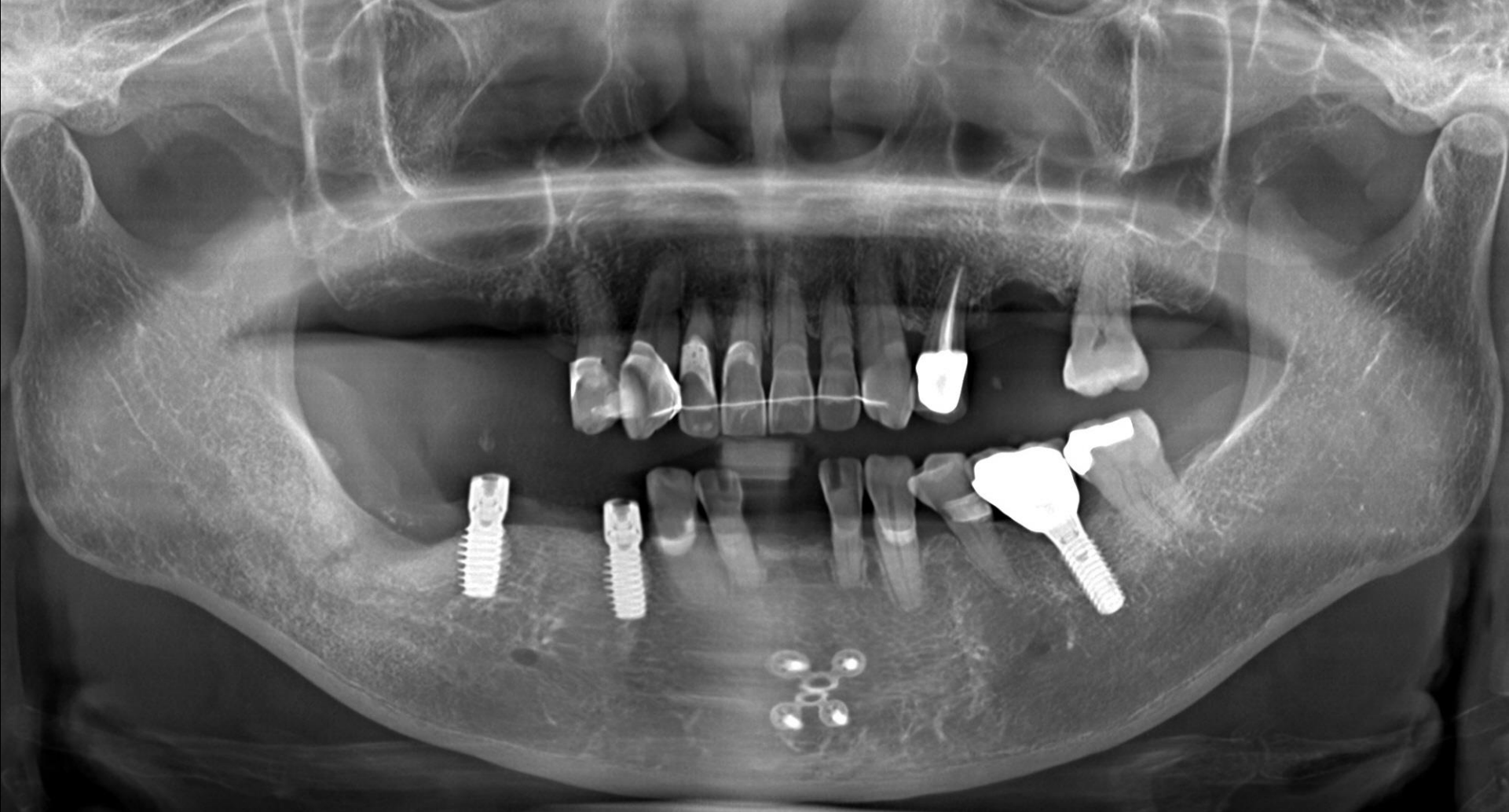Orthodontics Final Check (2017-07-27)



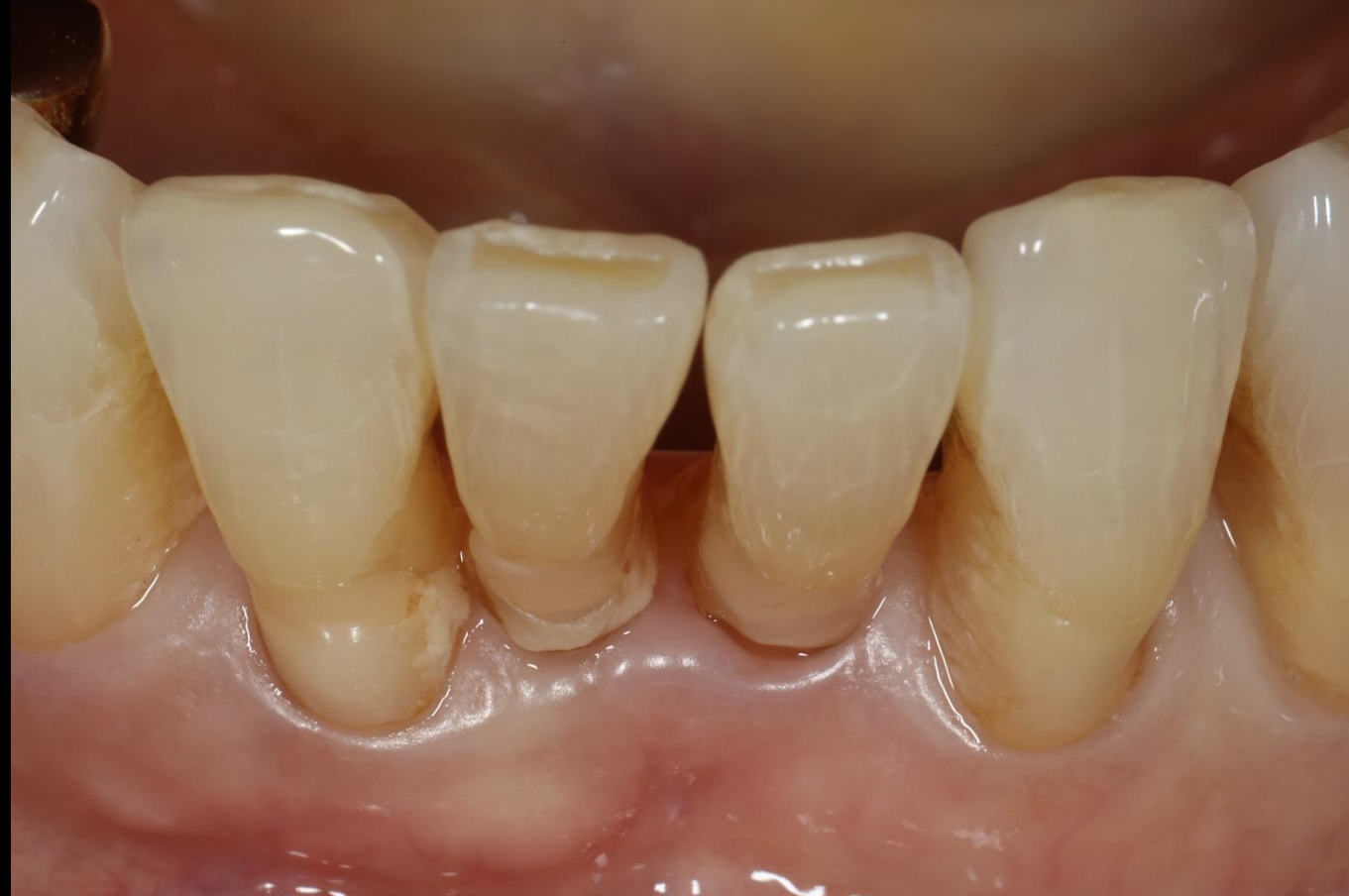Pre-op (2019-06-26)



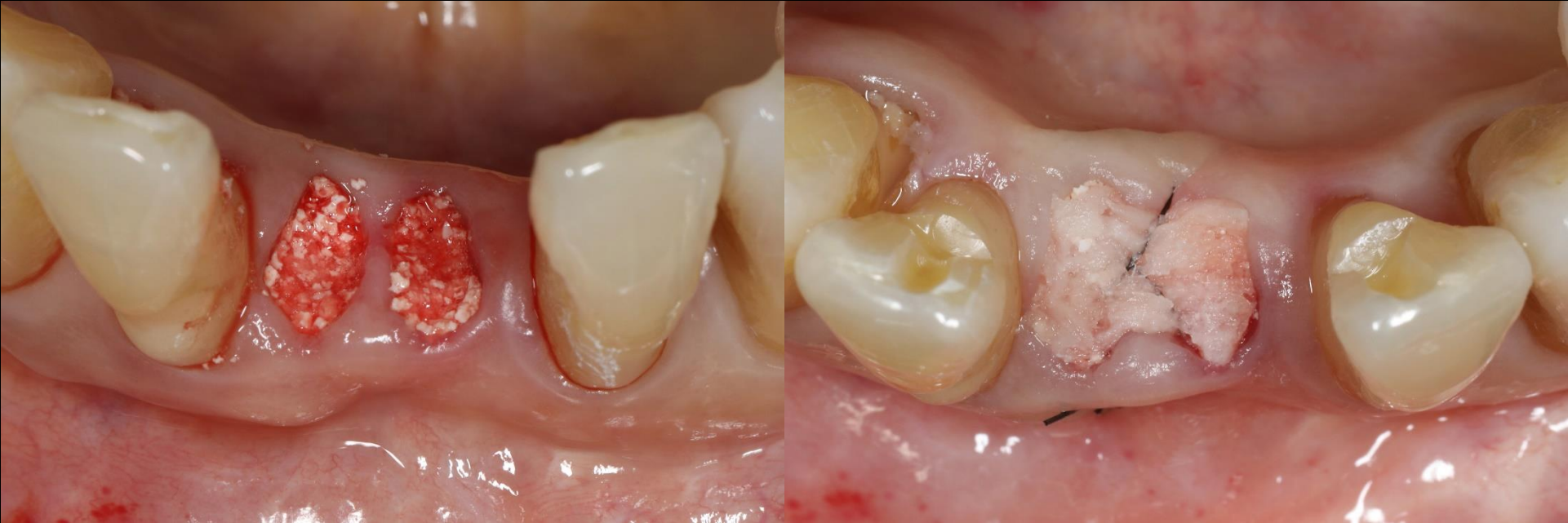Post-op (2019-07-31)



Pre-op (2019-07-31)



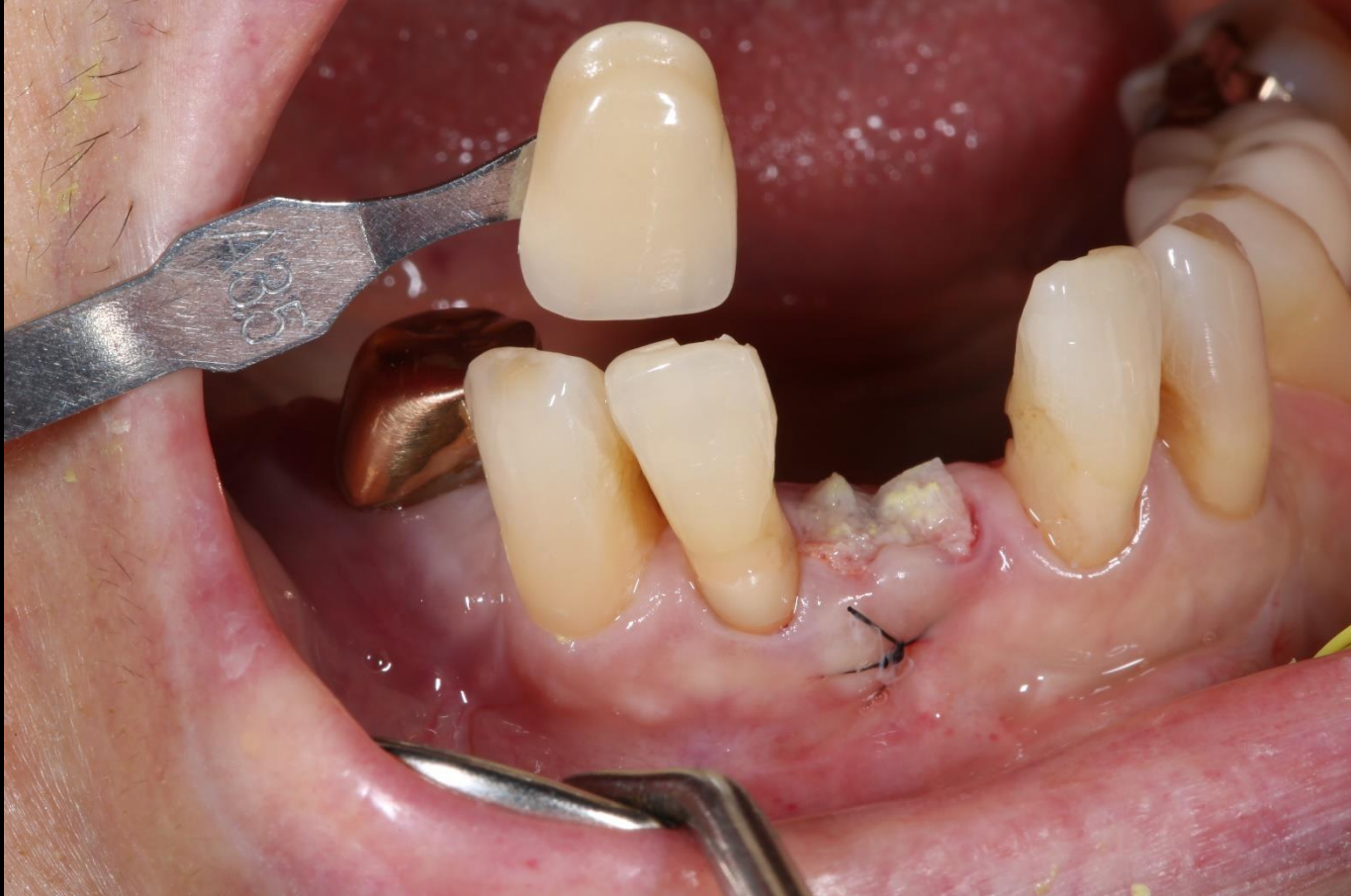Surgery (2019-07-31)



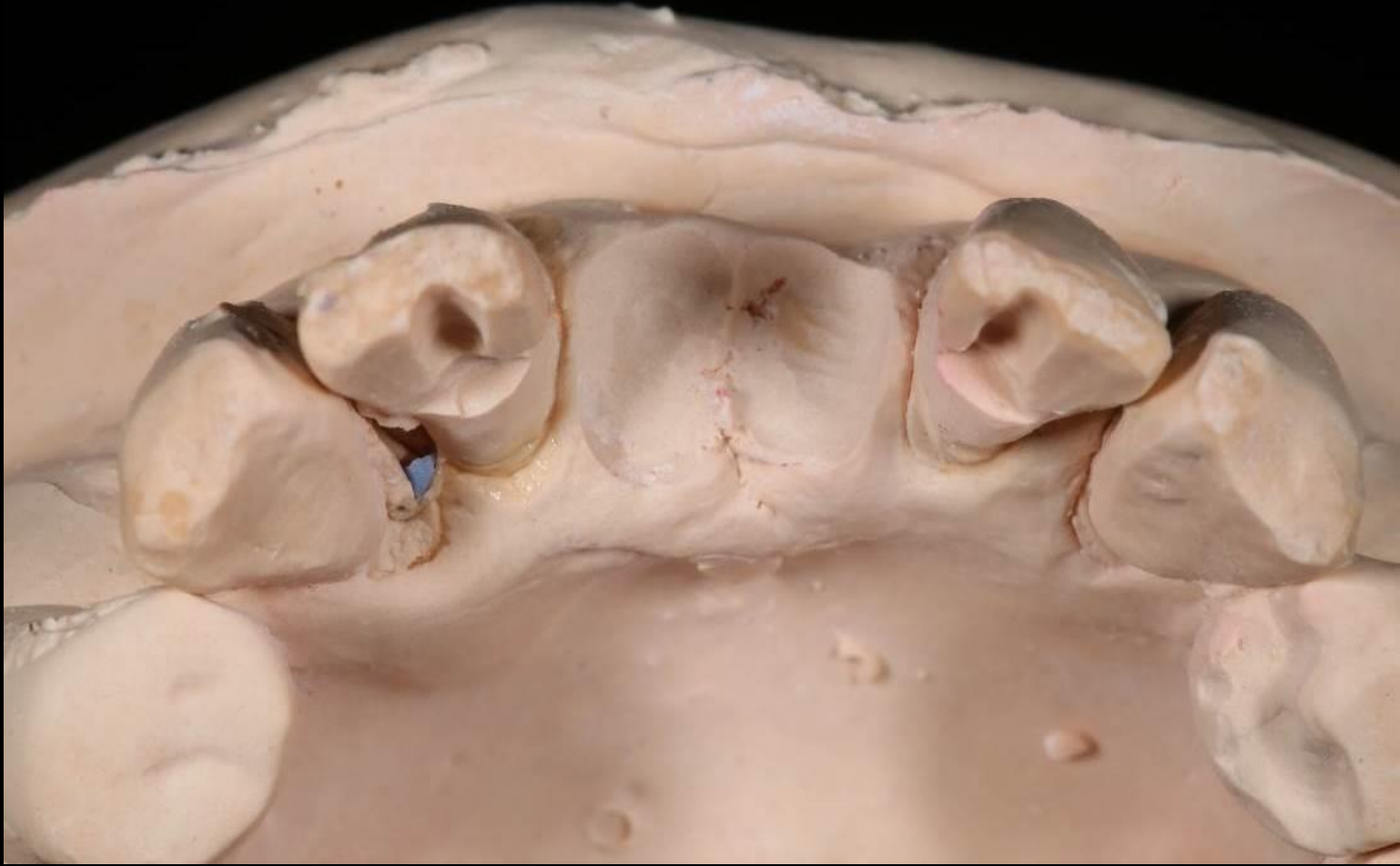OSTEON™ 3 Collagen

Collagen Graft / Suture

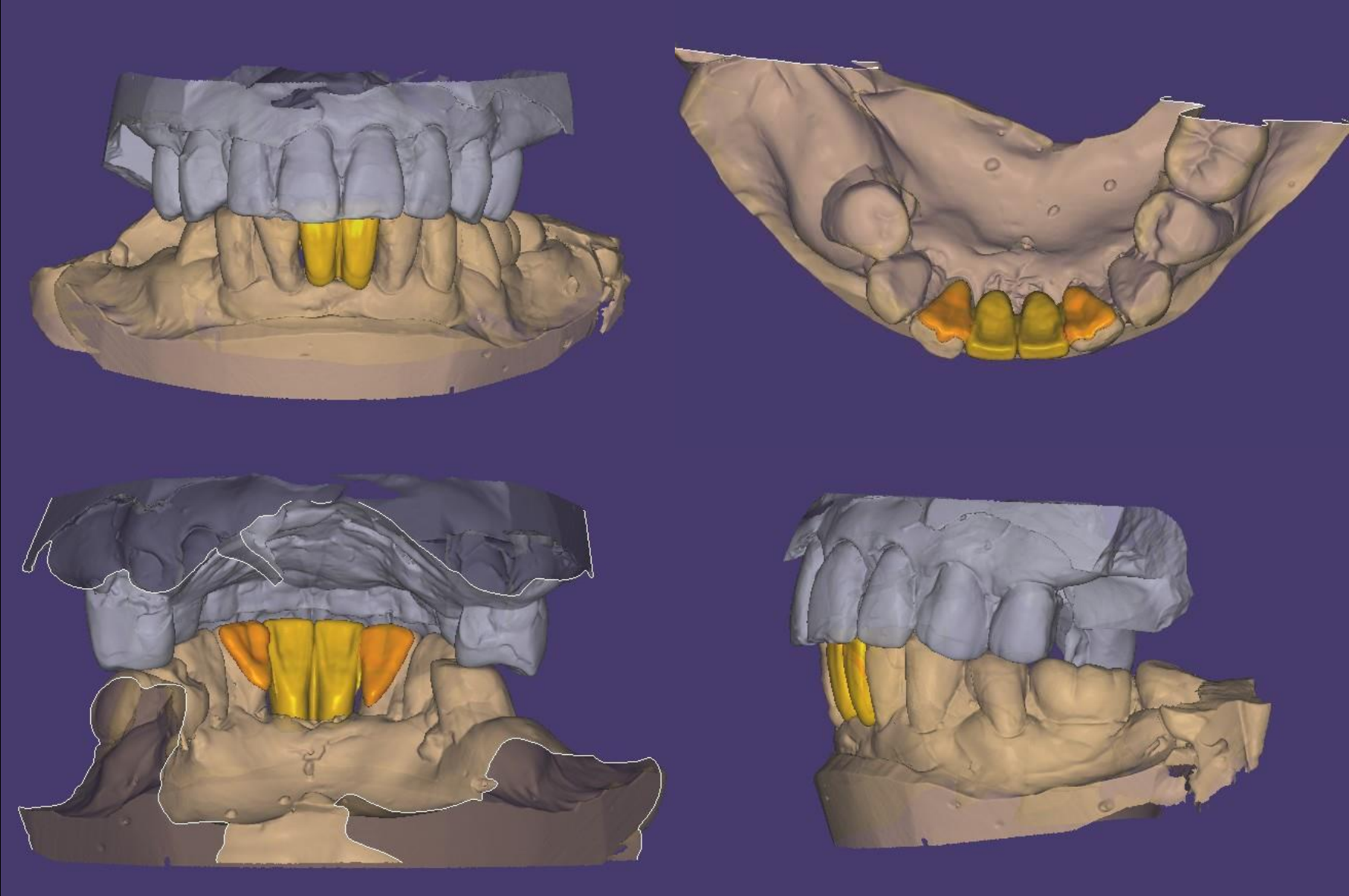
Shade taking



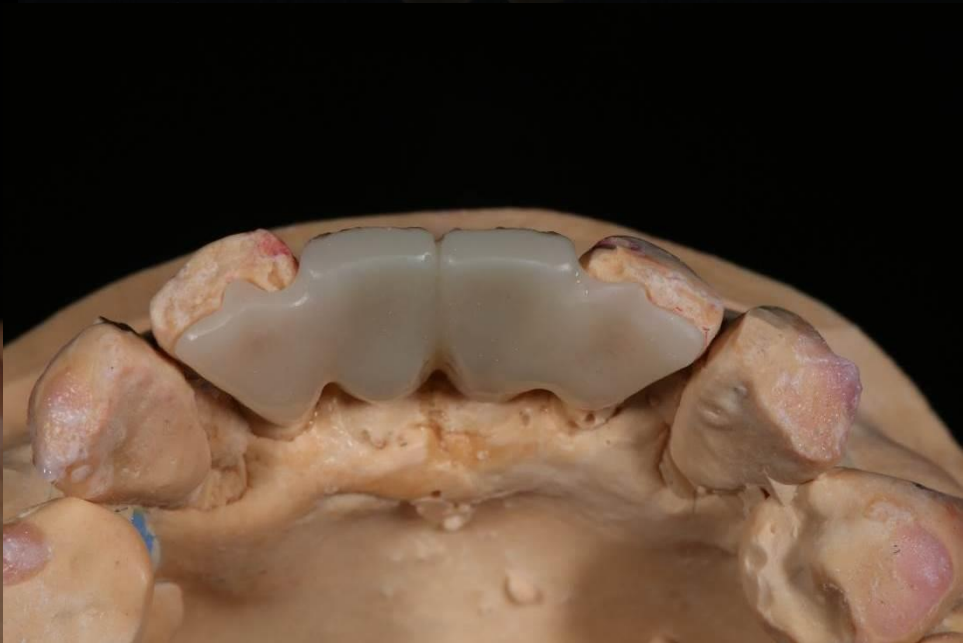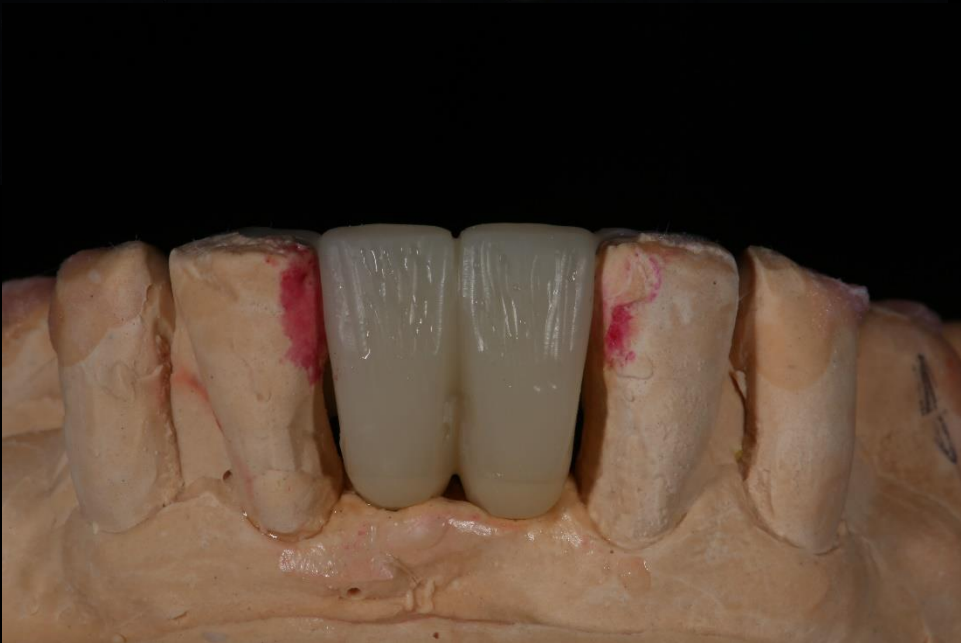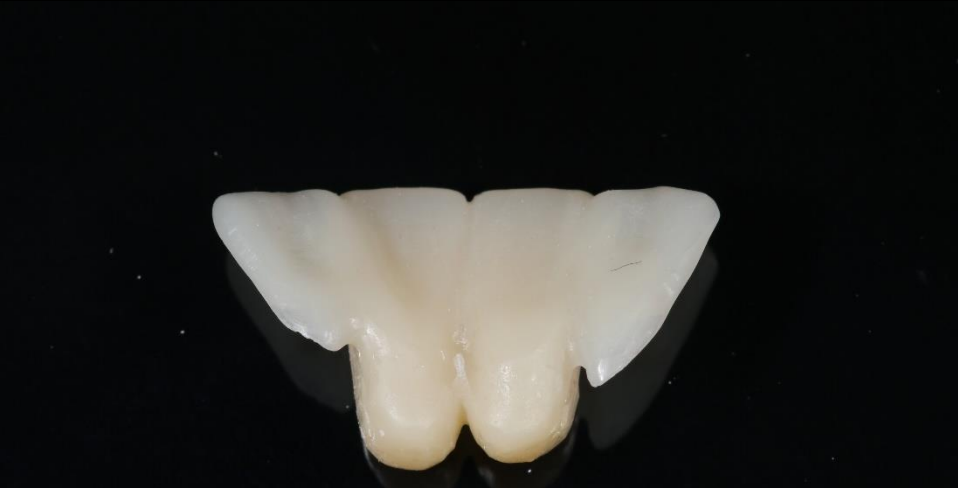
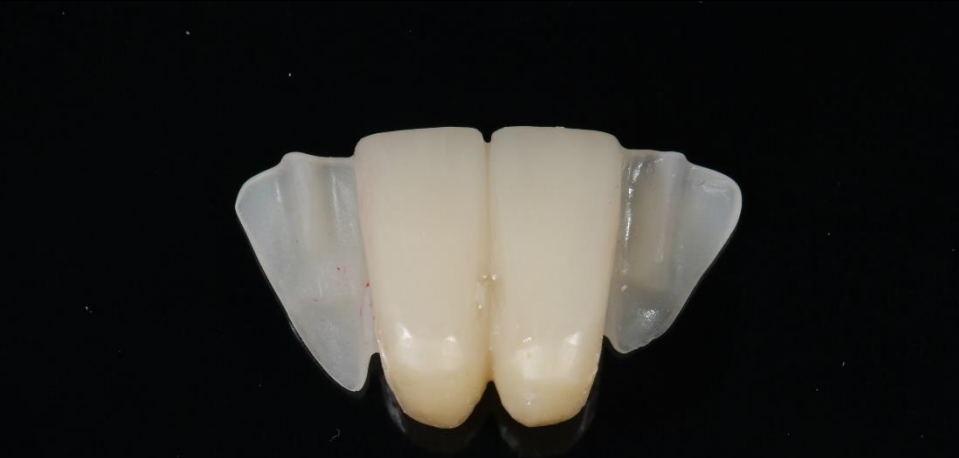Model



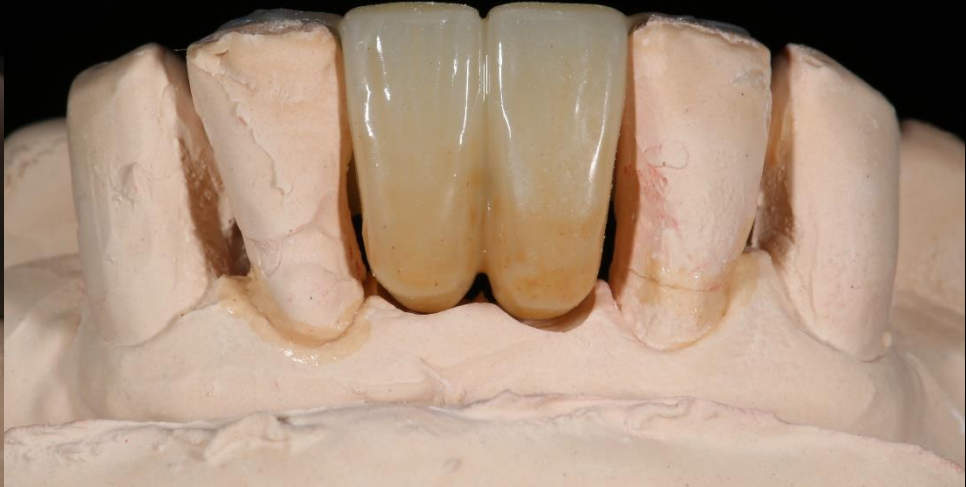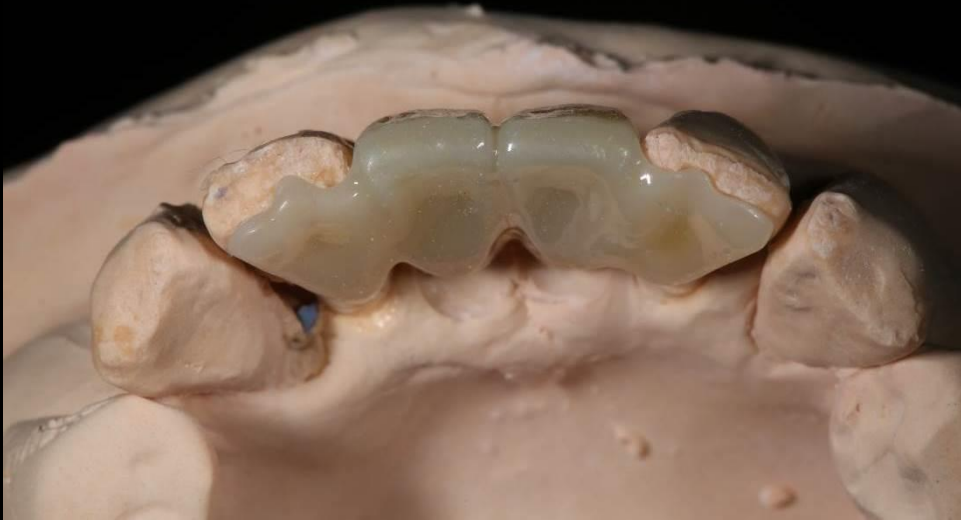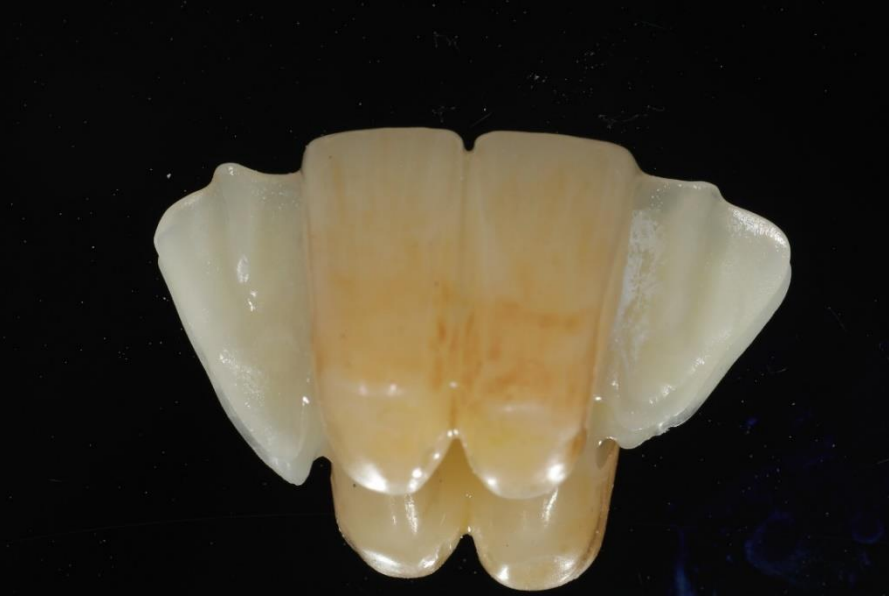CAD Design (Final prosthesis)



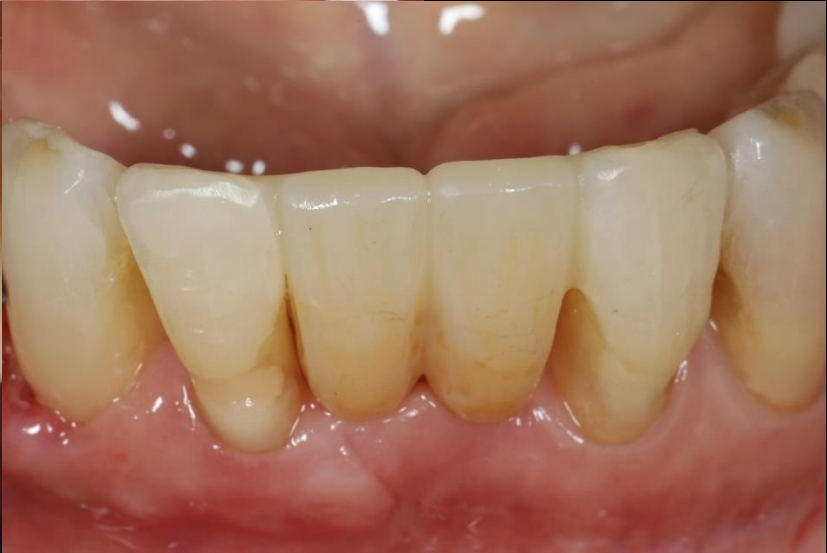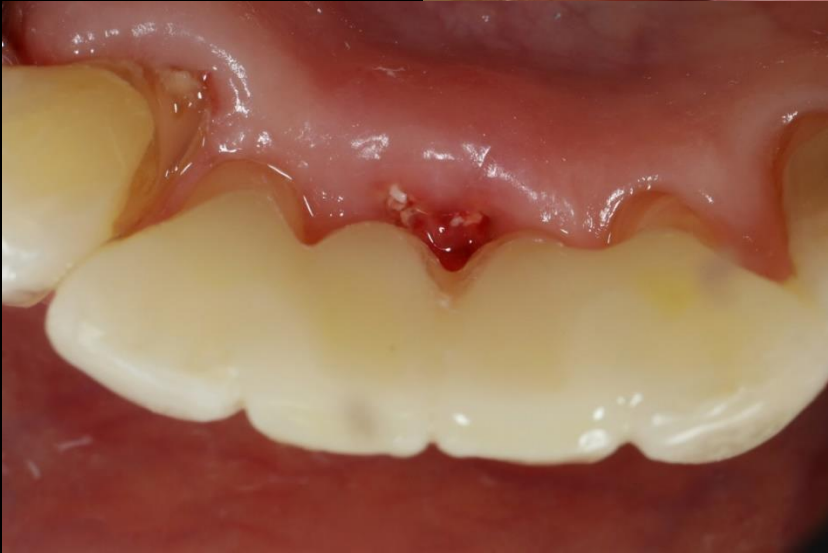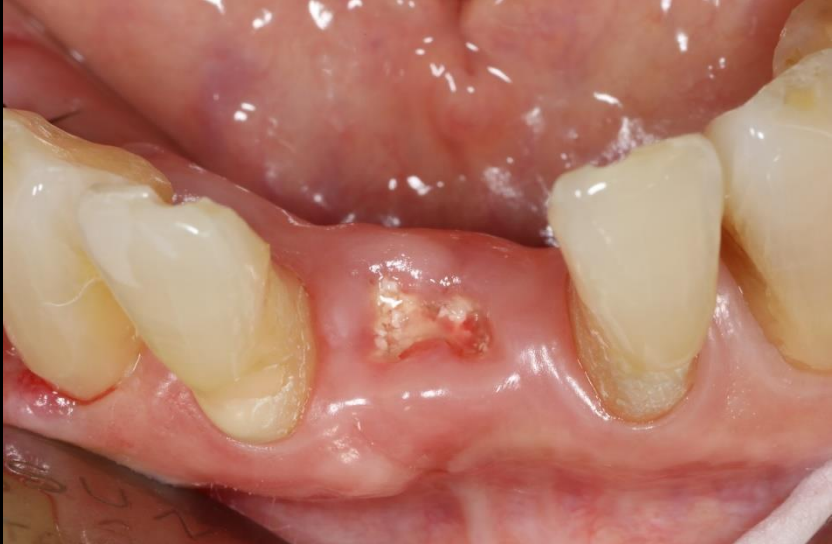Sintering



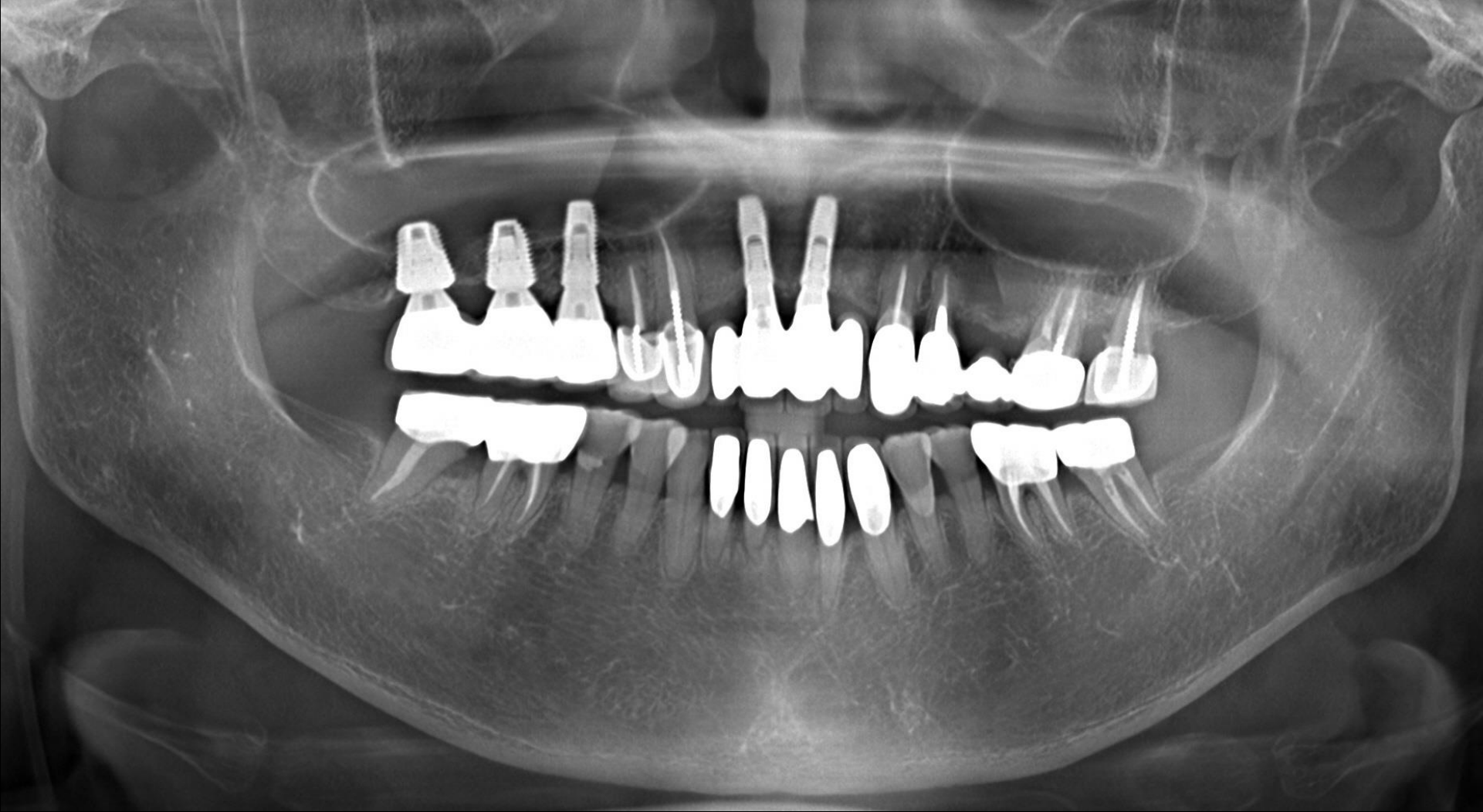Finishing



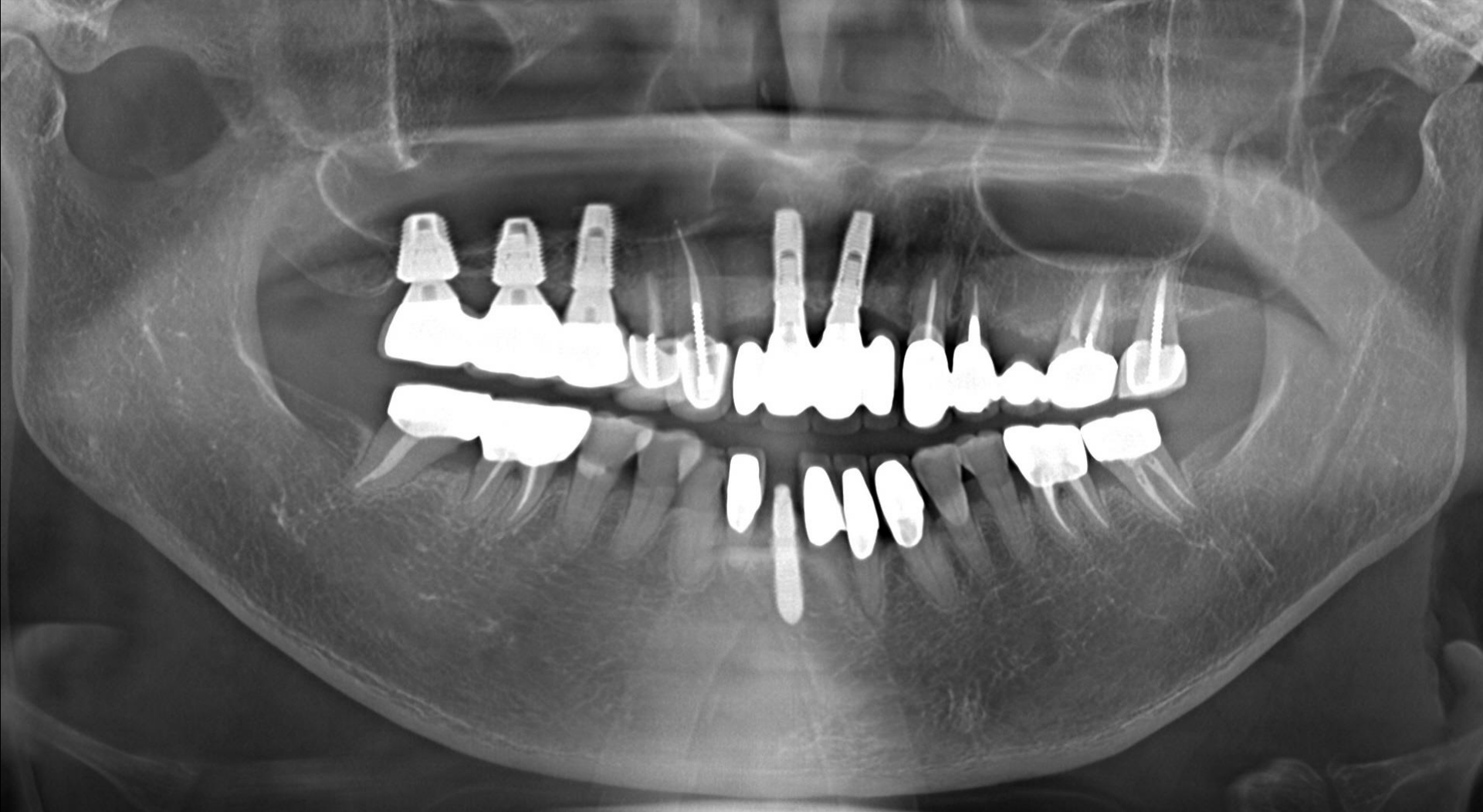Healing : 1 week / Final prosthesis (2019-08-07)



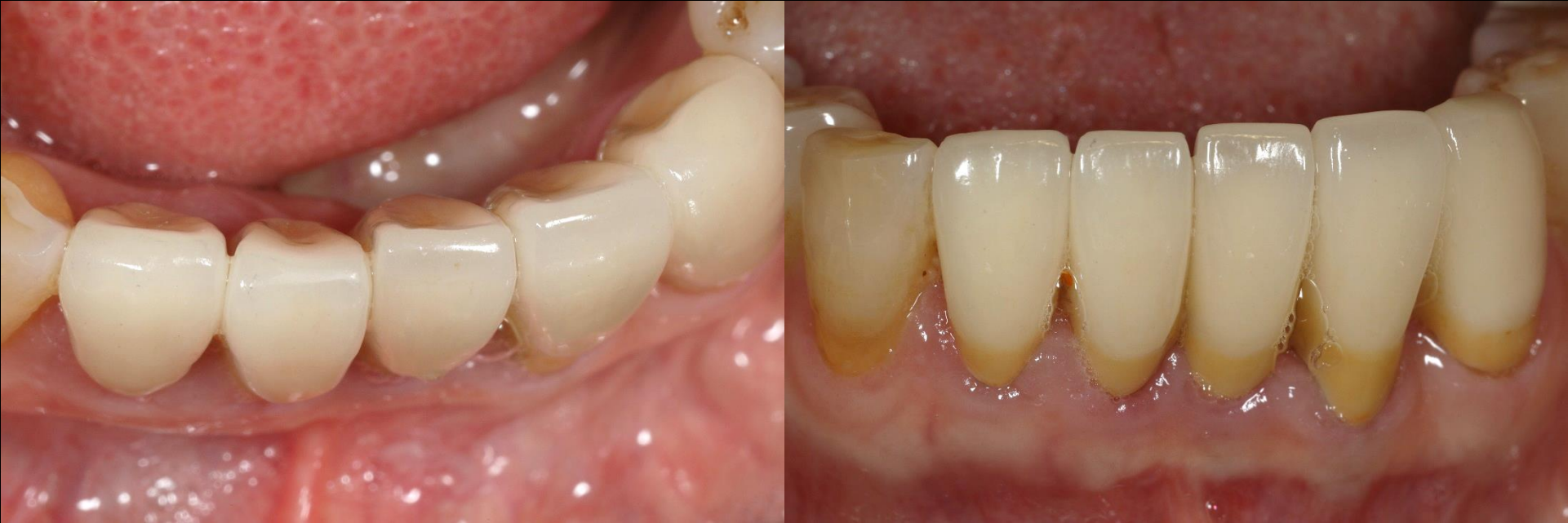Pre-op (2019-10-10)



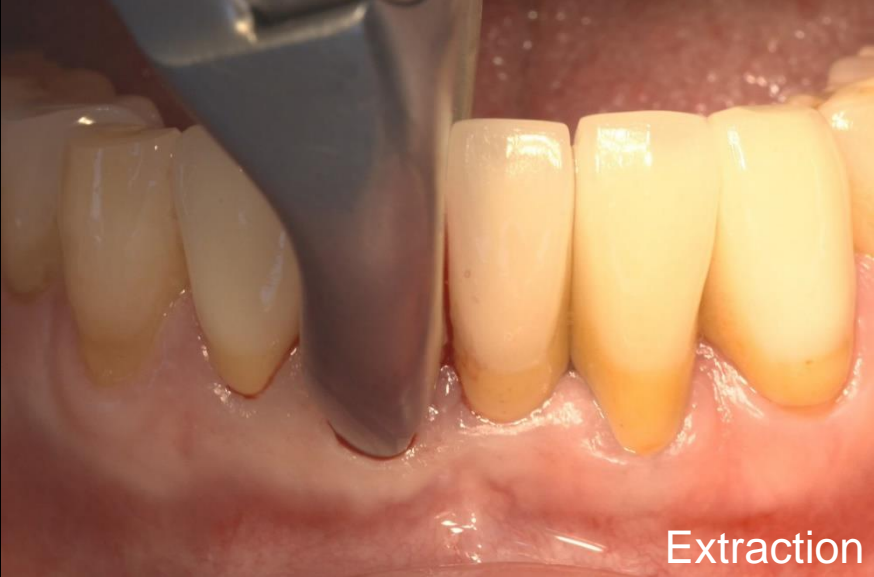Post-op (2019-10-16)



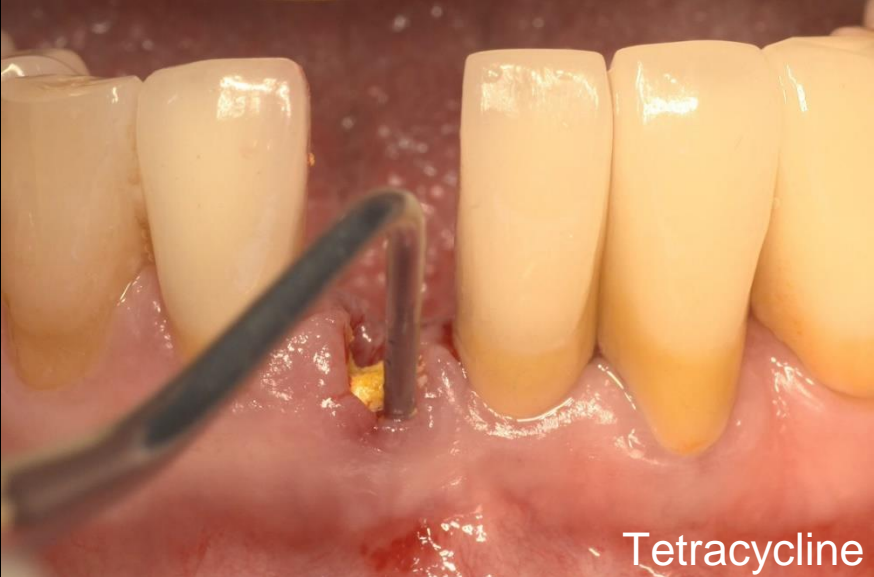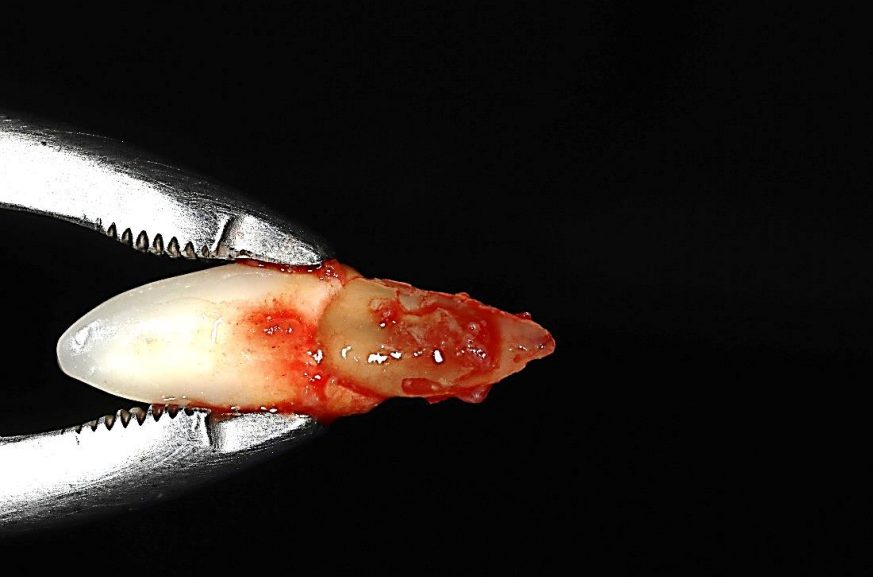Pre-op (2019-10-16)



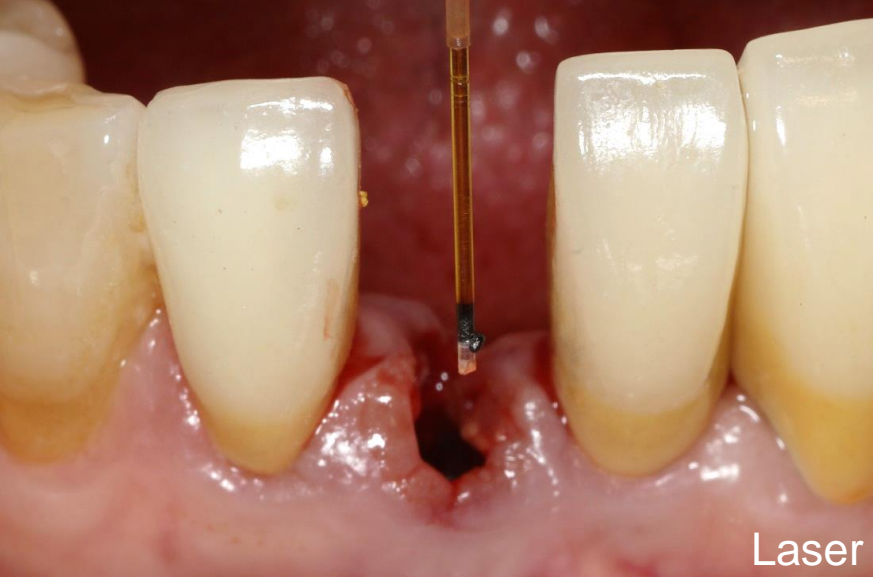Surgery (2019-10-16)



Extraction

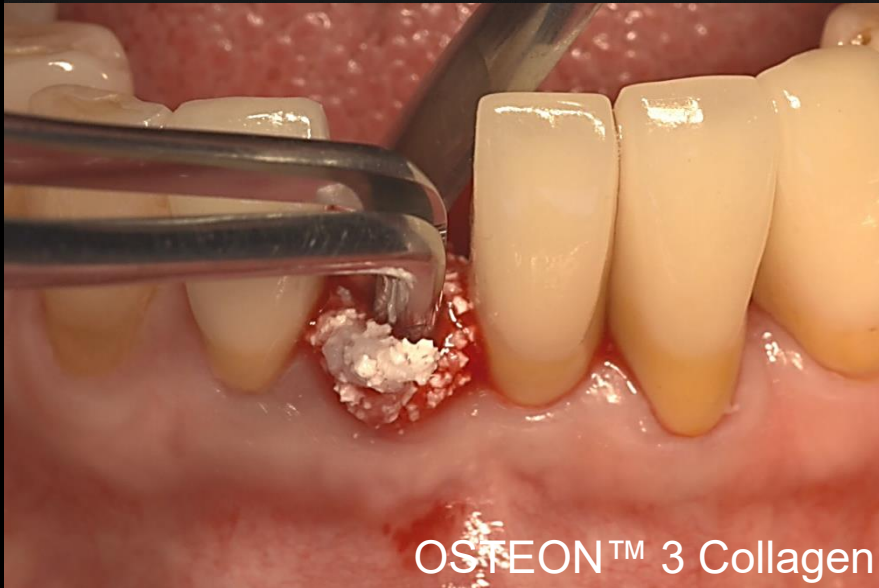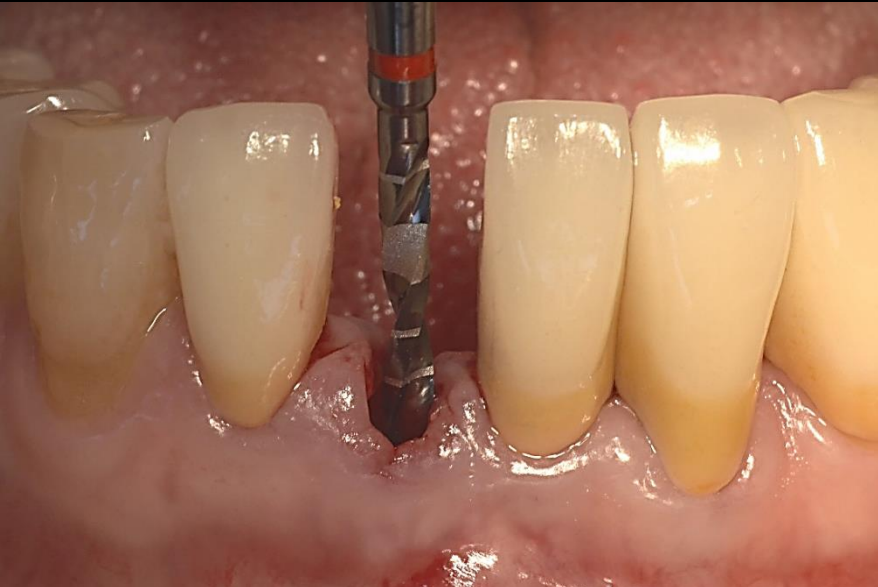



Tetracycline



Laser

Surgery (2019-10-16)

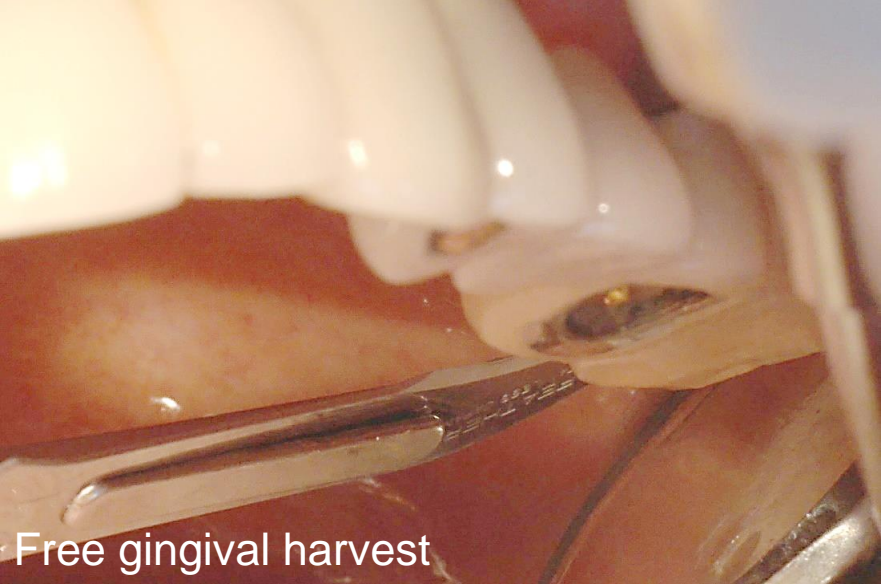
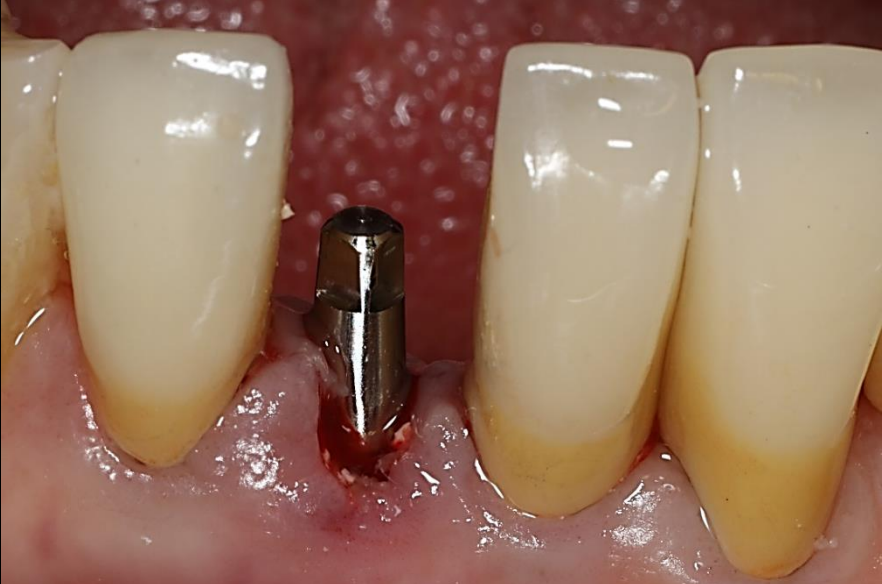
OSTEON™ 3 Collagen

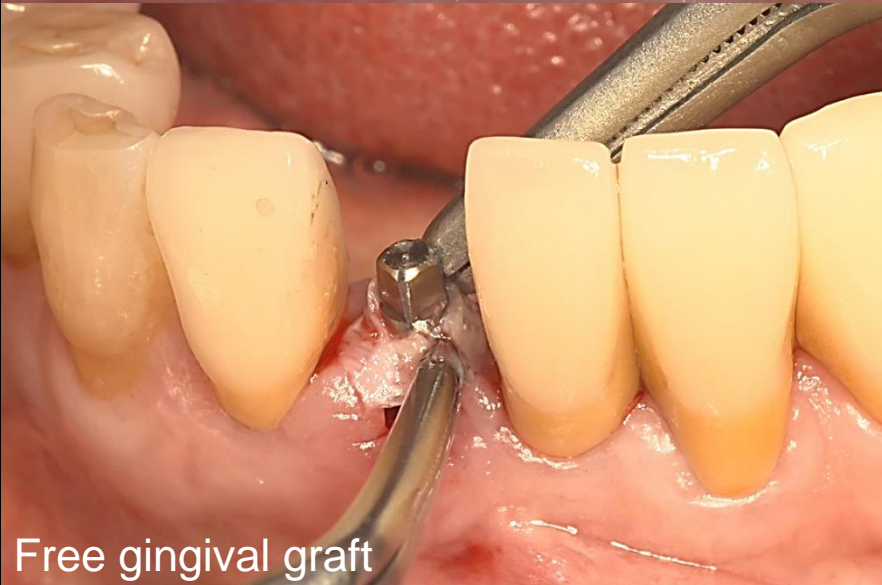

SlimLine (281512)

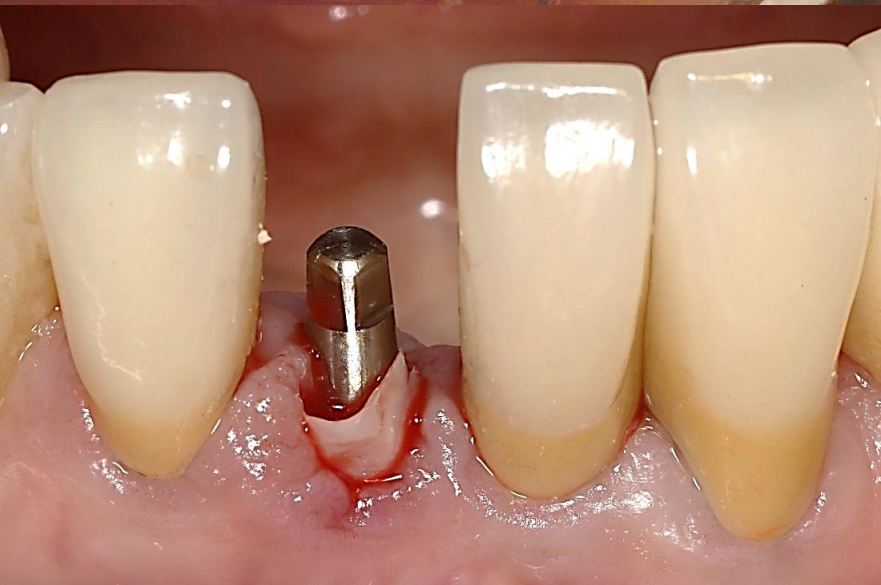
Surgery (2019-10-16)



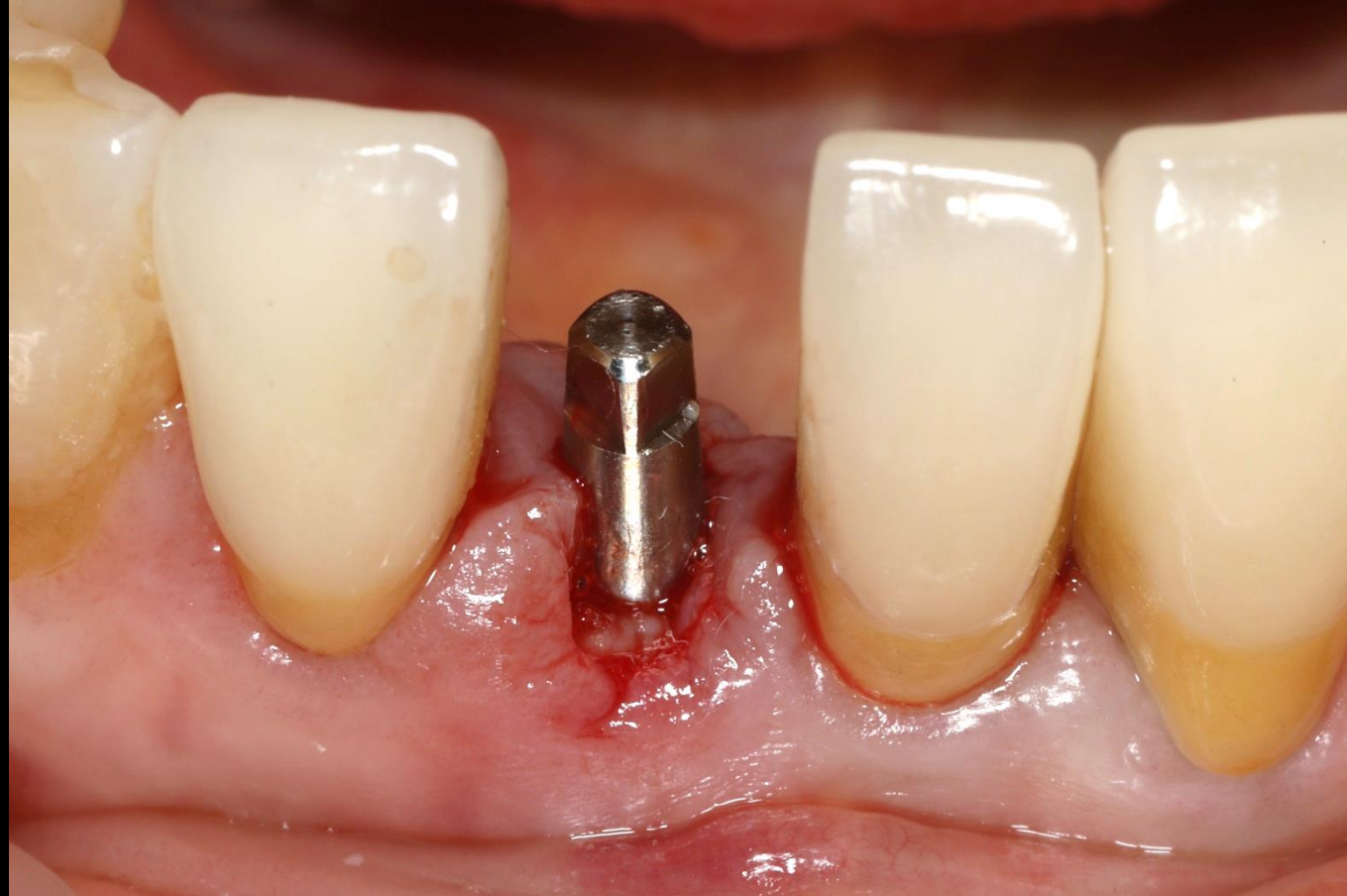
Free gingival harvest



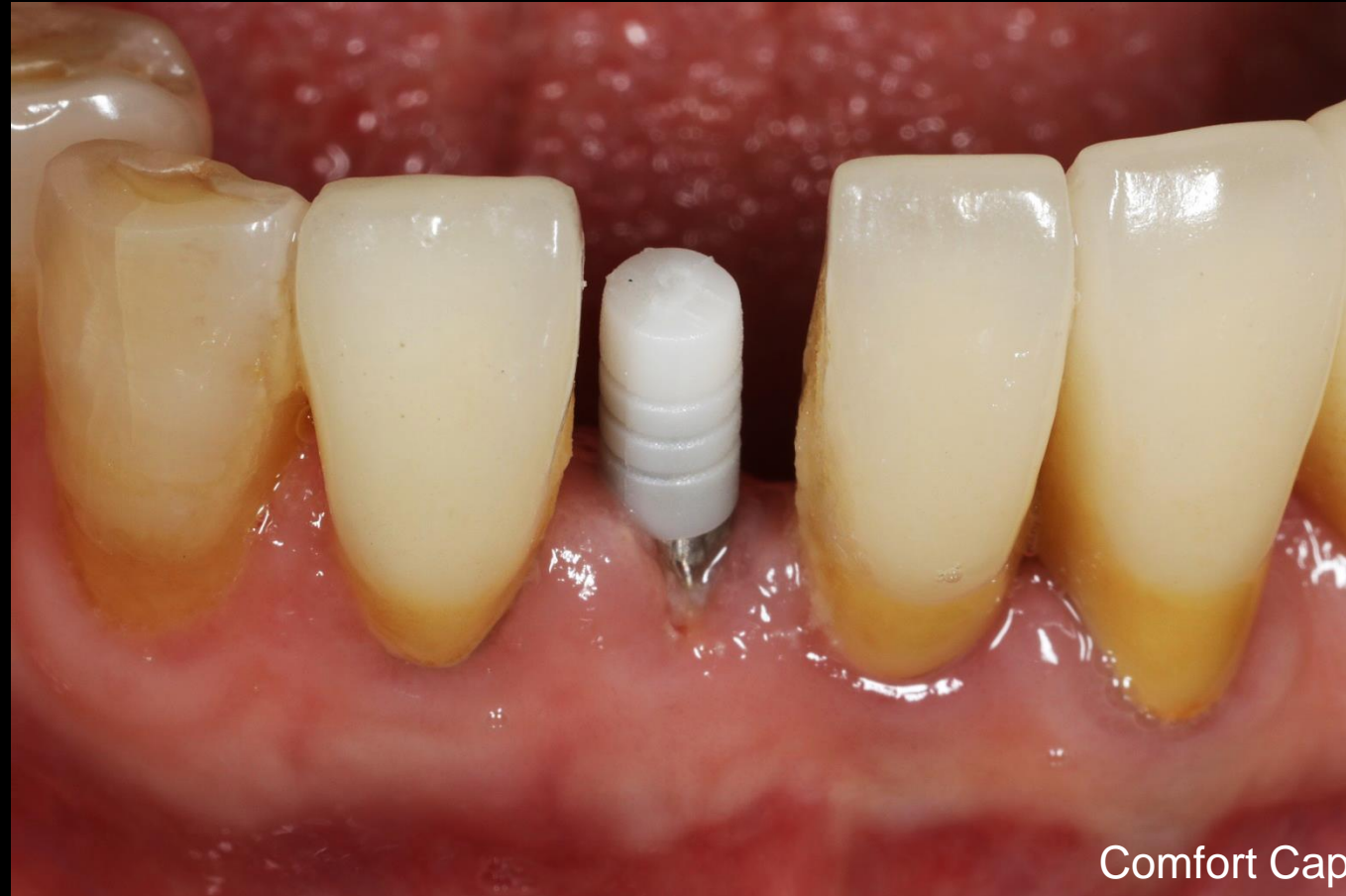Free gingival graft



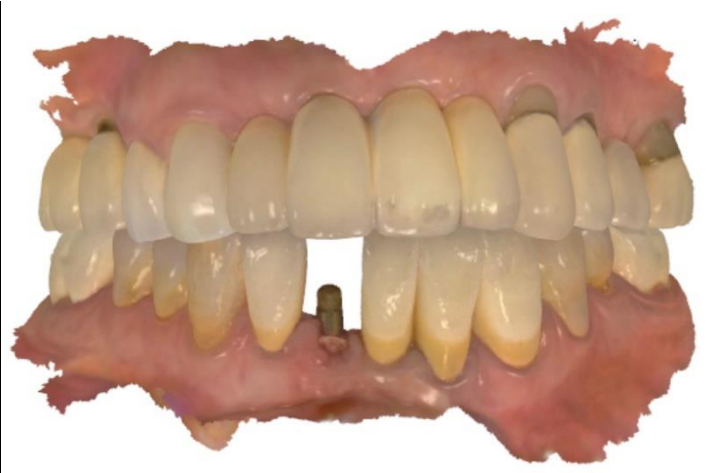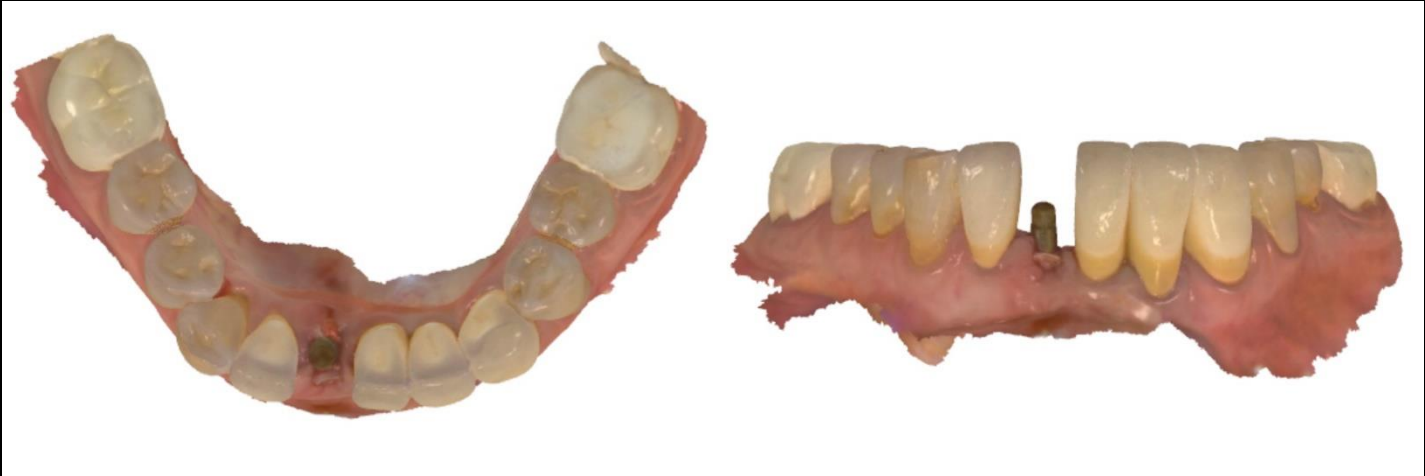Post-op (2019-10-16)



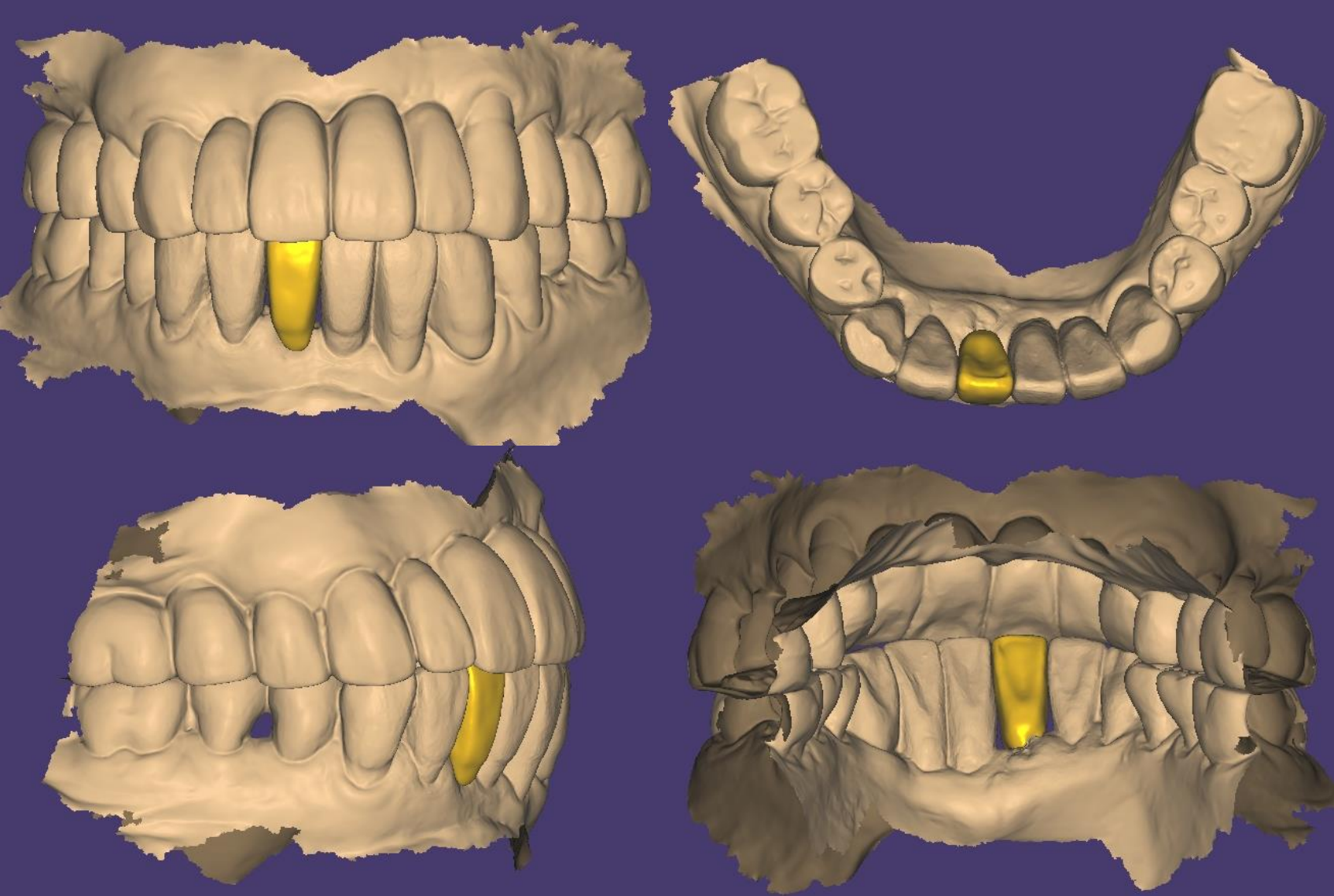
Healing : 1 week (2019-10-25)



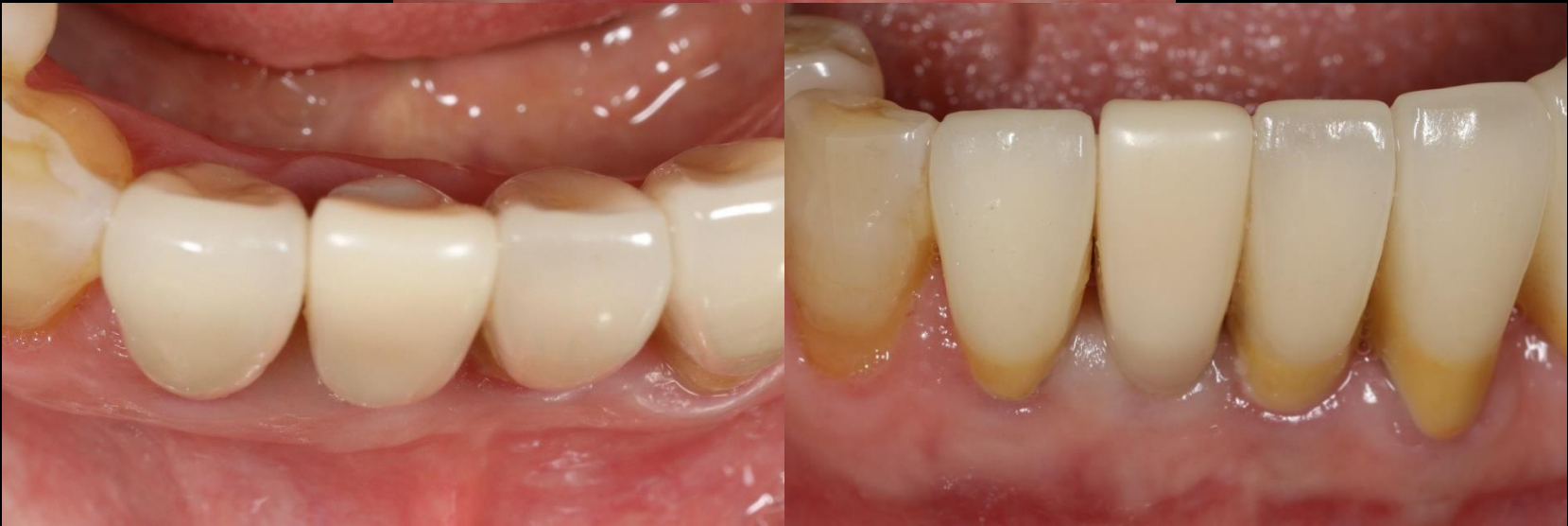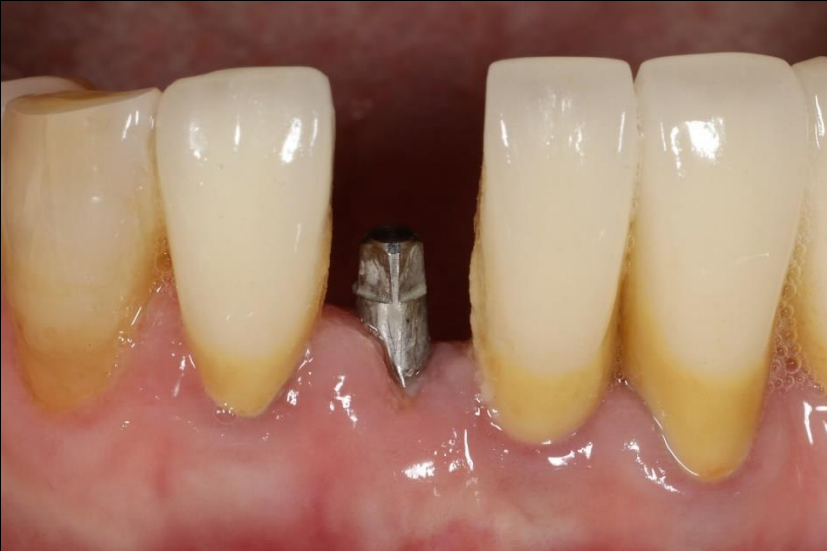Intra Oral Scanning



CAD Design (Temporary)



Provisional restoration (2019-10-25)

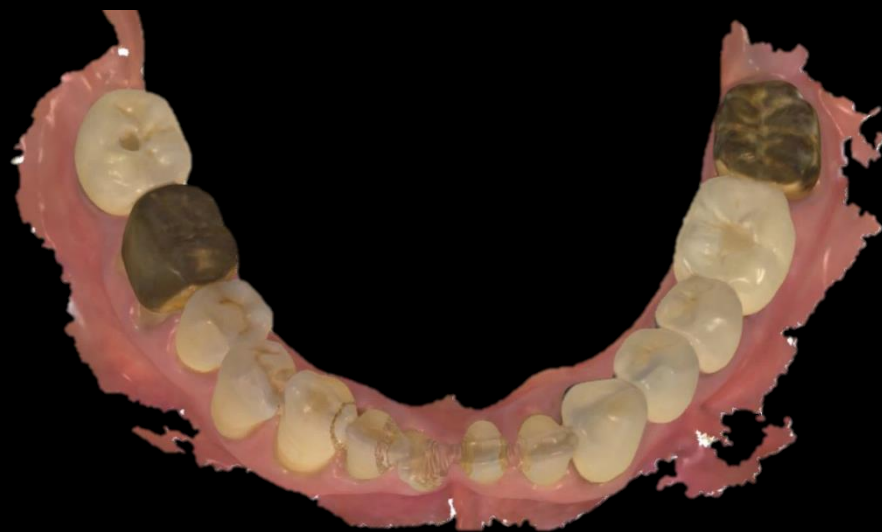
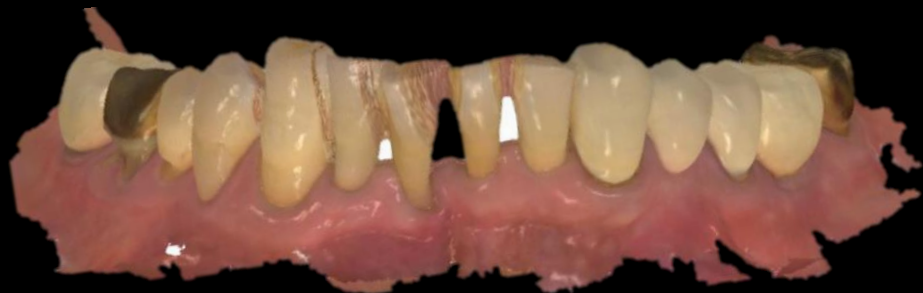
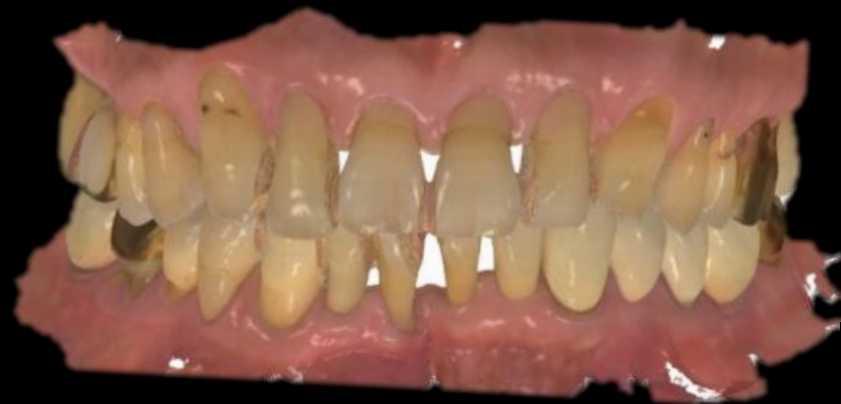Immediate Implantation

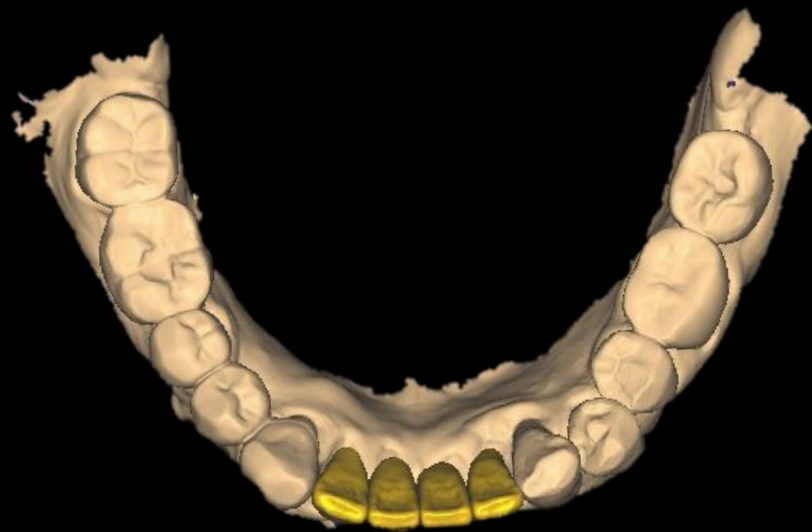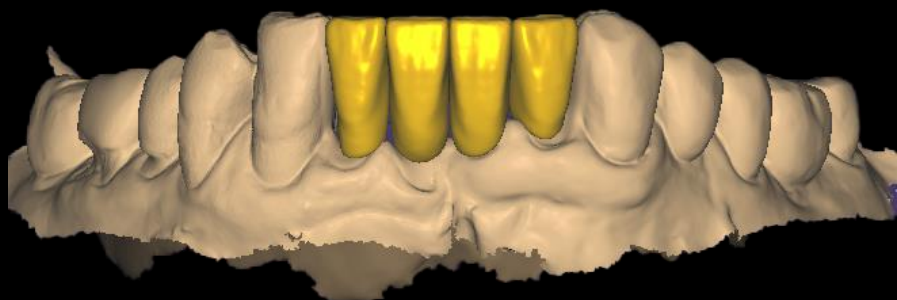
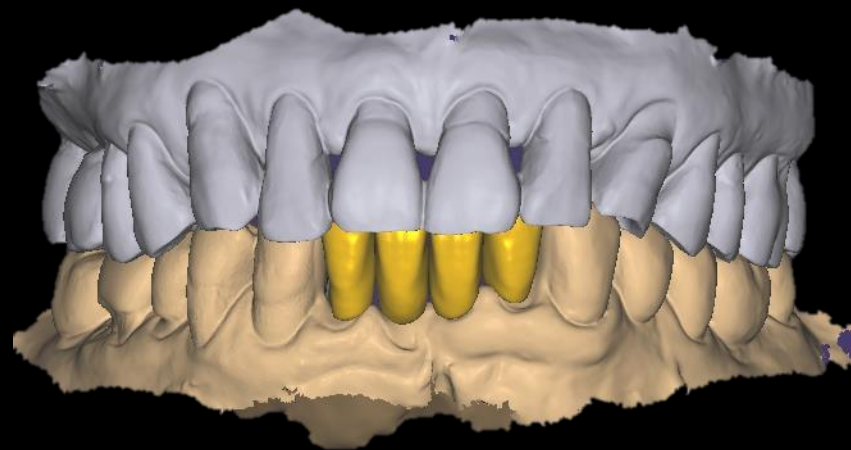
How to avoid unknown infection & failure

- Premedication
- Irrigation & granulation tissue removal


Intra Oral Scanning (2021-03-17)



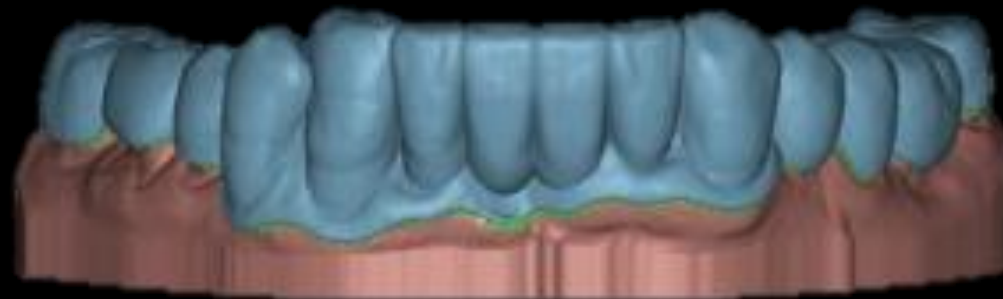
Virtual Set up



Essix Temporary Design

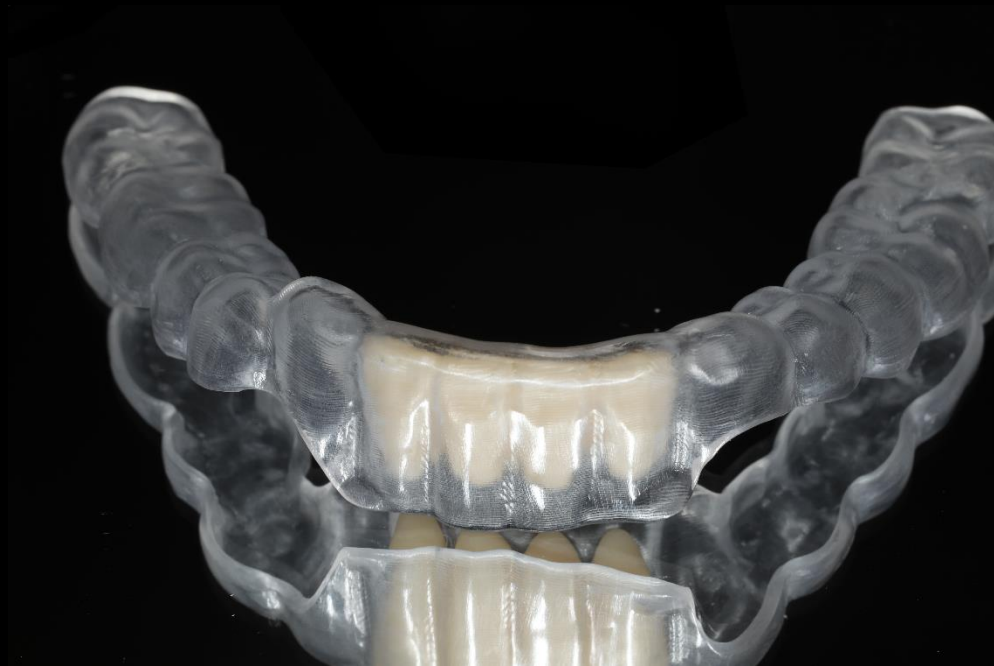

<Milling>

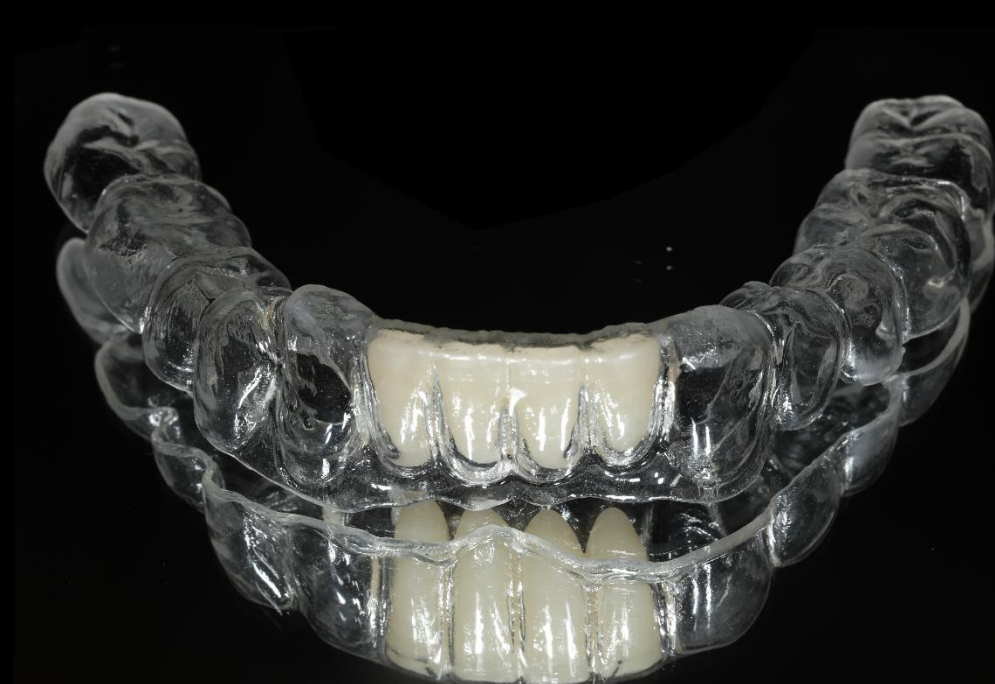

<Printing>

Essix Temporary

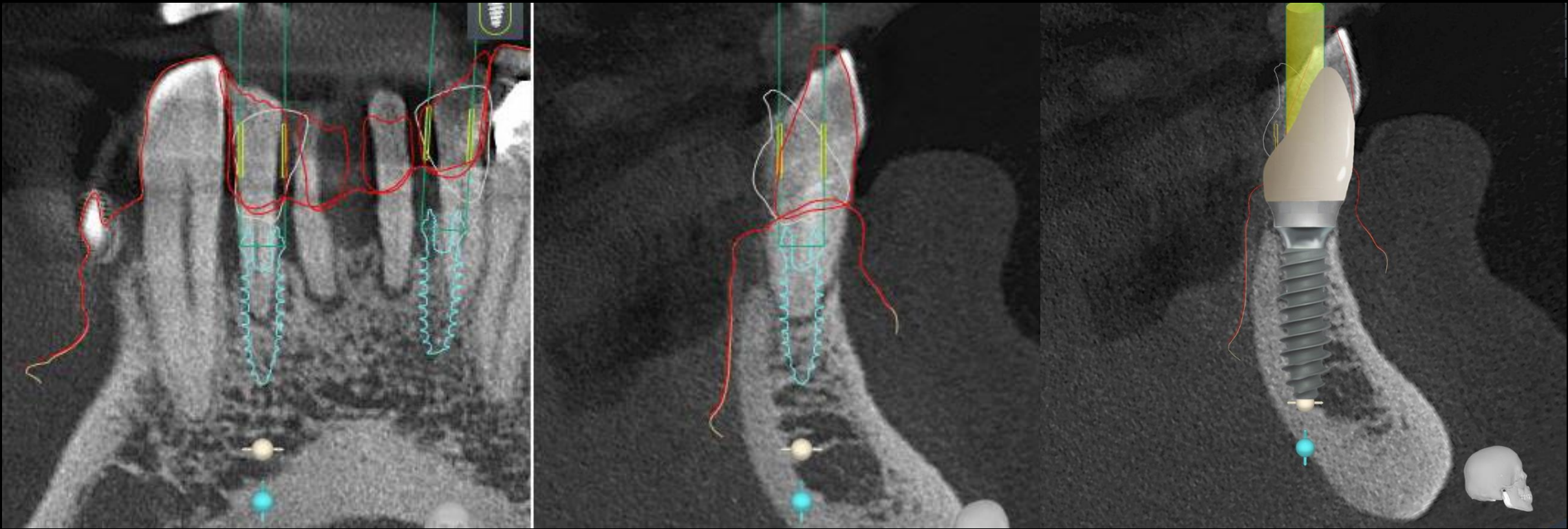


<Milling>

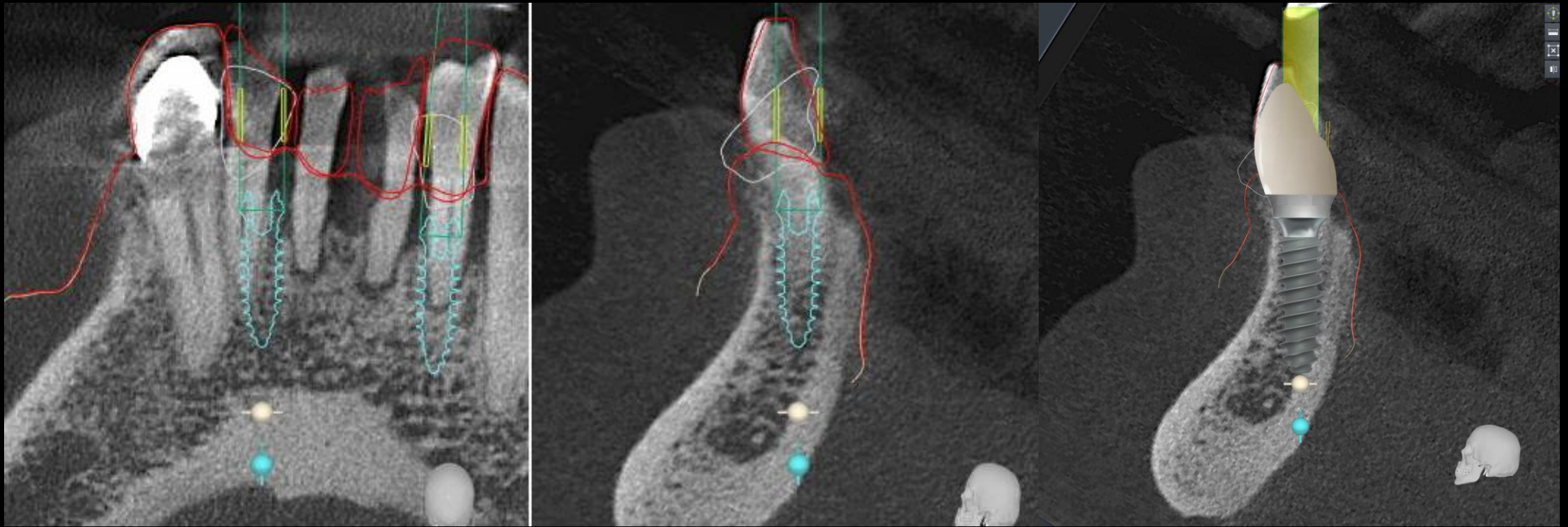


<Printing>

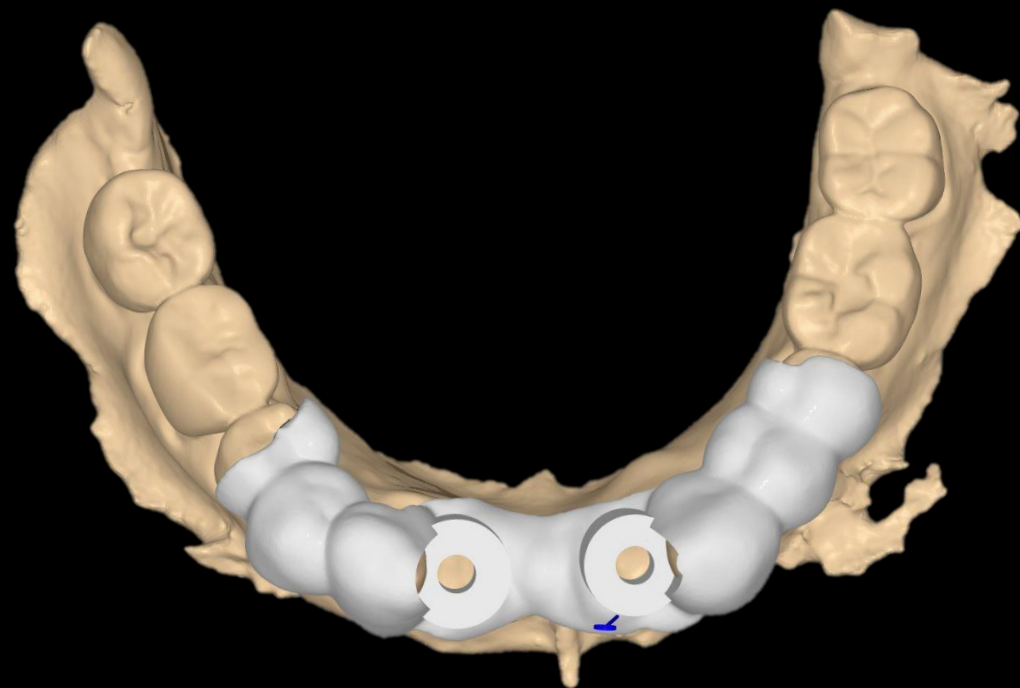
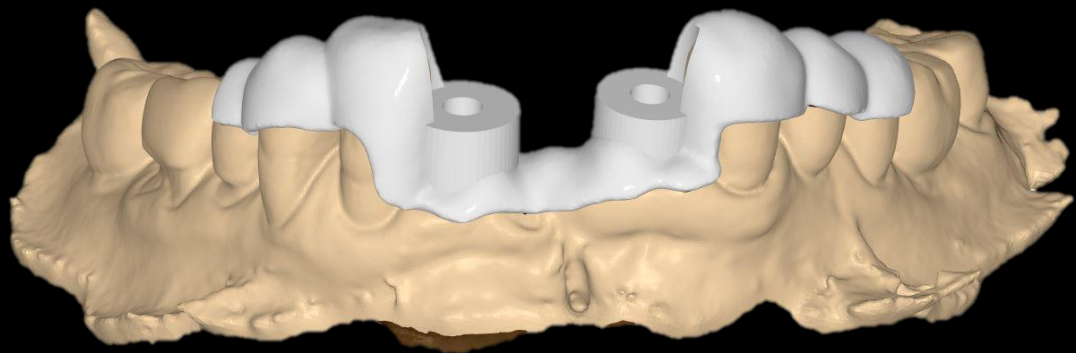
Implant Planning (#42 bright Tissue Level Ø3.0 * 9mm)



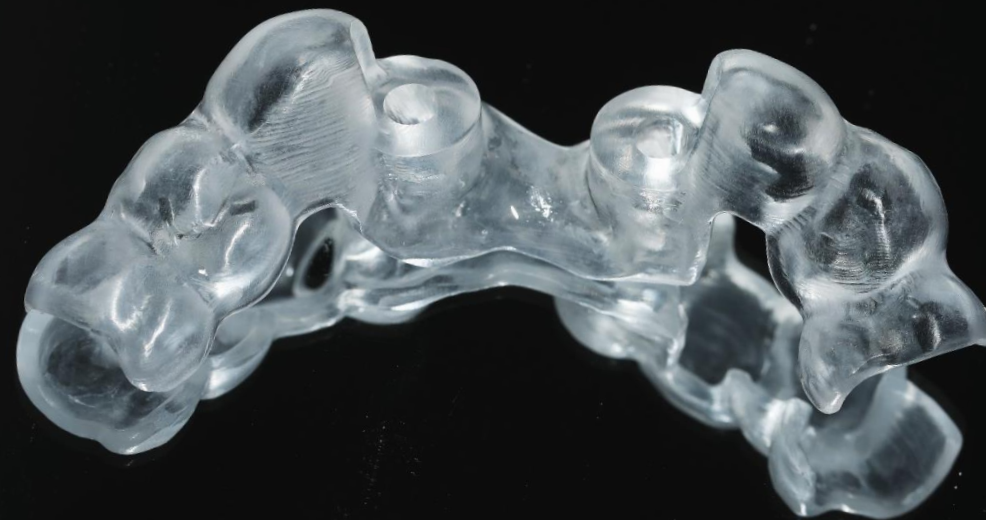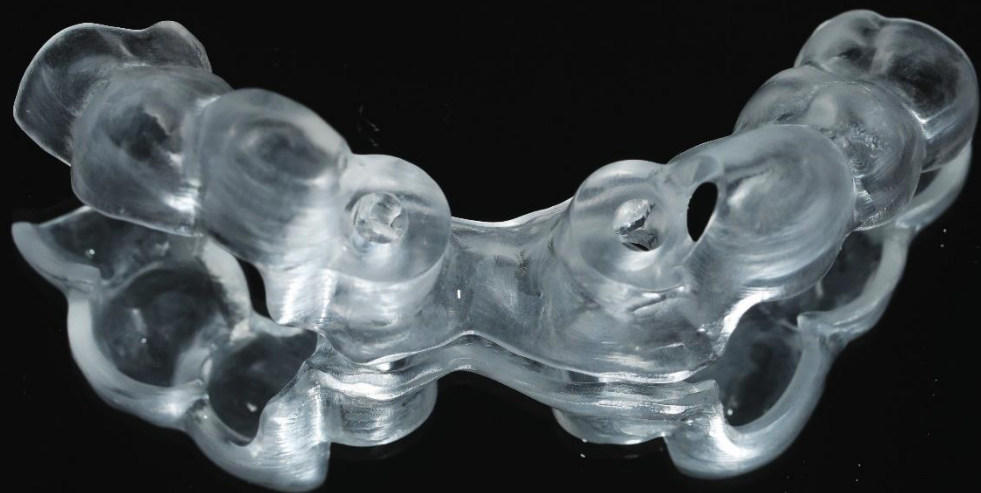Implant Planning (#32 bright Tissue Level $\text{\O}3.0 * 9\text{mm}$)



Stent design

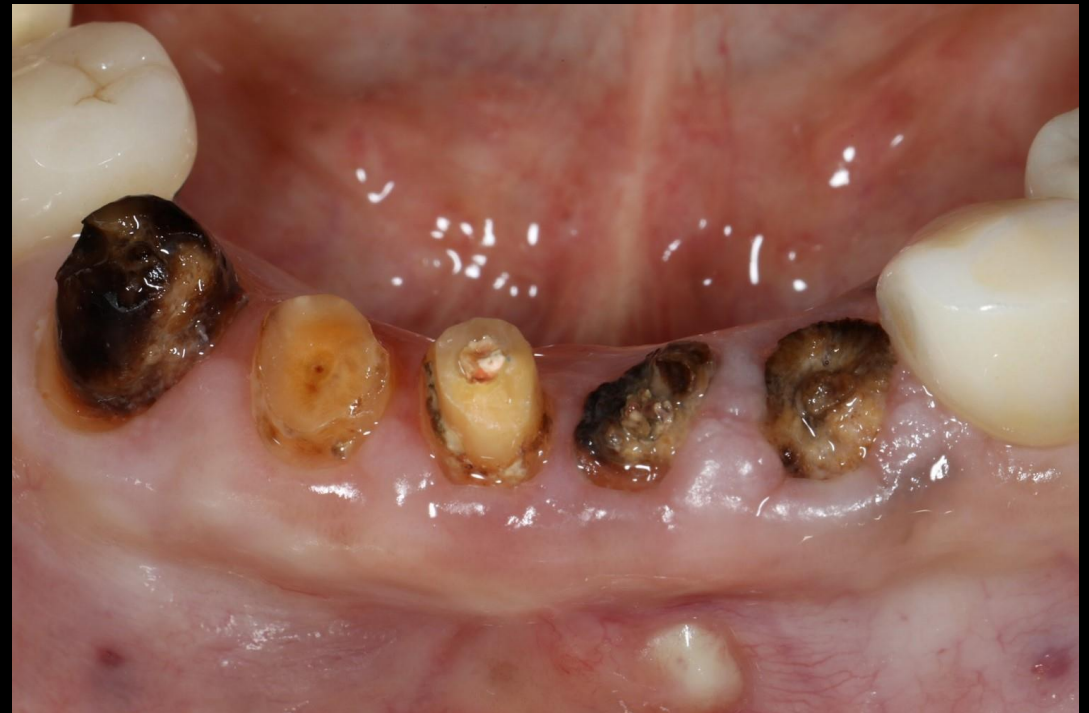
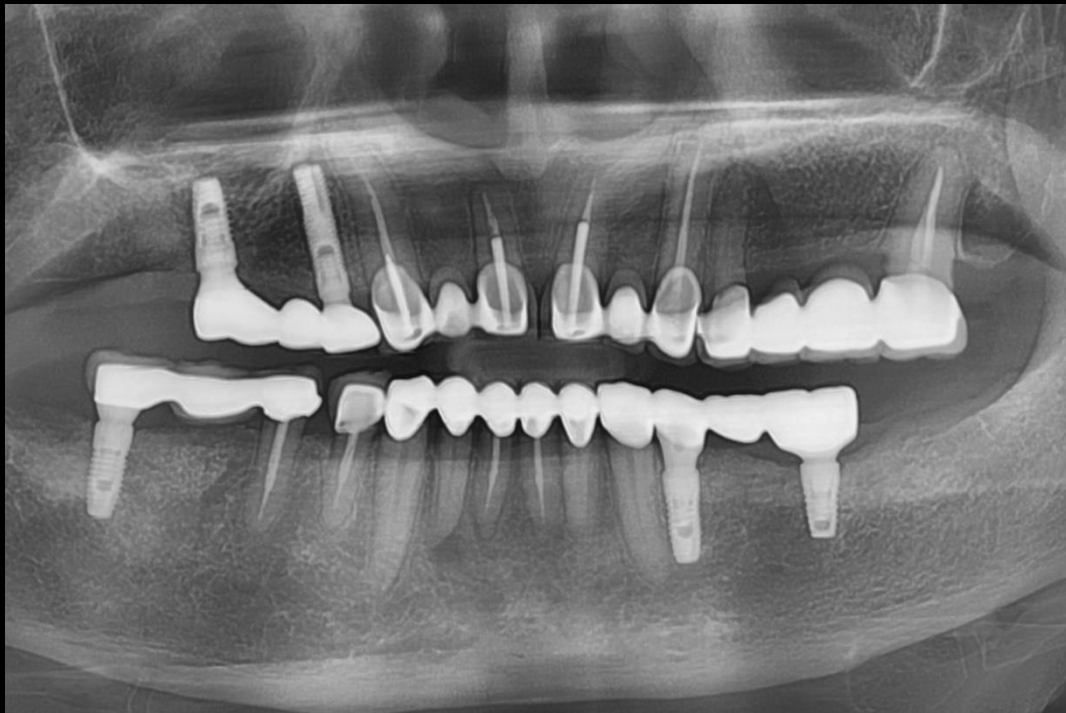
Milling Stent



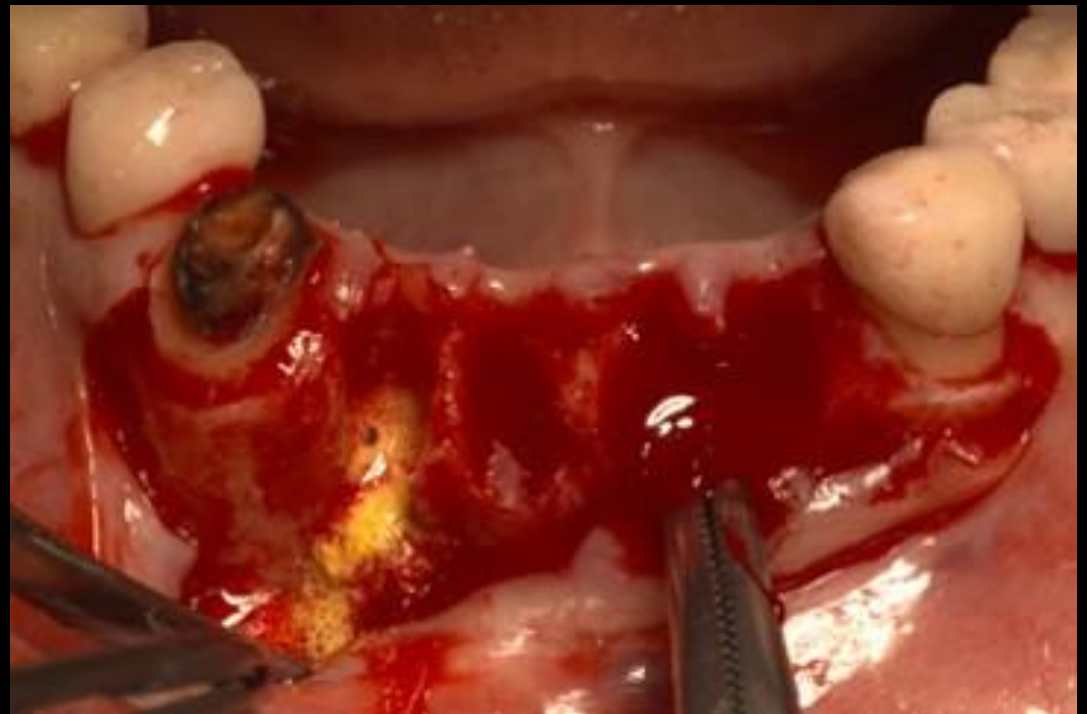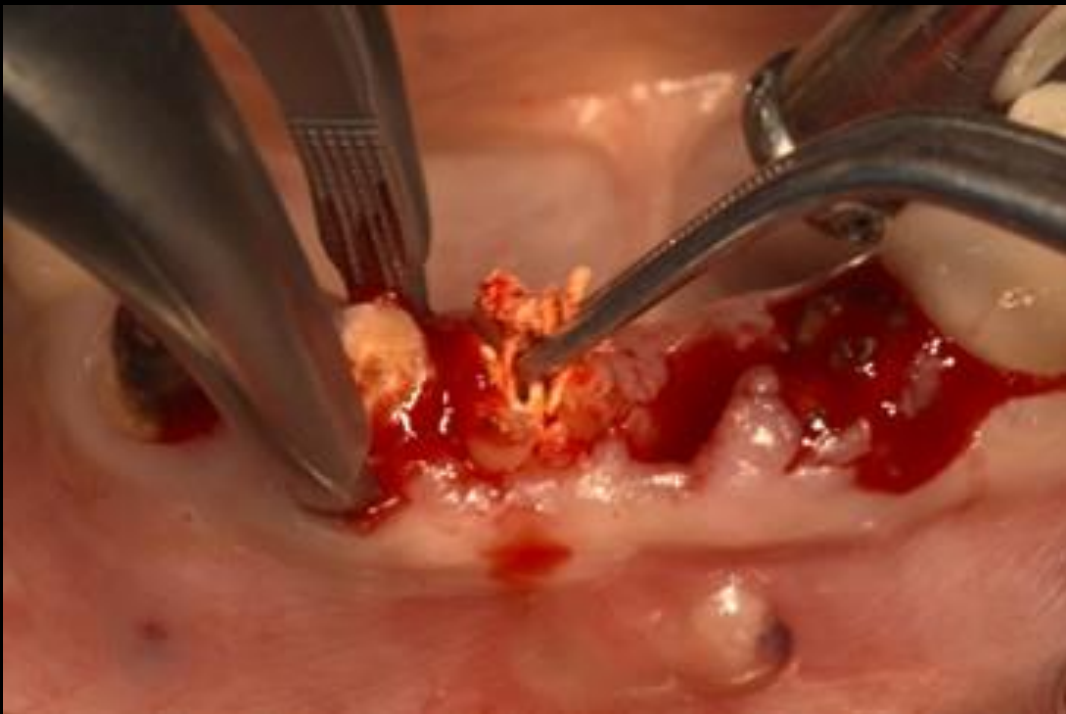
Similar case 1

Immediate implantation & GBR



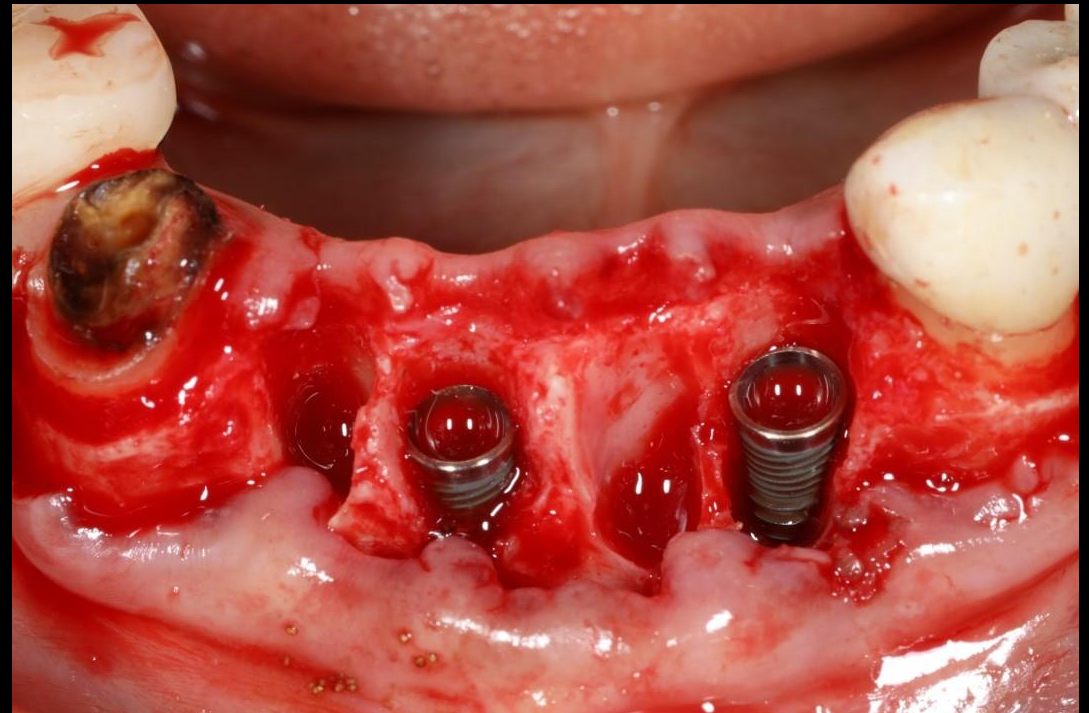
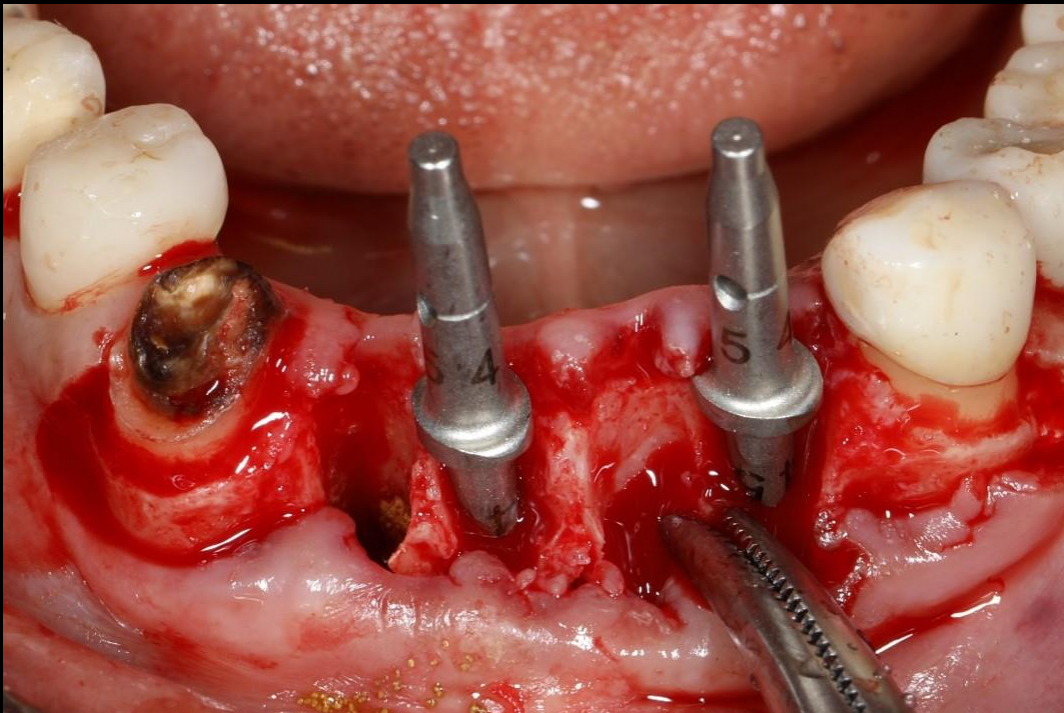
Similar case 1

Immediate implantation & GBR



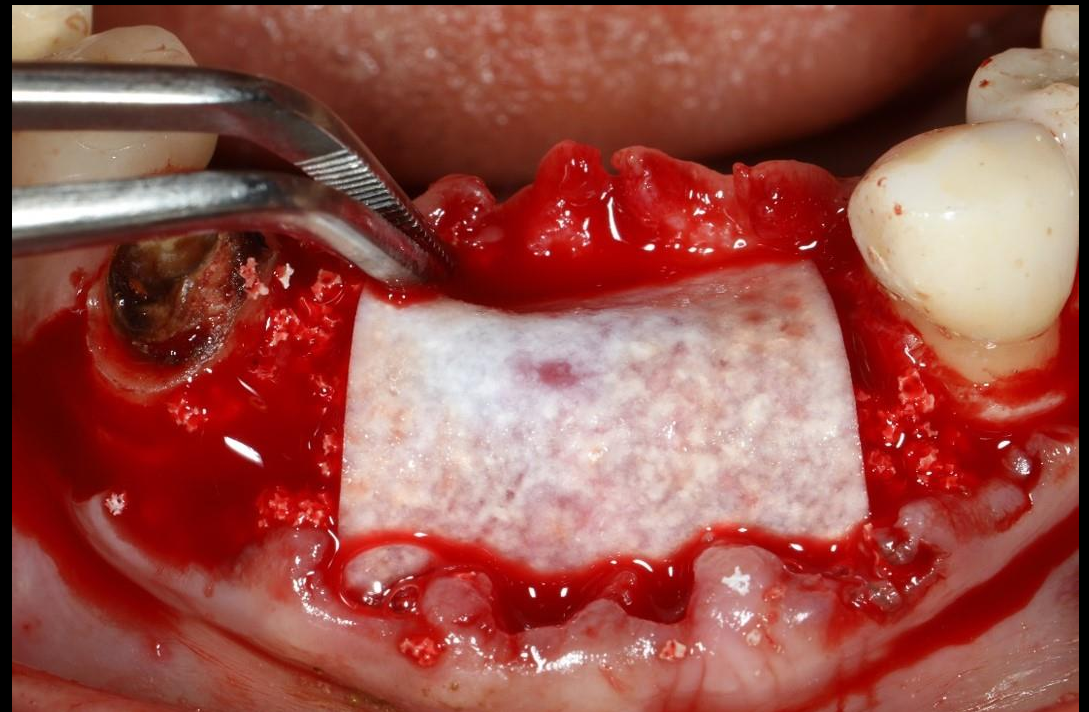
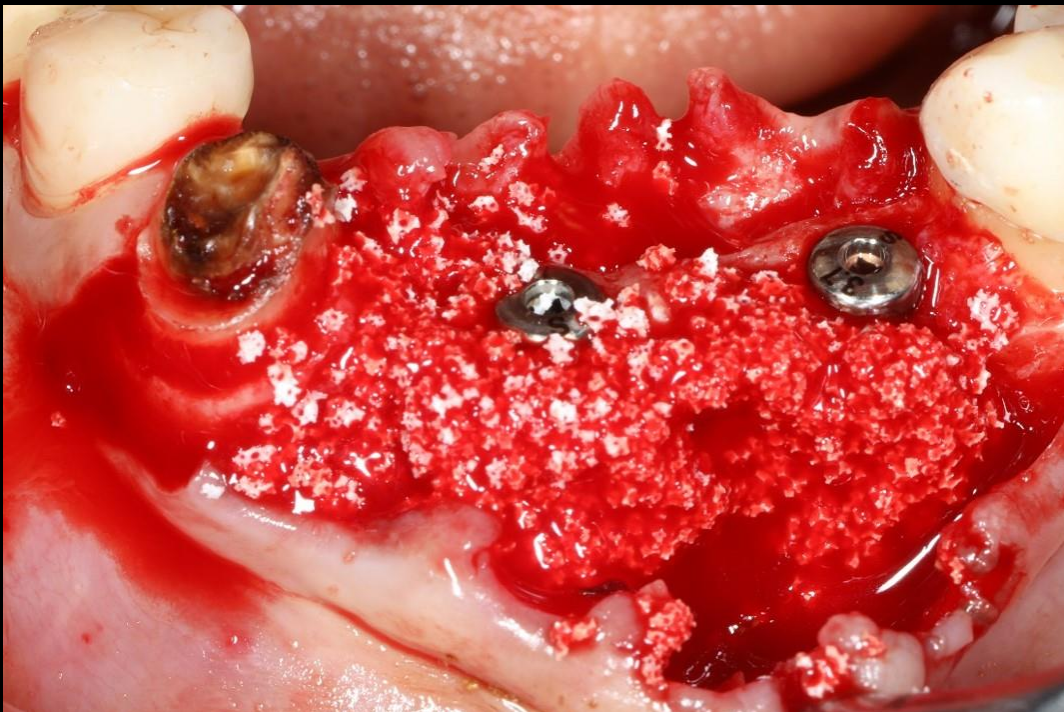Similar case 1

Immediate implantation & GBR



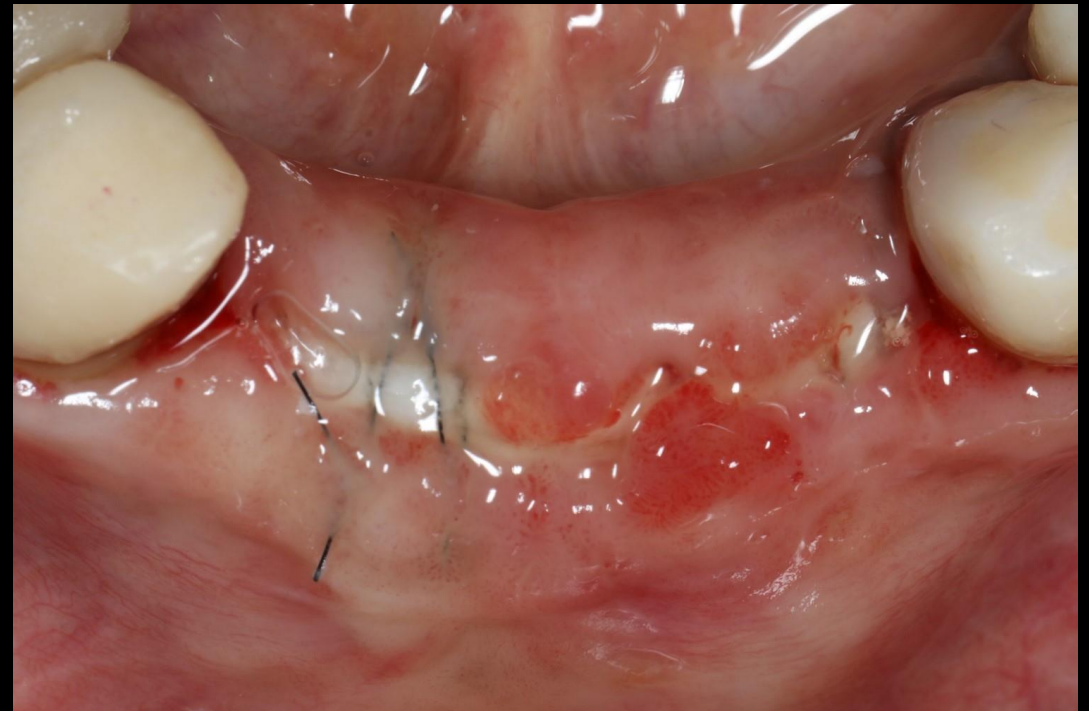
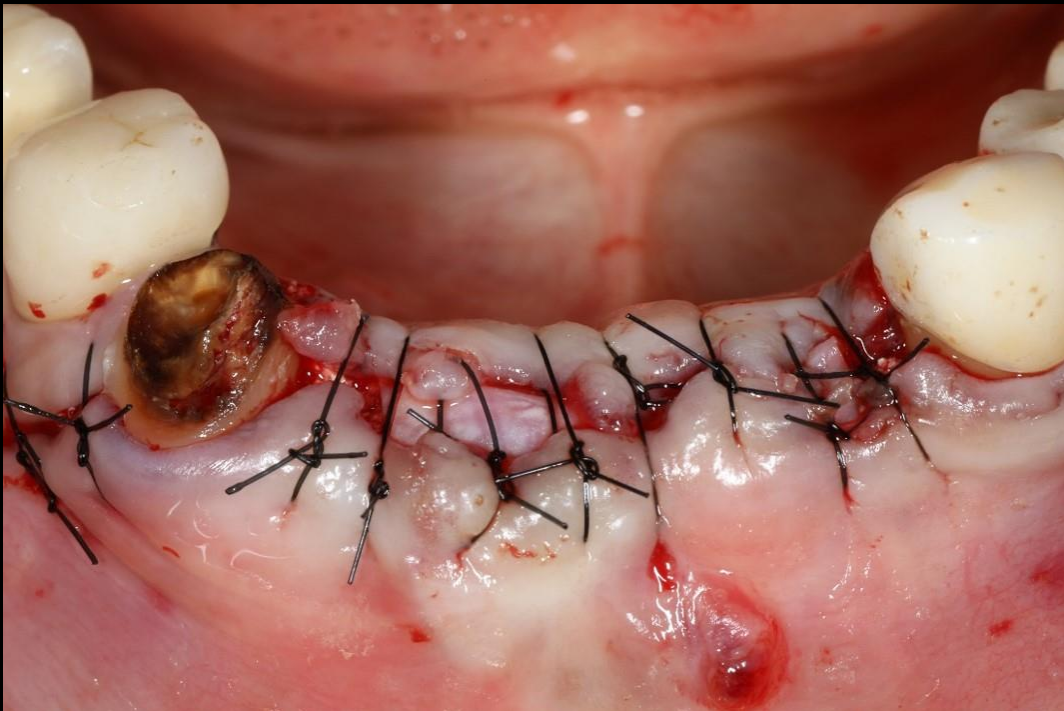Similar case 1

Immediate implantation & GBR



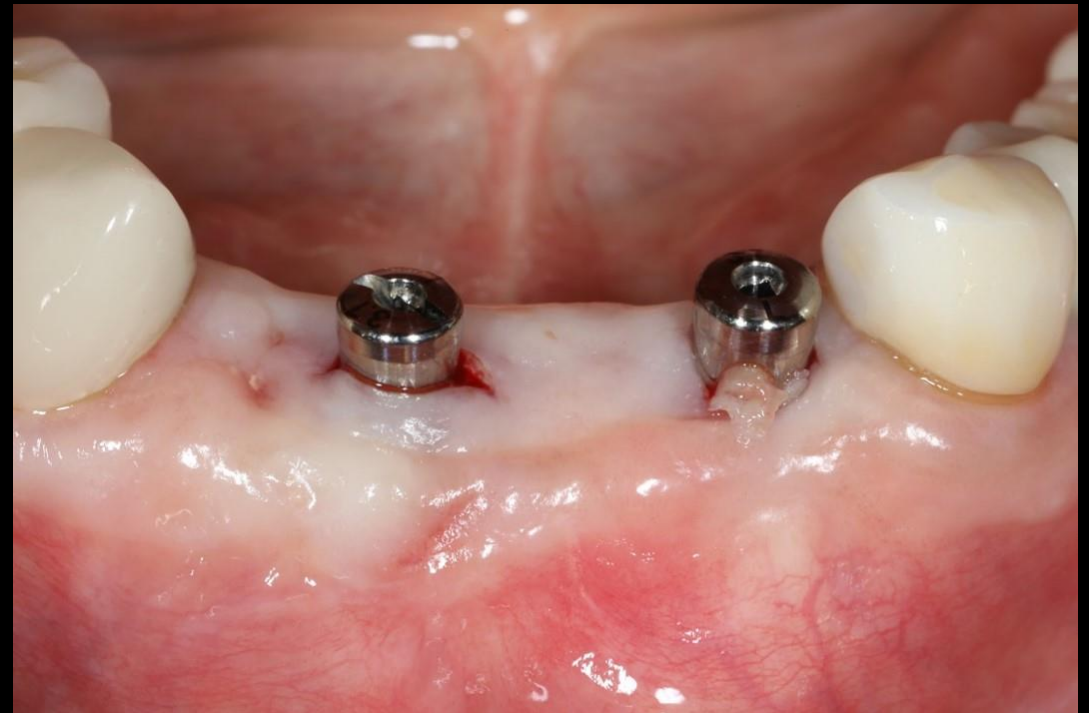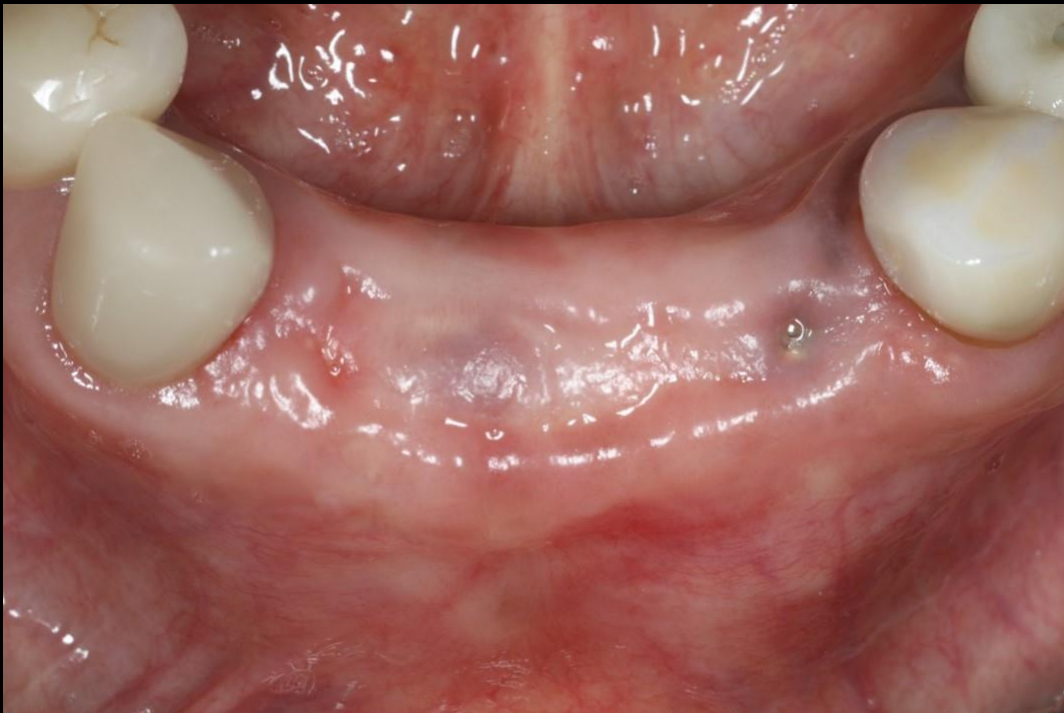Similar case 1

Immediate implantation & GBR



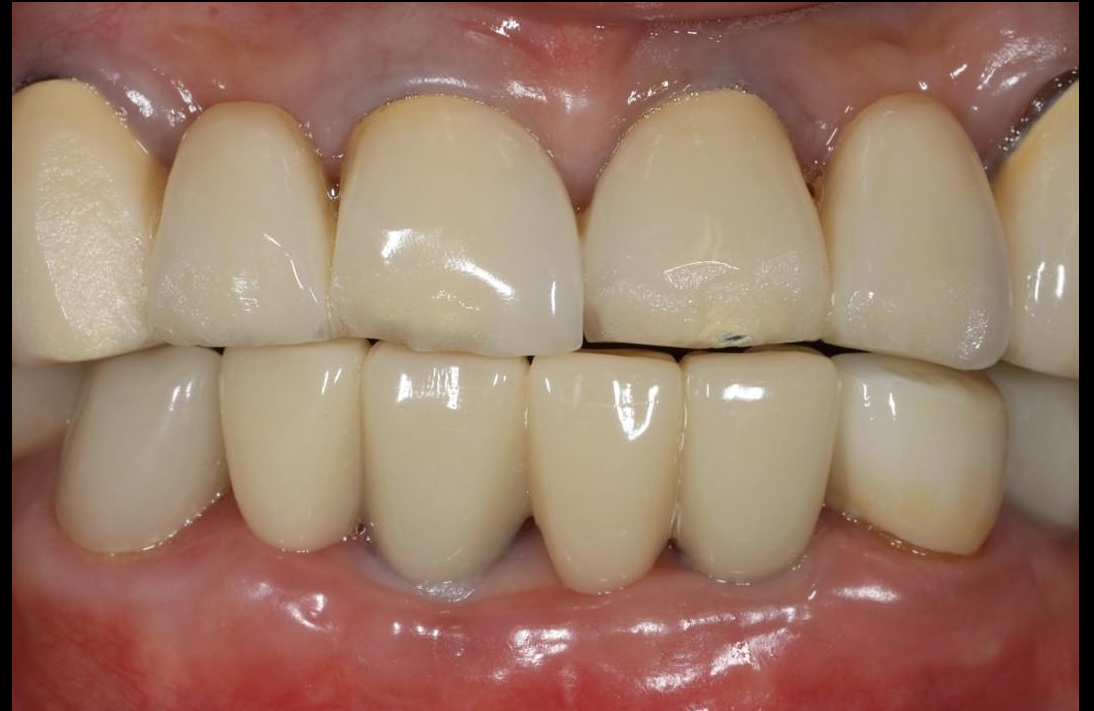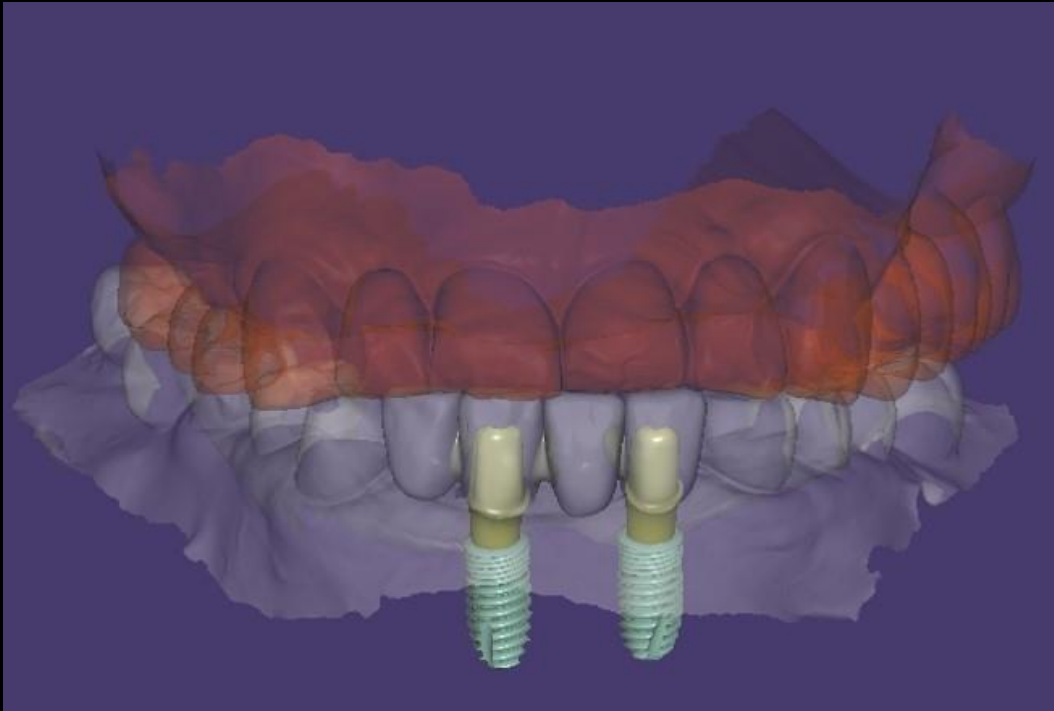
Similar case 1

Immediate implantation & GBR



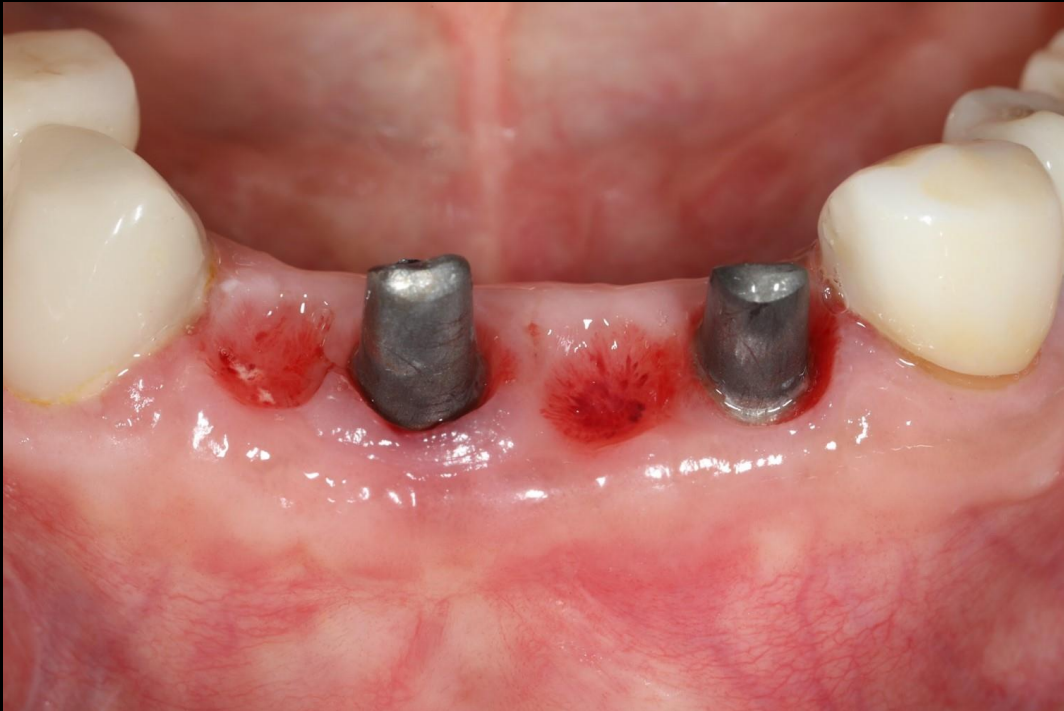Similar case 1

Immediate implantation & GBR



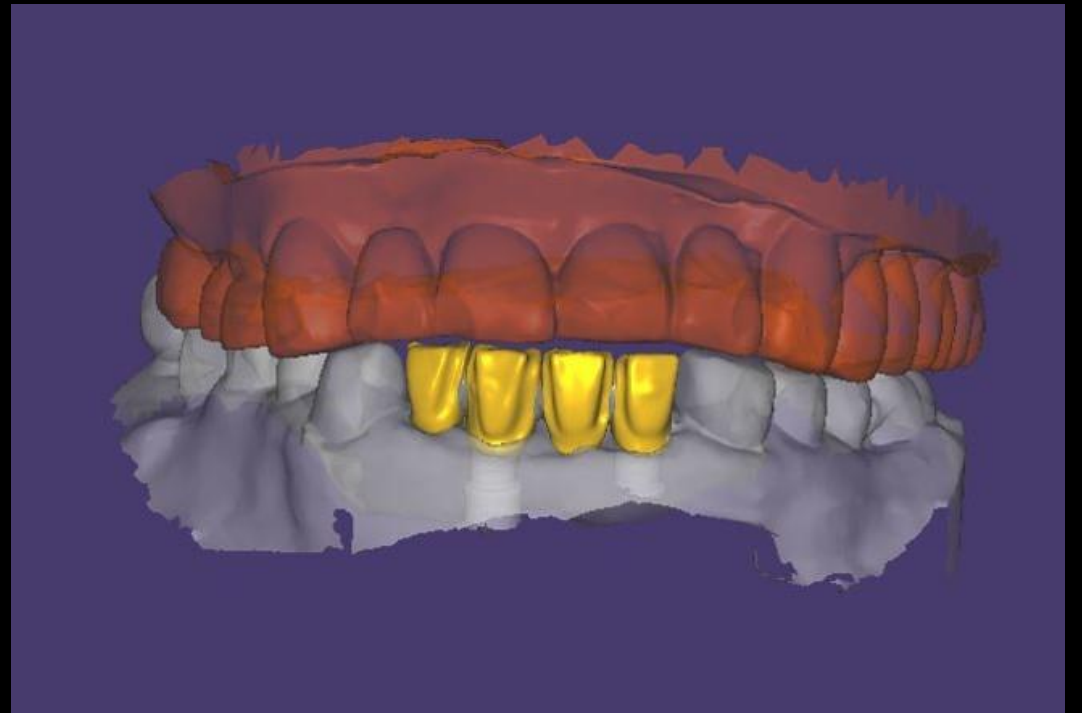
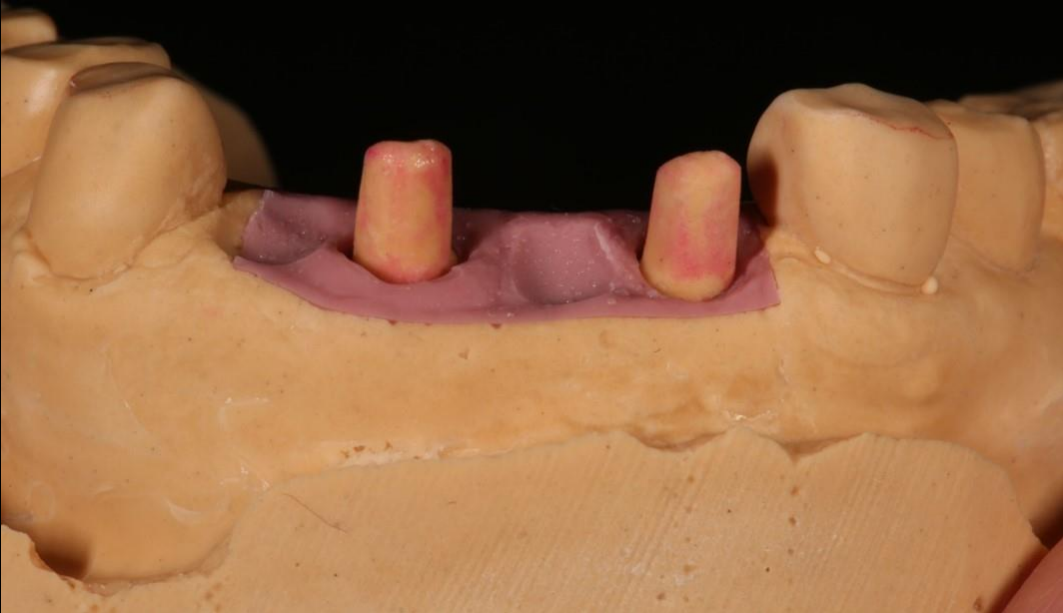Similar case 1

Immediate implantation & GBR



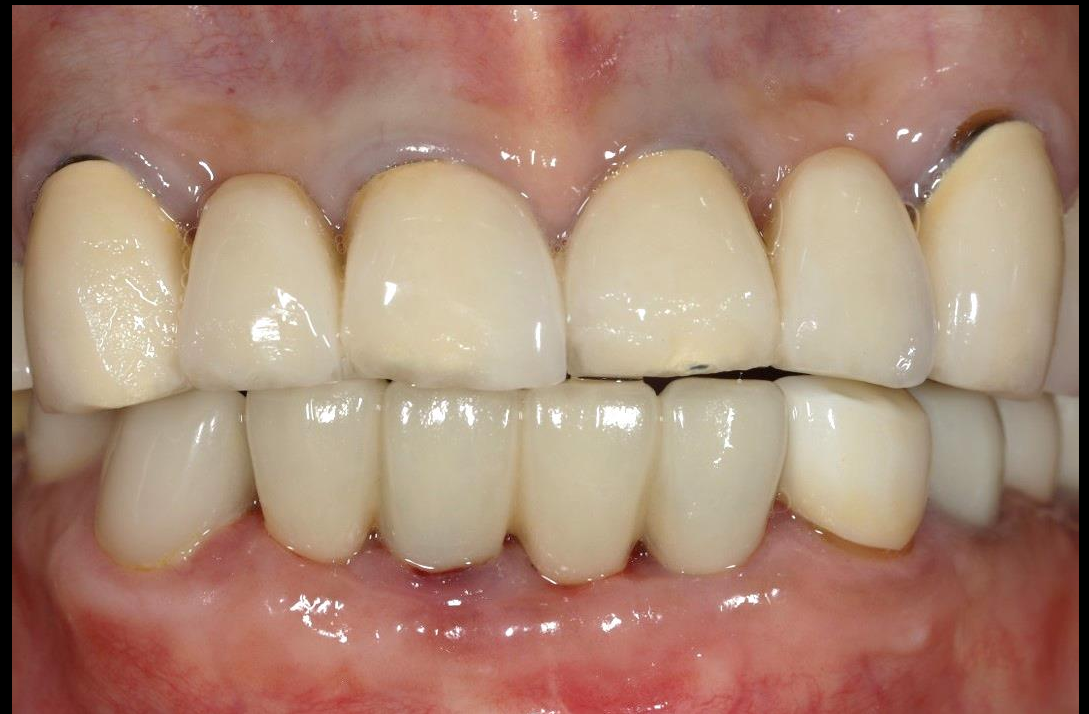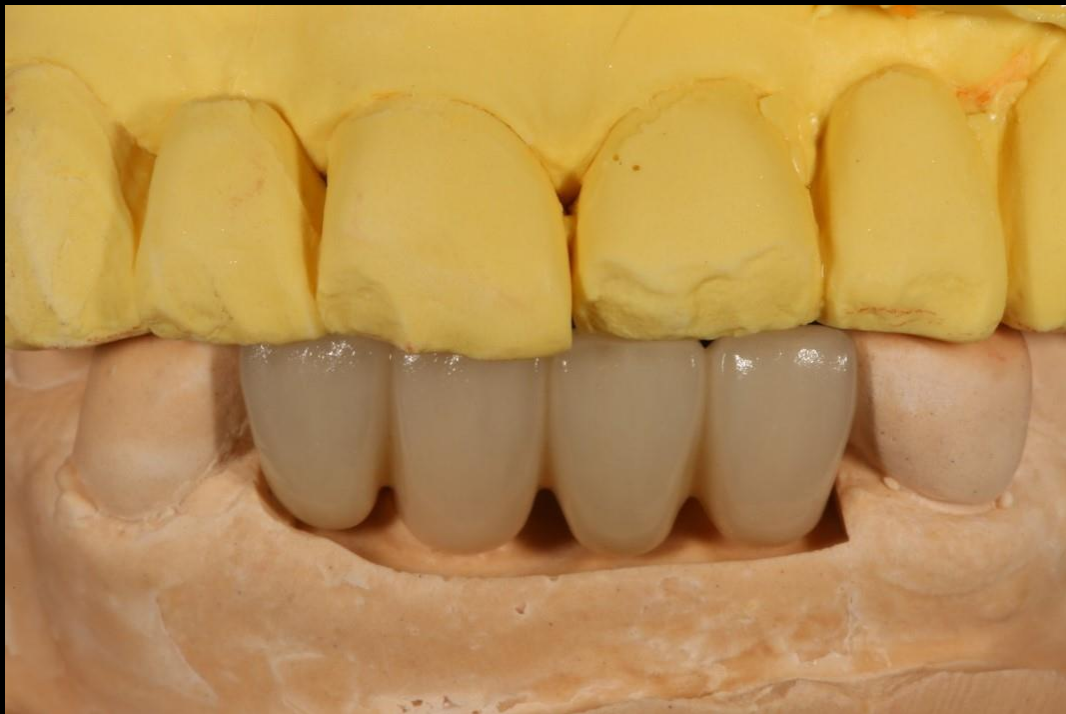Similar case 1

Immediate implantation & GBR



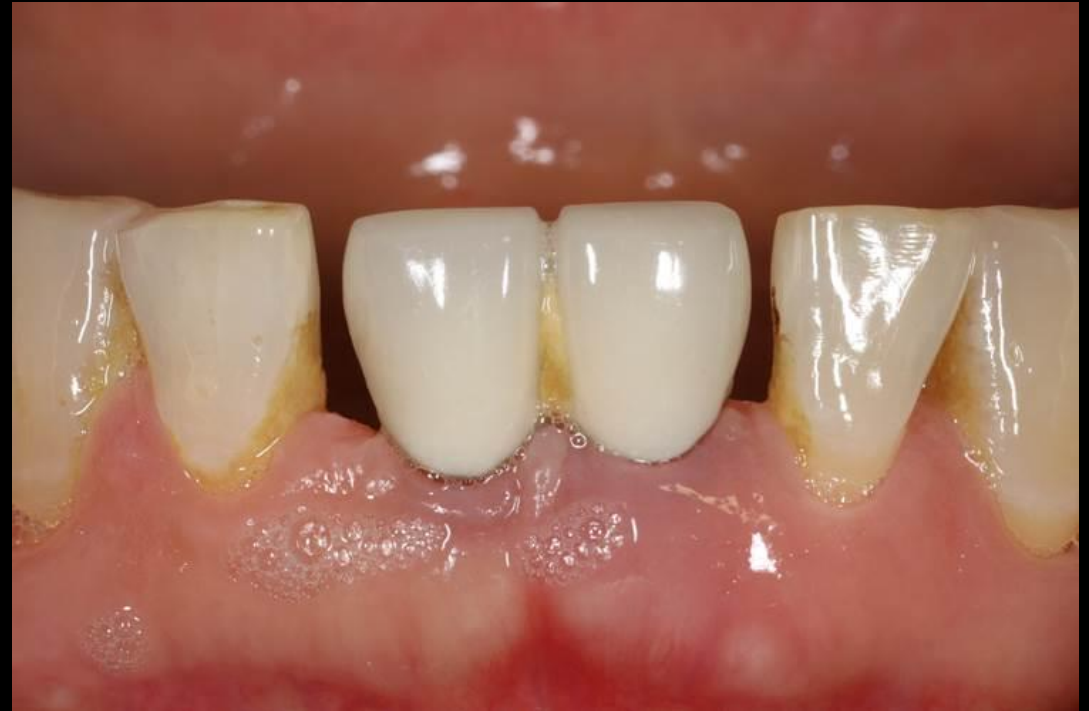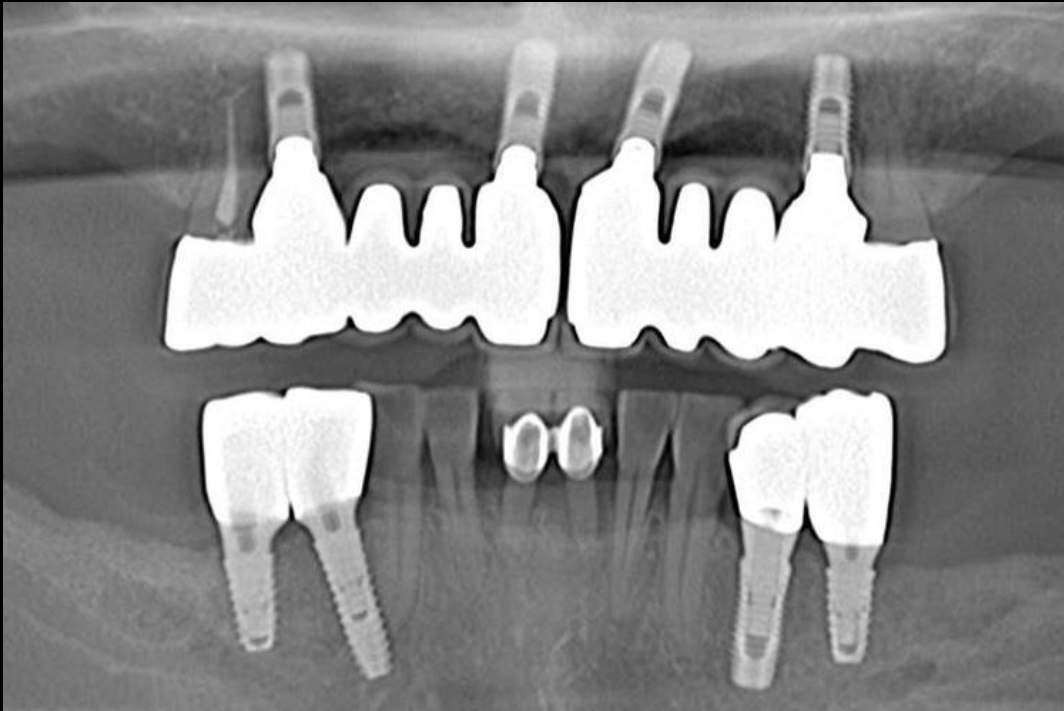
Similar case 1

Immediate implantation & GBR



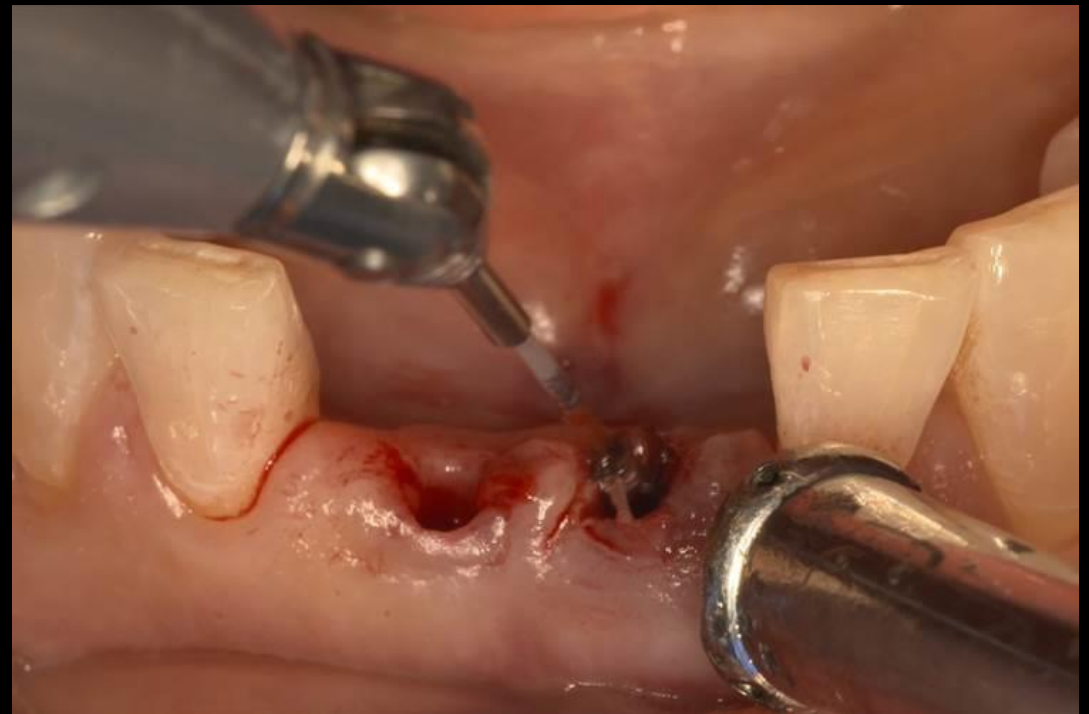
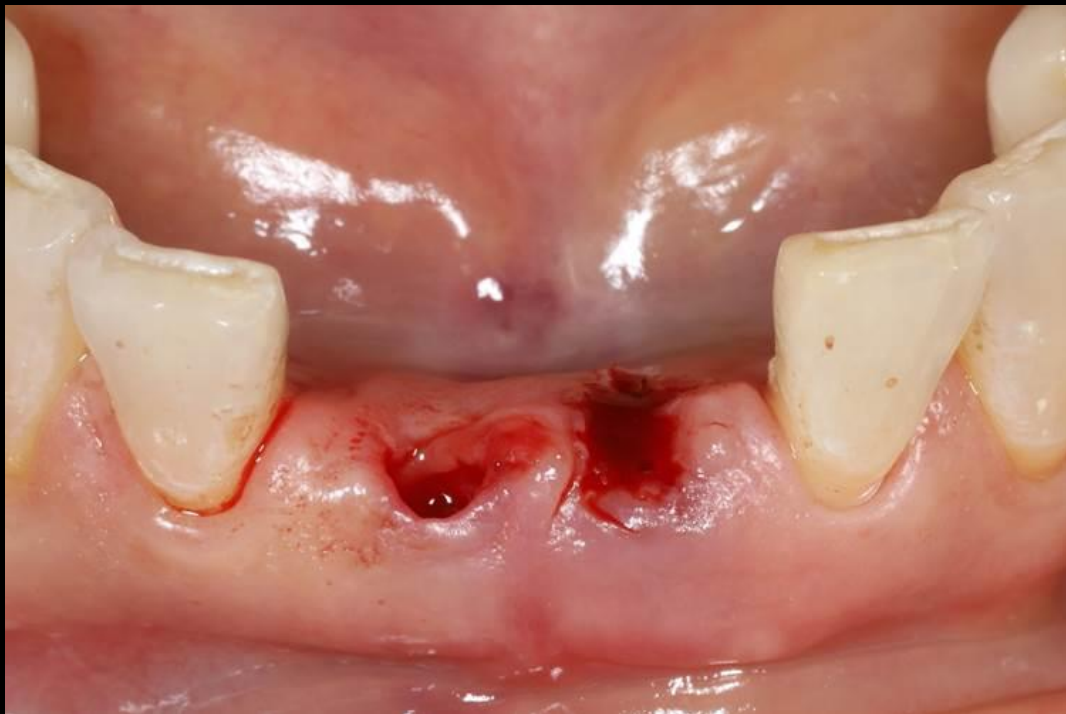Similar case 2

Minimal invasive surgery



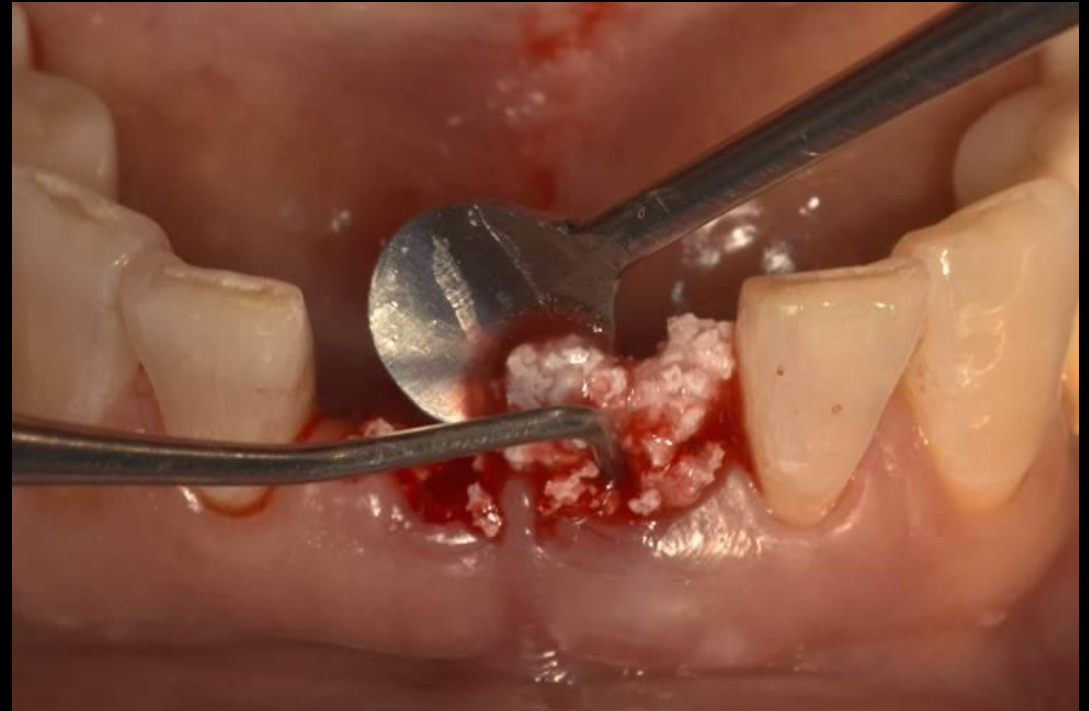
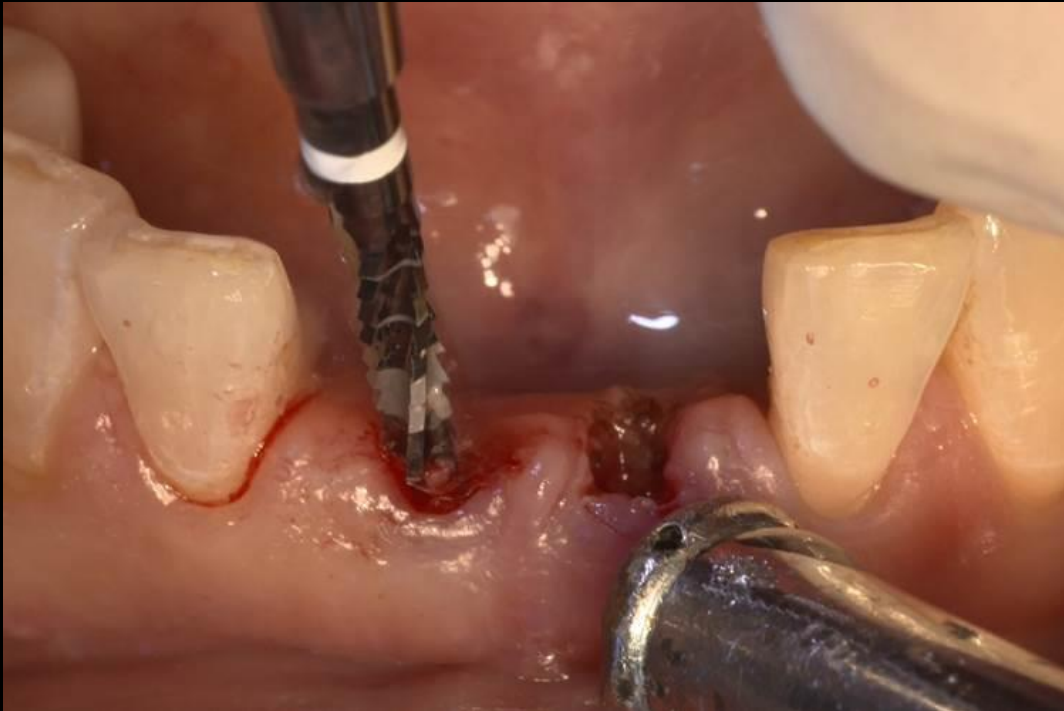Similar case 2

Minimal invasive surgery



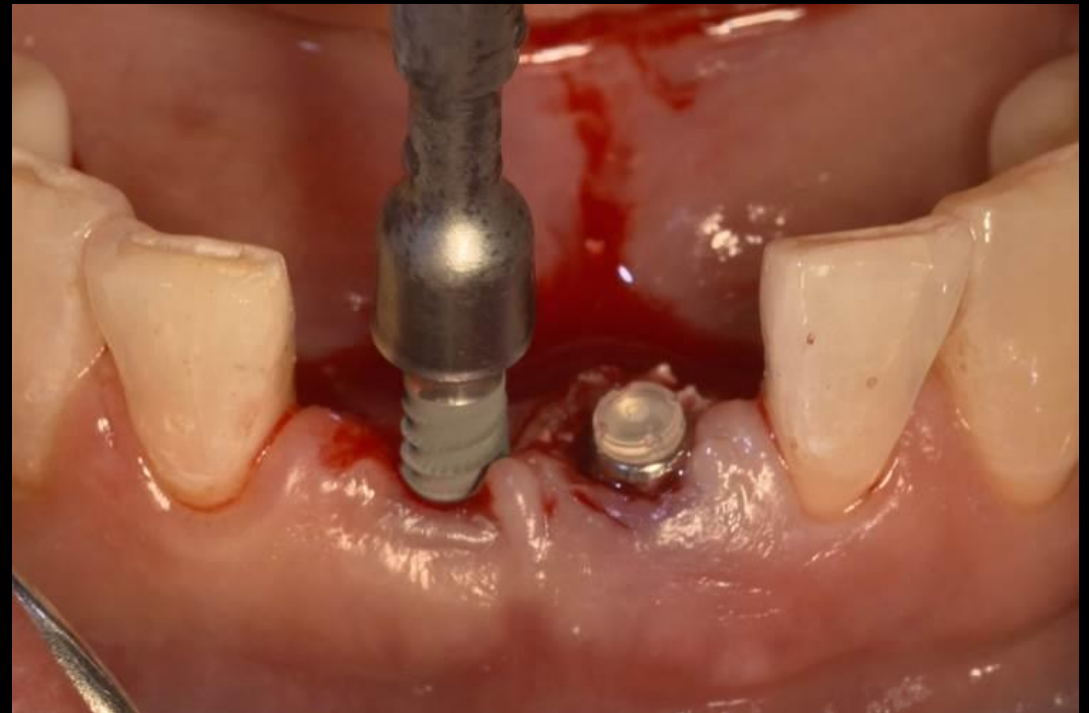

Similar case 2

Minimal invasive surgery



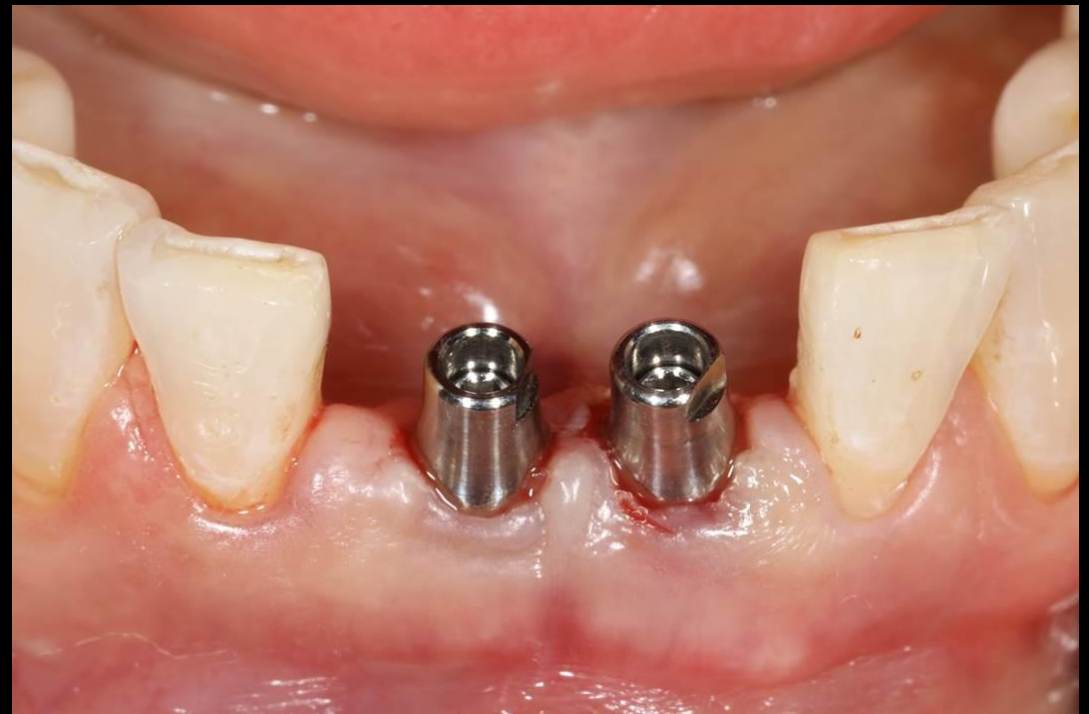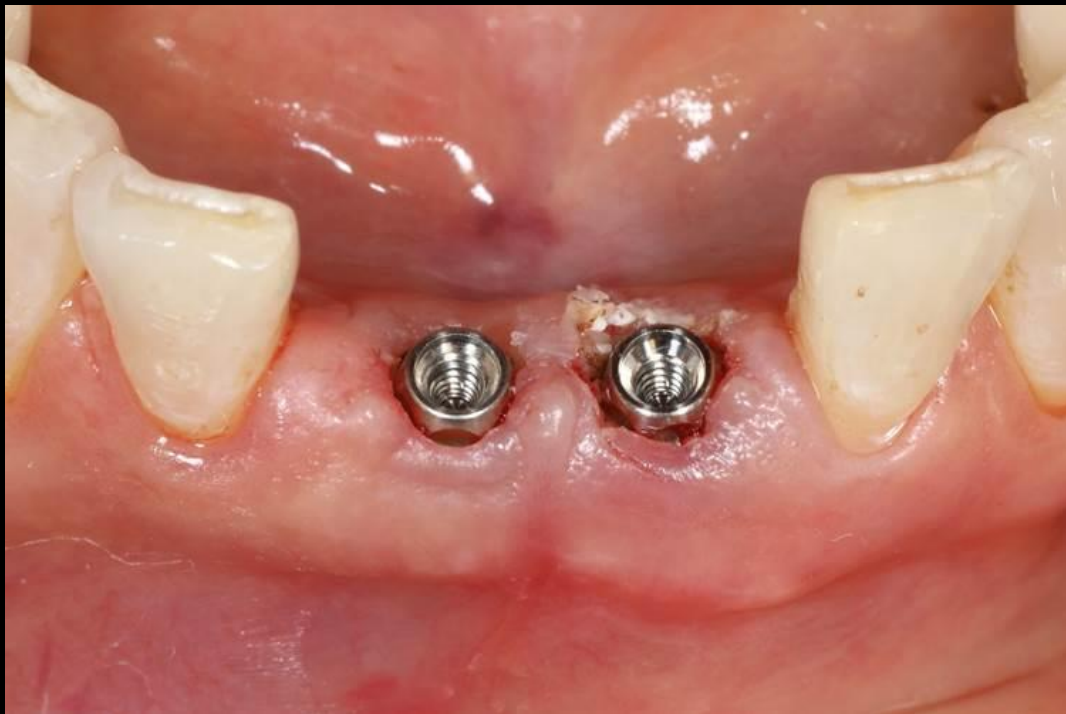Similar case 2

Minimal invasive surgery



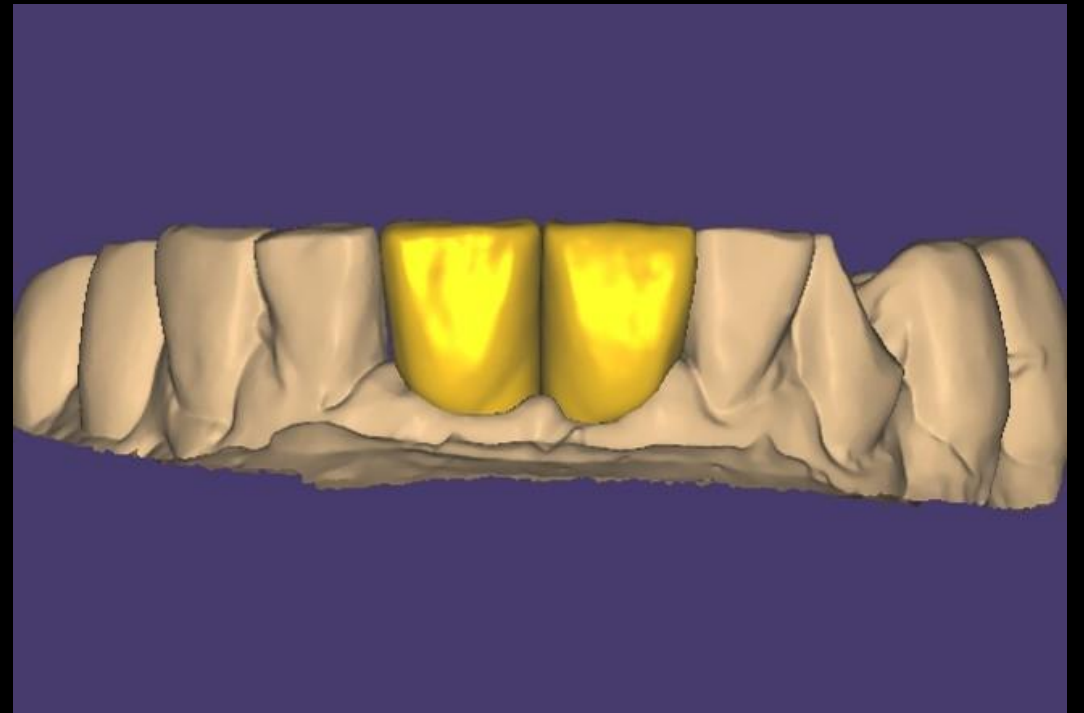
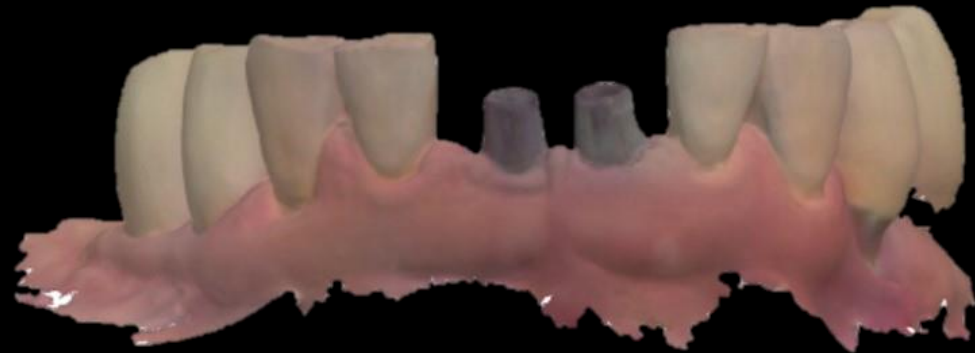Similar case 2

Minimal invasive surgery



Similar case 2

Minimal invasive surgery



Similar case 2

Minimal invasive surgery

