



LIVE

Surgeries

Dr. Seung Keun Lee (Dr.Teddy)

2025. 02. 21 (FRI.)



[Case Preview]

bright Implant : Immediate Implantation and Bone Augmentation

Patient Information

Age : 63

Sex : Male

Chief Complaint

I would like to get implants to restore the broken teeth.

Past Dental History

- Old Bridge Fracture (#35-37)

Present illness

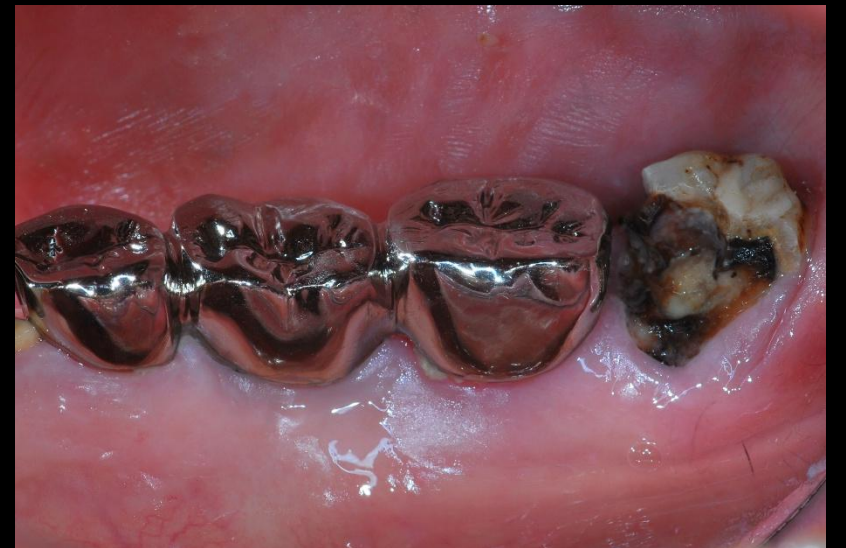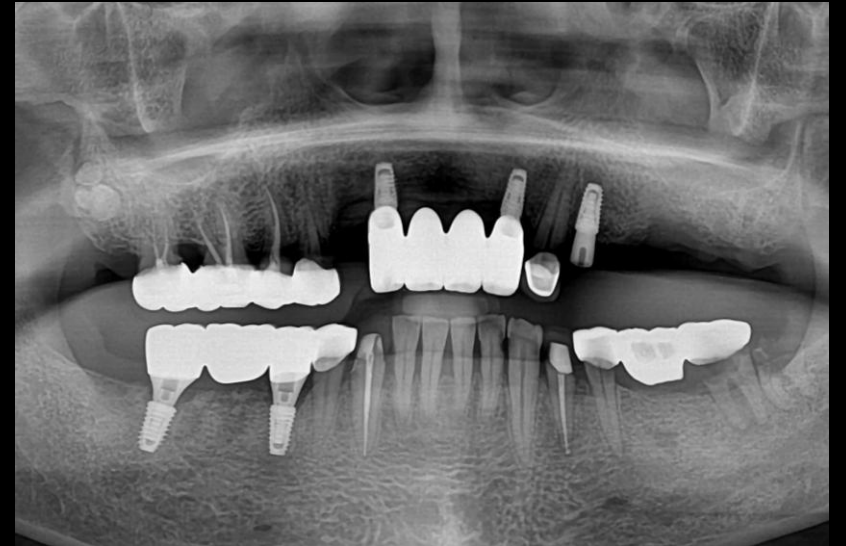- #35 : Root rest state (Root caries)

- #37, 38 : Tooth extracted

Today's Surgery Plan

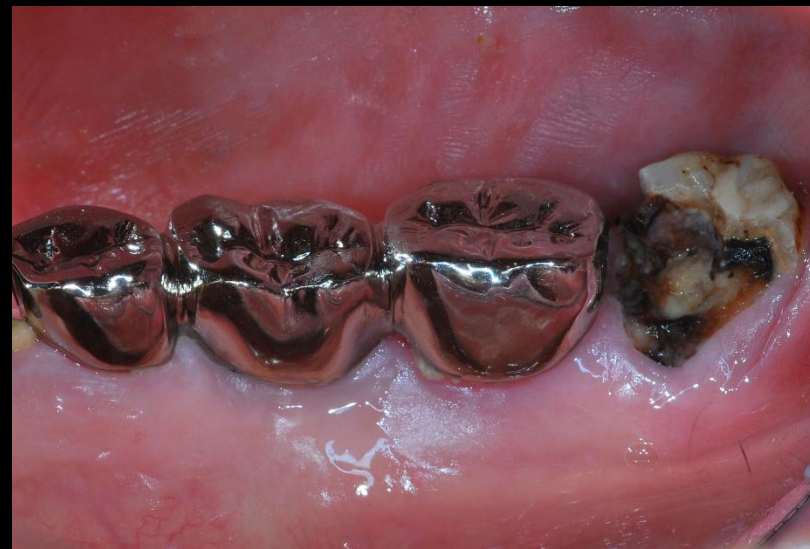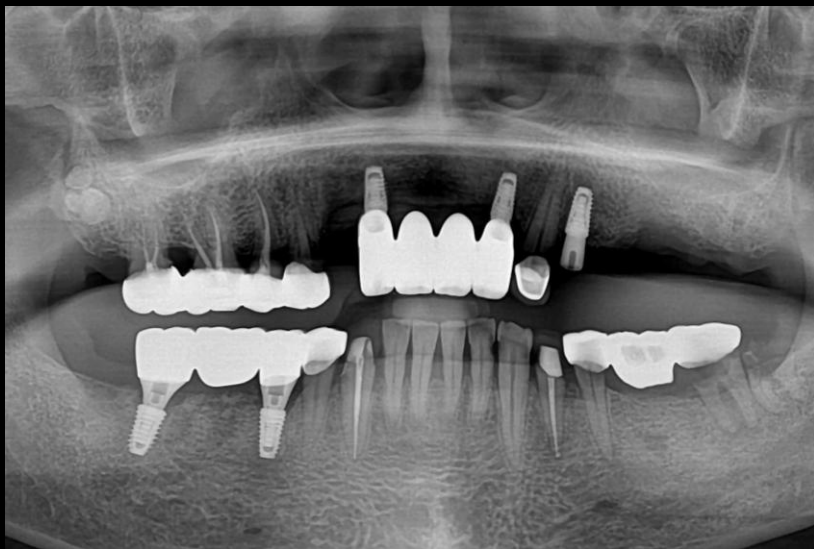Surgical Plan

- Extraction on #35
- Immediate implant placement on #35,36
- (bright Bone Level Implant)
- Gap filling at #35 site
- GBR at #36 site



Pt. Park (63/Male)

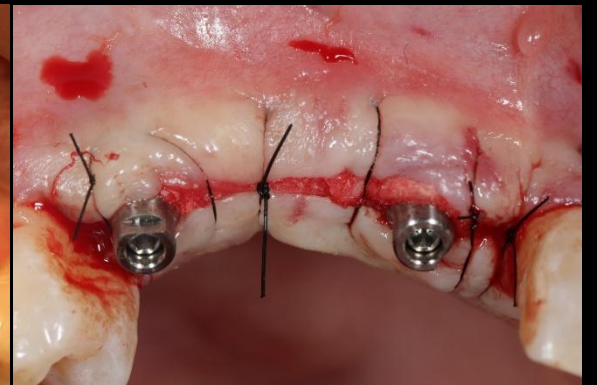
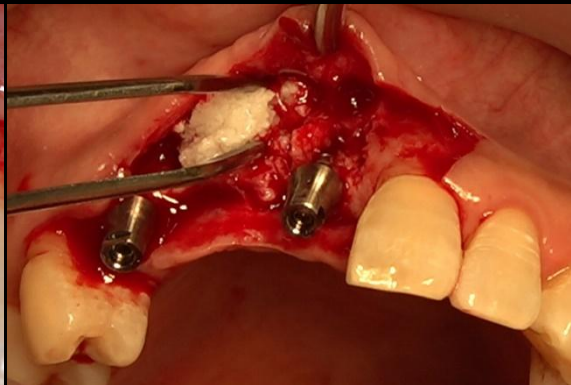
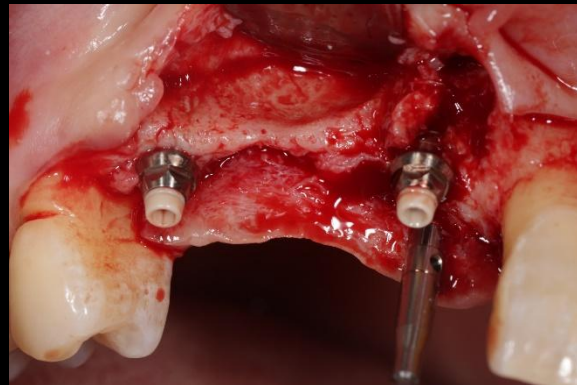
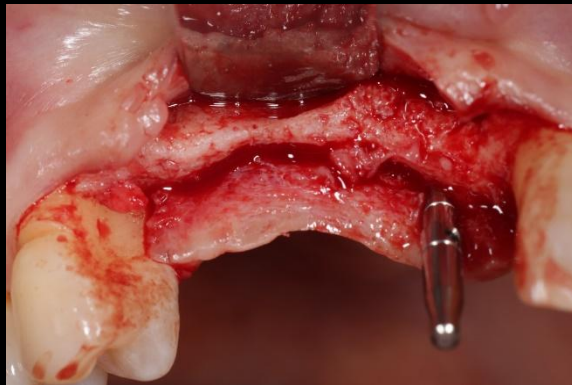
X ray exam



OSTEON™ Xeno Collagen

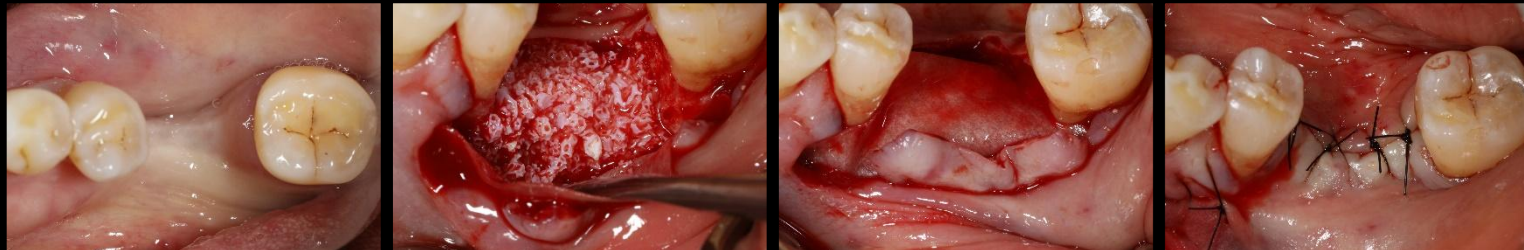


- Ossification ability of Xeno graft
- Easy handling of collagenized bone graft
- Optimal collagen absorption speed



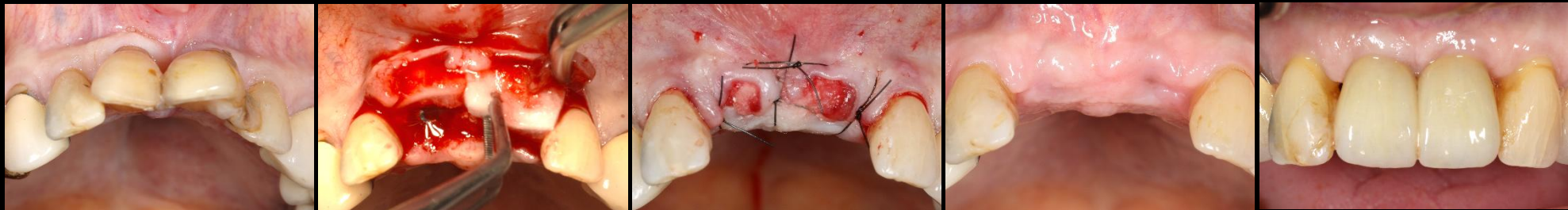Collagen Membrane 2

- Faster wetting and Easier manipulation, Pin-friendly (tear-resistant)
- Resorbable barrier membrane for GBR
- Long-term stability over 6 months
- Multi-layered microstructure



Collagen Graft 2

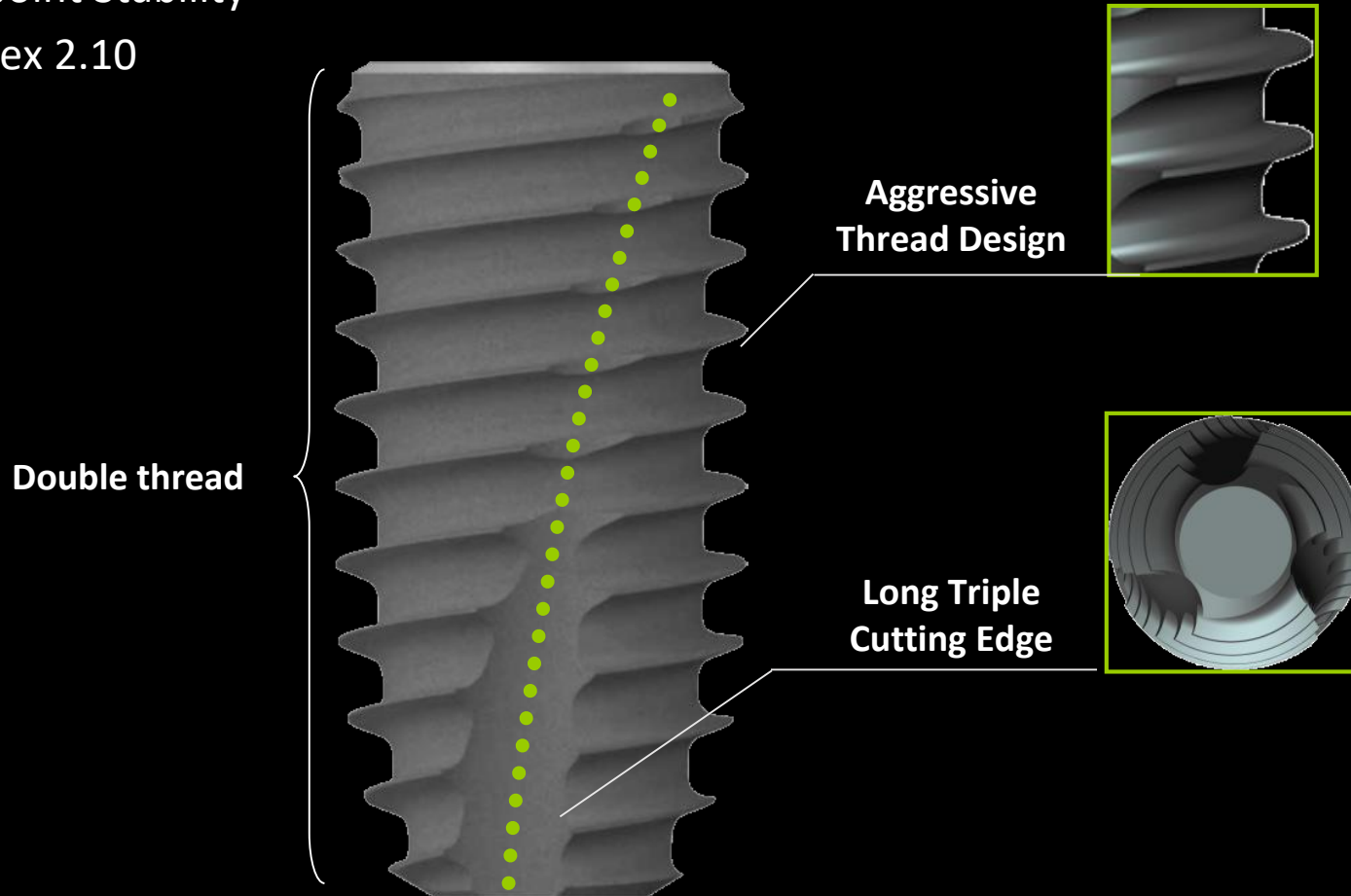
- Ridge preservation
- Porcine tendon derived type I collagen
- Faster soft tissue healing by epithelization



bright Bone Level

10° , 3.70 mm Deep Connection

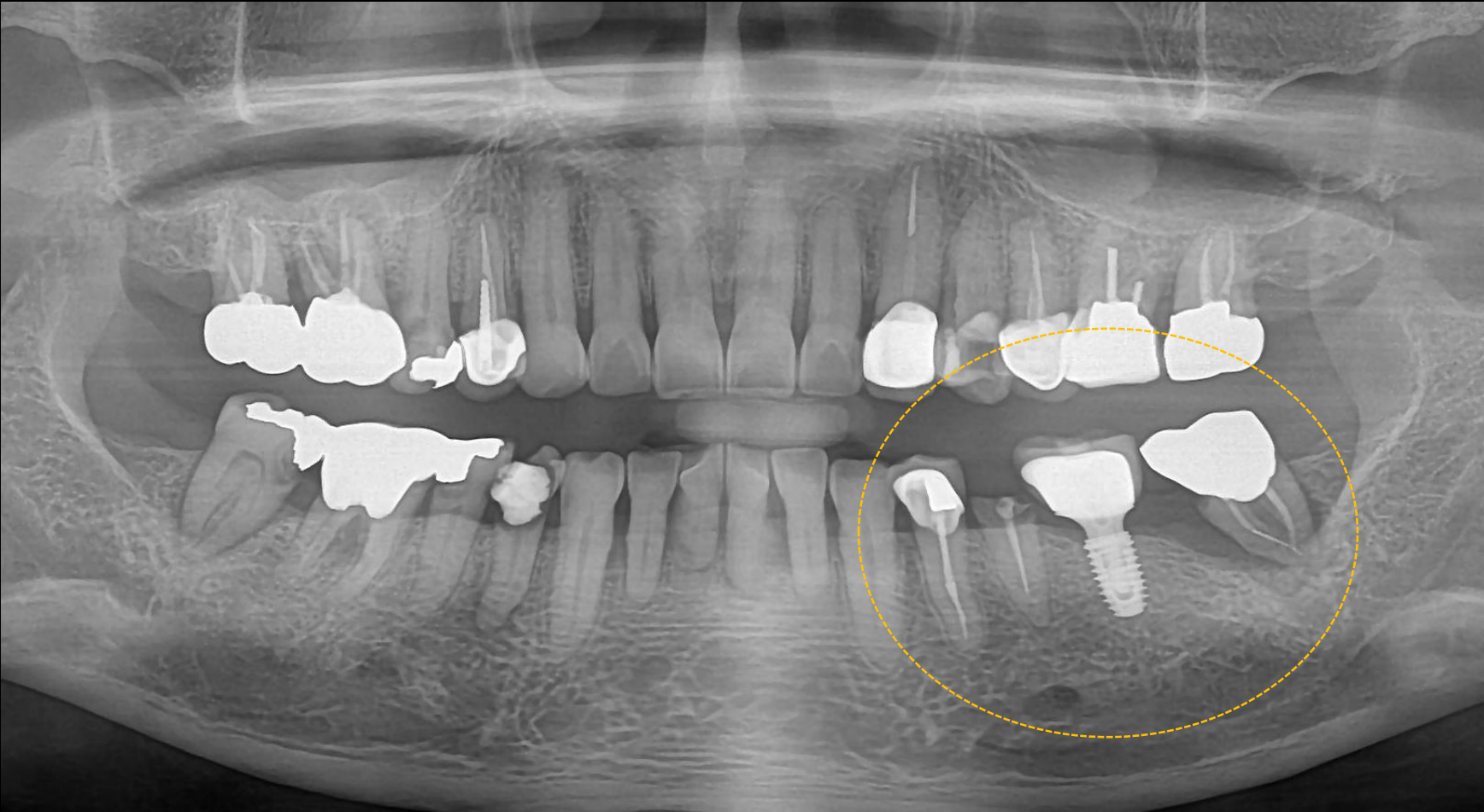
- Excellent Joint Stability
- Internal Hex 2.10



Similar case

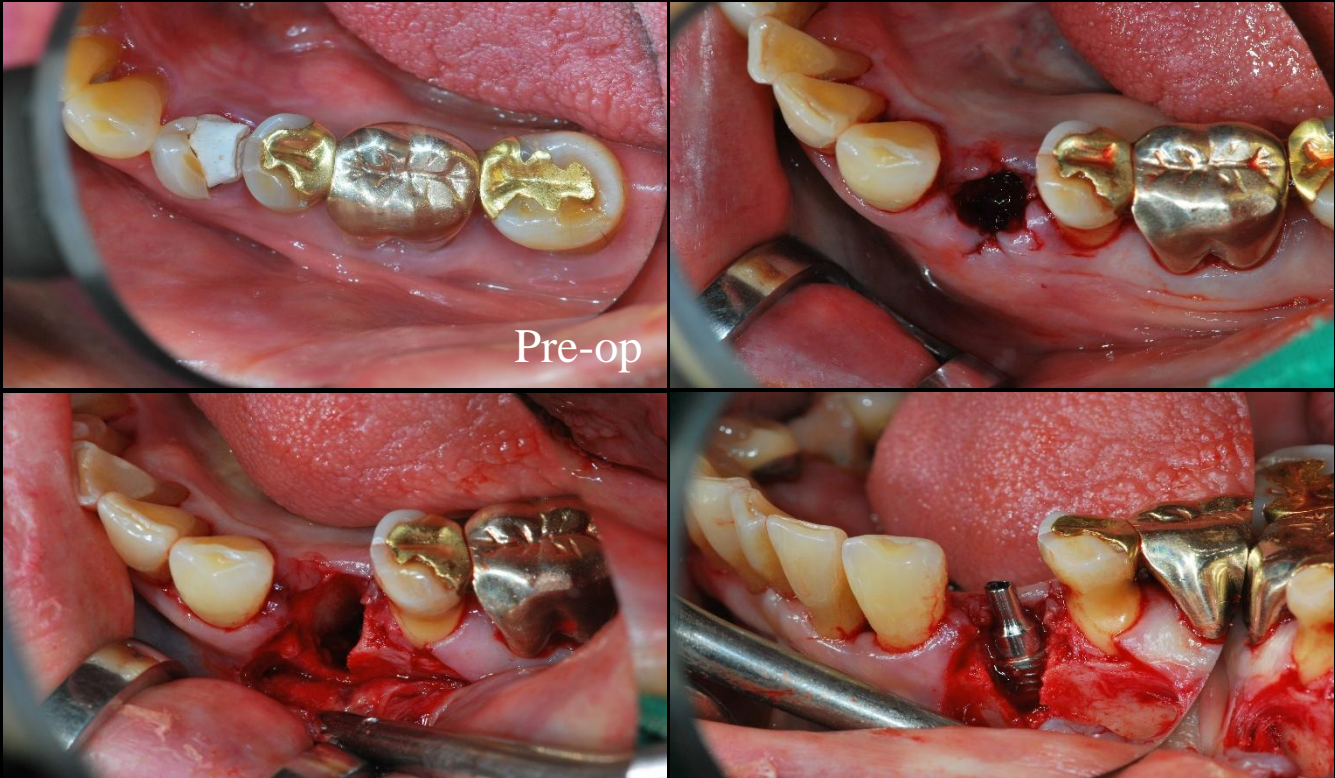
Immediate implant placement using bright Bone Level Implant

Pre-op



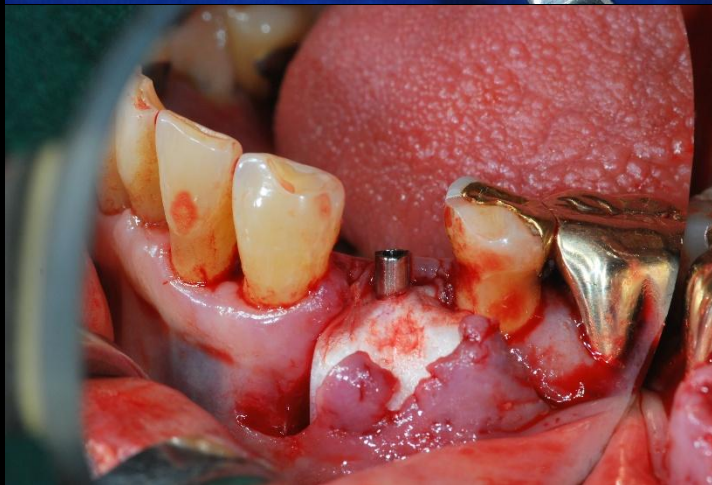
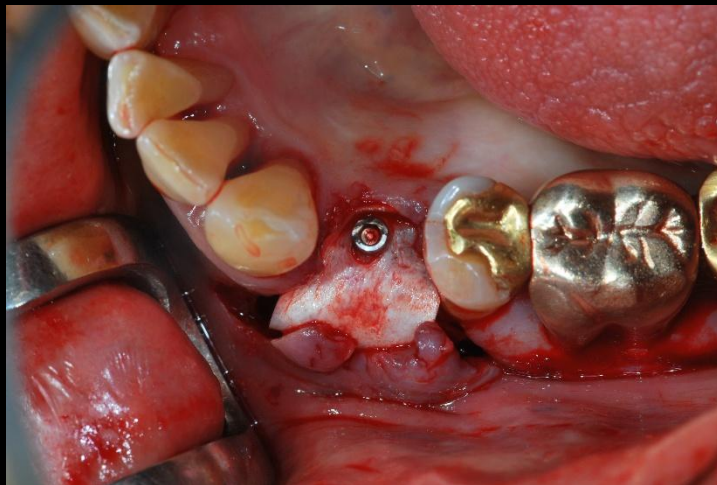
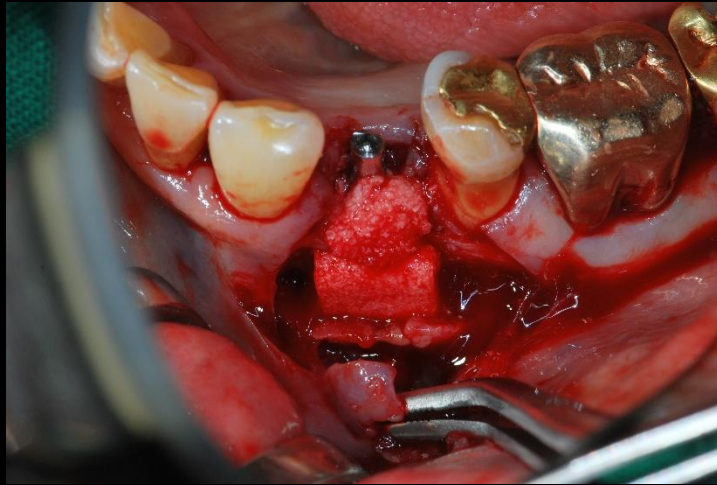
Similar case

Immediate implant placement using bright Bone Level Implant



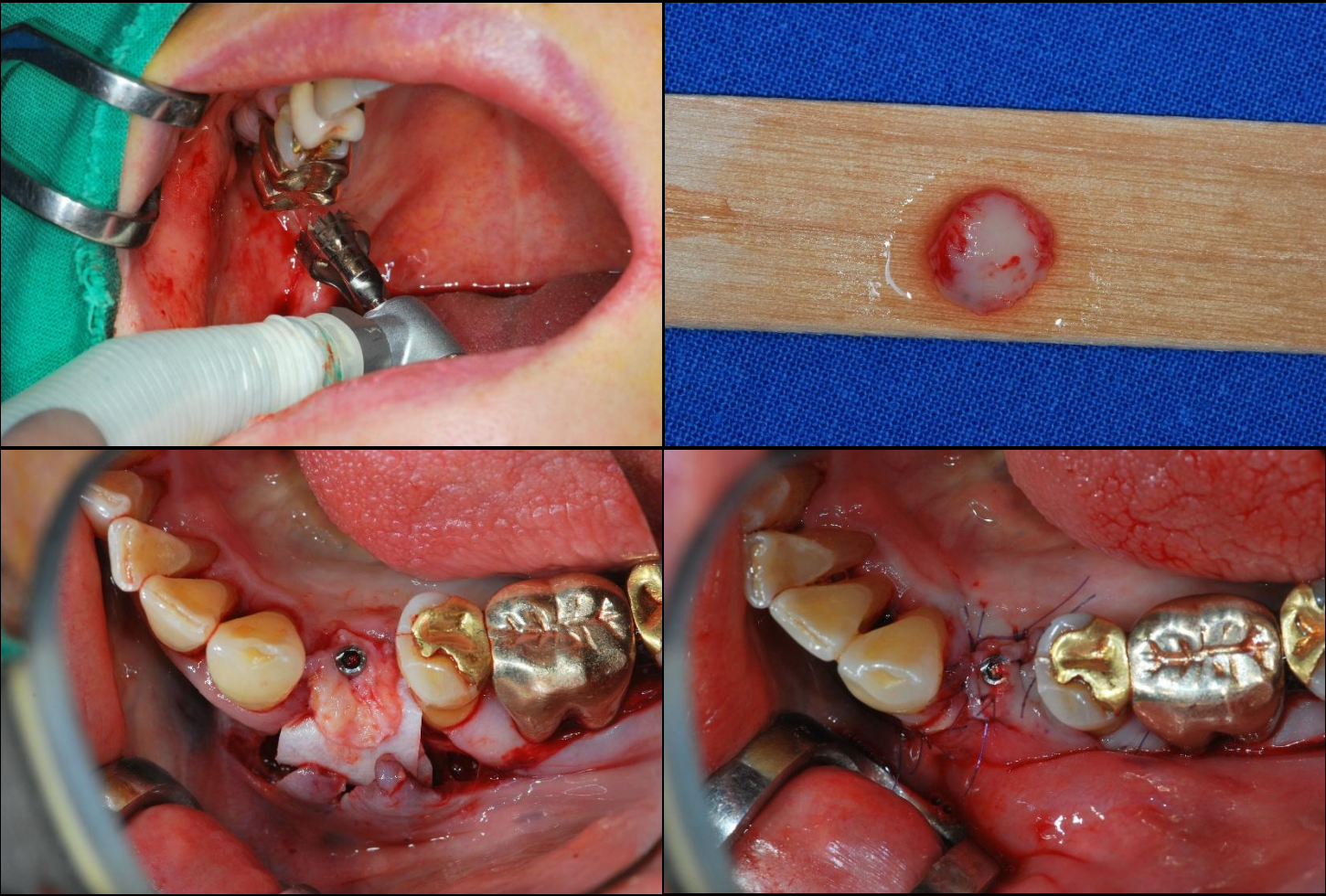
Similar case

Immediate implant placement using bright Bone Level Implant



Similar case

Immediate implant placement using bright Bone Level Implant



Similar case

Immediate implant placement using bright Bone Level Implant

Post-op

