

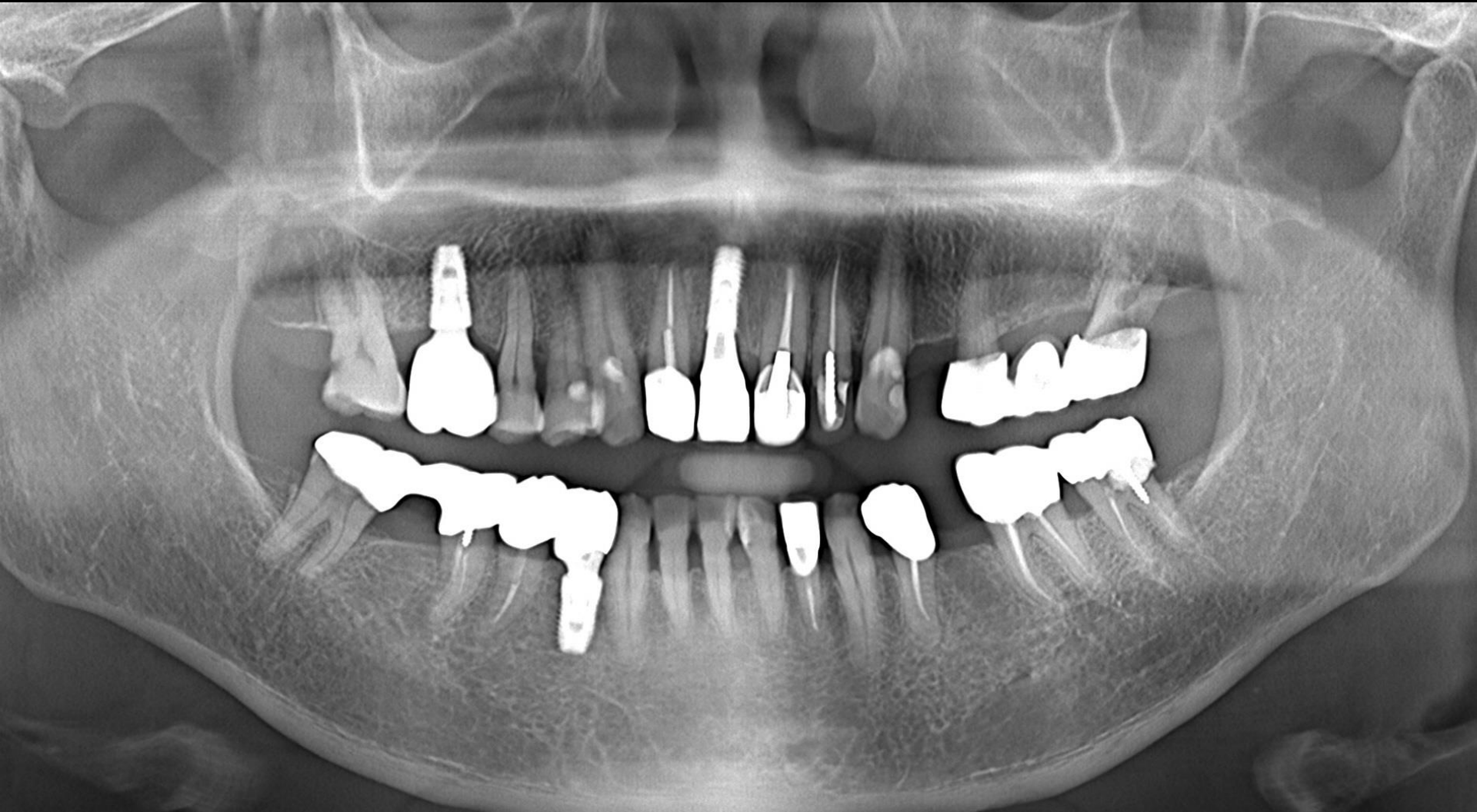
# Implantation with Flapless

(Bone Level, Implant guide)

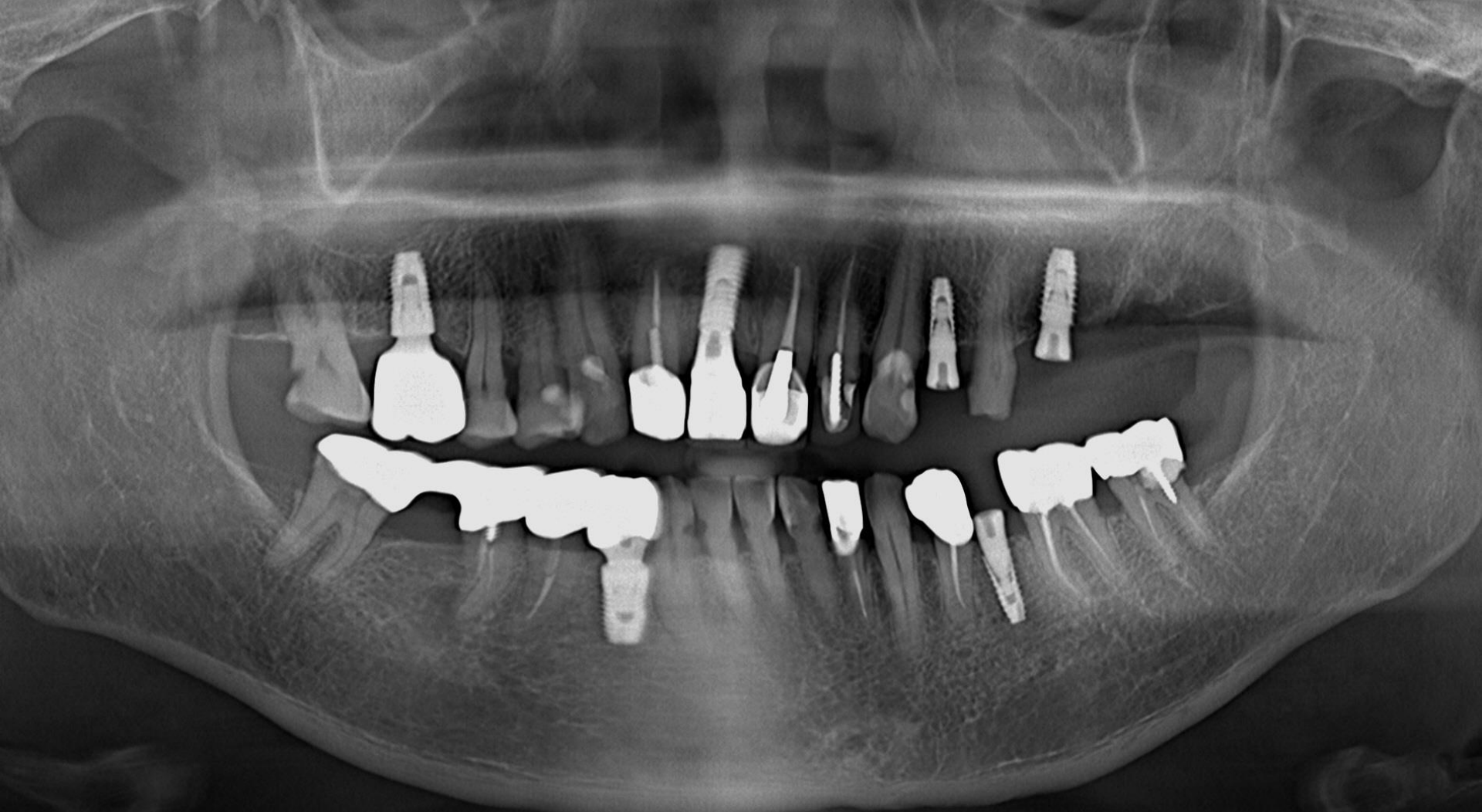68y/F

Dr.SM Chung

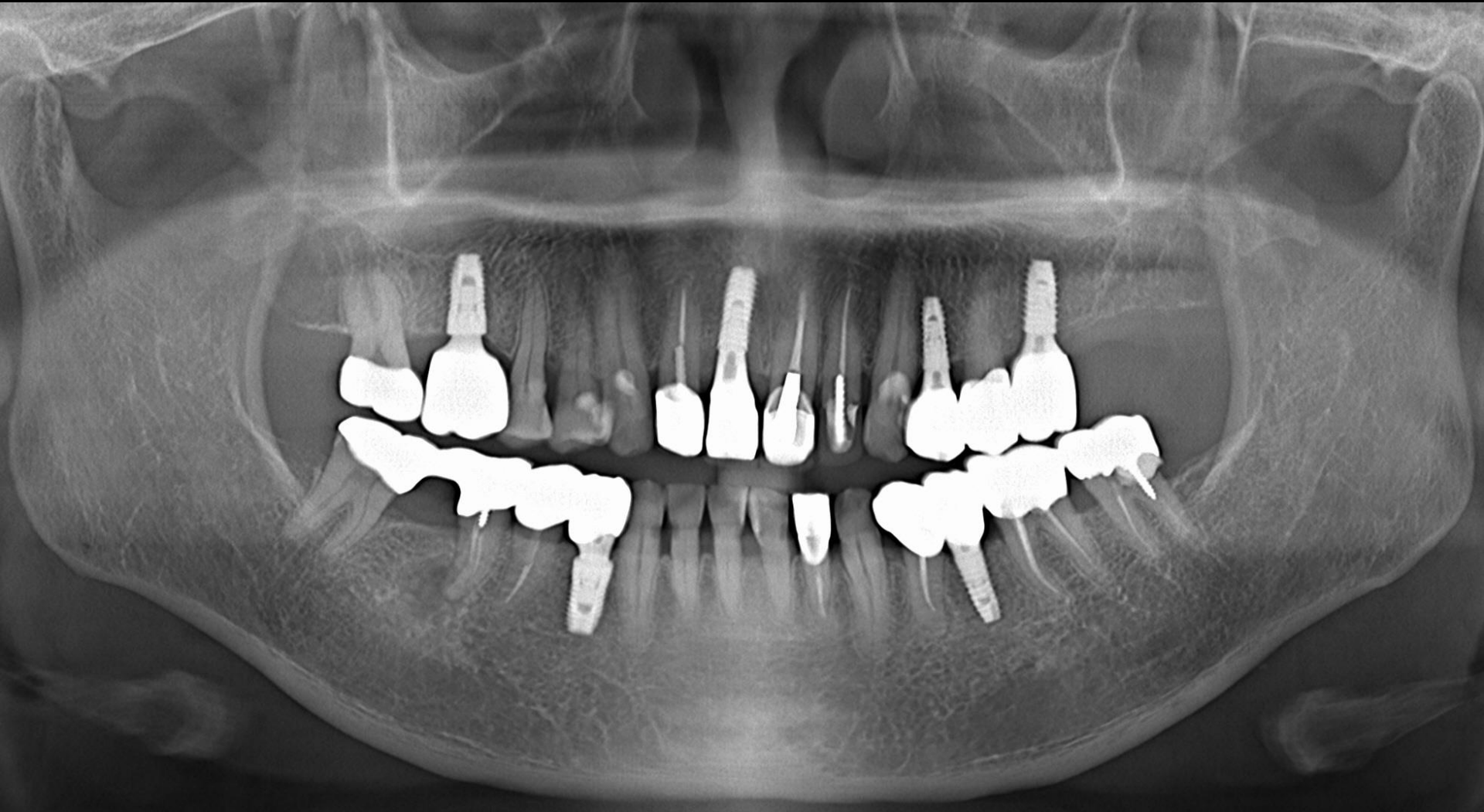
Pre-op (2018-06-05)



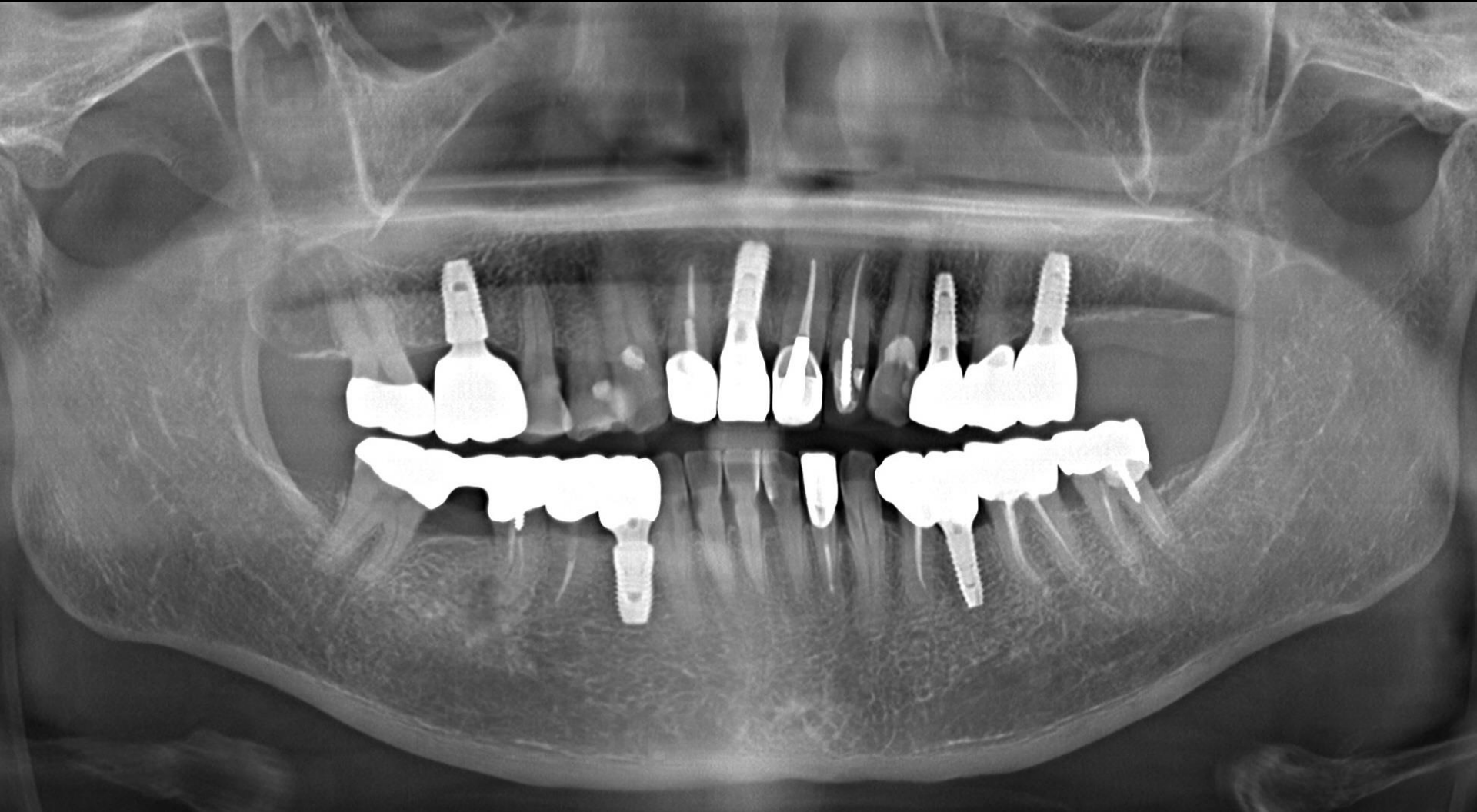
Post-op (2018-10-04)



Final prosthesis (2019-03-22)

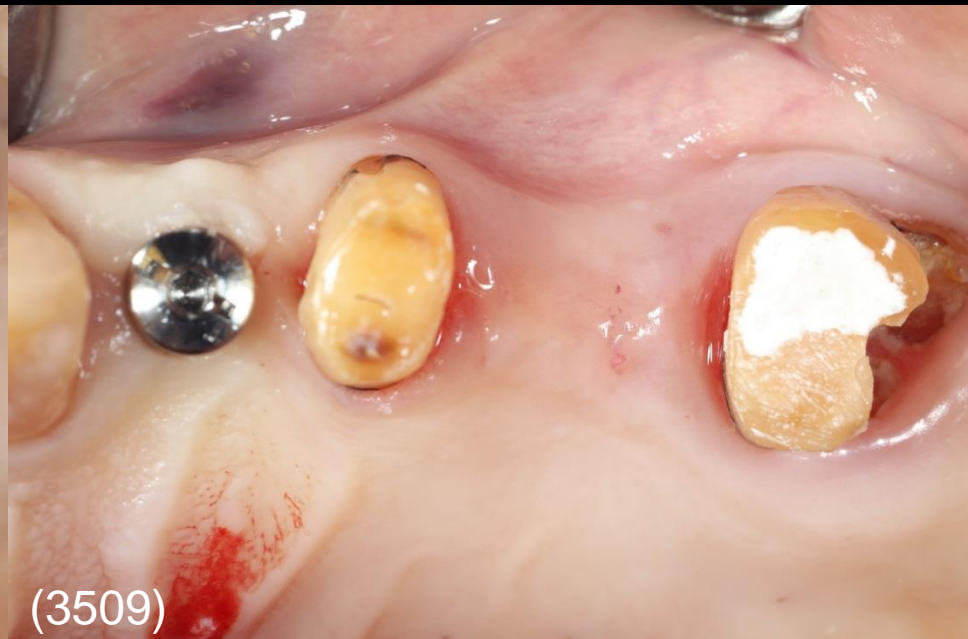
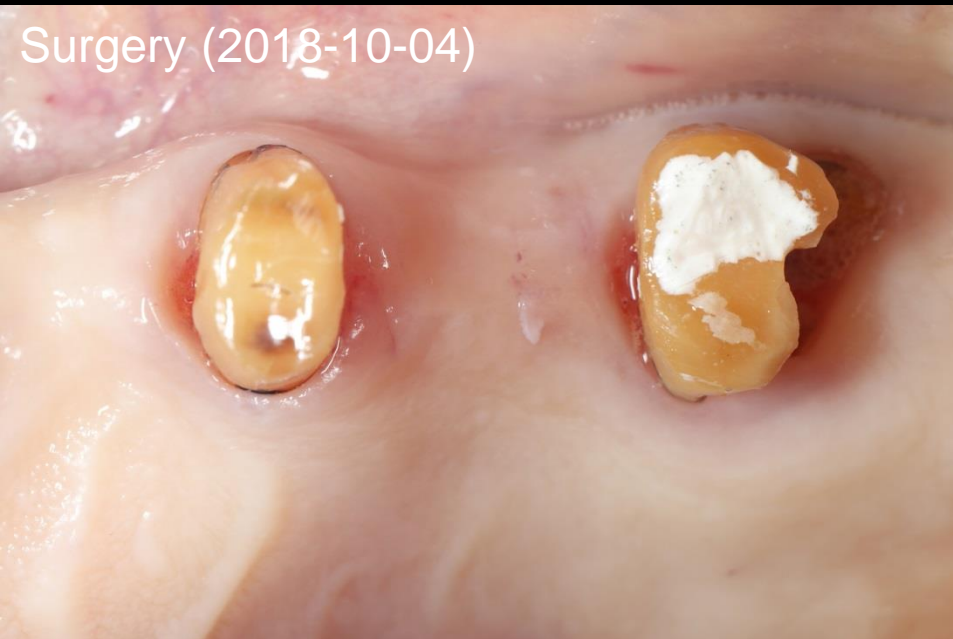
Follow up : 4 months (2019-08-02)

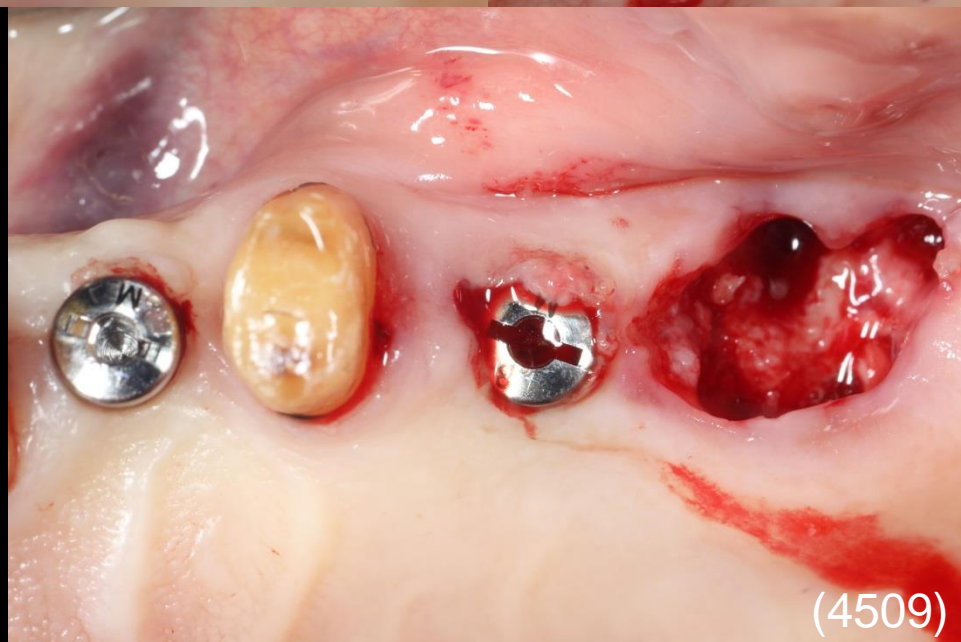




Surgery (2018-10-04)

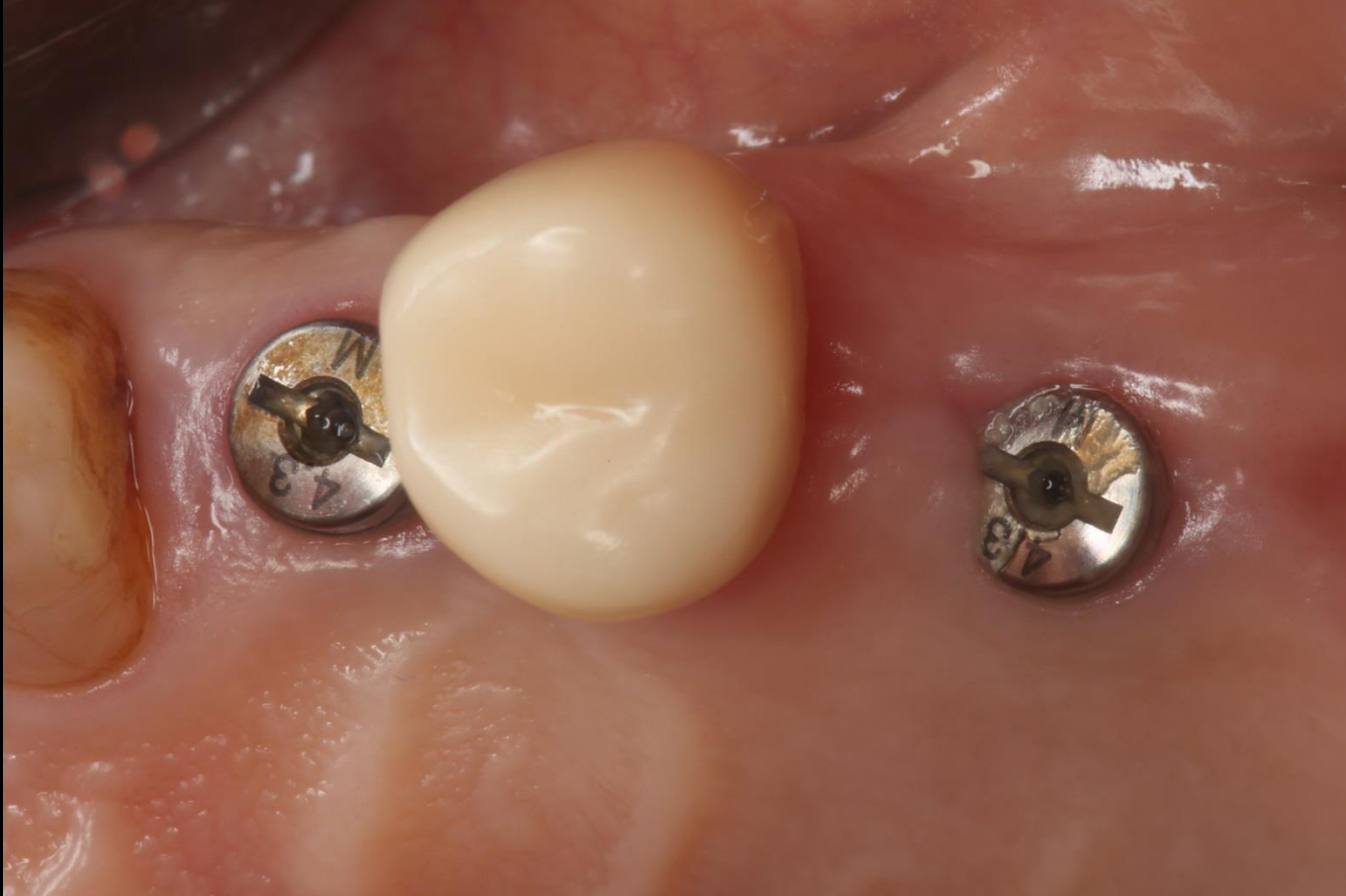

(3509)

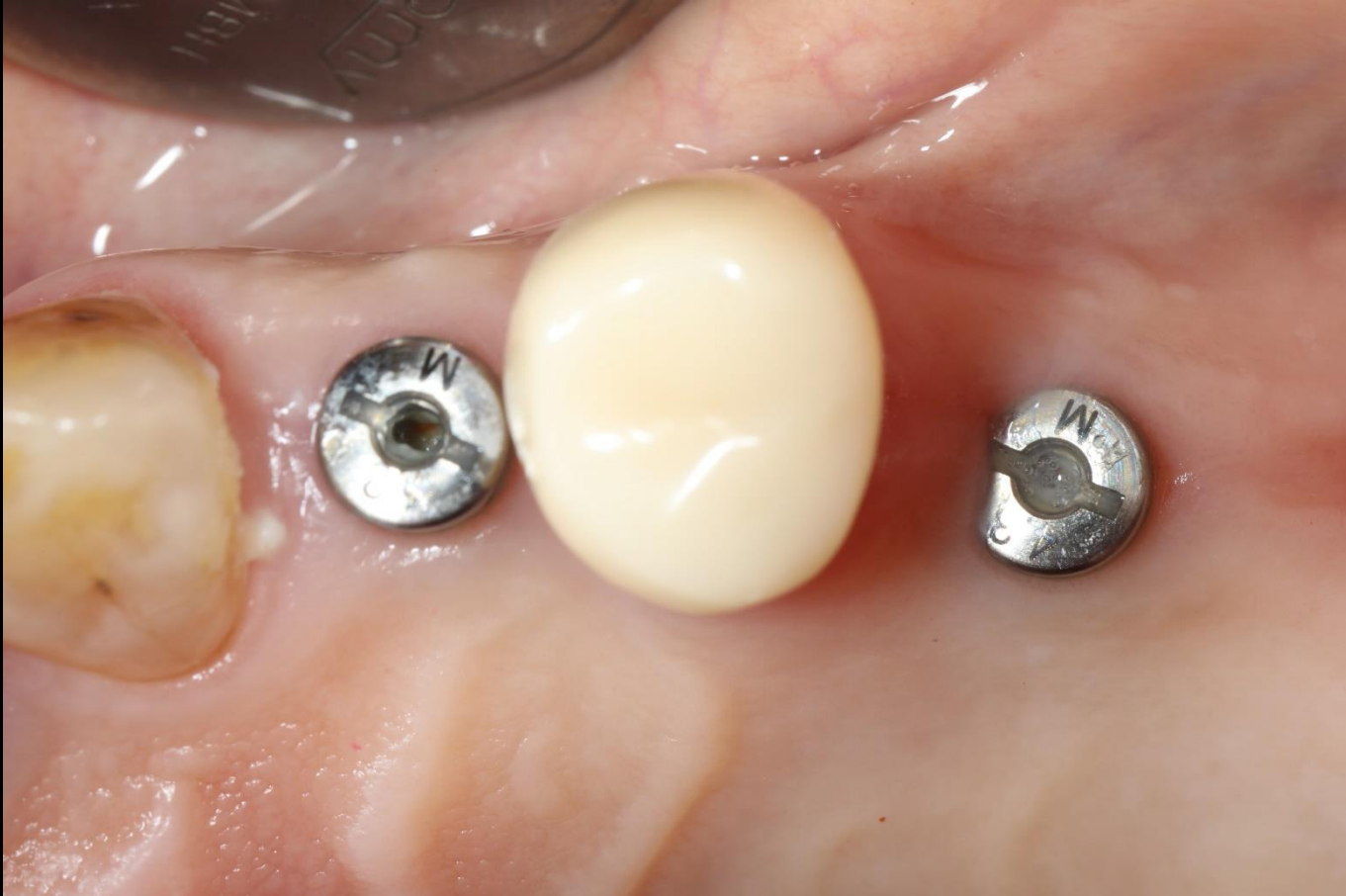

(4509)

Healing : 2 weeks (2018-10-19)

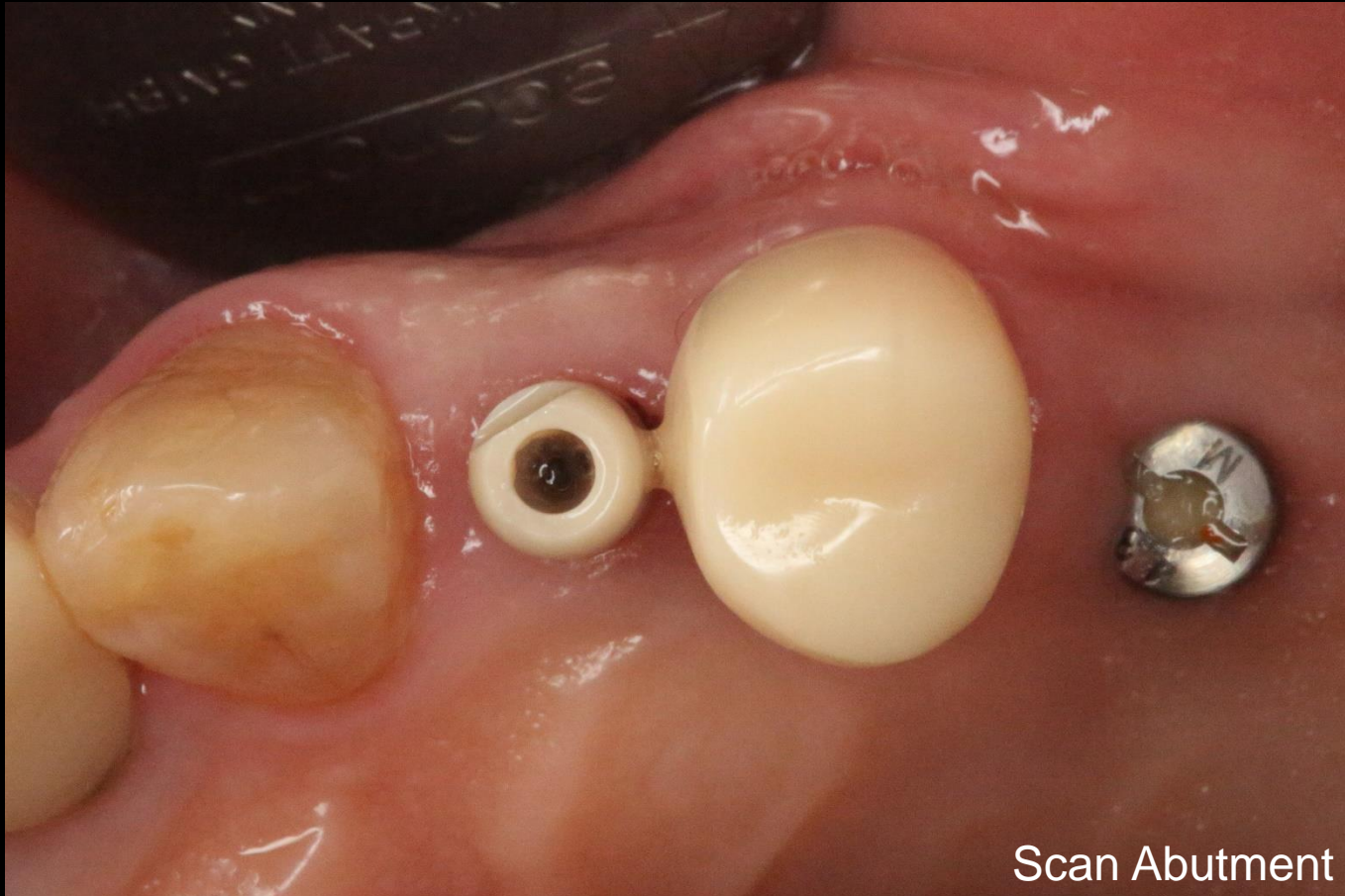


Healing : 1 month (2018-11-09)

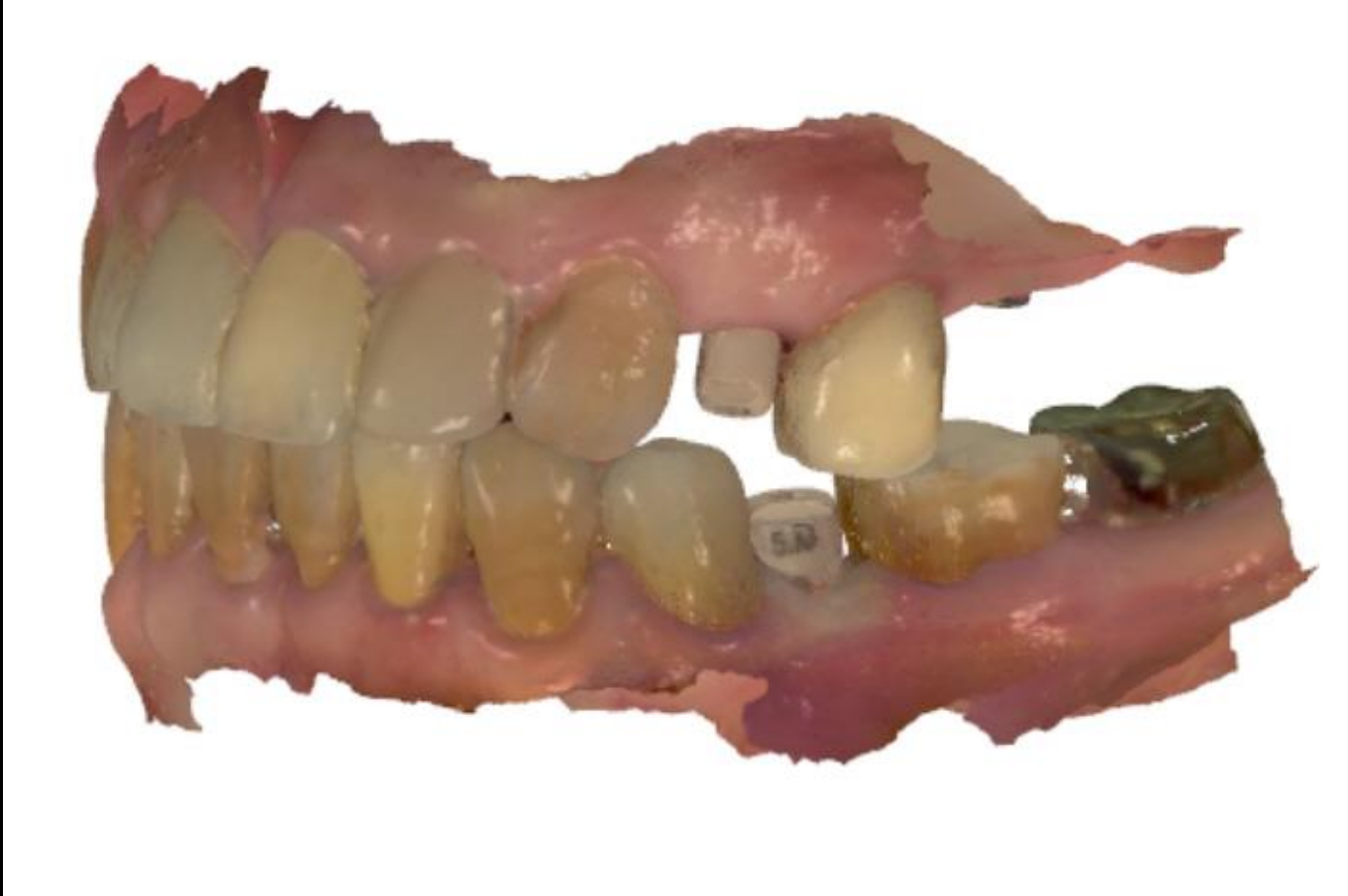



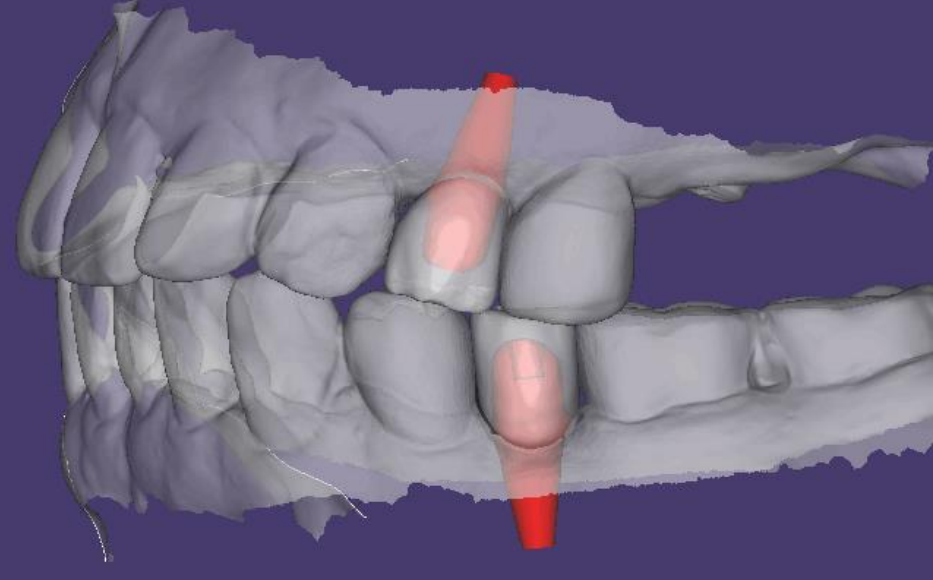
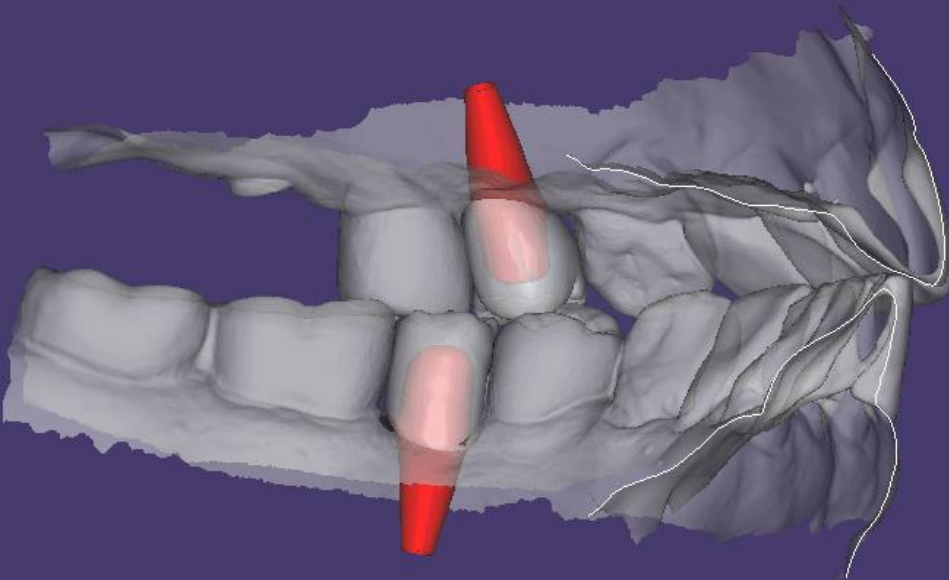
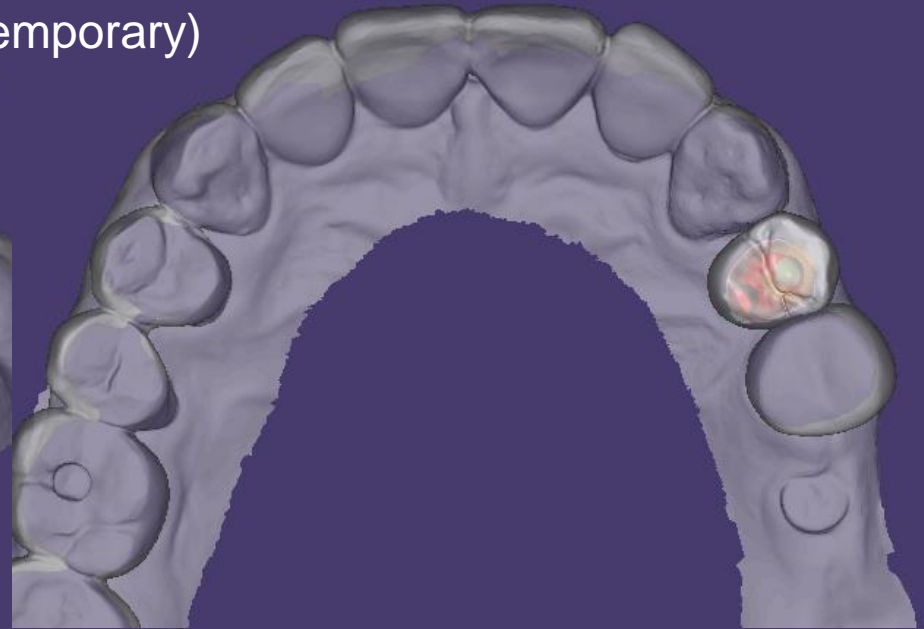
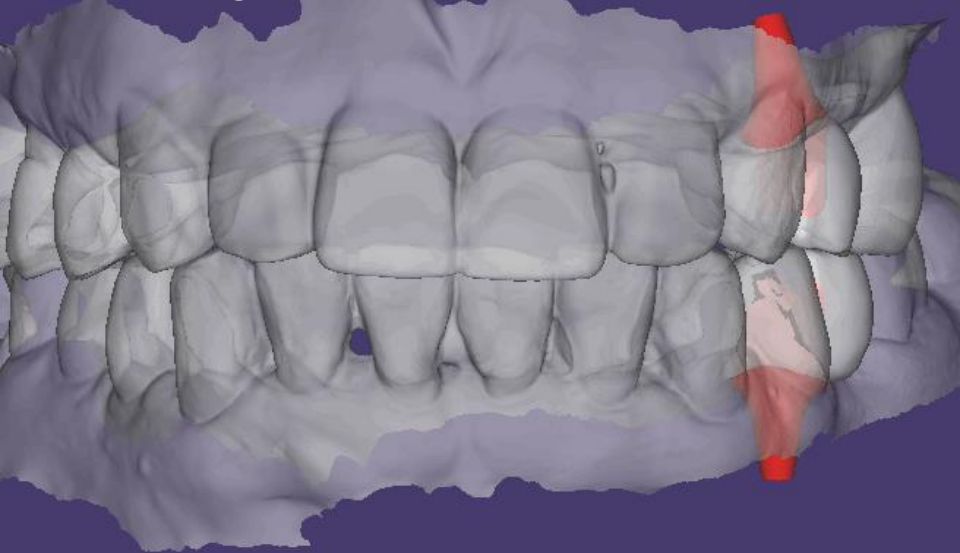Healing : 1 month 3 weeks (2018-11-23)



# Intra Oral Scanning



CAD Design (#24 Customized abutment / Temporary)

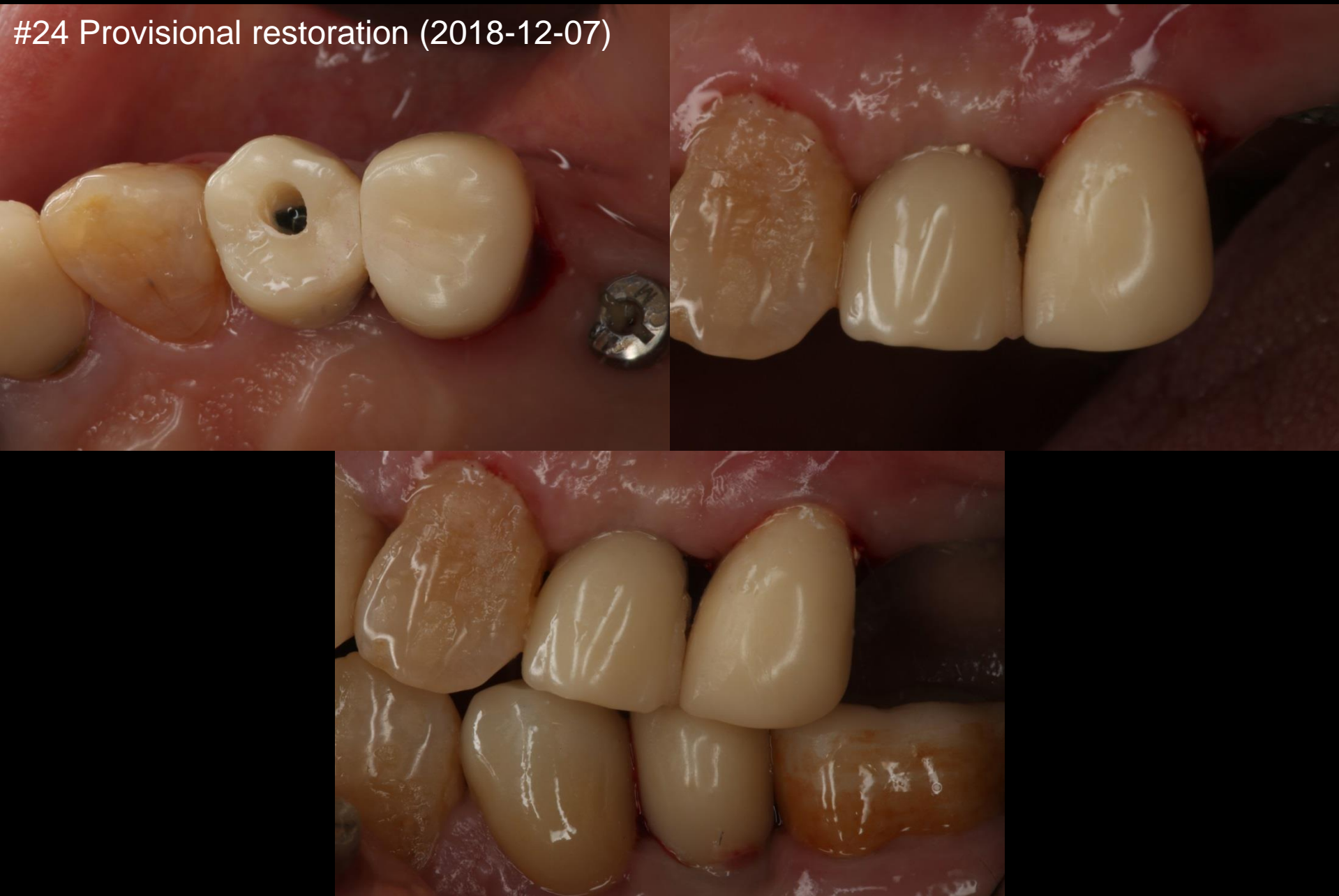

## #24 Customized abutment / Temporary



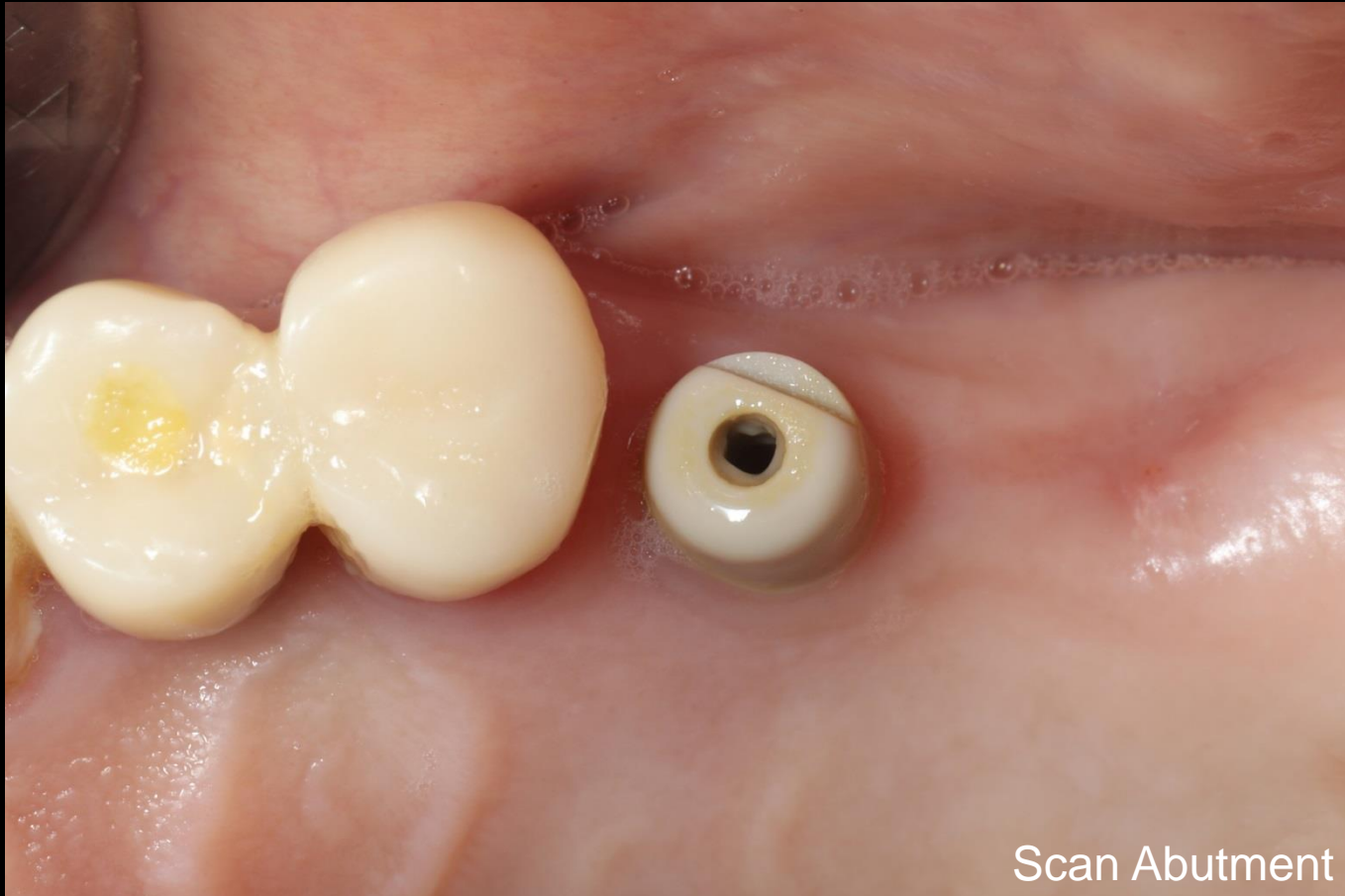


#24 Provisional restoration (2018-12-07)



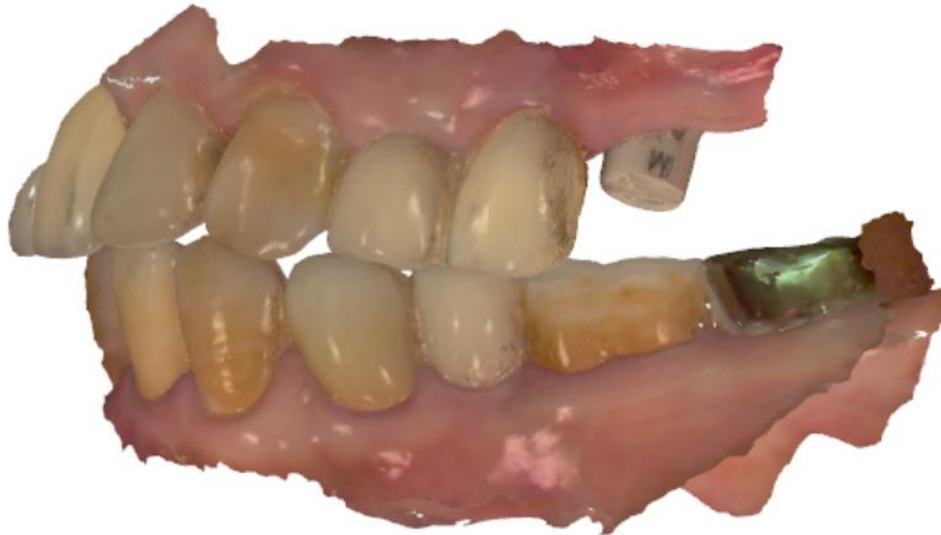
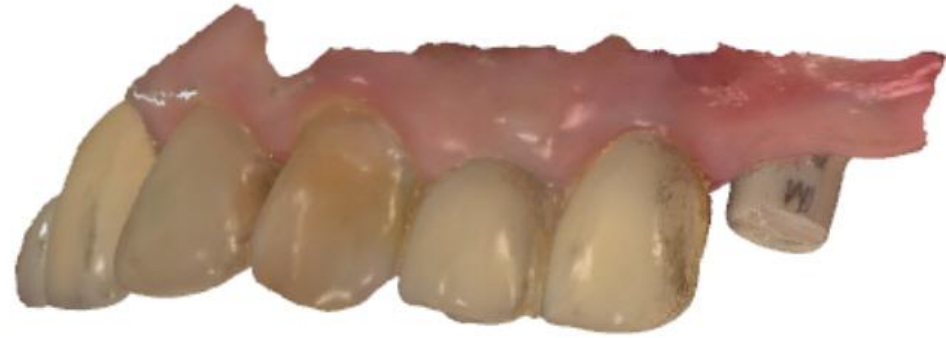
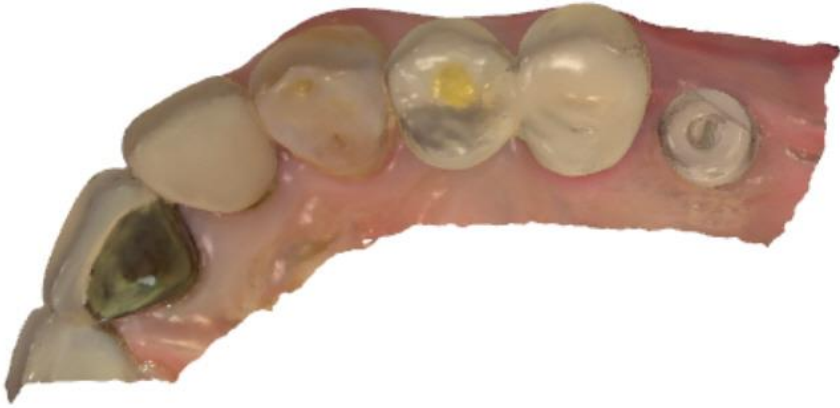#26 Healing : 3 months (2019-01-11)

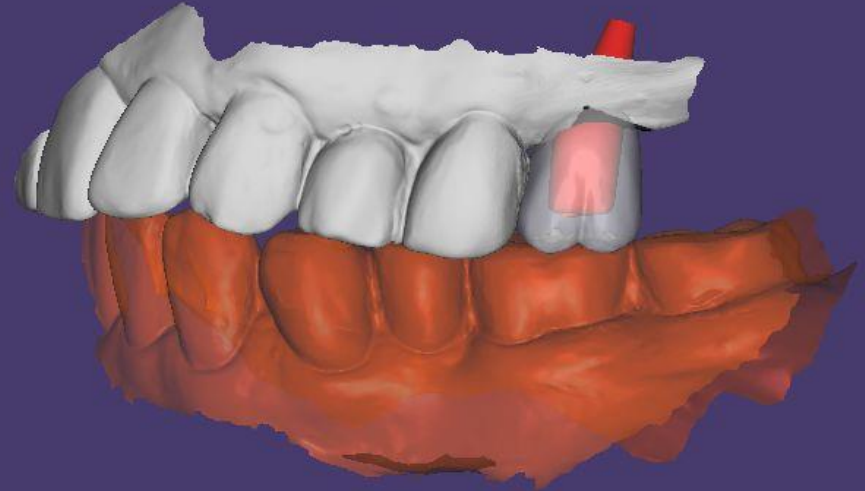
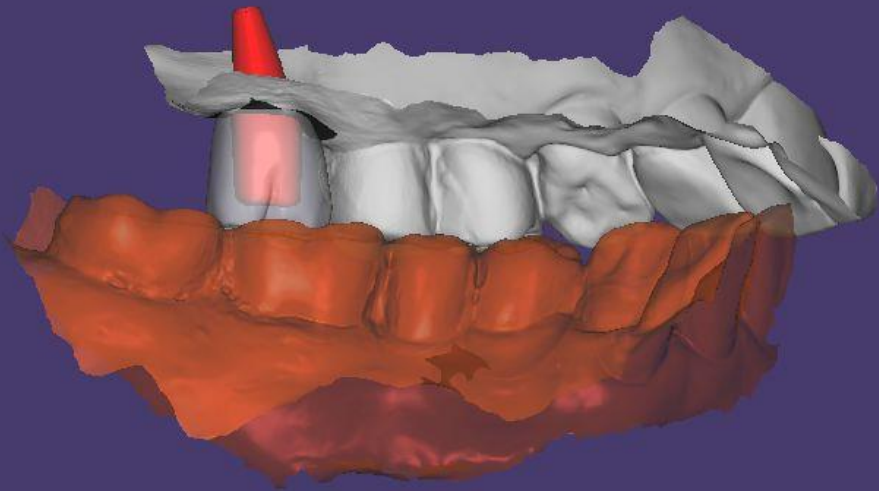
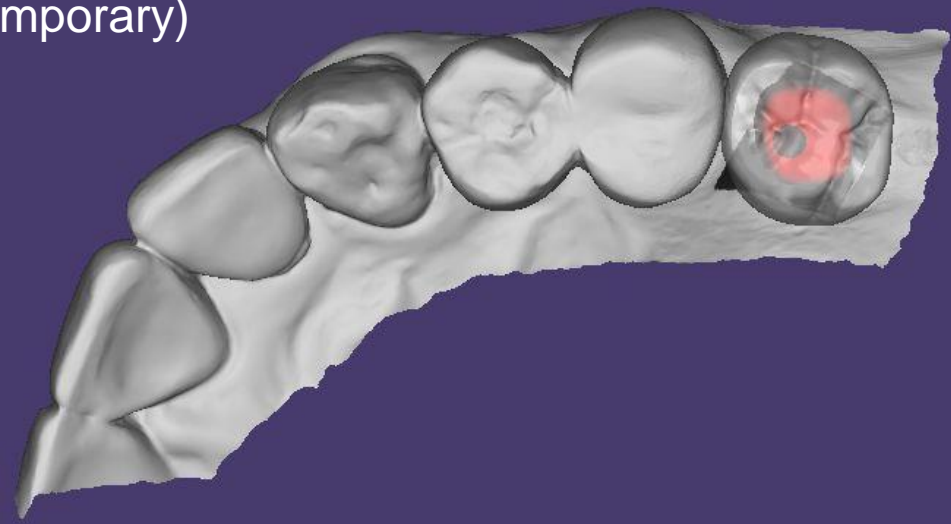
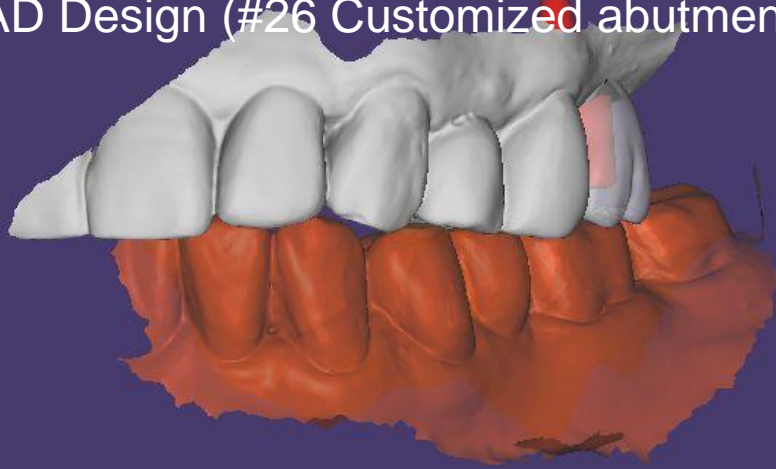

Scan Abutment

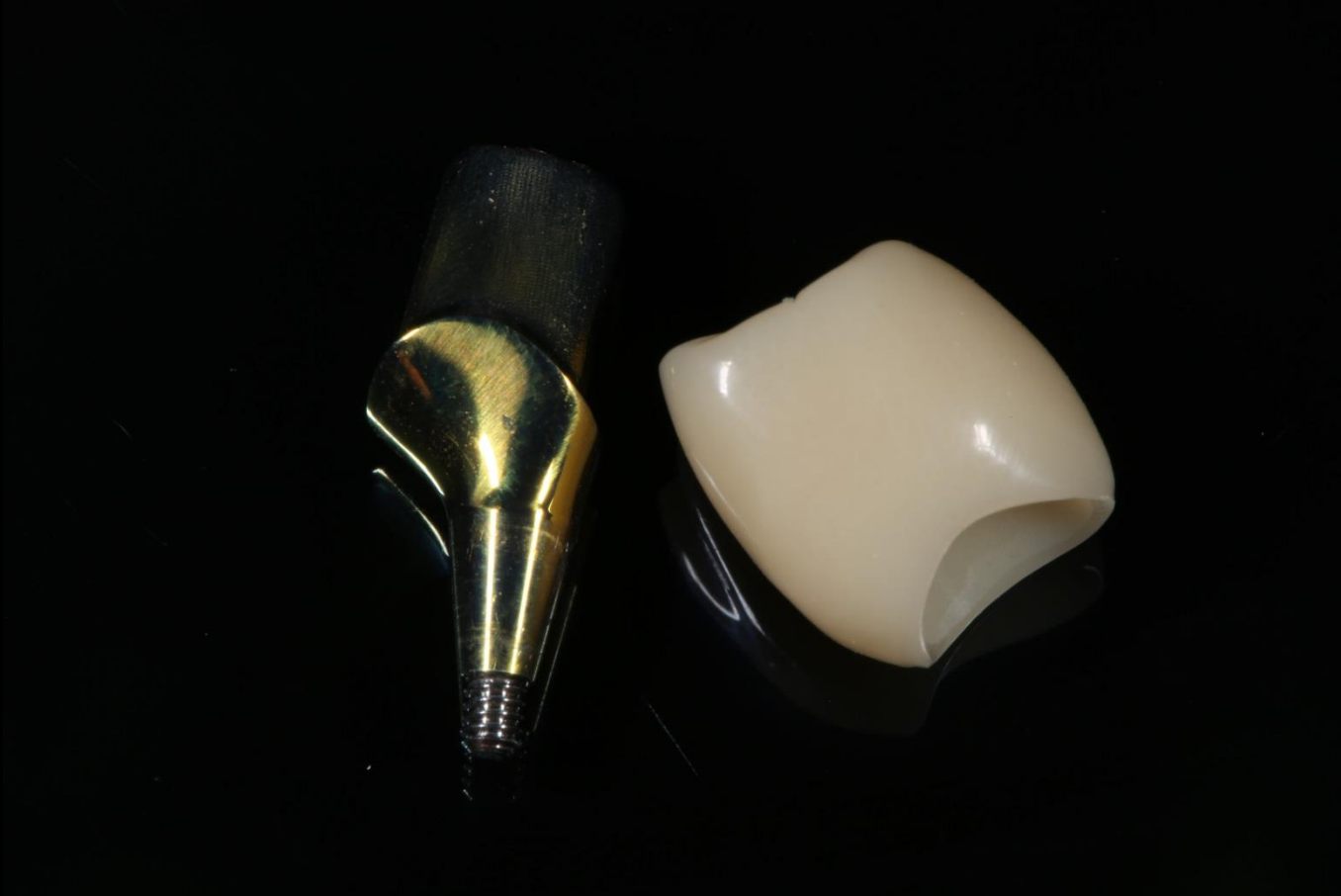# Intra Oral Scanning



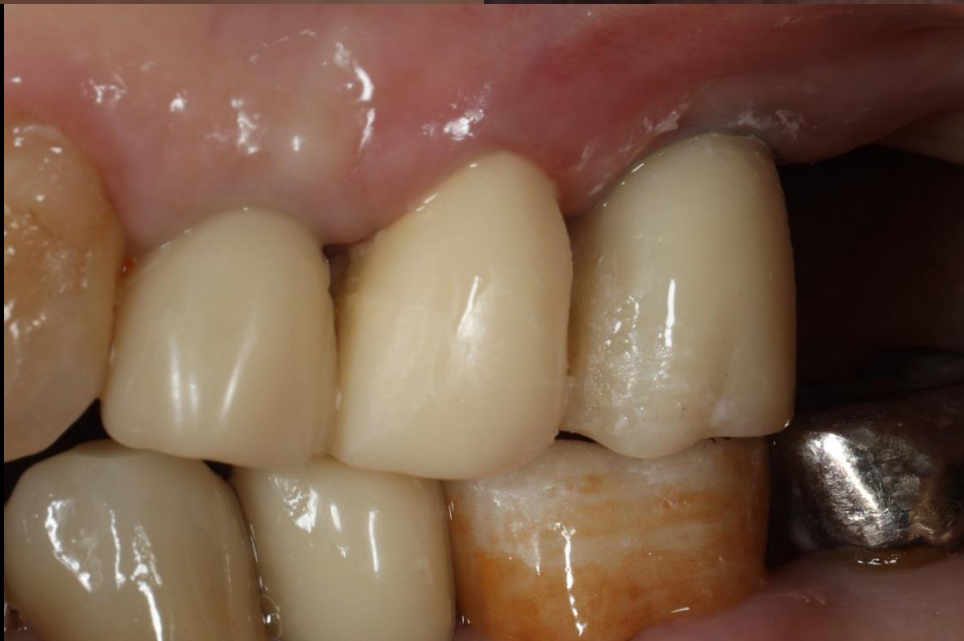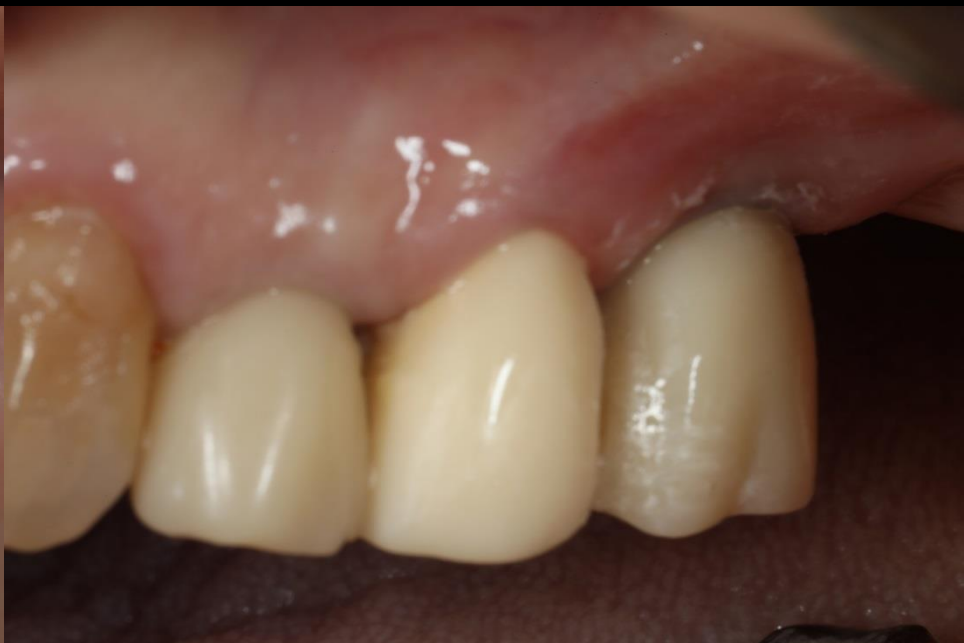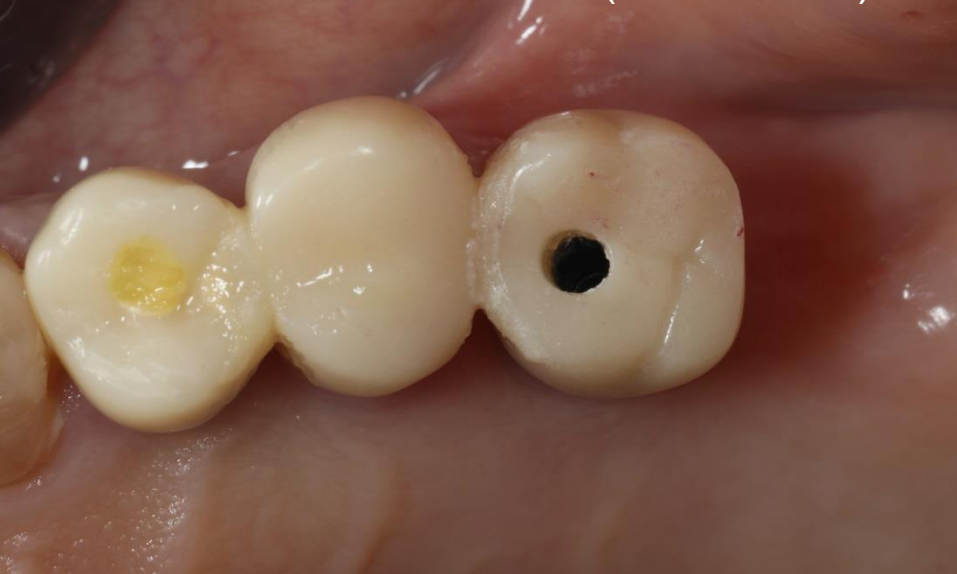CAD Design (#26 Customized abutment / Temporary)



## #26 Customized abutment / Temporary

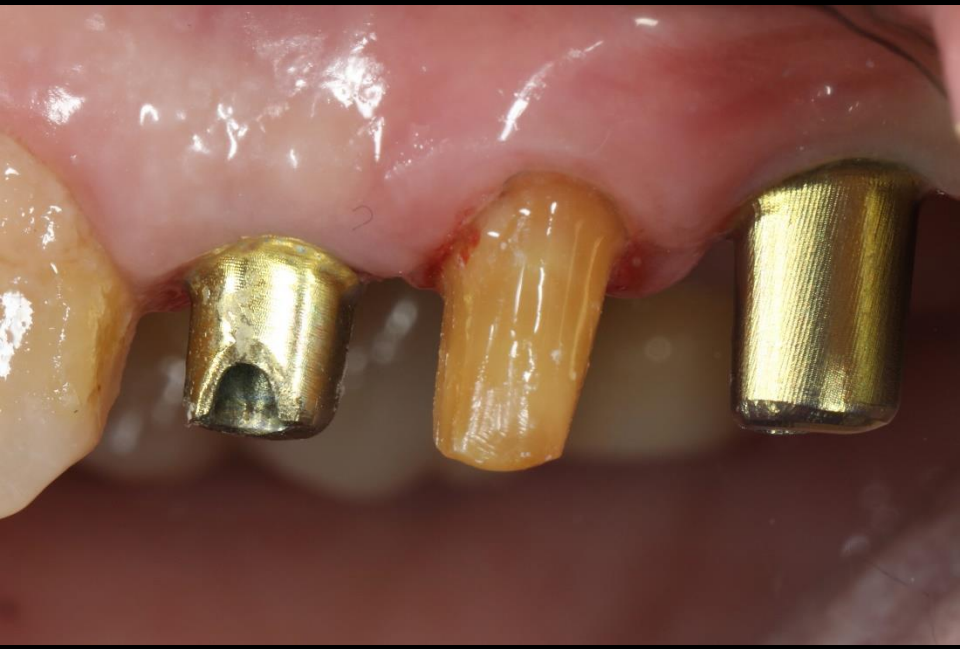
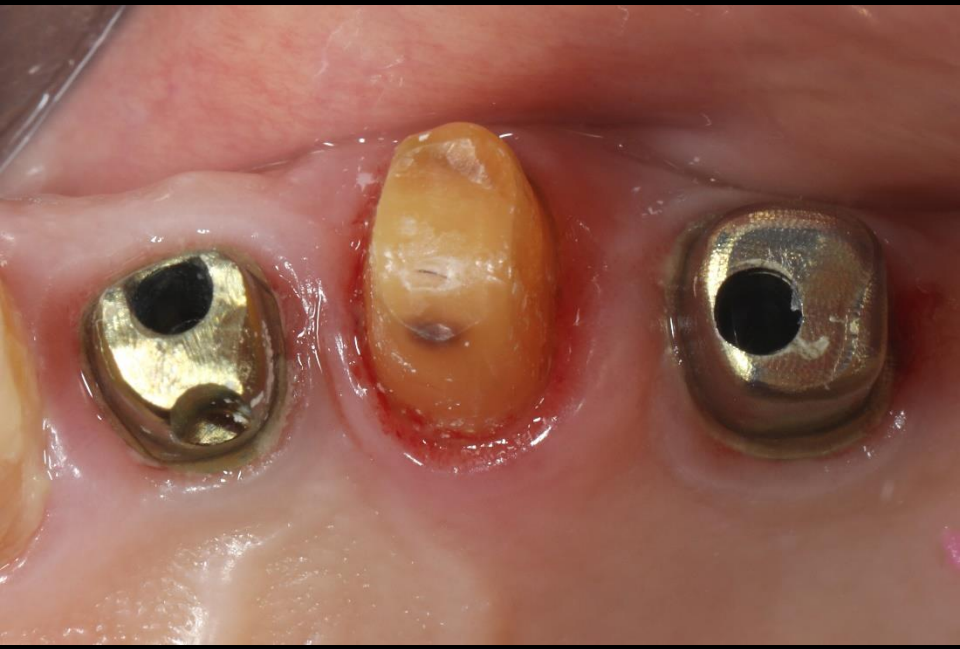
#26 Provisional restoration (2019-01-11)

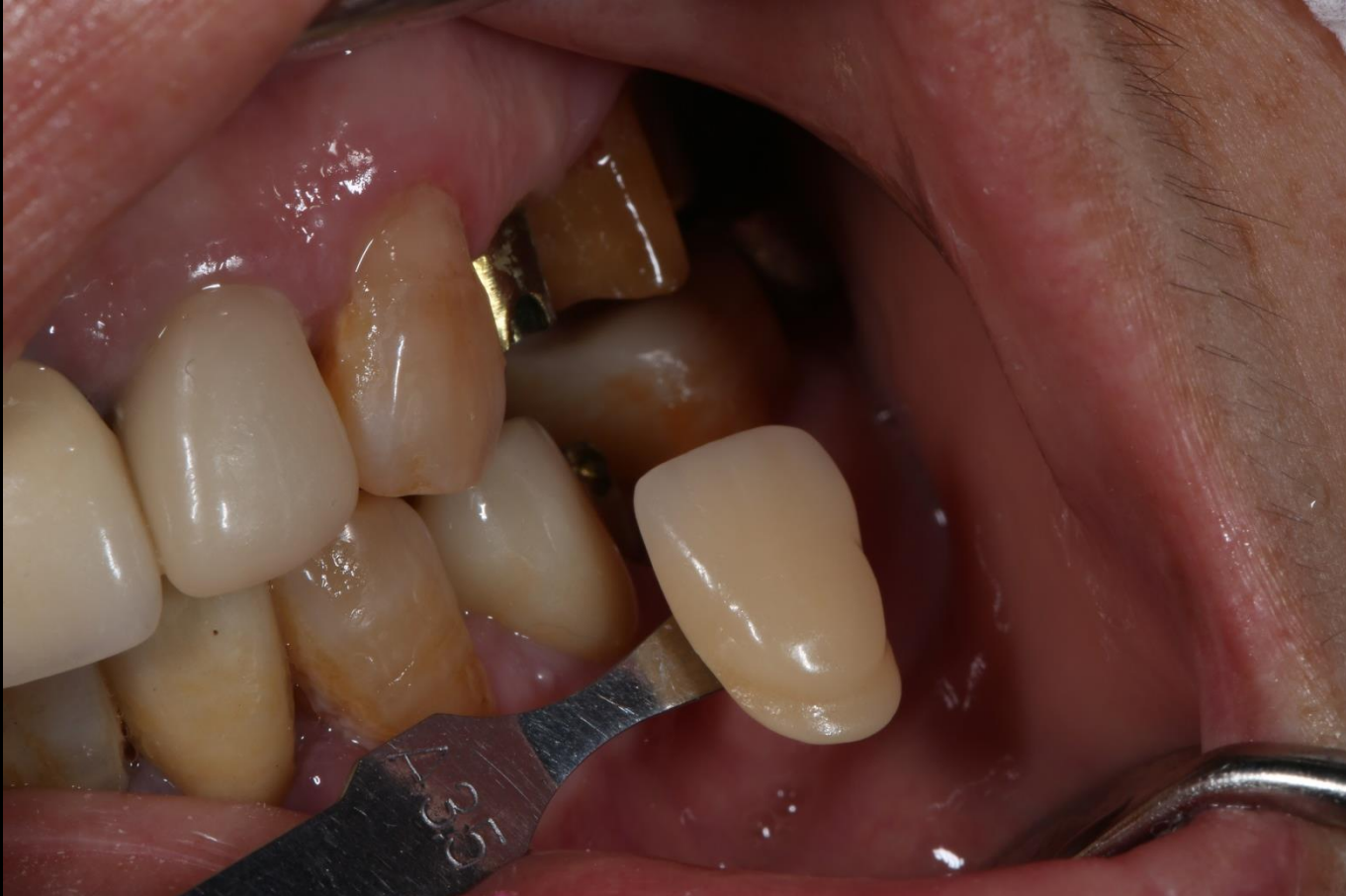



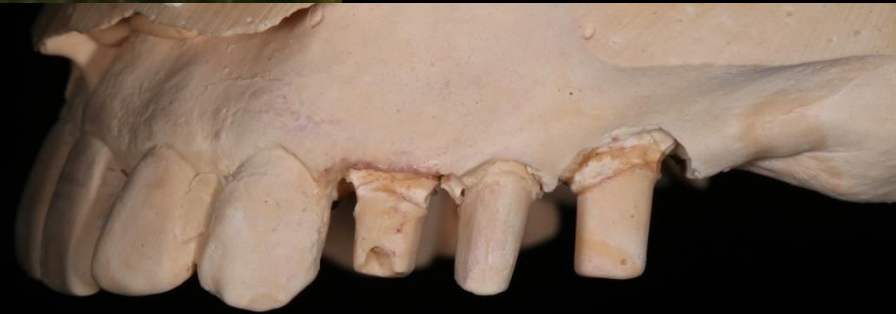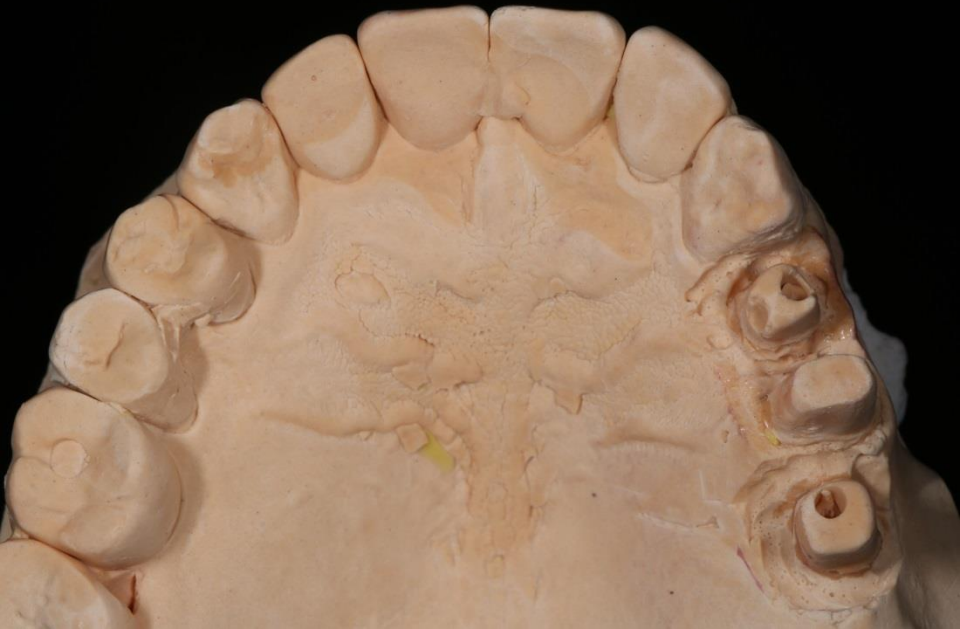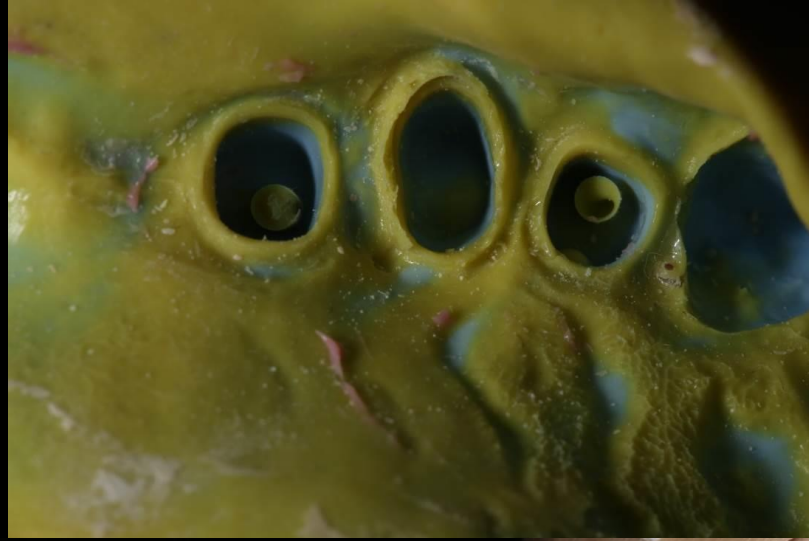Impression (2019-02-22)



# Shade taking

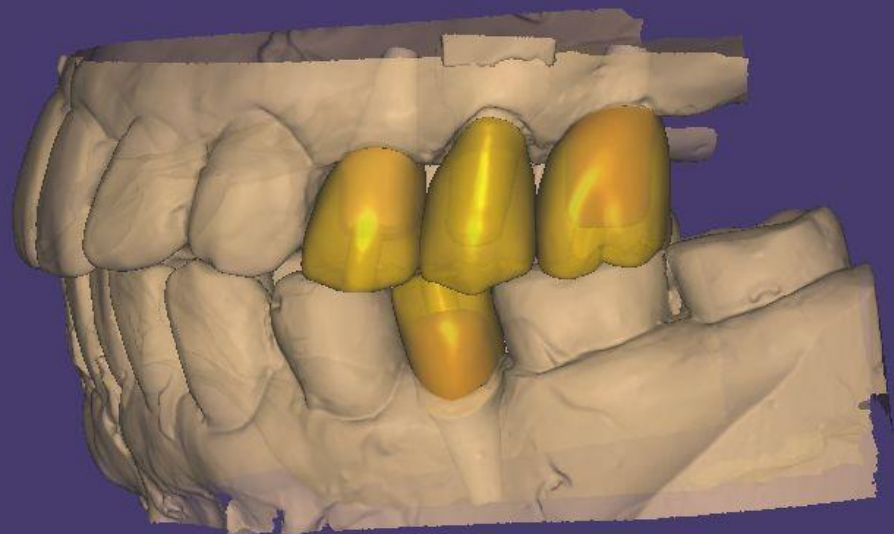
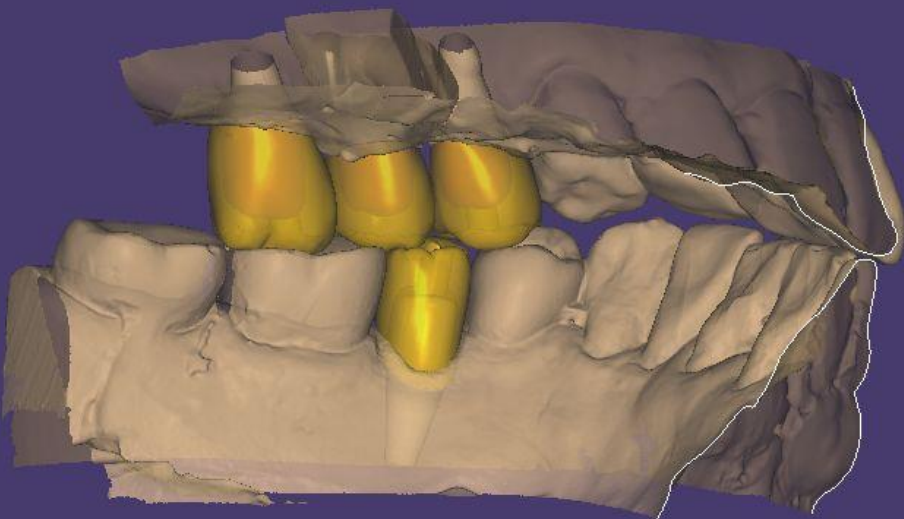
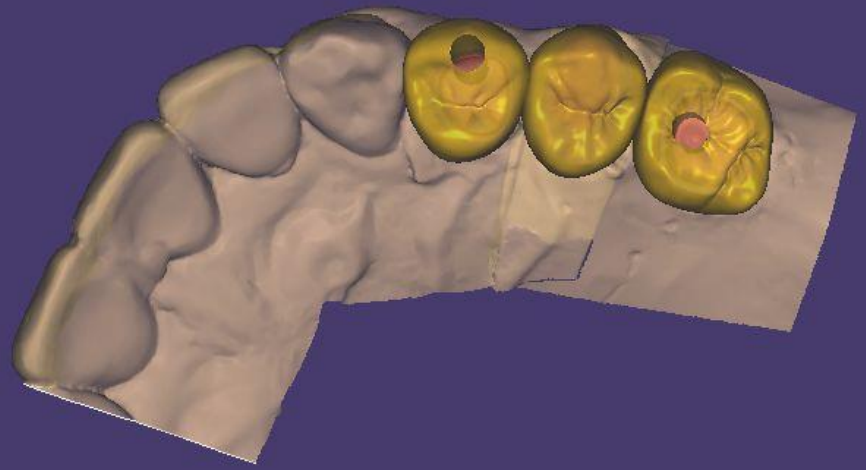
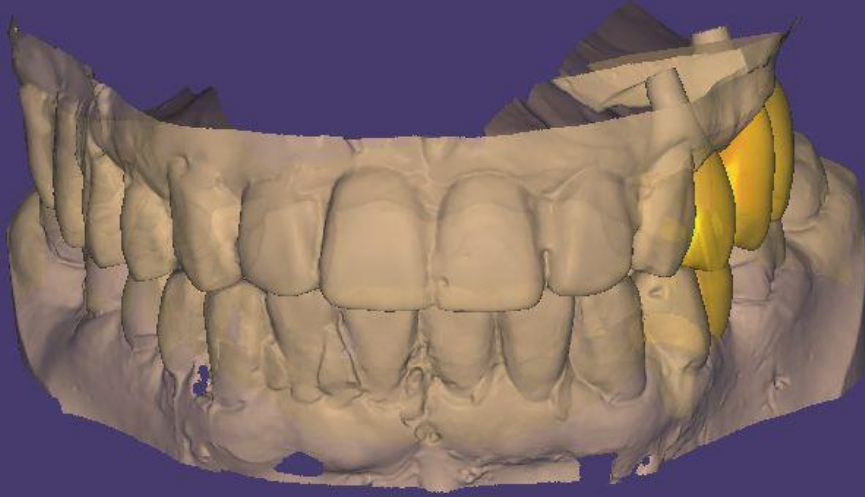


# Impression model / Model

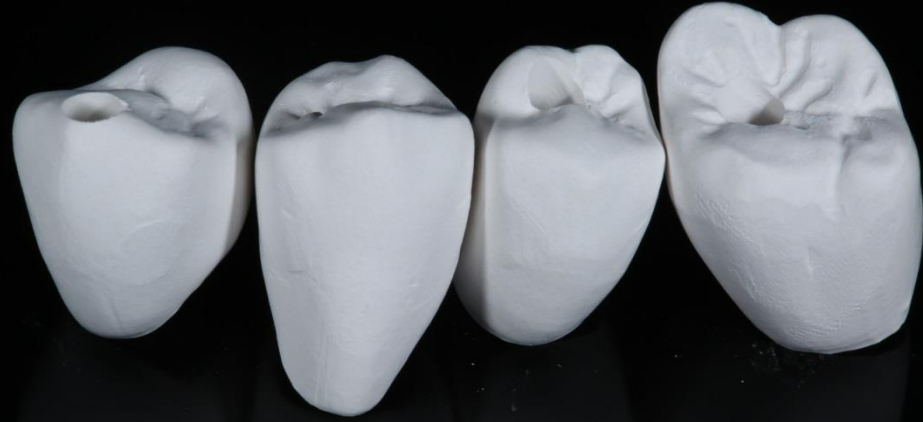
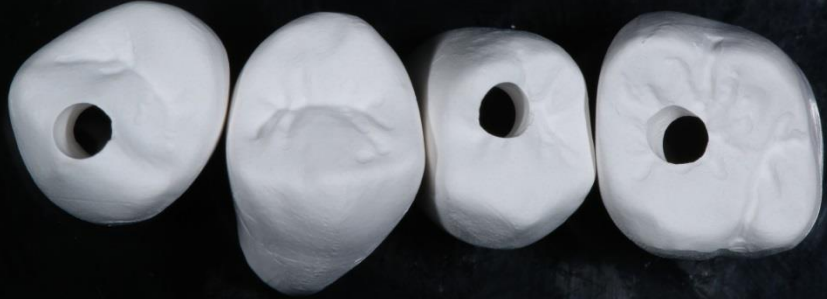


# CAD Design (Final prosthesis)

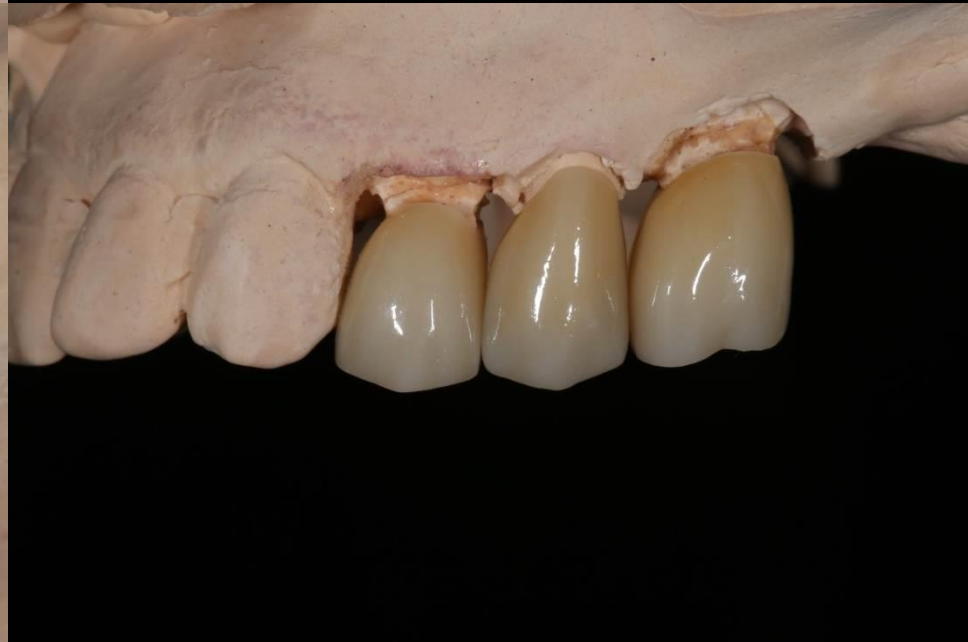
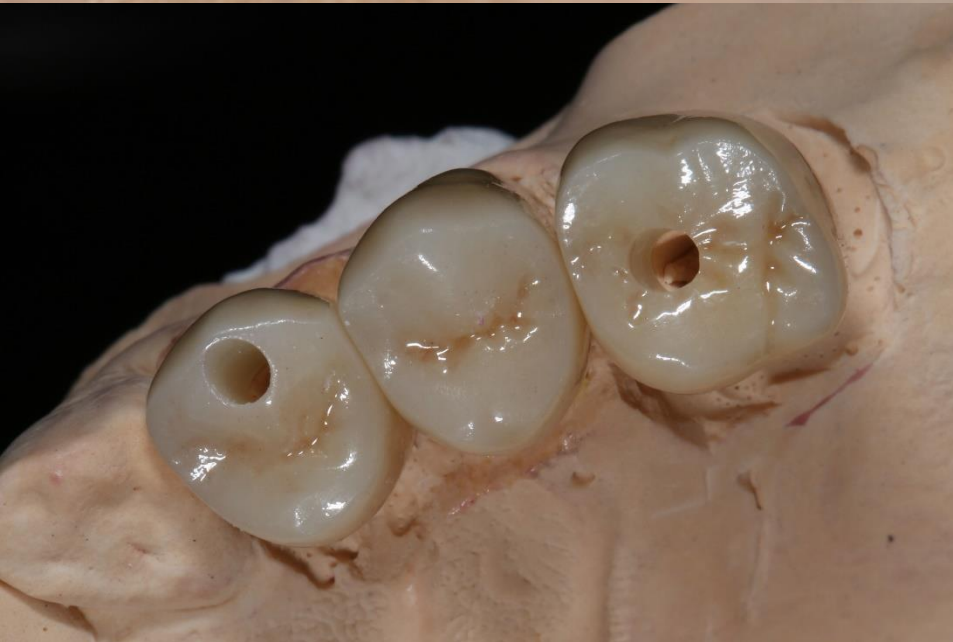
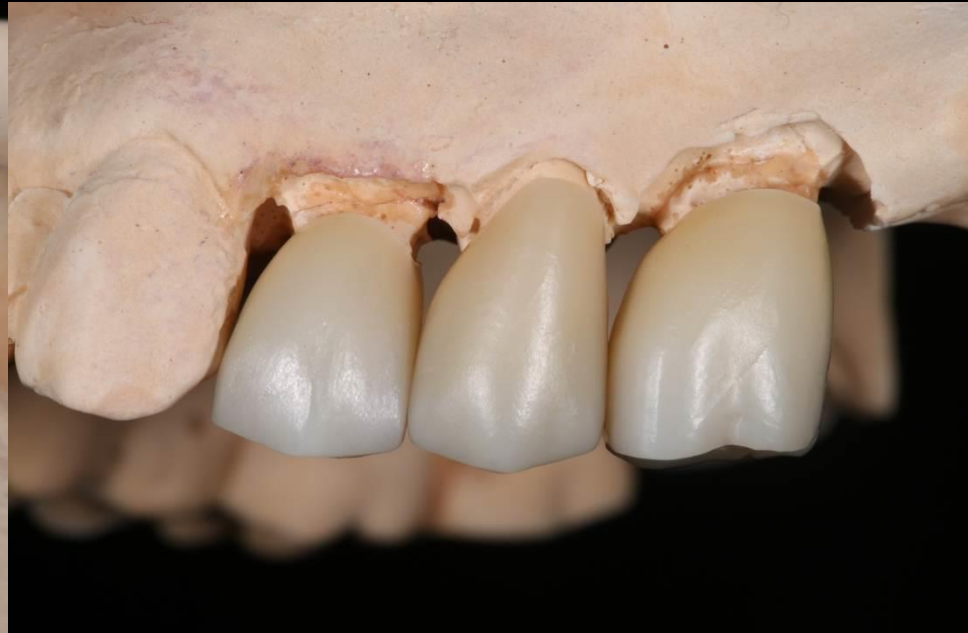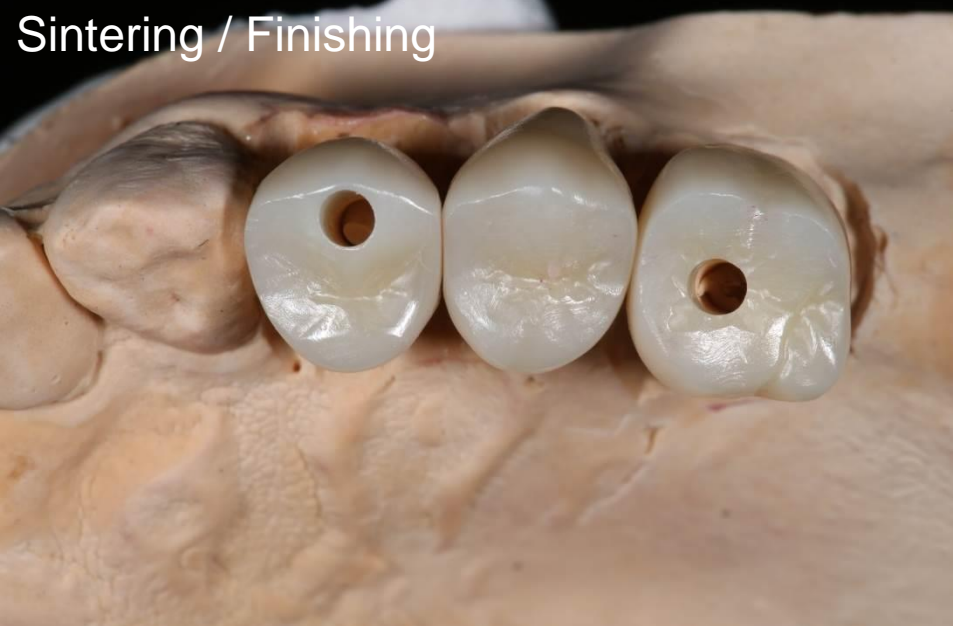Milling / Brushing

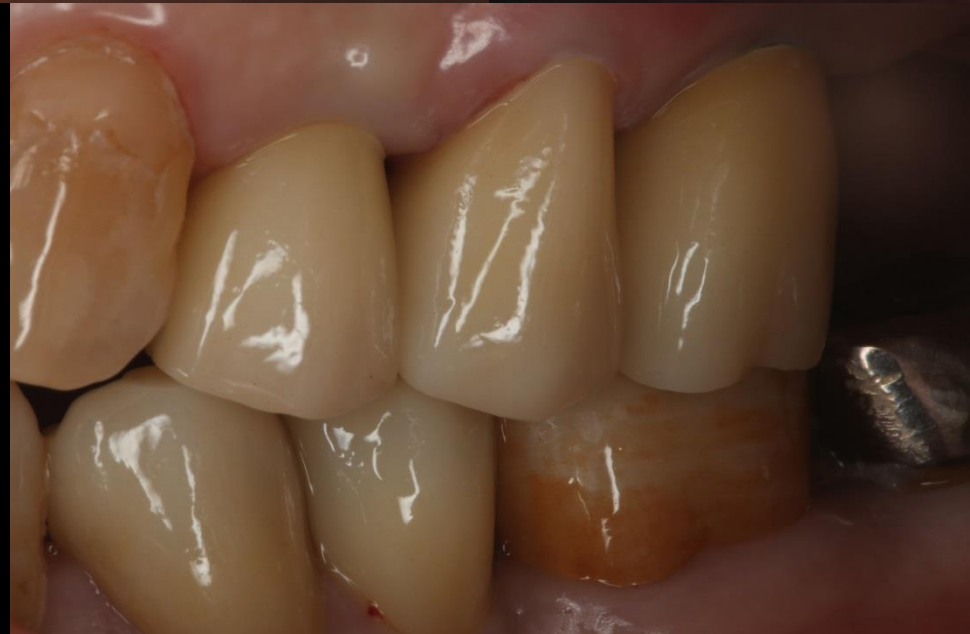
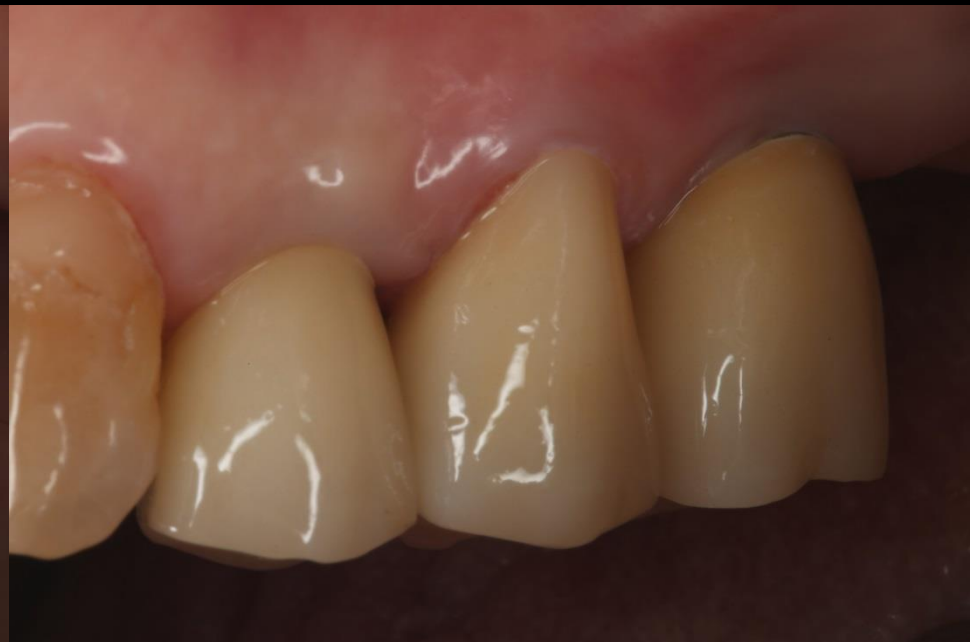
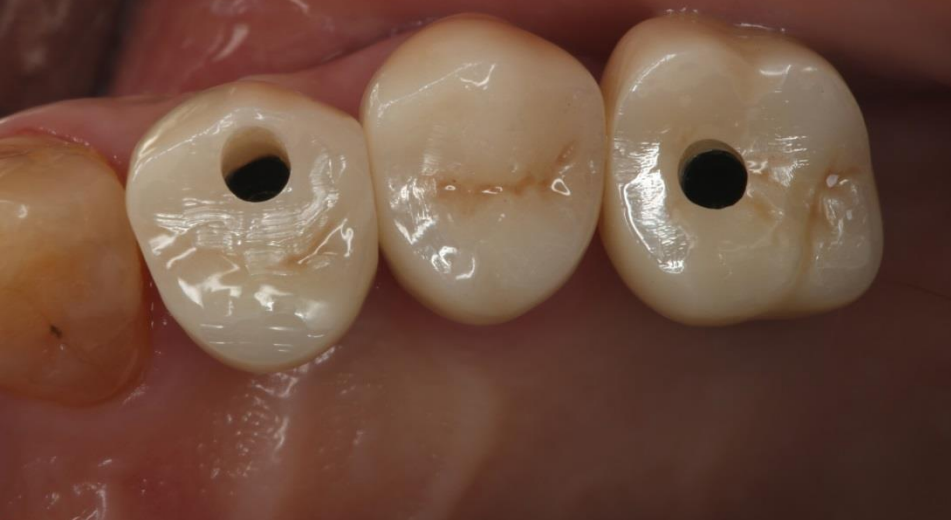

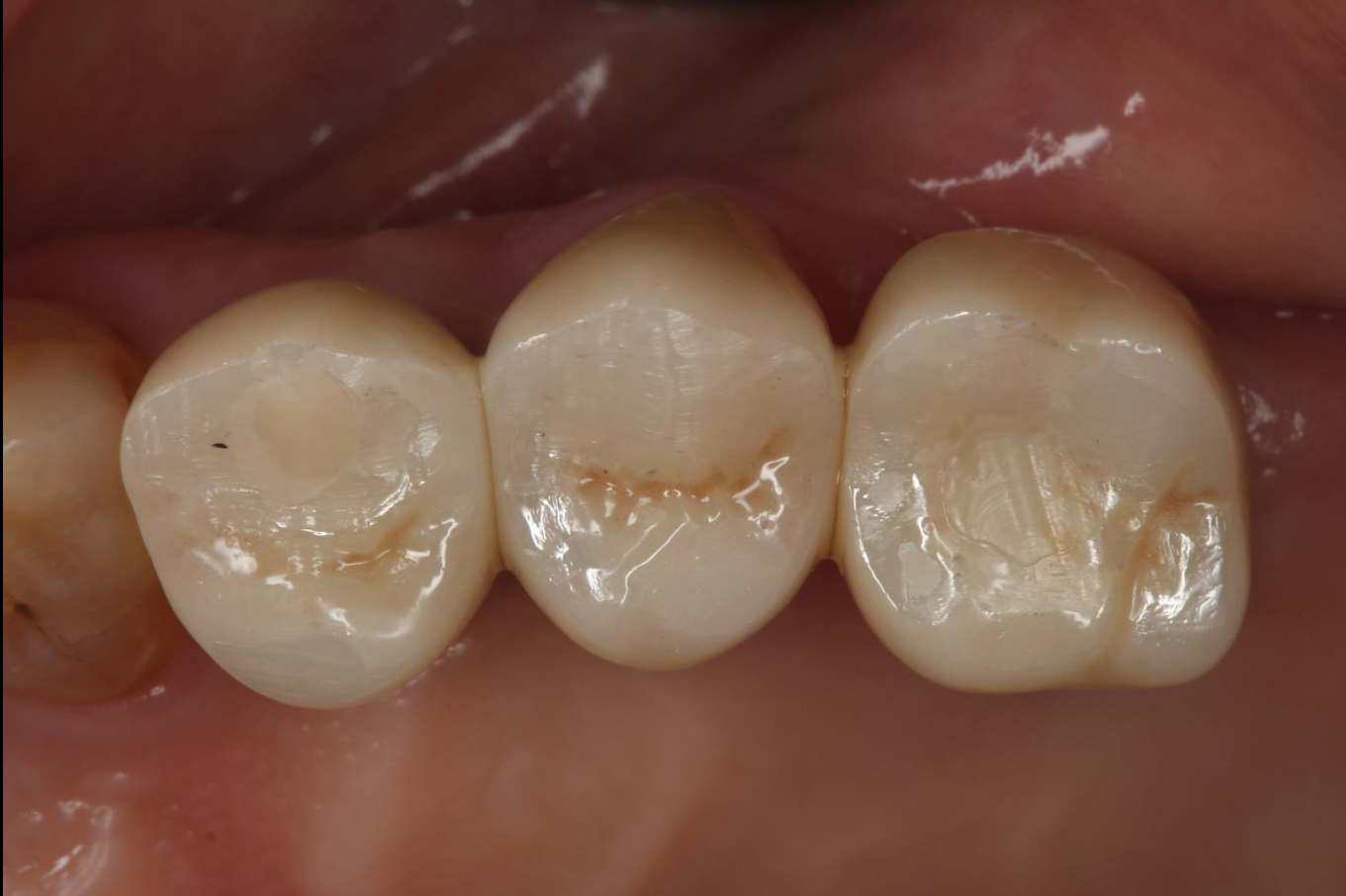Sintering / Finishing



Final prosthesis (2019-03-22)



HRF (2019-04-12)



Follow up : 4 months (2019-08-02)

