

Removal of malpositioned implant fixture on post.Maxilla

SuperLine



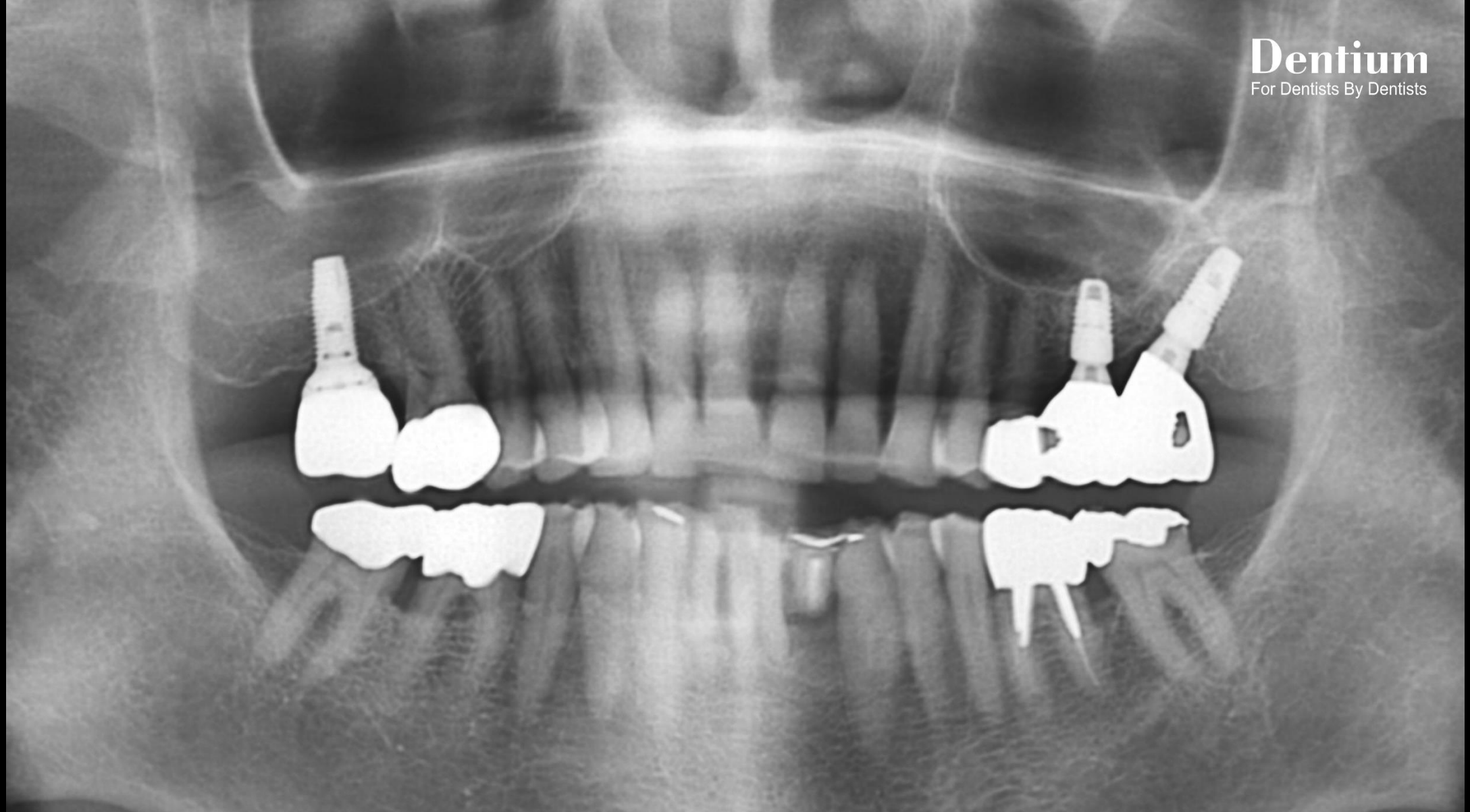
OSTEON™ II



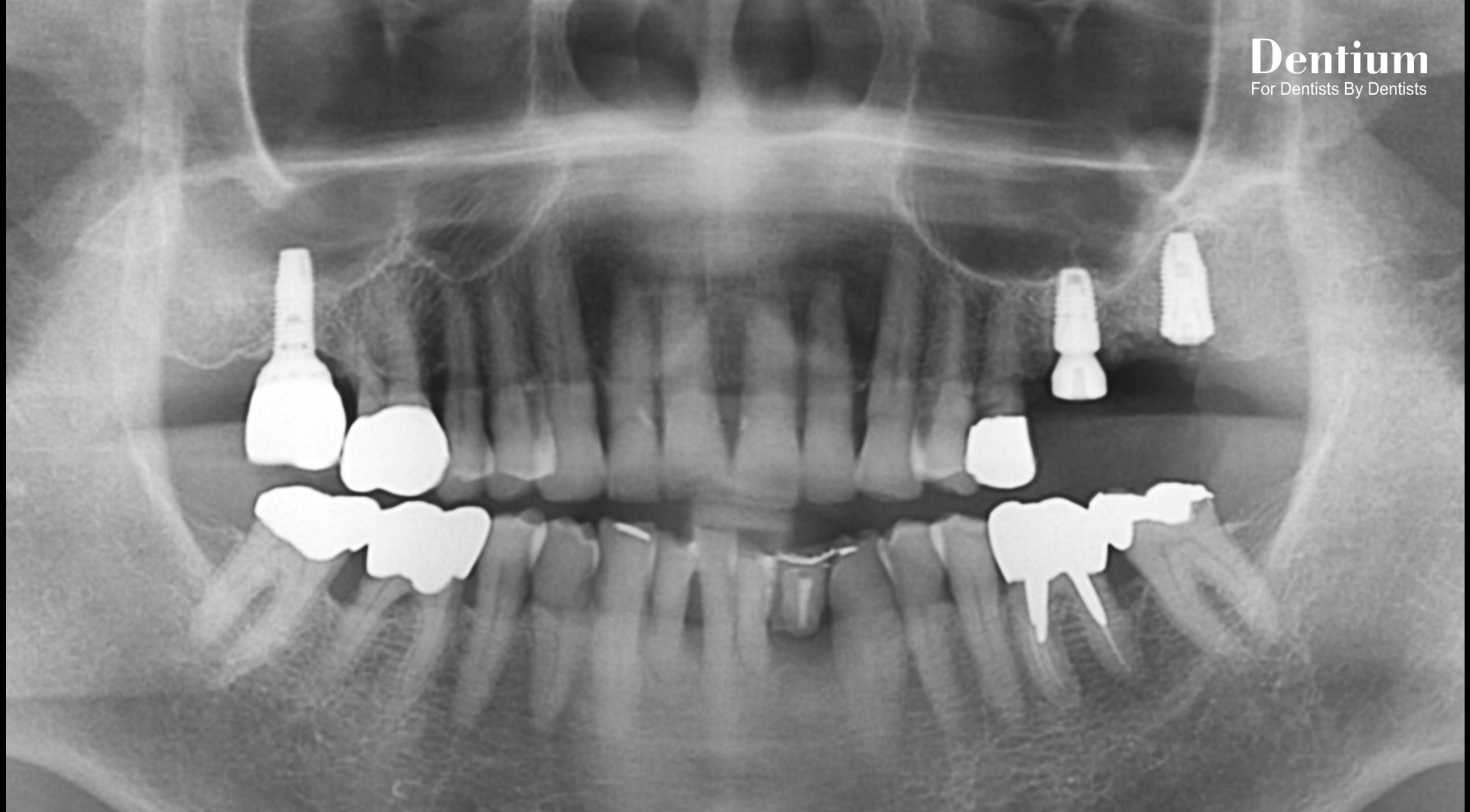
Collagen Membrane



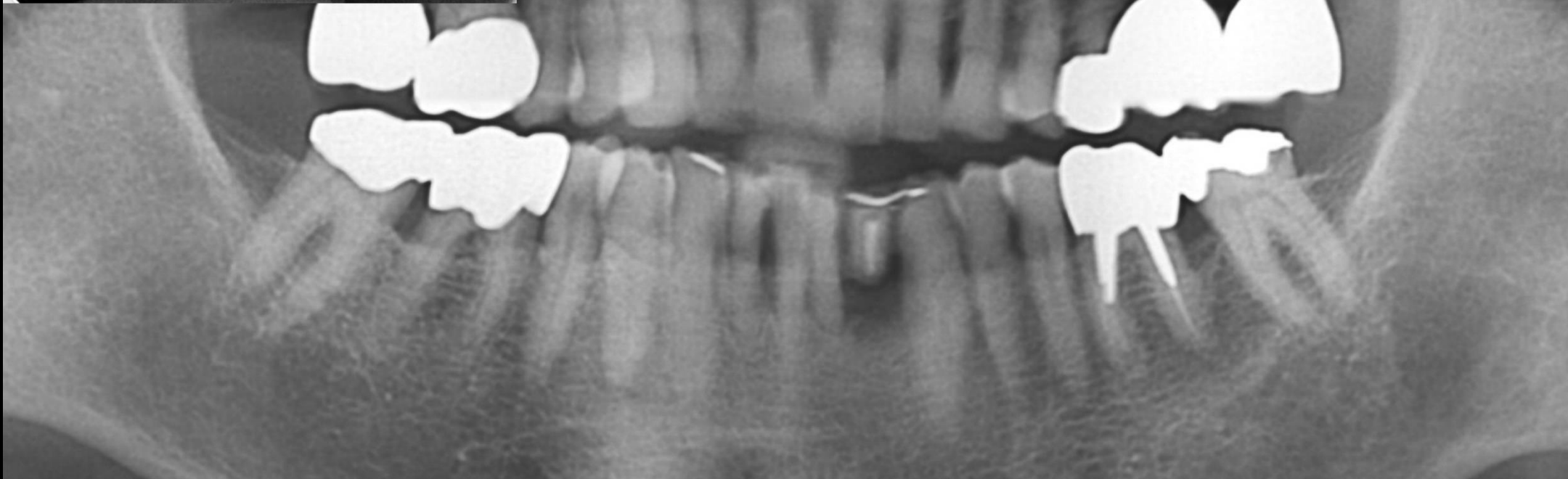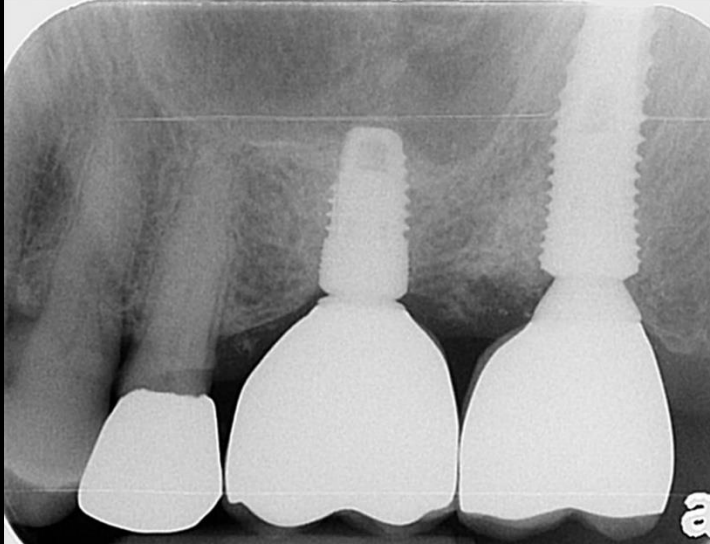
Dr.root
Well dental clinic



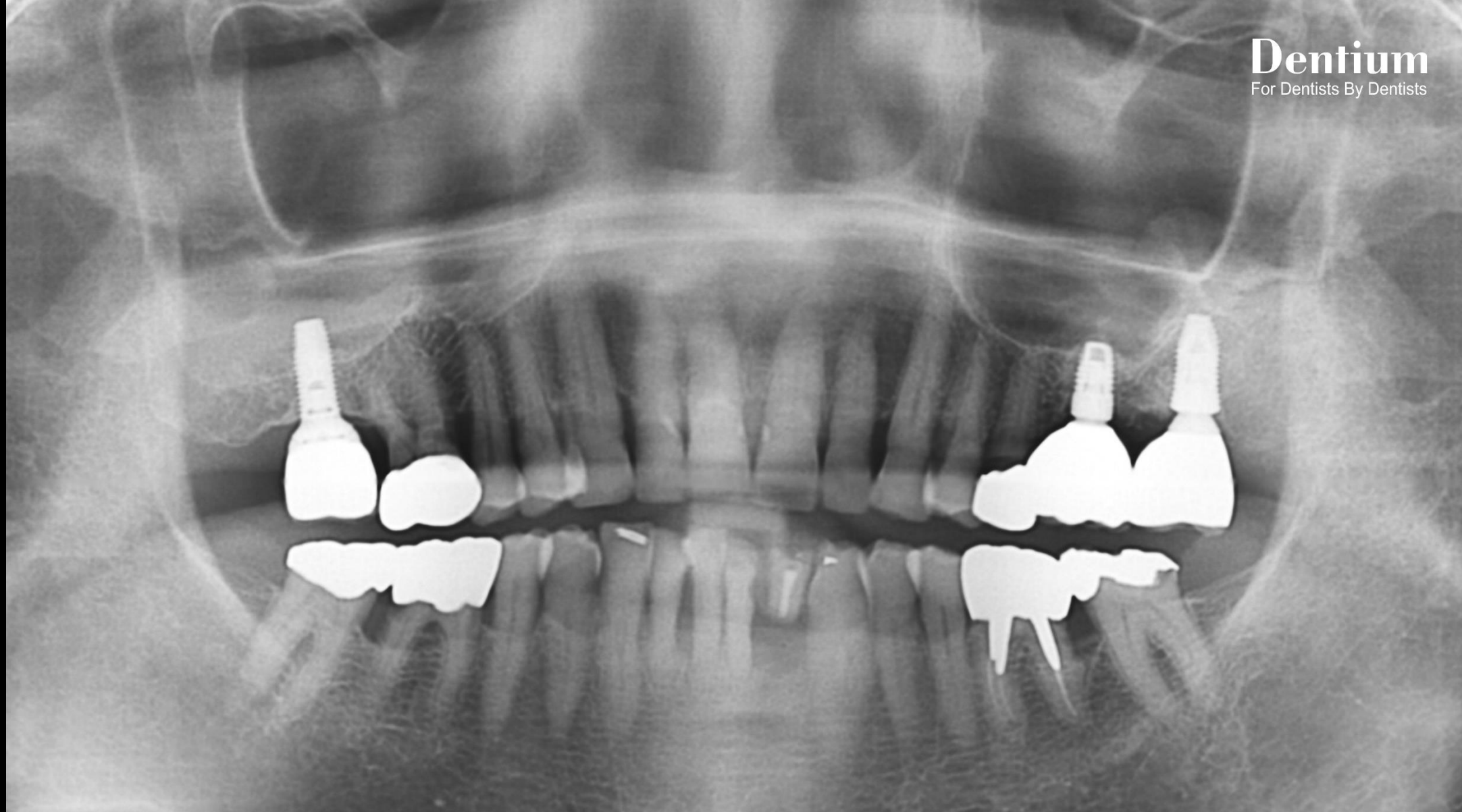
Pre-op



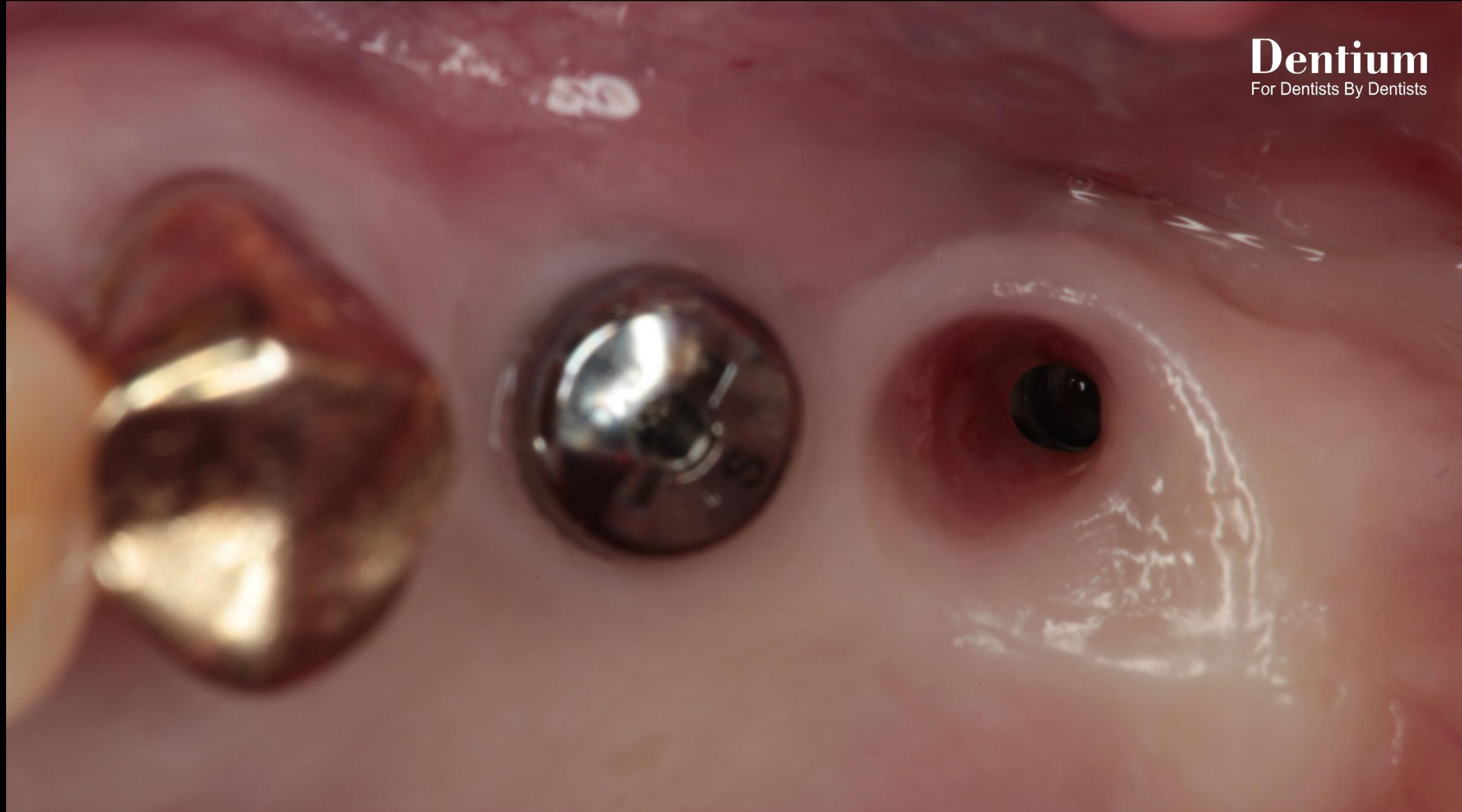
Post-op



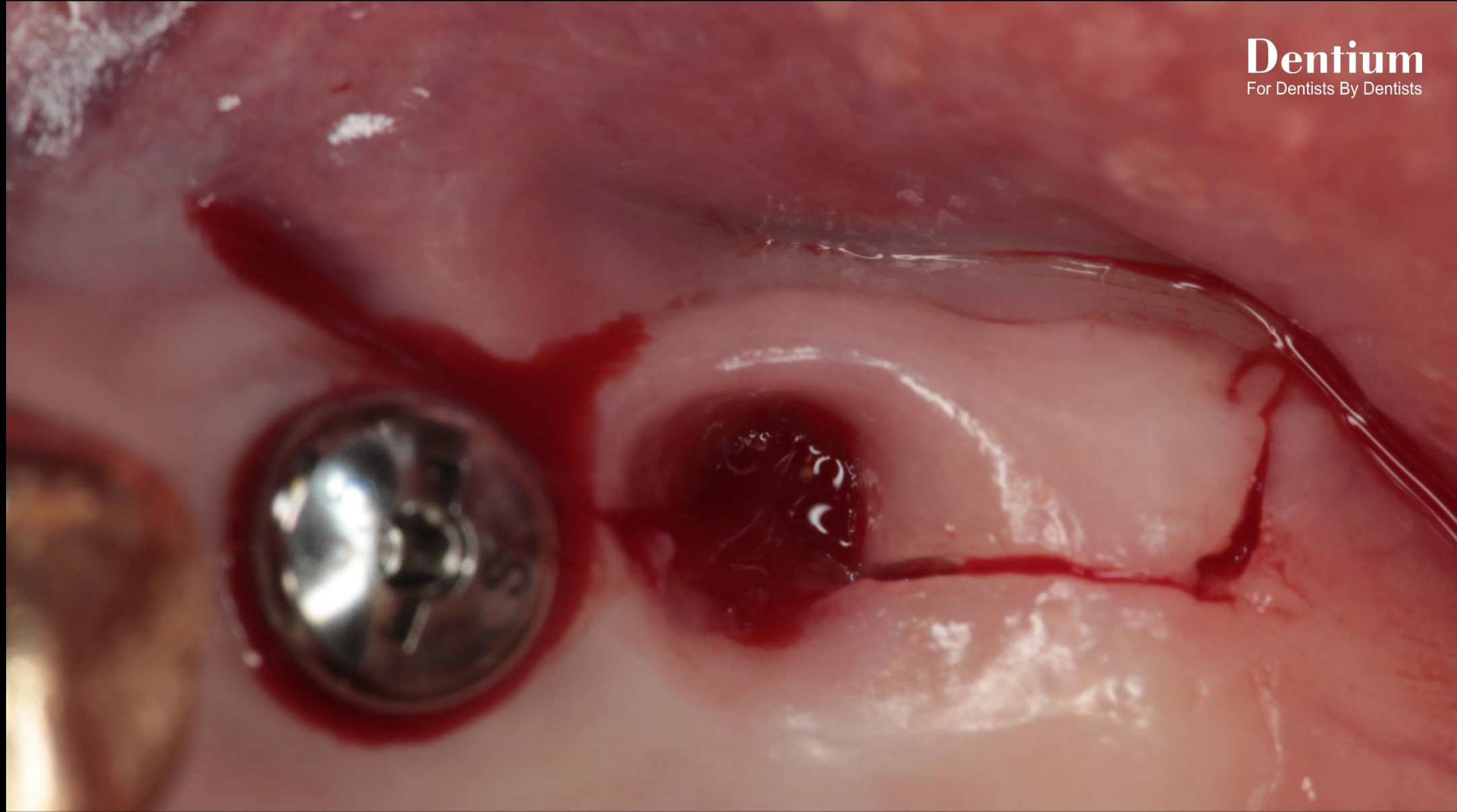
Final prosthesis



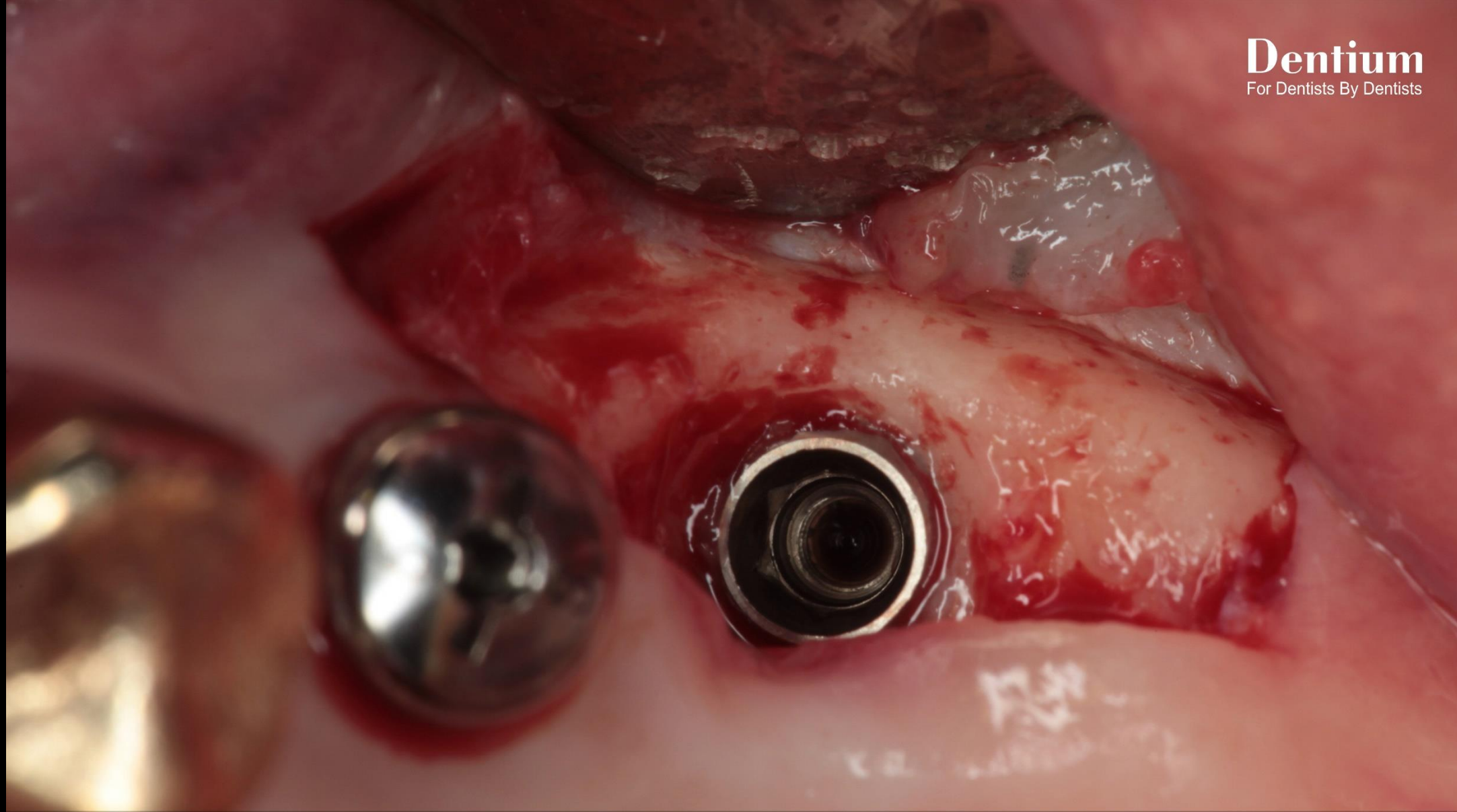
Follow up : 1 year 2 months



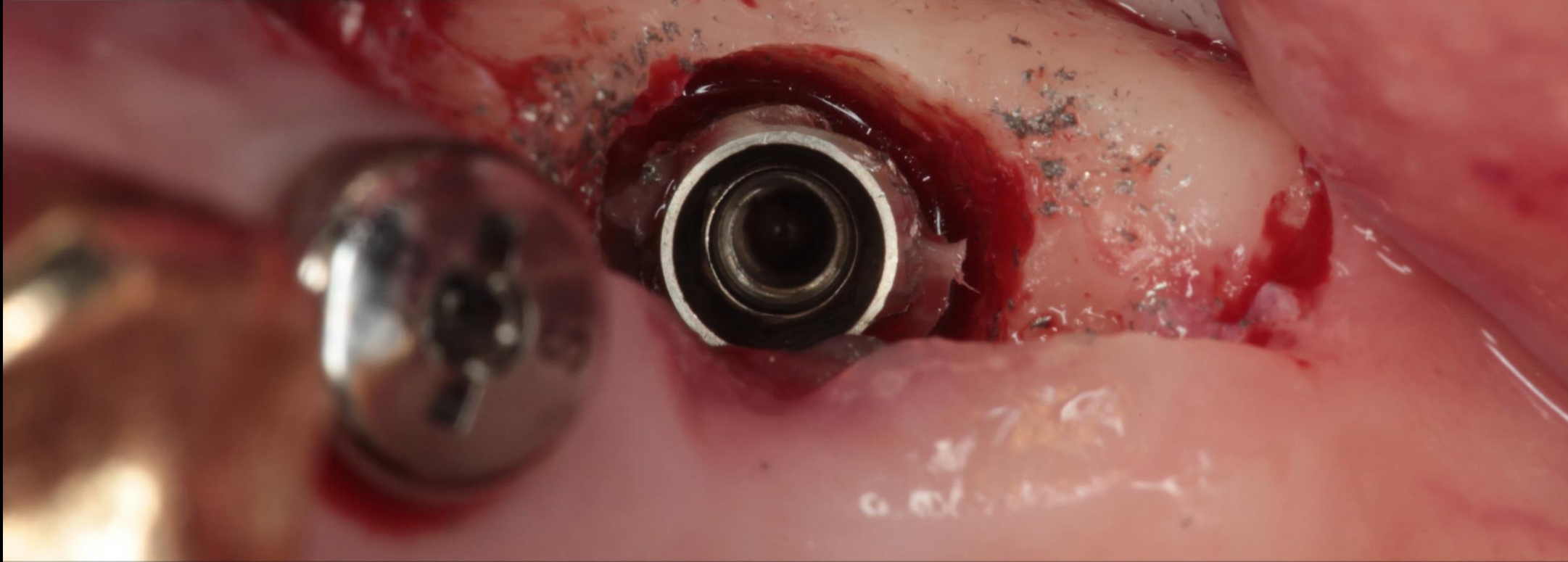
Pre-op



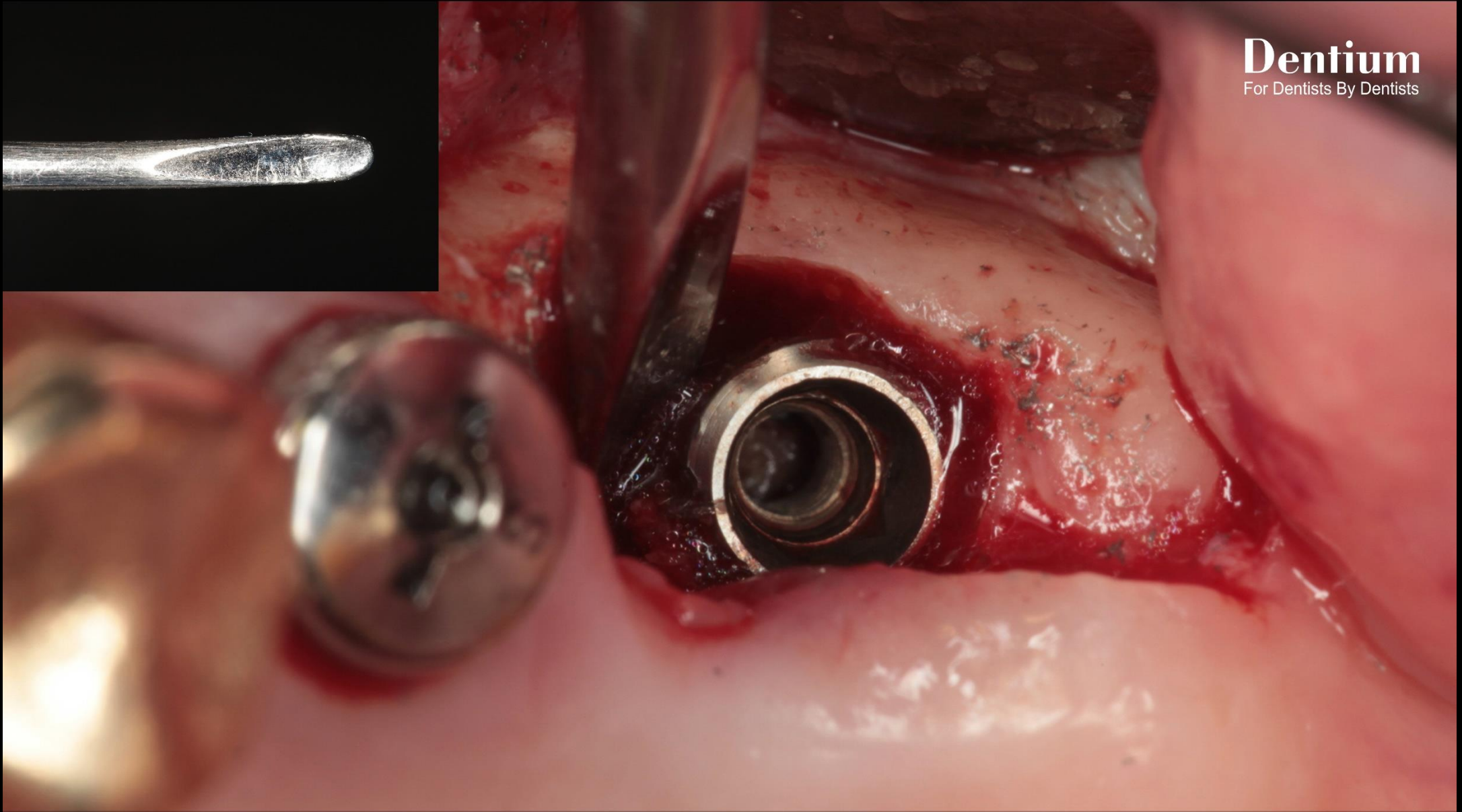
Incision



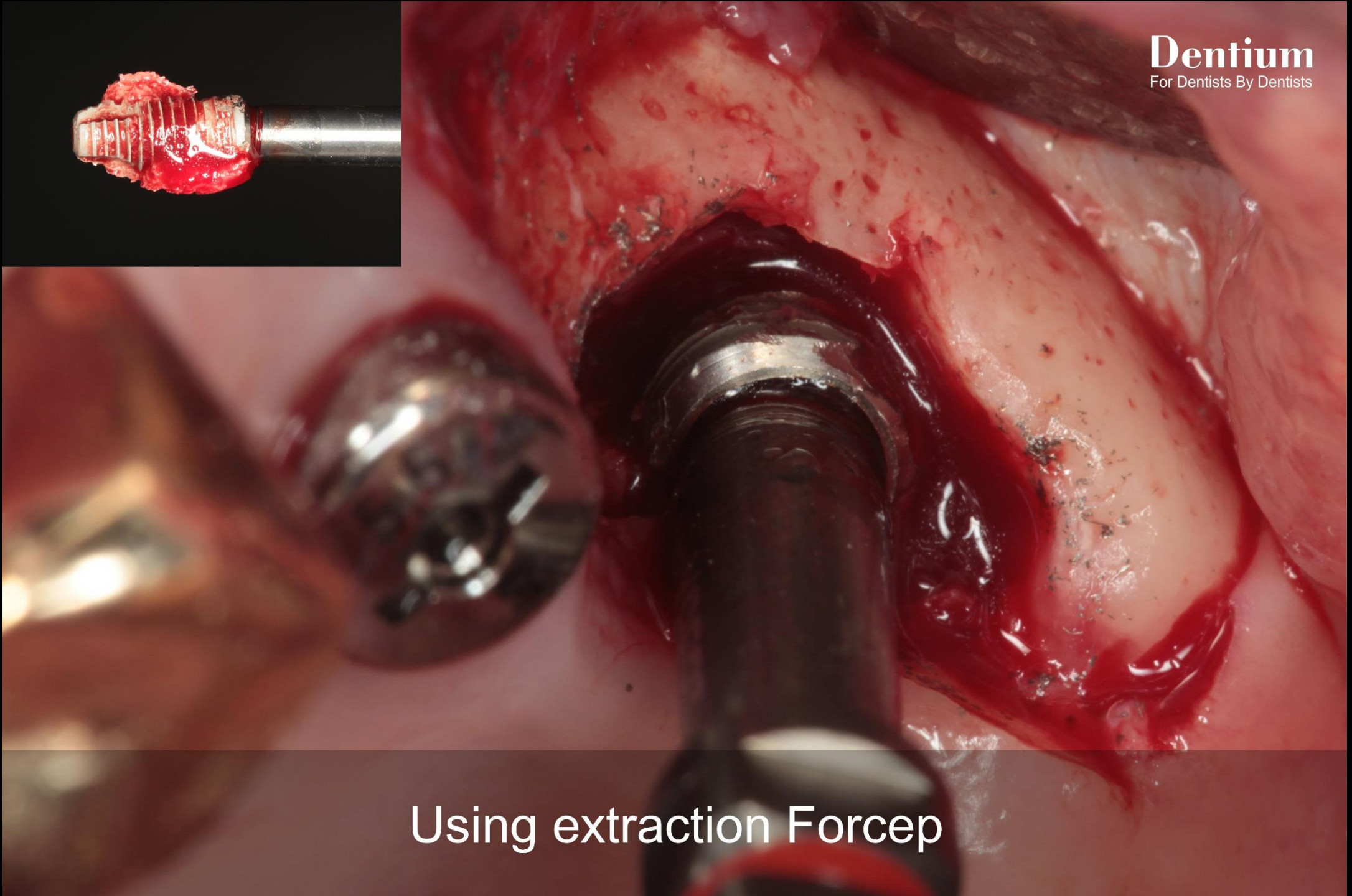Flap reflection



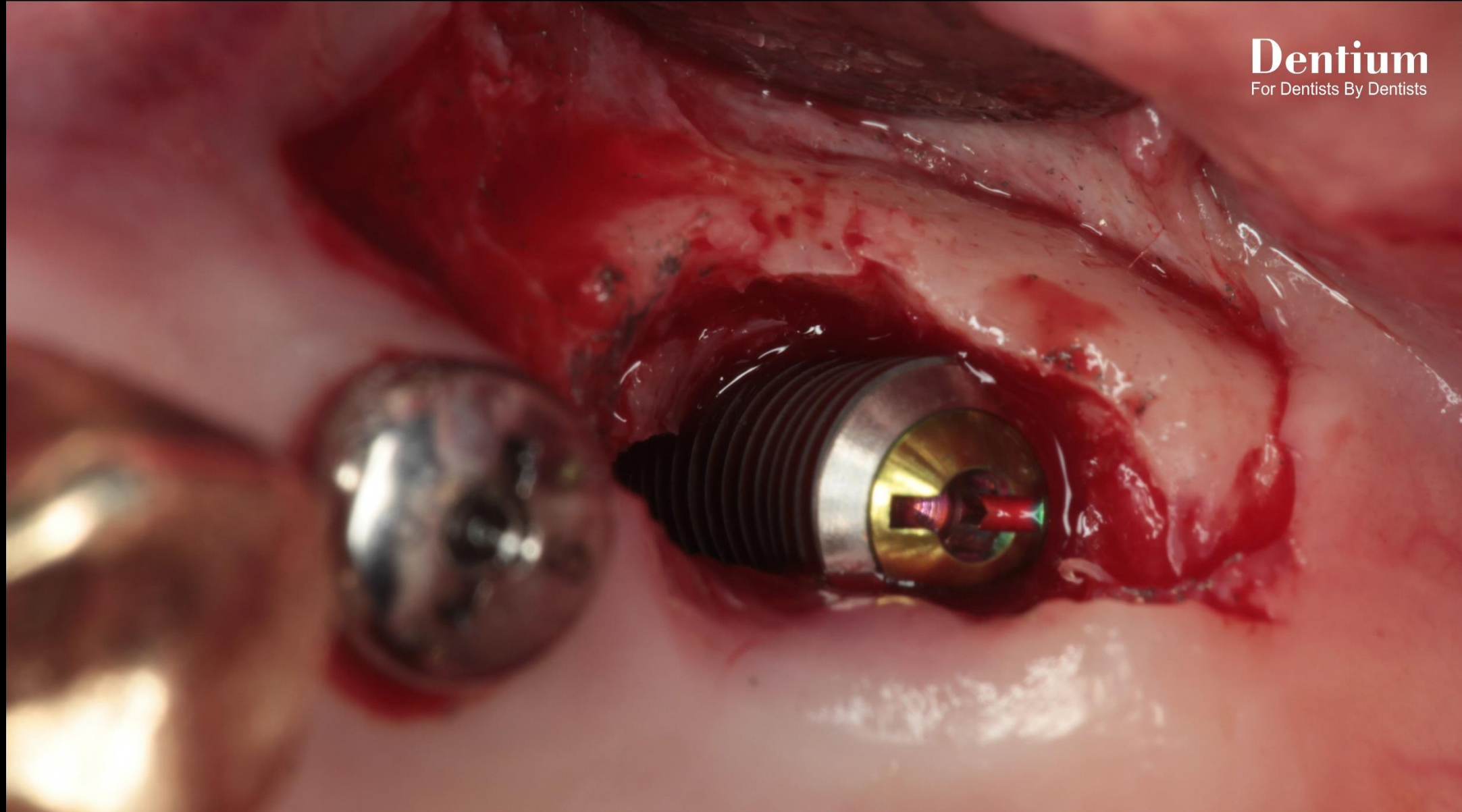
Making 3~4 mm gap between
old fixture & bone using #330 bur



Separate implant fixture from the bone using elevator
(Using small and narrow tip elevator)



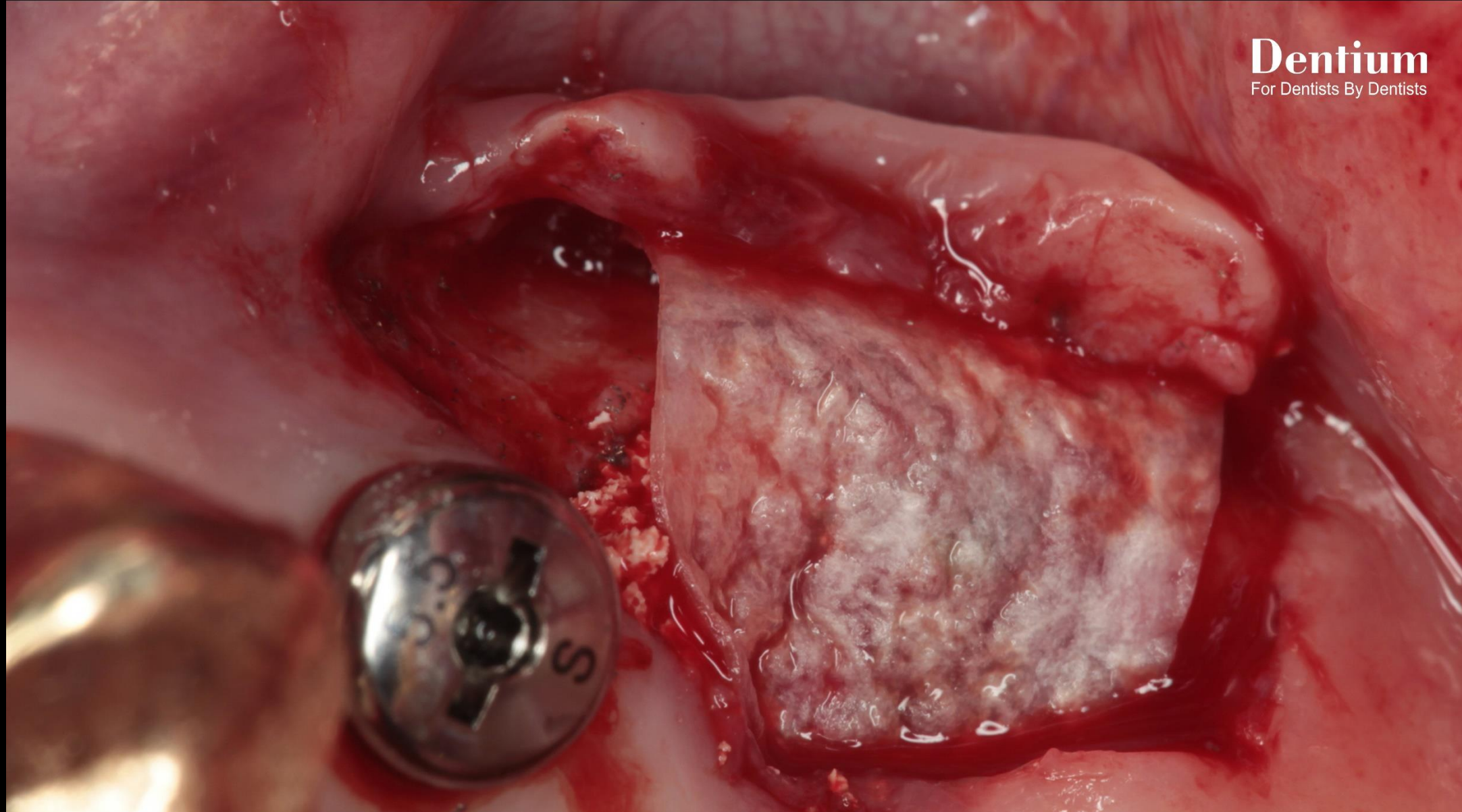
Using extraction Forcep



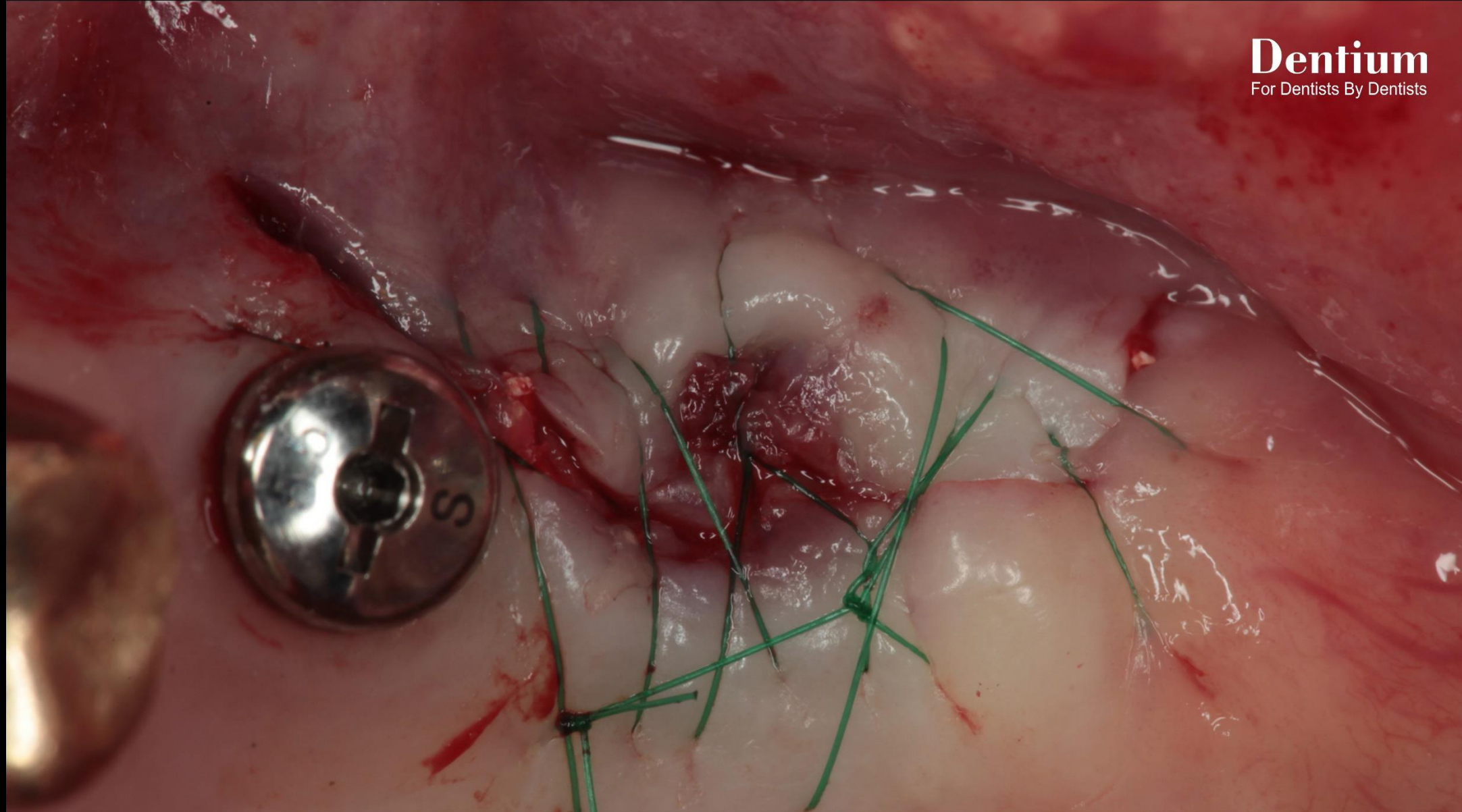
SuperLine 5010



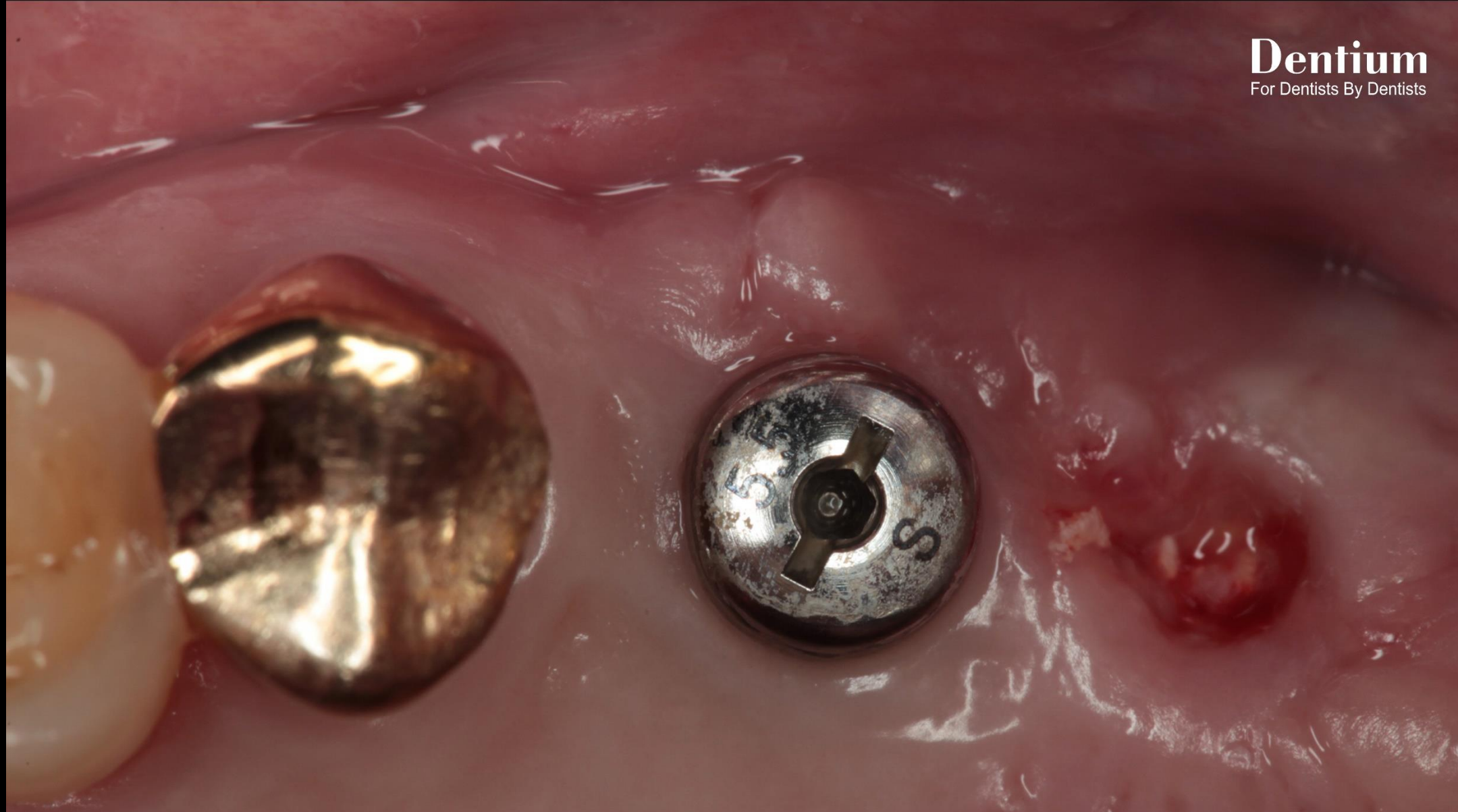
Grafting material : OSTEON™ II



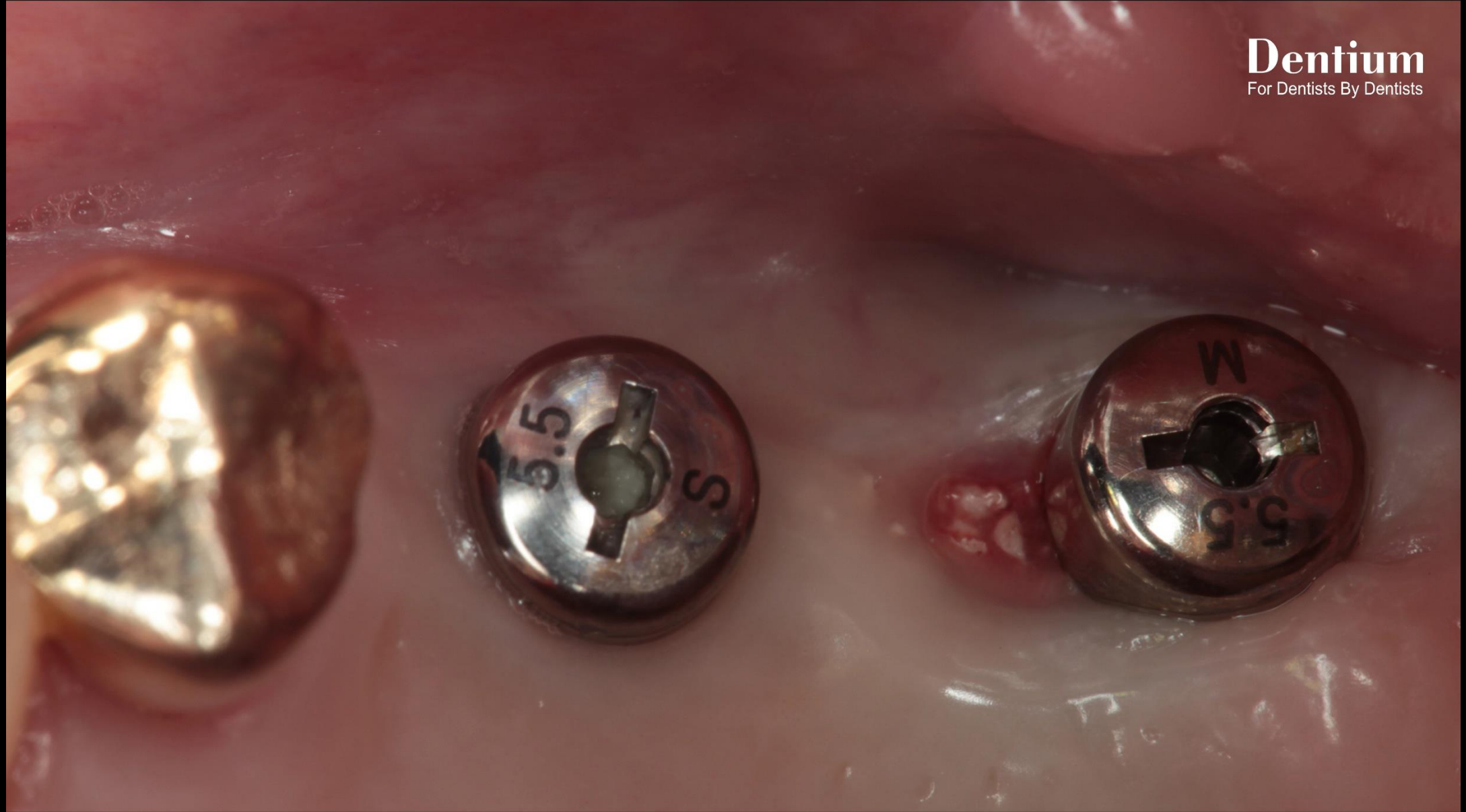
Collagen Membrane application



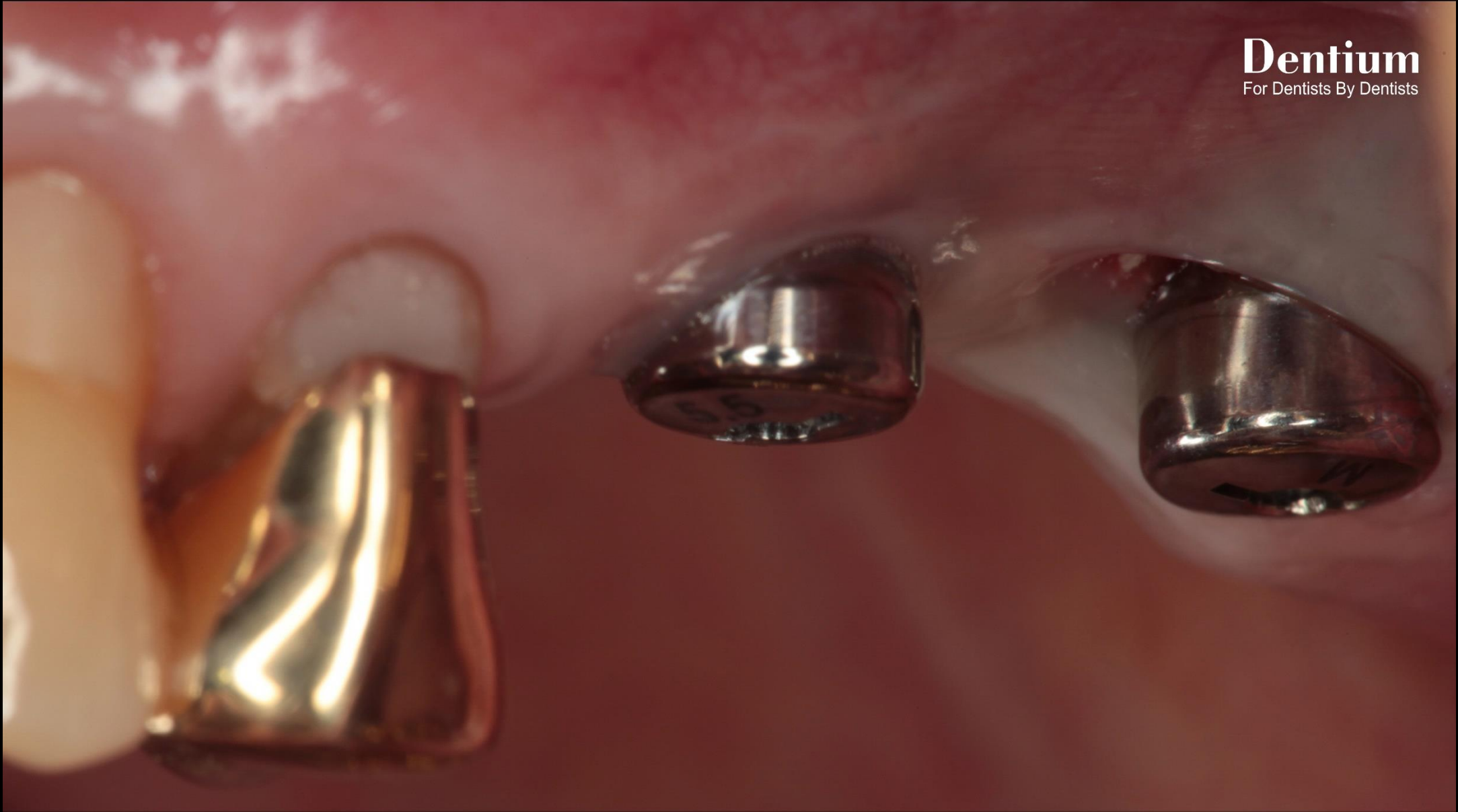
Post-op



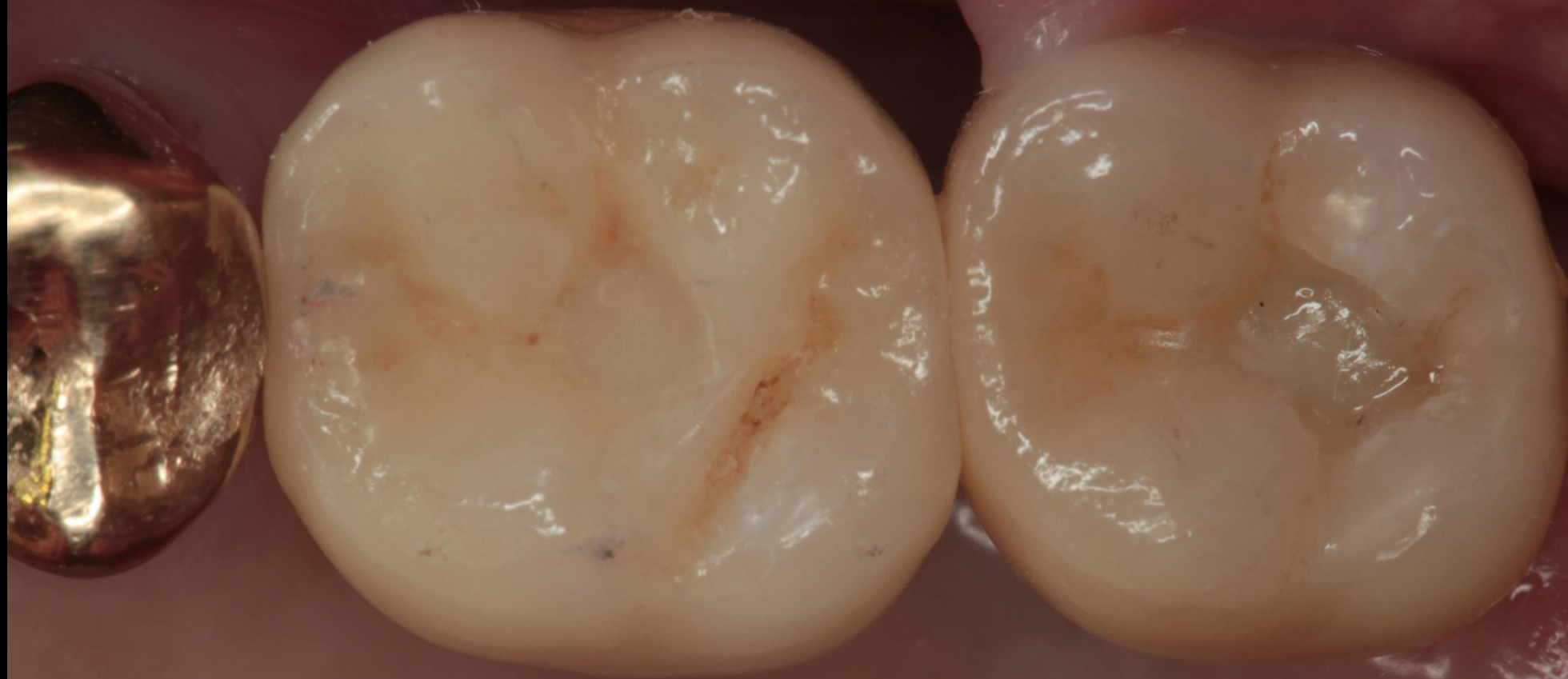Healing : 2 weeks



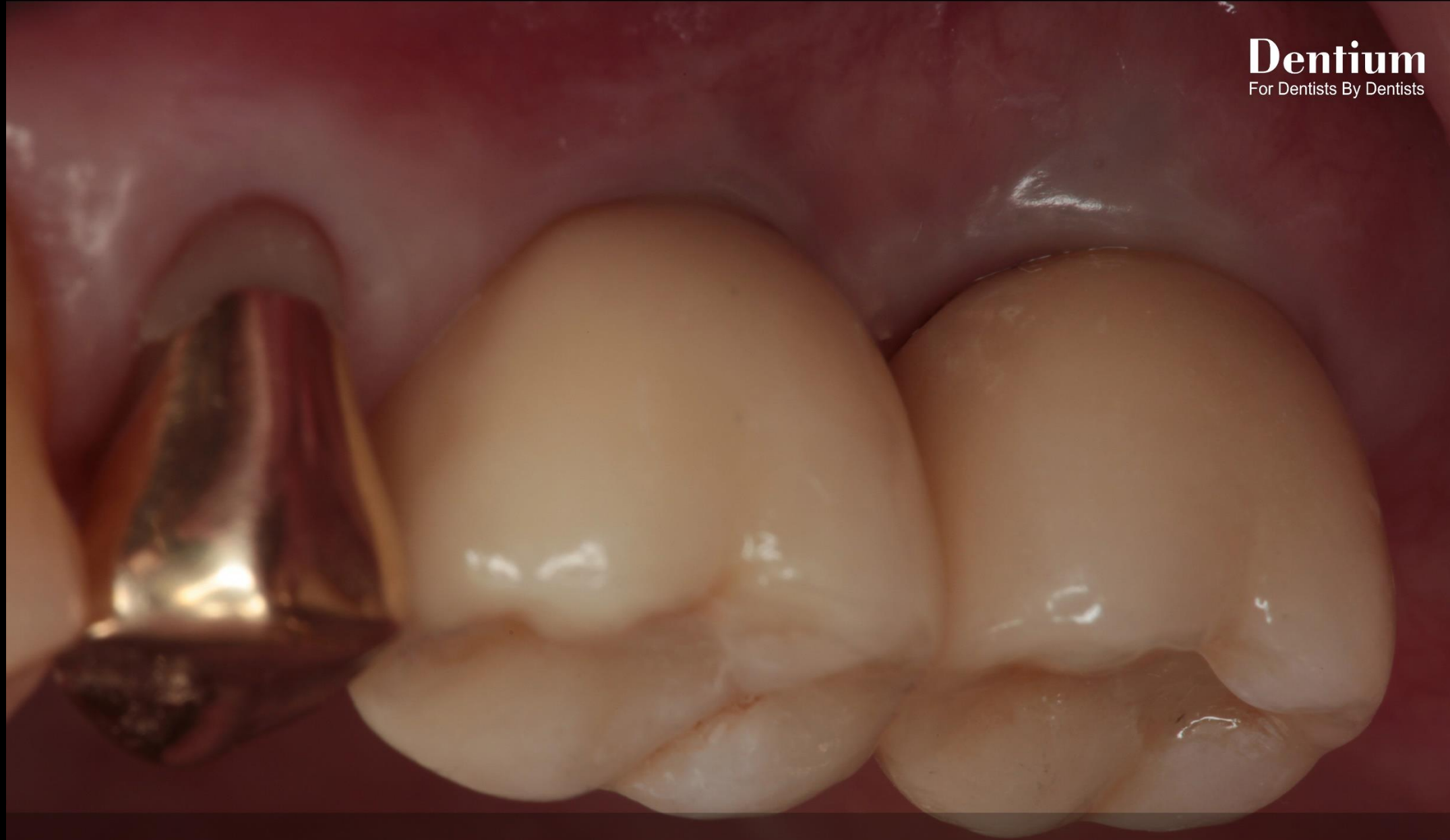Healing : 2 months (Second stage surgery)



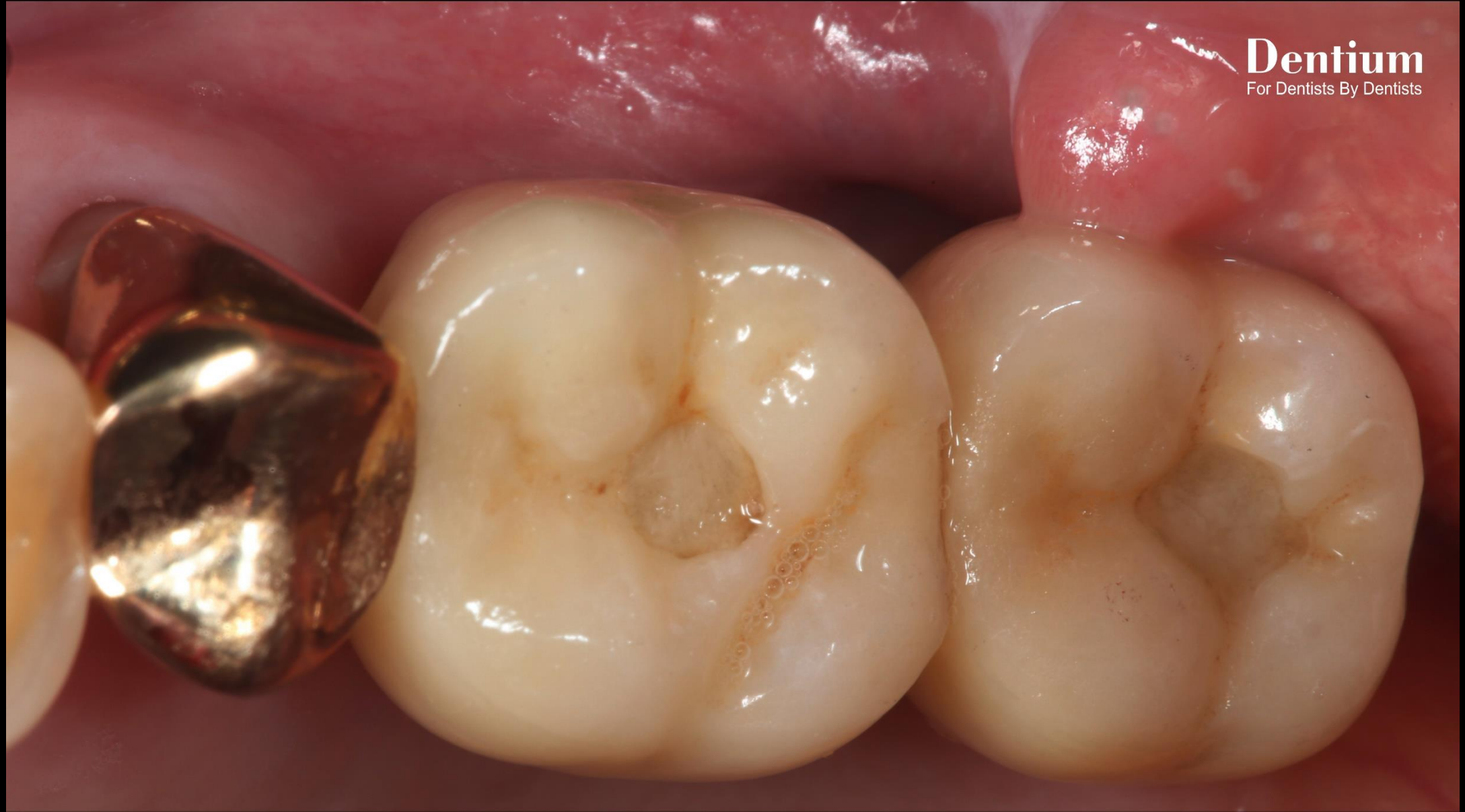Healing : 2 months (Second stage surgery)



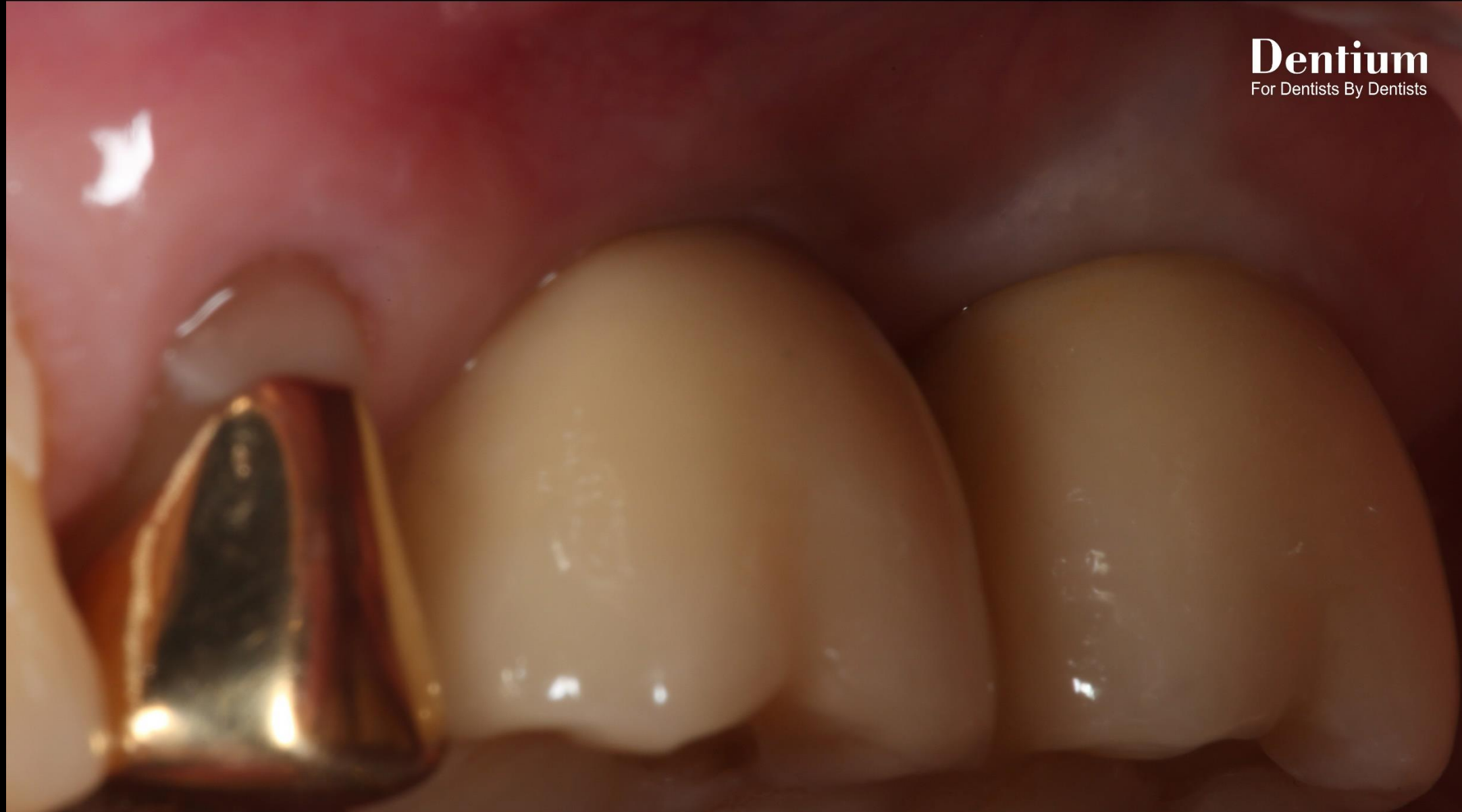Final prosthesis



Final prosthesis



Follow up : 1 year 2 months



Follow up : 1 year 2 months