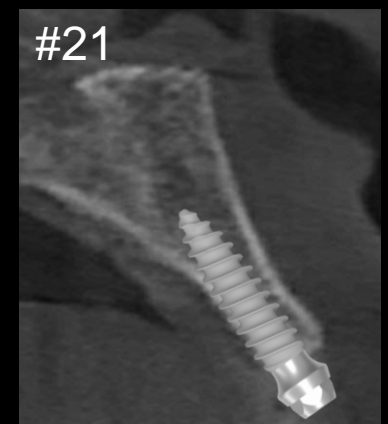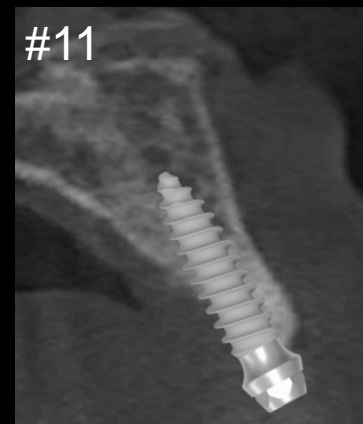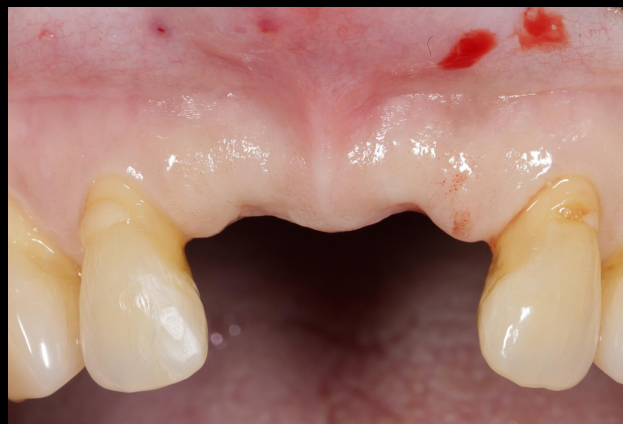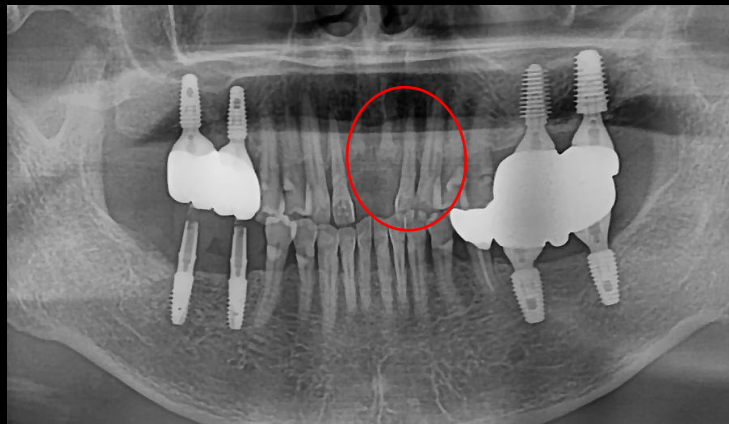


**LIVE** & Follow up

# Narrow ridge Simple Implantation Using Pin guide



Dr. SM Chung

2025.04.04. (Fri)

# Patient Information

**Age** : 64

**Sex** : Female

## Chief Complaint

: I want to get a front tooth implant.

## Past Dental History

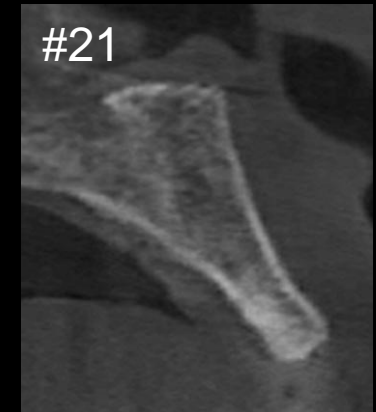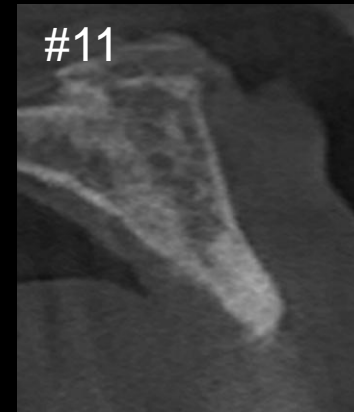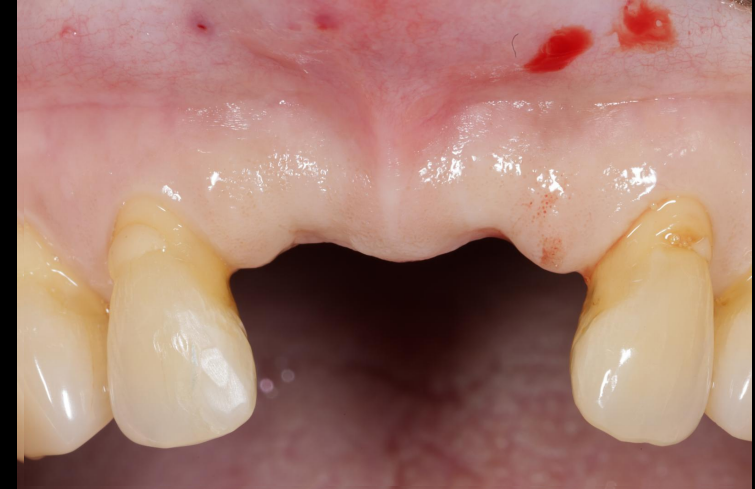: Tooth extraction due to tooth extrusion 1 year 3 months ago.

Bone grafting was performed when extracting these tooth

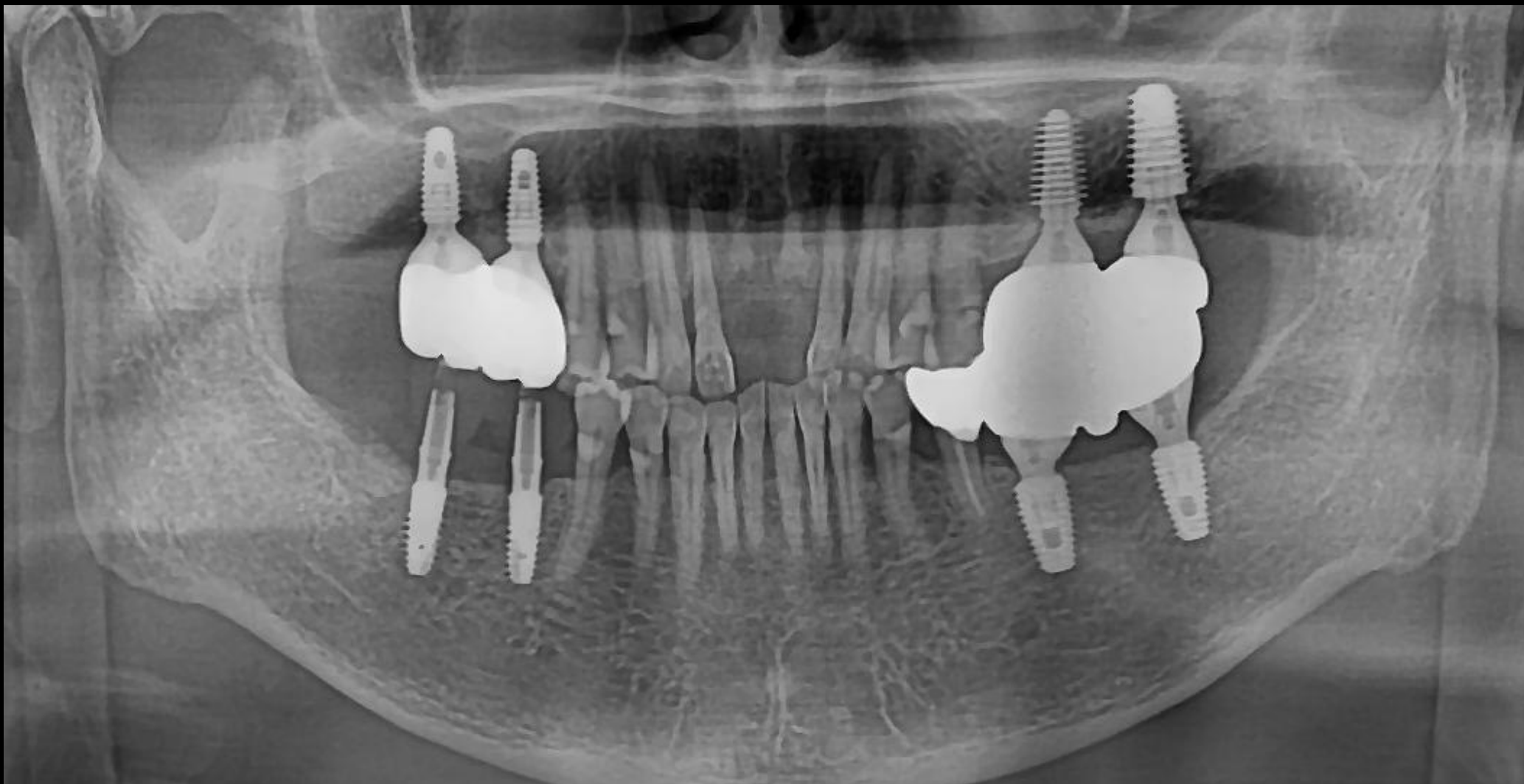
## Past Medical History

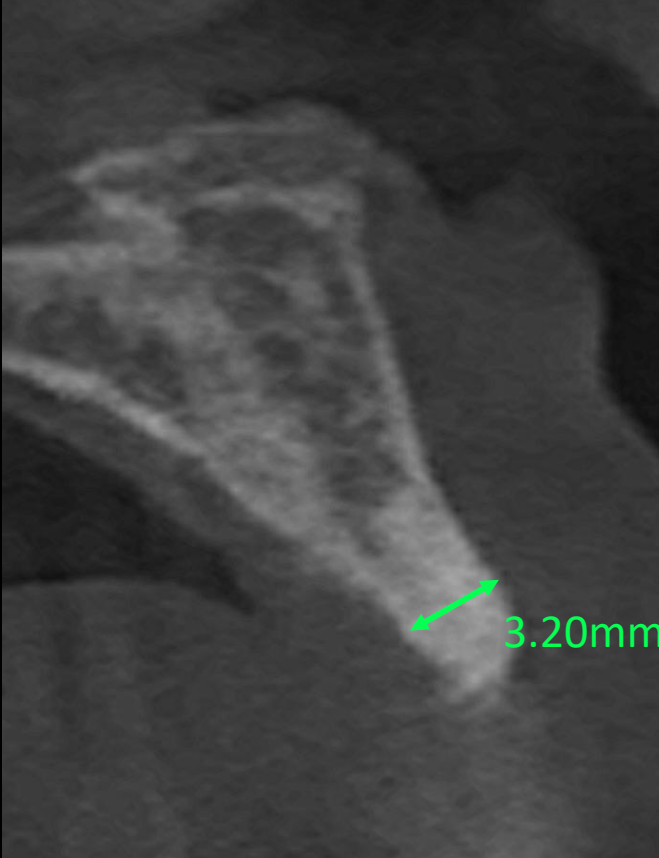
: breast cancer, stage 2/3

(undergoing anticancer treatment)

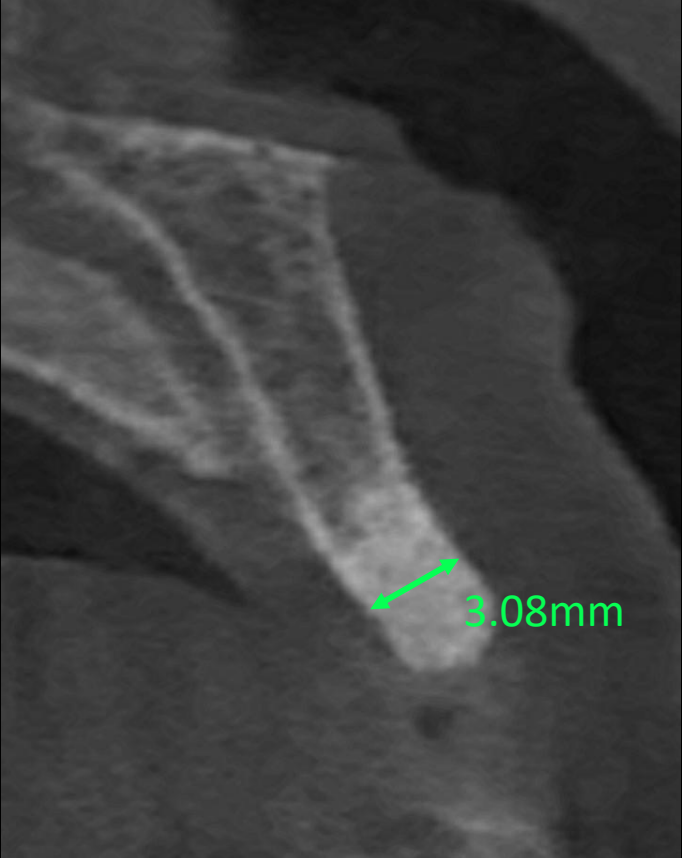


Pre-op



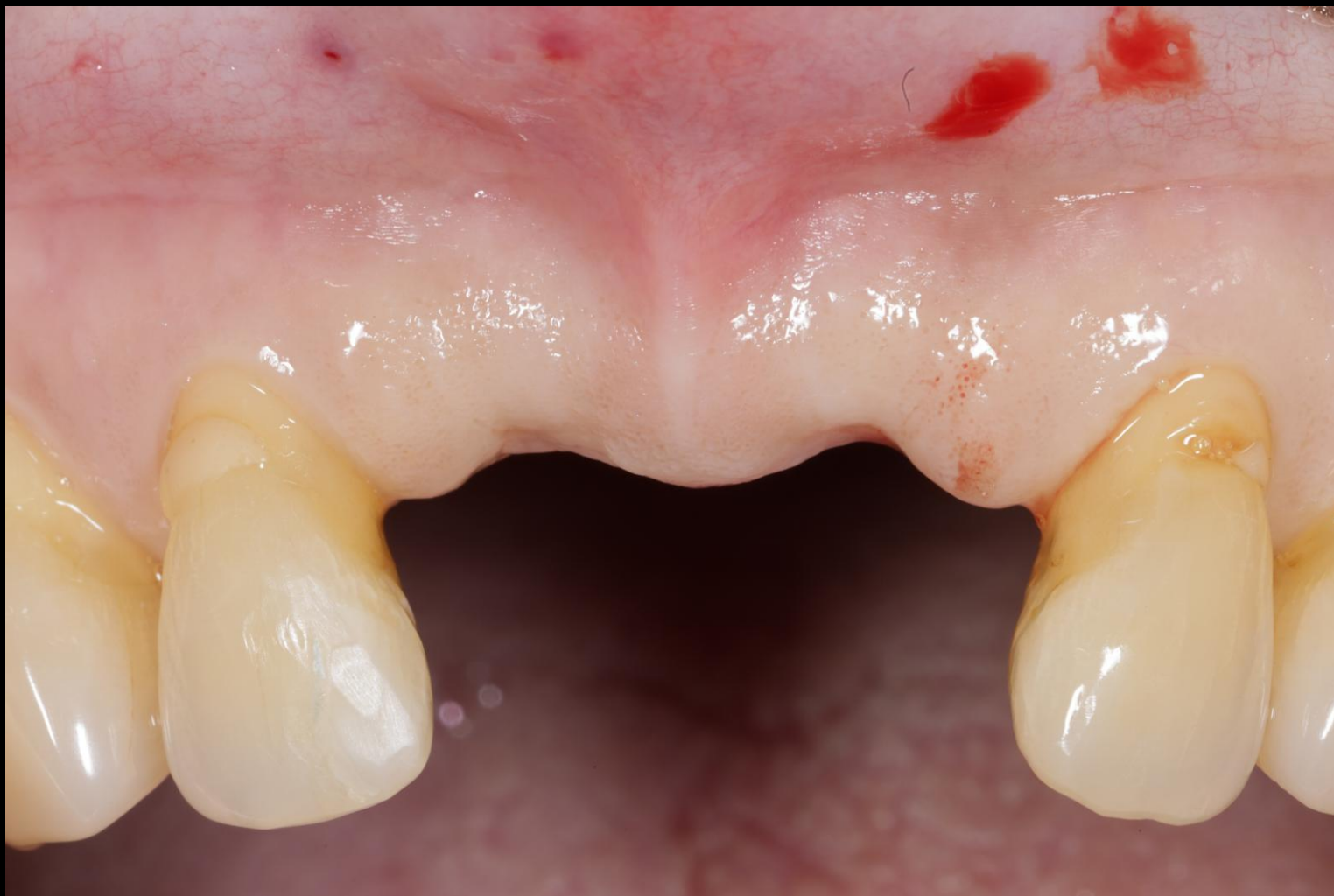

#11



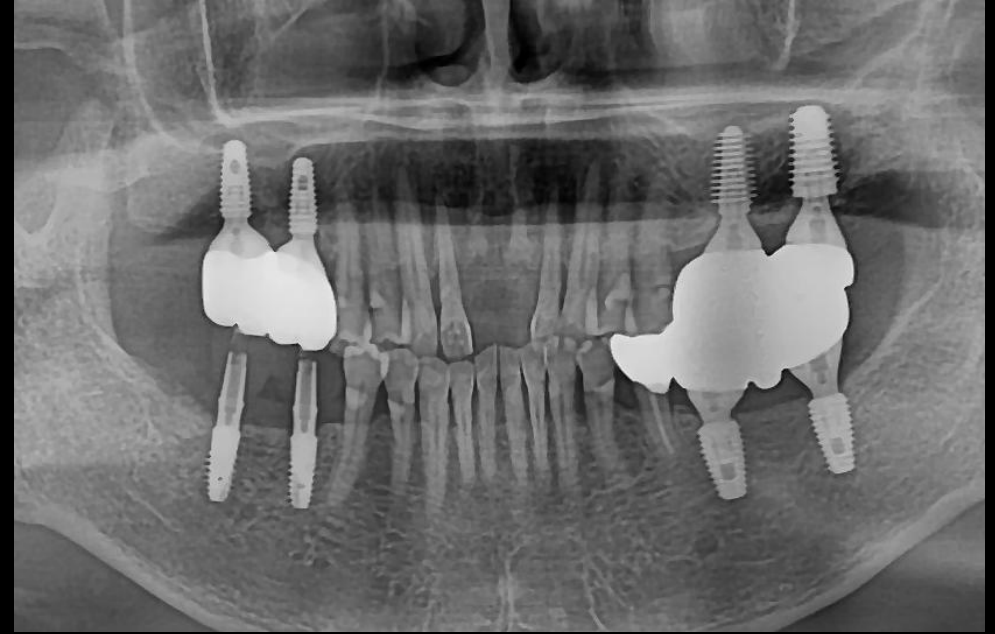
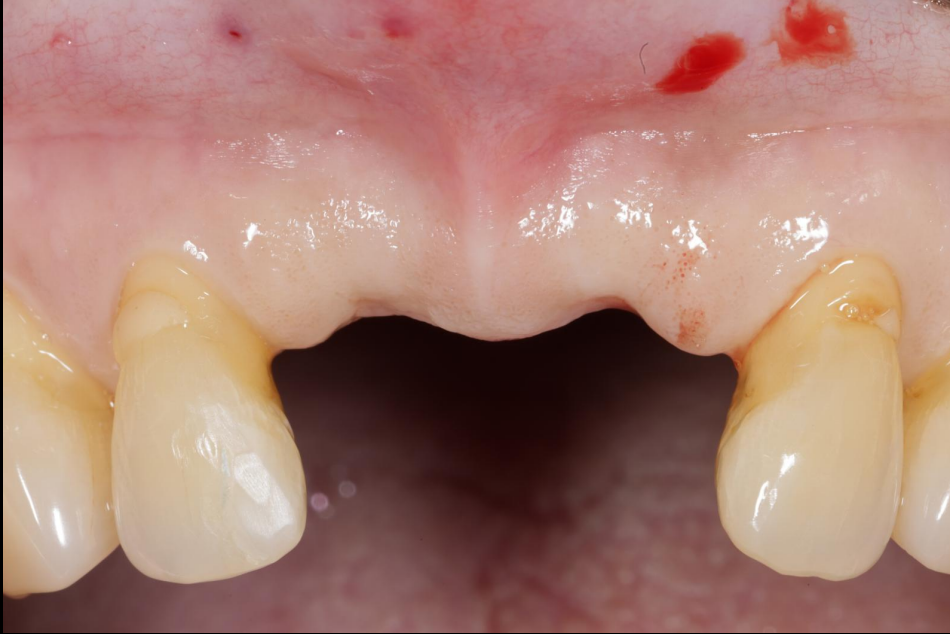#21

Pre-op





## Surgery Plan (#11,21)



- Implantation on #11, 21 using **bright Tissue Level 3.0**
- Flapless implantation with **Pin Guide**

# bright Implant **Tissue Level**

✓ **Narrow, Yet Strong**

- Excellent Joint Stability

✓ **20° External Tapered & External Hex**

- Excellent Joint Stability

- Multi Purpose and Easy-to-Use  
Connection on Trans-Mucosa

✓ **Concaved Neck**

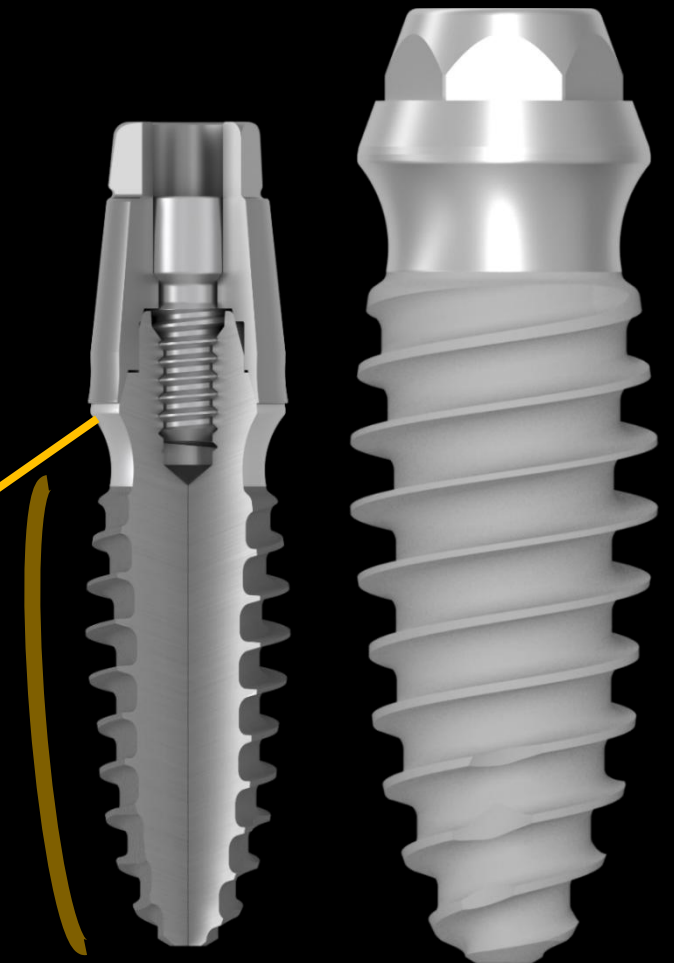
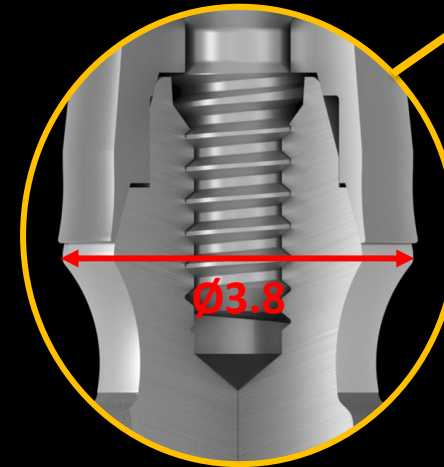
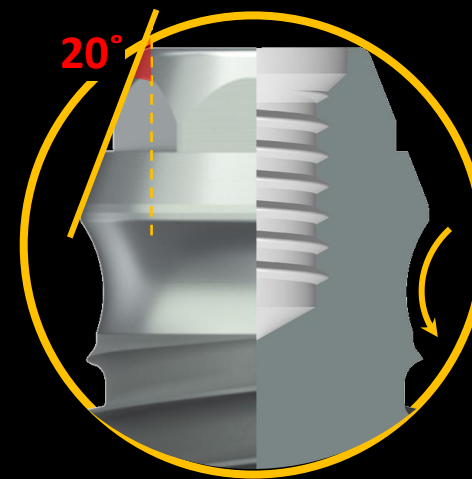
- Better Contour Management for Soft Tissue

✓ **Dome Shaped Body**

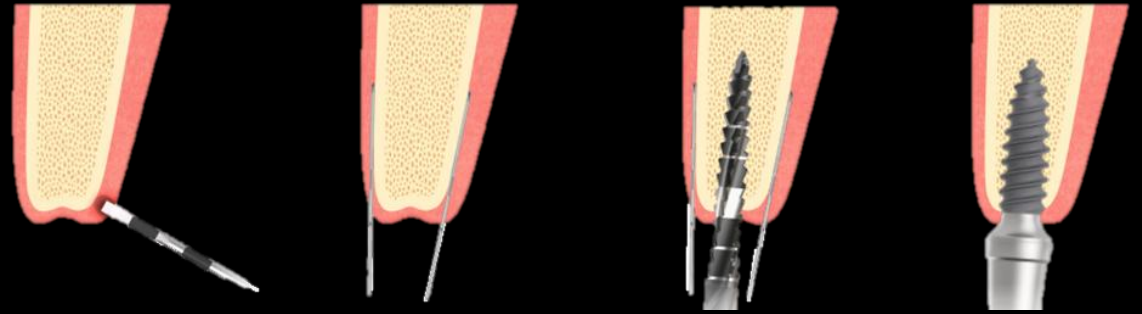
- Better Primary Stability  
- Better BIC on Cancellous Bone  
- Marginal Bone Preservation

✓ **Ø3.8 Single Platform**

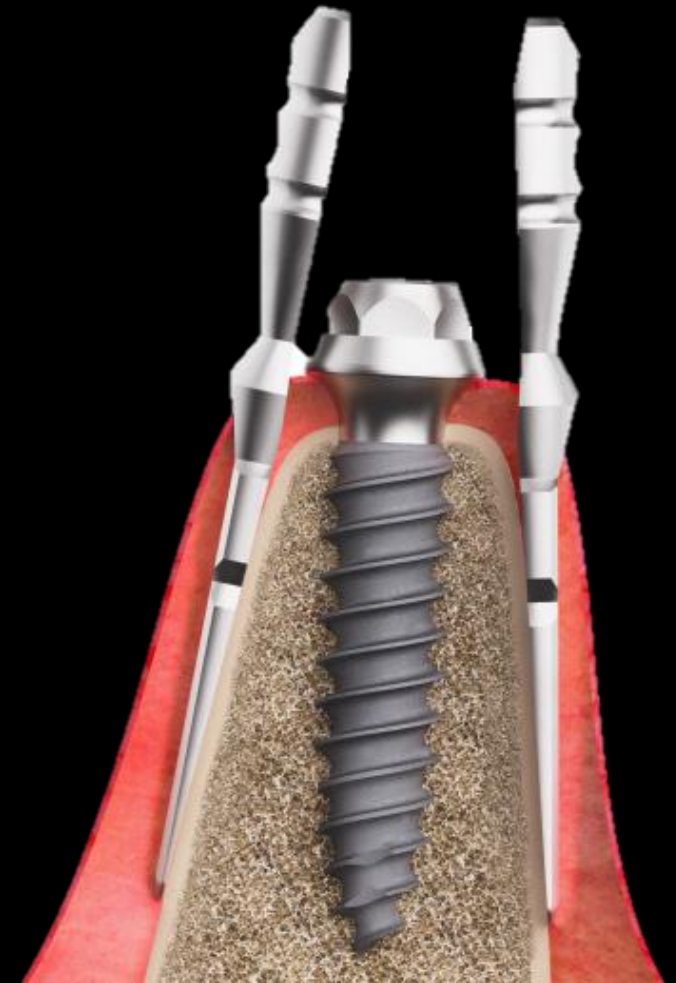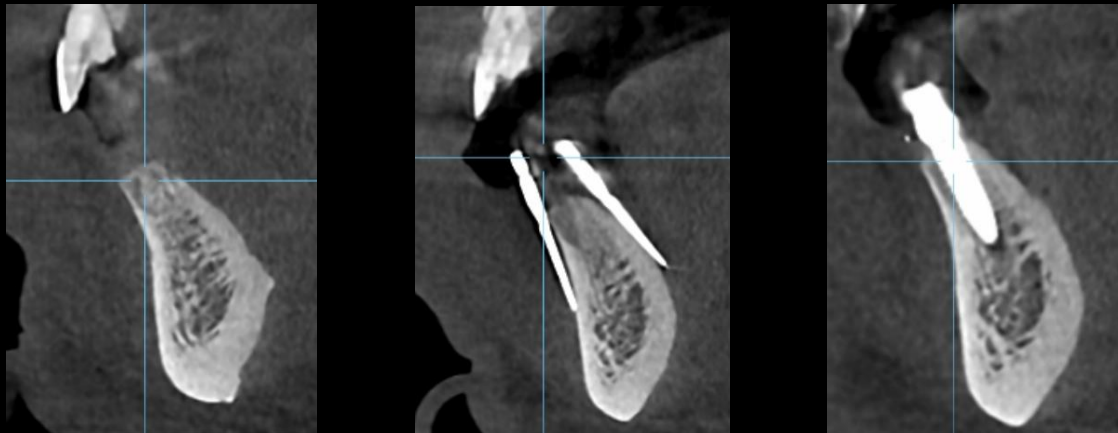
- One Connection / One Prosthetic Line



# Pin Guide

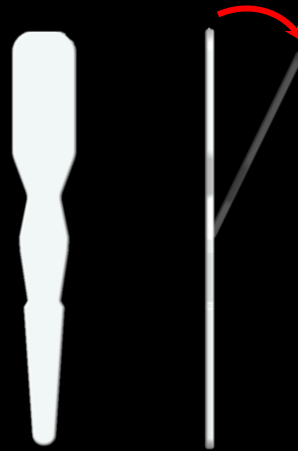
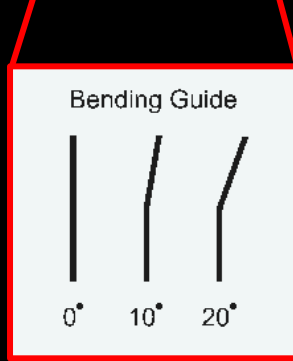
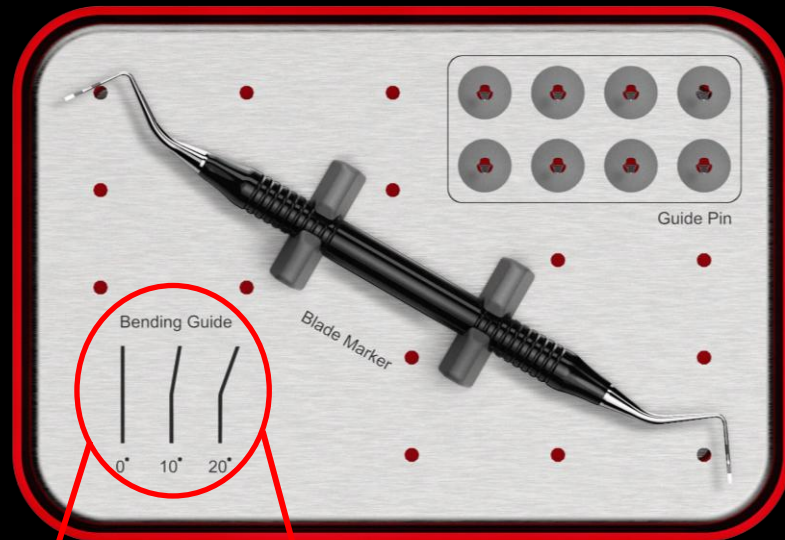


- ✓ Mapping alveolar bone
- ✓ Optimized for flapless surgery
- ✓ Excellent performance in narrow ridge case

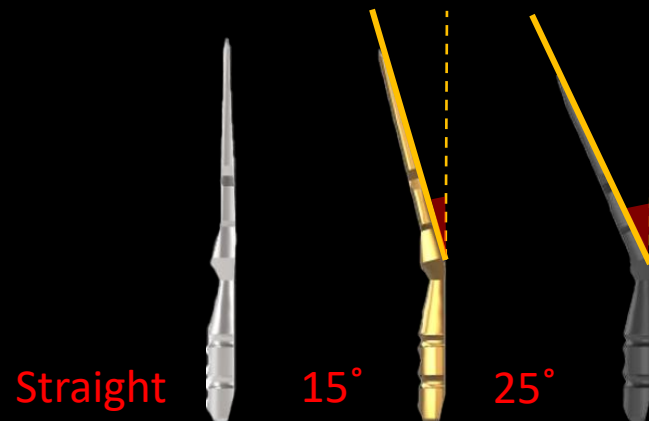





# Pin Guide *Simple*

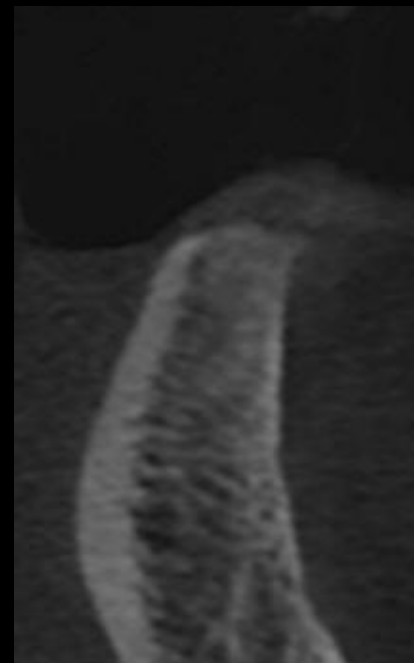
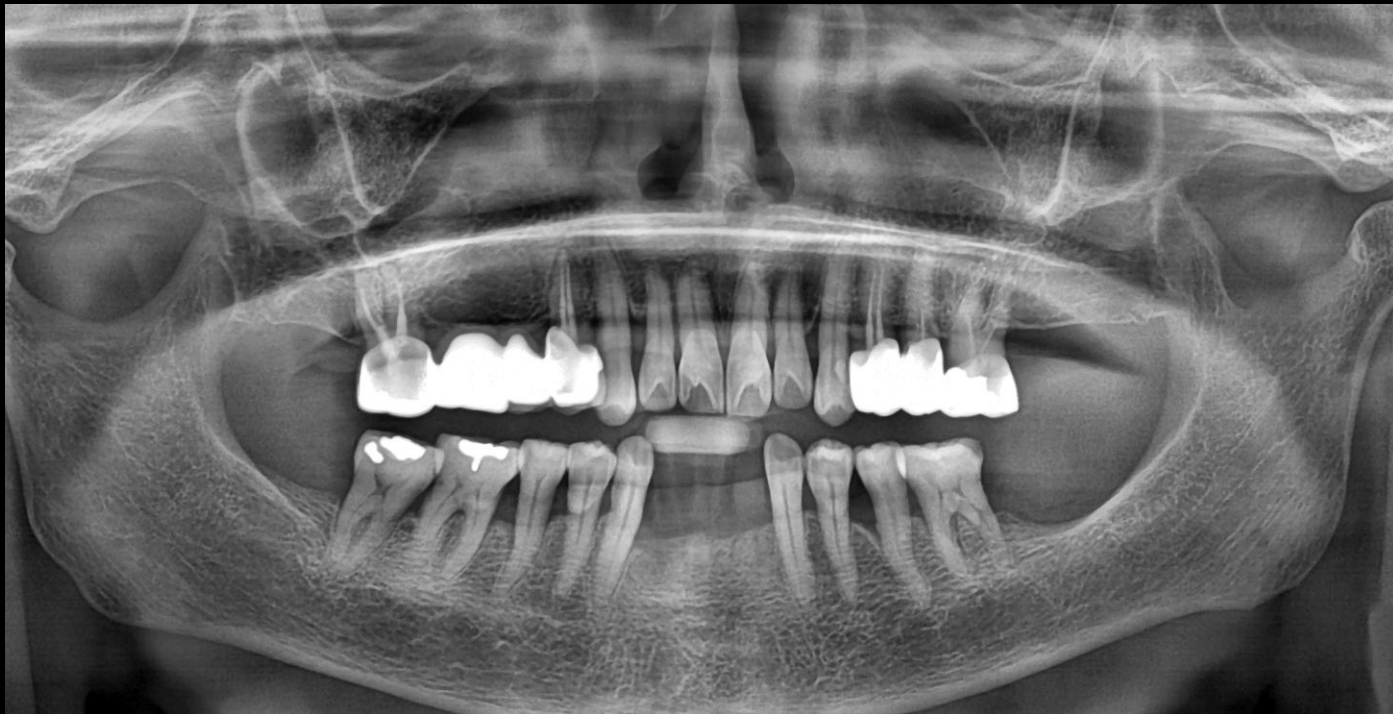

# Pin Guide *Full*

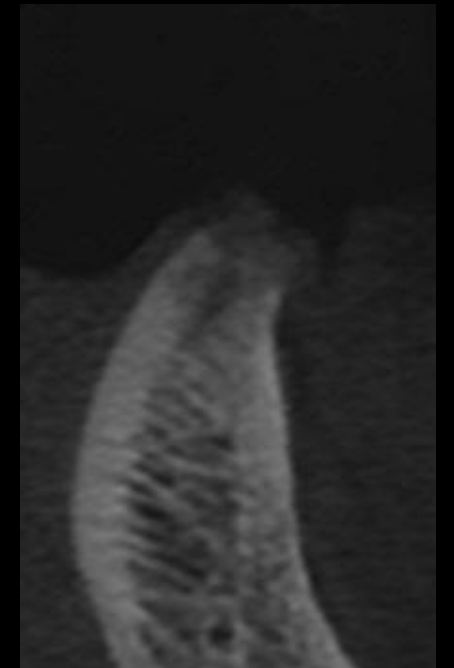

**Similar case 1**

**Simple implant placement with Pin guide**



**#32**

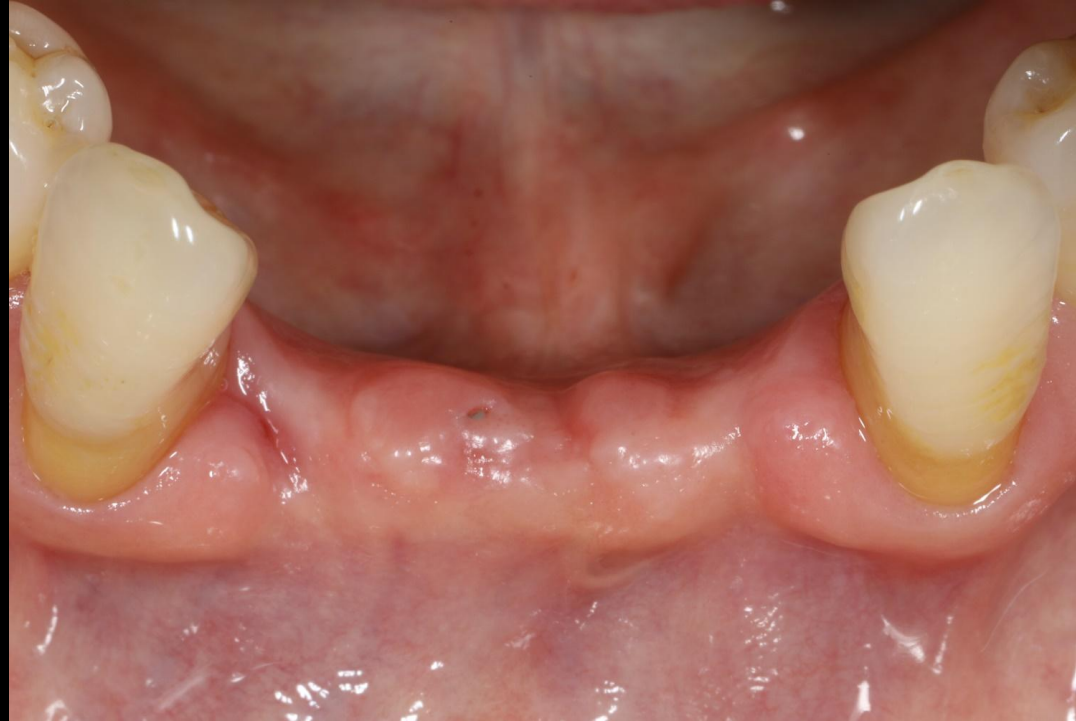

**#42**

Pre-op

**Similar case 1**

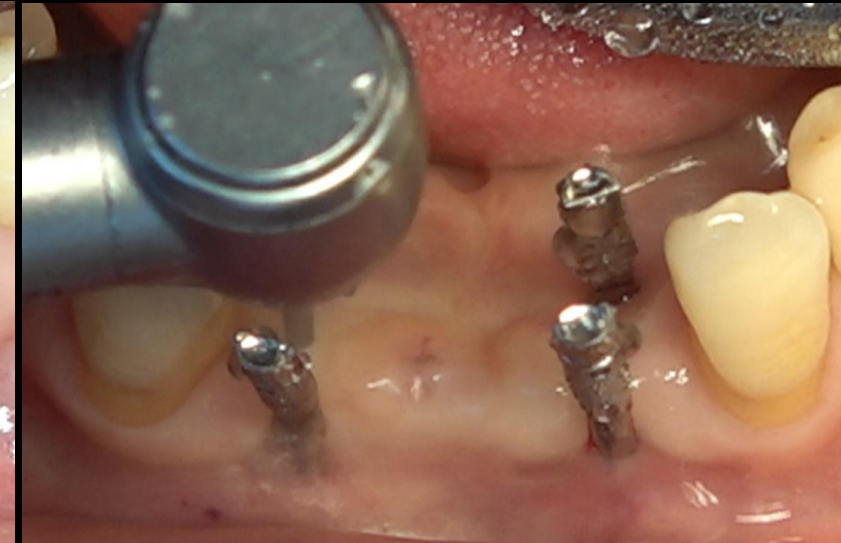
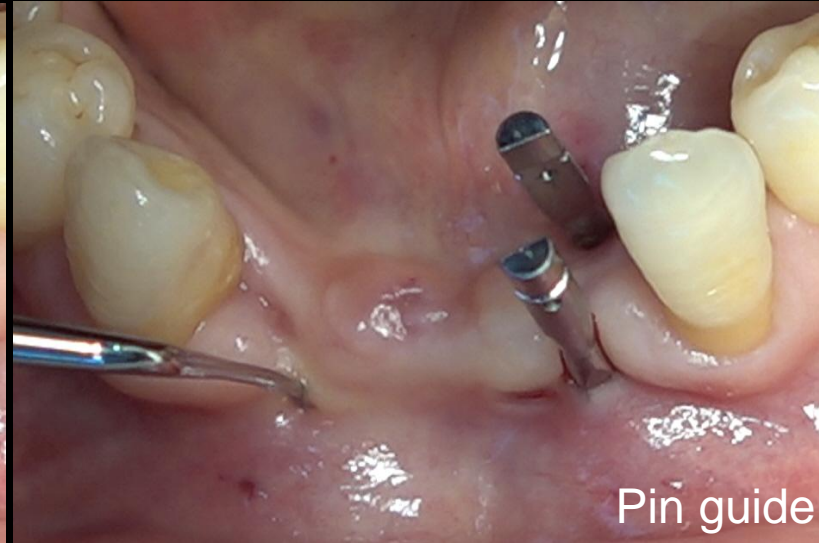
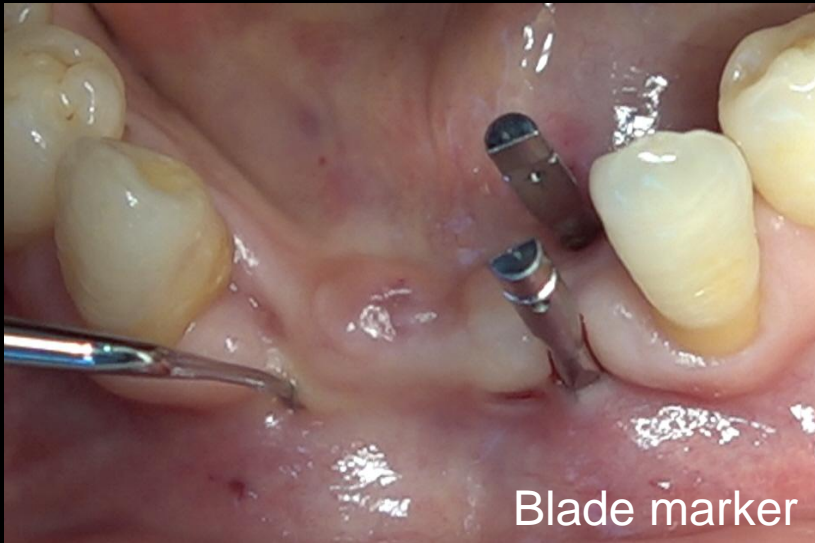
**Simple implant placement with Pin guide**



Pre-op

## Similar case 1

## Simple implant placement with Pin guide

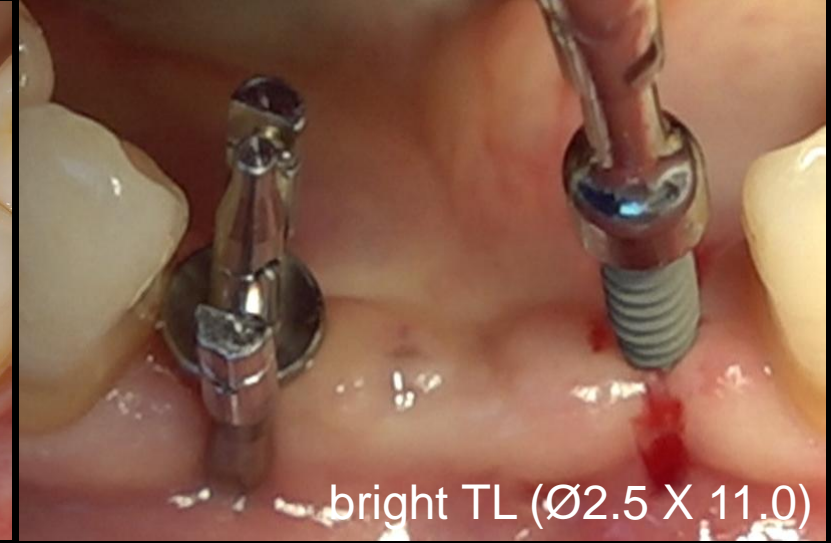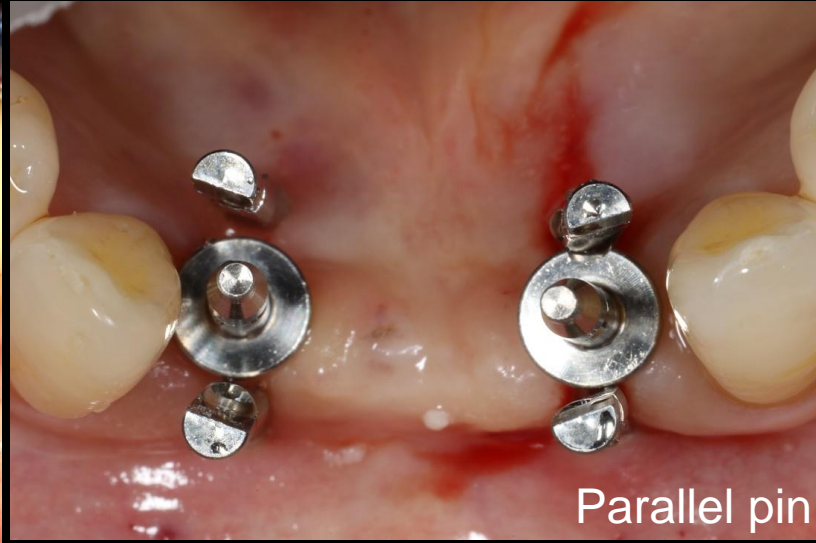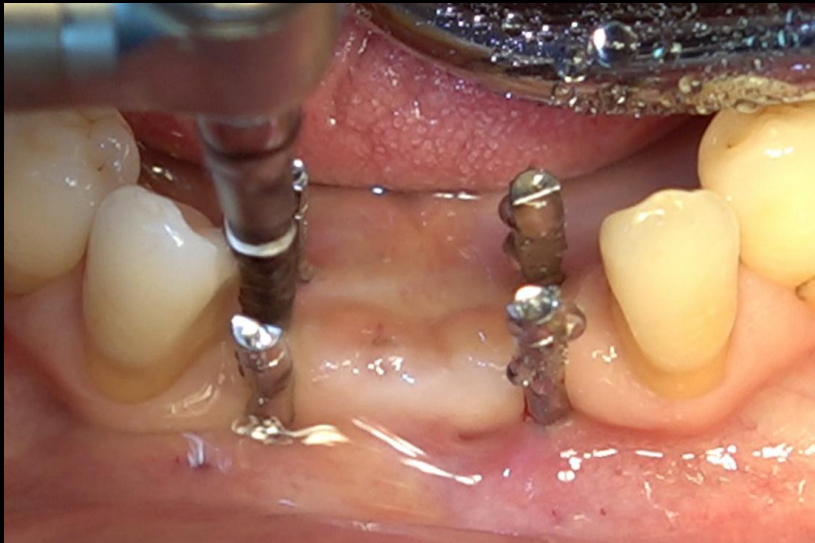


Surgery



## Similar case 1

## Simple implant placement with Pin guide

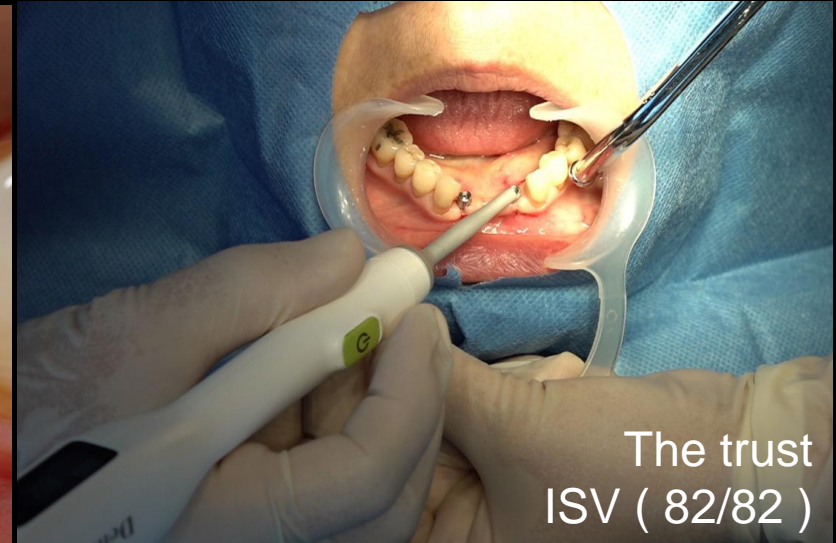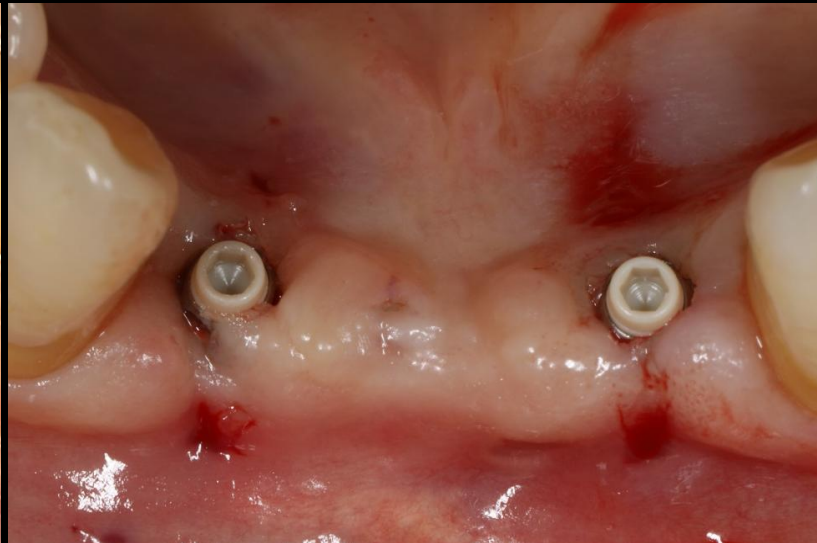

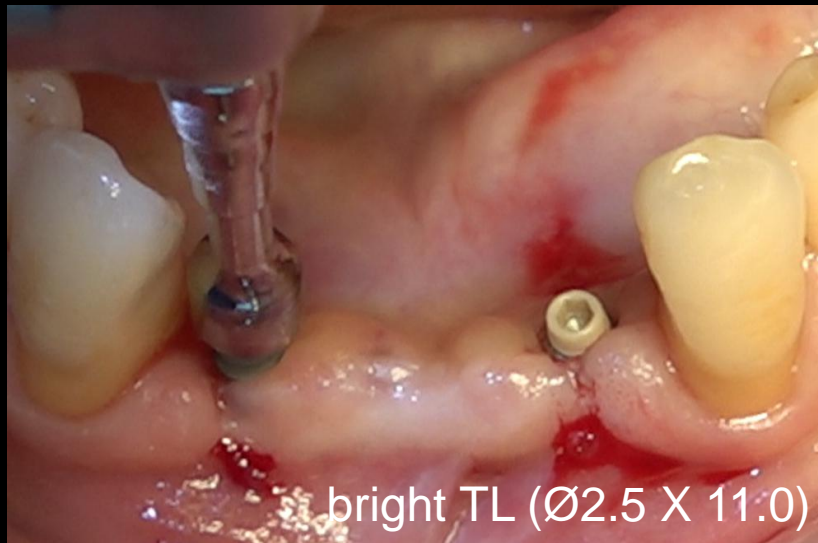
Surgery



## Similar case 1

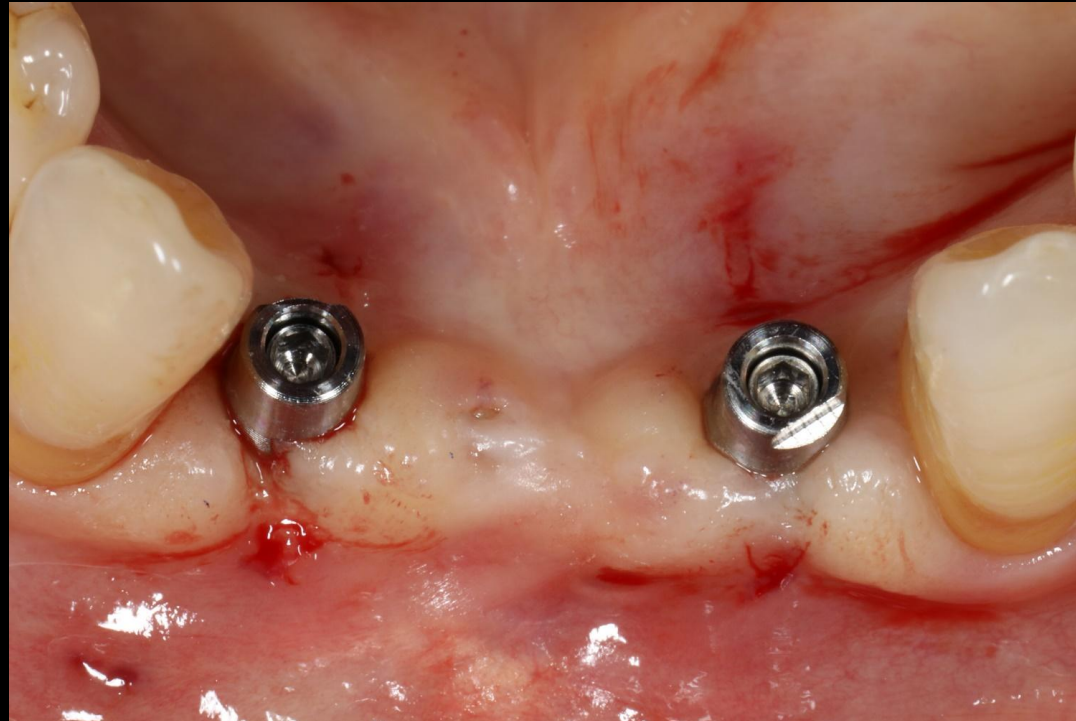
## Simple implant placement with Pin guide



Surgery

**Similar case 1**

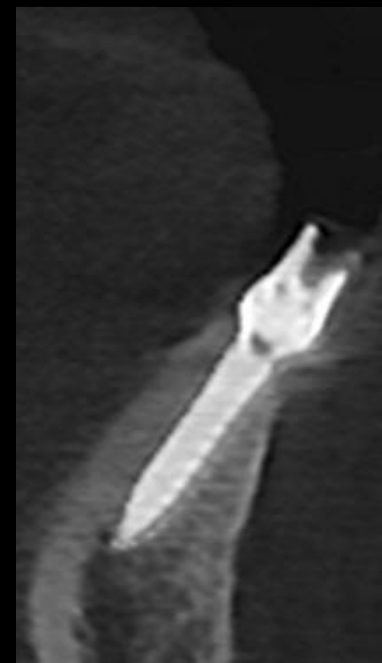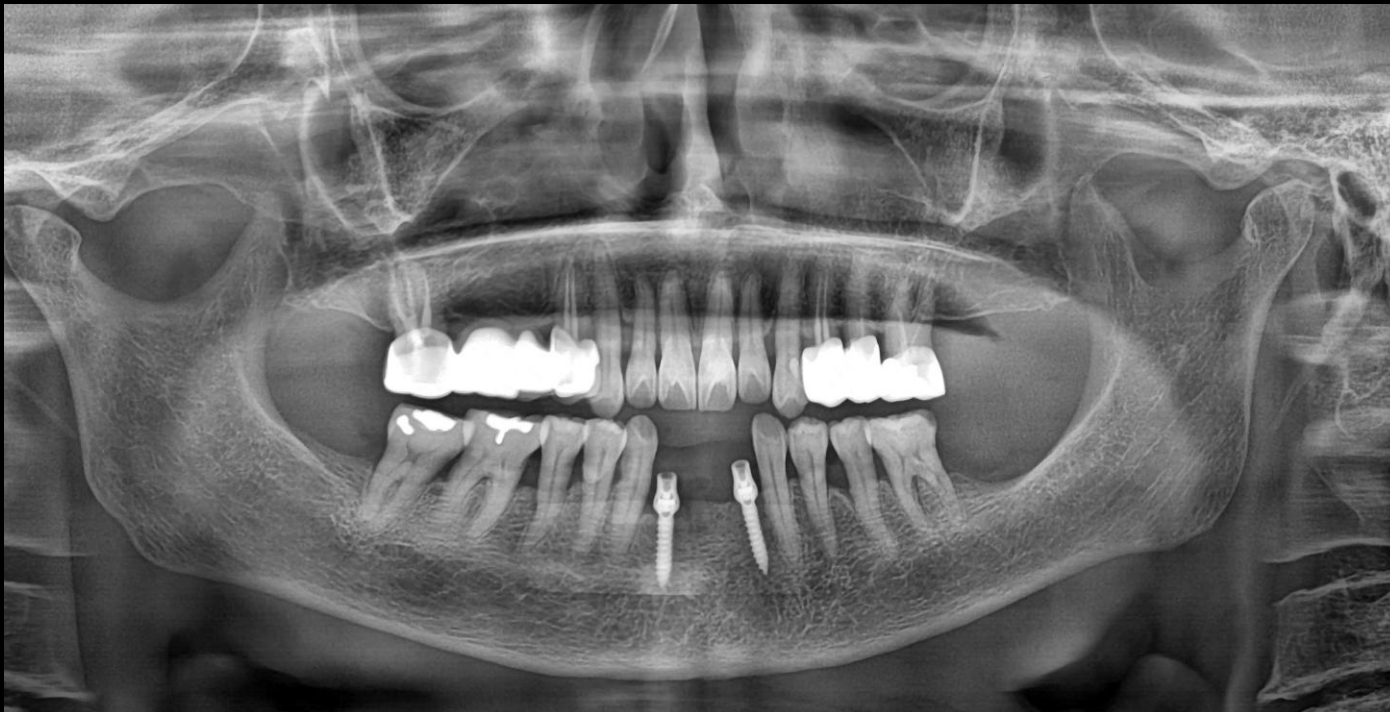**Simple implant placement with Pin guide**



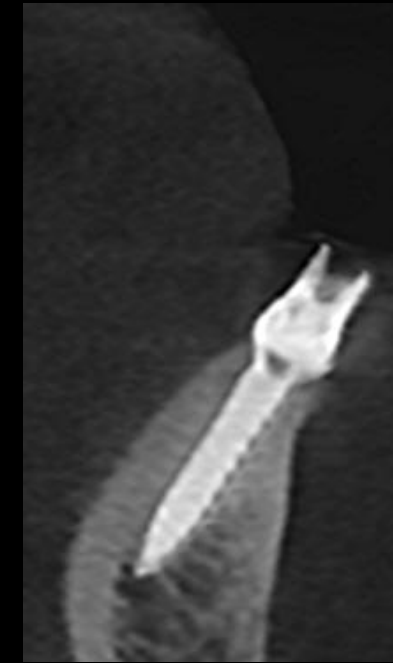Post-op

## Similar case 1

## Simple implant placement with Pin guide



#32

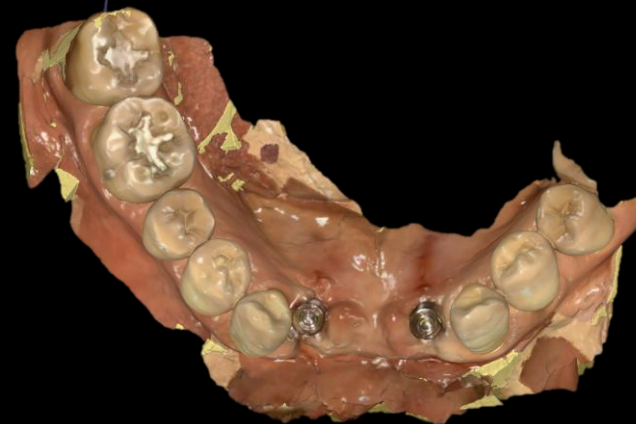
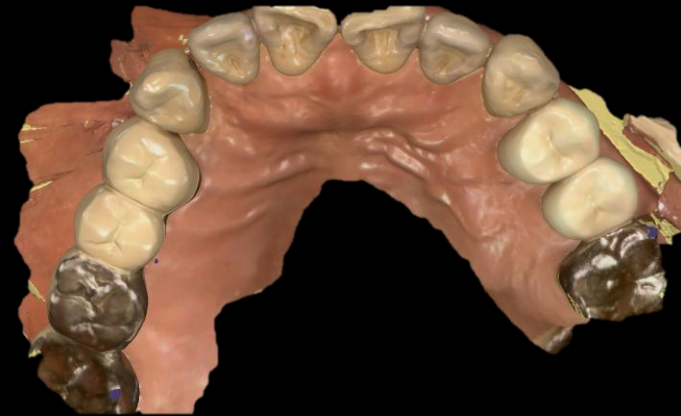
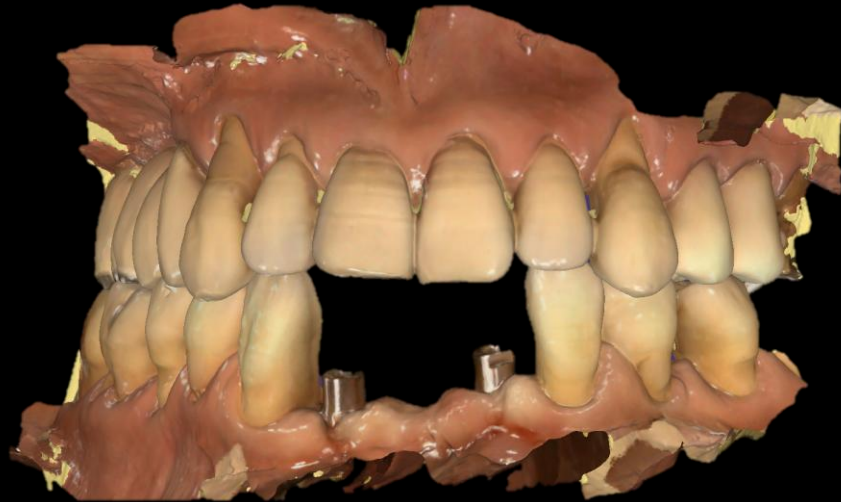#42

Post-op

## Similar case 1

## Simple implant placement with Pin guide

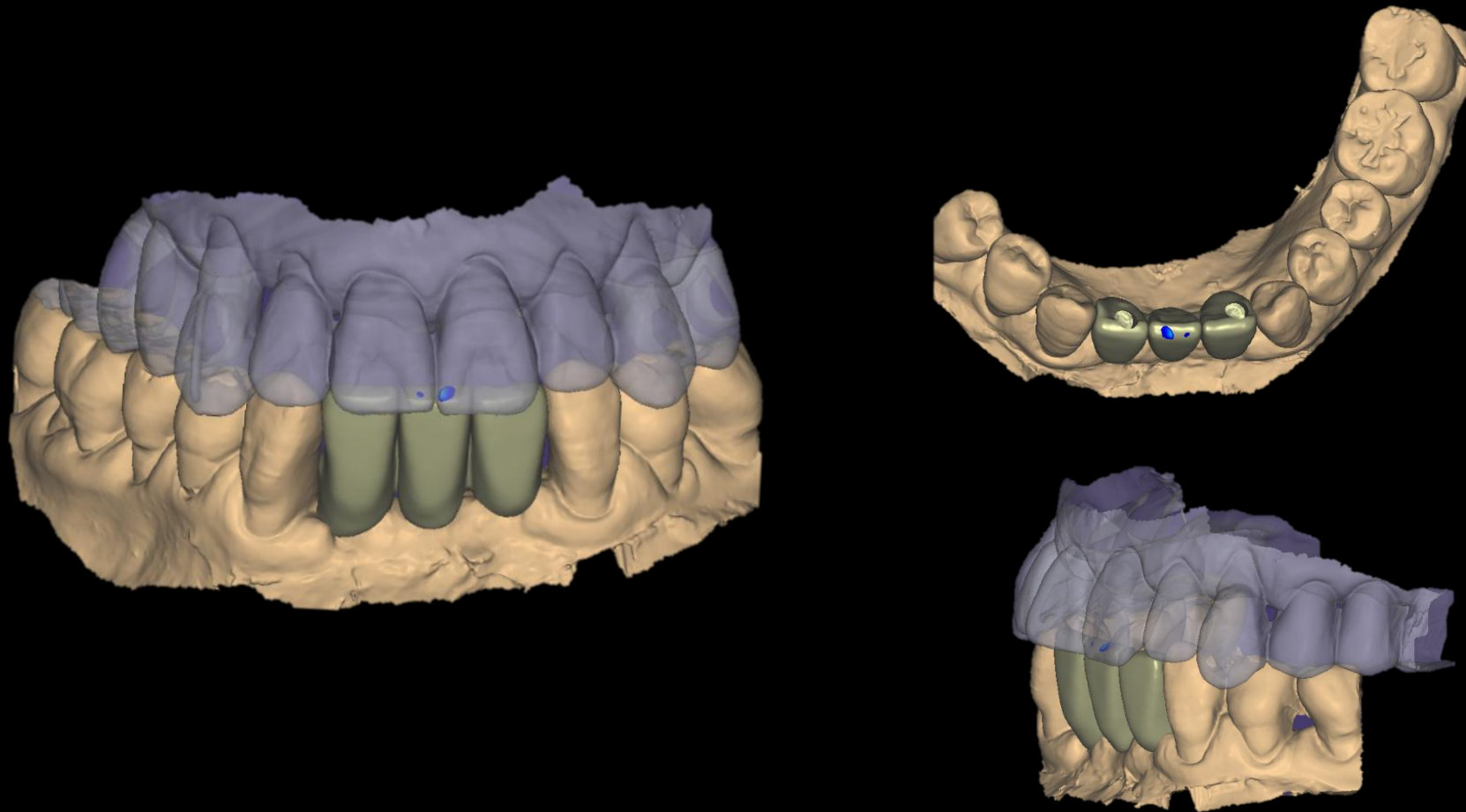


IOS



## Similar case 1

## Simple implant placement with Pin guide

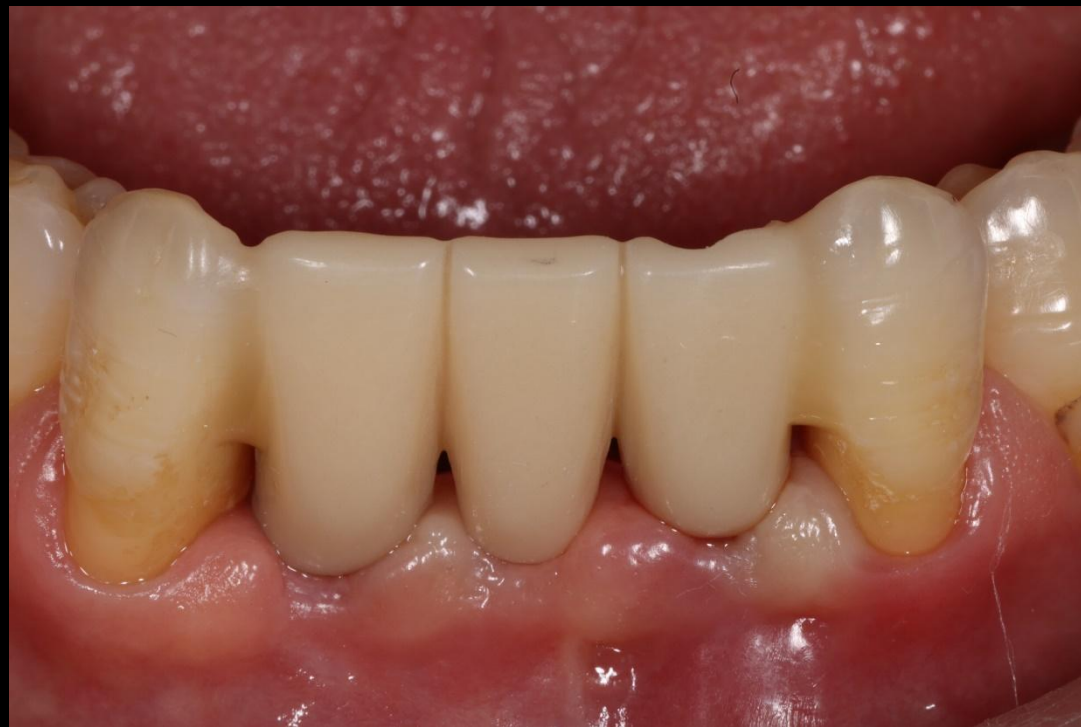
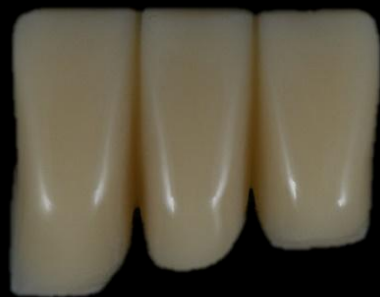
CAD (Temporary)



## Similar case 1

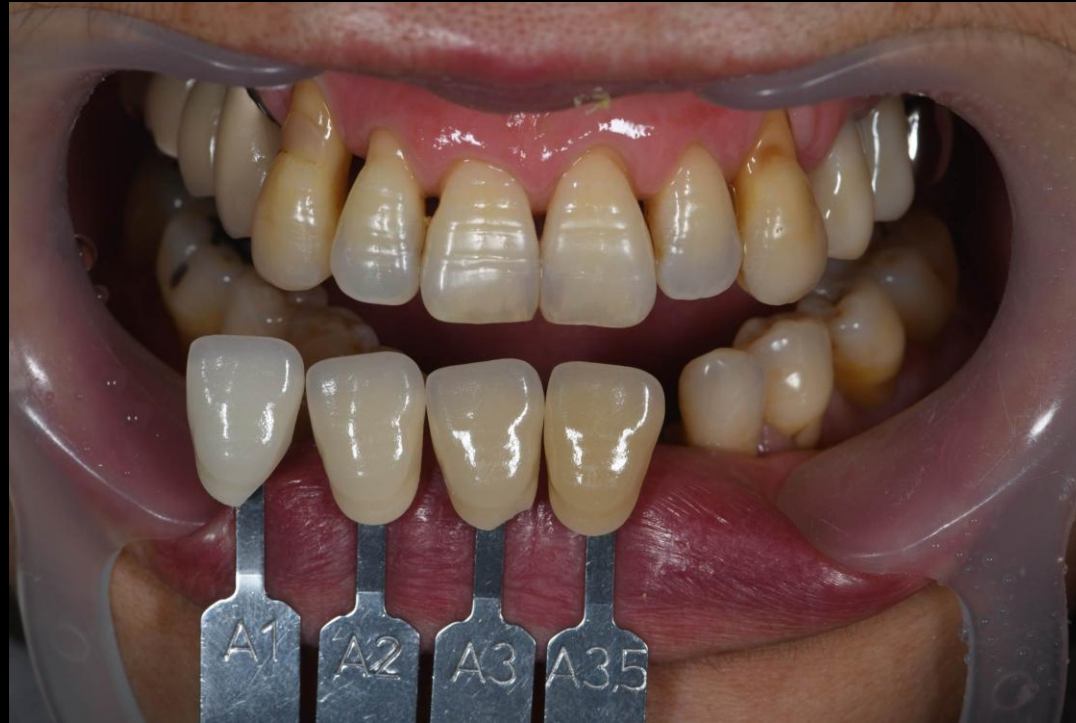## Simple implant placement with Pin guide



Provisional restoration

## Similar case 1

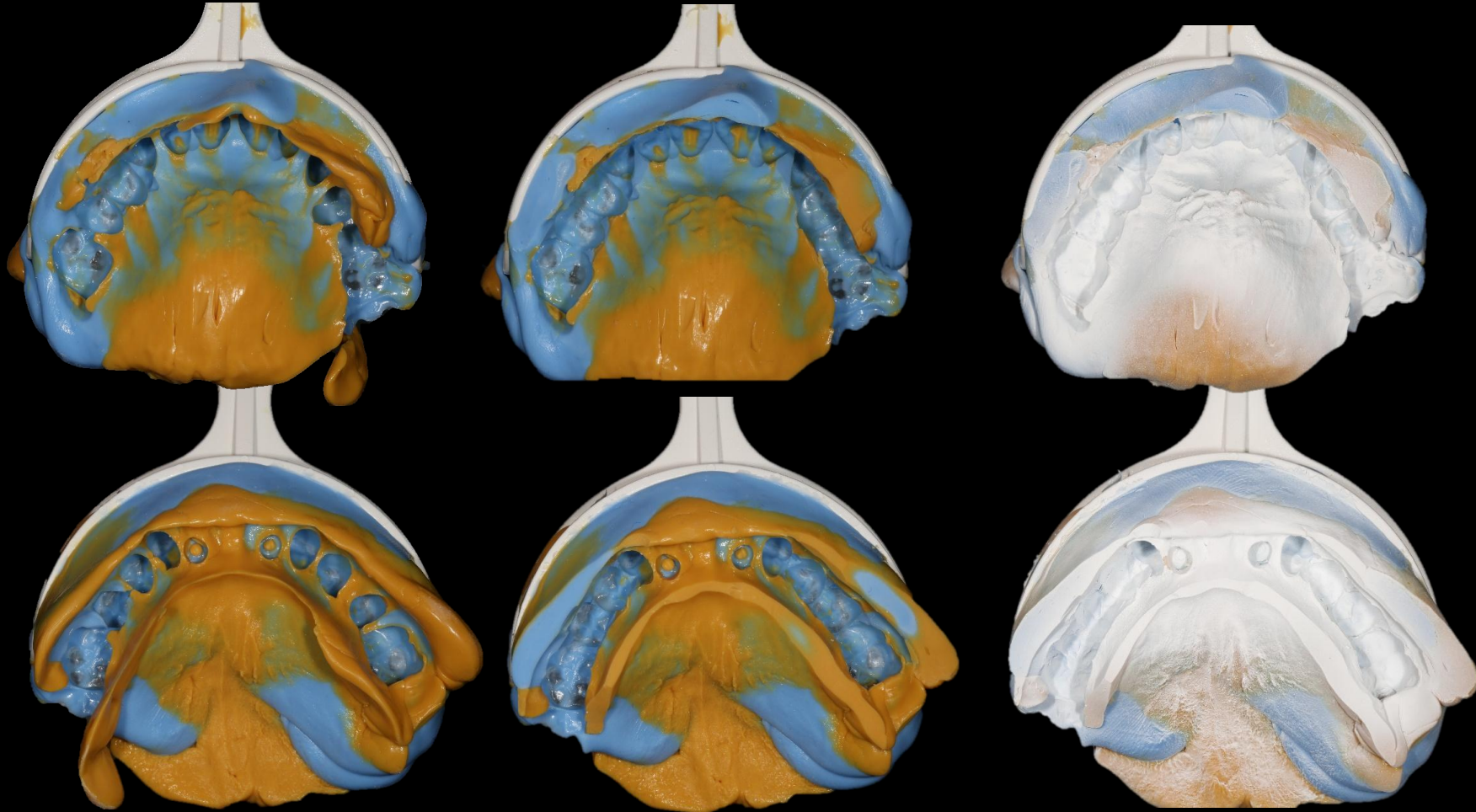
## Simple implant placement with Pin guide



Shade taking

**Similar case 1**

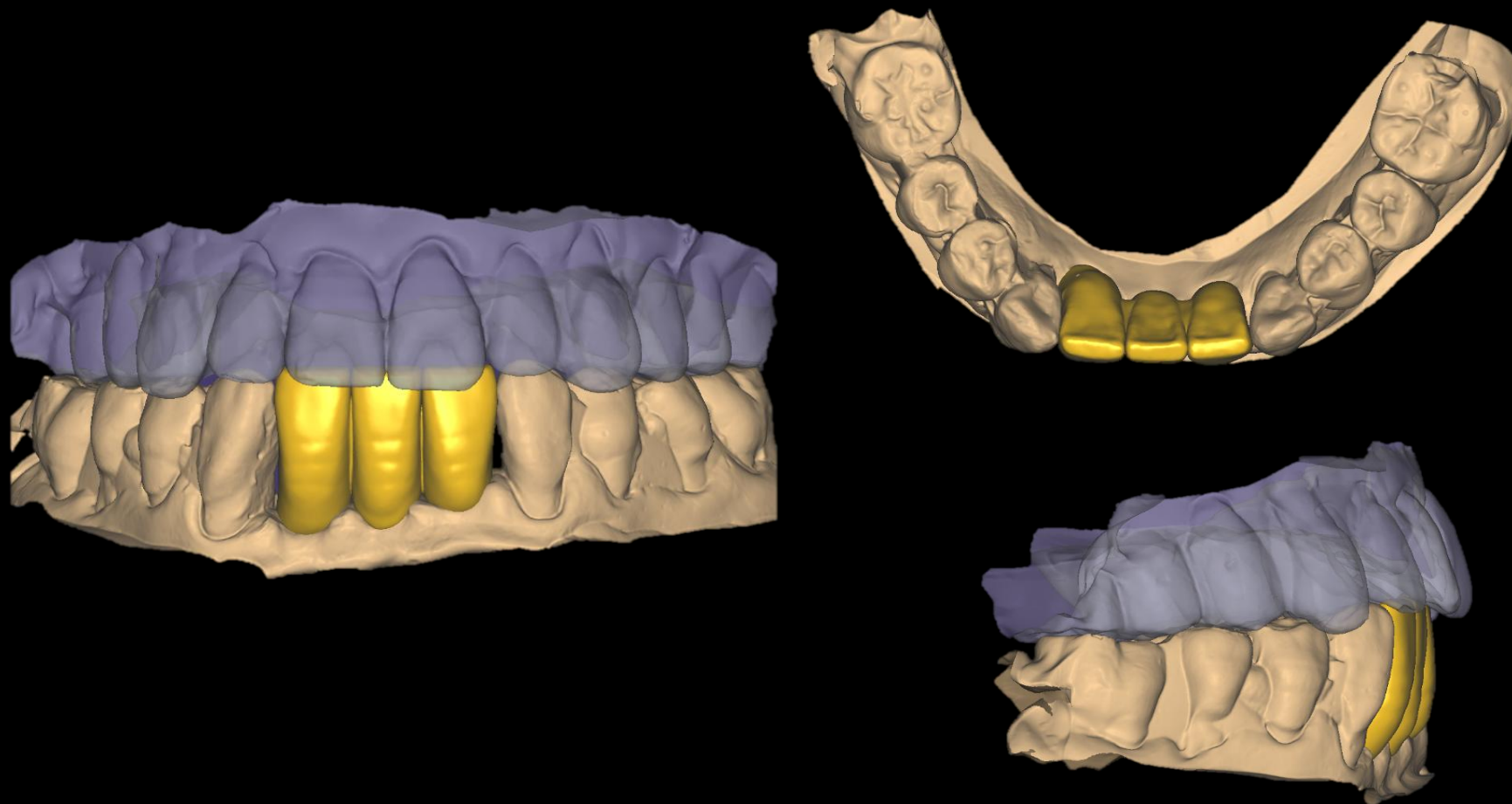
**Simple implant placement with Pin guide**



Bite Tray Impression & Impression Scan (B.T.S)

## Similar case 1

## Simple implant placement with Pin guide

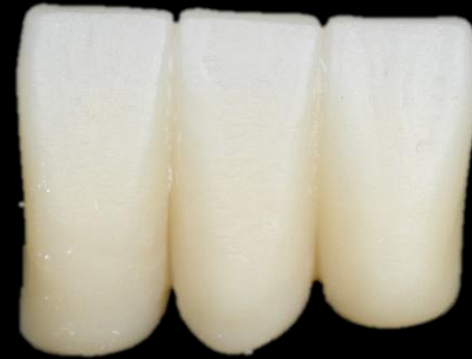
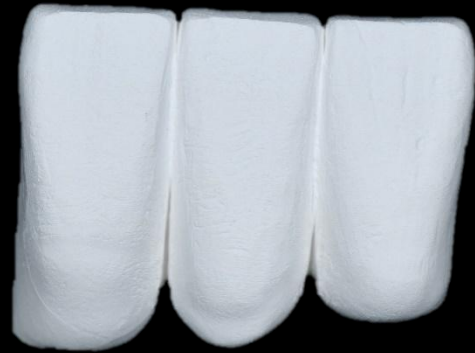
CAD (Final restoration)



**Similar case 1**

**Simple implant placement with Pin guide**

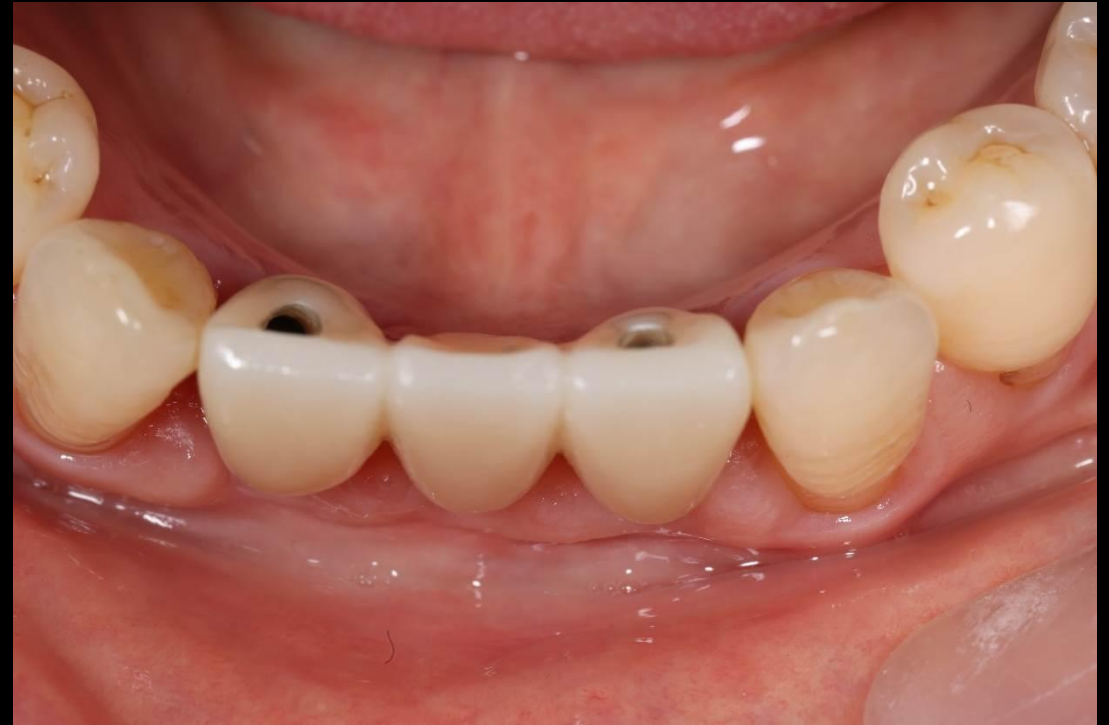
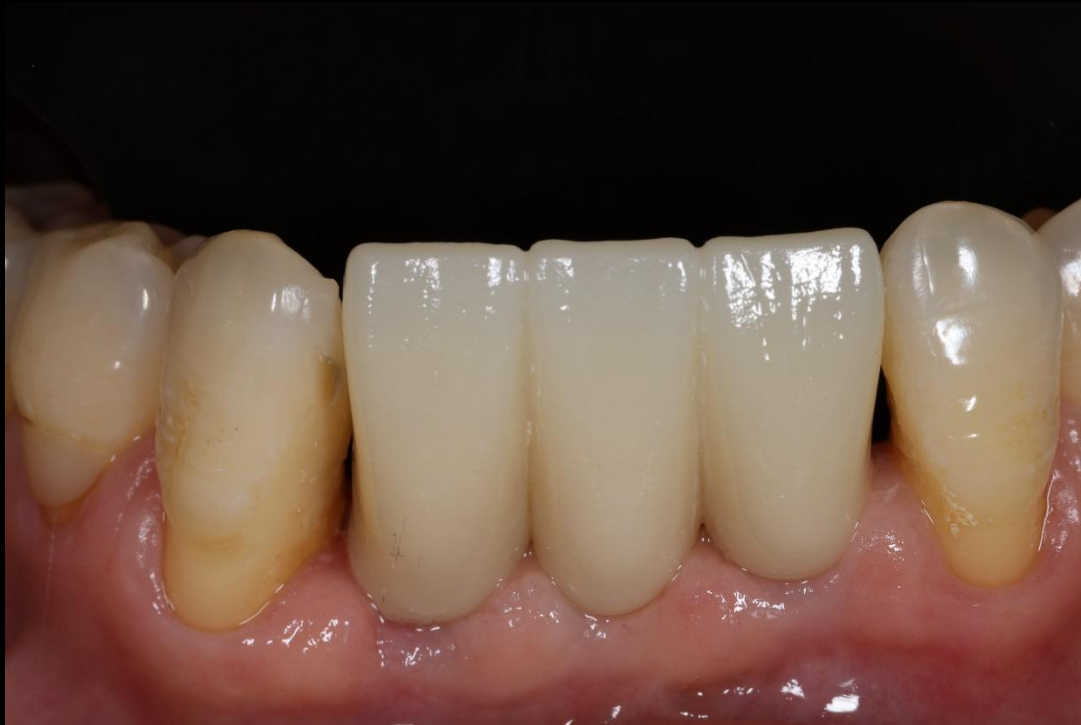
Milling / Sintering / Glazing



## Similar case 1

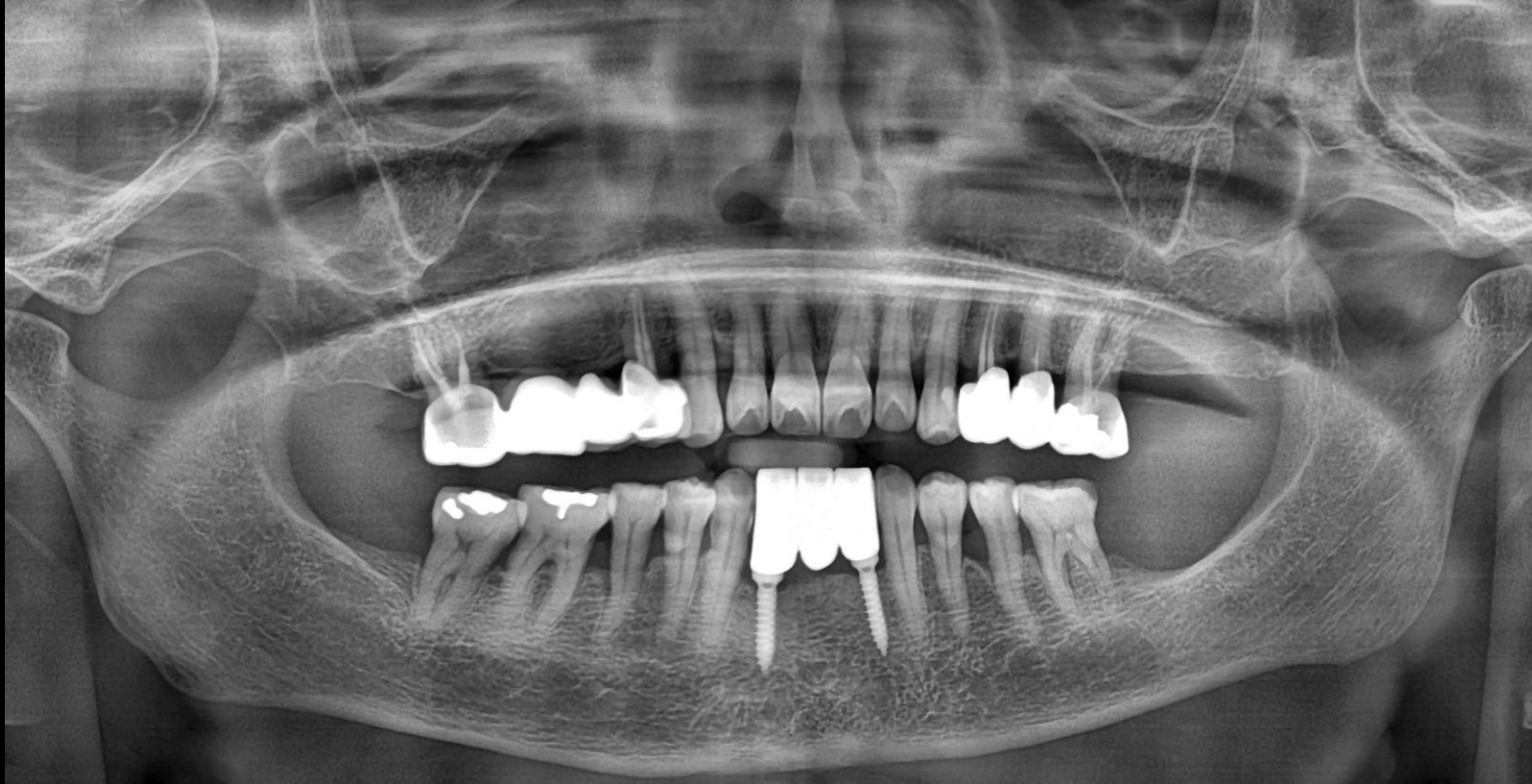## Simple implant placement with Pin guide



Final prosthesis

## Similar case 1

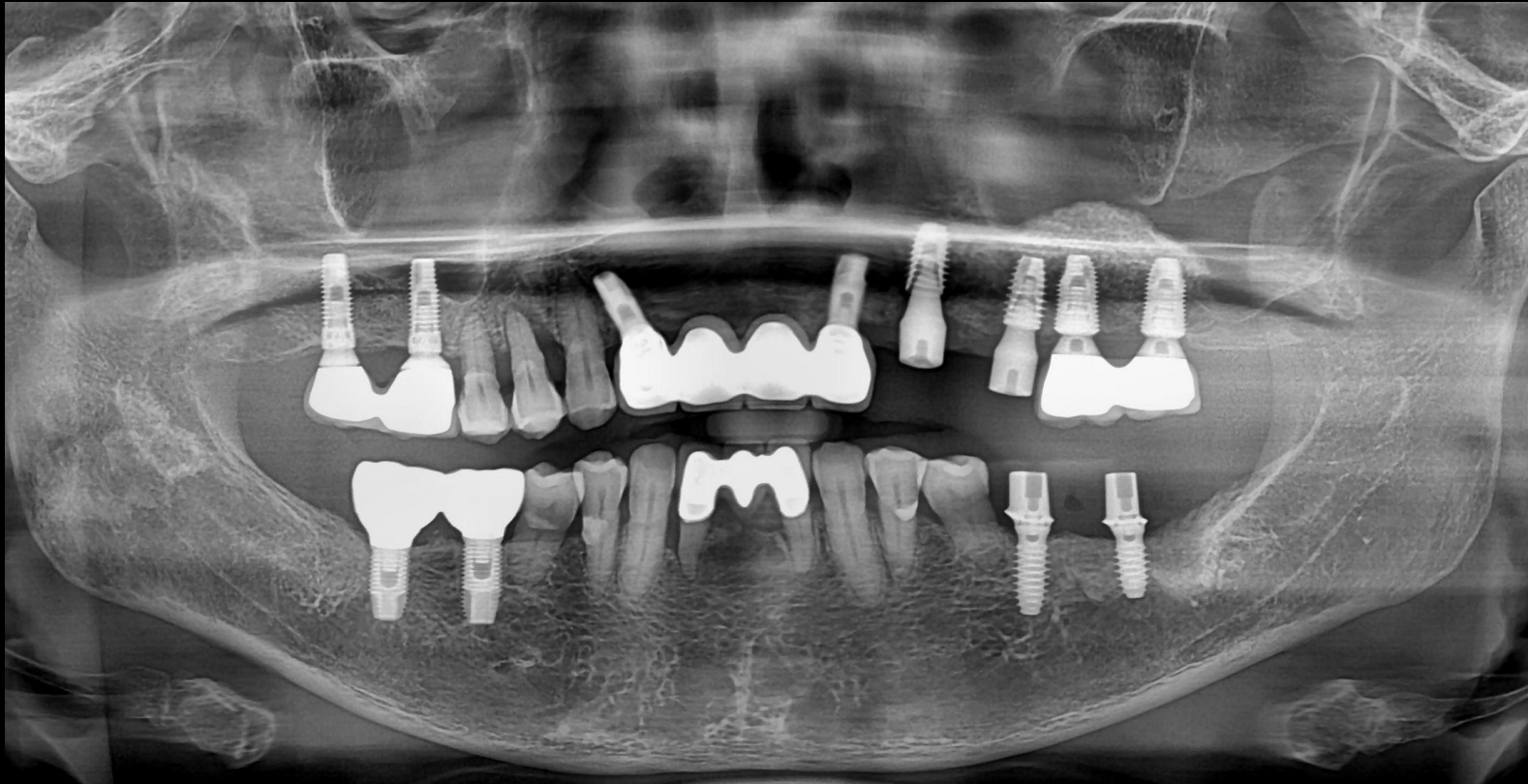## Simple implant placement with Pin guide



Final prosthesis

## Similar case 2

Implant placement using pin guide at pre-molar site

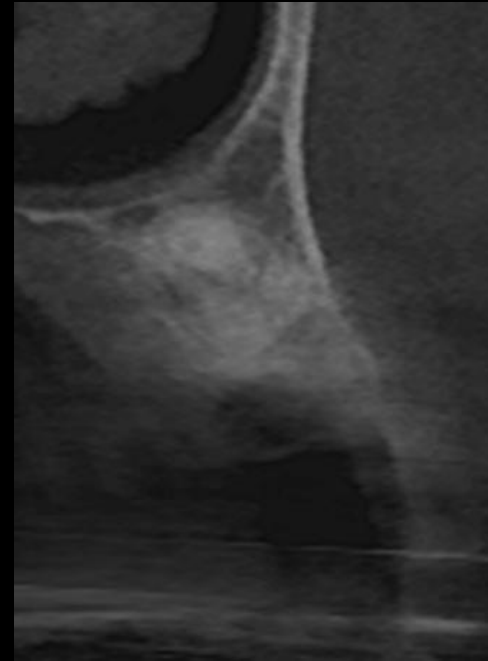
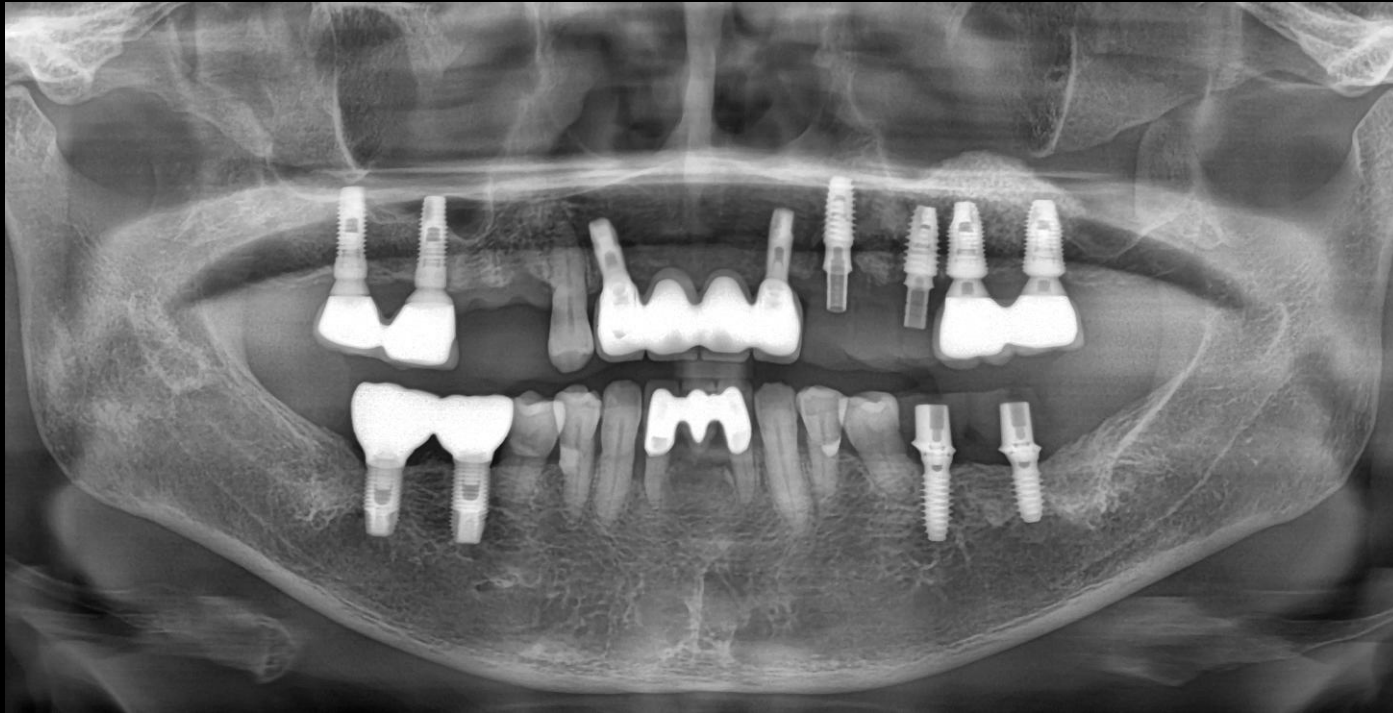

Oral Exam

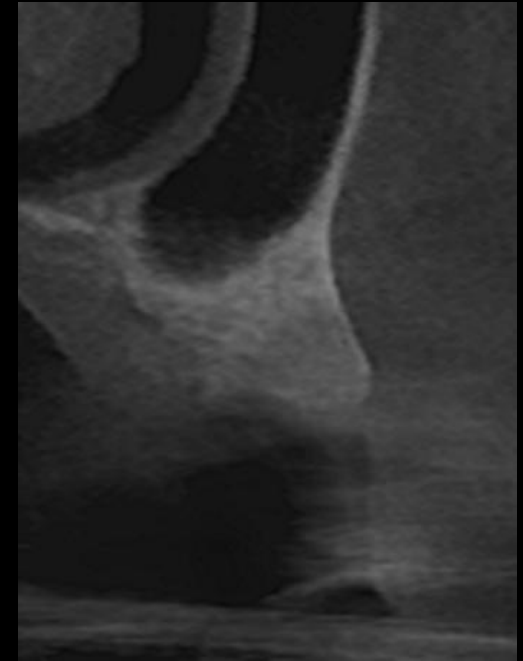

**Similar case 2**

**Implant placement using pin guide at pre-molar site**



**#14**

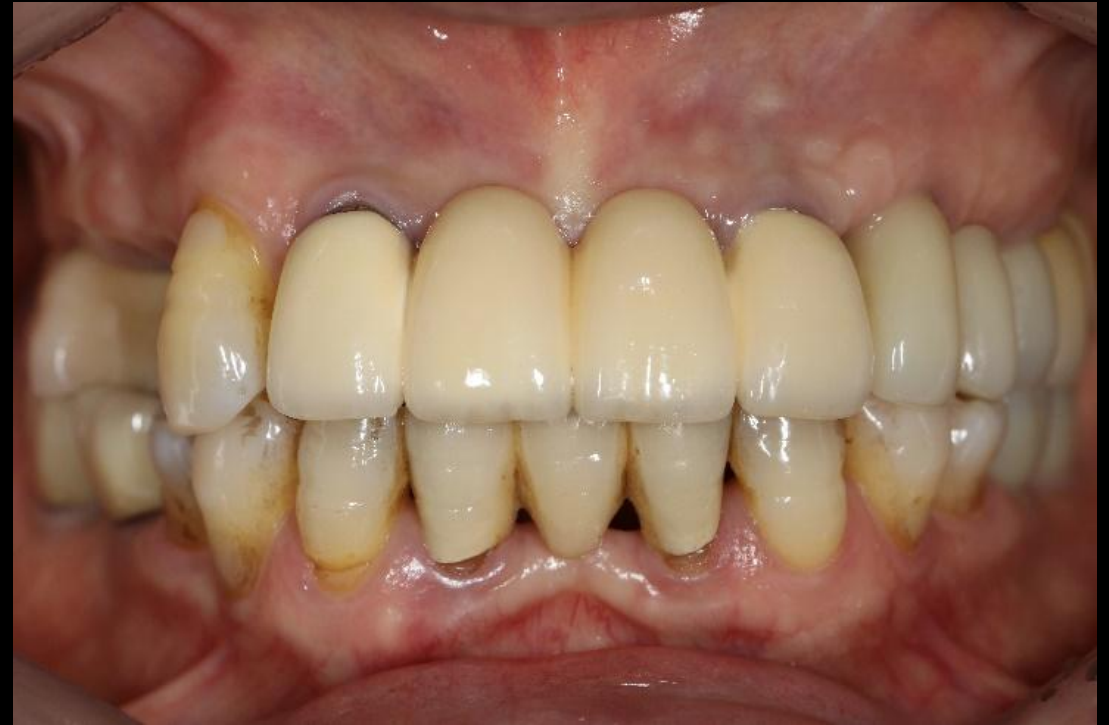
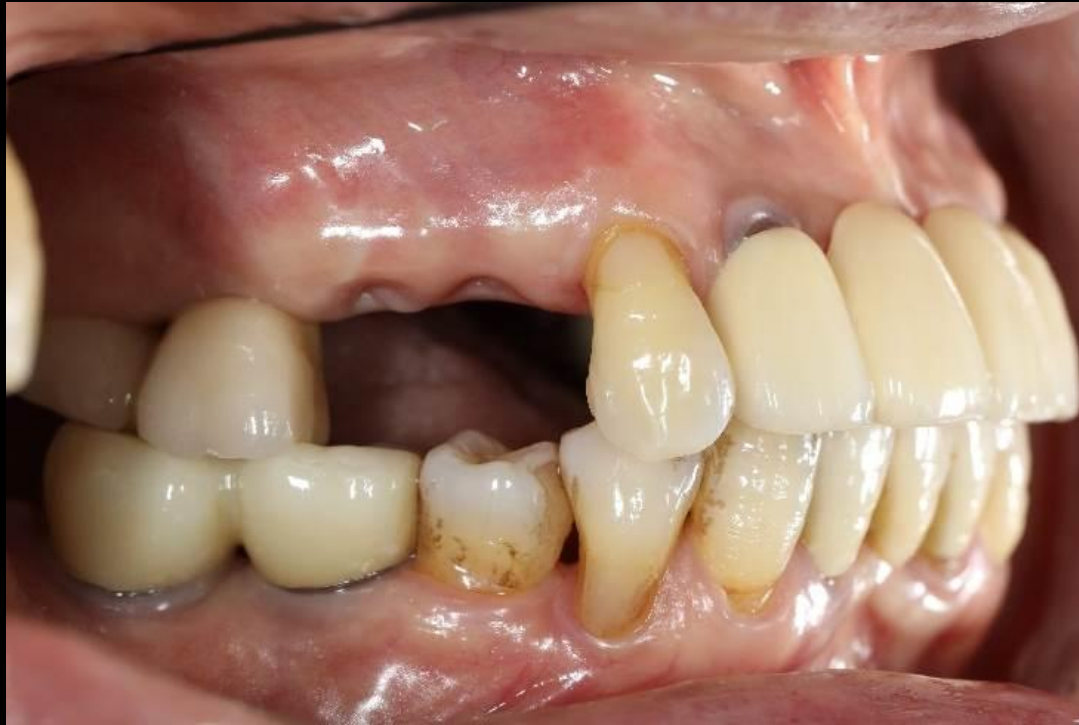
**#15**

Pre-op

## Similar case 2

Implant placement using pin guide at pre-molar site

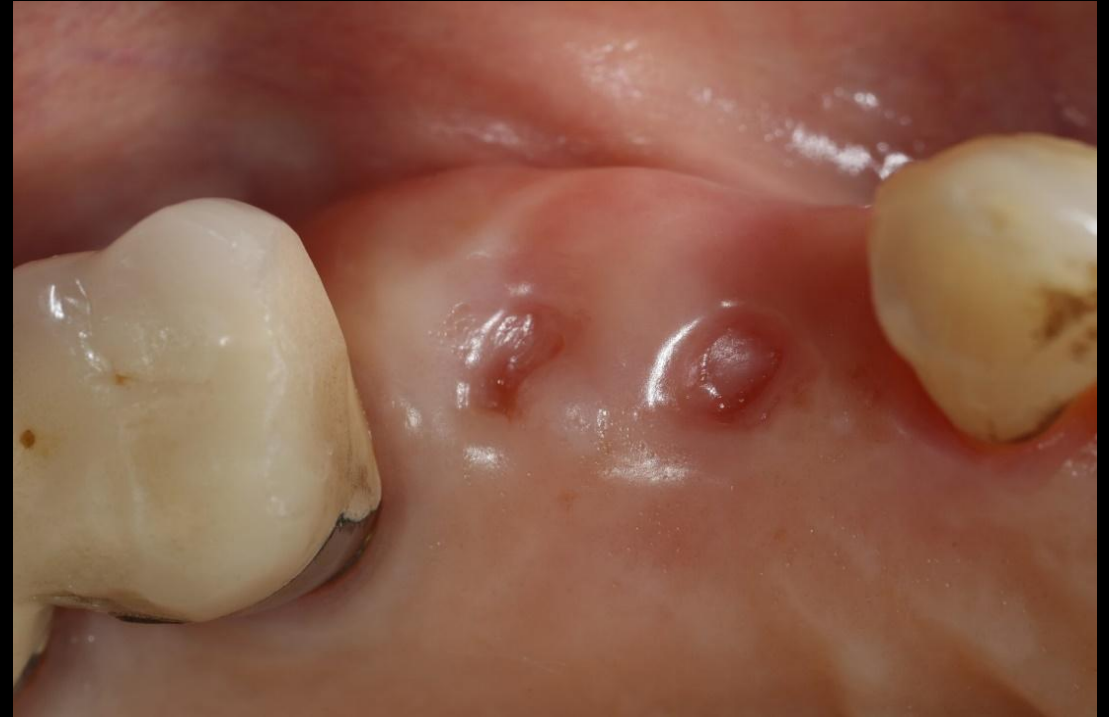
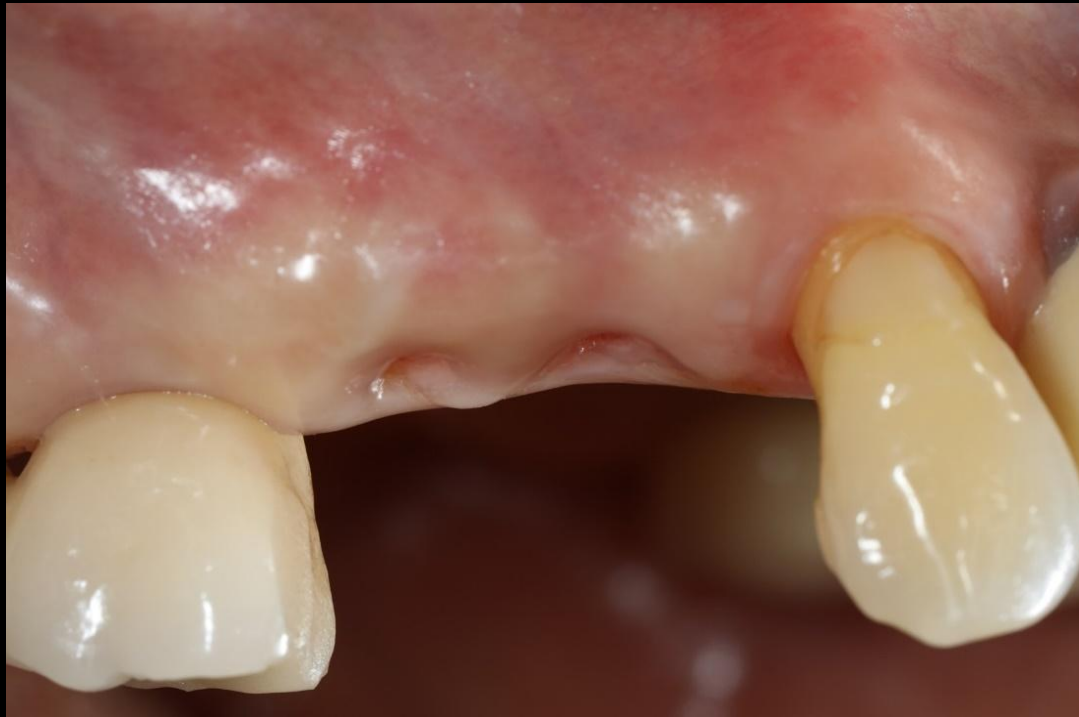
Pre-op



**Similar case 2**

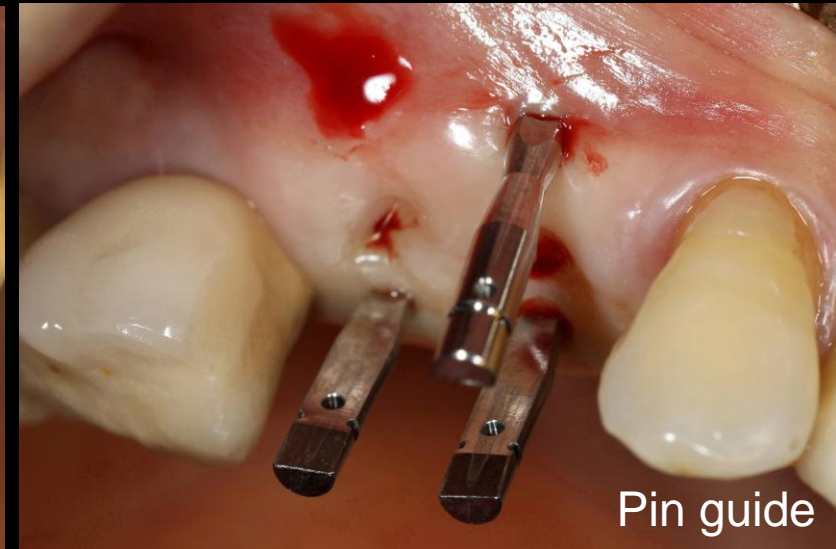
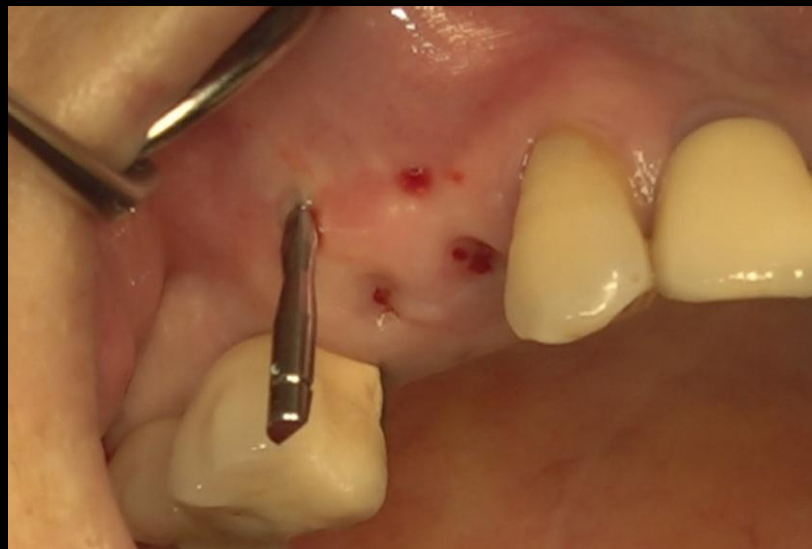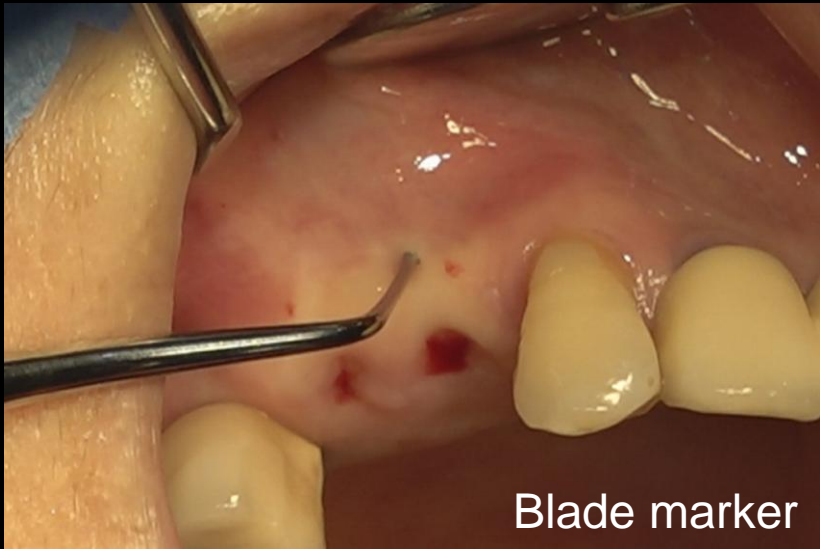
**Implant placement using pin guide at pre-molar site**



Pre-op

## Similar case 2

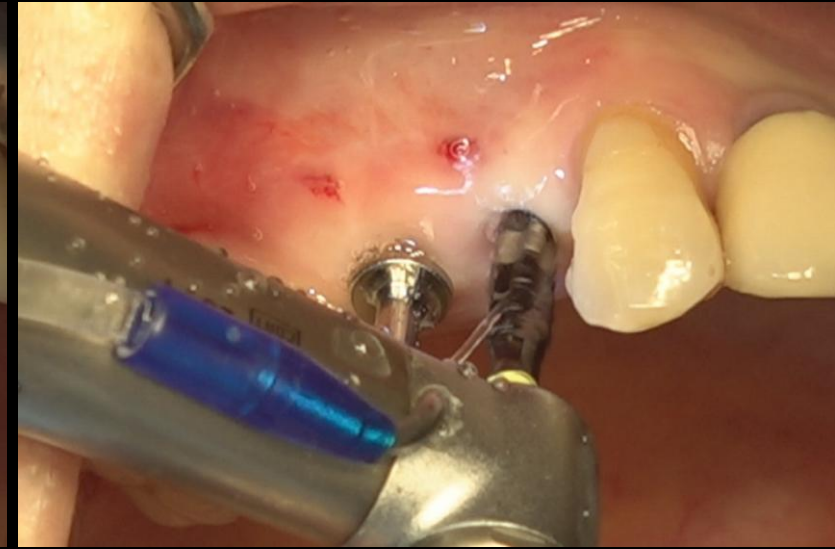
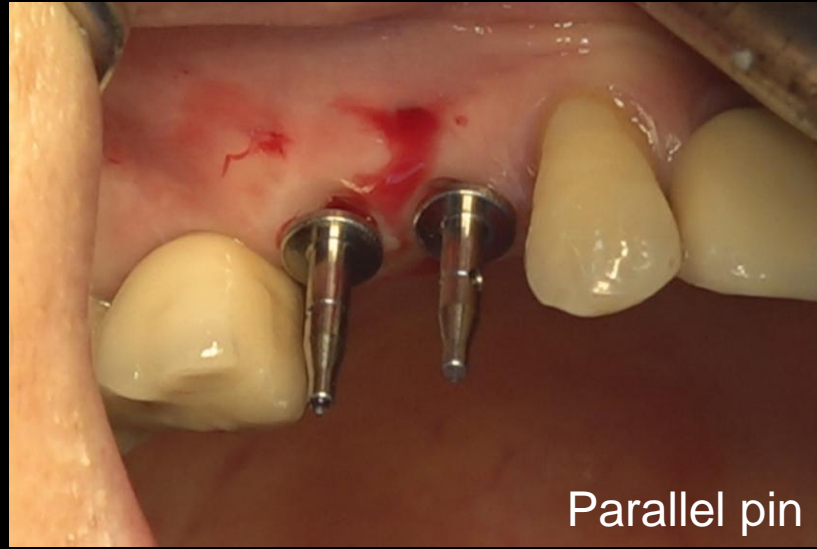
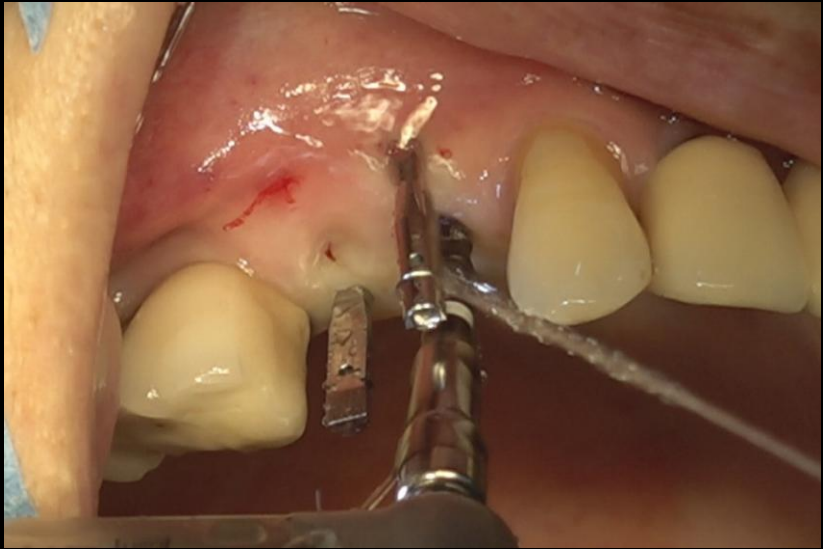
## Implant placement using pin guide at pre-molar site



Surgery

## Similar case 2

## Implant placement using pin guide at pre-molar site

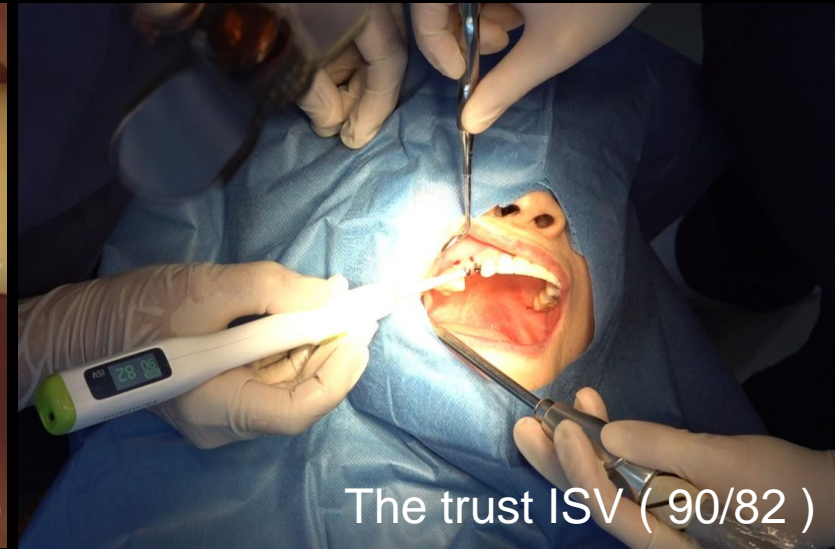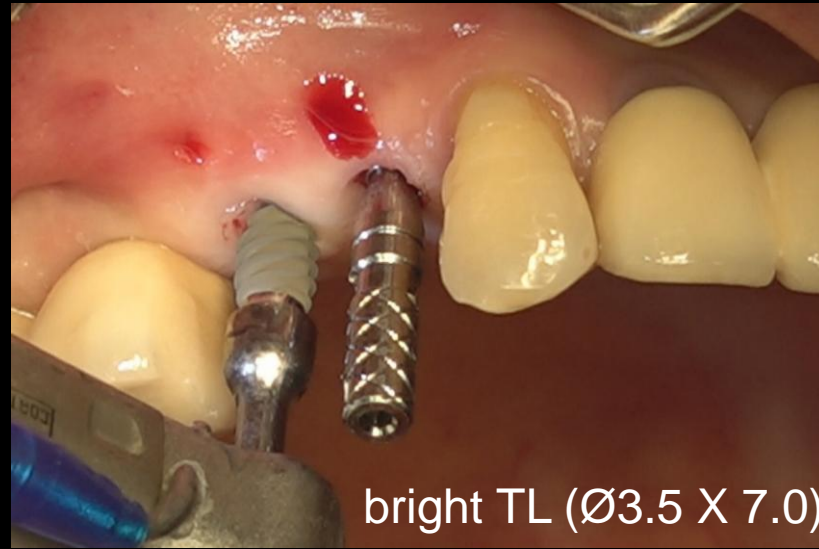

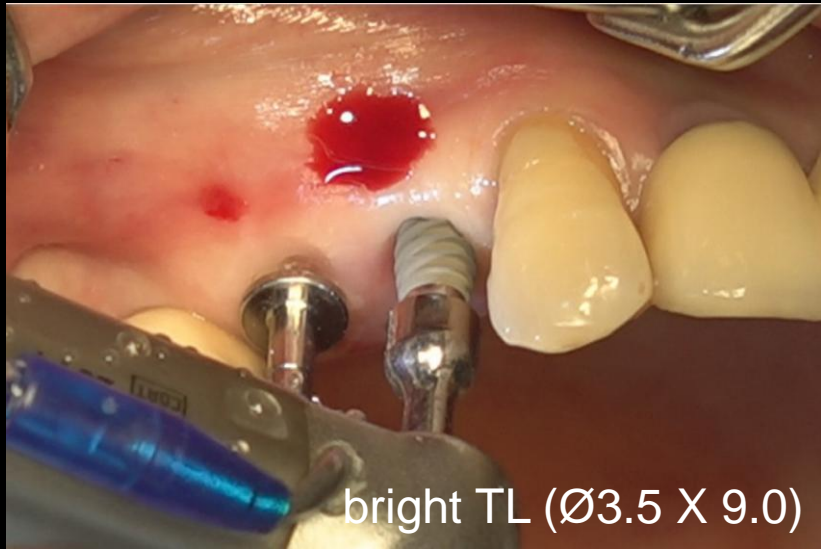
Surgery



## Similar case 2

## Implant placement using pin guide at pre-molar site

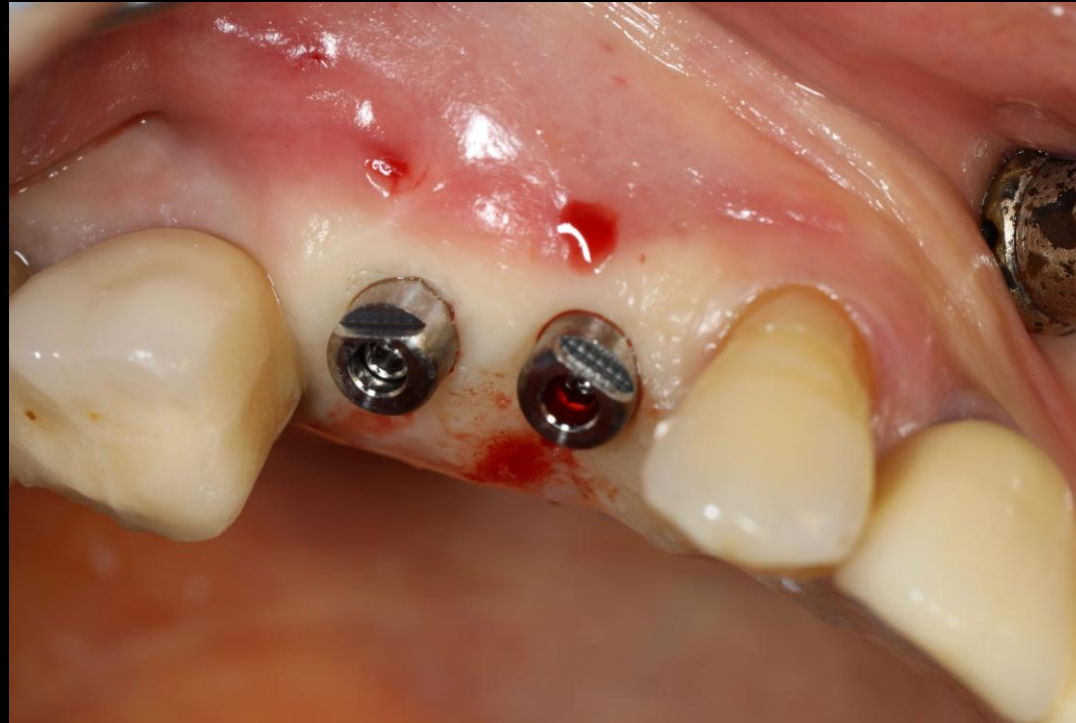

Surgery



## Similar case 2

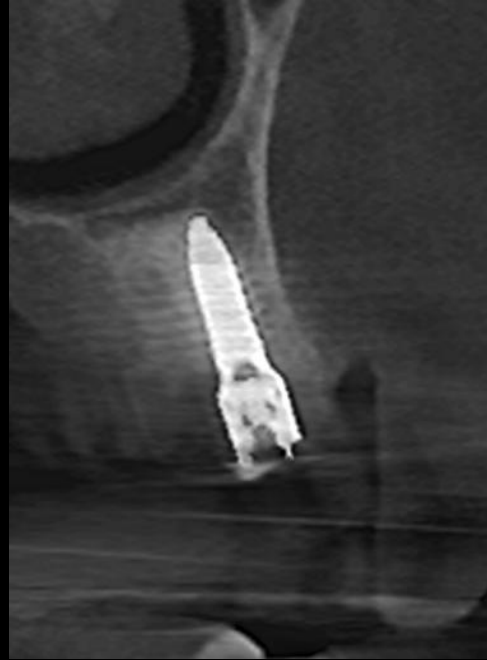Implant placement using pin guide at pre-molar site



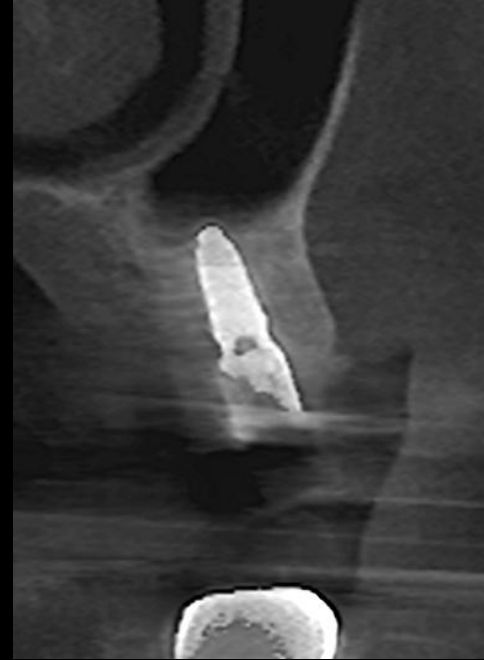Post-op

## Similar case 2

Implant placement using pin guide at pre-molar site



#14

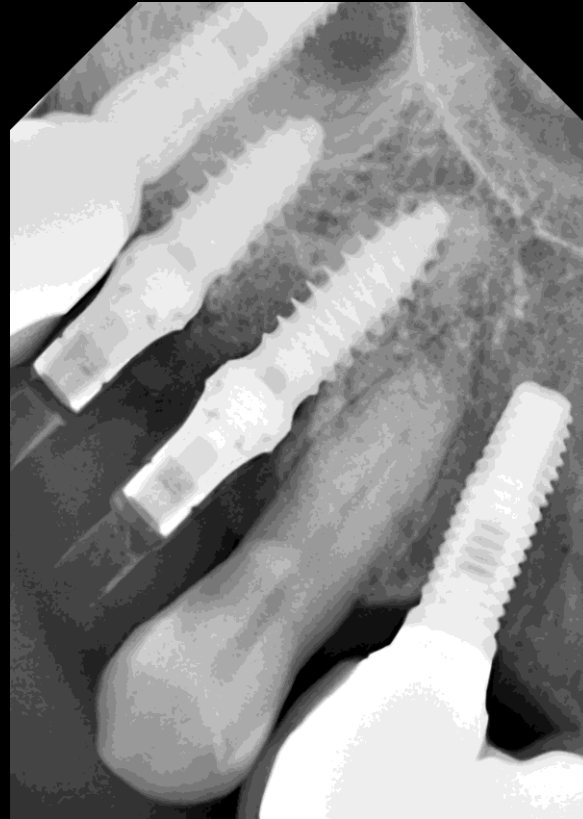

#15

Post-op

## Similar case 2

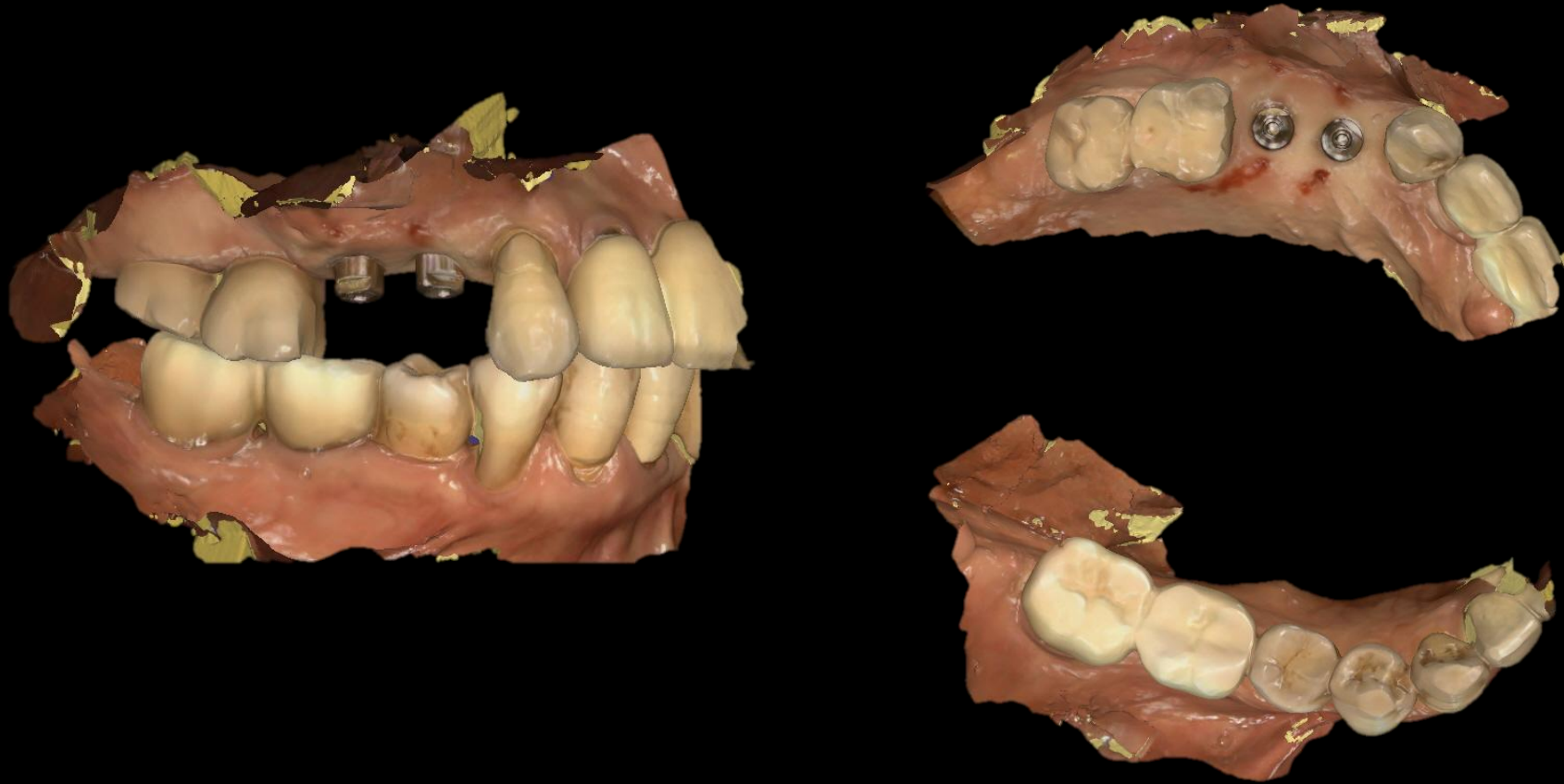Implant placement using pin guide at pre-molar site



Healing 4 weeks

**Similar case 2**

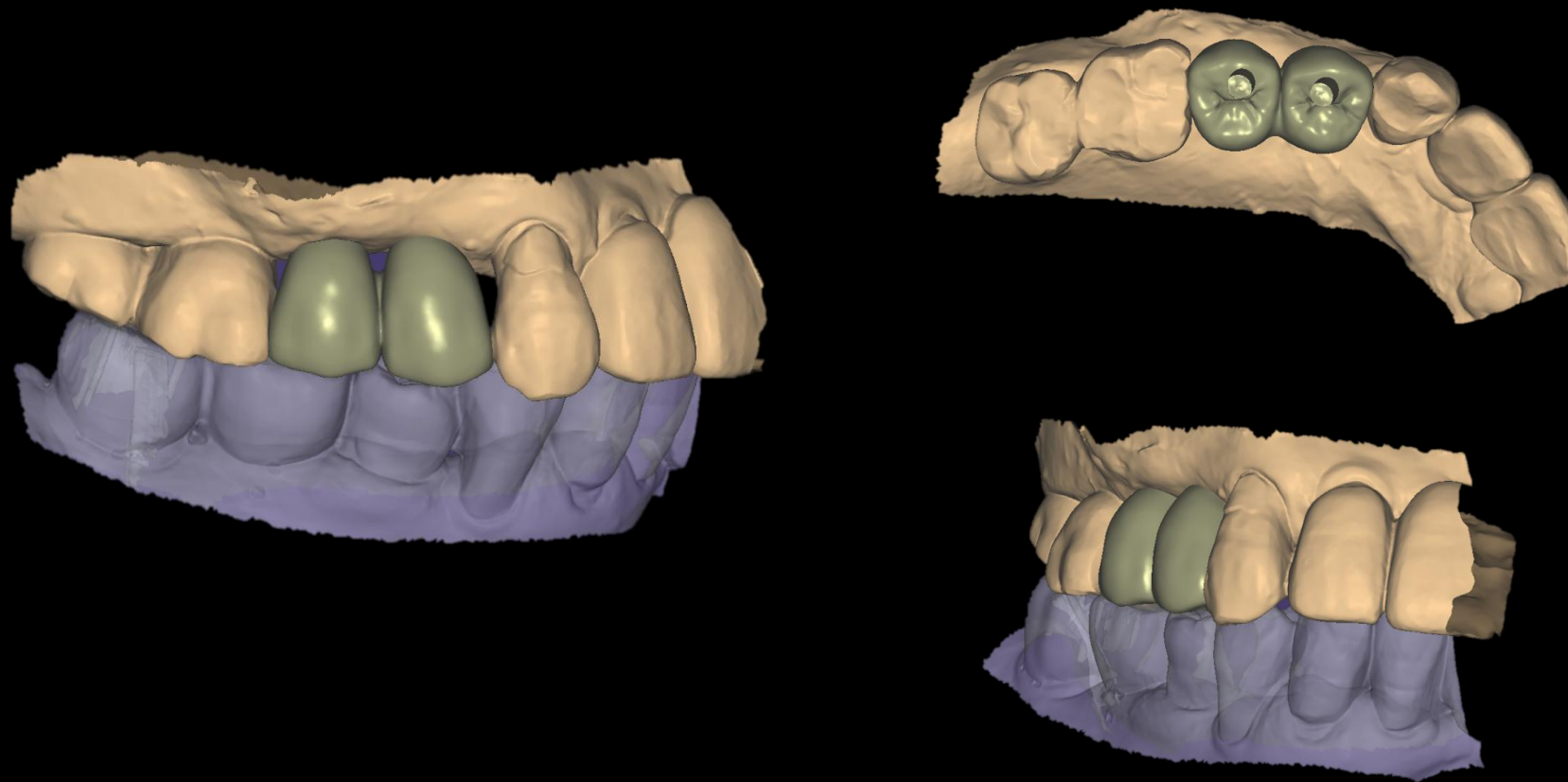
Implant placement using pin guide at pre-molar site





## Similar case 2

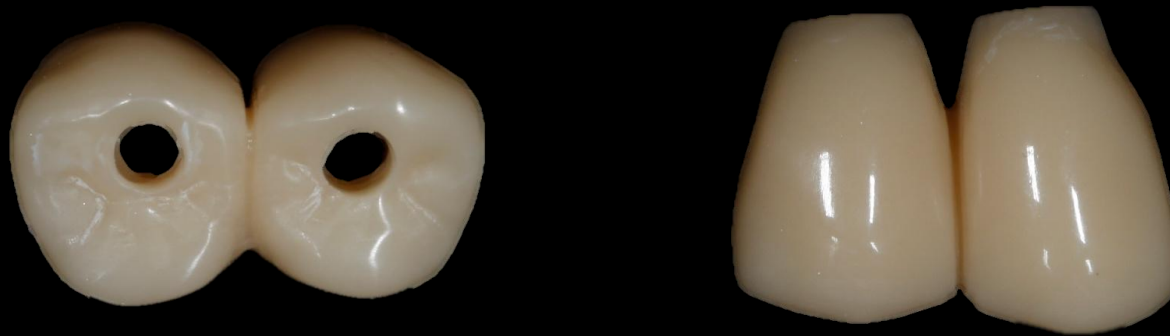Implant placement using pin guide at pre-molar site



CAD (Temporary)

**Similar case 2**

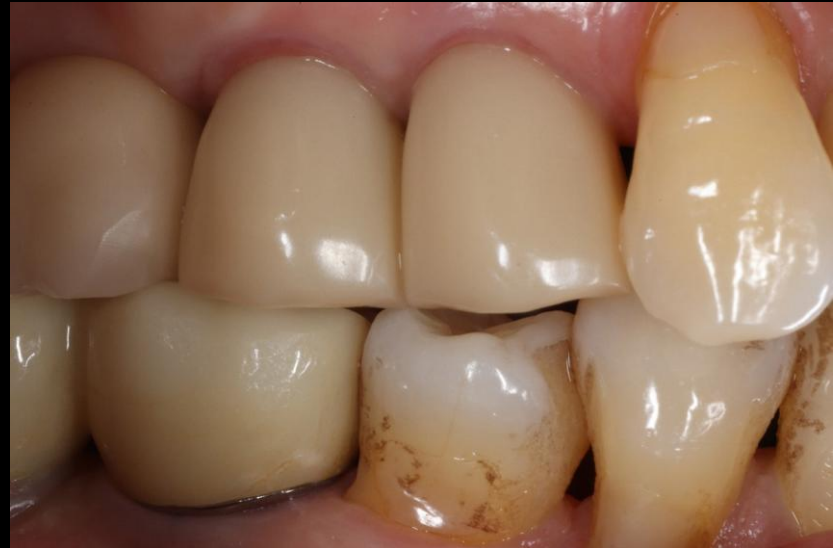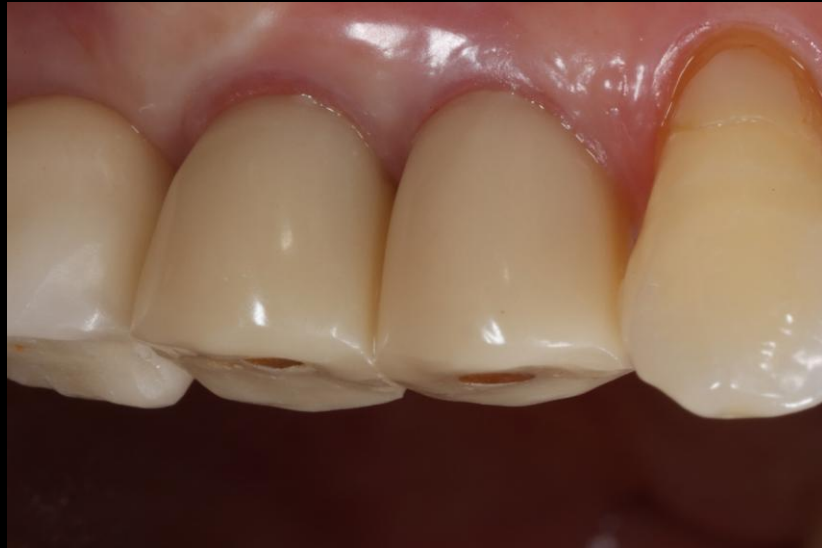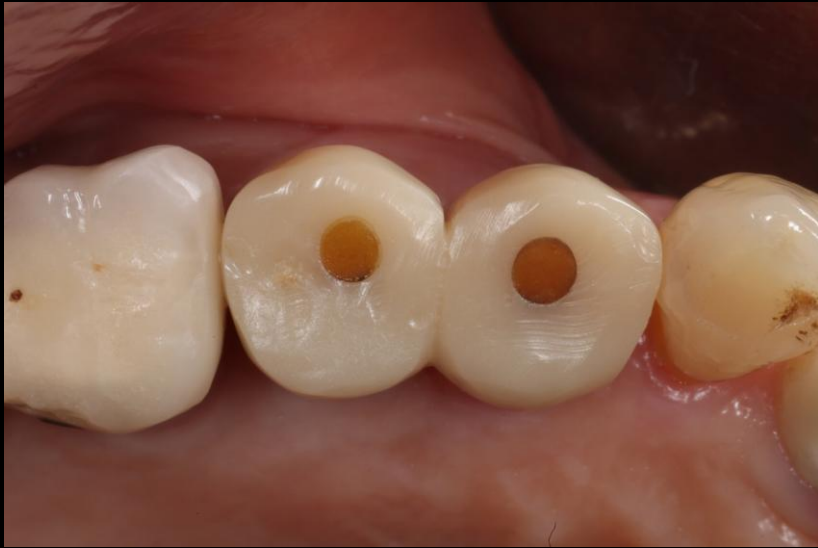Implant placement using pin guide at pre-molar site



Temporary Crown

**Similar case 2**

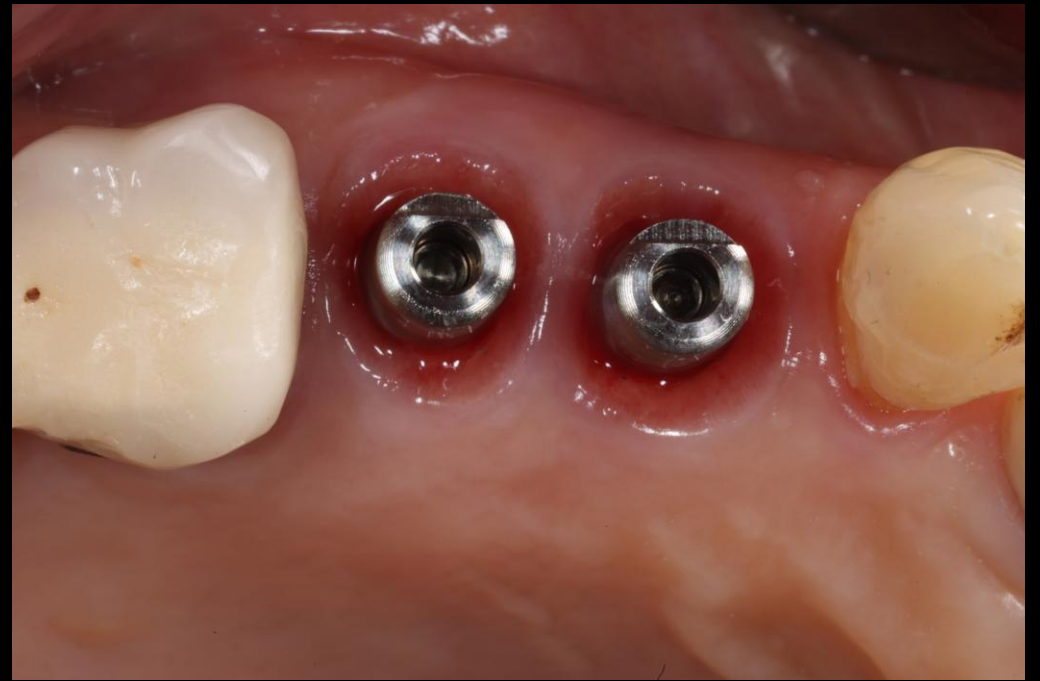
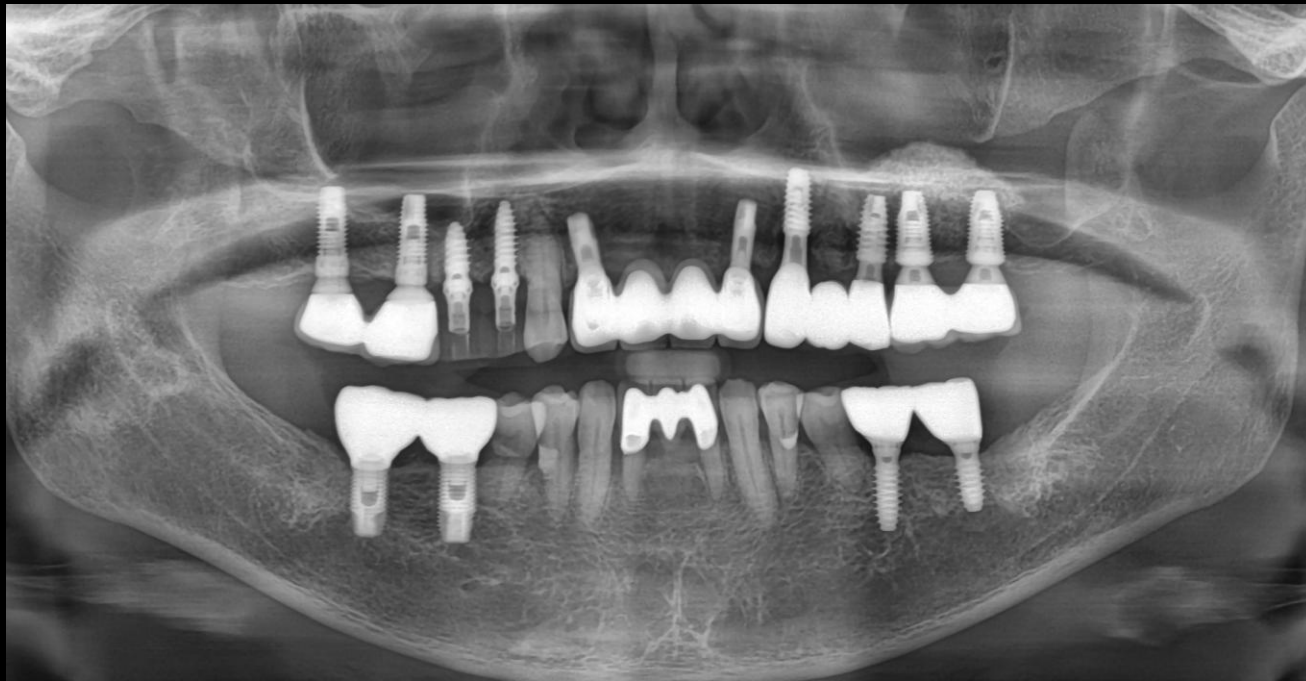**Implant placement using pin guide at pre-molar site**



Provisional restoration

**Similar case 2**

**Implant placement using pin guide at pre-molar site**

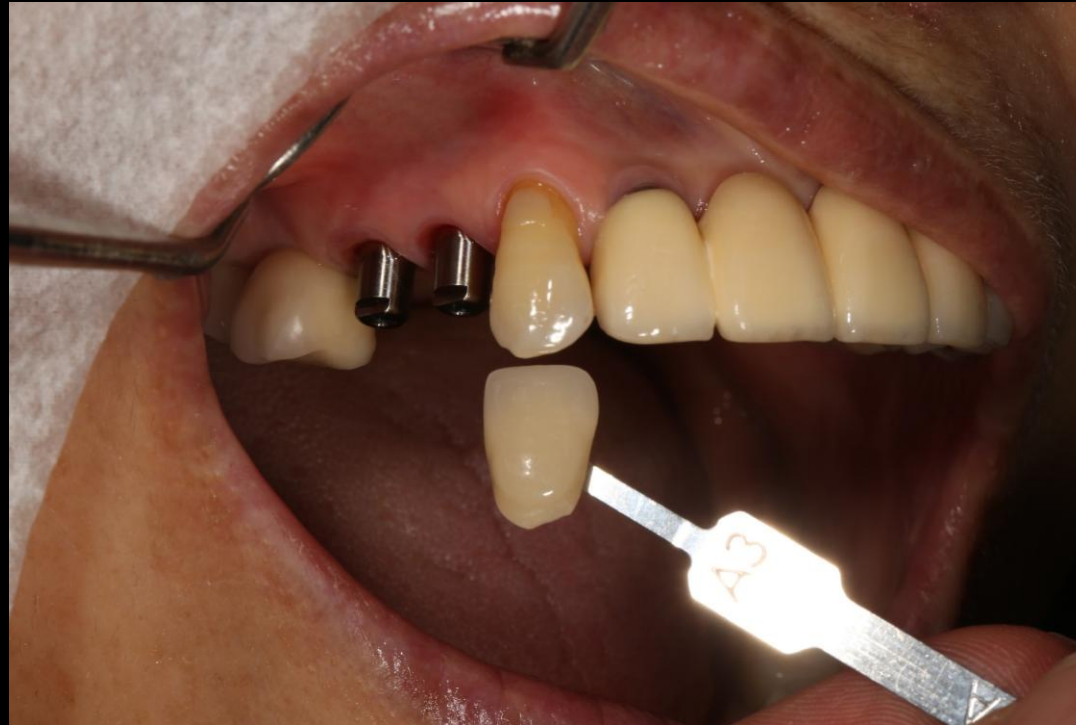

Healing 3 months



**Similar case 2**

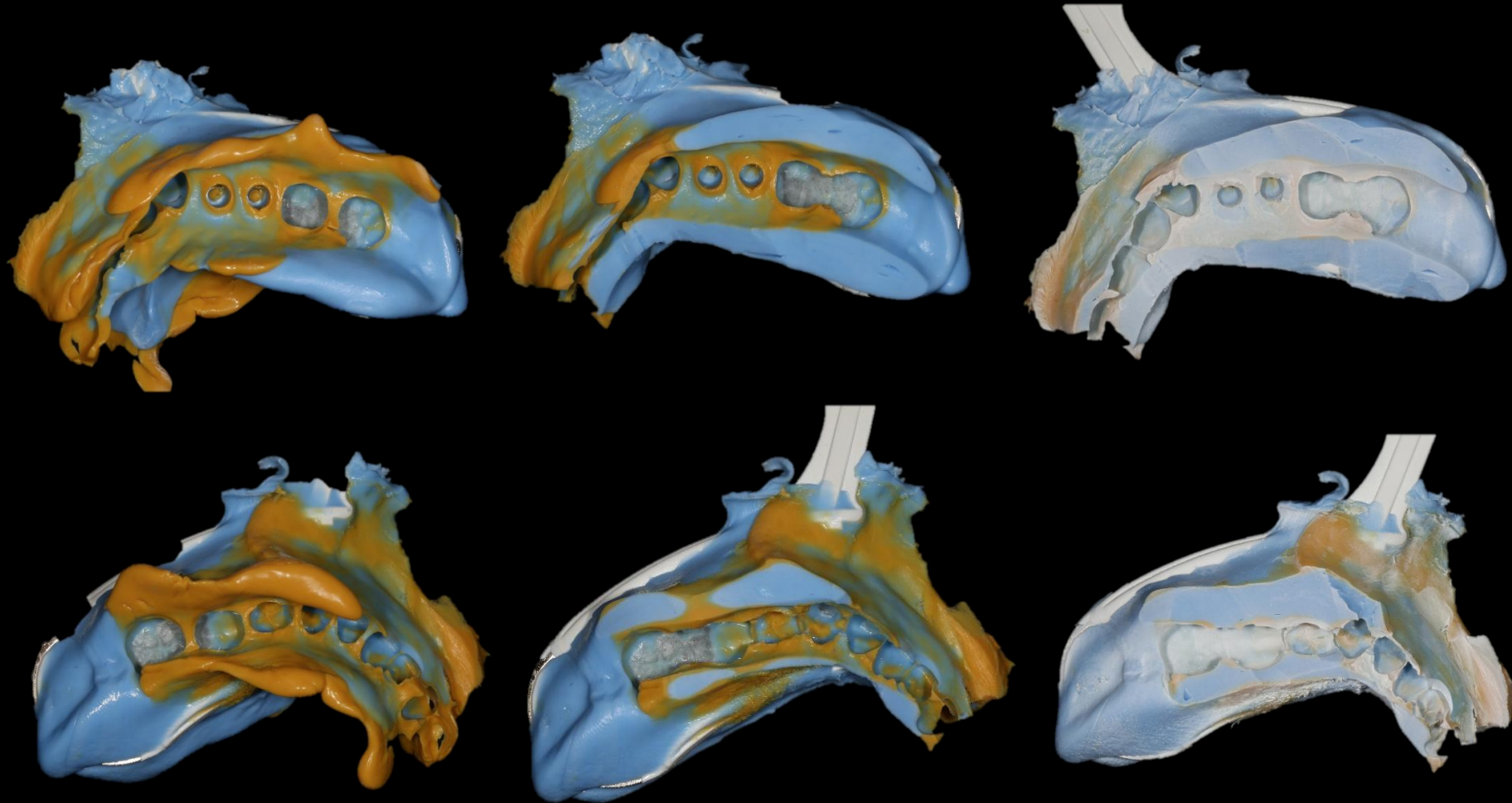
**Implant placement using pin guide at pre-molar site**



Shade taking

**Similar case 2**

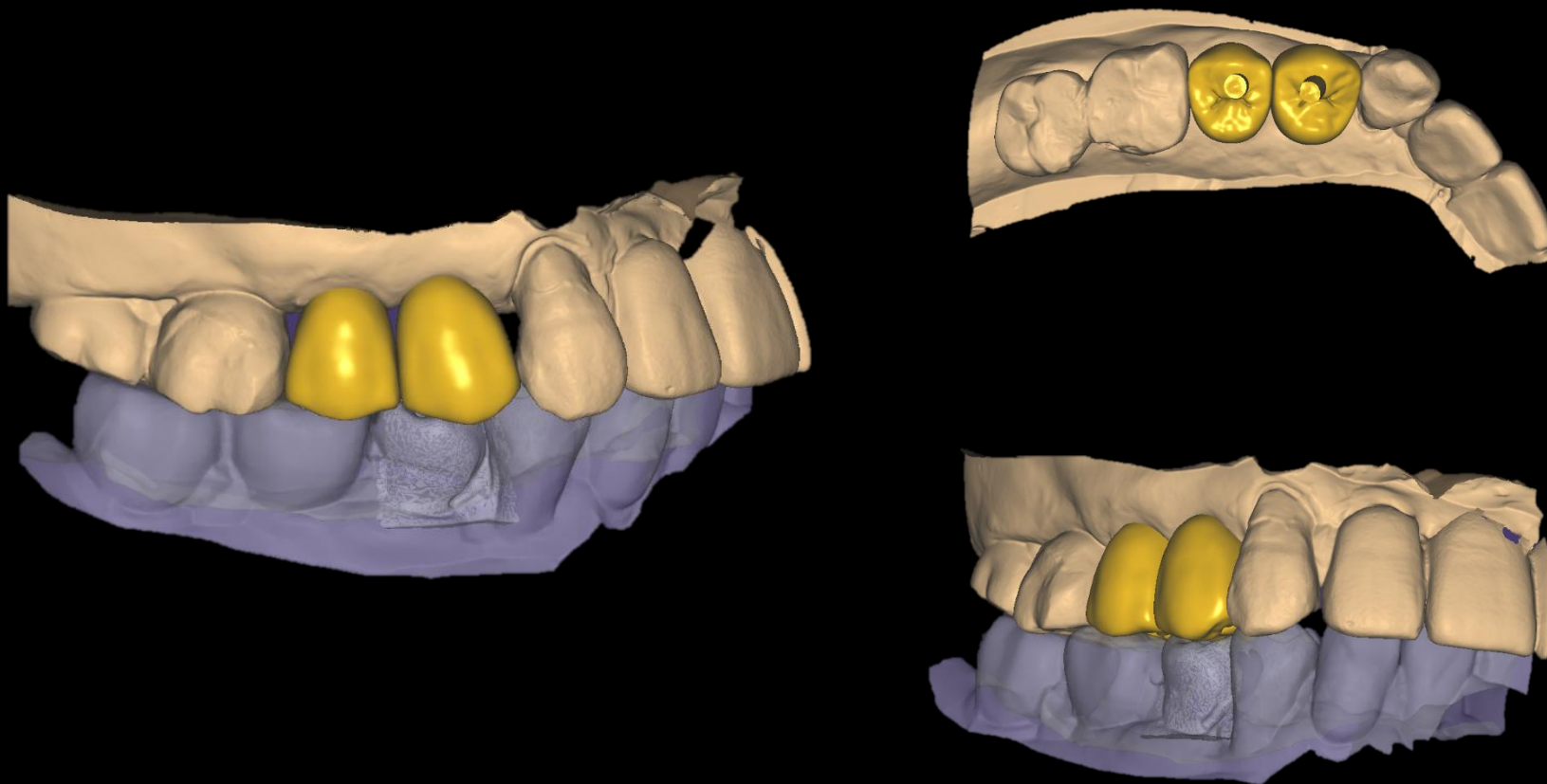
Implant placement using pin guide at pre-molar site



Bite Tray Impression & Impression Scan (B.T.S)

## Similar case 2

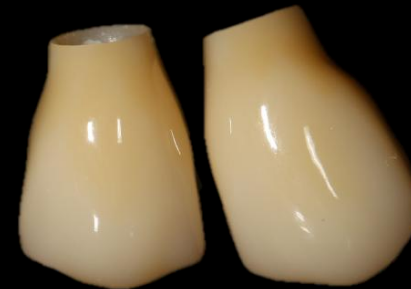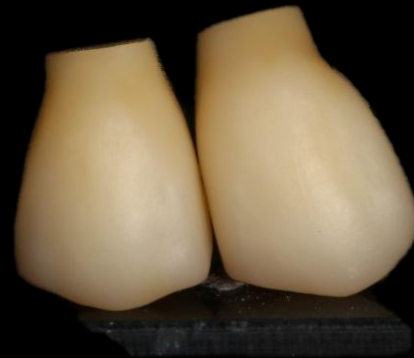Implant placement using pin guide at pre-molar site



CAD (Final restoration)

## Similar case 2

Implant placement using pin guide at pre-molar site

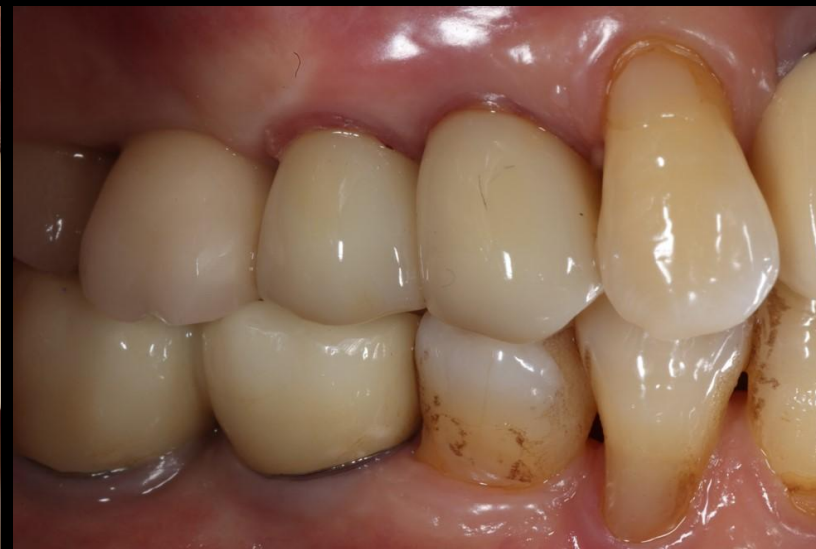
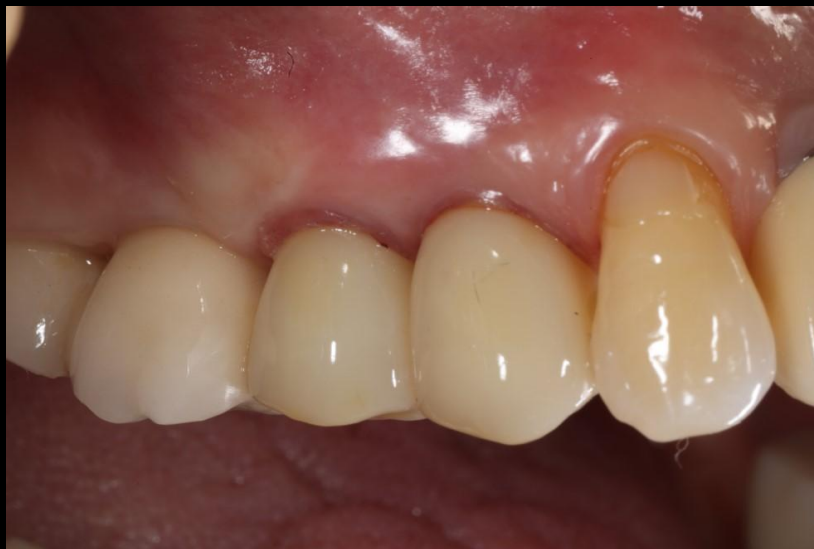
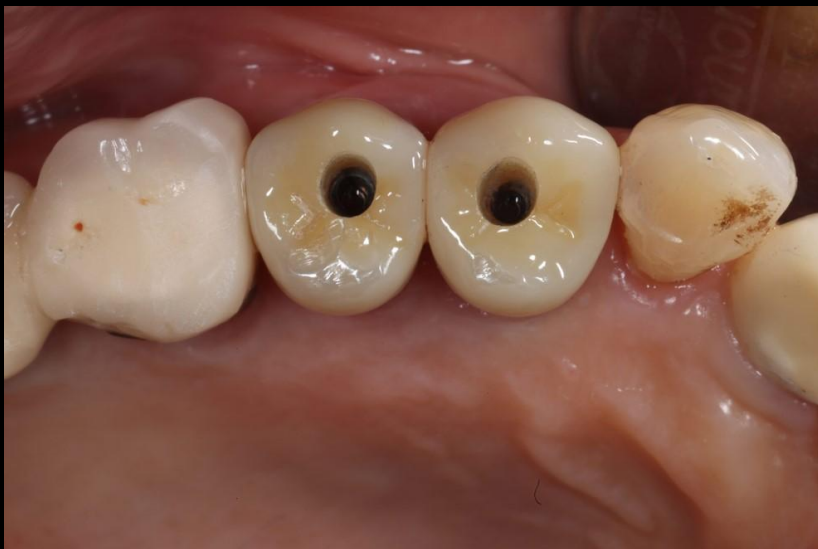Milling / Coloring / Sintering / Glazing



## Similar case 2

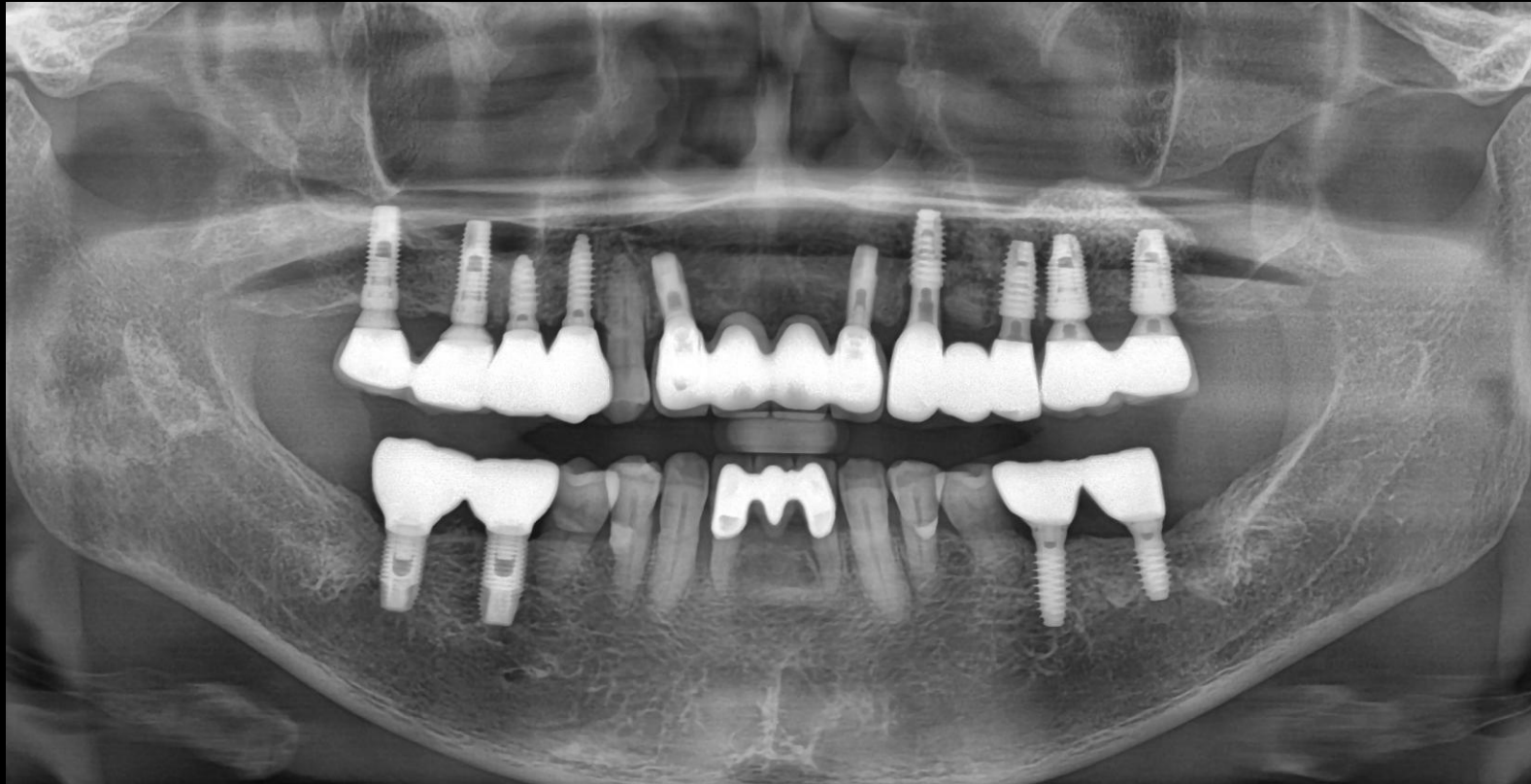Implant placement using pin guide at pre-molar site



Final prosthesis

## Similar case 2

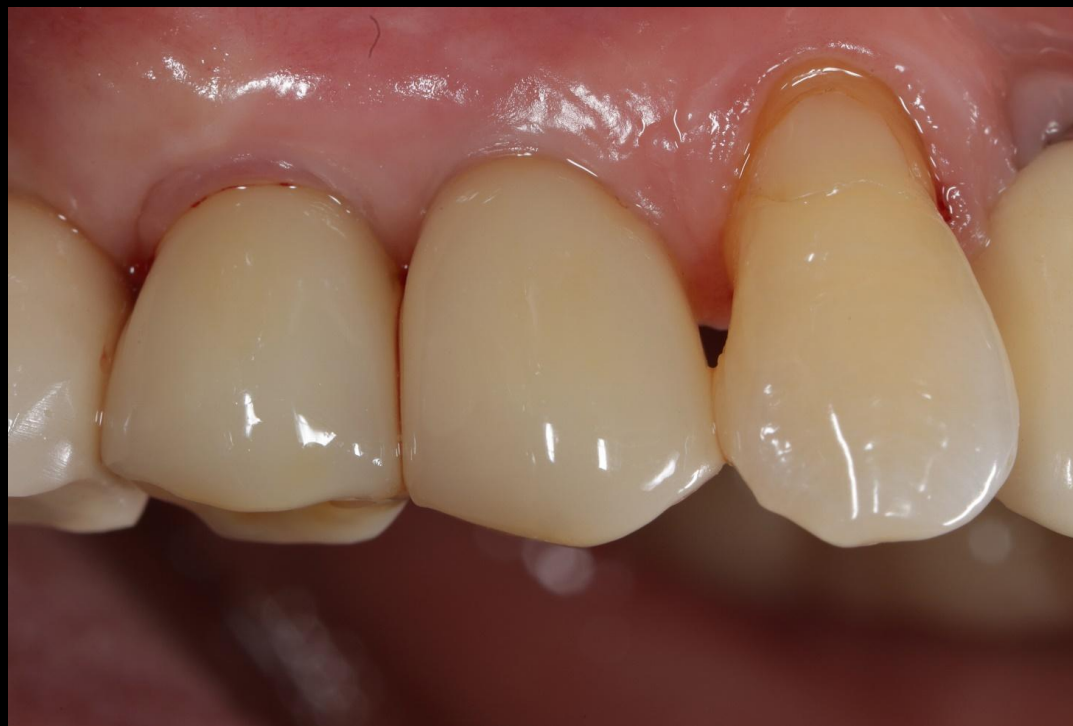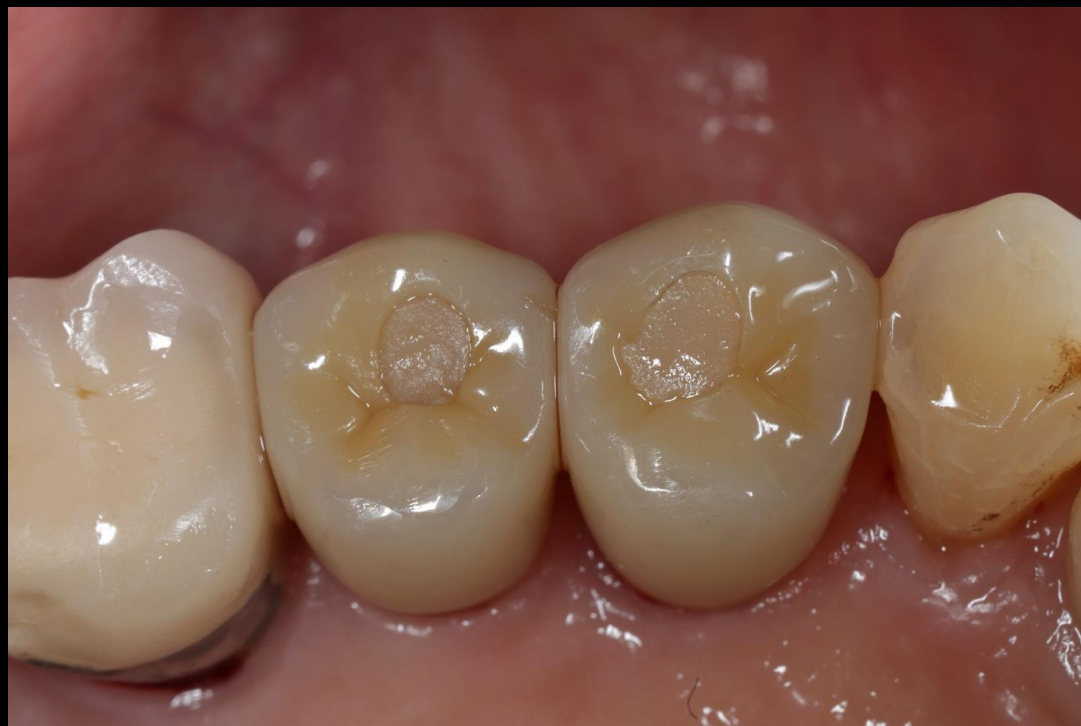Implant placement using pin guide at pre-molar site



Final prosthesis

## Similar case 2

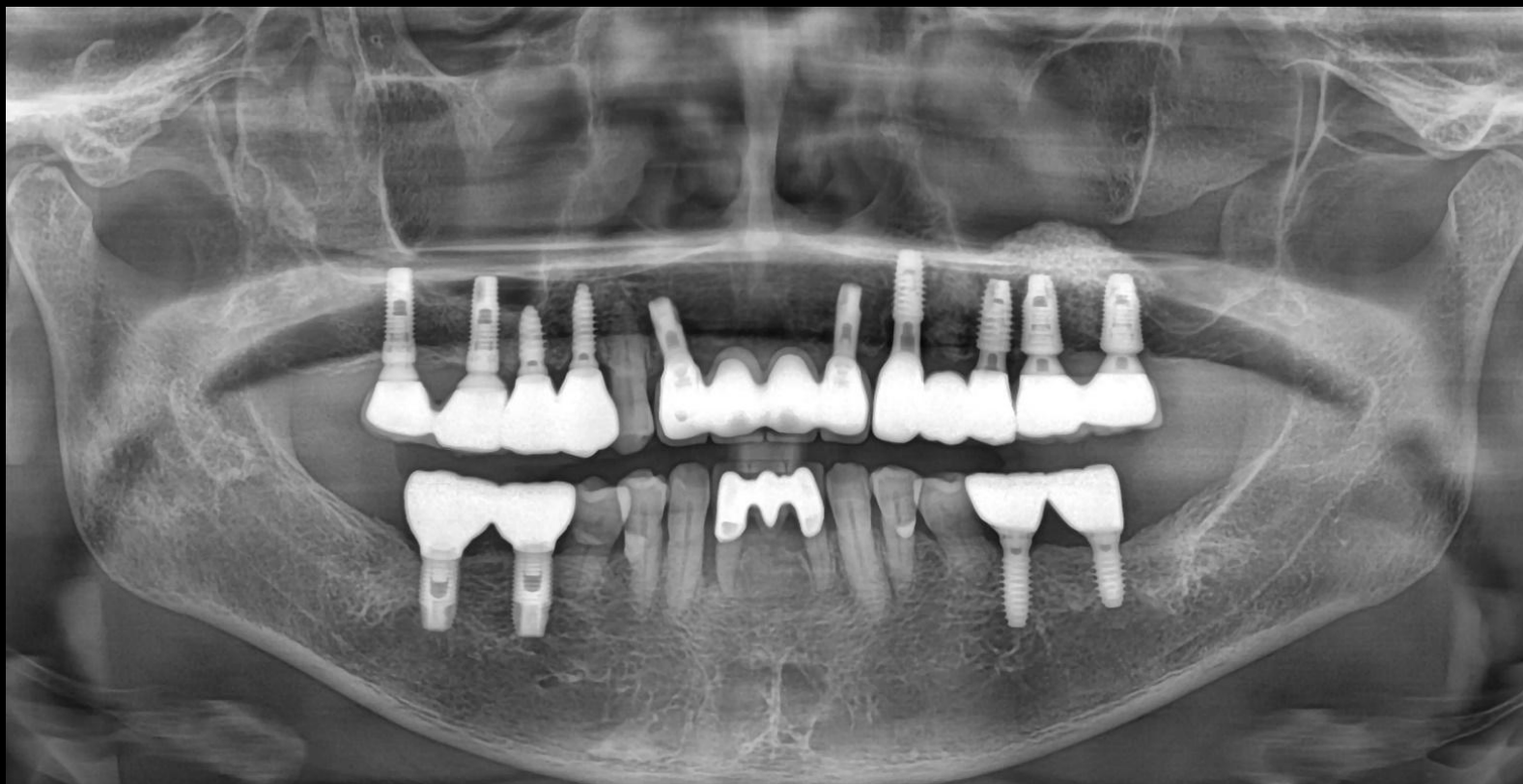Implant placement using pin guide at pre-molar site



Follow up 6 months

## Similar case 2

Implant placement using pin guide at pre-molar site

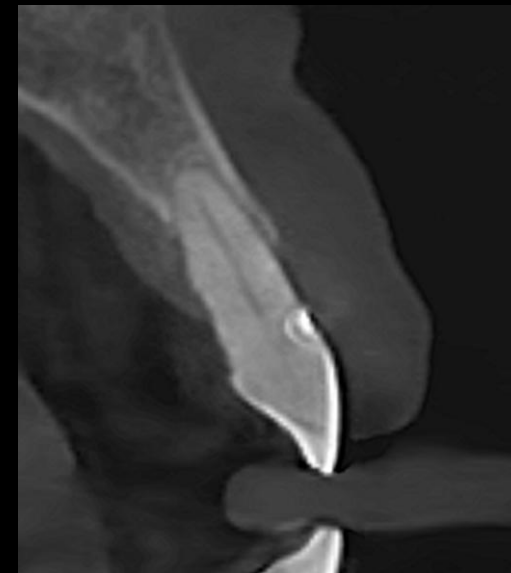
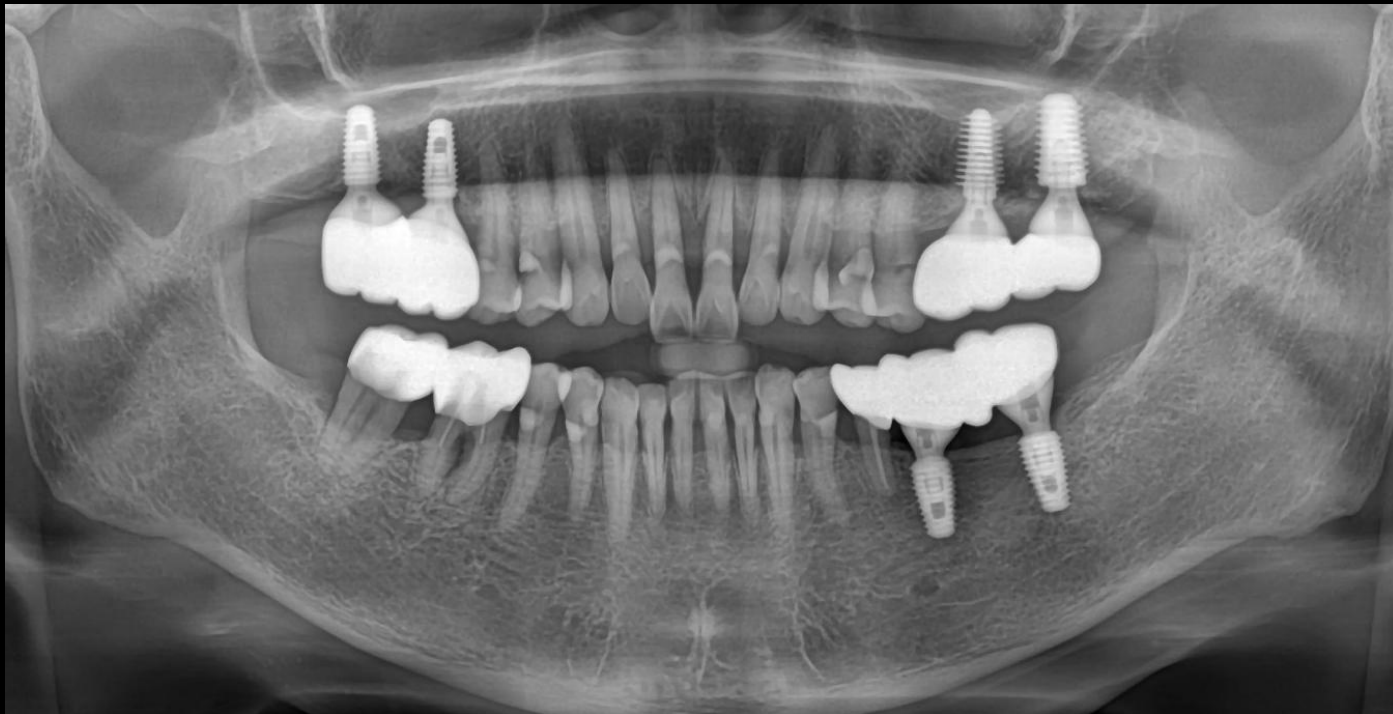
Follow up 1 year

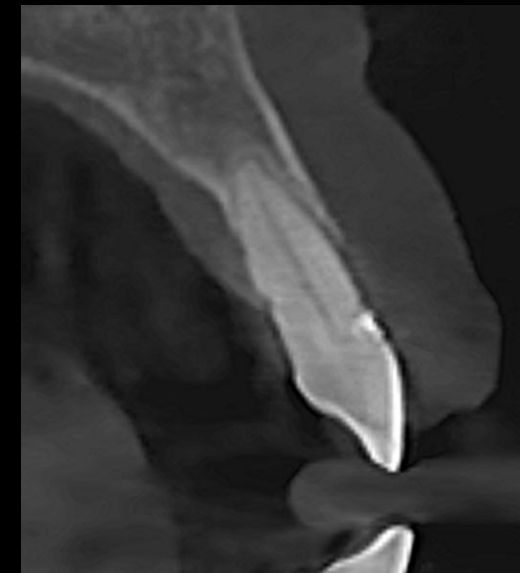


## Previous Surgery

Extraction and Bone graft at extraction socket



#11

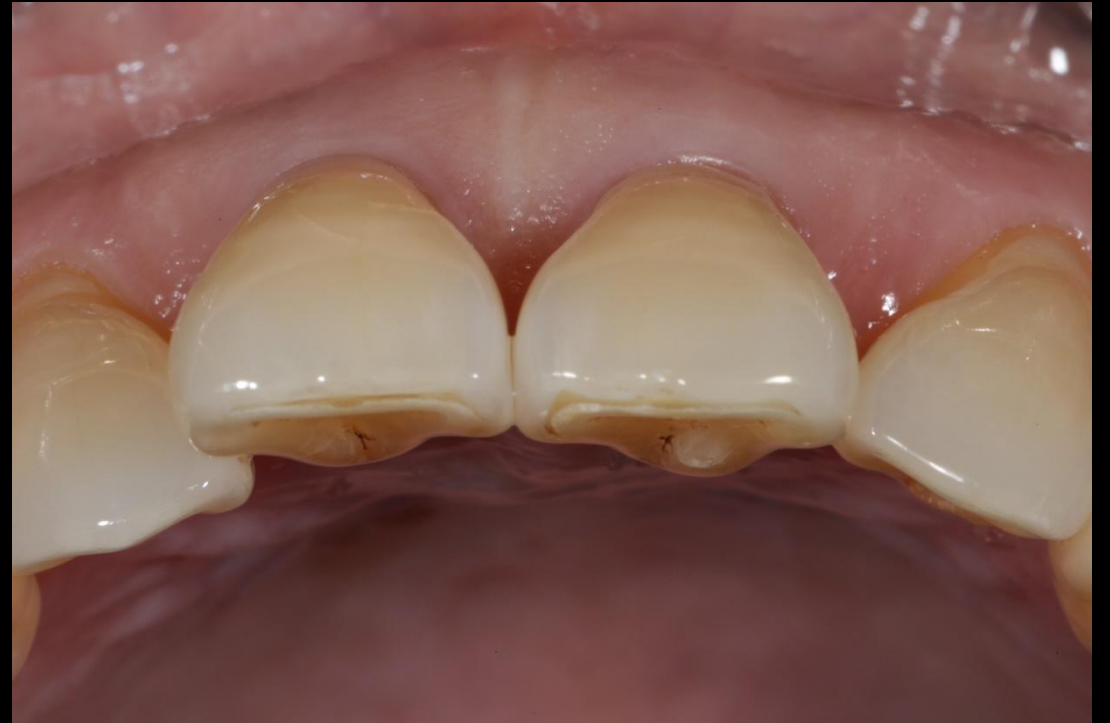
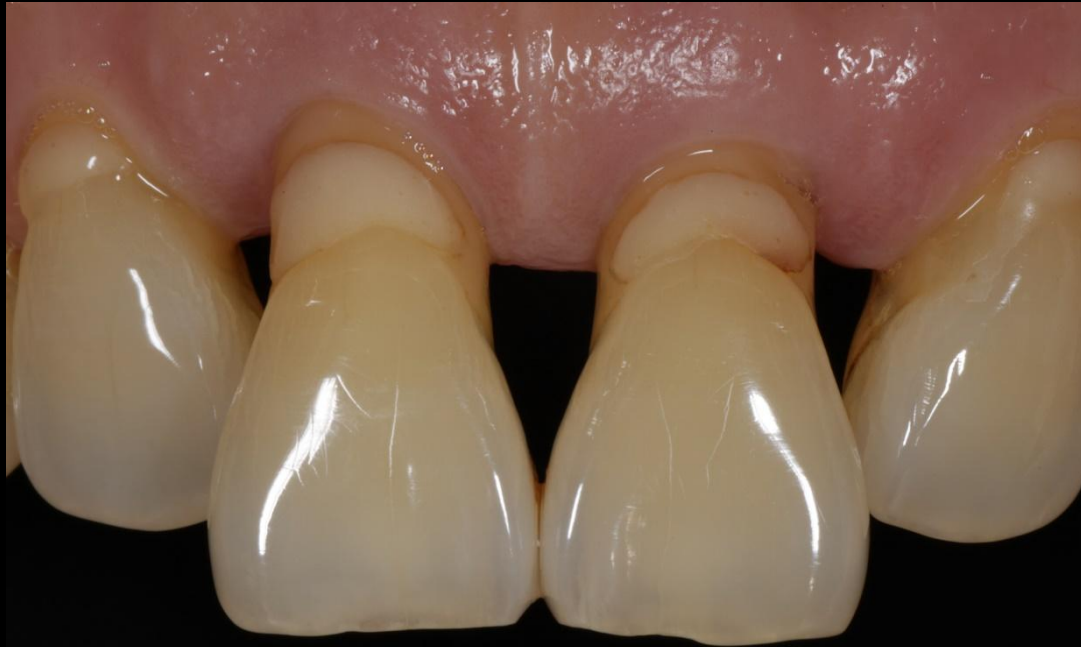
#21

Pre-op

## Previous Surgery

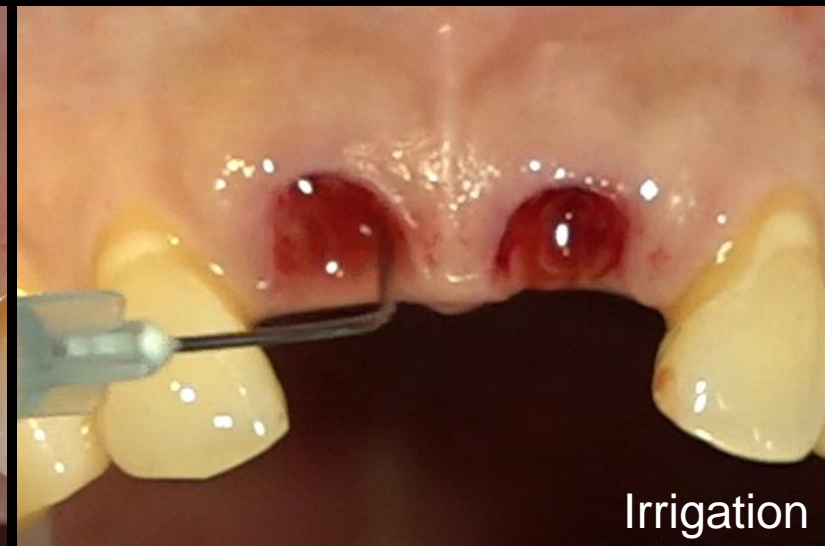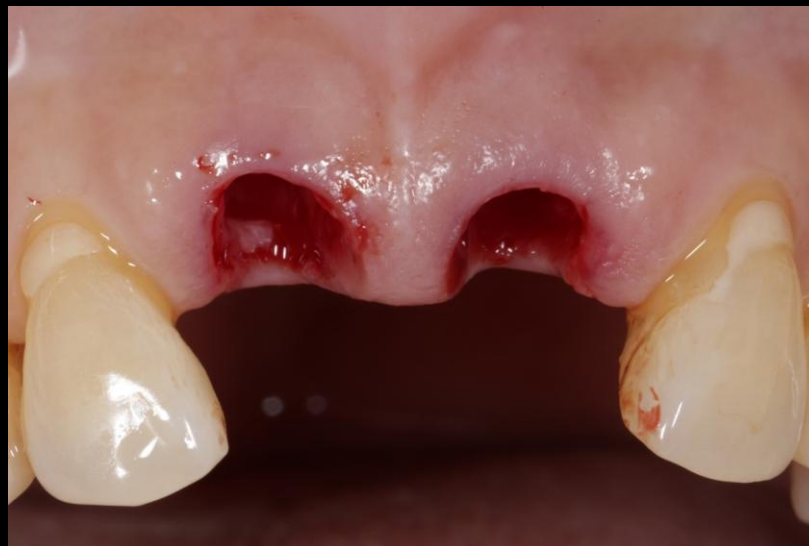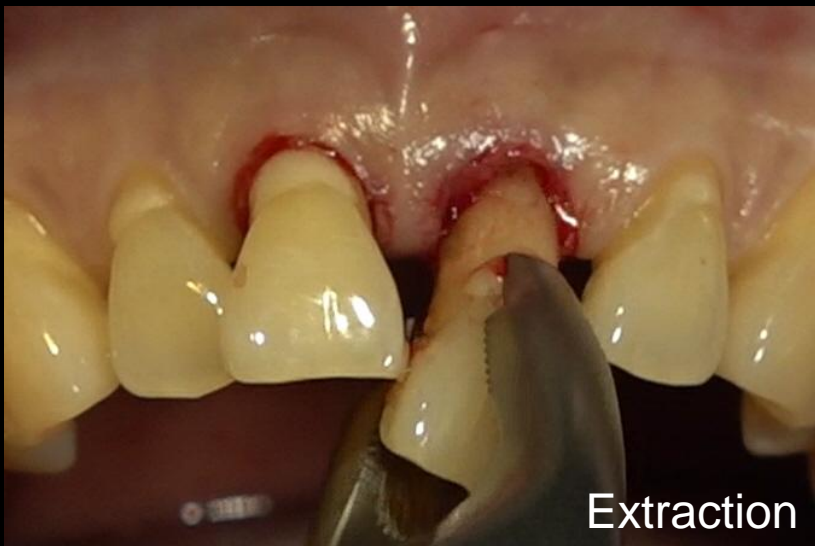Extraction and Bone graft at extraction socket



Pre-op

## Previous Surgery

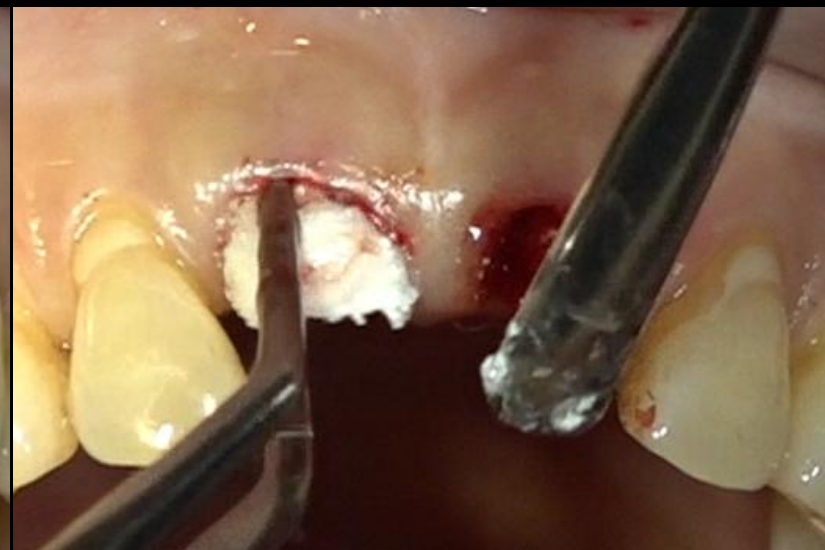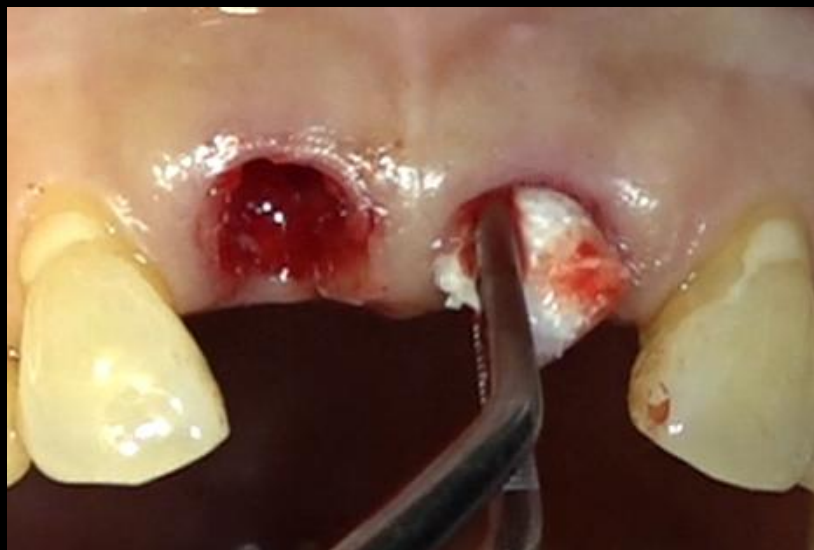## Extraction and Bone graft at extraction socket



Surgery

## Previous Surgery

Extraction and Bone graft at extraction socket

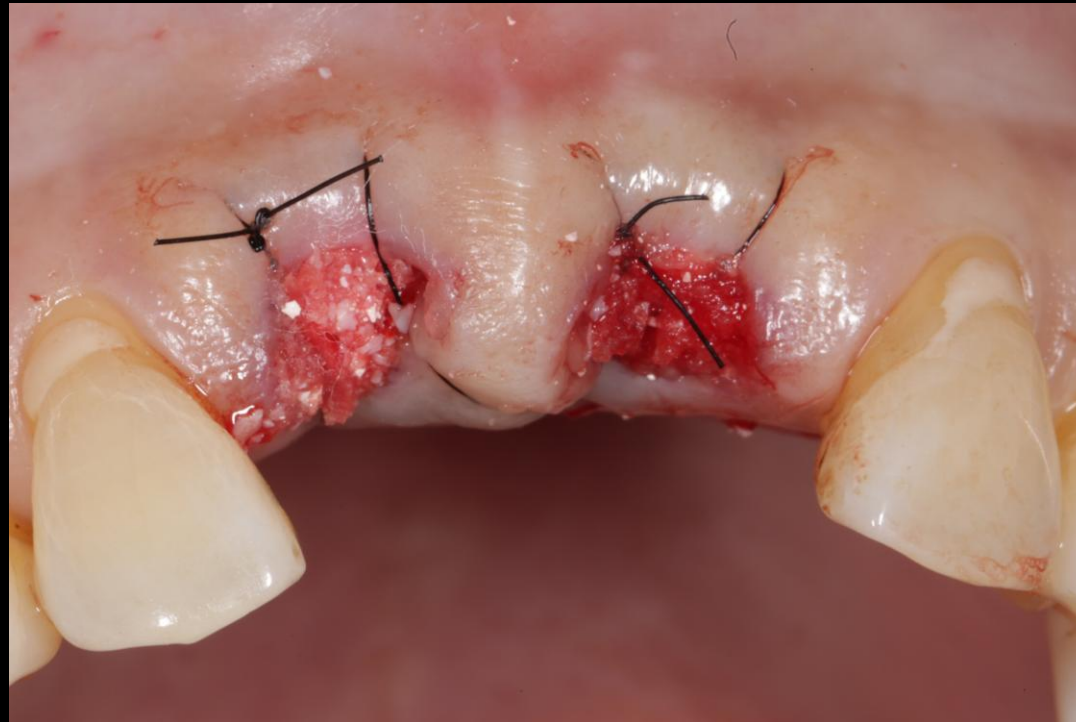


Surgery



## Previous Surgery

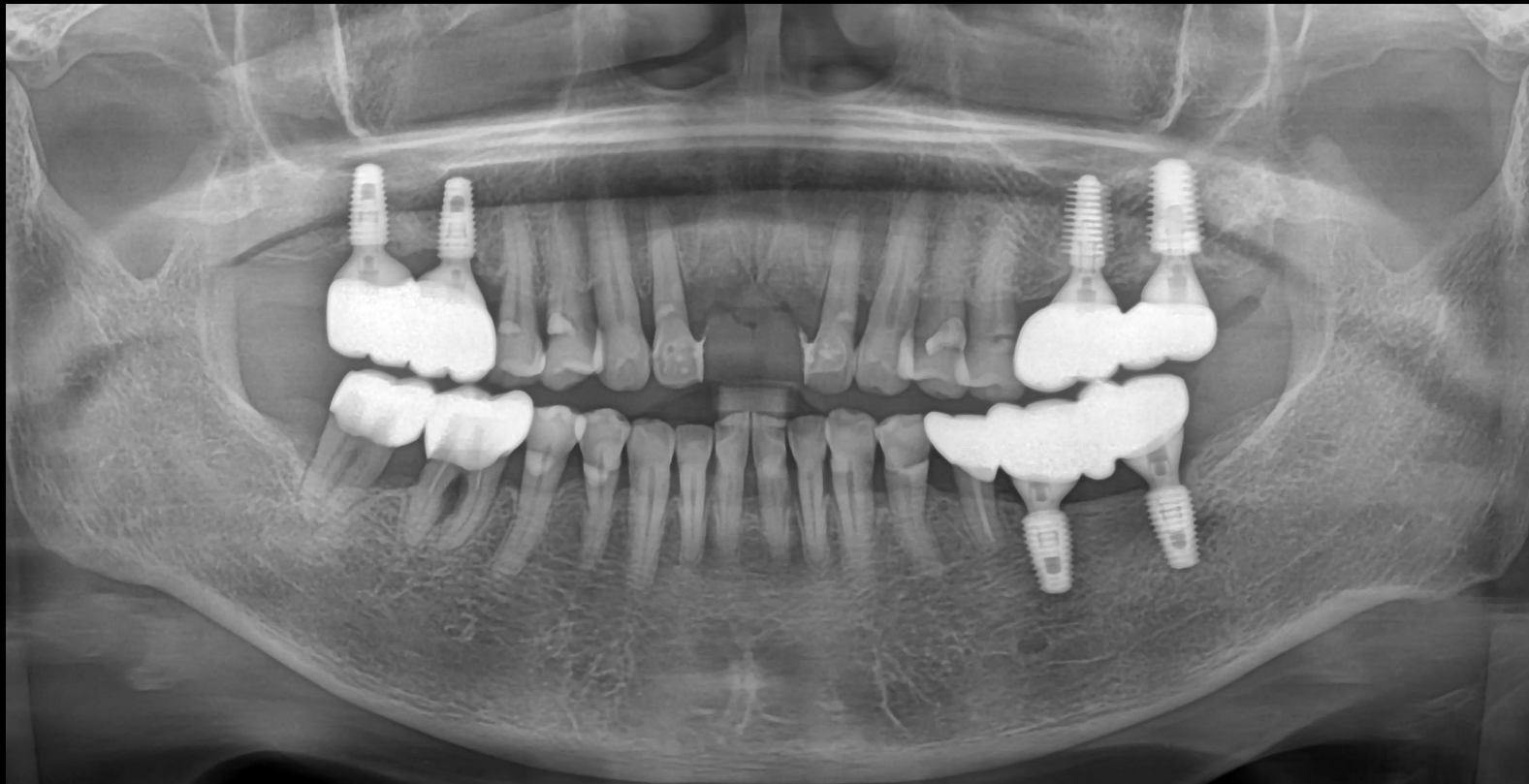
Extraction and Bone graft at extraction socket



Post-op

## Previous Surgery

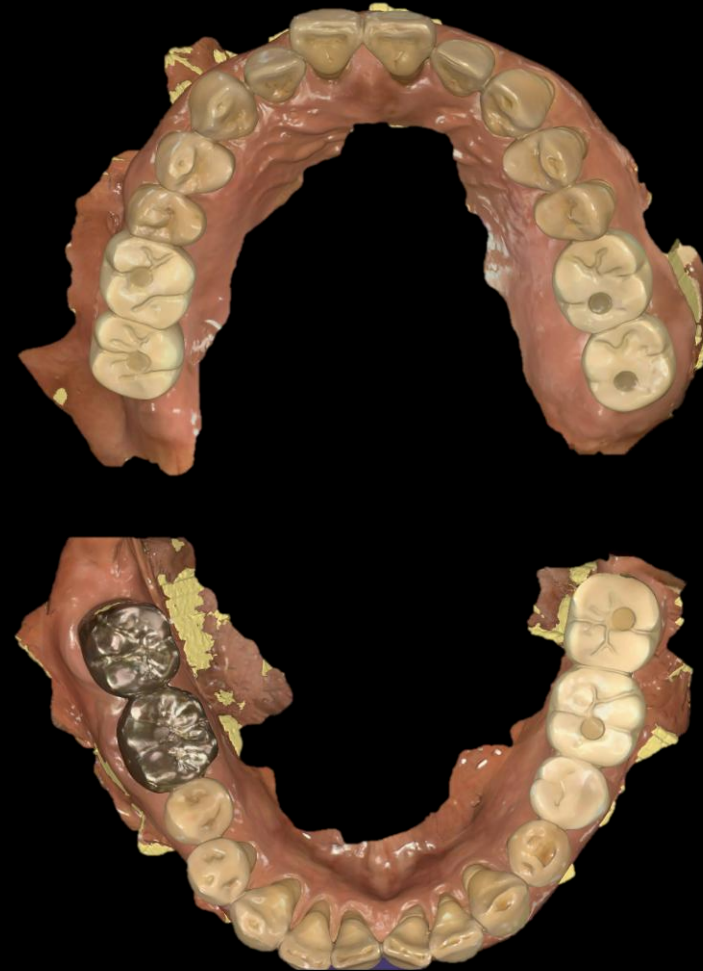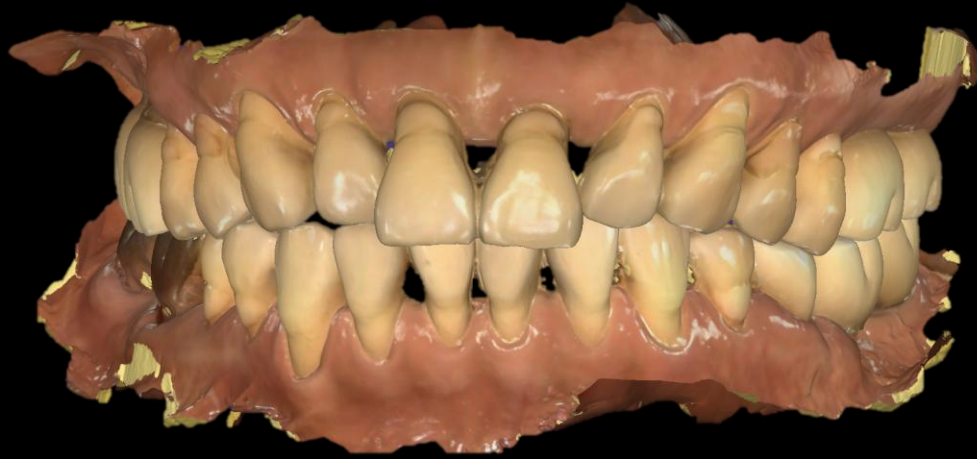Extraction and Bone graft at extraction socket



Post-op

## Previous Surgery

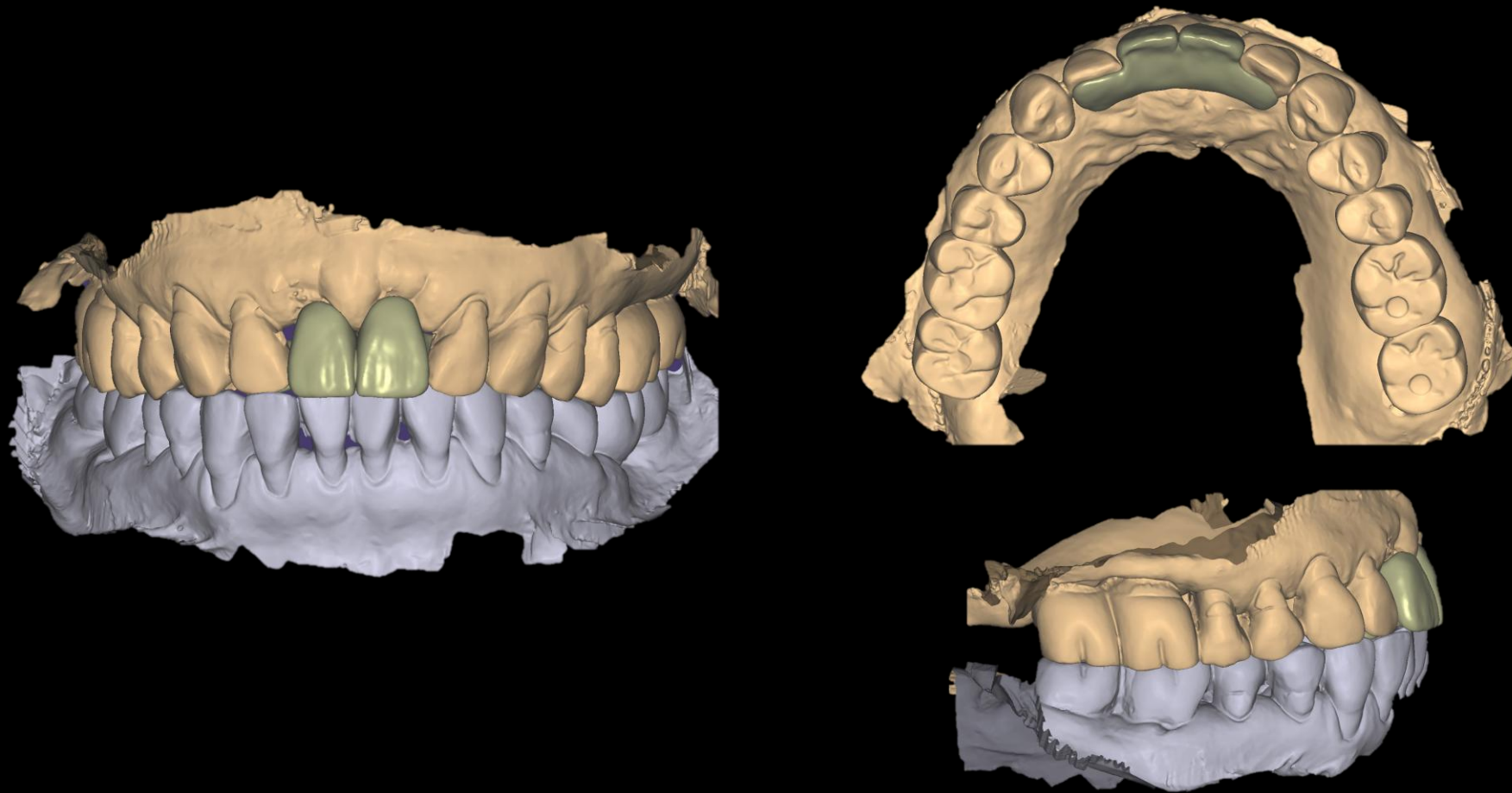
Extraction and Bone graft at extraction socket



IOS

## Previous Surgery

Extraction and Bone graft at extraction socket

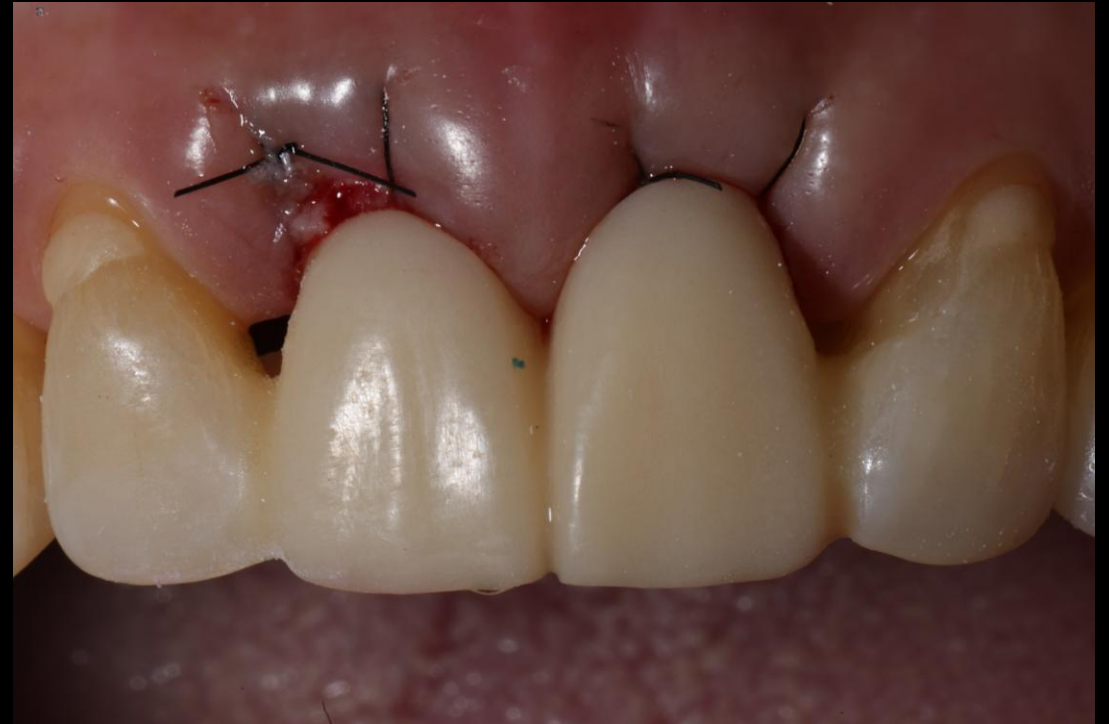
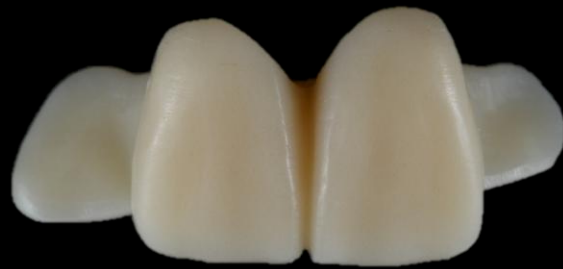
CAD (Temporary)



## Previous Surgery

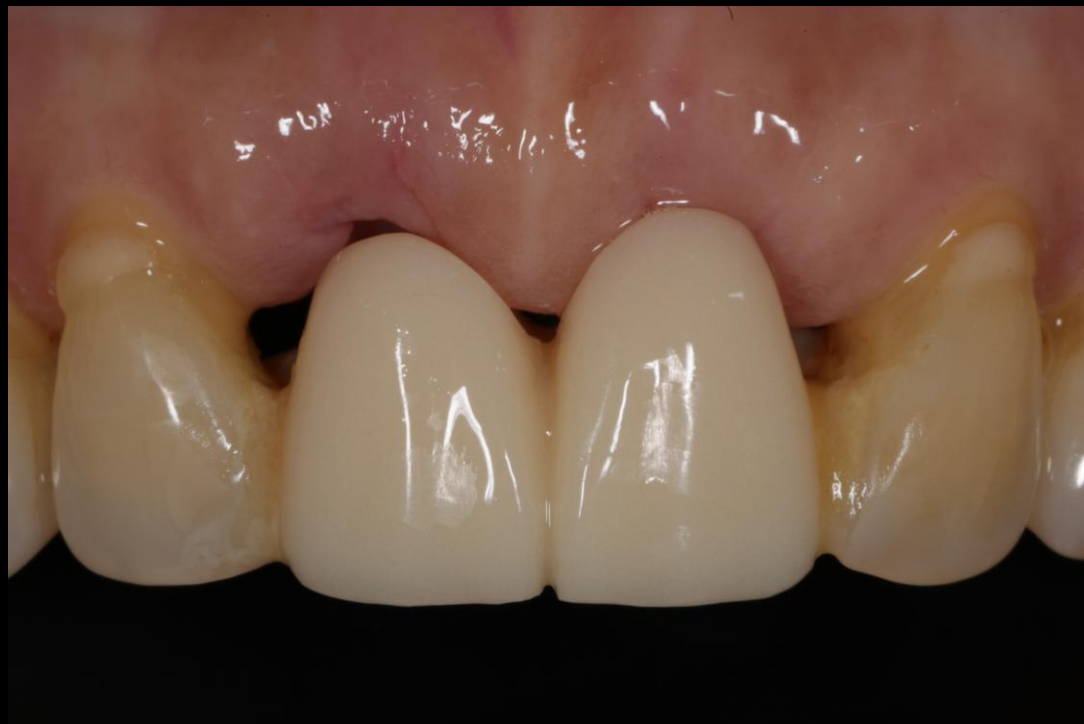Extraction and Bone graft at extraction socket



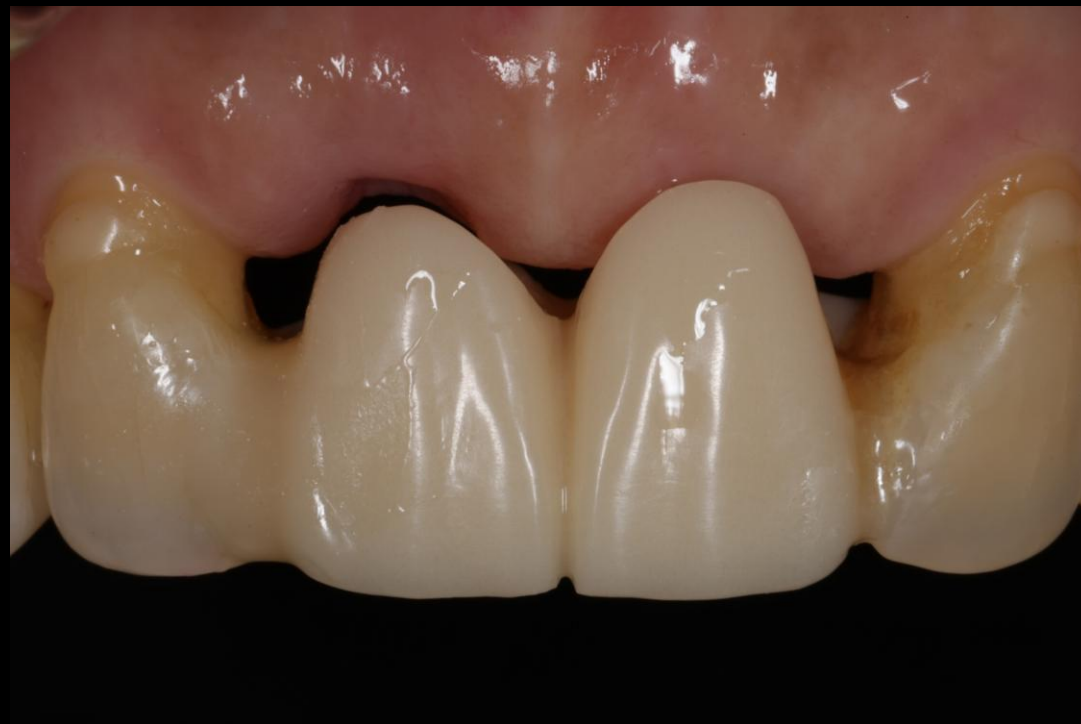Provisional restoration at same day

## Previous Surgery

Extraction and Bone graft at extraction socket



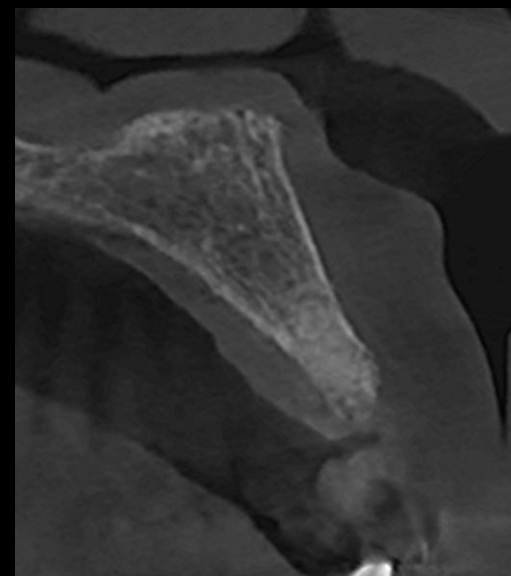
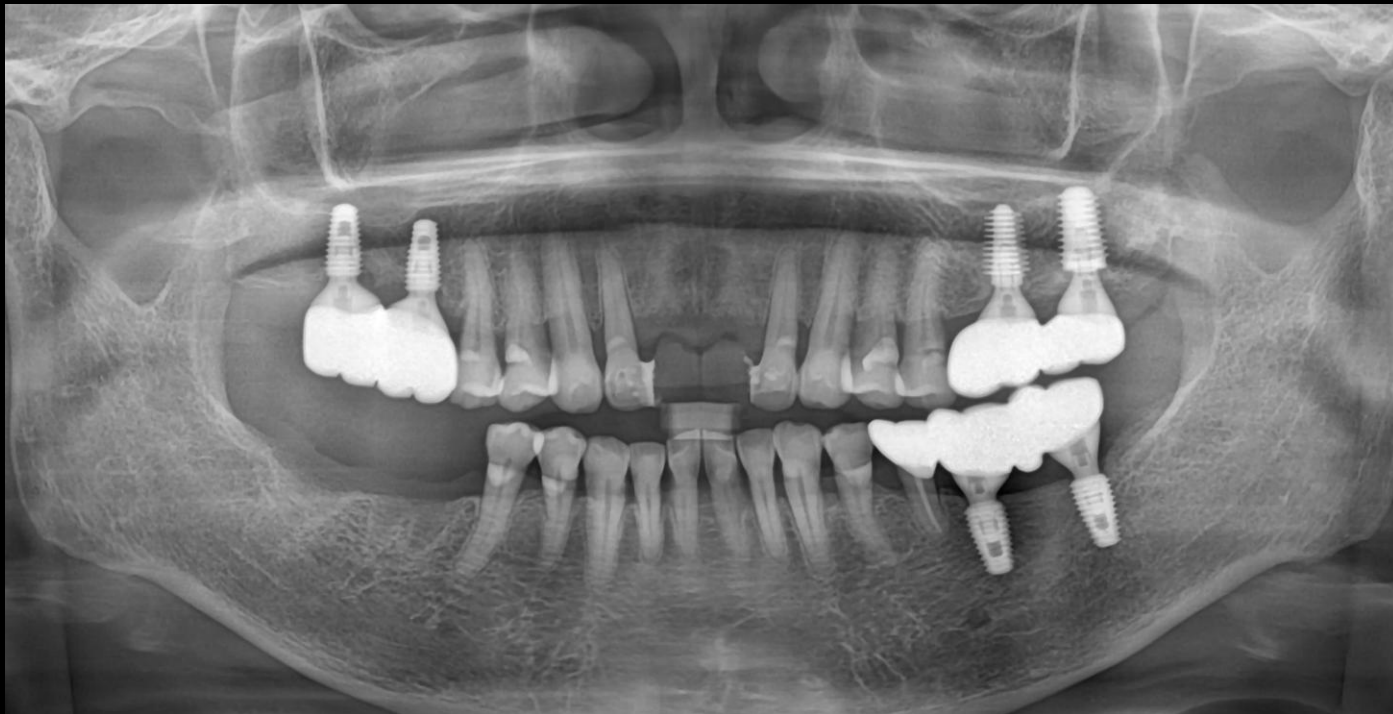
Healing 1 week



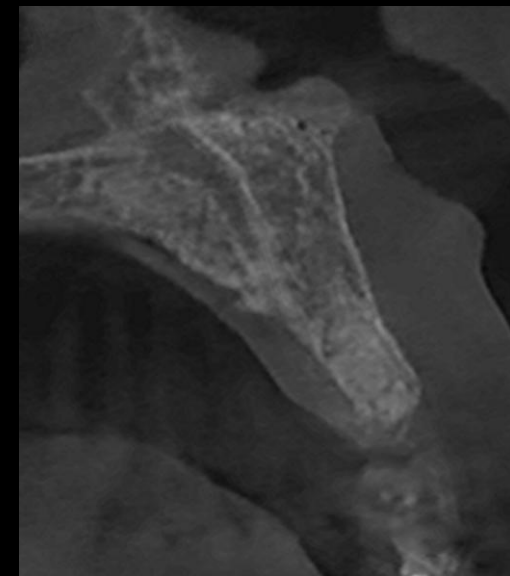
Healing 1 month

## Previous Surgery

Extraction and Bone graft at extraction socket



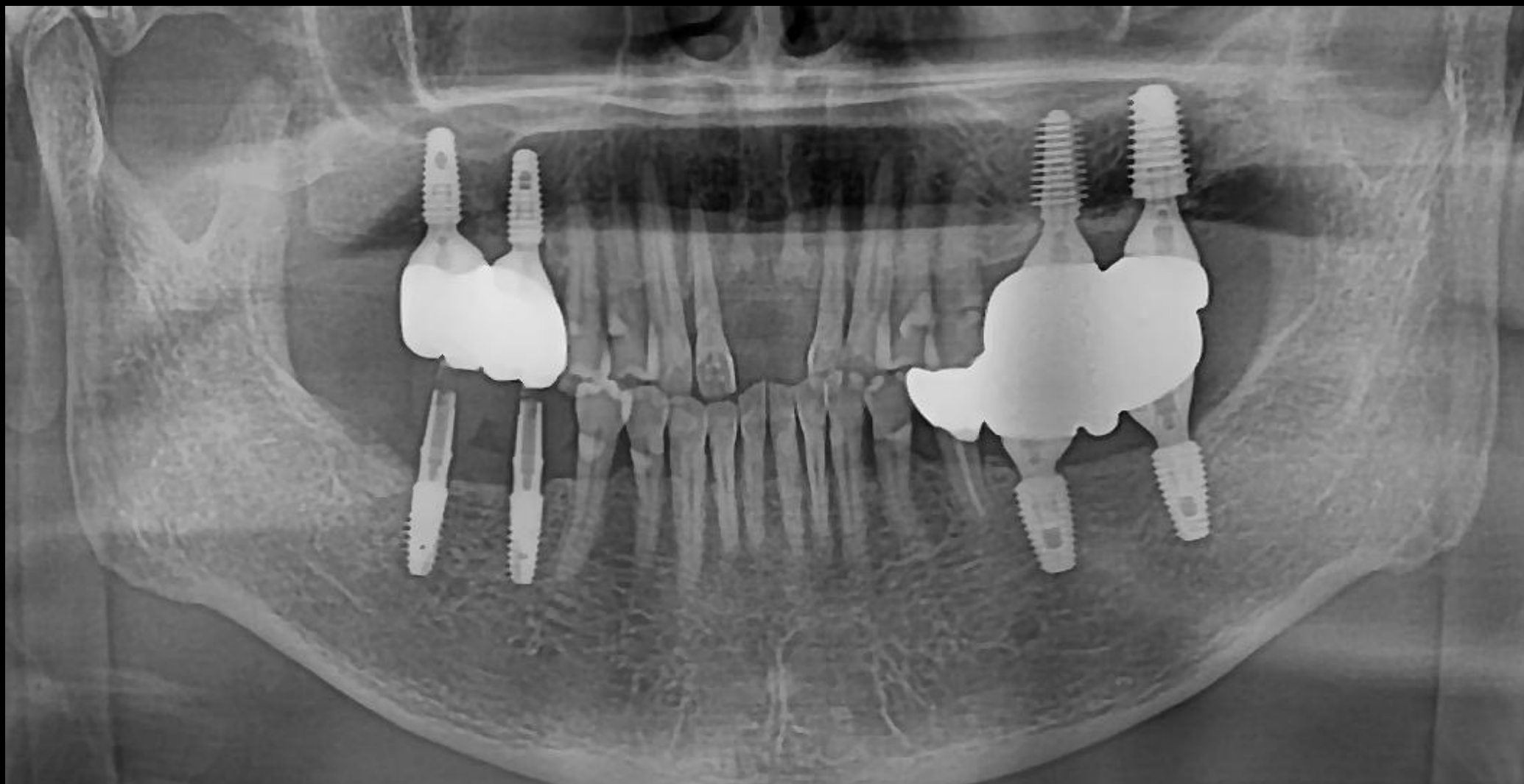
#11



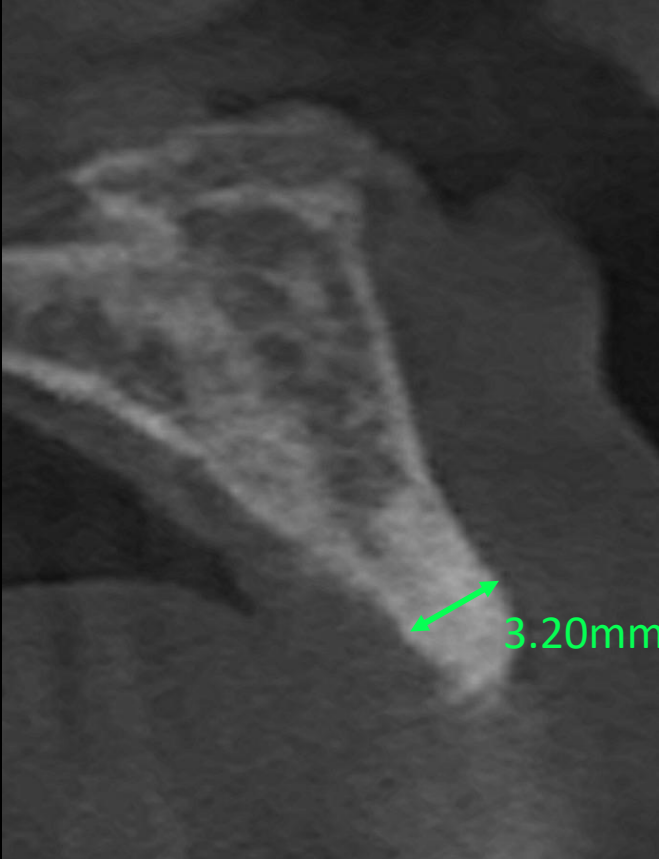
#21

Healing 3 months

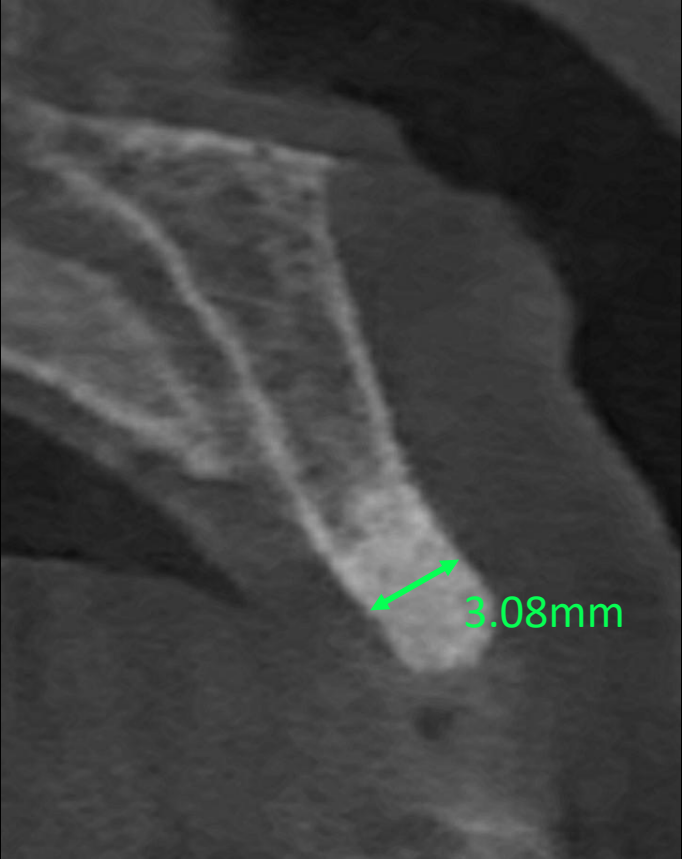
Pre-op







#11

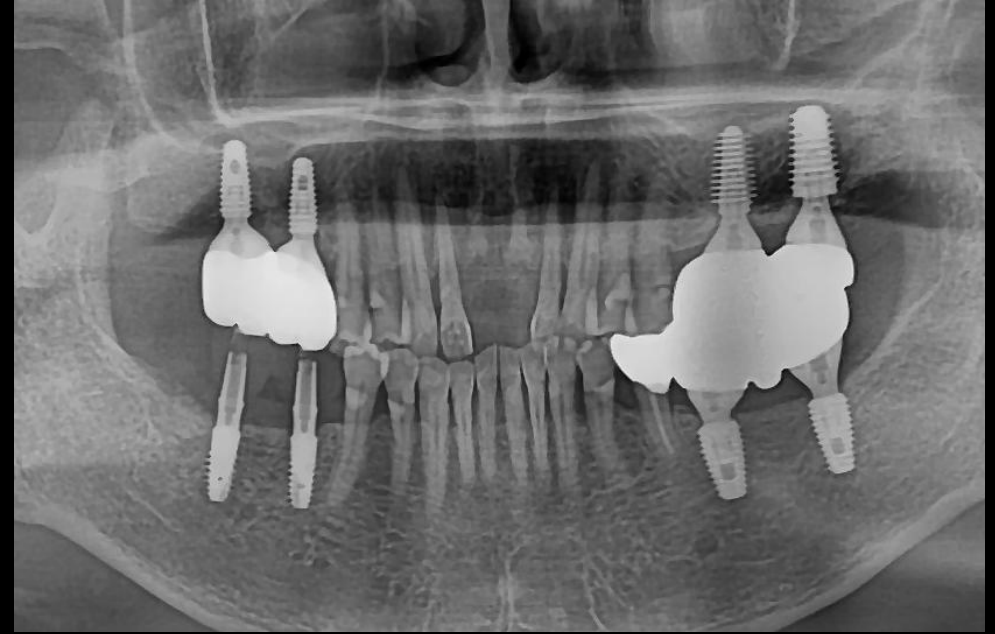


#21

Pre-op



## Surgery Plan (#11,21)



- Implantation on #11, 21 using **bright Tissue Level 3.0**
- Flapless implantation with **Pin Guide**

